



Subsurgery Mini-OSCE

020 & 019 collection

**Collected by:
Shahed Atiyat**

Links of another past papers and useful summaries :)

Ophthalmology

Summaries

https://doctor2020.jumedicine.com/wp-content/uploads/sites/12/2024/07/Ophthalmo-summary_Shahed.pdf

<https://doctor2020.jumedicine.com/wp-content/uploads/sites/12/2024/07/Summary.pdf.pdf>

<https://doctor2020.jumedicine.com/wp-content/uploads/sites/12/2024/07/ophthalmology-mini-osce-1.pdf>

Past papers

<https://doctor2019.jumedicine.com/wp-content/uploads/sites/10/2023/07/UROLOGYOPHTHALMO-MINIOSCE.pdf>

<https://drive.google.com/drive/folders/14OMfivNLDfFyZPbrKC4K6gmf1H2Eg3gR>

ENT

Summaries

https://drive.google.com/file/d/14ao2ZWuzxY_ePAy-AQFU7l6EkF_AcePS/view?usp=drivesdk

Past papers

<https://doctor2018.jumedicine.com/wp-content/uploads/sites/9/2022/06/ENT-Summary-.pdf>

https://drive.google.com/drive/folders/1bcEUQYh-SxqHo436us4Kd_bgc3KTRGC6

Neurosurgery

Past papers

<https://doctor2020.jumedicine.com/wp-content/uploads/sites/12/2024/07/Pastpaper-1-1.pdf.pdf>

<https://doctor2020.jumedicine.com/wp-content/uploads/sites/12/2024/07/Mini-OSCE-1.pdf>

<https://doctor2020.jumedicine.com/wp-content/uploads/sites/12/2024/07/Neurosurgery-summary.pdf.pdf>

<https://doctor2020.jumedicine.com/wp-content/uploads/sites/12/2024/07/MiniOSCE-017.pdf.pdf>

Urology

Past papers

<https://doctor2020.jumedicine.com/wp-content/uploads/sites/12/2024/07/Mini-OSCE-018.pdf>

020 Mini-OSCEs

Special thanks to 🙌

1st rotation:

Heba Aburumman

Saif Abdulsalam

Jana Alkalili

2nd rotation:

Salah Mustafa

Afnan Edwan

Laith Sami

3rd rotation:

Shahed Atiyat

Roaa Jaber

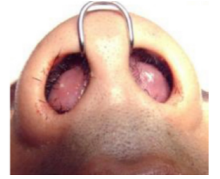Rania Tayseer

First rotation (MCQ)

ENT

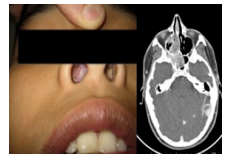
Q1: Patient presented to the clinic complaining of swelling in his nose, according to the picture, what is the best management to do?

Answer: Incision and drainage



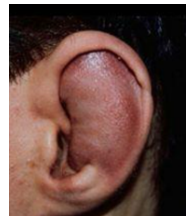Q2: A 15-year-old boy presents with a few months history of recurrent epistaxis, what is the investigation of choice in this case?

Answer: Angiography



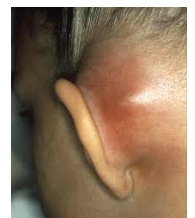Q3: According to this picture, the best management is:

Answer: Incision and drainage and topical antibiotics



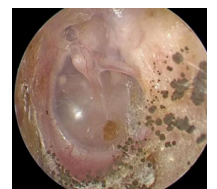Q4: An 8-months baby with fever, what is the next step?

Answer: Admission



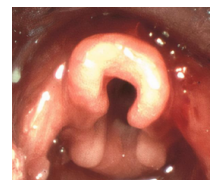
Q5: Patient with continuous otorrhea, dose not improve after antibiotics uses, management?

Answer: Stop antibiotics and start topical anti-fungal agent for 3 weeks



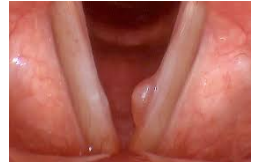Q6: 3-month baby with stridor and feeding well, management?

Answer: Supraglottoplasty?



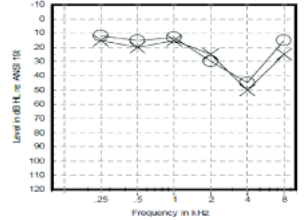
Q7: Management of vocal cord polyp?

Answer: Surgery



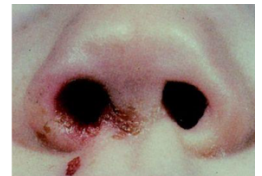Q8: Management of noise-induced hearing loss.

Answer: High dose steroid



Q9: A 27-year-old presented with a 3-month history of right nostril discharge, what is the cause?

Answer: Intranasal foreign body



Urology

Q1: Which of the following does not have laser ablation as a part of management?

Answer: Testicular tumor

Q2: X- ray imaging showing DJ catheter.

Q3: Lady with 12 mm obstructed stone in the right ureter (proximal), management to do?

Q4: Elderly patient with intermittent painless hematuria, ddx?

Answer: Transitional cell carcinoma of urinary tract?

Q5: Causes of terminal hematuria.

Answer: Bladder neck and prostate inflammation

Q6: Injury to which nerve during pelvic surgery, the nerve is responsible for thigh adduction.

Answer: Obturator nerve

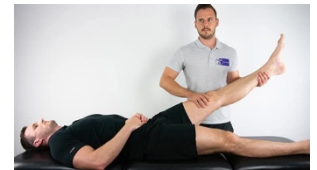Neurosurgery

Q1: According to this picture, what is the diagnosis?

Answer: myleomeningocele

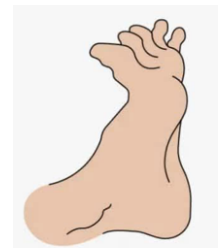
Q2: Name of this test?

Answer: straight leg raise test



Q3: Female with radiculopathy signs, with this presentation when examining reflex, what to do next?

Answer: Laminectomy




Ophthalmology

Q1: Earliest sign of diabetic retinopathy?

Answer: Microaneurysms

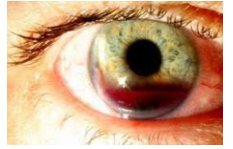
Q2: Not correct about this device.

- A. least accurate (answer)
- B. It uses fluorescence dye
- C. It uses blue cobalt light
- D. It is not necessary for dx of glaucoma



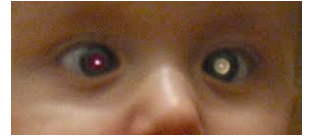Q3: Patient presented to ER with this... what you see?

Answer: hyphema



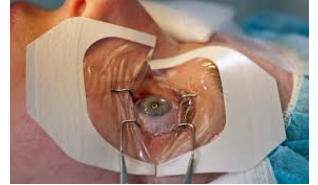Q4: All of the following may cause this sign except.

Answer: hypermetropia



Q5: Not a contraindication of LASIK.

Answer: Makeup :)



Second rotation

Collected by: Salah Mustafa, Afnan Edwan & Laith Sami

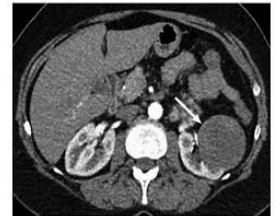
Urology

Q1: Hx of sudden testicular pain

- What's your diagnosis? Testicular torsion
- How do you confirm your diagnosis? Surgical exploration
- How do you treat? Detorsion and orchidopexy plus fixation of the contralateral testicle

Q2: Abdominal axial MRI with contrast showing enhancement of a mass in the kidney, size of the mass was 3 cm.

- What is your diagnosis? Renal cell carcinoma
- What is your management? Partial nephrectomy
- What is the scoring system for renal masses? Bosniak score

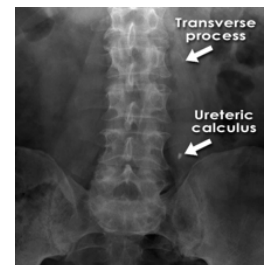


Q3: Name 2 irritative and 1 obstructive symptom of BPH

- Obstructive: hesitancy, post void dribbling, straining while urinating
- Irritative: frequency, nocturia, urgency

Q4: KUB Xray showing a right ureteral stone

- Name 2 ways to relieve the obstruction? Double J insertion/
Tube nephrostomy



Q5: Write the correct diagnosis for each definition:

- Gas within the renal parenchyma → emphysematous pyelonephritis
- Lipid laden macrophages → Xanthogranulomatous pyelonephritis
- Pus and destruction of the renal parenchyma → pyonephrosis

Q6: Pediatric patient with scrotal swelling and positive transillumination test

- What is your diagnosis? Hydrocele
- Name 2 other causes of hemi-scrotal swelling? Hematocele, testicular torsion, varicocele, testicular CA

Q7: Hx of a patient with grade 4 renal trauma

- What is your management? Bed rest and conservative treatment
- Name 2 late complications: urinoma/abscess/av fistula

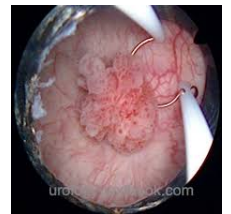
Q8: Image of swollen scrotum and “a bag of worms”

- What is your diagnosis? Varicocele
- Name 1 indication for surgery other than infertility? Severe pain



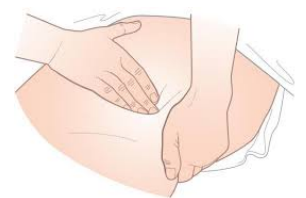Q9: Image of ureteroscopy showing bladder CA

- What's your next step? TURBT to obtain a biopsy
- Name 2 histological types? Urothelial (transitional) and squamous cell carcinoma



Q10: Name 3 physical examinations we can do on the kidney:

1. Bimanual kidney examination
2. Ballotment kidney exam
3. Costovertebral angle tenderness



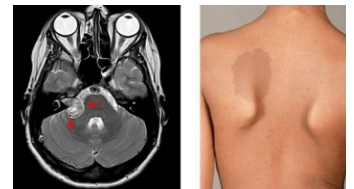
Neurosurgery

Q1: Sagittal spinal MRI T1 sequence with contrast showing intradural extramedullary mass

- Describe what you see (you have to describe the MRI first before saying the findings)
- Give 3 differentials: meningioma/neurofibroma/schwannoma

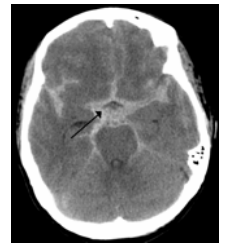Q2: Patient presenting with progressive hearing loss and this rash on his back

- What is your diagnosis of the tumor? Vestibular schwannoma
- Name of skin finding? café au lait spot



Q3: Axial CT without contrast, showing subarachnoid hemorrhage

- What is your diagnosis? subarachnoid hemorrhage
- What is the grading system used based on the Glasgow coma scale? WFNS grading system

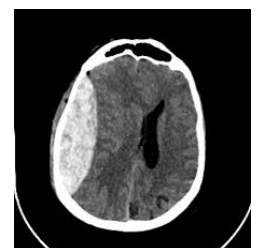

Q4: Sagittal MRI of the lumbosacral region T2 sequence, showing disc herniation at level L5-S1. Patient is complaining of pain in his big toe

- Describe the finding
- Which nerve root is affected? L5

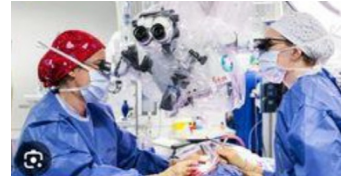Q5: Axial CT without contrast showing epidural hemorrhage. Patient eye opens to pain, patient is not oriented to place or time, and localizes to pain

- Describe the finding
- What is his GCS? 11/15



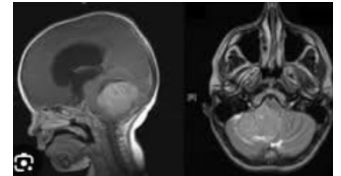
Q6: This image ...

- What is the name of the device being used? Microscope
- Name 2 surgical uses: ACDF/ brain aneurysms?



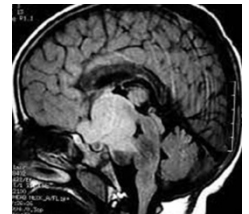
Q7: Sagittal brain MRI of a 9-year-old showing a posterior fossa tumor

- What is your diagnosis? Medulloblastoma
- What is the peak age of this tumor? 5 years old?



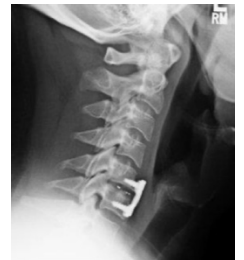Q8: Sagittal MRI showing a suprasellar mass with symptoms of decreased libido and gynecomastia

- What is your diagnosis? Pituitary adenoma
- Treatment: Intranasal trans sphenoidal resection



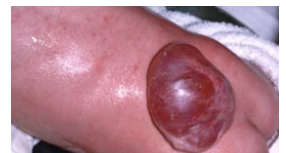Q9: A similar image to this ...

- What is the name of the procedure done? Anterior cervical discectomy and fusion (ACDF)
- At what level was the cage placed? C6-C7
- Name one complication of this surgery? Dysphagia



Q10: Image of a pediatric patient with myelomeningocele

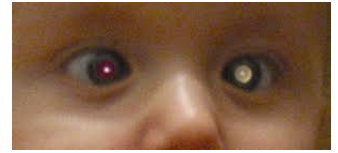- What is your diagnosis
- What is the outcome of neurologic deficits if this defect was corrected? Neurologic deficits won't improve but we will reduce risk of infection



Ophthalmology

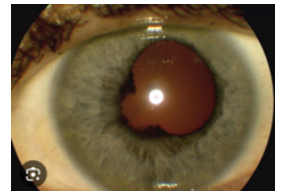Q1: Name 2 causes for this finding besides cataract?

Retinoblastoma/congenital glaucoma



Q2: A case of a patient with suspected ankylosing spondylitis, with this ocular finding?

- Name of the finding? Posterior synechia/iritis?
- Name 2 systemic investigations you would do to confirm your suspected diagnosis? HLA-B27 and ESR/CRP

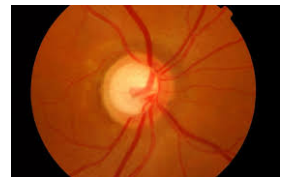


Q3: Patient with graves' disease and picture of their left eye is pulled downward. Which muscle is involved?

Inferior rectus

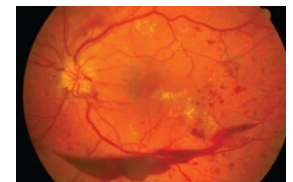
Q4: Name 3 tests to diagnose/exclude glaucoma:

Tonometry, gonioscopy, visual field examination, optic nerve head imaging



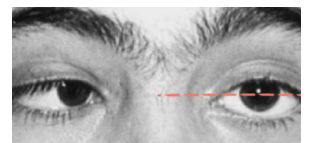
Q5: Patient with longstanding DM, complaining of decreased vision...

- Name 3 findings? Vitreous hemorrhage, neovascularization, cotton wool spots
- What is your diagnosis? Proliferative diabetic retinopathy
- What is the cause of visual loss? Tractional retinal detachment



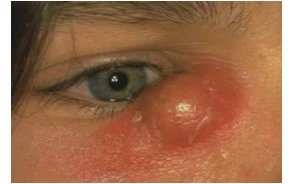
Q6: Name 2 causes for this finding other than trauma?

Cavernous sinus thrombosis/ Compressing aneurysm/Brain herniation



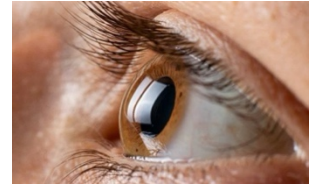Q7: What is the most common cause of this finding?

Staphylococcus aureus




Q8: This image ...

- Whats your diagnosis? Keratoconus
- How do you confirm your diagnosis? Surface corneal tomography
- 2 modalities of treatment? Corneal grafting/cross linking procedure



Q9: This image ...

- Whats your diagnosis? Ectopia lentis
- Name 2 causes? Marfan syndrome/Trauma



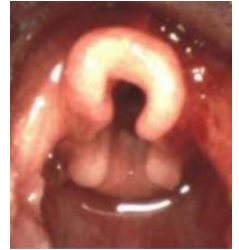Q10: I can't find a similar picture. The question wanted the diagnosis?

Its either bacterial keratitis or nasolacrimal duct obstruction

ENT

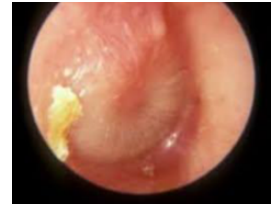Q1: Pediatric patient complaining of stridor has this finding

- Whats the diagnosis? Laryngomalacia
- Medical management? PPI
- Surgical management? Supraglottoplasty



Q2: A similar image to this ...

- Whats the diagnosis? Acute otitis media
- Treatment? Oral amoxicillin for 5-7 days
- Which ear this? (in the exam it was a left ear)

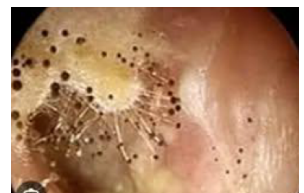

Q3: Image of a perforated septum

- Whats your diagnosis
- Name 2 causes? Trauma/untreated septal hematoma/cocaine sniffing/wegners granulomatosis
- Management? Conservative management and lubrication initially, if it fails, we can do septoplasty

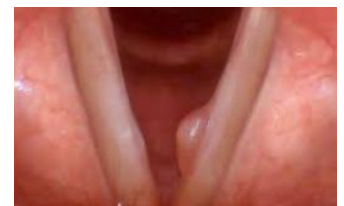Q4: This image

- Whats the diagnosis? Otomycosis- aspergillus
- Management and duration? Antifungals for 3 weeks duration



Q5: A smoker, complaining of hoarseness of voice was found to have this cyst on laryngoscopy

- What is your diagnosis? Laryngeal cyst
- Medical management? Voice rest/smoking cessation
- Surgical management? Surgical excision

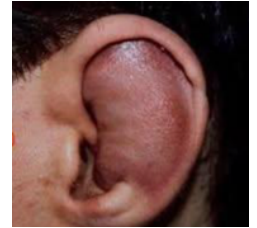

Q6: Hx of a 15-year-old male with recurrent epistaxis

- What is your diagnosis? Juvenile nasopharyngeal angiofibroma
- How do you confirm it? CT angiography
- Treatment? Complete surgical excision

Q7: Hx of a boxer presents with this ear

- Name the complication? Cauliflower ear
- Treatment? Surgical incision and treatment

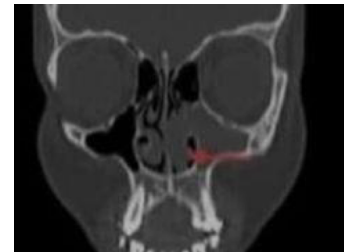


Q8: Picture of cholesteatoma

- What is the diagnosis
- Treatment? Surgical excision+tympanoplasty+mastoidectomy

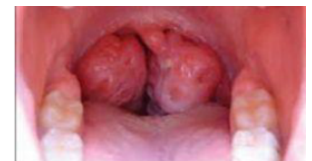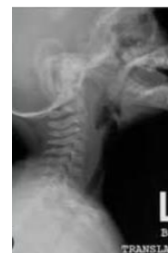Q9: The following image

- What is the diagnosis? Antrochoanal polyp
- Treatment? Medical treatment is nasal corticosteroid and nasal decongestants if failed then surgical excision



Q10: Pediatric patient complaining of daytime sleepiness (NOT very sure of the answers)

- What is your diagnosis? Adenoid hypertrophy?
- How do you confirm? Lateral Xray
- Treatment? Adenoidectomy

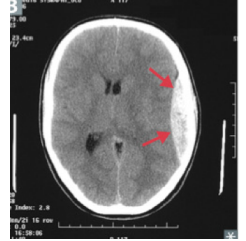


Third rotation

Neurosurgery

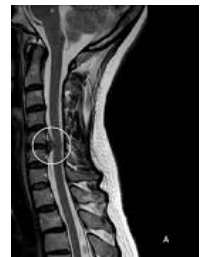Q1: Case of head trauma, the patient open eye for painful stimulus, take inappropriate words and flex his arms in response to pain...

- Describe what you see in this image? Axial CT scan shows left fronto-parietal biconvex hyperdense lesion (acute epidural hemorrhage).
- Calculate GCS?
- What is the type of this head injury?



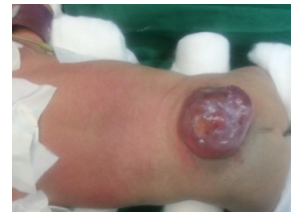Q2: Case of cervical disc herniation, the patient experiences a painful electrical sensation that travels from the neck down to the spine when the patient flex's the neck (not the exact picture of exam)

- Describe the image and what the findings?
- What is the name of that sign? Lhermitte's sign
- Management/ the name of the surgery? ACDF



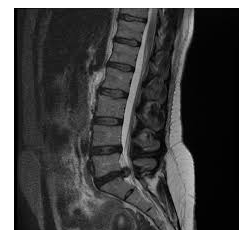Q3: The patient complained of this and hydrocephalus...

- The name of this syndrome? Chiari malformations 2
- The incidence of hydrocephalus in this syndrome? 85-90%



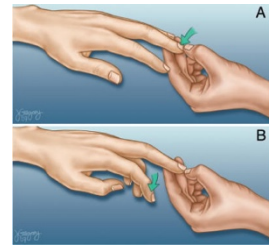
Q4: Lumbosacral MRI (sagittal and axial) showing disc prolapse at L5-S1

- Describe both images?
- Important reflex that may be affected? Achilles tendon reflex
- Which dermatome? S1



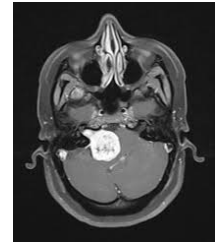
Q5: This image ...

- The name of the test? Hoffman test
- What it's clinical significance if it's positive? Indicates UMN disease



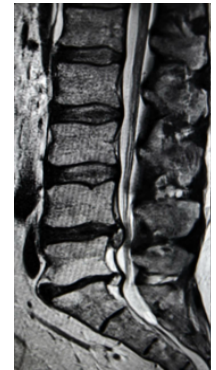
Q6: This image and the patient have a hearing loss, tinnitus, ...

- What is the diagnosis? Vestibular Schwannoma
- Write another ddx? Dermoid cyst
- Other two symptoms? Vertigo and balance problems, headache



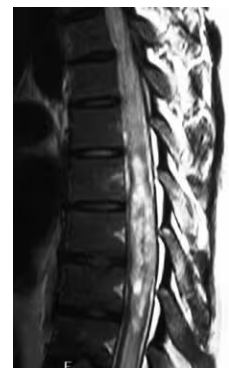Q7: Image of lumbar disc prolapse...

- What is the most common site of disc herniation? L5-S1
- Name of the surgery? Discectomy



Q8: Something like this image ...

- Describe the image? Sagittal spine MRI (I think it was T2) showing an intradural intramedullary hyper-intense lesion with heterogeneity in the cervico-lumbar area.
- The most likely diagnosis? Ependymoma



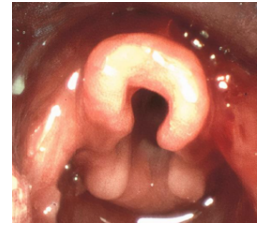
Q9: Patient with fixed dilated pupils, with CT scan ...

- What is the type of herniation? Uncal herniation

ENT

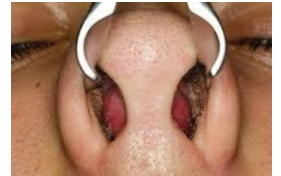Q1: An infant presented with (I forgot :). This is his fiber-optic laryngoscopy during the inspiratory phase.

- Three advices you will give for the parents?



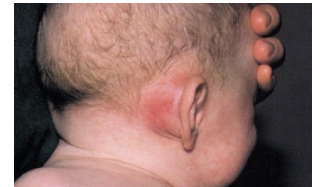Q2: This image ...

- What is the diagnosis? Bilateral septal hematoma
- Two complications? Infection with abscess formation; septal perforation.



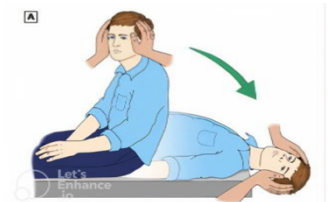Q3: This image, does not respond to oral antibiotics...

- Two lines of treatment?
 1. IV antibiotics + tympanostomy tube.
 2. Mastoidectomy in severe or refractory cases.



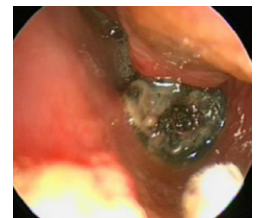Q4: This image...

- The name of the test? Dix hallpick test
- Which organ does it test? Semicircular canal



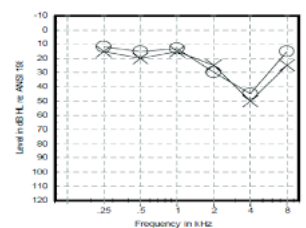
Q5: The patient presented with nostril discharge ...

- Diagnosis? Intranasal foreign body
- Management? Removal of foreign body



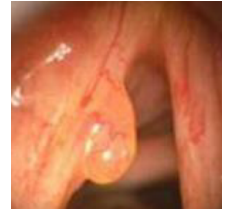Q6: Young female complains of tinnitus since 3 days ...

- What is the first line of management? Steroids
- If the first line failed what is the other line of management? Hearing aid or cochlear implant?



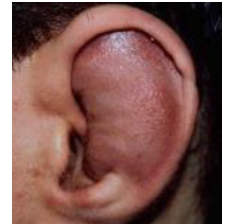
Q7: This image ...

- Three questions to the patient in the history? Smoking, Hx of GERD, voice abuse
- Three management.
 1. Voice rest
 2. Speech therapy?
 3. Surgical excision of the polyp



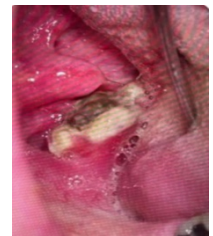Q8: This image ...

- Two lines of management?
 1. Incision and drainage
 2. IV antibiotics



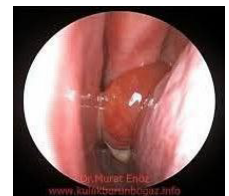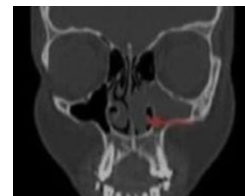Q9: This image...

- Diagnosis? Tonsillar cancer (SCC)
- First step in investigation? Biopsy and histopathology



Q10: This image...

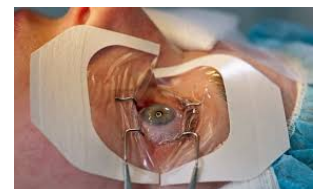- What is the diagnosis? Antrochoanal polyp
- Treatment? Medical treatment is nasal corticosteroid and nasal decongestants if failed then surgical excision



Ophthalmology

Q1: Write two contraindications for LASIK surgery?

Answer: keratoconus, severe dry eye syndrome, pregnancy

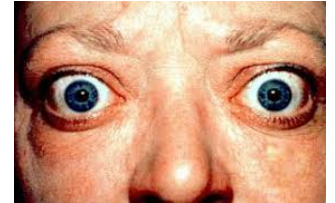

Q2: 5-year-old boy with eyeglass prescription form, the readings indicated hypermetropia (the Dx was written in the exam:), give two cases?

Answer: Physiological (small eyeball), lens dislocation

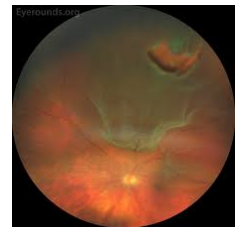Q3: Female complained of tearing and redness of the eye ...

- Diagnosis? Thyroid eye disease
- Two causes of blurry vision? Corneal ulceration, compressive optic neuropathy



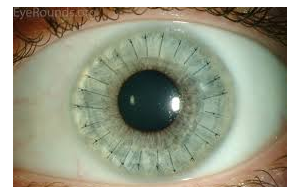Q4: This image...

- What is the type of this retinal detachment? Rhegmatogenous retinal detachment
- Write two symptoms? Floaters, scotoma, vision loss
- 3 lines of treatment?
 1. Vitrectomy
 2. Surgical repair
 3. Laser photocoagulation & anti-VEGF



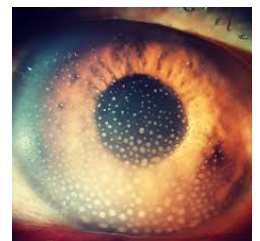Q5: This image ...

- The name of this surgery? Keratoplasty
- The most common complication? Rejection
- If it recognized early how you will treat? Steroids



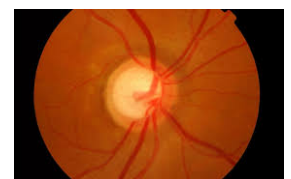
Q6: Patient with sarcoidosis and this image ...

- The name of this sign? Keratic Precipitates
- Three systemic test to confirm the diagnosis? Chest x-ray, serum ACE, serum calcium level



Q7: The patient diagnosed with glaucoma. Write 3 test to confirm it.

Answer: Tonometry, gonioscopy, visual field examination

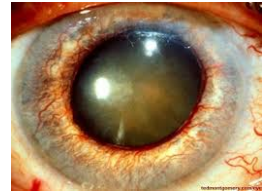

Q8: Complication of cataract surgery one day after surgery other than infection?

Answer: iris prolapse & macular edema

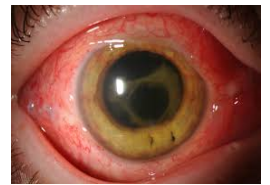Q9: This image...

- The name of this sign? Rubeosis Iridis
- Two causes? PDR, central retinal vein occlusion



Q10: Two cases of painful red eye other than conjunctivitis?

Answer: scleritis, bacterial keratitis



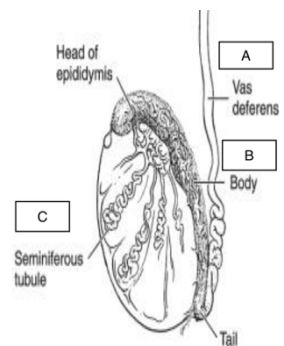
Urology

Q1: Radiological image of choice in each of the following:

- Kidney injury? CT- scan with IV contrast with delayed phase
- Bladder injury? Cystography (conventional or CT- cystography)
- Urethral injury? Retrograde urethrography

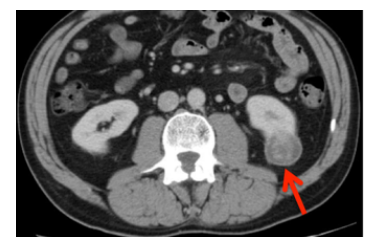Q2: Name A, B & C structures (this was the exact image in exam 😊)

- A: vas deferens
- B: body of epididymis
- C: seminiferous tubules



Q3: Write 3 examples of benign renal tumors.

Answer: Angiomyolipoma, Oncocytoma, Hemangiomas



Q4: Write the medical term for each of the following.

- Difficultly in the initiation of urination? Hesitancy
- Involuntary leak of urine of fall bladder in BPH patient? Overflow incontinence
- Multiple times of urination during night? Nocturia

Q5: Case of male infertility ...

- Best initial test? I think semen analysis
- The most common treatable cause of infertility? varicocele
- Which hormone is responsible for spermatogenesis? FSH

Q6: Write three main markers of testicular cancer.

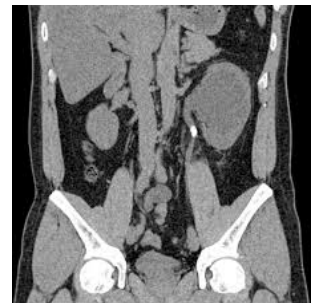Answer: AFP, Beta-HCG, LDH

Q7: Patient with prostate cancer ...

- What is the marker for prostate cancer? PSA
- What is the best image to do? Mp-MRI
- If it was localized what the best surgery to do? Radical prostatectomy

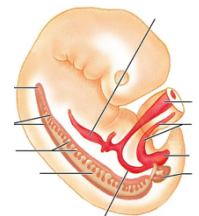
Q8: The patient has a flank pain and this is the CT

- What is the diagnosis? Upper uretric stone
- Write two modalities to relieve the pressure on kidney? DJ catheter insertion and nephrostomy



Q9: Write the three embryological developmental stages of kidney (in order)

1. Pronephrones
2. Metanephrones
3. Mesonephrones



Q10: write three inguinal canal content you will see in the surgery?

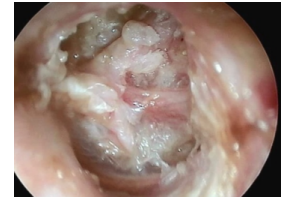Answer: Vas deferense, Testicular artery, Pampiniform plexus

019 Mini-OSCEs

ENT

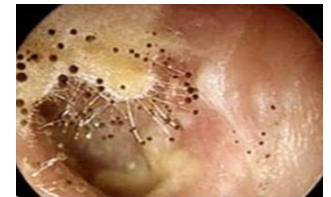Q1: A patient presented to the clinic complaining of ear discharge that is foul smelling.

1. Diagnosis? Cholesteatoma
2. Hearing status? Conductive hearing loss
3. Treatment? Surgical excision, mastoidectomy & tympanoplasty



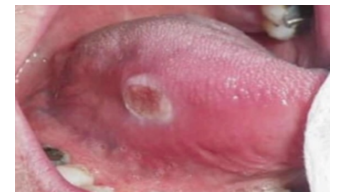Q2: A patient with a history of ear itching.

1. Diagnosis? Otomycosis
2. Treatment? Topical anti fungal and aural toilet



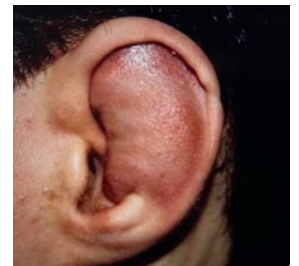Q3: This image ...

1. Diagnosis? SCC
2. Treatment? Excision & radiotherapy



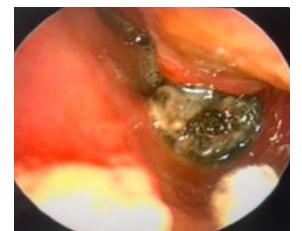
Q4: Patient presented to ER complaining of this

1. Diagnosis? Auricular hematoma
2. Most common complication? Cauliflower ear
3. The most common cause? I think trauma
4. Treatment? Incision and drainage



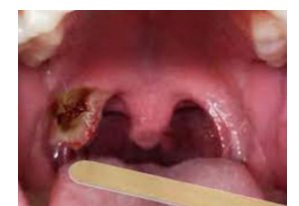Q5: Patient with history of nostril discharge

1. Diagnosis? Foreign body
2. Most common complication? Aspiration
3. Treatment? Removal by suction or forceps



Q6: This image...

3. Diagnosis? Tonsillar cancer



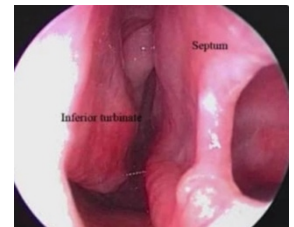
4. Write 3 presenting symptoms? Dysphagia, neck swelling, pain in throat
5. Investigation? Biopsy and histopathology
6. Treatment? Bilateral tonsillectomy and radiotherapy

Q7: 17-year-old boy came with bilateral tinnitus of 2 days duration, pure tone audiometry showing bilateral sensorineural hearing loss with notch at 6k hz

1. Type of hearing loss? Bilateral noise-induced sensorineural hearing loss
2. Cause? acoustic trauma
3. Treatment? Steroids (cause it's acute)

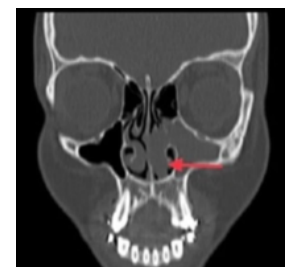Q8: The patient presented with pain following a nasal septal surgery ...

1. Diagnosis? Septal perforation
2. The cause? A possible complication of septal surgery and it could happen due to untreated septal hematoma
3. Management? Irrigation and lubrication of the area



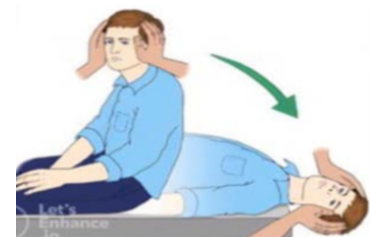Q9: This image ...

1. Diagnosis? Antrochoanal polyp
2. Management? Medical treatment is nasal corticosteroid and nasal decongestants if failed then surgical excision



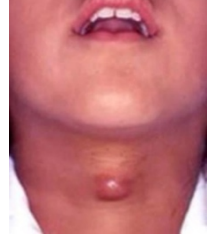
Q10: This test ...

1. What is the name of this procedure? Dix hallpick maneuver
2. What ear is tested? Left ear
3. What organ is tested? Semicircular canal
4. Diagnosis? BPPV
5. Treatment? Epley maneuver



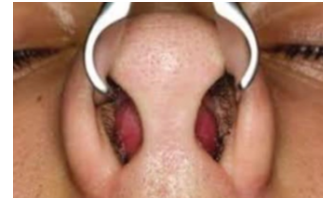Q11: This image ...

1. Diagnosis? Thyroglossal duct cyst
2. Cause? Embryologic remnant that forms due to the failure of closure of the thyroglossal duct
3. Treatment? Surgical removal of the cyst & central part of the body of hyoid bone (Sistrunk operation) after resolution of any infection.



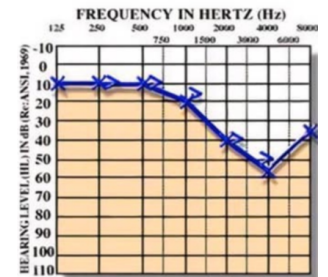
Q12: A patient presented with a trauma 3 days ago.

1. Diagnosis? Septal hematoma
2. Cause? Facial trauma
3. How to treat saddle nose deformity? Rhinoplasty
4. Mention 2 complications? Infection with abscess formation, septal perforation



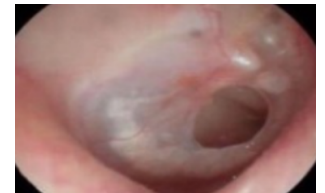Q13: 35-year-old complaining of decreased hearing

1. Diagnosis? Noise-induced hearing loss
2. Important question to ask? Occupation



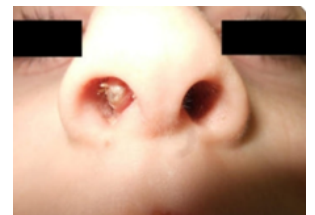Q14: This image ...

1. Diagnosis? Tympanic membrane perforation
2. Most common cause? Middle ear infection



Q15: 15-year-old young patient presented with recurrent epistaxis ...

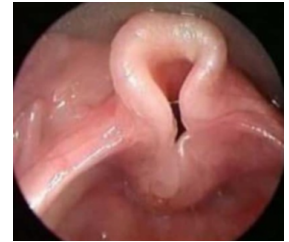1. Diagnosis? Juvenile Nasal angiofibroma
2. Diagnostic test? CT angiography
3. Treatment? Complete surgical excision



Extra: Biopsy is contraindicated in JNA.

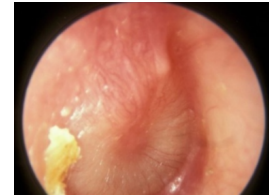
Q16: Pediatric patient complaining of stridor has this finding

1. Diagnosis? Laryngomalacia
2. Medical treatment? PPI
3. Surgical treatment? Supraglottoplasty



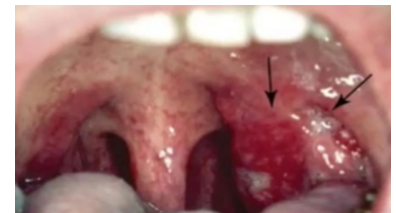Q17: Similar picture to this ...

1. Diagnosis? Acute otitis media
2. Two complications? Brain abscess, mastoiditis, meningitis



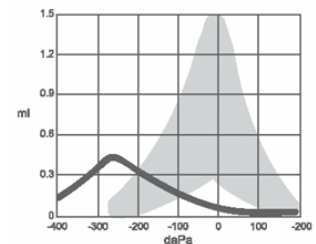
Q18: Picture of oropharyngeal cancer, 60-year-old patient...

1. Diagnosis? Oropharyngeal cancer
2. Expected symptoms to present with? Dysphagia, neck swelling, pain
3. Best investigation to do? Biopsy and histopathology



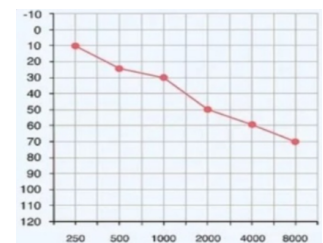
Q19: This test (tympanogram type C)

1. The name of the test? Tympanogram
2. Diagnosis? Eustachian tube dysfunction
3. Two important risk factors contributing to it?



Q20: 65 years old patient came with right hearing loss and tinnitus for 3 years duration. Otoscopic examination was normal.

1. Type of hearing loss? Sensorineural hearing loss
2. Diagnosis? Presbycusis
3. Your next investigation?



Q22: A picture of lateral neck red mass, the patient was febrile and ill

1. Diagnosis? I think it was an infected brachial cyst
2. Two management lines? Antibiotics and excision

Urology

Q1: What are the missing arteries/veins?

Answer: Segmental artery, efferent artery, IVC

Q2: Write three main markers for testicular cancer.

Answer: AFP, HCG, LDH

Q3: The patient has BPH, write 3 obstructive and 3 irritative symptoms

Answer: Obstructive (hesitancy, post void dribbling, poor stream), irritative (dysuria, frequency, urgency)

Q4: Upon cystoscope you saw this appearance

1. Next step? TURBT and biopsy for staging
2. The most common histological subtypes of bladder cancer? Transitional cell carcinoma and squamous cell carcinoma

Q5: Patient with painless mass and hematuria

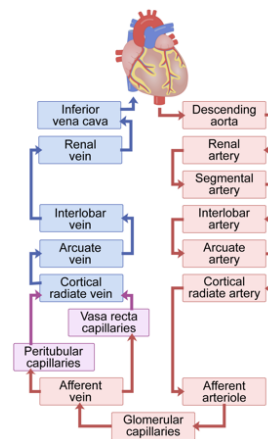
1. Diagnosis? RCC
2. Treatment? Radical nephrectomy
3. What is the classification cyst for renal cyst? Bosniak classification system

Q6: CT scan for kidney and ureters shows ureteric stone, write 2 modalities for relieving the pressure on kidney?

Answer: Nephrostomy and DJ insertion

Q7: Write 3 physical examination of the kidney

Answer: Bimanual kidney exam, ballottement kidney exam & CV angle tenderness



Q8: Patient presented complaining of infertility presented with this condition; a picture of varicocele along with picture of bag of worms

1. What's your diagnosis? Varicocele
2. Give one other indication in addition to infertility to do the surgery? Pain
3. What's the surgical management? Vein ligation / varicocelectomy

Q9: A baby presented with hemiscrotal swelling that increases with crying, it had transillumination to light

1. Diagnosis? Communicating hydrocele
2. Give 2 other ddx for hemiscrotal swelling in general? Testicular cancer, hematocele, testicular torsion.

Q10: What is the clinical presentation of testicular tumor?

Answer: painless mass, hematuria, testicular heaviness

Q12: Treatment options for prostate cancer?

Answer: watchful waiting, radical prostatectomy, chemotherapy & radiotherapy

Q13: What is the labeled structure (picture of testes)

Answer: Vas deferens, body of the epididymis, lobules

Q14: Embryological stages of kidney (in order)?

Answer: pronephrones, mesonephrones, metanephrones

Q15: Write three complications for VUR?

1. UTI
2. Reflux nephropathy with hypertension
3. Progressive renal failure

Q16: What is the medical term of passage of air with urine?

Answer: Pneumaturia

Q17: Three ways to manage uretric stone?

Answer: ESWL, PCNL, uretroscopy with laser treatment

Q18: Three ways to treat erectile dysfunction

1. Psychosexual therapy
2. Medical Tx: Phosphodiesterase type-5 inhibitors, Dopamine receptor agonist, intraurtethral PGE1, testosterone replacement therapy (for hypoginadism)
3. Devices: vacuum erection device, penial prosthesis

Q19: Three ddx for hemiscrotal swelling.

Answer: Hydrocele, hematocele, testicular torsion

Q20. Three things you look at when you do a semen analysis.

Answer: semen volume, sperm concentration, sperm motility, sperm vitality, sperm morphology

Extra: You should also memorize the lower reference limits for each of them:

- Semen volume: 1.5 mL
- Sperm concentration: 15 million sperm/mL
- Progressive motility: 32%
- Total motility: 40%
- Vitality: 58% alive
- Morphology: 4% normal form

Q21: The definition of each of the following:

1. Urge incontinence? This occurs when a patient experiences involuntary leakage of urine coincident with sensation of urinary urgency.

2. Stress incontinence? refers to the involuntary leakage of urine with any activity that increases intra-abdominal pressure.
3. Overflow incontinence? occurs when the urinary volume within the bladder approaches and exceeds bladder capacity, resulting in an increase in intravesicle pressure greater than urethral outlet resistance.

Q22: Three common histological type of bladder cancer.

Answer: TCC, SCC, Adenocarcinoma

Q23: When you do a DRE what are the three findings that look for in prostate

1. Nodularity
2. Symmetry
3. Consistency

Q24: Define each of the following.

1. Emphysematous pyelonephritis? Necrotizing infection characterized by the presence of gas within the renal parenchyma or perinephric tissue. About 80-90% of patients have diabetes.
2. Xanthogranulomatus pyelonephritis? A form of chronic bacterial infection of the kidney. The affected kidney is almost always hydronephrotic and obstructed, Characteristically, foamy lipid-laden histiocytes (xanthoma cells)
3. Chronic pyelonephritis? Results from repeated renal infection, which leads to scarring, atrophy of the kidney, and subsequent renal insufficiency.

Q25: What is the classification system for each of the following?

1. Prostate cancer? Gleason grading system
2. Renal cyst? Bosniak classification system
3. Multi-parametric MRI? PI-RAD

Q26: Write three ddx for flank pain.

Answer: pyelonephritis, RCC, kidney stones

Q27: Write three urological malignancies may present with hematuria.

Answer: RCC, bladder cancer, prostate cancer

Q28: Write three Inguinal canal contents you see in surgery.

Answer: testicular artery, pampiniform plexus, vas deferens

Q29: Write the medical term for each of the following.

1. Strong sudden desire for urination? Urgency
2. Difficulty in the initiation of urination? Hesitancy
3. Passage of air in urine? Pneumaturia

Q30: Patient with erectile dysfunction, write 3 medical conditions you should ask about in history?

Answer: Medical illness (DM, HTN, peripheral vascular disease), penile or pelvic surgery, radiotherapy.

Q31: 25-year-old male with unilateral acute testicular pain, write 3 ddx.

Answer: Testicular torsion, Varicocele, epididymitis

Q32: Patient with infertility

1. Diagnosis? Varicocele
2. Which grade?
3. Indication of treatment? Infertility and pain

Q1: About corneal transplant surgery, which is wrong?

- A. Success rate of the surgery is 50%
- B. The graft should be extracted within 24 hours from deceased donors
- C. HLA compatibility is not needed
- D. The suture size that is used in surgery is 10-0
- E. Astigmatism is a possible complication of the surgery

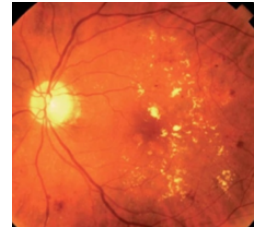
Answer: A

Q2: What is corneal cross-linking surgery used for?

Answer: Progressive keratoconus

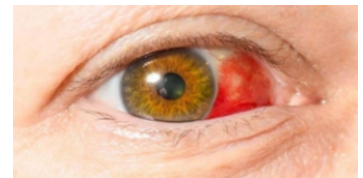
Q2: What is the earliest sign in this condition?

Answer: Microaneurysms



Q3: Patient presented with sudden painless lesion as in the picture, what is your management?

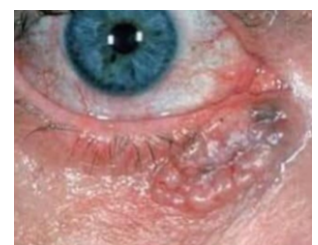- A. Check retina for possible retinal detachment
- B. Give topical steroids
- C. Check his blood pressure



Answer: C

Q4: Patient presented with a painless lesion on his eyelid, it appeared 3 months earlier and it bleeds every now and then, what's your diagnosis?

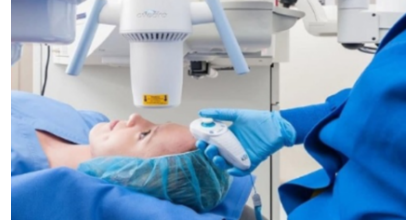- A. SCC
- B. BCC
- C. Chalazion



Answer: A

Q5: What is the use of this procedure?

Answer: Keratoconus

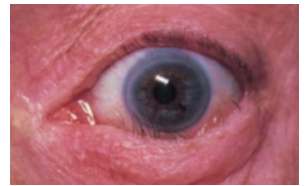


Q6: Two contraindication of LASIK surgery

Answer: Keratoconus, severe dryness, pregnancy

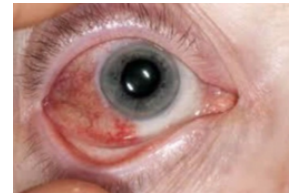
Q7: What is the diagnosis?

Answer: Entropion



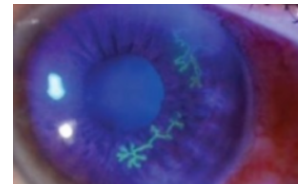Q8: The most likely diagnosis?

Answer: Episcleritis



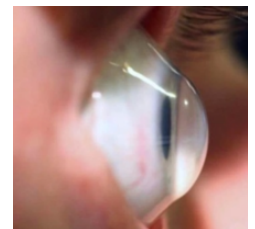
Q9: This disease is caused by?

Answer: HSV 1



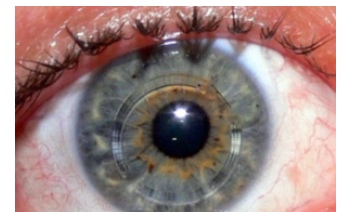
Q10: The cause of vision loss in this case?

Answer: Progressive myopia and astigmatism



Q11: What is the diagnosis?

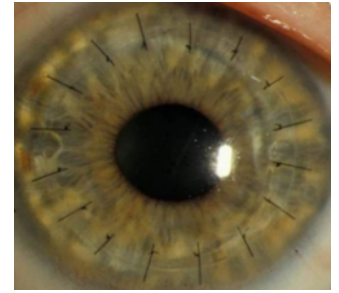
Answer: Keratoconus



Q12: What causes of graft rejection?

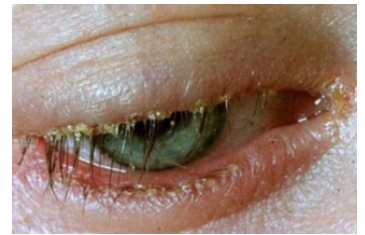
- A. Small corneal graft
- B. Tight sutures
- C. Donor- recipient junction blood vessels
- D. ABO blood
- E. HLA type

Answer: I think is C




Q13: What is the diagnosis?

Answer: Blepharitis



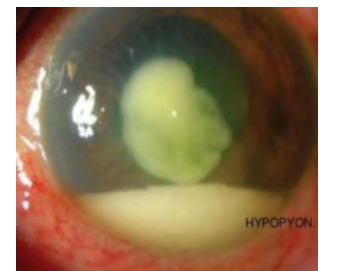
Q14: 1 year patient presents with this finding, what's the diagnosis?

Answer: Dermoid cyst




Q15: What is the diagnosis?

Answer: Bacterial keratitis



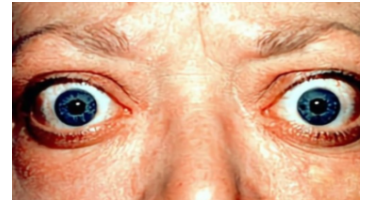Q16: Two causes of this finding?

Answer: Marfan syndrome, trauma, homocystenuria



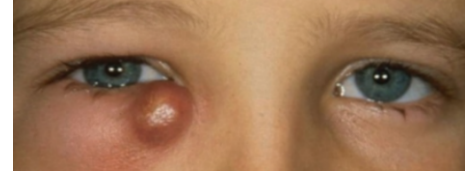Q17: Other than proptosis, write a sign in this patient?

Answer: lid retraction



Q18: 23-year-old female with 6 months of this complaint

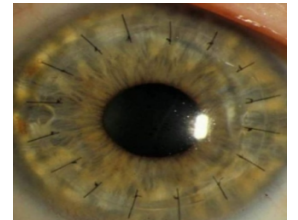
- A. Keratitis
- B. Acquired nasolacrimal duct obstruction
- C. Congenital nasolacrimal duct obstruction
- D. Punctuate obstruction



Answer: B

Q19: Which one of these is the most common cause of failure of this surgery:

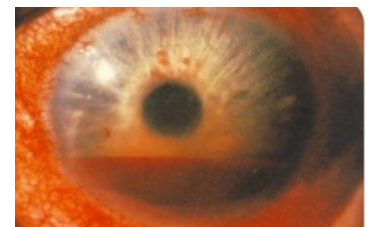- A. Infection
- B. Astigmatism
- C. Recurrence
- D. Rejection



Answer: I think D

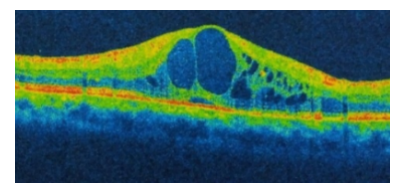
Q20: Patient with trauma to the eye, IOP =35 which of the following is false:

- A. We should use mydriatics in treatment
- B. Immediate glaucoma is considered as secondary closed-angle glaucoma
- C. Something about Delayed glaucoma
- D. Washing is indicated in case of corneal staining



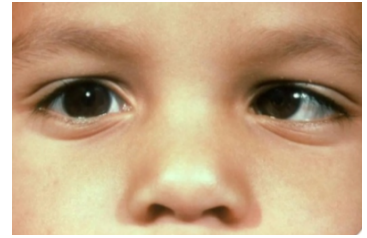Q21: This picture + picture of retina with hard exudates very close to macula, best treatment?

- A. YAG laser
- B. Intra-vitreous VEGF
- C. Panretinal laserphotocoagulation



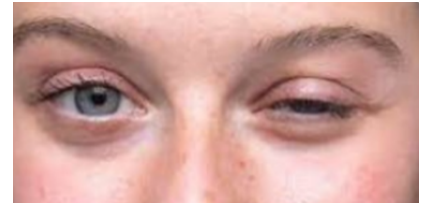Q22: Which of the following is NOT a cause of esotropia?

- A. Wide nasal bridge
- B. Hypermetropia
- C. Amblyopia
- D. Cataract



Q23: This finding happens at the evening, diagnosis?

Answer: Myasthenia gravis

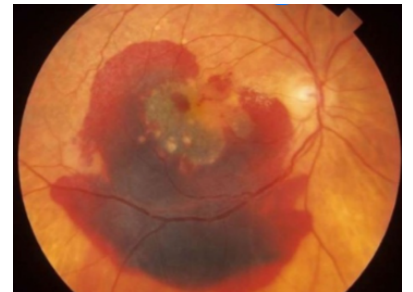

Q24: In case of eye trauma which of the following would you NOT expect to find in relation to all complications?

- A. Hypopyon
- B. Hyphema
- C. Glaucoma

Q25: Elderly female patient came with sudden vision loss. which of the following is the most common cause?

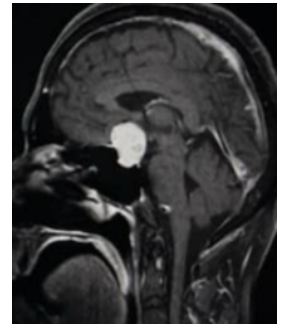
- A. Central retinal vein occlusion
- B. Central retinal artery occlusion with cherry red spot
- C. Wet age-related macular degeneration
- D. Vitreous detachment



Neurosurgery

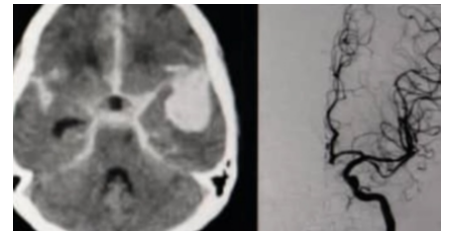
Q1: Female patient presented with headache and galactorrhea.

1. What is the diagnosis? Pituitary adenoma
2. What is visual defect you expect to be present in this patient?
Why? Bilateral hemianopia due to compression on optic chiasm
3. What is the laboratory investigation you would order for diagnosis? Prolactin
4. What is the first line treatment? I think the answer is dopamine agonist like bromocriptine
5. What is the surgical management approach? Trans-sphenoidal hypophysctomy



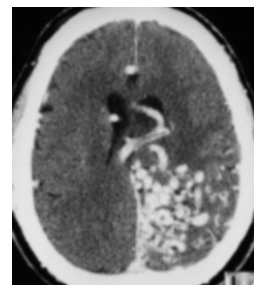
Q2: A patient with severe headache

1. Findings on CT? Hyperdense subarachnoid hemorrhage in middle cerebral artery area
2. Imaging modality of choice? Digital subtraction angiography (DSA)
3. Cause? Ruptured aneurysm
4. Treatment? Clipping and coiling



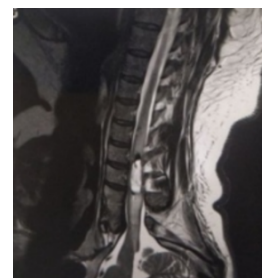Q3: What is the finding in the image CT scan showing?

1. Finding? AV malformation
2. Possible complication? Spontaneous SAH
3. Prognosis? 5 years 50%



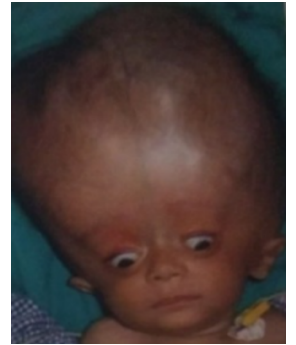Q4: This image ...

1. What is model of imaging? MRI T2 with contrast sagittal cut
2. What is 2 ddx? Ependymoma - meningioma
3. What is most likely diagnosis? Ependymoma



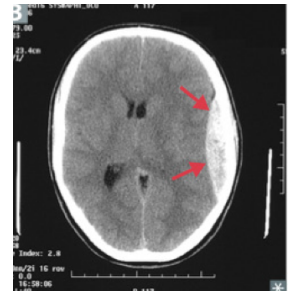
Q5: A 2-year-old patient is brought by his parents to the hospital as a case of hydrocephalus.

1. What is the name of this sign? Sunset eye sign
2. Mention 4 other findings you'll find when examining the head of the patient.
 - Tense/bulged fontanelle
 - Increased head circumference
 - Tense, shiny skin
3. What is the most common cause of hydrocephalus in this patient? Cerebral aqueduct stenosis
4. What is the best diagnostic method for the diagnosis of hydrocephalus? MRI
5. What are 2 definite surgical treatments for this patient? Endoscopic third ventriculostomy, VP shunt



Q6: CT showing (acute) subdural hematoma with midline shift

1. Asking about diagnosis? Acute epidural hematoma
2. Glasgow coma scale? It was 9/15
3. Treatment? Craniotomy + evacuation



Q7: Myelomeningocele question ...

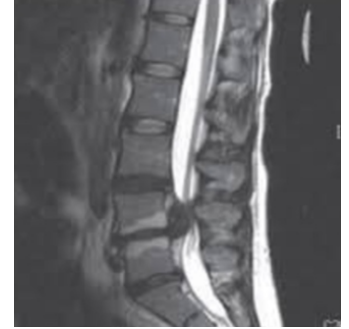1. Would he improve after surgery? No
2. Intervention you would do to a woman pregnant of a baby with this condition? Intrauterine myelomeningocele surgery

Q8: Patient presented with sudden neck pain radiating to her right arm, photo was cervical disk prolapse MRI

1. Describe the photo
2. What other symptoms could be present?
3. Whats the most important reflex you search for?
4. The name of the surgery? ACDF

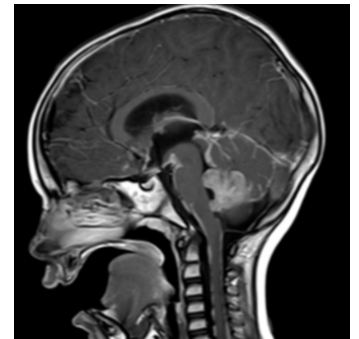
Q9: Patient presented with acute sudden severe back pain radiating to his right lower limb along with urinary incontinence

1. Describe the image
2. Diagnosis? Cauda equine syndrome
3. The best time to do surgery? It's an emergency; within the first 48 hours of onset
4. The name of surgery? Discectomy



Q10: A child with a brain tumor, image like this:

1. Describe? MRI T1 with contrast demonstrating a heterogeneously enhancing lesion in the infratentorial area
2. Treatment? Treat hydrocephalus and surgical excision of tumor
3. The most possible diagnosis? Medulloblastoma

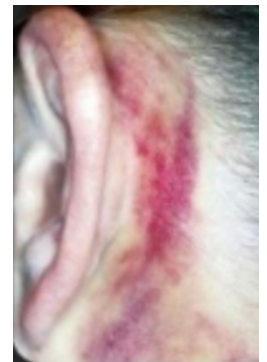

Q11: A female with a spinal cord injury, has weakness in upper limbs more than the lower limbs, diagnosis?

Answer: central cord syndrome

Q12: A case of RTA the patient presented with this sign, open eyes spontaneously, not oriented to place, obeys commands

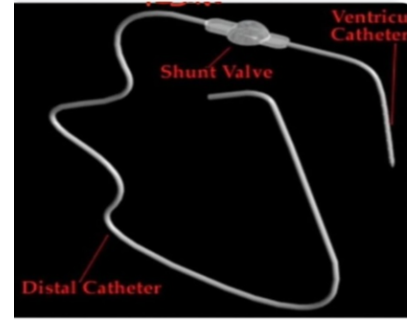
1. What is the GCS? 14/15
2. The type of head injury? Mild head injury
3. What is the name of this sign? Battle sign
4. Mention other three signs associated with basilar skull fracture?
Raccoon's eye, CSF leak (rhinorrhea & otorrhea) conjunctival hemorrhage
5. Mention two test to differentiate CSF leak? Beta 2 transferrin, surge tests



Q13: Question about straight leg rising test, is it passive or active, when it is positive?

Q14: Write the parts of this shunt

Answer: ventricular catheter, shunt valve, distal catheter

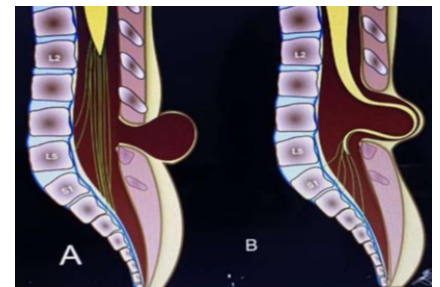


Q15: Picture of foot drop ...

1. The name of this sign? Foot drop
2. Which nerve root is affected? L5
3. Best investigation? Lumbosacral spine MRI

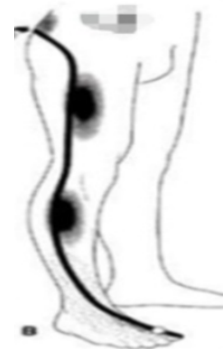Q16: These are two types of a common congenital anomaly seen in the neurosurgical practice.

1. Name the anomalies seen in figures A&B?
A: meningocele, B: Myelomeningocele
2. How can you differentiate between them on clinical examination (mention two differences)?



Q17:

1. Dermatome?
2. Myotome?
3. Investigation? Lumbosacral spine MRI



Best of luck