

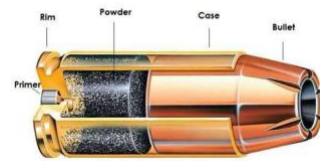
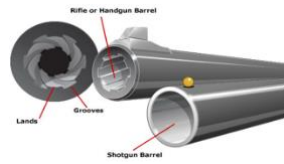FORENSIC & TOXICOLOGY SUMMARY

Done by Shahed Atiyat

Firearm injuries

Firearms are broadly classified into two categories depending on the type of barrel:

1. Rifled weapons.
2. Smooth bores rifled (shotgun).



Anatomy of a Cartridge

Types of gunpowder:

- Black powder: it produces flame, smoke and heat, and consists of granular.
- Ingredients, like sulfur, charcoal and saltpeter (potassium nitrate).
- Smokeless powder: more effective than black powder as it burns more efficiently and produces much less smoke, resulting in less blackening and tattooing around the entry wound.

Factors responsible for the injurious effects of missile:

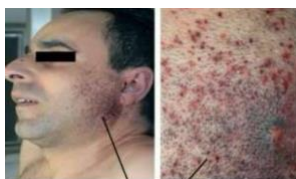- Speed of the bullet.
- Size and shape of the bullet.
- Character of the missile's movement in flight.

Characteristics of firearm wounds depend on:

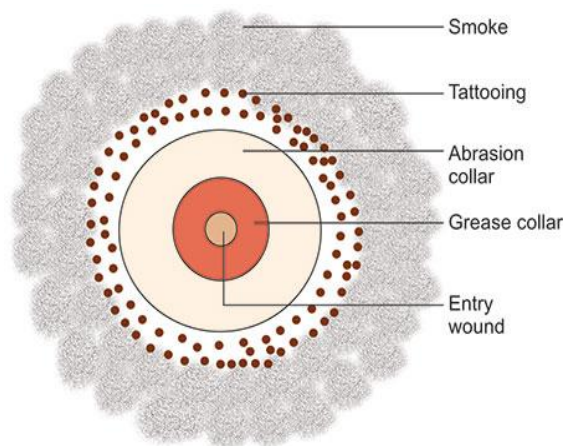
- Nature of the firearm, whether shotgun or rifle.
- Shape and composition of the missiles.
- Range (distance) of firing.
- Part of the body struck (head or trunk).
- Direction of firing.

Grease collar: black colored narrow ring of skin, lining the defect and is sharply outlined from the removal of substances from the bullet as it passes through the skin.

Tattooing: Appear as **reddish-brown** punctate abrasions surrounding the wound **entrance**.

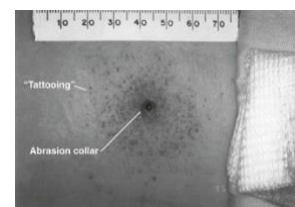


Tattooing



Abrasion collar: **reddish-brown ring around a bullet entry wound**, caused by the bullet stretching and rubbing against the skin before penetration.

Blackening (smoke): appear as **black-gray** discoloration surrounding the wound **entrance**.

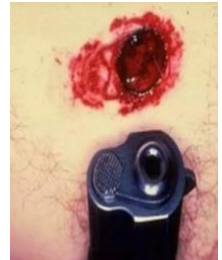

Tattooing (stippling)	Blackening
It consists of unburnt or partially burnt powder particles that are embedded in and under the skin.	It consist of burnt powder particles that are expelled from the firearm
Appear as reddish-brown punctate abrasions surrounding the wound entrance	Appear as black or gray discoloration around the wound entrance
Can't be wiped off	Can be wiped off

What is Muzzle/recoil imprint mark?

A **muzzle imprint mark** refers to the distinctive pattern or injury left on a person's skin when the muzzle (the end of the barrel) of a firearm is in direct **contact with or very close** to the skin at the time of discharge.

“يعني شكل فوهة السلاح بطبع على الجلد وهاد دليل إنه المسافة قليلة جدًا وملامسة لسطح الجلد”



What is Blowback phenomenon?

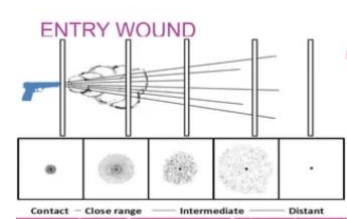
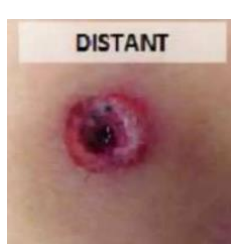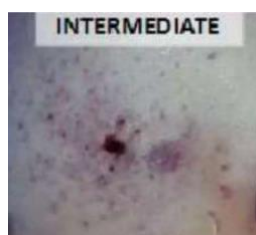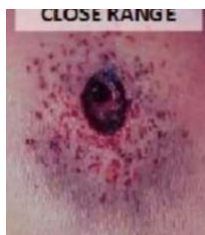Blowback is the **backward movement** of **blood, tissue, hair, or fibers** into the barrel of a firearm after a **contact or close-range gunshot wound**.

Classification of gunshot wounds:

1. Penetrating wounds: entry wound only.
2. Perforating wound: entry and exit wounds.

Entry wound appearance:

Contact shot 0 cm	<ul style="list-style-type: none"> ○ Muzzle Imprint may be present. ○ Burned & blackened edges. ○ Red cherry tissue (from CO). ○ Blowback effect. ○ Stellate (Star-Shaped) wound with everted margins happens if is over a bony surface (skull).
Close shot Up to 15 cm (6 inches)	<ul style="list-style-type: none"> ○ Small, circular wound with inverted margins. ○ Tattooing & blackening are present. ○ Grease collar & abrasion collar.
Near shot (intermediate) 15 - 60 cm (6 - 24 inches)	<ul style="list-style-type: none"> ○ Tattooing is present, but blackening disappears. ○ Wound size: similar to the bullet caliber. ○ Abrasion collar still visible.
Distant shot Beyond 60 cm	<ul style="list-style-type: none"> ○ Only the bullet penetrates, no blackening or tattooing. ○ Wound is clean-cut, round or oval with an abrasion collar. ○ No surrounding burns, marks, or muzzle imprints.



Exit wound appearance:

- Exit wounds, regardless to the distance, all have the same general characteristics.
- In contact wounds and very close range, exit wound is smaller than entry wound due to elastic nature of the skin. However, **as range increases, the size of exit wound also increases.**
- Exit wounds do **not show burning, blackening, tattooing**, abrasion or contusion collar. The edges are **everted**, torn or puckered with pieces of contused, hemorrhagic subcutaneous fat or muscle protruding out of the defect.

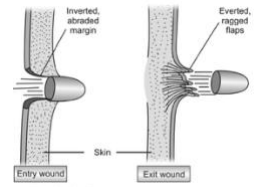


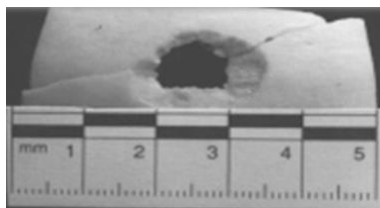
Fig. 12.18: Firearm entry and exit wounds

Differentiation 12.1: Entry and exit wound (Fig. 12.18)		
Feature	Entry wound	Exit wound
Size	Smaller than the diameter of the bullet (except contact shot)	Bigger than the bullet
Edges	Inverted	Everted, puckered
Skull	Clean cut on outer table and beveled in the inner table	Beveled in the outer table and clean cut on inner table
Bruising, abrasion and grease collar	Present	Absent
Burning, blackening, tattooing	May be seen	Absent
Bleeding	Less	More
Fat	No protrusion	May protrude
Wound track	May be cherry-red due to carboxyhemoglobin	No color change
Fibres of clothes	Turned in	Turned out
Radiological/micro-chemical examination	Lead ring may be seen	Absent
Spectrograph	More metal is found	Not so

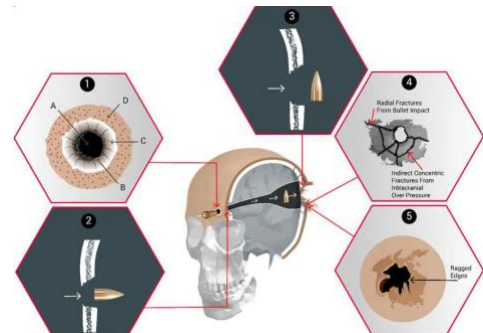
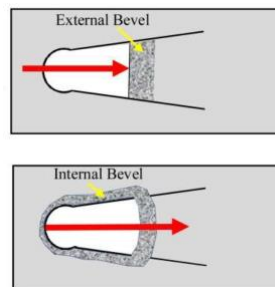
Differentiation 12.2: Suicidal, accidental and homicidal firearm injury			
Feature	Suicide	Accident	Homicide
Site of entry wound	Head or heart	Any area	Any area
Shot distance	Contact or very close range	Close or very close	Any range, usually distant
Direction	Upward or backward	Any direction	Usually upward
Number of wounds	Usually one	One	Any number
Powder residue on hand pressing trigger	Present	Present	Absent
Cadaveric spasm	May be seen with the weapon firmly grasped	Not so	Not so
Weapon at scene	Found	Found	Not found
Scene	Usually his house	In his house or while hunting/handling	Any place, evidence of struggle
Sex	Usually males	Usually males	Any sex
Motive	Insanity, illness, financial loss	Nil	Gang feuds, robbery, revenge

Skull wound due to firearm:

- In perforating gunshot wounds to the head, entrance and exit wounds show a typical feature called beveling, distinguishing between entrance and exit.
- Beveling is a sort of cone shaped bone erosion in the direction of the bullet path through the cranial vault.
- Entrance wounds can be round / oval or stellate in shape and show an internal beveling.
- Exit wounds are usually irregular and show an external beveling.
- Even if the bullet does not penetrate into the cranial cavity, its energy is still transferred to the bone and central nervous system, resulting in fractures and severe damage.



External beveling



Note: When tattoo marks are destroyed (e.g., by burns, trauma, or decomposition), their presence can sometimes still be inferred by detecting pigment particles in the:

- **Regional lymph nodes**, because:
 - Tattoo pigment can be phagocytosed by macrophages.
 - These pigment-laden macrophages may migrate to regional lymph nodes via lymphatic drainage.