



# Family medicine Mini-OSCE

Collected by:  
Shahed Atiyat

**This file includes ALL available mini-OSCE exams:**

**020 Mini-OSCE**

**019 Mini-OSCE**

**018 Mini-OSCE**

**017 Mini-OSCE**

**And another questions from another years**

اللَّهُمَّ إِنِّي أَسْأَلُكَ فَهَمَ النَّبِيِّينَ وَحِفْظَ الْمُرْسَلِينَ وَالْمَلَائِكَةِ الْمُقَرَّبِينَ  
اللَّهُمَّ اجْعَلْ أَلْسِنَتَنَا عَامِرَةً بِذِكْرِكَ وَقُلُوبَنَا بِخَشْيَتِكَ وَأَسْرَارَنَا بِطَاعَتِكَ إِنَّكَ عَلَى كُلِّ شَيْءٍ  
قَدِيرٌ وَحَسْبُنَا اللَّهُ وَنِعْمَ الْوَكِيلُ  
اللَّهُمَّ إِنِّي أَسْأَلُكَ عِلْمًا نَافِعًا وَرِزْقًا طَيِّبًا وَعَمَلًا مُتَقَبَّلًا  
بِسْمِ اللَّهِ الرَّحْمَنِ الرَّحِيمِ

# 020 Mini-OSCEs

## **Special thanks to**

**Hana Arikat**

**Roa'a Jaber**

**Rahaf Truab**

**Haitham Alsaifi**

**Noor Ashraf**

**Mohammad Mahmoud**

**Alaa Motaz**

**Tityana Soury**

**Fawzi Qadoomi**

**Insaf Alammouri**

**Hani Shihadeh**

**Saif Abdulsalem**

**Leen Farah**

**Sumayah Al-Kasaji**

## 1st rotation

**Q1: A 83 year old female presented with lower back pain lasted for 10 days.**

A. Give 2 DDx.

1. Fracture
2. Septic discitis

B. If she has a fever what do you suggest a diagnosis?

Vertebral osteomyelitis

C. Give 2 DDx for a 38 year old female patient's with the same presentation.

1. UTI
2. Muscle strain, Truma

**Q2: Labs: TSH: 10.2 (Elevated) with normal T4, normal T3**

A. What is the diagnosis?

Subclinical hypothyroidism

B. Mention one lab that is important in this case.

Anti-TPO antibodies

C. What is the next step?

Give levothyroxine

**Q3: A 38 year old patient complained of difficulty of swallowing for 3 months.**

A. Mention one thing indicates a serious presentation.

Weight loss

B. If this patient has a systemic disease what would you ask?

Any symptom of scleroderma

C. One risk factor for this presentation.

Smoking

**Q4: Picture of countertransference.**

Describe the picture.

**Q5: A 55 year old male patient diagnosed recently with DM, what is the level of prevention in each of the following.**

A. Control his blood sugar readings.

Tertiary prevention

B. Do exercise.

Tertiary prevention

C. Measure HbA1C for his son

Secondary prevention

D. Advise his son to do exercise.

Primary prevention

**Q6: A 52 year old male patient with a history of ischemic heart diseases. He is smoker with 30-pack year. Presented with shortness of breath. (+ x ray image)**

A. Describe what you see in X ray.

Cardiomegaly, diffuse bilateral infiltrates, widening of mediastinum, pleural effusion.

B. Give one diagnosis.

Congestive heart failure

C. Medication of choice.

Furosemide

**Q7: Case of anger patient, mention five strategies for managing this situation.**

Remain calm, establish eye contact and step back trying to analyse what is happening then, ask the patient to sit down and try to adopt a similar position (the mirroring strategy), address the patient by the appropriate name, listen intently allowing patients to ventilate their feelings, then giving appropriate reassurance, allow time at least 20 minutes). If a threatening aggressive patient, set the closest to the door to allow escape.

**Q8: Differentiate between multimorbidity and comorbidity.**

Comorbidity: a group of morbidities in a single patient with one morbidity being the dominant.

Multimorbidity: a group of morbidities in a single patient without a dominant morbidity.

## 2nd rotation

**Q1: 30 year old female works as a teacher, read this ECG and answer the following.**

A. Describe the ecg.

Premature ventricular cintraction.

B. Give 2 causes for it

1. Excess caffeine consumption.
2. Anxiety.

**Q2: Patient want vitamin D prescription investigation (High Ca, low phosphat, normal albumin, vitamin D [need time])**

A. Give a diagnosis?

B. Management (4 points)?

**Q3: CBC (low Hb & low MCV)**

A. Give 2 ddx.

1. Iron deficiency anemia.
2. Thalassemia.

B. 3 important questions to ask?

Diet, family history of anemia, bleeding.

**Q4: Give 2 ddx for fatigue in each of the following.**

A. 67 year old patient for 2 months

1. Anemia.
2. Chronic kidney disease.

B. 25 year old patient for 2 days

1. Influenza.
2. Stress / poor sleep.

**Q5: Question about anxious patient.**

**Q6: Mention 3 fields where counseling can be applied.**

1. Chronic pain.
2. Marital problems.
3. Depression.

**Q7: What are the vaccines you want to give for a geriatric patient, mention 3 of them & at what age & frequency.**

1. Pneumococcal ,65th, twice max.
2. Herpes zoster, 60th, once.
3. Tetanus and diphtheria, when needed, every 10 years.



## 3rd rotation

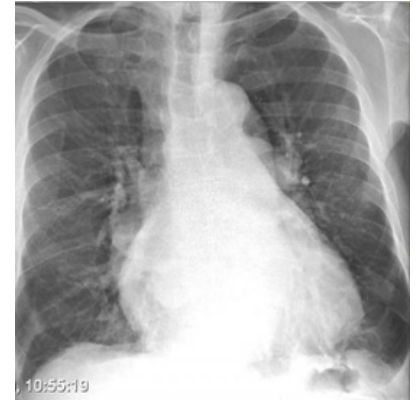**Q1: A 68 Year old male has been experiencing shortness of breath in the last 8 months, he had to stop to take his breaths after climbing stairs, his medical history is significant for hypertension and he is an ex smoker.**

A. Describe the X-ray finding.

Bilateral diffuse pulmonary infiltrates, cardiomegaly, cephalization of pulmonary vessels.

B. What is the possible diagnosis.

Congestive heart failure.



**Q2:**

A. describe the pic findings.

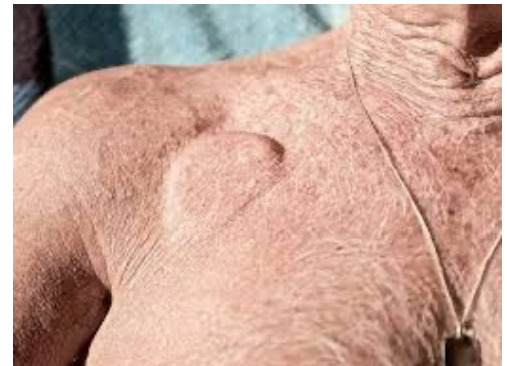Pacemaker.

B. Mention one indication for its use.

Complete heart block.

C. Mention one Complication.

Infection.



**Q3: You are interviewing a patient in the clinic and he wants to tell you how his symptoms developed and he is talking about his thoughts, what is the appropriate response/s to the patient?**

A. Politely interrupt the patient and ask closed ended questions.

B. Allow the patient to say his thoughts.

C. Tell the patient that time is essence.

D. Offer the patient to take another consultation to discuss his concerns,

E. Tell the patient that you will give him enough time to talk about his thoughts but after you finish history taking.

Answer is B

**Q4: A 85 years old male is brought by his family due to fatigue, he has a history of ischemic heart disease and type 2 diabetes, and hypertension. In the last 1 week he lost his ability to do basic activity of daily living .**

- labs (very high GGT, very high ALP, high normal AST, mildly high ALT, very high direct bilirubin.

A. What physical sign is relevant in examination?

Courvoisier sign (painless abdominal mass with jaundice) (not sure)

B. Describe the lab results.

Hyperbilirubinemia, increased GGT and ALP levels (cholestatic pattern).

C. The differential diagnosis?

Pancreatic ca, primary sclerosing cholangitis, cholangiocarcinoma

**Q5: Give 2 differential diagnosis for each of the following:**

A. 24 year old male with palpitations of 1 day.

1) Anxiety/SVT

2) Excess caffeine intake/PVC

B. 75 year old female with palpitations of 1 week.

1) Cardiac arrhythmia/A.fib

2) Anemia of chronic disease

**Q6: Give 2 examples of facilitation**

1) Head nod

2) "Tell me more"

**Q7: Mention 1 physiological change in geriatrics in the musculoskeletal and renal systems:**

Musculoskeletal system: Decreased muscle mass (sarcopenia).

Renal system: Decreased glomerular filtration rate 10 ml/decade. Or, decreased potassium excretion, decreased sodium excretion.

**Q8: Based on these pictures answer the following:**

A. What is the name of this test?

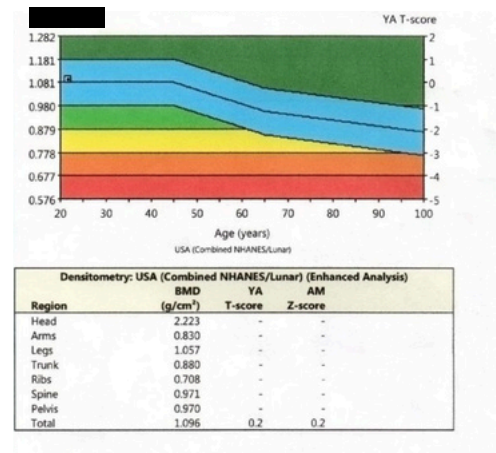
DEXA scan.

B. It is Used for?

To measure bone density (Osteoporosis screening).

C. At what age we start screening?

65 female, 70 male.



**Q9: What are the levels of prevention, give one example for each?**

Primary prevention -> immunization (covid, flu,...).

Secondary prevention -> screening (mammogram for breast cancer).

Tertiary prevention -> following blood pressure readings for hypertensive patient.

## 4th rotation

### **Q1: CBC interpretation (thrombocytopenia)**

A. Three questions to ask the patient.

B. Most probable diagnosis is?

ITP.

### **Q2: Three questions for a case with vertebral fracture image**

A. Most probable diagnosis is?

Osteoporotic vertebral fracture.

B. Risk factors?

Chronic corticosteroids use and her age (she was 73y/menopause).

C. Investigation to do?

DEXA scan.

### **Q3: Three questions about hemostenosis.**

### **Q4: The difference between chunk and check and spotposting in consultation?**

### **Q5: Case of spontaneous abortion and you have to tell the mother.**

ABCDE or SPIKE approach.

### **Q6: 52y male anxious patient because his elevated blood pressure readings for the last 2 weeks, office blood pressure is 150/90, he has no history of high blood pressure for the last year, what is the next step in management? (MCQ)**

### **Q7: Three differentials ddx (common, less common, serious) for each of the following:**

A. Dizziness, 23 year old lady for 1 day duration.

Stress & BPPV.

B. Dizziness, 73 year old male for 2 months duration.

Anemia & brain tumor.

**Q8: ECG interpretation (was a sinus bradycardia)**

A. Spot diagnosis.

Sinus bradycardia.

B. 2 Important points during evaluation.

C. 2 Possible causes.

Ischemic heart disease.

Acute myocardial infarction.

Digoxin, Beta-blockers.

## 5th rotation

**Q1: Picture of mini-cog test.**

A. What is the name of this test?

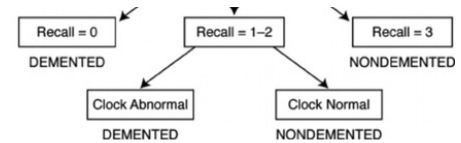
## Min-cog test.

### B. What is it used for?

## Evaluating mental state of elderly (ability to recall).

B. Name other formal test?

## Mini mental state.



**Q2: 25 yo pt complaining of mass in the throat of short duration & picture of goiter.**

A. Give 3 causes.

Graves / hashimoto / goiter.

B. Two questions to ask in history?

Dysphagia / heat or cold intolerance / weight changes.

**Q3: A 65 year old female came for routine check up mention 8 screening to do.**

1. HTN (take blood pressure readings).
2. Dm (FBG).
3. Dyslipidemia (lipid profile).
4. Depression (PHQ2 /9).
5. Colon CA (colonoscopy).
6. Breast CA (mammogram).
7. Cervical CA (pap smear).
8. Lung CA (LD-CT).

**Q4: 63 yo female underwent following surgery (pic of knee scar), then started complaining of same complaint on the other side.**

A. What is the diagnosis?

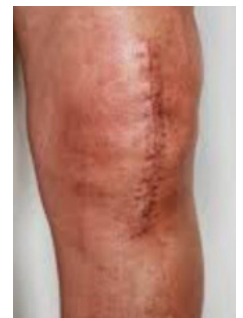## Osteoarthritis.

B. Give other treatment modalities rather than surgery.

Steroid injection? / pain medication (NSAID / paracetamol).

C. Mention 2 Risk factors?

Gender (female and post-menopause) & Old age.



**Q5: A 20 year old, coughing blood**

A. The most likely causes?

Epistaxis / trauma.

B. Other 2 cases?

TB / lung CA / drug (warfarin) / blood disorders.

C. What to do as priority?

Rule out serious causes like lung ca (LD-CT).

D. What would you do in history and physical examination in order to know the patient's triage?

Take vital signs (BP /O<sub>2</sub> / HR / RR).

Ask relevant q in hx (recent upper resp infection / trauma...).

**Q6: Mention 2 ddx for SOB in each of the following**

A. A 84 year old female for 3 months duration.

COPD / heart failure.

B. A 21 year old female for 2 days duration.

Anxiety / acute upper respiratory tract infection.

**Q7: A 20 year old athletes with incidental elevated CK.**

A. Mention 2 possible causes.

Rhabdomyolysis / Dehydration.

B. Mention the management in RAPRIOP format? explain that the findings are abnormal.

1. Advice patient to drink more water and decrease exercise.
2. Prescribe medication if needed.
3. Observe and follow up.
4. Prevention: screen for hypertension and depression.
5. Investigation: order labs as needed.
6. Refer to specialist if indicated.

## 6th rotation

**Q1: Female patient came with scars over her eyelid. She claims that is a fungal infection:**

1. What is the most likely diagnosis?

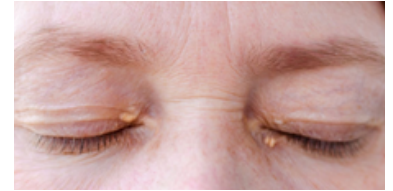Xanthelasma

2. Most likely causes of this condition?

Dyslipidemia, alcohol, weight gain, chronic liver disease, atherosclerosis... etc

3. Most important Lab tests to do?

Lipid profile (LDL,HDL,Cholesterol,Triglycerides), LFTs



**Q2: 60 years old female presents with right knee pain with this x-ray:**

1. Most likely diagnosis?

Osteoarthritis

2. What You recommend for this Patient?

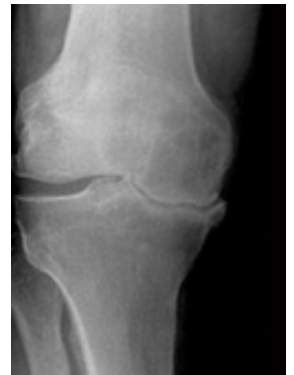Lifestyle modifications (weight loss,exercise (swimming))

3. Most appropriate treatment (MCQ):

1. Acetaminophen

2. Ibuprofen

3. Morphine



**Q3: A 34 year old male complains of groin pain with movement.**

1. Mention 2 common diagnosis:

Inguinal hernia, hip OA, muscular strain or injury

2. Mention 2 uncommon diagnosis:

AVN, torsion

3. Mention 2 red flags:

Sudden severe pain not relieved by analgesia, signs of sepsis or shock, visible peristalsis

**Q4: What technicalities should be considered when interviewing an elderly patient?**

Signposting, chunk and check, avoid jargon, use effective physical and visual techniques of communication



**Q5:**

1. Mention the 4 tasks of stott and davis model of consultation:

Manage presenting problem, manage continuing problems, modify health seeking behaviors, opportunistic health promotion

2. Questions to ask about the first task

How can I help you?, how are you doing today?

**Q6: In the following CBC ( WBC count was  $2.8 \times 10^9$ , neutrophils were 24%, lymphocytes were 56%)**

1. Mention the most marked abnormality:

High lymphocytes

2. Mention 2 causes of this:

Viral tonsillitis, viral pharyngitis, AI diseases, cancers like CLL

3. Mention other tests that need to be done:

PCR

**Q7: Case 7: A male complains of recurrent palpitations that increase at rest and mild exercise but does not increase with exertion , no chest pain, normal heart sounds, frequent dizziness. His ECG was normal but he handled you a previous ECG reading obtained by his smart watch.**

1. Diagnosis:

premature ventricular contracture

2. Next step (MSQ):

1. Immediate cardioversion

2. b blockers

3. Electrolytes and TSH

**Q8: 12 year old, fever of 4 days, difficulty swallowing, did not improve when given acetaminophen ..., unable to lie down because he can't breathe**

1. Most likely diagnosis:

Peritonsillar abscess

2. Next step:

To do oral exam using tongue depressor

## 8th rotation

**Q1: Give 2 Ddx of lower abdominal pain for:**

A. 20 years old female, pain for 2 days:

Cyclic Pain, Recurrent Ovarian Cyst

B. 42 years old female pain for 2 months:

IBD, Diverticulitis

**Q2: 50 pack years smoker, 60 of age, presented to the clinic complaining of SOB and fatigue that has been going for 1 year, he was admitted two times for respiratory infections this year:**

A. Your diagnosis?

COPD

B. Primary prevention:

Smoking cessation

C. Secondary Prevention:

Lung CA screening ( low dose CT)

D. Tertiary Prevention:

Managing with Drugs or Vaccines to prevent exacerbations

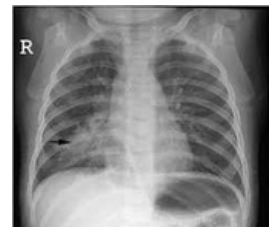**Q3: Patient with fever, cough with productive sputum, and abnormal chest xray:**

A. Mention 3 causes:

Pneumonia, Lung Ca, Atelectasis

B. Mention any preventive measure:

Lung CA screening



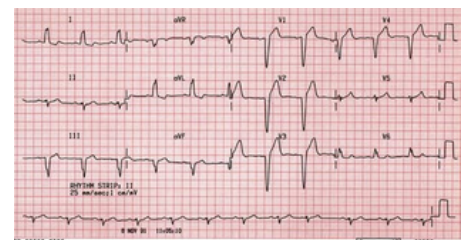
**Q4: Patient with heart problems, came to you complaining of recent mild exertional dyspnea and non-productive cough**

A. Diagnosis?

LBBB

B. First step in Management:

Rule out any other serious causes ( not sure)



**Q5: 50 years old patient, no dyslipidemia, diagnosed with Diabetes this year and his HbA1c was: 7.8, has a family history of liver disease, presented to the clinic with fatigue and joint pain which he attributes to diabetes**

**(Ferritin was high, CBC normal):**

**A. Give 3 ddx:**

Hereditary Hemochromatosis, autoimmune Hepatitis, osteoarthritis

**B. Management:**

Rule out any other serious causes and if Hemochromatosis dx was confirmed > Blood donation or Phlebotomy

**Q6:**

**A. Define Comprehensive Geriatric Assessment:**

Multidisciplinary diagnostic and treatment process that identifies medical, psychosocial, and functional limitations of a frail older person in order to develop a coordinated plan to maximize overall health with aging

**B. Mention four of its domains:**

1- Nutritional status 2- Medications 3- Functional Status 4- Cognitive status

**Q7: Difference between patient centered and doctor centered ( past) mention 3 points:**

1. Letting the patient explore the nature of his problem
2. Strengthening patient Autonomy
3. Considers Patient thoughts

**Q8: 17 year old male, with fever and inflamed tonsils:**

**A. Which of the following is the least likely in a bacterial tonsillitis:**

1. Fever
2. Exudate
3. Malaise
4. Posterior Petechiae
5. Rhinorrhea

**B. Tool for assessment?**

Centor Criteria

## 9th rotation

**Q1: You're about to break the news to a 60 year old patient that she has incurable cancer, she already expressed she wants minimal knowledge about the situation.**

A. How will you speak to her using SPIKES?

(so like write the questions and sentences you'd say to her)

B. What is the most common and most lethal cancer for this patient.

Most common: breast cancer.

Most lethal: lung cancer.

**Q2: Labs for a patient with microcytic anemia, MCV was 60 the normal range for labs were available.**

A. How will you tell the patient about their results?

B. Diagnosis? Microcytic anemia

C. What are the causes? IDA, thalassemia, anemia of chronic diseases.

**Q3: ECG shows SVT**

A. Describe the ECG.

B. DDx.

**Q4: What is the difference between senescence and aging?**

**Q5: One physiological change in geriatrics MSS**

Answer: decrease muscle mass

**Q6: You have a cardiac patient that you want to REFER i dont remember the details but the question was what are your responsibilities as the doctor referring this patient regarding**

A. The patient

B. The cardio doctor

**Q7: Give 3 ddx for each of the following:**

A. 60 year old with 1 week headache

Answer: Migraine, Temporal Arteritis, HTN.

B. 40 year old with a headache of 2 months duration

Migraine, Tension headache, secondary to medication overuse (rebound headache).

## 10th rotation

**Q1: Answer the following:**

- A. Define homeostenosis
- B. What is homeostenosis a hallmark of?

**Q2: Give one hematological physiological change in geriatrics.**

**Q3: A 67-year-old married woman, name four screening tests recommended at her age.**

**Q4: A patient with hypertension (150/90 mmHg) confirmed on two separate visits and with home readings:**

- A. Give three pieces of advice to help manage his blood pressure.
- B. List three investigations you would order for this patient.

**Q5: Chest X-ray findings:**

- A. Mention two findings: bilateral diffuse infiltrates, cardiomegaly
- B. Most likely diagnosis:

Answer: Heart failure

**Q6: Scenario-based question:**

- A. What is the type of difficult patient described in the scenario?

Answer: Entitled Demander

- B. Mention three communication strategies you would use with them.

**Q7: Give two most common differential diagnoses for each:**

- A. 27-year-old female with low back pain for 4 months
- B. Elderly female with low back pain for a few days

**Q8: An elderly male with a unilateral painful rash on his chest for 5 days:**

- A. Name two risk factors you would ask about in history
- B. Would you give medication? And why?
- C. What is the name of the medication you would give?

# 019 Mini-OSCEs

## 1st rotation

**Q1: A 19 year old male patient visit the clinic complaining off sore throat 3 times, what is the type of consultation you will use?**

Stott and Davis

**Q2: Mention 2 physiologic changes in geriatric immunity.**

1. Decrease the cellular immunity.
2. Increase the autoantibodies.

**Q3: 29 year old female with low back pain for 10 days duration.**

A. Mention top 2 DDx:

1. UTI
2. Truma

B. If there is fever what is your ddx?

Osteomyelitis, pyelonephritis

C. What is the ddx for a 82 year old with the same complaint?

Herniated disc?

**Q4: Mention and explain 5 things or strategies that can be used with anger patients?**

Remain calm, establish eye contact and step back trying to analyse what is happening then ask the patient to sit down and try to adopt a similar position (the mirroring strategy), address the patient by the appropriate name, listen intently allowing patients to ventilate their feelings, then giving appropriate reassurance, allow time at least 20 minutes). If a threatening aggressive patient, I'll set the closest to the door to allow escape.

**Q5: A 80 year old female patient with unilateral headache and shoulder pain.**

A. What's most serious differential?

Temporal arteritis?



**Q6: A 43 year old male, smoker with well controlled HTN. He Concern about his health because his friend was diagnosed with lung cancer.**

A. Name and explain the appropriate tool of counseling can be used to address the risk factors of the patient?

4As:

Ask clinical questions.

Acquire the best evidence.

Assess the evidence / critical appraisal. (importance, validity, relevance, consistency).

Apply evidence to patient care.

B. Name 2 modalities of treatment?

**Q7: A 72 year old patient with history of fatigue with CBC (Hb: 10.2, MCV: 102).**

A. What is the diagnosis?

Anemia

B. What's predicted to seen on blood film?

Macrocytic anemia

C. Mention 3 causes:

1. B12 deficiency
2. Folate deficiency
3. Medication (MTXJ, Phynetoin)
4. Alcoholism

**Q8: Elderly female with history of bilateral symmetrical hand joints pain, that is better at morning and becomes worse after daily activities, no stiffnes. (Pic of hand with swollen joints)**

A. What is the diagnosis?

Osteoarthritis.

B. Mention 2 deformity seen in the image.

1. Heberden nodes
2. Abnormal extension of the PIPs?

C. A test to confirm the dignosis?

X-ray.

## 2nd rotation

**Q1: A 45 year old man with the following lab results (normal ALT, AST and elevated ALK, GGT, Bilirubin), give 4 ddx:**

1. Primary biliary cholangitis.
2. Primary sclerosis colangitis.
3. Choledocholithiasis.
4. Cholestasis.

**Q2: Define Healthy aging.**

The process of developing and maintaining the functional ability that enables wellbeing in older age

**Q3: A 41 year old woman has concerns because her 83 year old father died in colon cancer, mention 4 screening tools you will advise her to do.**

HTN, Depression, DM, colonoscopy

**Q4: Mention 4 risk factors for colorectal cancer.**

Smoking, Alcohol, IBD, Obesity

**Q5: How does patient-centered medicine differ from doctor-centered medicine, explain with details in 3 points.**

**Q6: A 24 year old female has abdominal pain for 2 days.**

A. Give 2 ddx.

1. Menstrual cycle pain.

2. UTI.

B. If the pain started 2 months ago, give 2 ddx.

1. IBD.

2. Peptic ulcer disease.

C. If the patients' age was 83, give 2 ddx.

1. Acute appendicitis.

2. Diverticulitis.

**Q7: A 23 year old female is complaining of moderate unilateral headache for a few days, otherwise she is medically free except for attacks of numbness along the last year.**

A. What is the most serious differential you have?

Brain tumor.

B. What is your first investigation modality?

Brain MRI.

## 3rd rotation

**Q1: Mention 2 ddx for weight loss 2 month.**

A. In a 23 year old patient.

1. Eating disorders.
2. IBD.

B. In a 70 year old patient.

1. Cancer.
2. DM.

**Q2: Mention 2 examples in facilitation.**

Not sure about the answer 🤔🗨️

1. A head-nod 🙄
2. "Tell me more about that"

**Q3: Case with these laboratory findings; ALP 600, GGT AST ALT within normal range give 2 ddx.**

1. Paget's Disease of Bone.
2. Malignancy.
3. Primary hyperparathyroidism.

**Q4: Give one example BADL and IADL name score.**

BADL: Katz Index

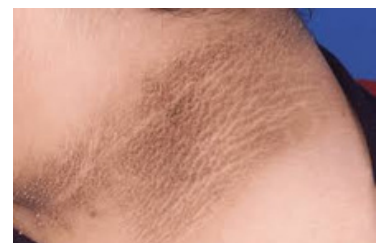IADL: Lawton Scale

**Q5: Obese patient with this picture.**

A. Name of skin lesion.

Acanthosis nigricans.

B. Lab test to do.



HbA1c, Fasting blood sugar

C. 3 Patient-centred medicine.

ABC (Anxiety, belief, concern)

**Q6: Case patient with cough and fever (+ x ray)**

A. Describe finding in x ray.

B. Give prevention method to prevent recurrent attack.

**Q7: Patient with high blood pressure.**

A. 2 lab investigations.

TSH, KFT.

B. 2 Advices to the patient.

1. Avoid salt diet.

2. Regular exercise.

C. 1 Secondary prevention.

DM screening.

## 4th rotation

### Q1: Homeostenosis

A. Define.

Narrowing of the body reserve capacity that leads to Decrease ability to maintain or restore homeostasis under certain stress.

B. Give two consequences/outcome.

C. Give an example.

Increasing the oxygen demand to the heart in a healthy young adult meets an increase in the cardiac output (heart response), however, in an elderly person, the heart cannot meet the demand and will augment the CO, this will lead to Myocardial infarction.

### Q2: Counseling vs Consultation.

Counseling: Therapeutic process of helping a patient to explore the nature of their problem in such a way that they determine their decisions about what to do, without direct advice or reassurance from the counsellor.

Consultation: Diagnostic procedure that is a systematic process of data-gathering designed to identify problems and to arrive at a conclusion, leading ultimately to treatment plan.

### Q3: Picture of a 14 year old's tonsils

A. Describe.

Hyperemic with exudate

B. Diagnosis.

May be bacterial tonsillitis

C. Give 3 clinical signs that help you.

Fever, enlarged tonsils, lymphadenopathy?

### Q4: Chest x-ray.

A. Describe the findings.

Cardiomegaly, bilateral chest infiltrate.

B. What is the Diagnosis & treatment?

**Q5: A 50 year old diabetic on metformin with image of ALT and AST levels only, ALT was elevated, AST normal.**

A. Give 2 ddx.

1. NAFLD.
2. Hepatitis.

B. Give 2 risk factors.

Obesity, Alcohol, DM.

**Q6: According to this picture.**

A. What is the diagnosis?

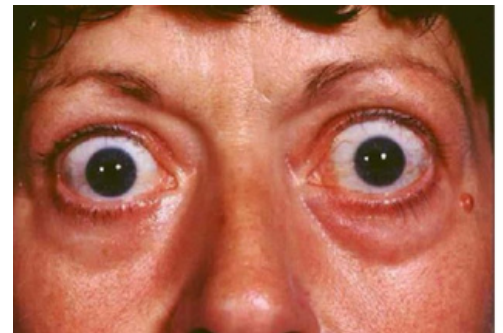Graves' disease.

B. Give 3 tests to confirm.

1. Thyroid function test (TSH, T<sub>3</sub> & T<sub>4</sub>).
2. TSH receptor antibodies.
3. Radioactive iodine uptake test.

C. Give 3 treatments.

1. B blockers (Propranolol) — to treat symptoms.
2. Anti thyroid drugs ( like Propylthiouracil).
3. Radioactive iodine therapy.
4. Surgery (Thyroidectomy).



**Q7: Give 2 ddx for knee pain with the most likely first for each of the following.**

A. A 22 years old male 2 days.

1. Fracture.
2. Meniscal Tears.

B. A 67 years old female 1 month.

1. Osteoarthritis.
2. Osteoporosis .

**Q8: Female with pain in hands came in clinic afraid she has rheumatoid.**

A. What do you want to tell her (picture of normal looking hands)?

## 5th rotation

**Q1: Write down the types prevention with their definition.**

- Primary prevention: prevent the occurrence of the disease by reducing the exposure to risk factor and promote the healthy behavior.
- Secondary prevention: Early detection of the disease (pre-symptomatic stages) to provide effective treatment this done by screening and regular checkups.
- Tertiary prevention: Detecting established incurable and unreported disease with a view to minimizing its harmful effect by appropriate treatment and rehabilitation.

**Q2: History of a child most probably with Asthma.**

A. What is a 4 questions you would ask?

B. Management.

**Q3: ECG (sinus tachycardia) + hyperthyroidism, what tests you would do?**

**Q4: Male with high Creatinine Kinase that was found incidentally.**

A. What 2 questions you would ask?

B. Management.

**Q5: Give 2 changes in nervous system in elderly.**

1. Small decrease in brain mass.
2. Decreased brain blood flow and impaired autoregulation of perfusion.



**Q6: X-ray for femoral head fracture.**

A. What is the screening tool?

Dexa scan (I think)

B. What is the 2 labs you would do?

B. When you start to screen for it?

If the Q ask about osteoporosis:

Females 65 and older.

Males 70 and older.

**Q7: Most common ddx for SOB in each of the following.**

A. A 21 year old patient.

Anxiety.

B. A 83 year old patient.

CHF, COPD.

**Q8: Doorknob.**

A. Definition.

The raising of a patient concern that happens as the doctor puts his or her hand on the doorknob to allow the patient to leave the room.

B. What a question you would ask to be proactive?

C. Causes/why it happens?

Full waiting room?

D. What is this phenomena called?

“Oh, by the way doctor” syndrome in the USA

E. How to avoid it?

Let patients know in advance that closure is being planned (and why) to allow them to not feel pushed out of the room (e.g. in case of a full waiting room).

## 6th rotation

**Q1: Mention 3 vaccination in elderly (with doses).**

1. Pneumococcal vaccine.
2. Herpes zoster.
3. Influenza.

**Q2: Define countertransference and give an example.**

Emotional involvement in the therapeutic interaction (feelings which the doctor has towards his patient).

**Q3: Blood film with 3 scenarios asking you to mention the type of anemia if this blood film belong to this patient and why?**

- A. A 28 year old female and this blood film for her 6 years ago before marriage.
- B. A 41 year old female.
- C. A 78 year old male.

**Q4: Patient with headache and nausea for 2 months.**

- A. Give 2 ddx.
  1. Migraine.
  2. Sinusitis.
- B. What 2 questions you would like to ask the patient in the history?
  1. Site, unilaterally or bilateral.
  2. Medications.

**Q5: A 3 year old boy was playing with his small toys and then he complaint of abdominal pain his mother brought him and you did x ray (+ x-ray image).**

- A. RAPRIOP for his mother.

**Q6: Mention Scott and Davis tasks.**

1. Manage presenting problem.
2. Manage continuing problems.
3. Modify health-seeking behaviors.
4. Opportunistic health promotion.

**Q7: A 11 year old female her father states that in the past 8 months she's withdrawn and has abdominal pain with no organic cause.**

Not sure about the answers :)

A. What is your top differential diagnosis?

Depression

B. What do you think the cause of her illness?

Psychosocial stress

C. What tool of screening you would use?

PHQ2, PHQ9

**Q8: Patient with uncontrolled DM with random blood glucose always above 200, complain of fatigue.**

A. Causes of his fatigue.

Hyperglycemia.

B. Causes of his uncontrolled DM.

Inadequate Medication Adherence

C. " ICE " of patient centered medicine.

Ideas: Understand the patient's thoughts about their condition and its management.

What do they believe is causing their uncontrolled blood glucose and fatigue?

Concerns: Identify the patient's concerns or worries related to their condition and treatment. Are they worried about the side effects of medications, or do they have concerns about the impact of diabetes on their daily life and long-term health?

Expectations: Clarify what the patient hopes to achieve with their treatment and management plan. What are their expectations for managing their diabetes and addressing their fatigue? Are they looking for specific outcomes or improvements in their quality of life?

## 7th rotation

**Q1: Give an example of:**

- A. A leading question.
- B. A reflective question.

**Q2: Define healthy aging according to WHO.**

The process of developing and maintaining the functional ability that enables wellbeing in older age.

**Q3: Give a ddx for each of the following.**

A. Lower abdominal pain for 2 month in a female. (2 ddx)

- 1. Ovarian cyst.
- 2. Bowel obstruction.

B. A serious ddx.

Colon cancer.

C. A ddx if the duration was 1 day.

Menstrual cycle pain.

D. A ddx if the patient is male.

IBD/ diverticulitis

**Q4: Picture of a lady looking anxious and depressed.**

A. Describe her body language.

B. The tool you use to assess her

PHQ9.

C. Diagnosis.

Depression.

**Q5: Labs of a lipid profile of a male.**

- A. Interpret the results.
- B. How you would approach?
- C. 2 questions to ask in history.
- D. How you will manage him?

**Q6: ECG picture.**

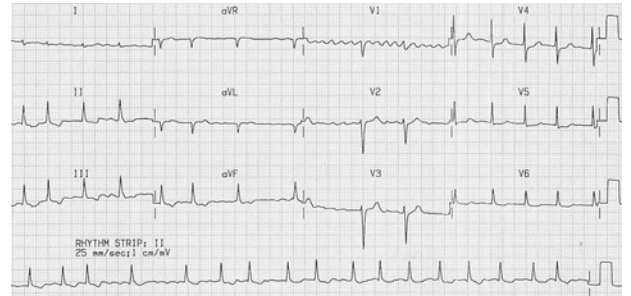
- A. Spot diagnosis.

Atrial fibrillation.

- B. How you manage?

Unstable Afib: Perform emergency electrical cardioversion.

Stable Afib: Rate control with B blockers or CCB



**Q7: According to this picture.**

- A. Spot diagnosis?

Bells palsy

- B. Mention one cause

Viral infection



**Q8: X-Ray of Colles' fracture in a 66 female. :)**

- A. Diagnosis

Colles' fracture

- B. Risk factor

Osteoporosis

- C. How you would approach her

## 8th rotation

### **Q1: ECG of premature ventricular contractions.**

A. Describe the ecg

No p wave and wide QRS complex

B. Causes

1. Hypoxia

2. Electrolytes abnormalities

C. Drug to give

Asymptomatic - R/o Heart Disease & B-Blockers & EPS +/- ICD/Ablation

Symptomatic - B-Blockers + Rx Cause

### **Q2: A patient coming to the clinic asking for vitamin D for herself and her daughter. Her labs show high calcium and low phosphorus levels.**

A. Diagnosis

B. Cause

C. Management

### **Q3: Labs showing low WBC, low neutrophils and high lymphocytes (with normal Hb).**

Not sure 100% 🧠

A. Diagnosis

Viral infection

B. Management

Supportive care

C. What in the labs confirms your diagnosis?

High lymphocytes count

**Q4: Shoulder pain, give "1 intrinsic and 1 extrinsic" differential diagnosis in the following cases.**

The answers from chatgpt 🤖💻

A. A 60 yo patient of 2 weeks right shoulder pain.

**Intrinsic: Rotator Cuff Tendinitis/Tear.**

**Extrinsic: Cervical Radiculopathy.**

B. A 60 yo patient of 2 days left shoulder pain.

**Intrinsic: Acute Bursitis.**

**Extrinsic: MI.**

C. A 20 yo or 30 yo patient of a month (not sure about the duration) & right should pain.

**Intrinsic: Shoulder Labral Tear (e.g., SLAP Tear).**

**Extrinsic: Glenohumeral Joint Instability.**

**Q5: A picture of someone who probably looks anxious (he was playing and looking at his hands while talking)**

A. Causes.

B. What do you want to ask him in history.

**Q6: X-ray of an elderly who takes insulin and has cough or whatever respiratory symptom**

A. Diagnosis.

B. What do you want to ask in history?

C. Management.

**Q7: CNS physiological changes in elderly (mention 2)**

1. Small decrease in brain mass.

2. Decreased brain blood flow and impaired auto-regulation of perfusion.

## 9th rotation

**Q1: Give three pertinent characteristics of geriatric syndromes/giants?**

not sure if these are the required answer.

1. Each Geriatric Giant does not stand alone.
2. There is a constant interplay, interdependence and interaction among all the Geriatric Giants.
3. Identifying and responding to one identified Geriatric Giant will impact upon all the Geriatric Giants.

**Q2: A 76 year old male comes to the clinic with his daughter requesting complete checkup.**

A. Give two important factors which must be taken into consideration when ordering the screening test.

Age and Family history of diseases?

B. Mention four screening tests and the disease they screen for?

HTN, DM, Osteoporosis, Dyslipidemia .

**Q3: Give two ddx for abdominal pain according the probability in order for each of the following?**

A. A 41 year old female with upper abdominal pain of 2 days duration.

1. Peptic Ulcer Disease.
2. Cholecystitis.

B. A 41 year old male with recurrent upper abdominal pain of 2 months duration.

1. GERD.
2. Chronic pancreatitis.



**Q4: Female present with PE.**

A. Give 3 important questions in the history that will aid the diagnosis.

1. History of DVT.
2. Recent major surgery with prolonged immobilization.
3. Using of OCPs.

B. MCQ: The presence of which of the following most likely supports the diagnosis of PE?

- Fever 38.
- SOB.
- Chest pain.

The answer is chest pain.

# 018 Mini-OSCEs

## 1st rotation

**Q1: Define "healthy ageing" per WHO.**

The process of developing and maintaining the functional ability that enables wellbeing in older age

**Q2: Mention the two most common ddx for dizziness in the following two scenarios:**

A. A 23 year old female for 1 day.

Anxiety, BPPV.

B. A 70 year old male for two months.

Polypharmacy, anemia.

**Q3: A picture shows transference.**

**Q4: Mention 4 screening test for a 65 year old female.**

DEXA scan for osteoporosis, colonoscopy for colon cancer, HbA1c for DM, Mammogram for breast cancer

**Q5: A mammogram showing calcifications indicating breast cancer. What main points would you consider in delivering bad news to this patient?**

Explain using ABCDE or SPIKES approach

A: Advanced preparation: to ask what the patient already knows or understands, arrange place and time, decide what words and phrases to use.

B: Build a therapeutic environment / relationship: Arrange private place, sit close to touch when appropriate.

C: Communicate well: be direct, without jargons, use repetition and written explanation

D: Deal with reactions: listen, explore feeling and express empathy.

E: Encourage and validate emotions: address further needs, evaluate the effect of the new.

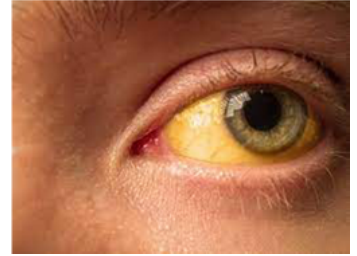**Q6: Patient with midgastric abdominal pain associated with nausea, vomiting once as well as fever.**

A. Mention the two most probable differential diagnoses.

Cholangitis, Mirizzi syndrome.

B. Mention three investigations you'd order next.

Ultrasound, Liver enzymes, total bilirubin.



**Q7: A picture of labs for the previous question.**

A. Describe the labs:

Mildly high ALT and AST, high ALK and GGT, very high bilirubin).

B. What is the most probable diagnosis now?

Acute cholangitis.

**Q8: Mention two indications for ordering ferritin labs.**

Fatigue, pallor, hair loss, dizziness.

## 2nd rotation

**Q1: Patient with elevated multiple abnormal BP readings.**

A. Mention 4 investigations you'd order to the patient.

TSH, ECG, urine analysis, KFT.

B. Mention 3 classes of drugs that used to treat the patient's condition.

CCB, ACEI, ARBS, DIEURETICS.

**Q2: Young male came to the clinic complaining from chest pain and fever for 3 days.**

A. Describe the ECG.

Diffuse PR depression and ST elevation.

B. What is the most likely diagnosis?

Acute pericarditis.

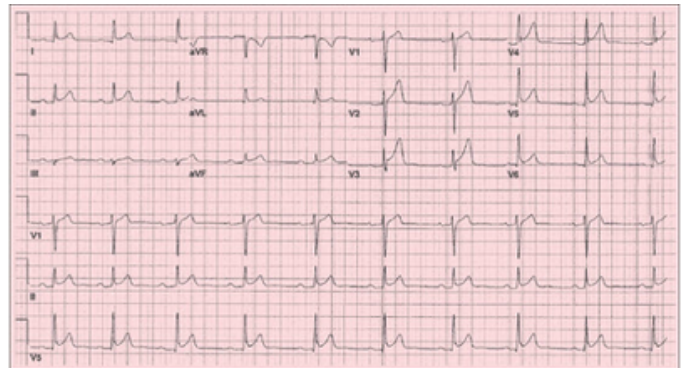
C. Mention other 4 possible diagnosis

Pneumonia.

Asthma exacerbation.

Infective endocarditis.

Myocarditis.



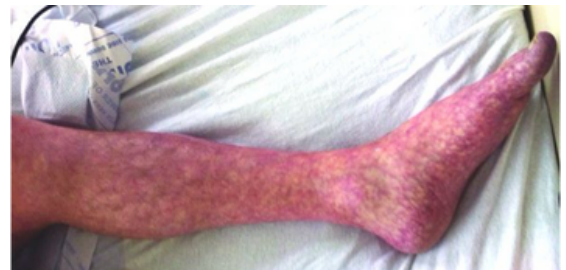**Q3: According to this picture answer the following.**

A. What is the differential diagnosis?

Livedo reticularis.

B. What you will advise the patient?

Avoid extreme heat and cold exposure to the legs.



**Q4: Mention 2 physiological changes in the respiratory system of geriatric patients.**

Decrease lung mass , chest wall stiffens.

**Q5: According to this picture answer the following.**

A. What is the differential diagnosis ?

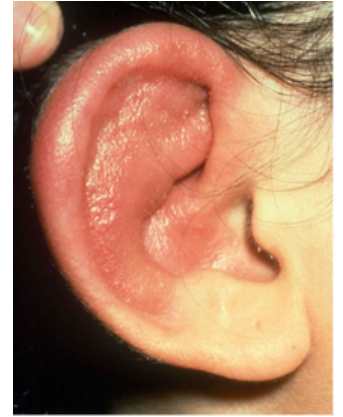Aural perichondritis.

B. What is the microorganisms that cause it

*P.aeruginosa*, *S. Aureus*.

C. Mention 3 risk factors.

Ear piercing, trauma, DM, swimming.



**Q6: Explain Stott and Davis 4 tasks.**

A: Management of presenting problems.

C: Management of continuing problems.

B: Modification of health seeking behavior.

D: Opportunistic health promotion.

**Q7: 60 years old male, complains from dyspnea for 3 months duration, CXR was done for him and it is shown below.**

A. Describe the CXR.

Diffuse bilateral pulmonary infiltrate.

B. Mention 2 question you will ask in the history.

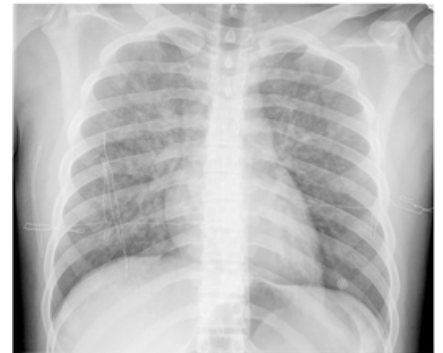Hemoptysis, weight loss, night sweat.

C. What is the most likely differential diagnosis?

TB

D. Mention one question that will help to reach the DDx.

Travel history.



## 3rd rotation

**Q1: A 22 year old female, complaining of palpitations that increased with exercise.**

A. Describe the ECG.

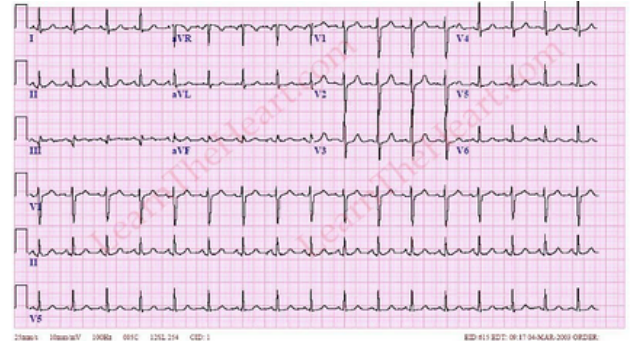
Sinus tachycardia (high rate, narrow QRS preceded by p wave, regular sinus rhythm).

B. Mention two causes.

Anxiety, anemia.

C. What two blood tests would you order if she told you she is picky with her diet?

CBC, Ferritin levels



**Q2: Write 4 screening tests for a 55 year old smoker with a 30 year pack history.**

Low dose CT, HbA1c, Lipid profile, Blood pressure measurement, PHQ2/PHQ9 for depression, HIV serology.

**Q3: Give two ddx (one common and one uncommon) for the same complaint in two individuals for headache:**

A. A 23 year old woman.

Common: Tension headache.

Uncommon: Subarachnoid Hemorrhage.

B. Elderly man.

Common: Tension headache.

Uncommon: BRAIN tumor.

**Q4: According to this picture answer the following.**

A. Describe this picture.

Elderly patient with facial deviation towards the left side, drop of the mouth, loss of the wrinkles above the right eye, inability to close the right eye.





B. What's your spot diagnosis?

Bell's palsy.

**Q5: Define homeostenosis.**

Narrowing of the body reserve capacity that leads to Decrease ability to maintain or restore homeostasis under certain stress.

**Q6: A 55 year old man, complains of progressive shortness of breath for years, worse in the winter. Last three days had cough with productive green sputum. 50 pack years, refuses to stop smoking. X-ray shown.**

A. Describe two radiological findings.

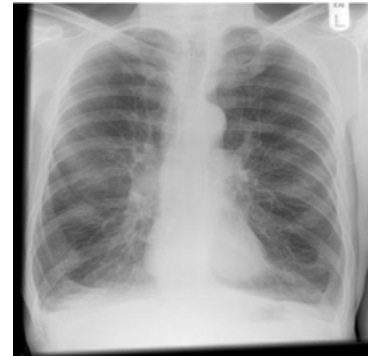
Hyperinflation ,Diffuse pulmonary infiltrate.

B. What is the most likely diagnosis?

Exacerbation of COPD.

C. What tests would confirm your diagnosis?

PFT, sputum culture, BNP to rule out HF.



**Q7: Man presented with facial coloring from 2 days before.**

A. What are three important questions to ask in the history?

Alcohol intake, abdominal pain, fever.

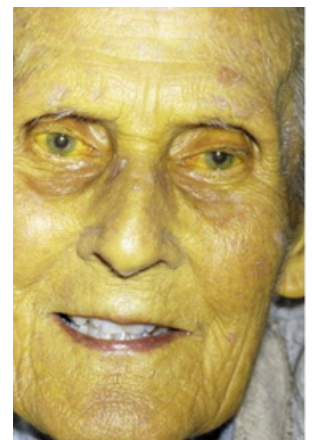
B. What is one important question to ask to differentiate between benign and malignant causes of this condition?

Weight loss, decrease appetite, night sweats.

C. Give one benign and one malignant cause of this condition.

Benign: Acute cholecystitis.

Malignant: Pancreatic cancer.





## 4th rotation

**Q1: A 21 year female presents with left eye irritation, tearing, and foreign body sensation with no pain for 1 day duration.**

A. Describe the image.

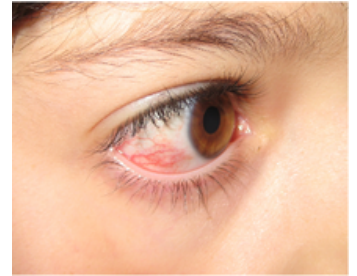
Redness of the white part ( sclera ) without any discharge , or excessive lacrimation.

B. Mention 2 likely differential diagnosis.

Episcleritis, viral conjunctivitis.

C. What is the Most likely diagnosis?

Episcleritis.



**Q2: These are lab findings for non pregnant 55 years old female.**

**T3:103 (normal), T4: 4, TSH: 9**

A. What is the Diagnosis?

Subclinical hypothyroidism.

B. Mention 2 possible causes.

Iodine deficiency, chronic autoimmune thyroiditis.

C. What is the next step?

give Levothyroxine.

**Q3: 45 years old man with HbA1C : 6.3**

A. What is the diagnosis?

Impaired glucose tolerance.

B. Mention 2 risk factors.

Obesity, lack of exercise, hyperlipidemia.

C. What is management?

Repeat HbA1c before confirm the diagnosis, and if the HbA1c is still in the range between 5.7 and 6.4, the diagnosis is confirmed (pre-diabetic) and metformin is given with life style modification advice.

**Q4: Mention 2 ddx (one serious) for each case below.**

A. Shortness of breath for 1 day duration in 24 year old female.

Pulmonary embolism, panic attack.

B. Shortness of breath for 3 months in a 55 year old male.

Angina pectoris, COPD, anemia, lung CA.

**Q5: ECG**

A. What is the Diagnosis?

Atrial fibrillation.

B. Mention 3 clinical symptoms.

SOB, chest pain, palpitations, dizziness.

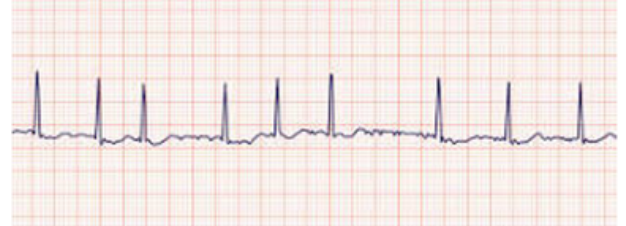C. Mention 2 causes.

Hypertension, mitral stenosis, hyperthyroidism.

D. What is the management?

If unstable: Synchronized cardioversion.

If stable: Rate control with b blockers or CCBs.



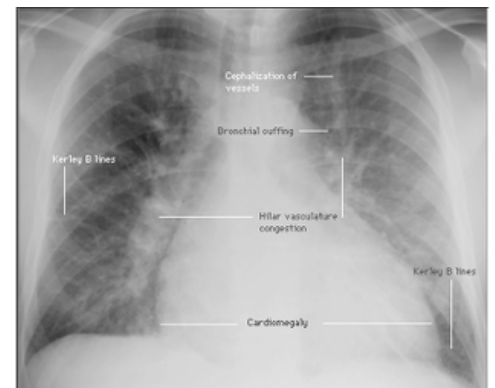
**Q6: A 25 year old male with symptoms of heart failure (severe dyspnea) and chest pain with inspiration. He took covid-19 vaccine last week.**

A. What is the Diagnosis?

Myocarditis (Also, Dr accepted pericarditis).

B. What is the management?

Admission + NSAID for pain + treat as heart failure (b blockers, ACEI, Diuretic if needed).



**Q7: Picture of old man:**

A. What is the definition of geriatric syndromes?

A term used to describe the common conditions and/or syndromes that can adversely impact a senior's functional abilities.

B. Mention 2 of them.

Depression, delirium.

## 5th rotation

### Q1: Answer the following:

A. What does each letter in the acronym HEADSSS stand for?

H: Home; E: Education/Employment; A: Activities; D: Drugs and Dieting; S: Sexuality; S: Suicide; S: Safety.

B. What is this acronym used for?

Used as an assessment tool when communicating with adolescents to evaluate risks and to recall points that should be covered when assessing an adolescent.

### Q2: Answer the following:

A. Define the Lawton scale.

An instrument used to assess the functional status/abilities of geriatric patients by evaluating eight different instrumental activities of daily living.

B. Name four elements of this scale.

Ability to use telephone, shopping, food preparation, housekeeping, laundry, mode of transportation, responsibility for own medications, ability to handle finances.

### Q3: An 18-year old patient presented with palpitations that had begun while playing tennis.

A. What is the diagnosis?

Supraventricular tachycardia.

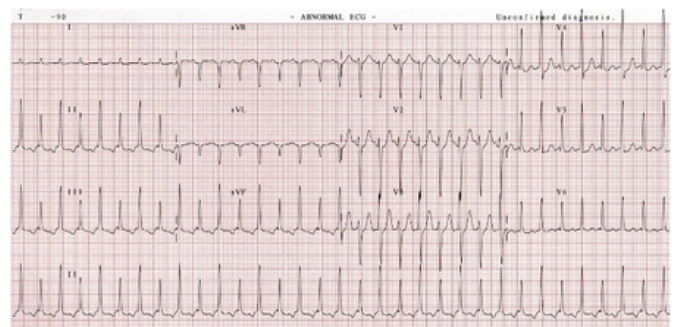
B. Name two non-pharmacological modes of treatment.

Vagal maneuvers (Valsalva maneuver, and carotid sinus massage)

Synchronized cardioversion if the patient is unstable .

C. Name one pharmacological intervention.

IV Adenosine.



**Q4: Mention two indications for statin therapy (one for primary prevention, and another for secondary prevention).**

Primary prevention: A patient with NO history of atherosclerotic cardiovascular disease who has an LDL > 130 but < 190 and a high 10-year ASCVD risk score (> 10%?)

Secondary prevention: A patient with a history of atherosclerotic cardiovascular disease (e.g., myocardial infarction, stroke, etc.)

**Q5: A 6 year old male patient comes to you complaining of “shaky hands” of three weeks duration.**

A. Mention four questions that can help you identify the cause of the patient’s complaint.

1. Does the patient take any specific medications (e.g., B<sub>2</sub>-agonists)?
2. Does the tremor increase with anxiety?
3. Do any family members have a similar tremor?
4. Does the tremor occur with movement or at rest?

B. Name two possible neurological and two possible non-neurological causes.

Neurological: Cerebellar stroke, Parkinson’s disease.

Non-neurological: Drug-induced tremor (B<sub>2</sub>-agonists), Hyperammonemia (due to liver cirrhosis).

**Q6: What is the difference between “illness” and “disease”?**

Disease is a pathological condition with an organic cause while illness refers to a condition that the patient finds debilitating or one that impairs his functionality (from the patient experience).

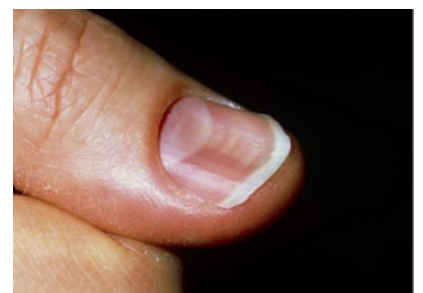**Q7: An 18 year old female patient has the nail findings shown in the picture**

A. What is the name of this finding?

Koilonychia (spoon-shaped nails).

B. Name two differential diagnoses.

IDA ,lichen planus, repeated exposure to detergents.



## 6th rotation

**Q1: A 41 year old female patient was concerned because her mother died at age 84 due to colon cancer, what would you advice her to do/no to do? (Mention 4 screening tests)**

Mammogram annual for breast cancer, blood pressure reading annually for hypertension, pap smear every three years for cervical cancer (or with HPV every 5 years), lipid profile every 5 years for dyslipidemia.

**Q2: Female in the 12 grade presented with recurrent attacks of headache in the past week.**

A. Mention 2 differential diagnoses.

Tension headache, migraine.

B. Mention 2 questions you would ask to aid you in diagnosis.

1. Describe the site of the pain (bilateral like a band vs unilateral).
2. Does the pain occurs at the end of the day or in the morning?
3. Has she been stressed lately?

**Q3: What is the CDC recommendation of pneumococcal and varicella zoster vaccine?**

Varicella vaccine once at or after the age of 60.

Conjugated pneumococcal vaccine once at or after the age of 65.

**Q4: According to this picture.**

A. Describe her body language.

Locked arms indicating defensive behavior (not open), depressed face.

B. What would you screen her for?

Depression

C. What is the screening test used?

Patient health questionnaire 9 (PHQ9).

D. What are the questions you would ask as patient centered?

- Are you anxious about anything?
- What do you believe is the problem?
- What are you concerned about?



**Q5: Male patient came with BP reading 170/120. urine analysis is shown (it revealed bacteria, mucus, protein +1, WBC 1-2, RBC 1-2).**

A. Give two ddx.

UTI, Hypertensive emergency.

B. Mention 2 questions you would ask him.

- Is there any feeling of frequency , urgency, pain with urination?
- Do you feel hotness or complains from chills, rigors?

C. What is the next step in management?

Control the blood pressure / start him on ACEI.

**Q6: Xray is shown.**

A. What's your spot diagnosis?

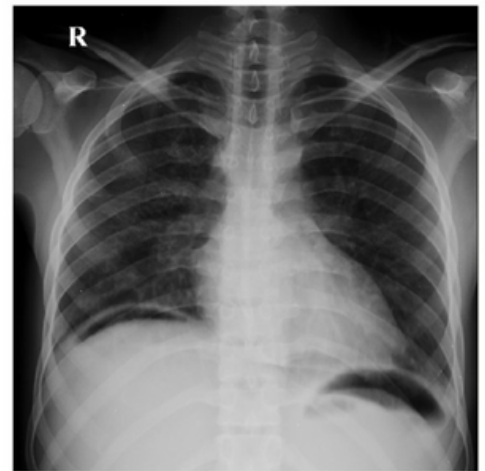
Air under diaphragm (perforated viscus).

B. Mention one risk factor.

Peptic ulcer disease/ recent endoscopy or surgery/ IBD.

C. What is your immediate management?

NPO, fluid and antibiotics, explorative laparotomy.



**Q7: Give 2 ddx for each, one common and one uncommon.**

A. Knee pain in 41 years old female for 1 day duration.

Common: Fracture, pseudogout.

Uncommon: Reactive arthritis.

B. Knee pain in 20 years old male for 1 day duration.

Common: Meniscal tear.

Uncommonm Septic arthritis.



## 7th rotation

**Q1: Give 2 top ddx for lower abdominal pain in these scenarios.**

A. A 23 year old female for two days.

Cyclical pain, UTI.

B. A 23 year old female for 2 months.

Pregnancy, recurrent ovarian cyst.

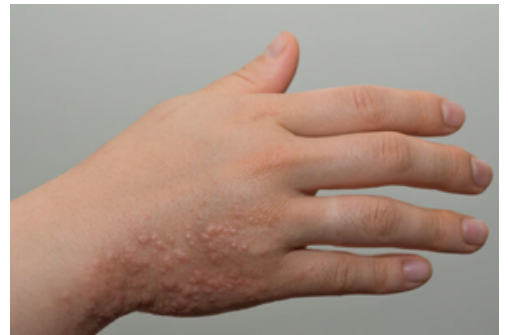**Q2: According to this picture.**

A. What is your spot diagnosis?

Shingles.

B. What is the next step in management?

Give acyclovir.



**Q3: Give 2 changes in the renal system of geriatric patient.**

Decreased potassium excretion and conservation.

Decreased concentrating and diluting capacity.

**Q4: A patient complains from testicular cancer, came to the clinic with SOB for 2 months.**

A. Describe the CXR.

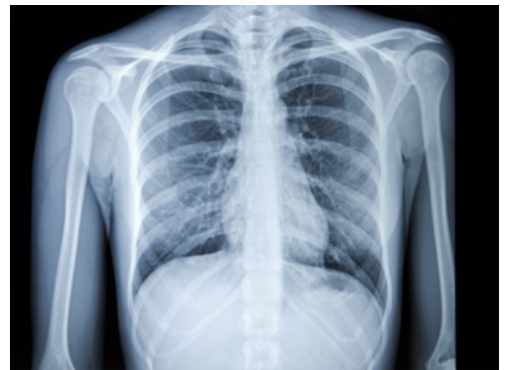Hilar lymphadenopathy, bilateral diffuse infiltrates.

B. What is the diagnosis?

Lung metastasis.

C. What is the management?

CT, PET CT.



\*Note: We don't know if the doctor mention the subtype of the testicular cancer, if we assume that the type is unknown, lab tests should be done to determine it: alpha-fetoprotein, B-HCG.

**Q5: According to this picture, answer the following.**

A. Describe what you see.

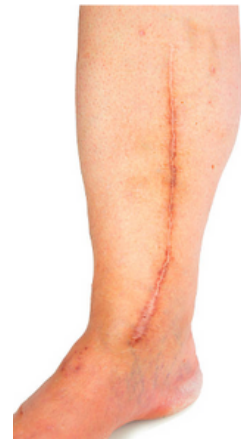Scar on the medial aspect of the leg below the knee to the medial malleolus, not infected (infected vs not infected), red in color (color), seems to be surgical scar (type of scar).

B. What is the diagnosis?

CABG scar.

C. Mention 2 risk factor.

Hyperlipidemia, smoking, HTN.



**Q6: According to this drug.**

A. Give 3 indications.

Thyroid storm, giant cell arteritis, CIDP.

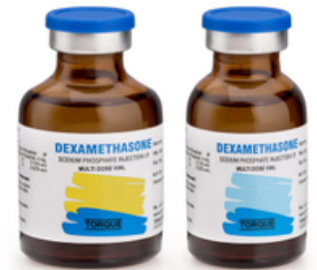B. Give 3 side effects.

Hyperglycemia, osteoporosis, low immunity.

C. If dexamethasone is given what is the concentration of it in the blood.

14 days after steroids injections, cortisol level remains lower than the ore injection level.

-not sure about the answer-



**Q7: PSA high level.**

A. What PSA indicate for?

Prostate specific antigen.

B. What is the importance of PSA test?

PSA test can detect high level of PSA which may indicate prostate cancer.

C. What is the next step of the management to reach diagnosis?

Prostate MRI (according to Amboss, but the resident said US).

D. What is the recommendation of PSA screening?

Men age between 55-69, grade C.

Men aged  $\geq 70$ , grade D.



## 8th rotation

**Q1: A 78 year old man presented with fatigue, had diarrhea and vomiting, BP: 115/80, random glucose 298, Sodium is: 125, rest of the labs are normal**

A. Give 2 reason for his fatigue.

Hyperglycemia (DM), dehydration leading to hyponatremia.

B. Mention 2 labs to confirm.

HbA1c, OGTT, Urine analysis.

C. What additional screening would you do?

FIT test for colon cancer & Lipid profile for hyperlipidemia.

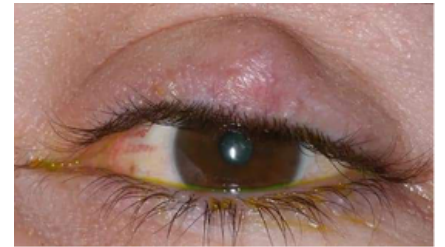
**Q2: Female patient complaining of eye swelling without fever, itching or redness**

A. What is your diagnosis?

Chalazion.

B. What is the Management?

Surgical excision, steroid.



**Q3: A 35 years old female presented with tremor and sweaty hands.**

A. Mention 2 most specific questions you'd in the history.

- Do you feel stressed in the last days?
- Do you complain from heat intolerance?

B. Write down 2 differential diagnosis.

Hyperthyroidism, anxiety and stress.

C. Order 2 lab tests.

TSH, T4

D. What would you give her to relieve the tremor during the diagnostic workup?

Propranolol.

**Q4: Explain “Doorknob presentation”.**

The raising of a patient concern that happens as the doctor puts his or her hand on the doorknob to allow the patient to leave the room.

**Q5: A 42 year old patient is angry after you refused to order MRI for her tension headache, mention 5 strategies to deescalate the situation.**

Rapport building, confrontation facilitation, clarification, searching.

**Q6: A 52 year old patient, history of ischemic heart disease presented with shortness of breath, CXR is shown:**

A. Describe chest x ray:.

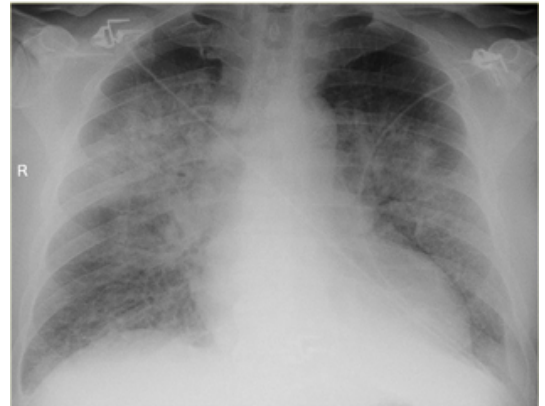Cardiomegaly, widened mediastinum  
& pulmonary infiltrates.

B. What is the Top differential?

Congestive heart failure.

C. What is the Medication of choice?

Furosemide.



**Q7: Mention 2 things to consider while prescribing a 87 year old man new medication.**

Drug-drug interactions (polypharmacy).

Life expectancy.

## 9th rotation

**Q1: Define multi-morbidity & comorbidity.**

Comorbidity: A group of morbidities in a single patient with one morbidity being the dominant.

Multi-morbidity: A group of morbidities in a single patient without a dominant morbidity.

**Q2: Give 2 ddx for these scenarios.**

A. Low back pain in male for 3 months.

Disk herniation, ankylosing spondylitis.

B. Low back pain in 60 years old female for 2 days.

Trauma, UTI.

**Q3: Explain the level of prevention and mention one example for each one.**

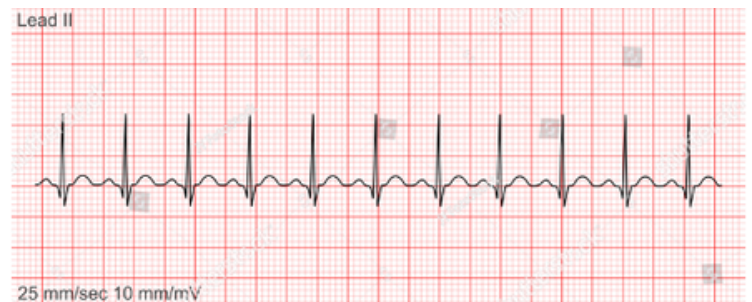**Q4: A 9 years old female complains from palpitation, her ECG is shown.**

A. Mention 2 question you will ask in the history.

- Does she feel chest pain?
- Symptoms of hyperthyroidism.

B. Give 2 lab tests you will order to her.

TSH, ferritin, CBC.



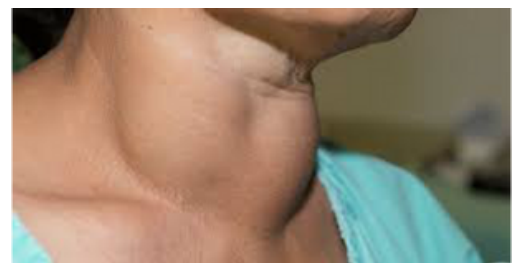**Q5: According to this picture.**

A. Give 3 ddx.

Thyroid disease (Graves, Hashimoto), thyroid nodule, papillary carcinoma.

B. What is the next step if all labs are normal?

US.

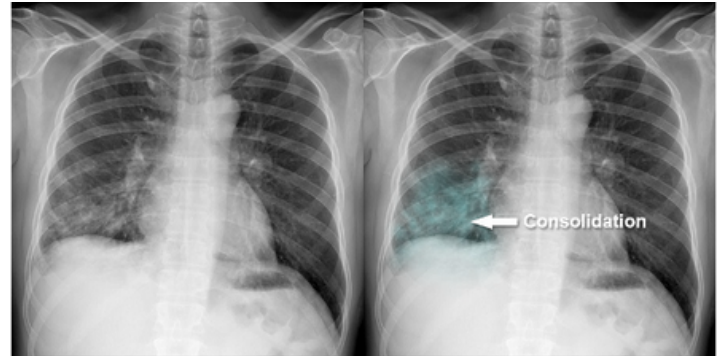


**Q6: According to this X-ray.**

A. Give 3 possible ddx.

Pneumonia, lung cancer, atelectasis.

B. Mention 4 question of patient centered medicine.



**Q7: A 23 years old female came to the clinic , CBC was ordered to her and these are the results.**

A. Give 2 ddx.

IDA.

Anemia of chronic disease.

B. 2 question you would ask her to reach the diagnosis.

- Ask about her diet, and menstrual cycle heaviness.
- Does she was diagnosed with chronic disease like SLE or scleroderma?

CBC		
Hb&Ht	:	10.8/35.4 g/dL
WBC	:	6.54 X10 <sup>9</sup> /L
MCV	:	73.1 fl
MCH	:	22.2 pg/cell
RBC	:	4.85 X10 <sup>12</sup> /L
MCHC	:	30.4 g/dL
RDW	:	16.9
Neut - Sig %	:	50.6 %
Eosinophil %	:	2.7 %
Basophil %	:	0.7 %
Lymphocyte %	:	38 %
Monocyte %	:	7.2 %
platelets count	:	243 X10 <sup>9</sup> /L
MPV	:	8.5 fl

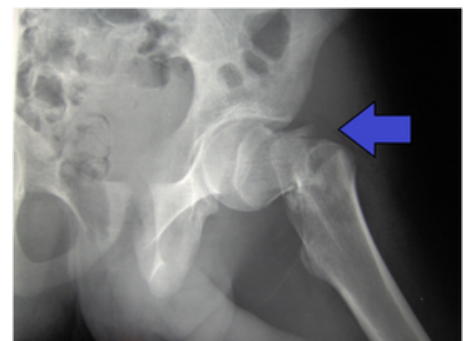**Q8: Elderly woman with a hip fracture + an x-ray (postoperative).**

A. What medication will you give her as secondary prevention?

Bisphosphonate.

B. When are women screened for this condition?

65 years and older.



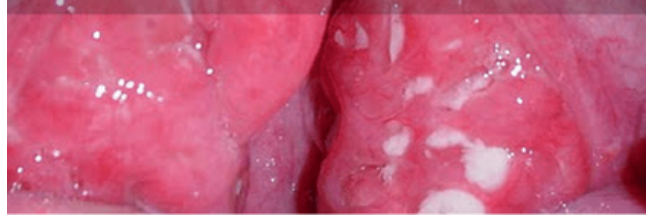## 10th rotation

**Q1: A 14 years old female presented with fever and sore throat.**

A. Give 2 ddx.

Viral tonsilitis (herps, EBV).

Strep throat.



B. What 5 criteria help you determine if you'll give antibiotics?

Centor criteria (age (4-13y), exudative tonsilitis, absent cough, temperature  $>38$ , tender or enlargement of anterior cervical lymph nodes).

**Q2: Give 1 common and 1 uncommon differential diagnoses in these 2 cases.**

A. Dizziness in a 21 year old female of 1 month duration.

Common: IDA.

Uncommon: Fibromyalgia.

B. Dizziness in a 78 year old male of 2 days duration.

Common: Dehydration.

Uncommon: BPPV.

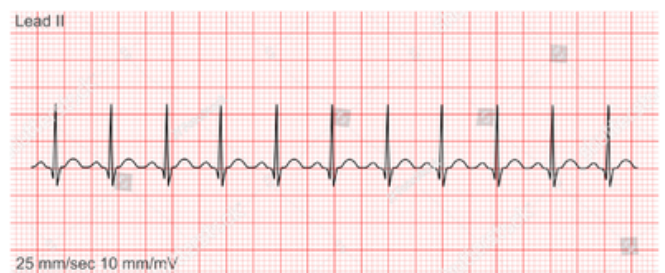**Q3: Woman presented to the clinic complaining from weight loss, sweating and palpitations.**

A. Describe the ECG.

Sinus rhythm, narrow QRS, preceded by P wave.

B. What is your top diagnosis based on the ECG?

Hyperthyroidism.



**Q4: Define homeostenosis.**

Narrowing of the body reserve capacity that leads to Decrease ability to maintain or restore homeostasis under certain stress.



**Q5: TFT results showing TSH: 6, T3 and T4 on the lower limit of normal.**

A. What's your diagnosis?

Subclinical hypothyroidism.

B. What one test you would do associated with the diagnosis?

Anti TPO antibodies.

**Q6: Patient came to the clinic complaining from exertional dyspnea.**

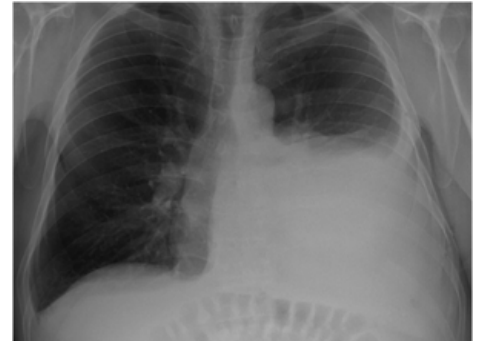
A. Describe what you see.

Unilateral blunting of the costophrenic angle on the left side homogenous density (pleural effusion).

B. What's your immediate management?

If the patient is unstable, begin with respiratory support

If the patient is stable, thoracentesis.



**Q7: Patient in her 20's felt a breast mass on self-exam, (MCQ).**

Ultrasound will be helpful in her case.

**Q8: According to the picture below.**

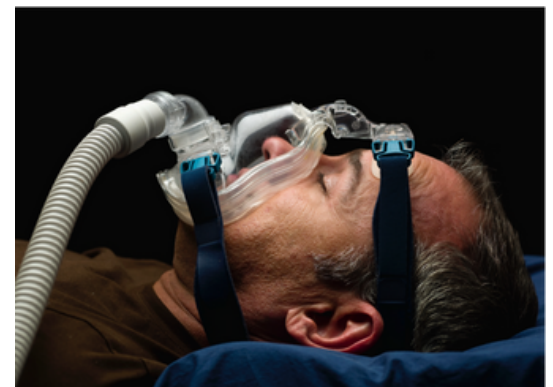A. What 2 modifiable risk factors for the patient's condition you will tell your patient to modify/control?

Weight reduction.

Smoking cessation.

B. Mention 3 complications that will occur if the patient doesn't use the device?

Respiratory acidosis, high BP, coma, convulsion.



# 017 Mini-OSCEs

**Q1: Scott and Davis: mention the 4 points.**

- A) Management of presenting problems.
- B) Modification of help seeking behaviors.
- C) management of continuing problems.
- D) opportunistic health promotion.

**Q2: Mention 3 screening tests and frequency in a 66 year old female.**

- A) Mammogram biennial.
- B) HbA1C annually.
- C) Osteoporosis DEXA every 2 years.

**Q3: Mention 2 ddx for each of the following.**

- A. Weight loss in a 21 year old female for 2 weeks .

Anxiety, eating disorders.

- B. Weight loss in a 78 year old male for 3 months.

Malignancy, DM.

**Q4: According to this picture.**

- A. What is your diagnosis?

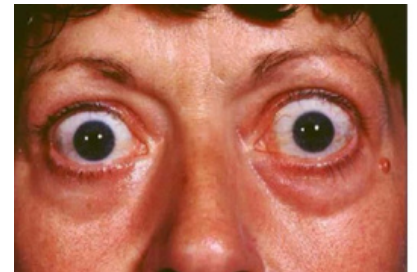Graves' disease.

- B. Mention 3 lab investigations to support it.

TFT, Radioactive iodine uptake, Anti-TSH (thyrotropin )receptor antibodies.

- C. Mention 3 treatments.

B- blockers, Anti thyroid drugs (Propylthiouracil), Radioactive iodine ablation.



**Q5: Write 2 physiological changes in elderly regarding the cardiovascular system.**

Impaired left ventricular filling.

Left atrial hypertrophy.



**Q6: Write 2 ddx for chest pain in each of the following.**

A. A 23 years old male with chest pain for 1 day duration.

Pneumonia, pneumothorax.

B. A 56 year old male with chest pain for 2 months duration.

Angina, heart failure.

**Q7: According to this test.**

A. What's the name of this test?

Dexa scan.

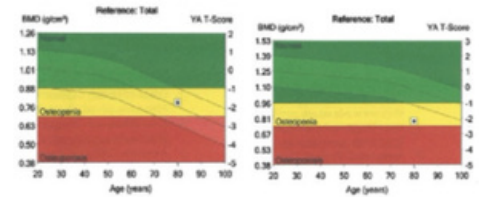
B. What it's used for and how often a person should do it?

Screening for osteoporosis. Should be done every 2 years.

C. What's the age when a female & a male starts screening?

For men evidence can't be assessed.

Every 2 years if women > 65 or in white women <65 with risk of fracture.



**Q8: Breaking bad news: mention SPIKES approach.**

S: Setting.

P: Perception.

I: Invitation.

K: Knowledge.

E: Emotion.

S: Summarize.

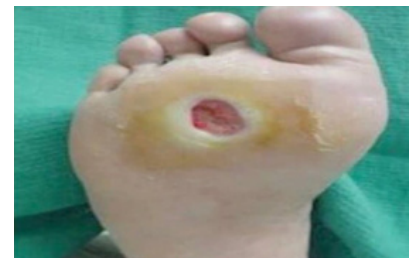**Q9: According to this picture.**

A. Describe this lesion.

Diabetic plantar foot ulcer.

B. What causes this lesion?

Diabetes: through lack of feeling in the foot, poor circulation, foot deformities and traumas as well as duration of diabetes.



**Q10: Mention 3 indications for counseling.**

1. Making a major decision or coming to terms with a major life event.
2. Chronic pain.
3. Sexual dysfunction, marital problem.

**Q11: Mention 2 diseases decrease immunity in adults.**

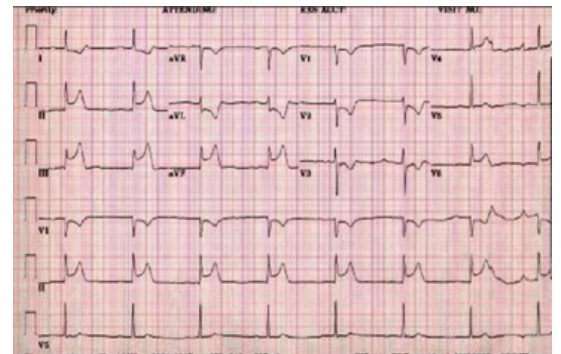
Diabetes, cushing syndrome

**Q12: According to this ECG.**

A. What's your diagnosis?

Acute inferior ST-elevation myocardial infarction.

B. Mention the steps in management.



**Q13: A hypertension patient.**

A. Mention 2 advices.

1. Eat DASH diet (low fat, low sodium).
2. Exercise (walk for 30-60 minutes, 5-7 days per week).

B. Mention 3 labs you would order for such a patient.

KFT, fasting blood glucose, lipid profile.

**Q14: An angry patient, state how you will deal with him.**

I will remain calm, establish eye contact and step back trying to analyse what is happening then I'll ask the patient to sit down and try to adopt a similar position (the mirroring strategy), address the patient by the appropriate name, listen intently allowing patients to ventilate their feelings and help to relieve their burdens, then giving appropriate reassurance, allow time (at least 20 minutes).

If a threatening aggressive patient, I'll set the closest to the door to allow escape.

**Q15: According to this picture.**

A. What's your diagnosis?

Thyroid goiter.

B. Mention 3 ddx.

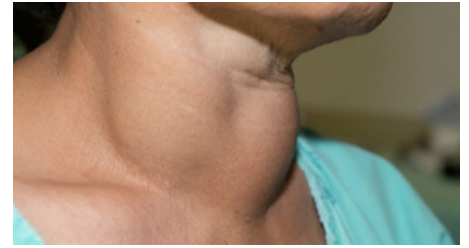Graves' disease, Hashimoto thyroiditis, Papillary carcinoma.

C. Top ddx in an elderly women?

Multi-nodular goiter.

D. Mention 4 steps in management.

1. Physical examination.
2. Test TSH.
3. Ultrasound,
4. Fine needle aspiration.



**Q16. Regarding to gluteal injection, mention 2 contraindications you need to ask the patient about.**

1. Muscular atrophy: delay drug absorption.
2. Thrombocytopenia or allergy to certain medications.

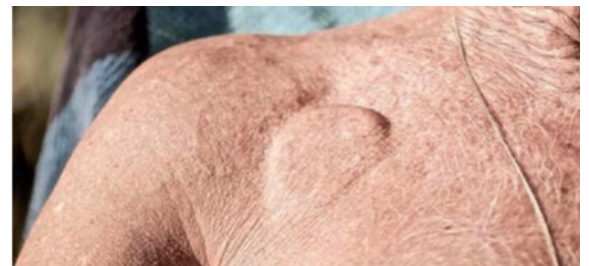**Q17: According to this picture.**

A. What is this?

A pacemaker.

B. Mention it's indication.

Sinus node dysfunction and high grade AV block.



**Q18: Differentiate between multi-morbidity & comorbidity.**

Comorbidity: A group of morbidities in a single patient with one morbidity being the dominant.

Multi-morbidity: A group of morbidities in a single patient without a dominant morbidity.

**Q19: Mention the reasons behind the failure of the consultation?**

The position of the doctor, there is a barrier between him and the patient, the doctor also seems to be busy with writing notes.



**Q20: A DM patient not compliant to her medications.**

A. Mention causes of non compliance.

The patient does not trust the doctor, not a good patient-doctor relationship.

B. Advice her.

Make a commitment to managing your diabetes because otherwise you will face DM complications; nephropathy, retinopathy, neuropathy and diabetic foot.

C. Mention 3 specific tests you would order for this patient.

HbA1C, renal function, lipid profile.

**Q21: According to this;**

A. What is the name of this test?

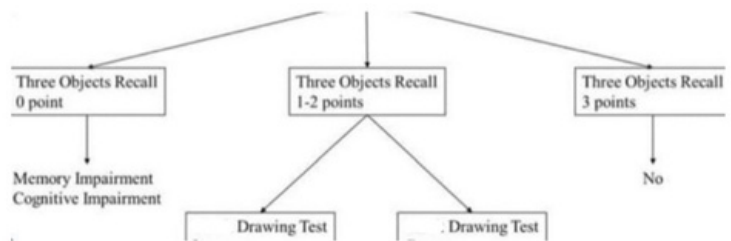
Mini cog test

B. What it's used for?

Rapid assessment of cognitive status.

C. What does the drawing refer to?

Drawing a clock.



**Q22: You are taking history from a patient.**

A. Write a leading question.

You didn't finish the course of antibiotics I prescribed, did you?

B. Write a reflective question.

How often do you exercise?

**Q23: What is the geriatric syndrome definition?**

Is the term used to describe a group of common health conditions in older people that do not fit into discrete disease categories. These conditions include frailty, functional limitations, falls, depression, polypharmacy, malnutrition and cognitive impairment.

**Q24: Mention 2 examples of geriatric syndromes that interact with each other and explain how.**

A) Constipation —> malnutrition —> delirium —> fall —> pain.

B) Decreased sleep —> immobility —> depression —> malnutrition —> delirium.

**Q25: Doorknob definition.**

The raising of a patient concern that happens as the doctor puts his or her hand on the doorknob to allow the patient to leave the room.

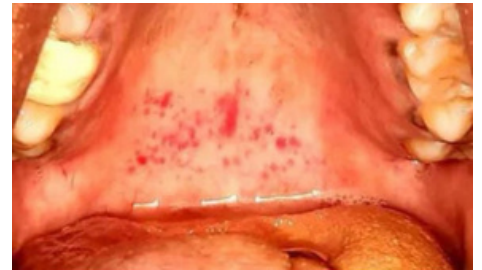**Q26: According to this picture.**

A. What is the finding?

Petechiae.

B. Mention a possible cause and a specific test to do.

Endocarditis, thrombocytopenia Blood tests, microbiological cultures.



**Q27: According to this ECG.**

A. What is the diagnosis?

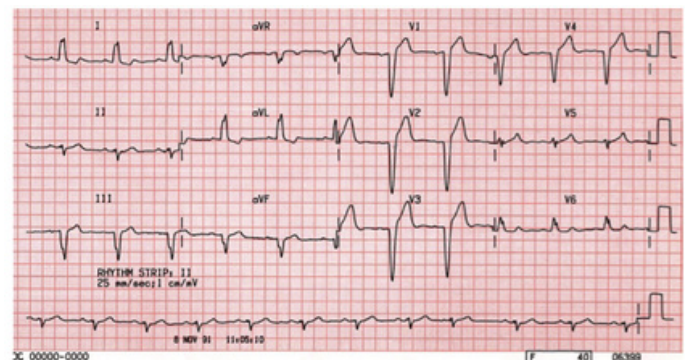
Left bundle branch block.

B. Mention the abnormal findings.

No R wave in lead V1.

Deep S waves.

Wide, notched R waves in leads 1, aVL, V5, V6 Loss of Q waves in leads 1, aVL, V5, V6.





**Q28: According to this x-ray.**

A. What is the diagnosis?

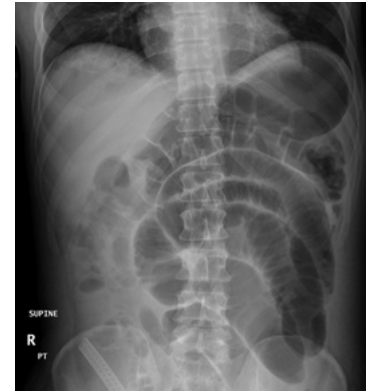Intestinal obstruction.

B. Mention 2 findings.

Dilation of the bowel loops, multiple air fluid levels.

C. Management?

ABCDE approach, NPO status, IV fluid resuscitation.



**Q29: A 6 years old patient with fatigue and weight loss, blood glucose reading is 425.**

A. How will you approach the parents?

B. How would you manage the patient?

IV insulin, electrolytes and fluid replacement.

**Q30: Write 4 screening tests for a 32 years old male.**

Blood pressure screening, lipid profile, PHQ9 for depression, HbA1C if there is any risk factors.

**Q31: Mention 2 most likely ddx for each of the following.**

A. A 24 years old female with low back pain for 2 days duration.

Kidney stone, UTI.

B. A 78 years old male with low back pain for 3 months duration.

Osteoarthritis in the spine, injury to discs.

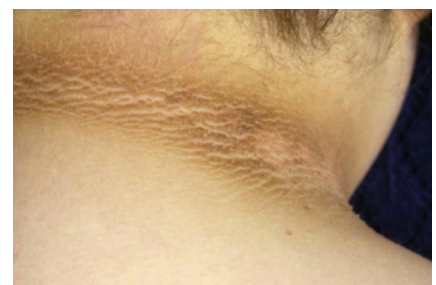**Q32: A 35 year old female with obesity BMI 36 has the following finding.**

A. What's the name of this skin lesion?

Nigricans acanthosis.

B. What test would you order for her?

Fasting plasma glucose.



**Q33: A 35 year old male patient with common cold that presented to the clinic and was found to have high blood pressure 160/100 and when repeated 155/93.**

A. How to approach the patient?

**Q34: A female patient with frequent headaches with negative CT scan, CBC and ESR, she keeps visiting the clinic every other week and frequently calls the doctor and also asked for the doctor's personal phone number.**

A. Describe this type of patient.

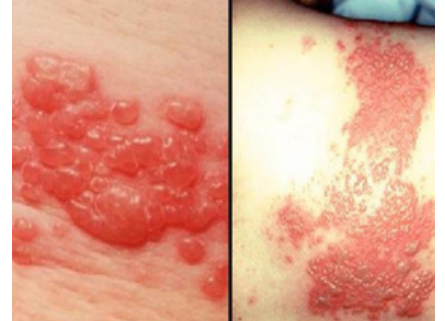The dependent clinger.

B. How do you approach this patient.

Empathic approach that needs to be delivered within clearly defined and enforced boundaries.

**Q35: Mention the RAPRIOP according to this finding.**

- Reassurance: The patient has shingles which is a viral infection.
- Advice: avoid antibiotics.
- Prescription: Acyclovir, pain killers (NSAID, tramadol) .
- Referral: No need.
- Investigation: No need if the presentation is typical .
- Observation: Follow up after 3 weeks.
- Prevention: Vaccination.



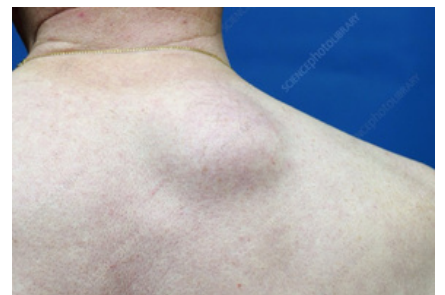**Q36: You have this finding which is painless.**

A. What questions you would ask?

If there is any similar presentation in his/her family?

B. Give 2 ddx.

Lipoma, sebaceous cyst.



**Q37: A young patient who works as a farmer presented to clinic with history of cough and shortness of breath of 1 month durations in the early spring he had similar previous attacks on physical examination he has bilateral wheezes and this is his chest X-ray.**

A. Your most likely ddx.

Hypersensitivity pneumonitis.

B. Mention 2 other ddx.

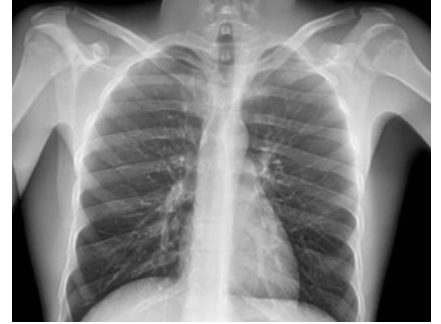Asthma, bronchiectasis.

C. Mention 2 questions you would ask for this patient.

Ask more about his work.

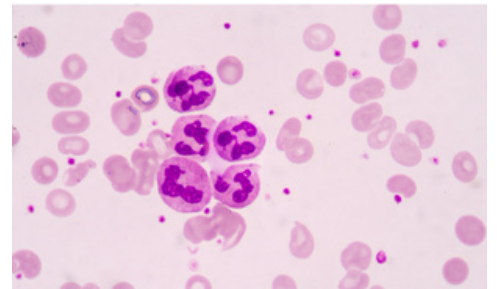
If he has birds in his house.

D. Management plan, which will you choose from RAPRIOP and what will you say?



**Q38: Mention 2 causes of this finding.**

Vitamin B12 deficiency anemia, folic acid deficiency.



**Q39: Write down 4 causes to order bone density exam.**

1. Women 65 and older and men over age 70.
2. Fracture over age 50.
3. History of hormone treatment for prostate or breast cancer.
4. Family history of osteoporosis.

**Q40: A patient felt a lump in her breast on self examination. Write down 6 steps in your management plan.**

- Reassurance: Don't panic it's extremely common for women of all ages to find bumps in their breasts. The majority will turn out to be benign.
- Advice: Watch and wait.
- Prescription: -
- Referral: Referral for radiology
- Investigations: Based on physical examination, age and risk of breast cancer, we will determine if breast imaging may be appropriate (mammogram/US/MRI).



- Observation: Re-checking the lump after 1-2 menstrual periods to see if it goes away  
Prevention: avoid smoking, avoid alcohol, stay active, healthy diet, manage stress.

**Q41: Write 3 physiologic changes in elderly regarding the musculoskeletal system and the renal system.**

MSS: Marked decrease in muscle mass (sarcopenia).

Decrease myosin heavy chain synthesis.

Increased fatiguability.

Renal: Decreased sodium excretion and conservation.

Decreased concentrating and diluting capacity Impaired secretion of acid load.

**Q42: A 28 year old female, sexually active, smoker, this finding appears with menstruation:**

A. Mention the most likely diagnosis.

Aphthous stomatitis.

B. Mention 2 important question to ask.

If there is fever, fatigue or any GI symptoms (nausea, weight loss)?

Use of NSAIDs like ibuprofen?

C. Advise the patient.

Eat a well balanced diet and drink enough fluids.

**Q43: A 35 year old female teacher with suspected PE.**

A. Ask her about 3 risk factors.

Do you had any recent surgeries? Cesarean delivery?

Are you pregnant or do you use any oral contraceptive pills?

Do you have a personal or family history of DVT or PE?

B. Which sign increases the likelihood of PE?

A) Fever of 38.

B) Orthopnea.

C) Chest pain.

Answer: C

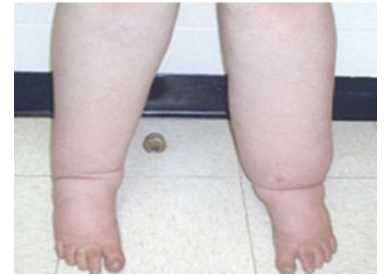**Q44: According to this picture.**

A. What medications cause this condition?

Calcium channel blockers (amlodipine), beta blockers, hydralazine.

B. Mention other causes of this condition.

Heart failure Renal failure Liver cirrhosis.



**Q45: Mohammad is 25 year old gentleman who presented to the clinic with sore throat, runny nose and congestion, no fever. On examination no tonsillar exudate was noticed and no swollen cervical lymph nodes, he denied cough and other symptoms. According to Centor criteria.**

A. Mention 2 ddx.

Influenza Viral tonsillitis.

B. What is his Centor score?

Zero.

D. Does this patient need antibiotics? And why?

No he doesn't need antibiotics because according to his Centor score (0) no antibiotics are indicated, only symptomatic treatment.

E. What is the next step in management?

Viral PCR.

**Q46: Lower abdominal pain, mention 2 ddx in each of the following.**

A. A 21 female patient for 2 days duration.

Menstrual cramps.

Appendicitis.

B. A 21 female patient for 2 months duration.

Pelvic inflammatory disease.

Inflammatory bowel syndrome.

**Q47: Mention 2 physiologic renal changes in elderly.**

Decreased vitamin D activation.

Decreased serum renin and aldosterone.

# Another Mini-OSCEs

هانت (:

**Q1: Picture of x-ray knees.**

A. What is the most likely diagnosis?

Osteoarthritis.

**Q2: Patient-Centered questions.**

A: Anxiety.

B: Beliefs.

C: Concerns.

F: Feelings.

I: Ideas.

F: Function.

E: Expectations.

**Q3: Transference question.**

A. What is this doctor-patient interaction called?

Transference.

B. If it was coming from the doctor?

Countertransference.

**Q3: Blood Test (CBC) for a 75 year old man with recent fatigue and not eating because of his toothache.**

A. Describe the findings.

B. Give two causes.

**Q4: Postpartum lady 34 years old.**

A. Describe her body language.

Depressed, tired.

B. What screening would you order?

Screen for depression (PHQ-9).

C. Other screening tests appropriate for her age and gender?

Cervical Cancer (Cytology) & HTN.

D. What preventive screening tests would you order for her father (54 years old)?

- Colon Cancer (FOBT, Colonoscopy OR sigmoidoscopy).
- HTN.
- DM if obese or overweight.

**Q5: Picture of breaking bad news (death), what is the approach used?**

**SPIKES.**

**Q6: A 40 year old female patient came to the clinic with high blood pressure 150/90, she measured it for a week, consider a management plan using RAPRIOP.**

**Q7: A 50 year old male patient, diabetic on metformin & liver function test.**

**ALT slightly elevated, AST normal**

A. Give 2 ddx.

B. Give risk factors.

**Q8: Mention 4 screening tests for 70 year old male patient, hypertensive and compliant to medications.**

**Q9: CBC showing a microcytic anemia, give 3 ddx.**

**IDA, thalassemi, anemia of chronic disease.**

**Q10: Picture of nail with pitting and redness of skin around the nail with white scales.**

A. Two history questions to aid in diagnosis.

B. Describe the findings.

C. Your differential diagnosis.

**Q11: Types of disease prevention and example for each one.**

**Q12: ECG (SVT), mention three parts of management not only medication**

**RAPRIOP**

**Q13: Patient with cough, fever, sputum + Xray**

A. Mention 3 ddx .

B. Based on patient centered medicine what you want to ask him to reach diagnosis.

**Q14: Patient with recent HTN, what is the treatment of choice**

**ACEI**

**Q15: Picture of Raynaud's phenomenon.**

- A. Describe the picture.
- B. What you want to tell / advice the patient.

**Q16: Mention the 8 components of IADL.**

**Q17: Four applications of counseling.**

**Q18: Chest X-Ray showing a mass in the right lung for a 50 year old female with history of smoking.**

- A. Describe what you see in this X-ray.
- B. What is the next step?

**Q19: Picture of 2 figures regarding the relation between diseases in geriatrics, identify each of them.**

- A. Comorbidity
- B. Multi-morbidity

**Q20: Write down 4 ddx for each case scenario (PreDiagnostic Interpretation).**

- A. A 84 year old male with SOB for 3 weeks.
- B. A 24 year old female with SOB for 2 days.

**Q21: A 4 year old child presented with his mother complaining of low-grade fever, sore throat, hyperemic throat.**

- A. What are your management headlines?

**Q22: Picture of CBC for a 70 yr old male showing macrocytic anemia.**

- A. Describe what you see in his lab results?
- B. Mention 2 causes for this condition.
- C. What anticipatory care you would ask for him ? and what type of prevention is it (primary, secondary, tertiary)?

**Q23: The most important for patient to take drugs correctly.**

Patient understanding of the illness.

**Q24: Lady with waist circumference 103cm, BP 135/90, FBS 120, HDL 25, cholesterol 170, what is the most appropriate management? (MCQ)**

- Serious lifestyle changes.
- Start on antihypertensive drugs.
- Give thyroxine.

**Answer is: Serious lifestyle changes.**

**Q25: One of the following about management is wrong.**

- Use instrument competently and sensitively.
- Discriminate use of investigations and referrals and drugs.
- Prepared to use time appropriately.
- Uses silence appropriately.
- Interpret verbal and non-verbal cues.

**Q26: What is the most important factor to make the pt more compliant with drugs?**

**Knowing about the disease.**

**Q27: Wrong statement.**

- Acute major cases about 15%.
- MI and ruptured aneurysm is life threatening.
- Minor self limiting 40%.
- Chronic problems 25%.

**Answer is: Minor self limiting 40%.**

**Q28: Wrong management plan.**

**Made by the doctor alone because he knows more about condition of his patient.**

**Finally done 🎉**  
**Best of luck 💖**