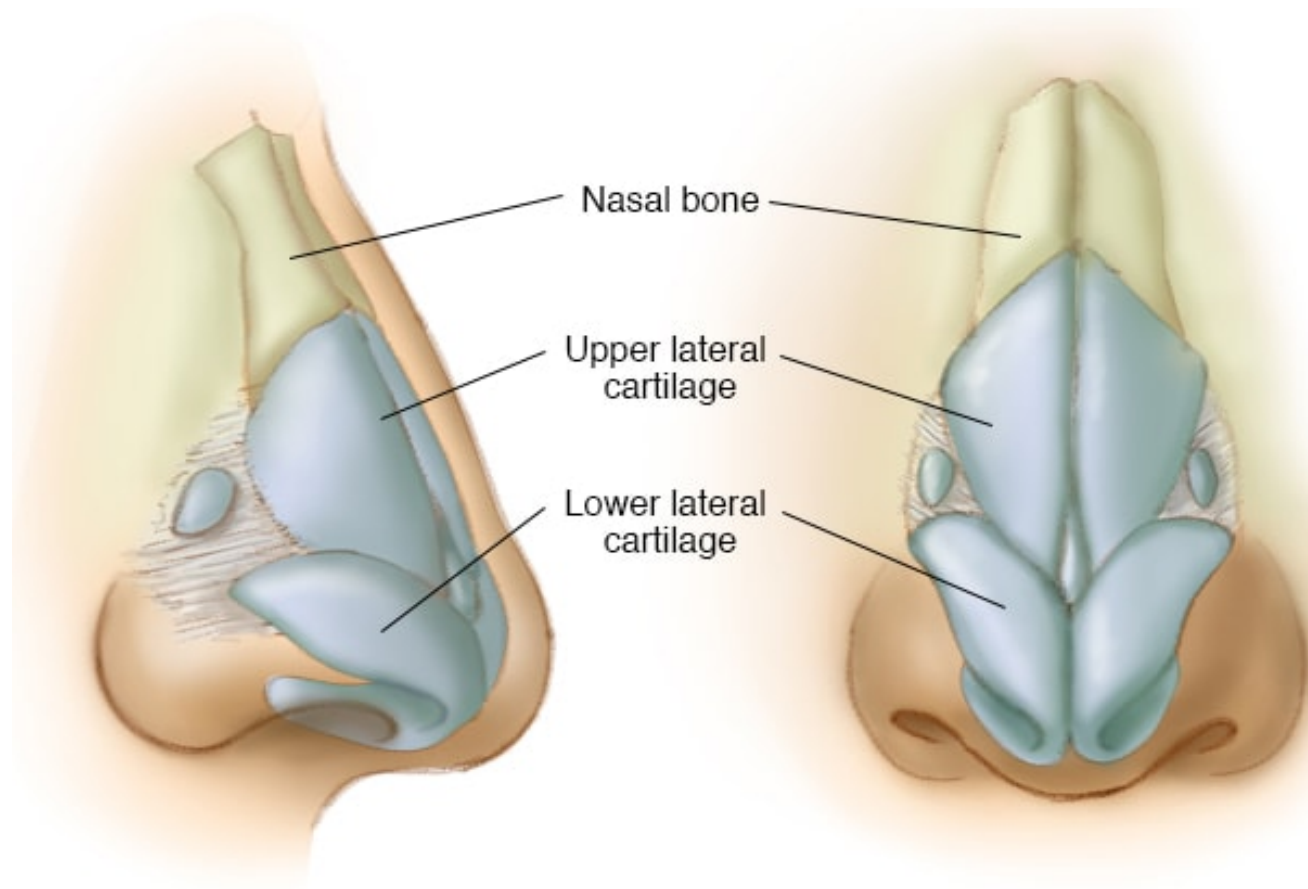




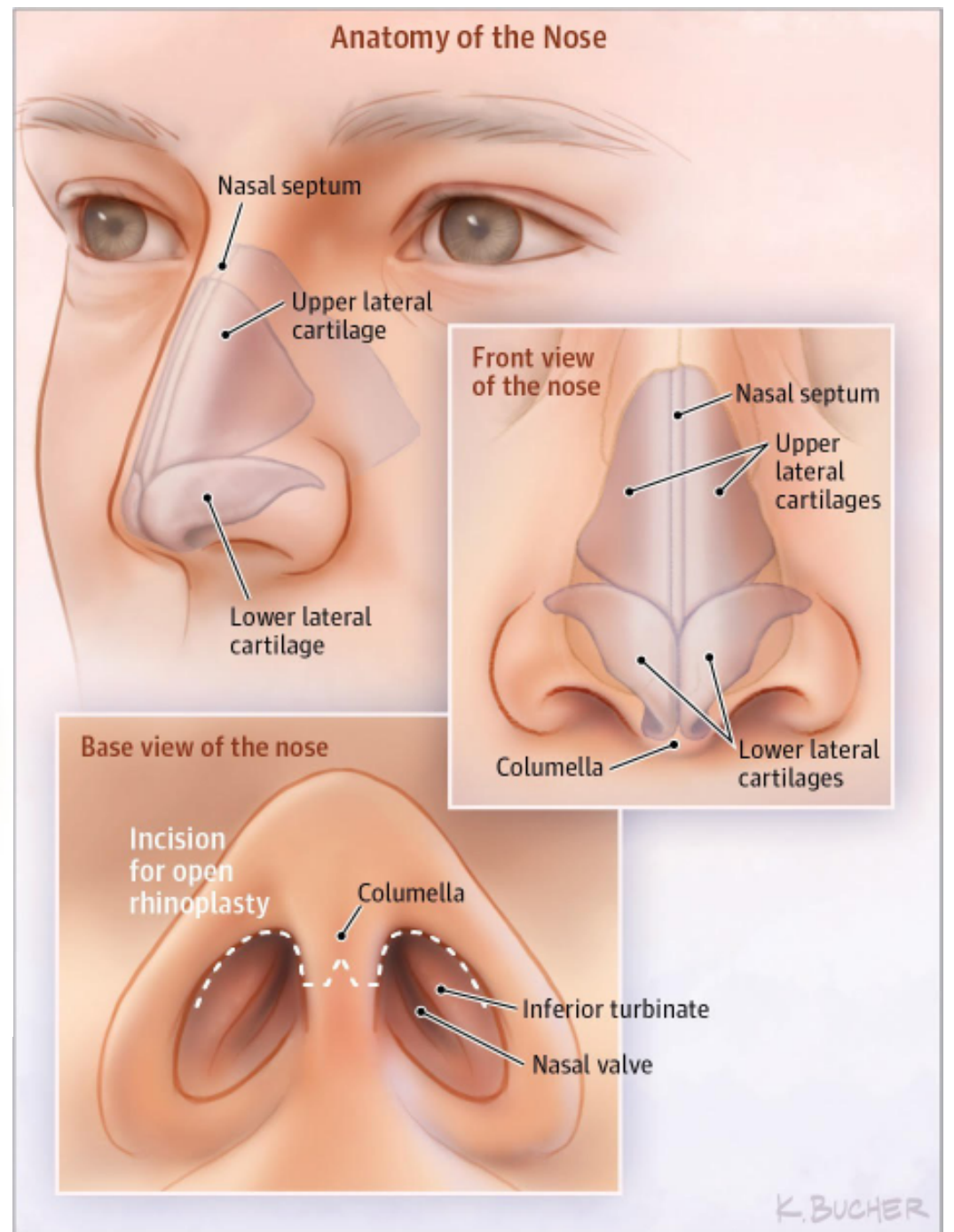
# ENT Pictorial Review

***Rhinology***

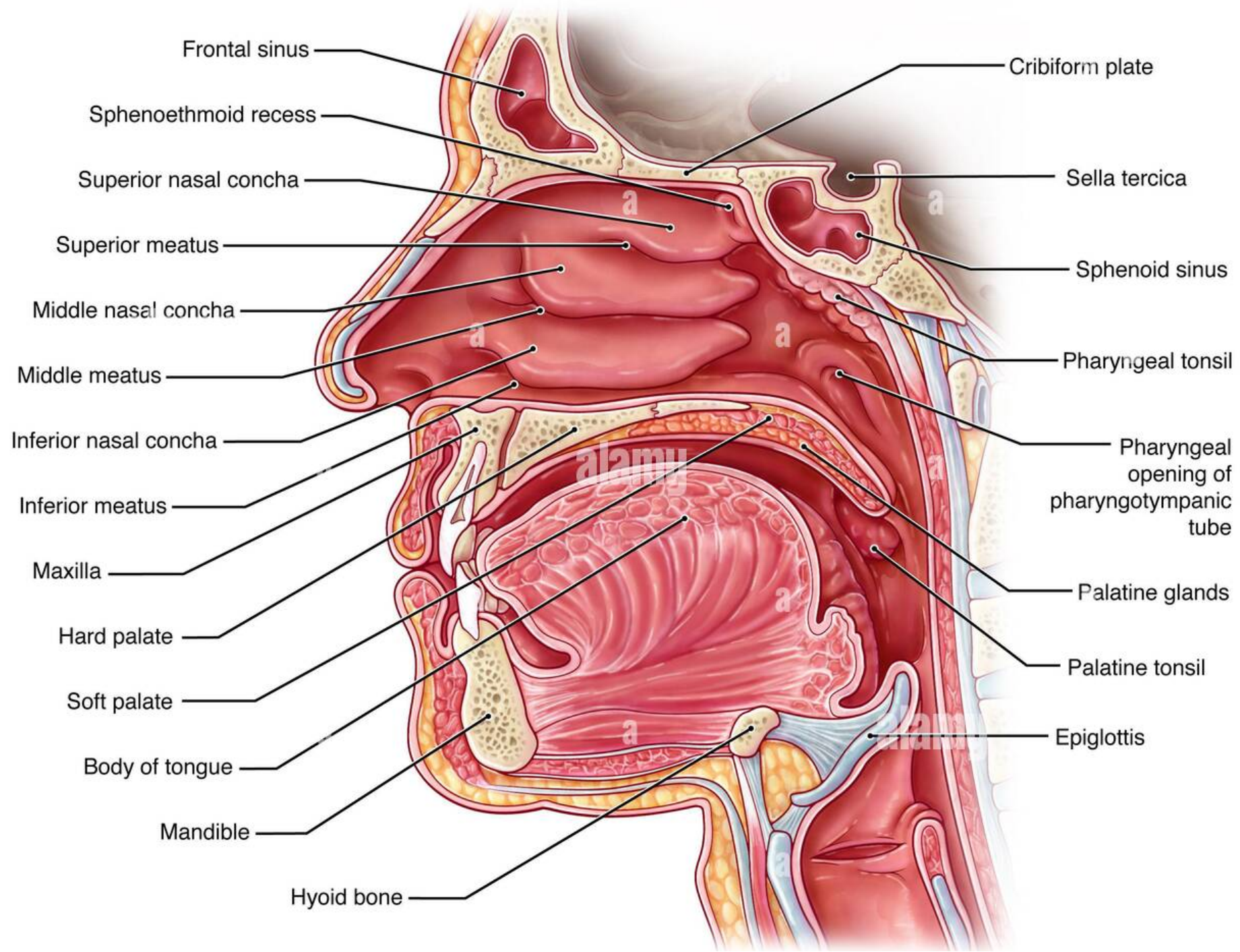




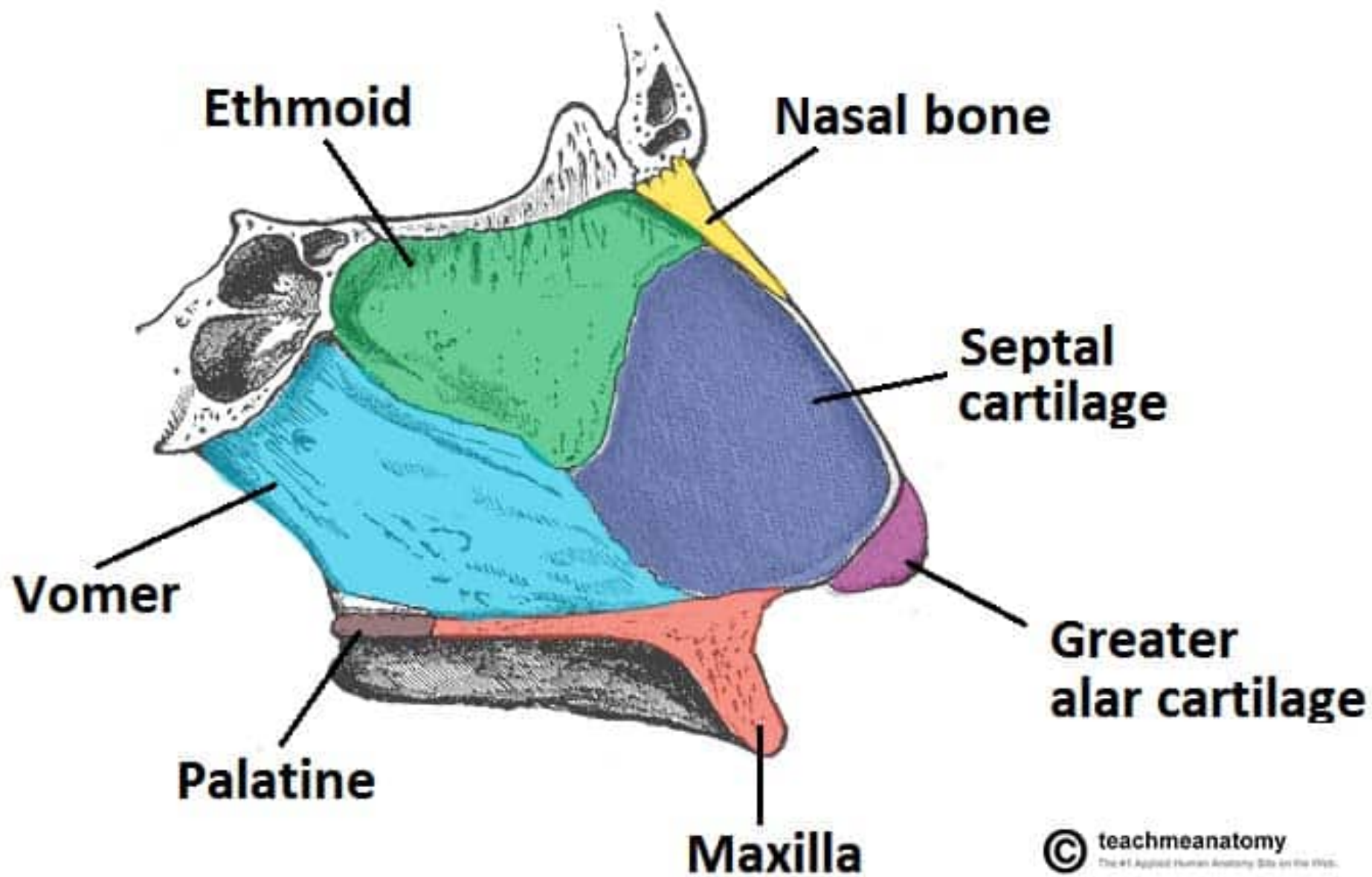
© MAYO FOUNDATION FOR MEDICAL EDUCATION AND RESEARCH. ALL RIGHTS RESERVED.



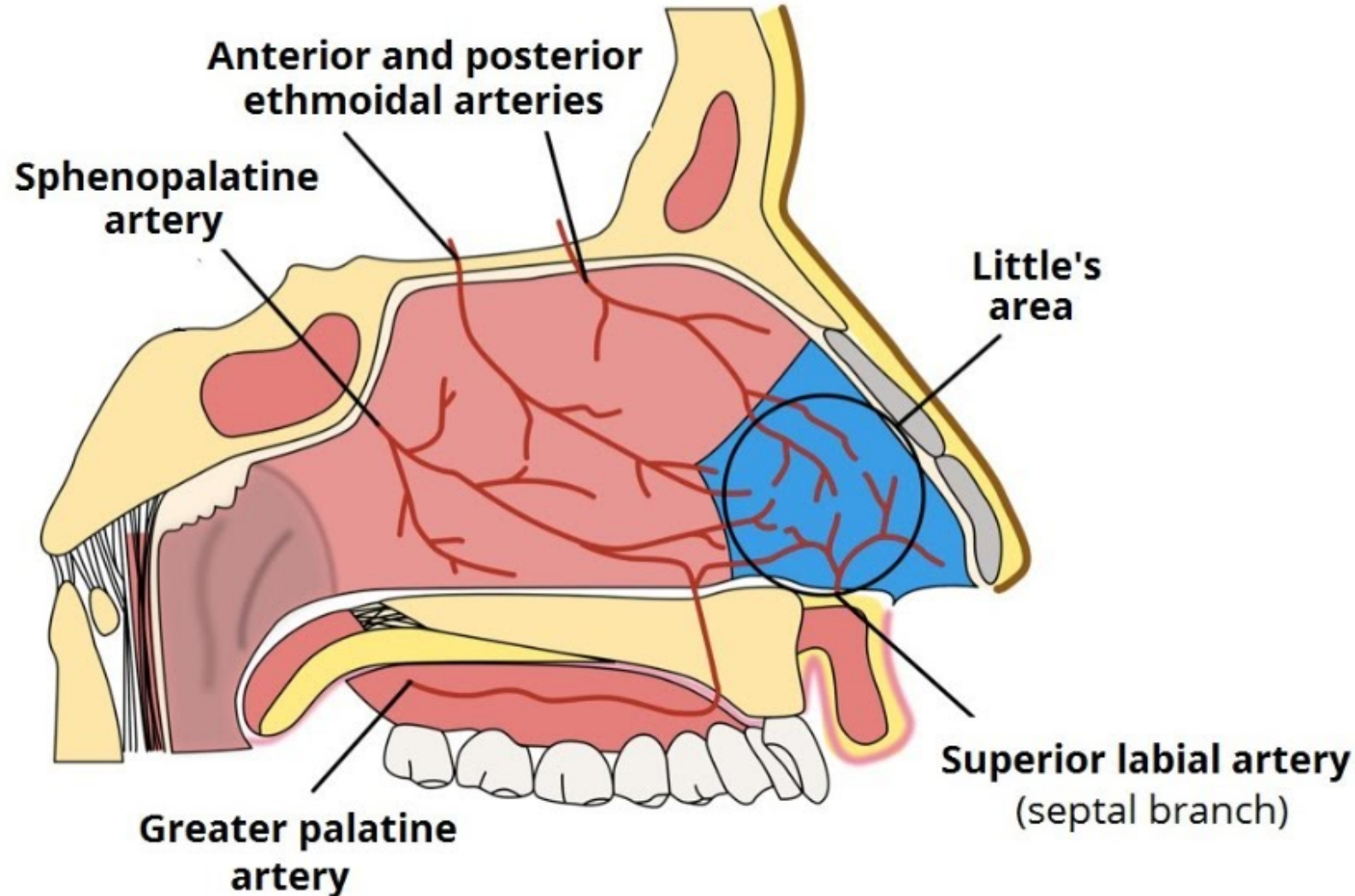
K. BUCHER



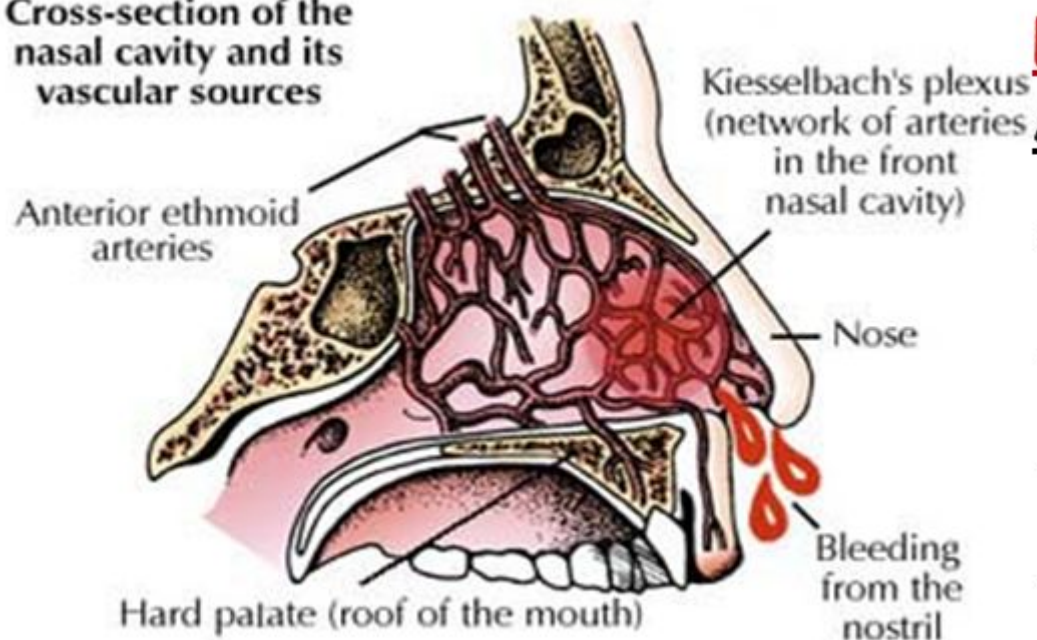




# Little's Area (Kiesselbach's plexus)



Cross-section of the nasal cavity and its vascular sources

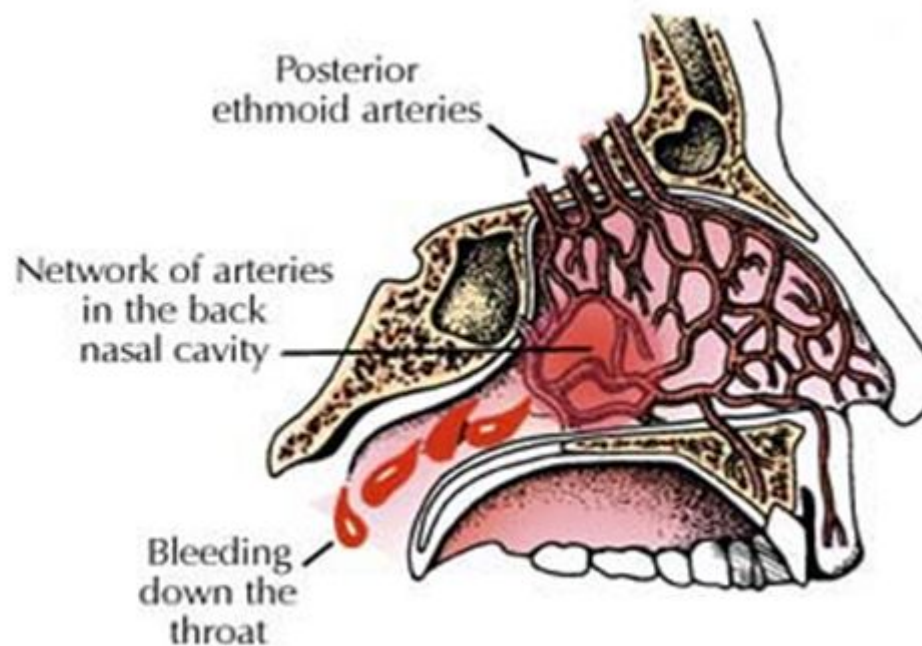


## Kiesselbach's Plexus/Little's Area:

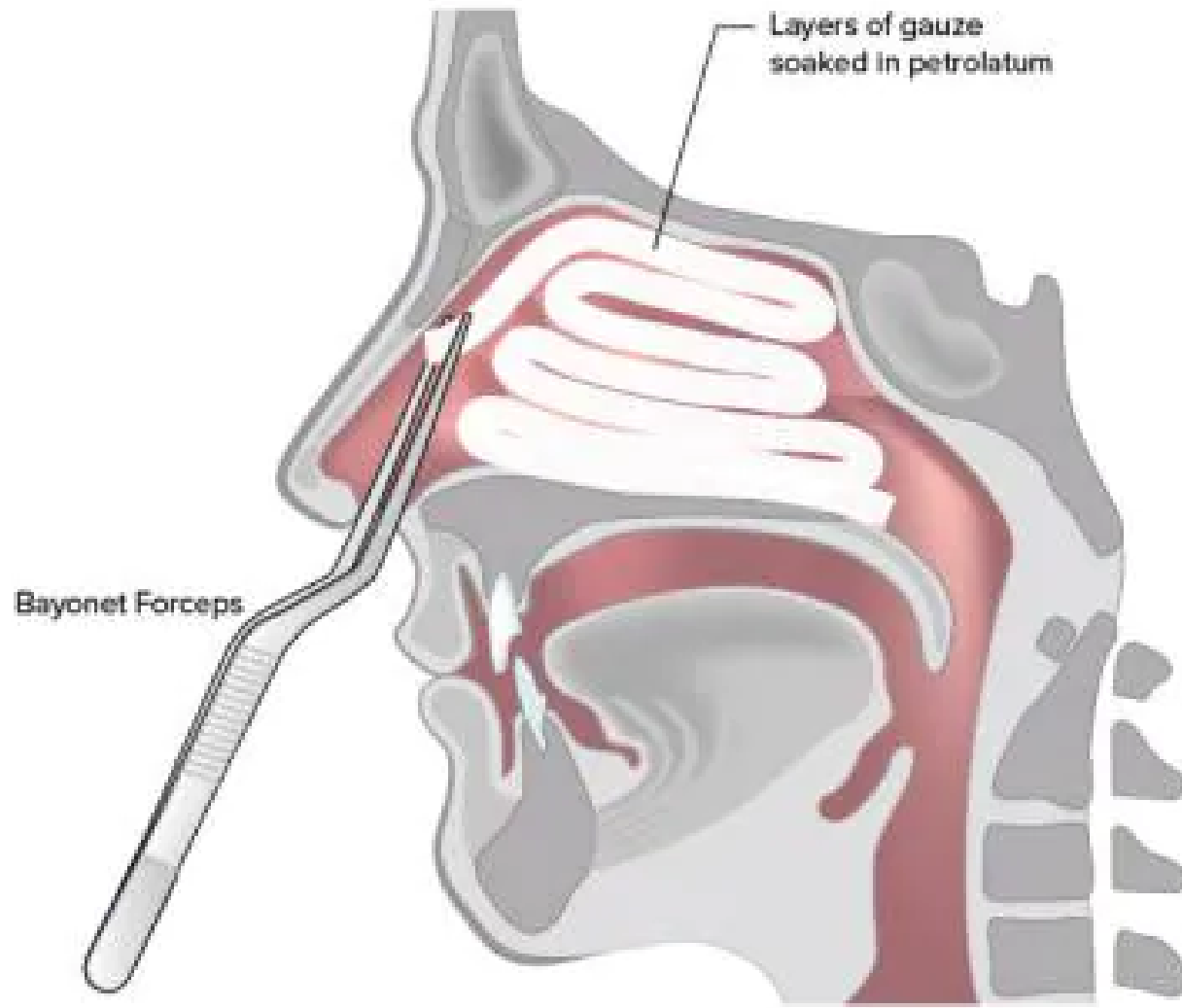
- Anterior Ethmoid (ICA)
- Superior Labial A (Facial)
- Sphenopalatine A (IMAX)
- Greater Palatine (IMAX)

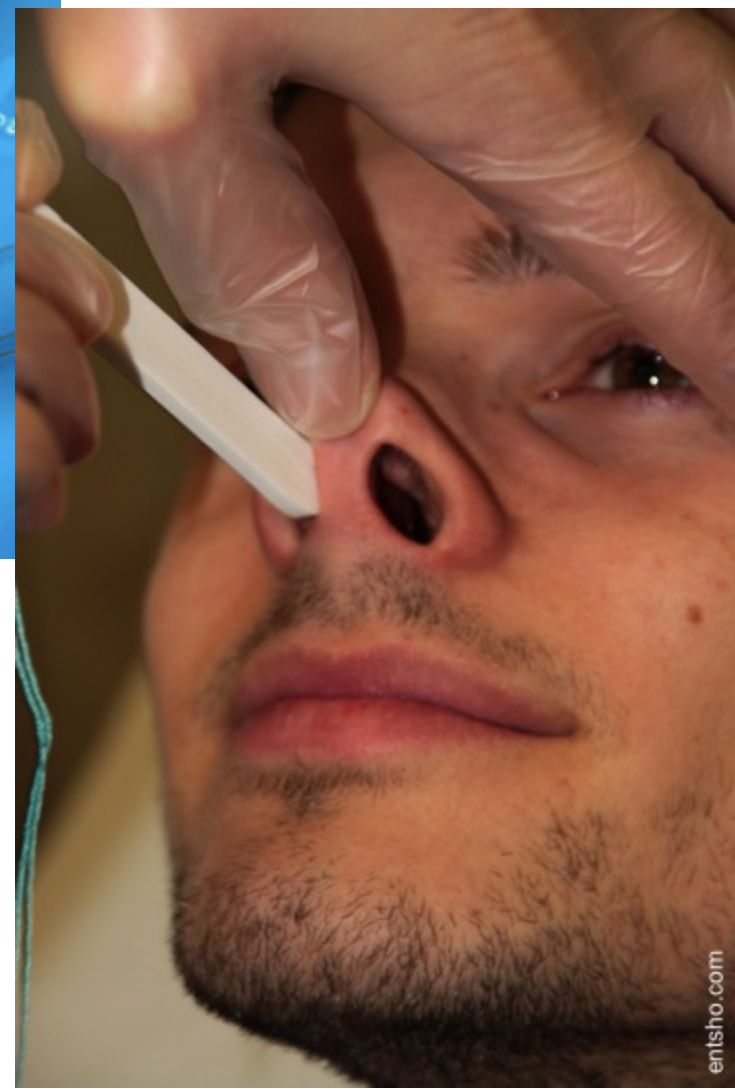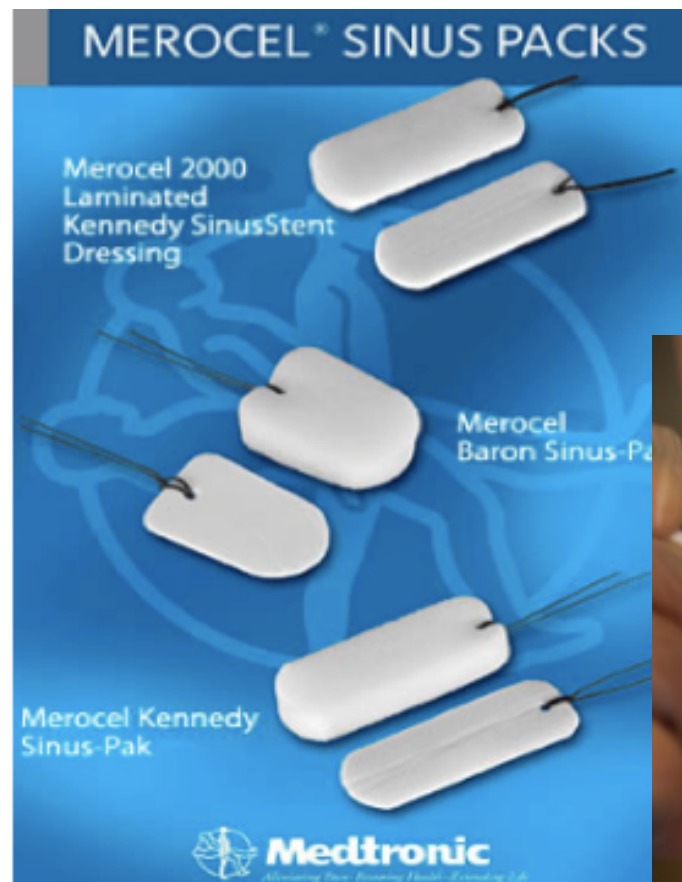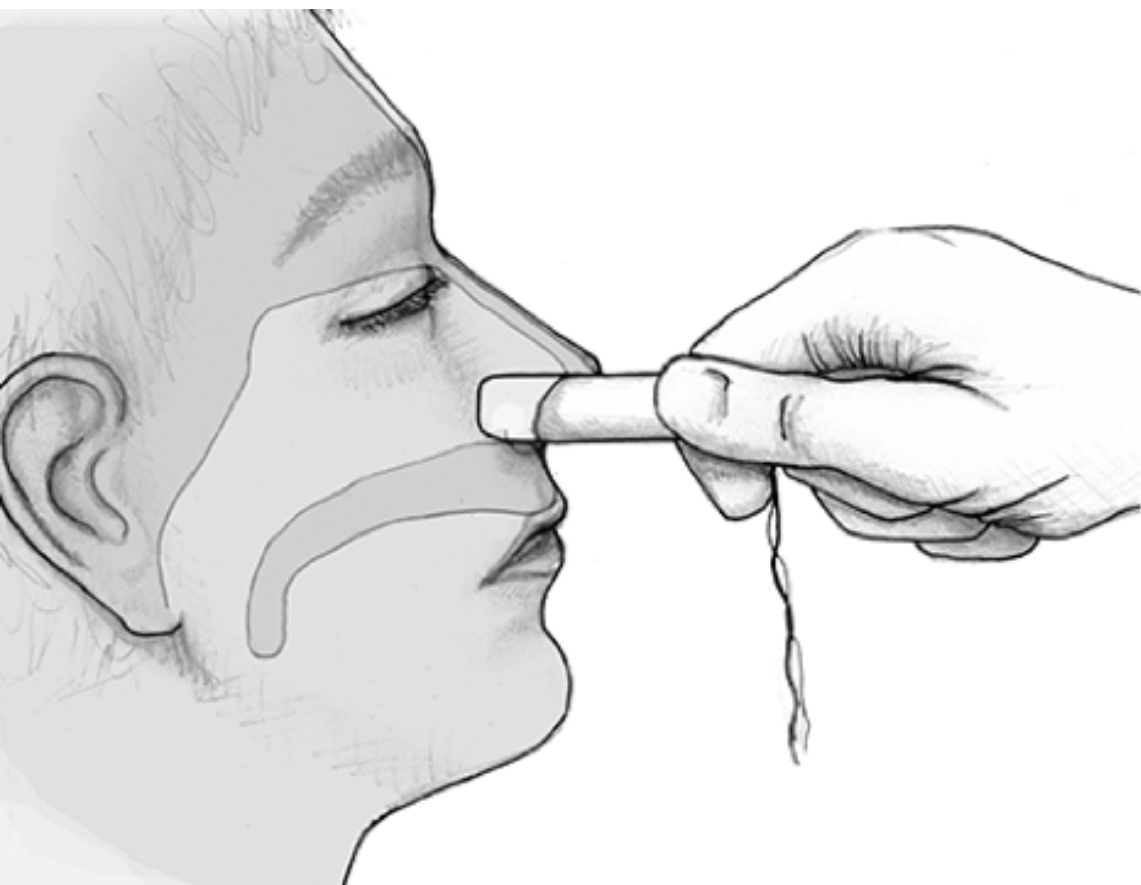
## Woodruff's Plexus:

- Sphenopalatine A  
(Pharyngeal & Post. Nasal branches)  
(IMAX)
- Posterior ethmoid (ICA)

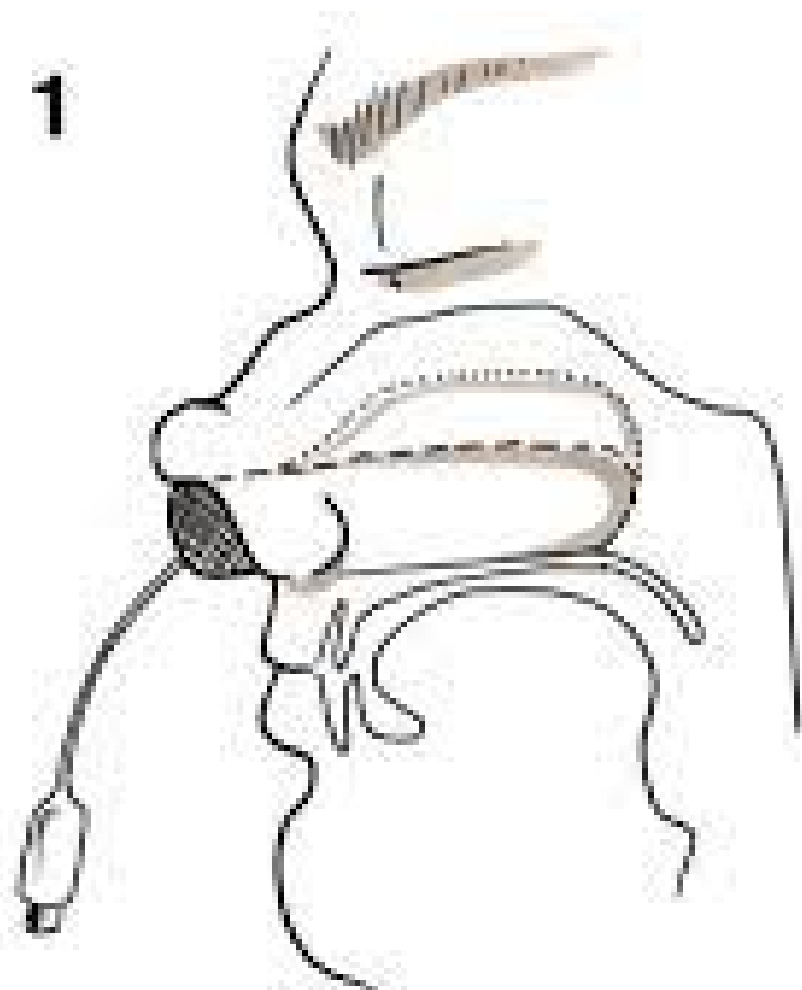




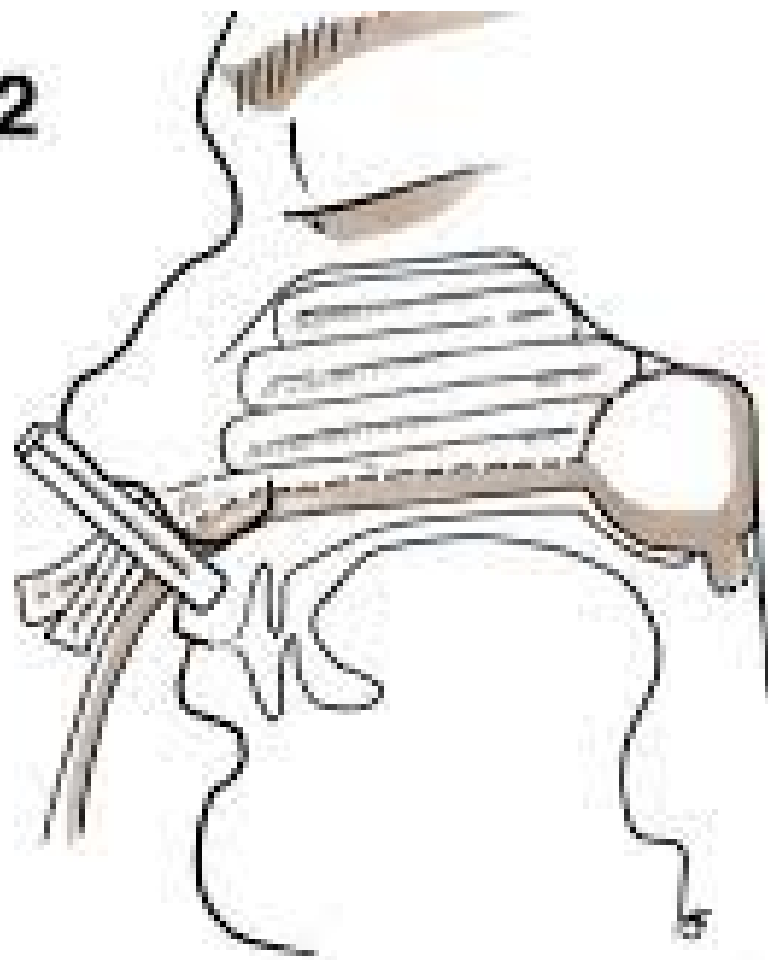




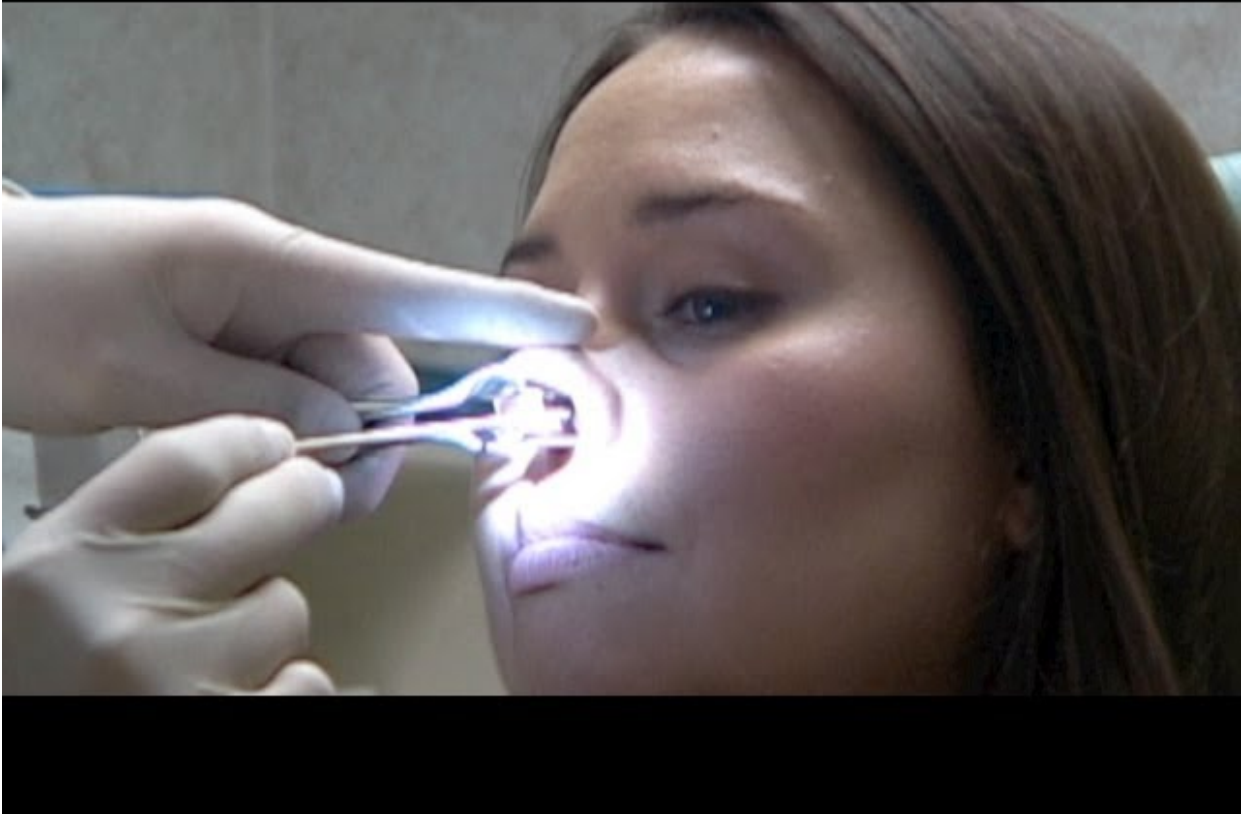1

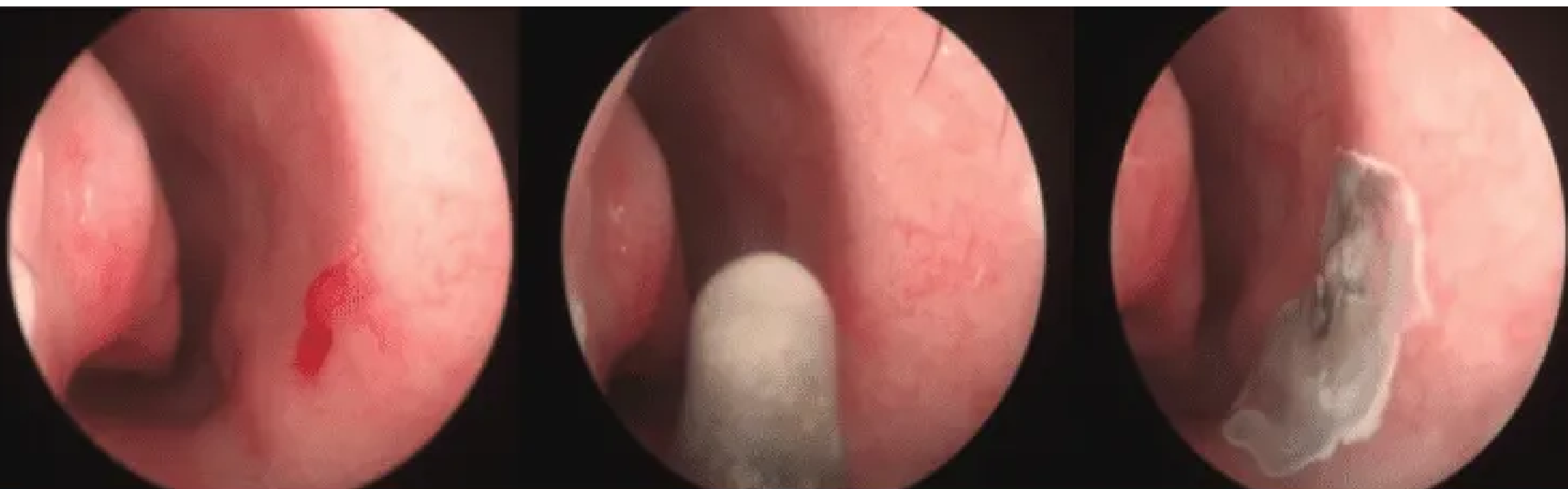

2



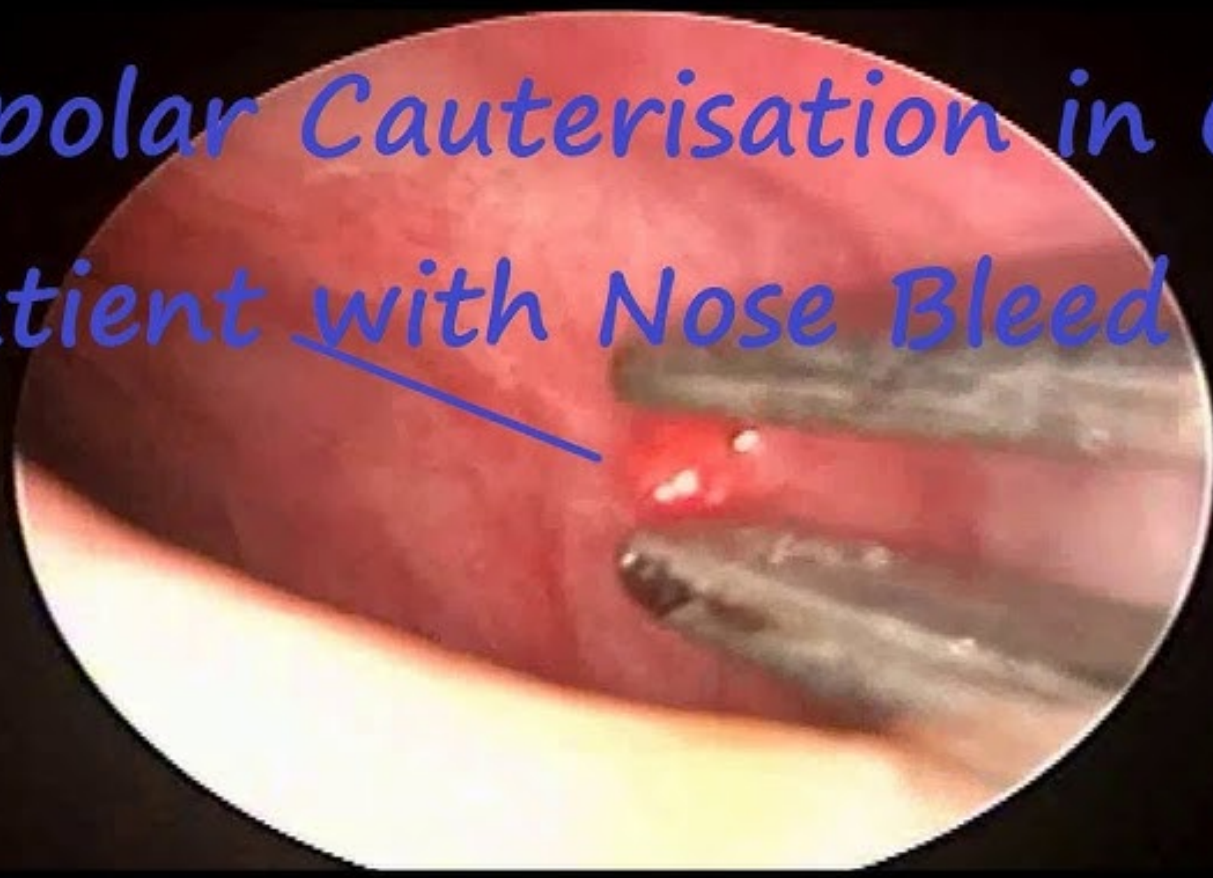

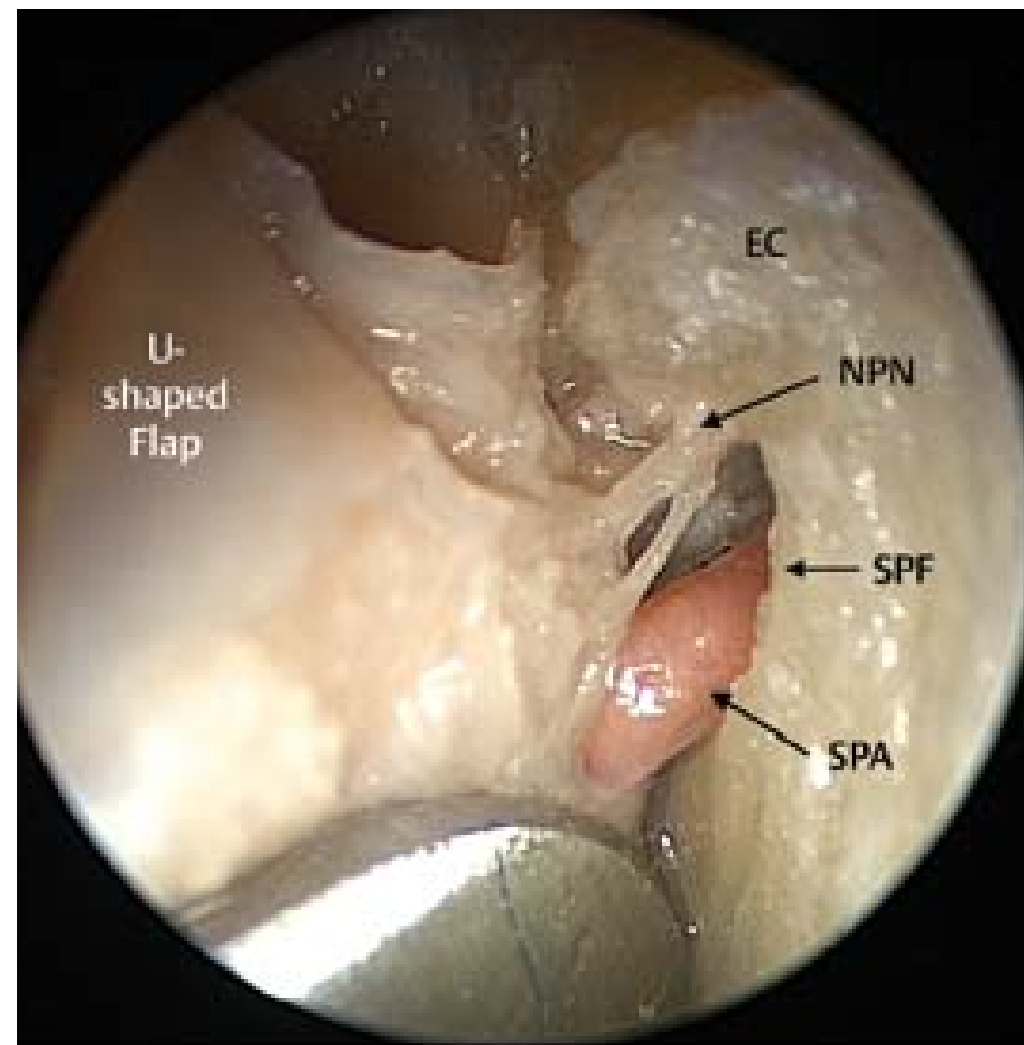
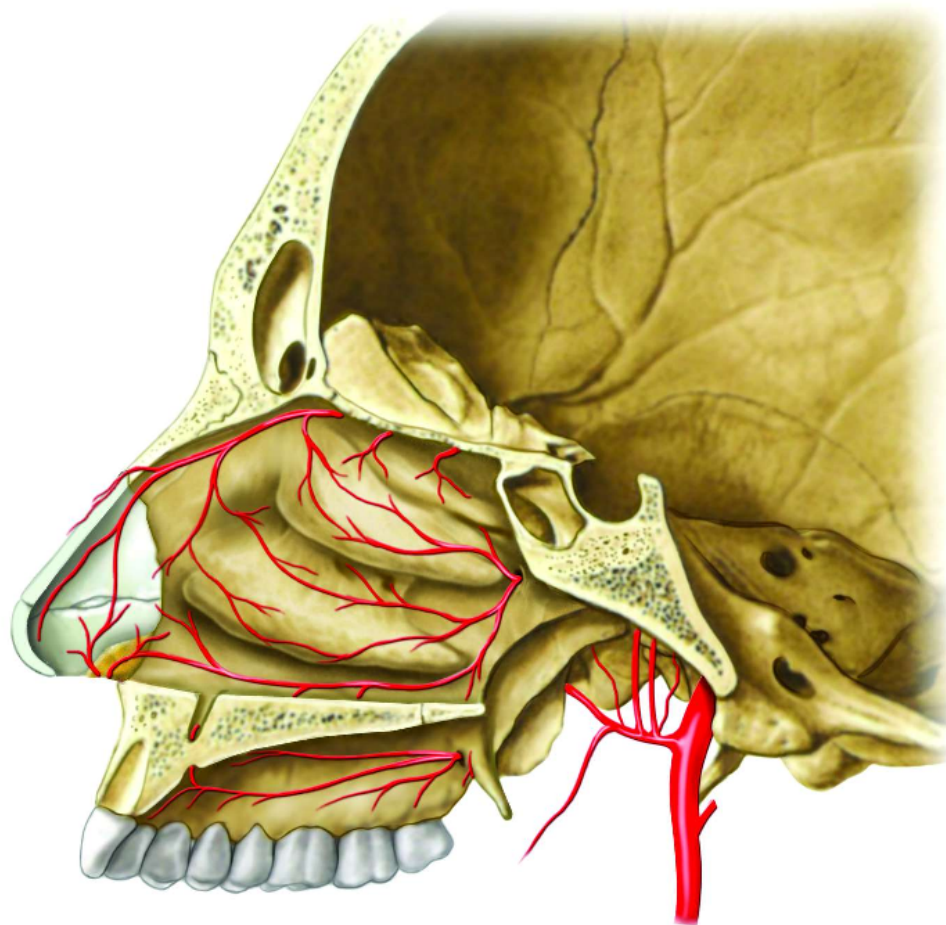




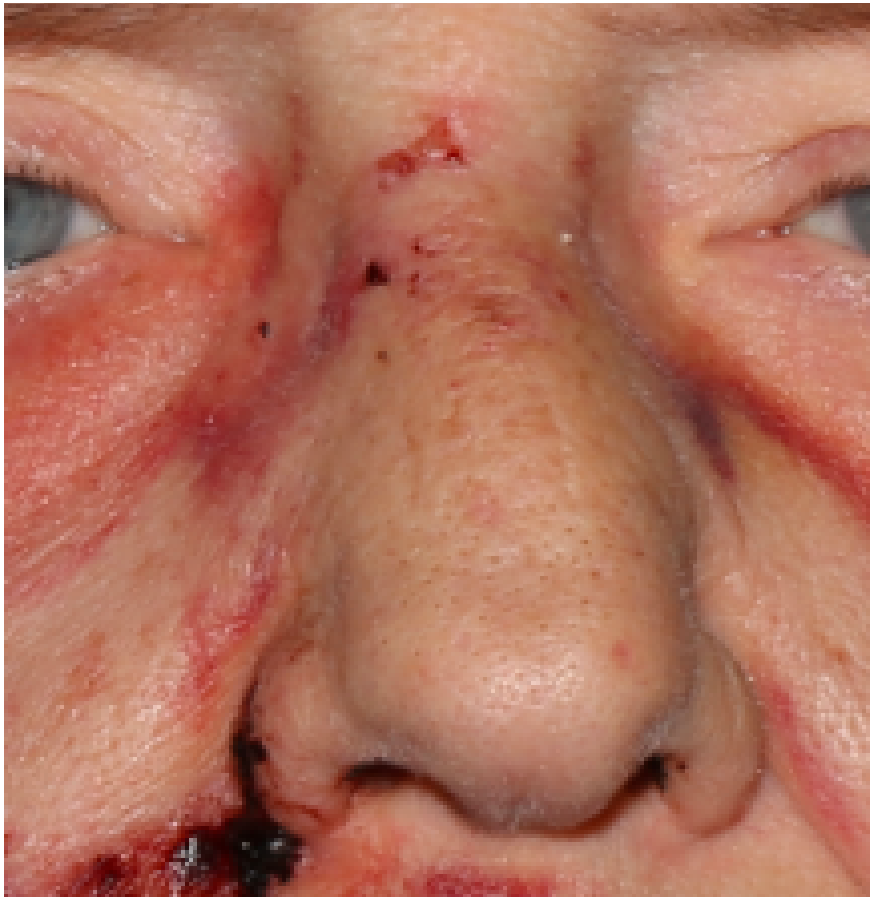*Figure 3b - 3d - Endoscopic picture of the right nasal cavity showing a bleeding vessel from the right nasal septum, application of silver nitrate stick to seal the burst vessel and appearance of the right nasal septum after silver nitrate cautery.*

# Bipolar Cauterisation in Old Patient with Nose Bleed

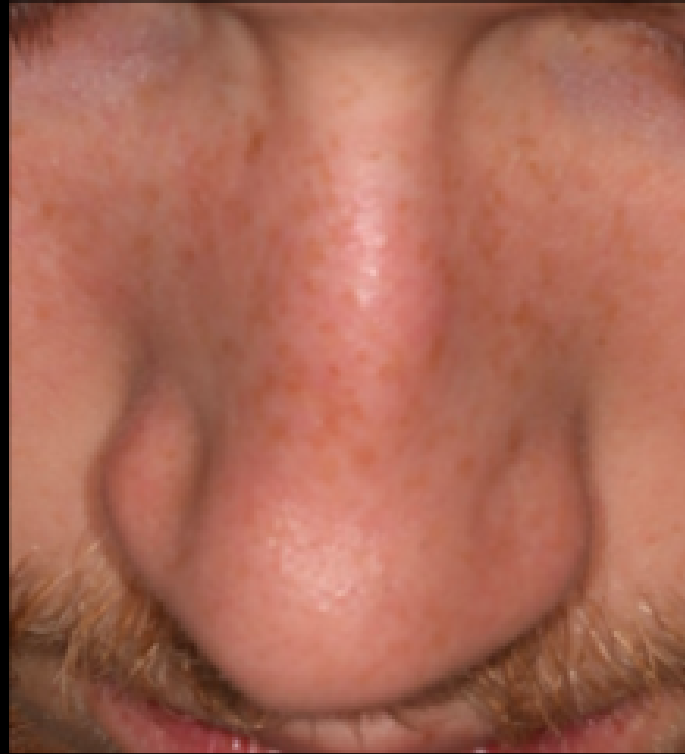



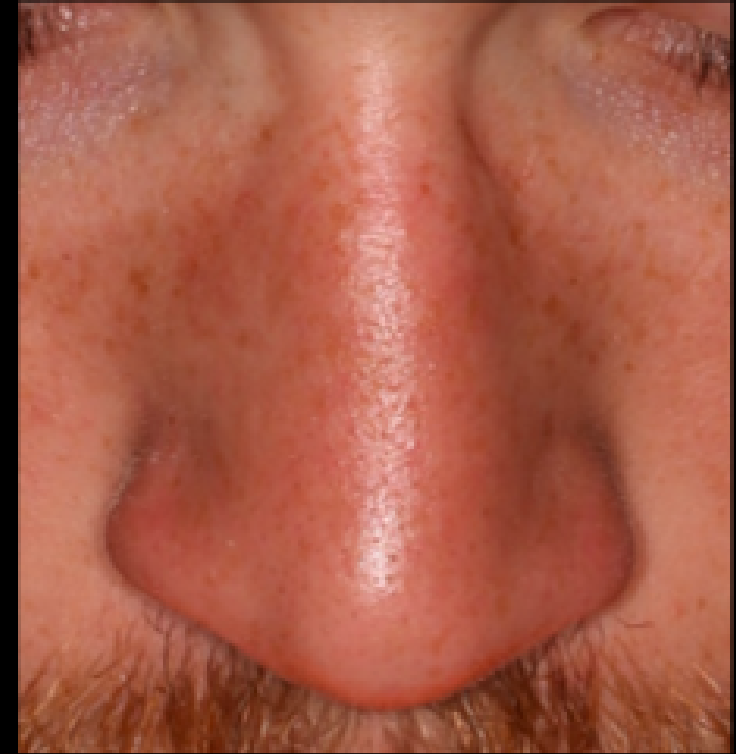B



Broken Nose



Before



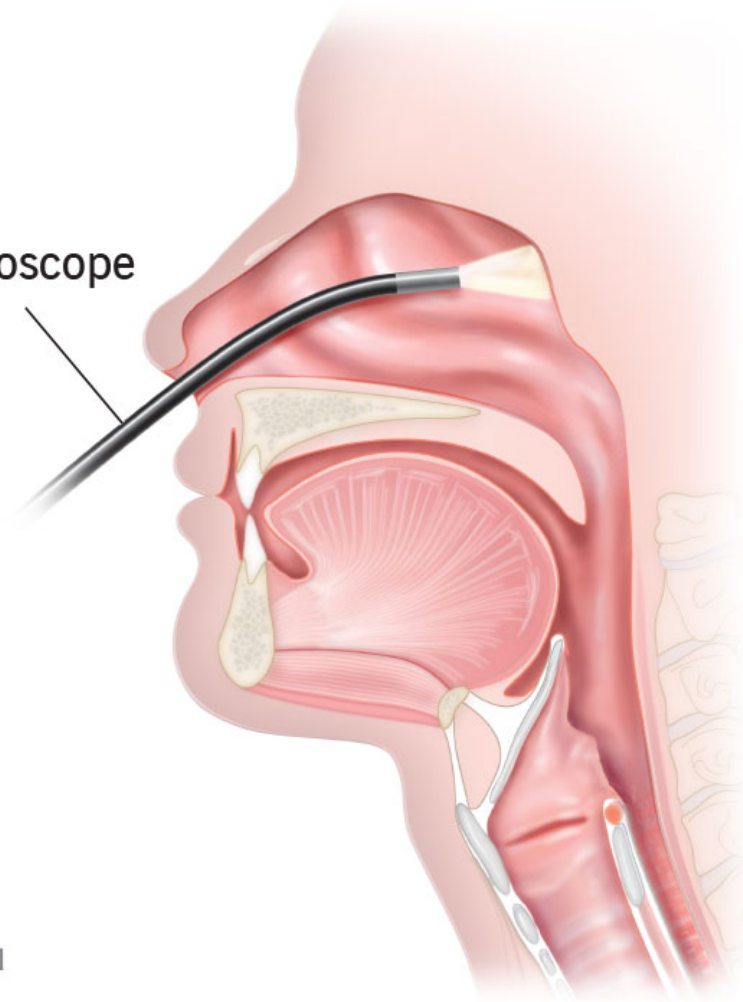
After

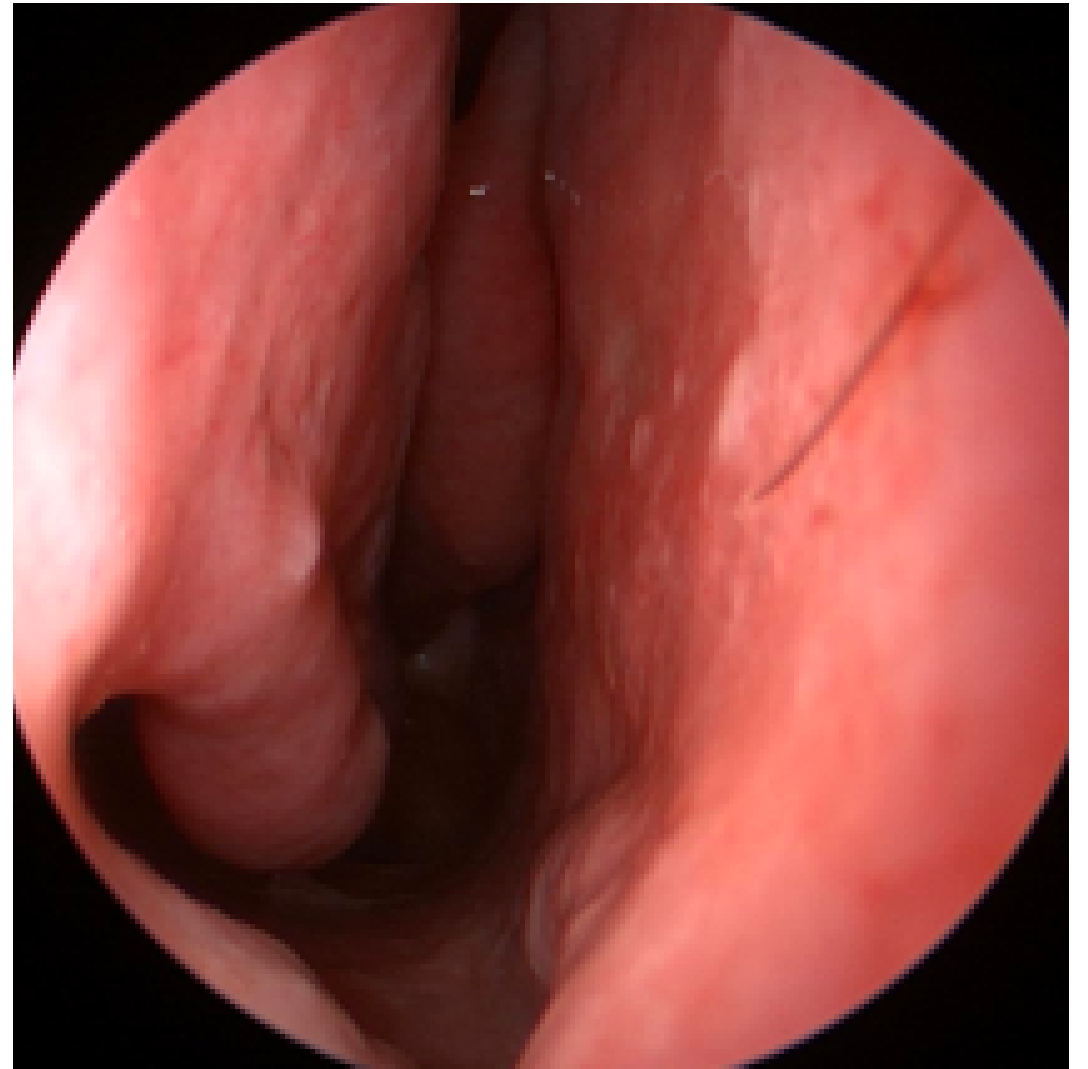
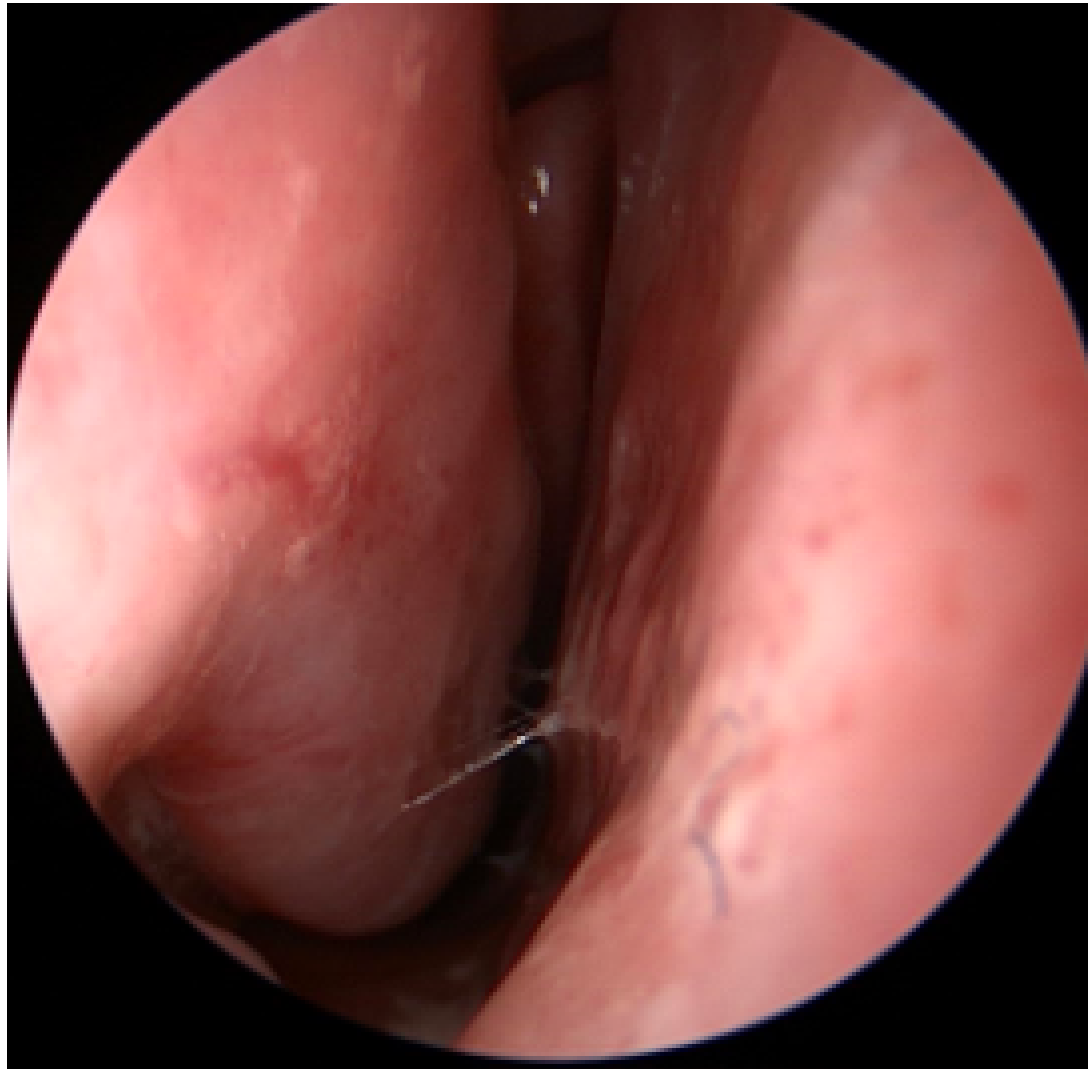
Fractured Nasal Bones Before & After  
Repair

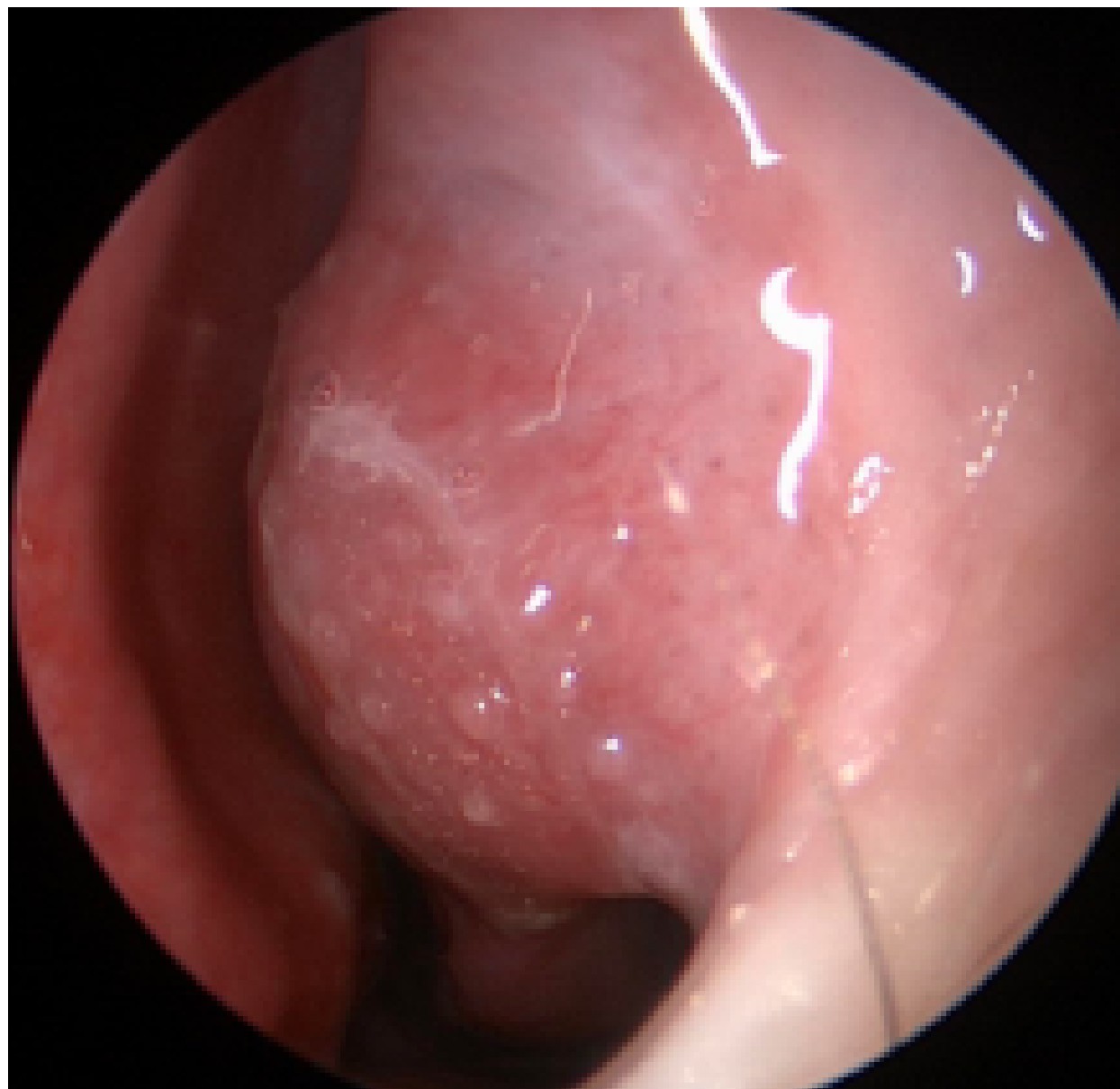


# Nasal endoscopy

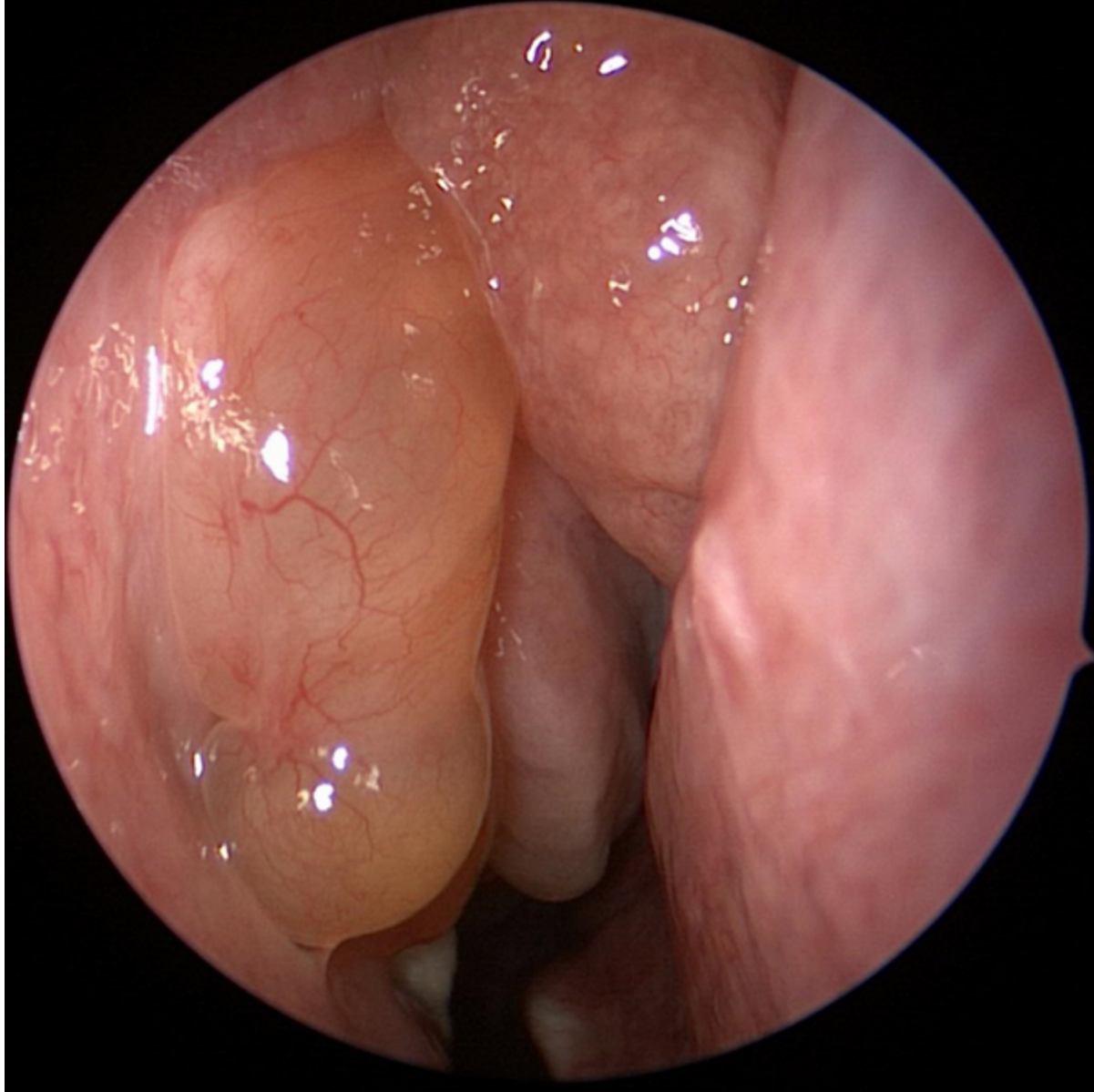
Endoscope

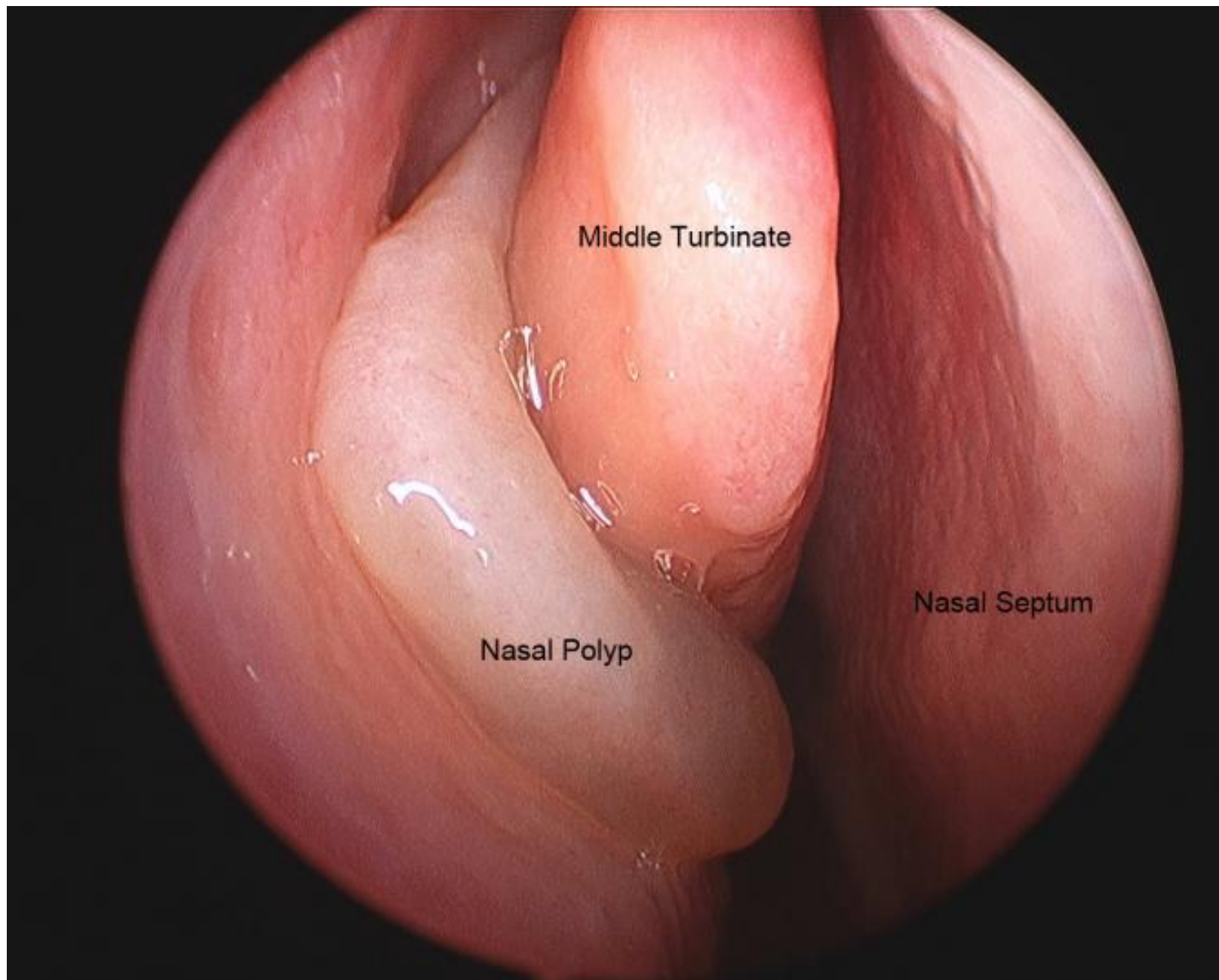


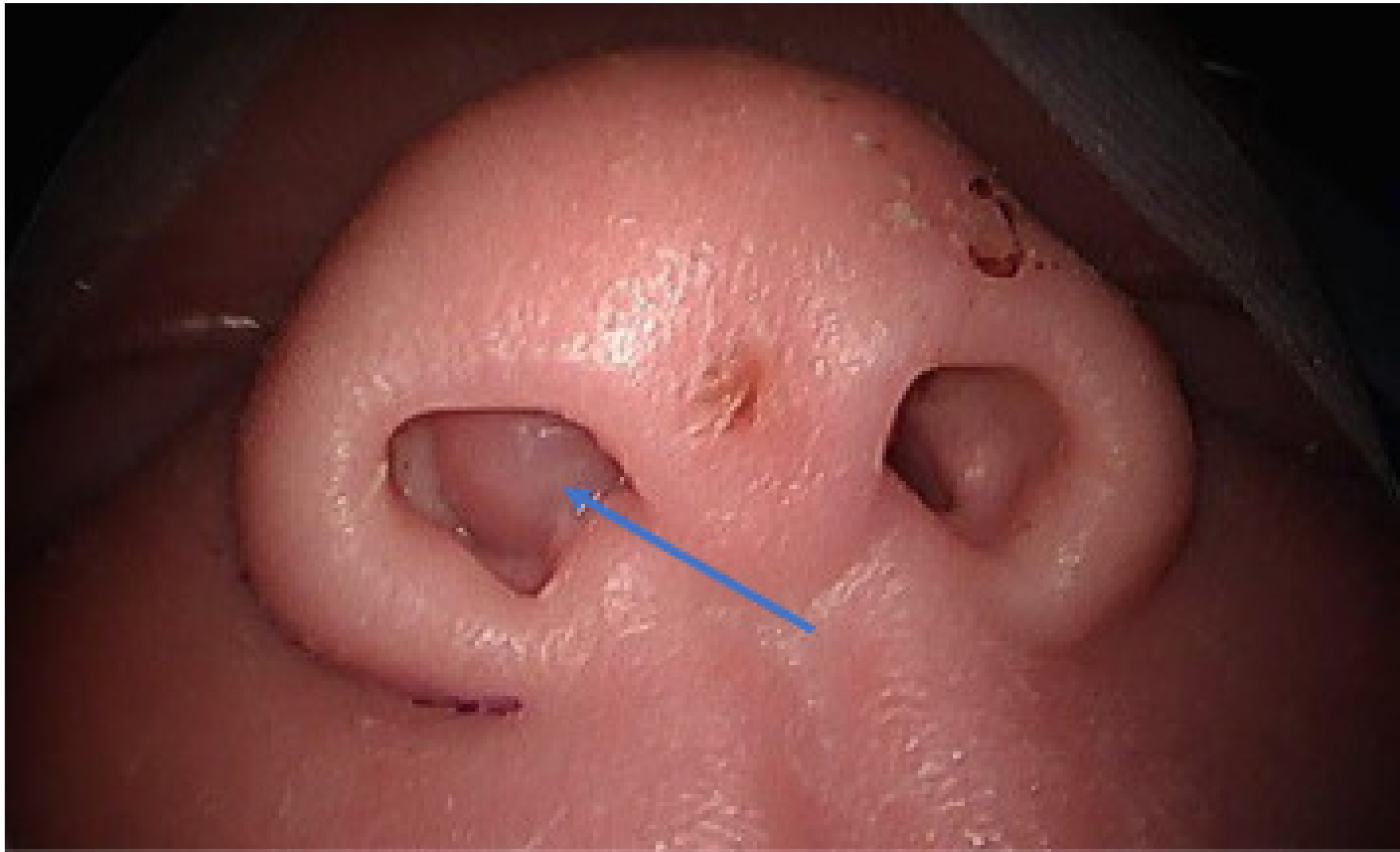


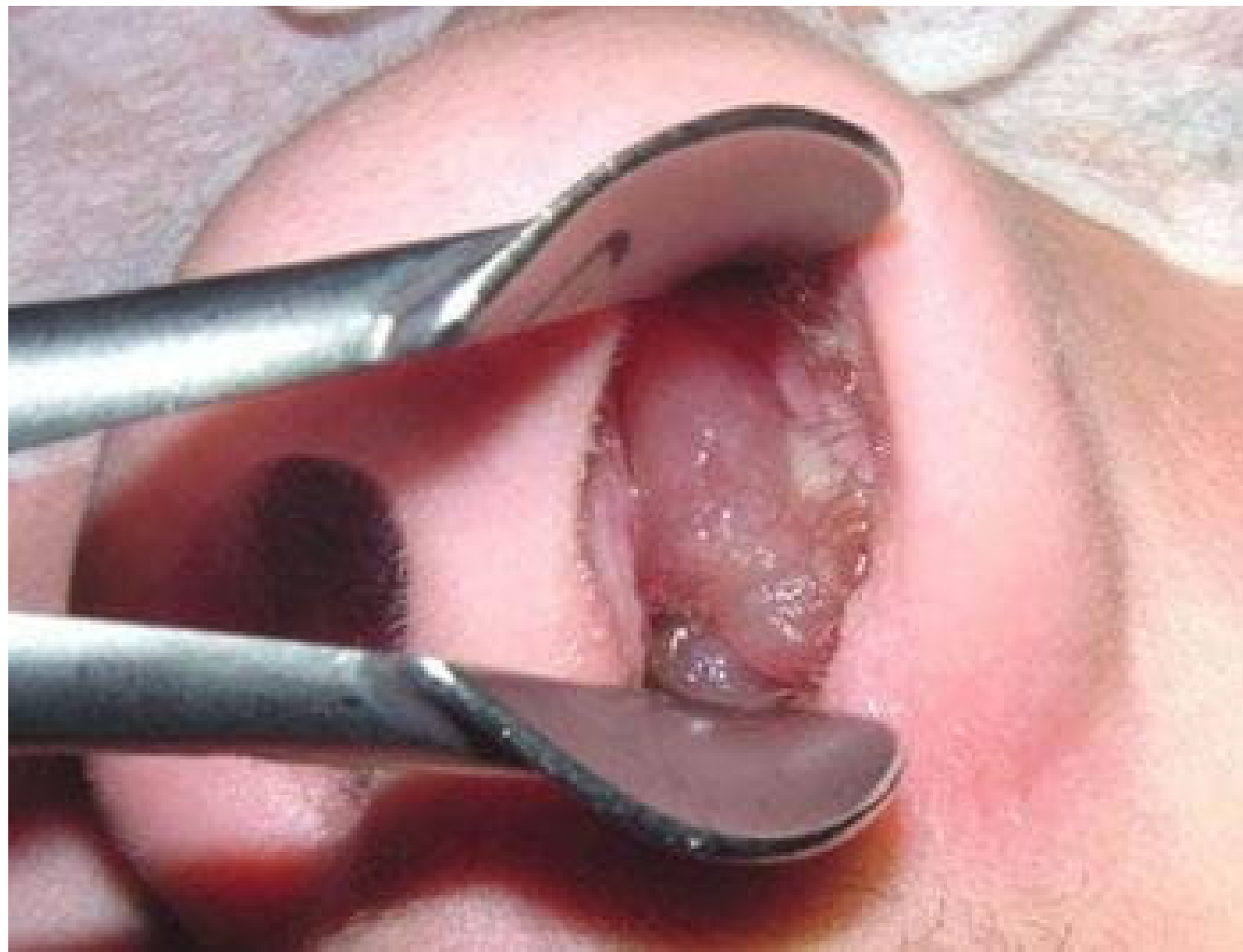



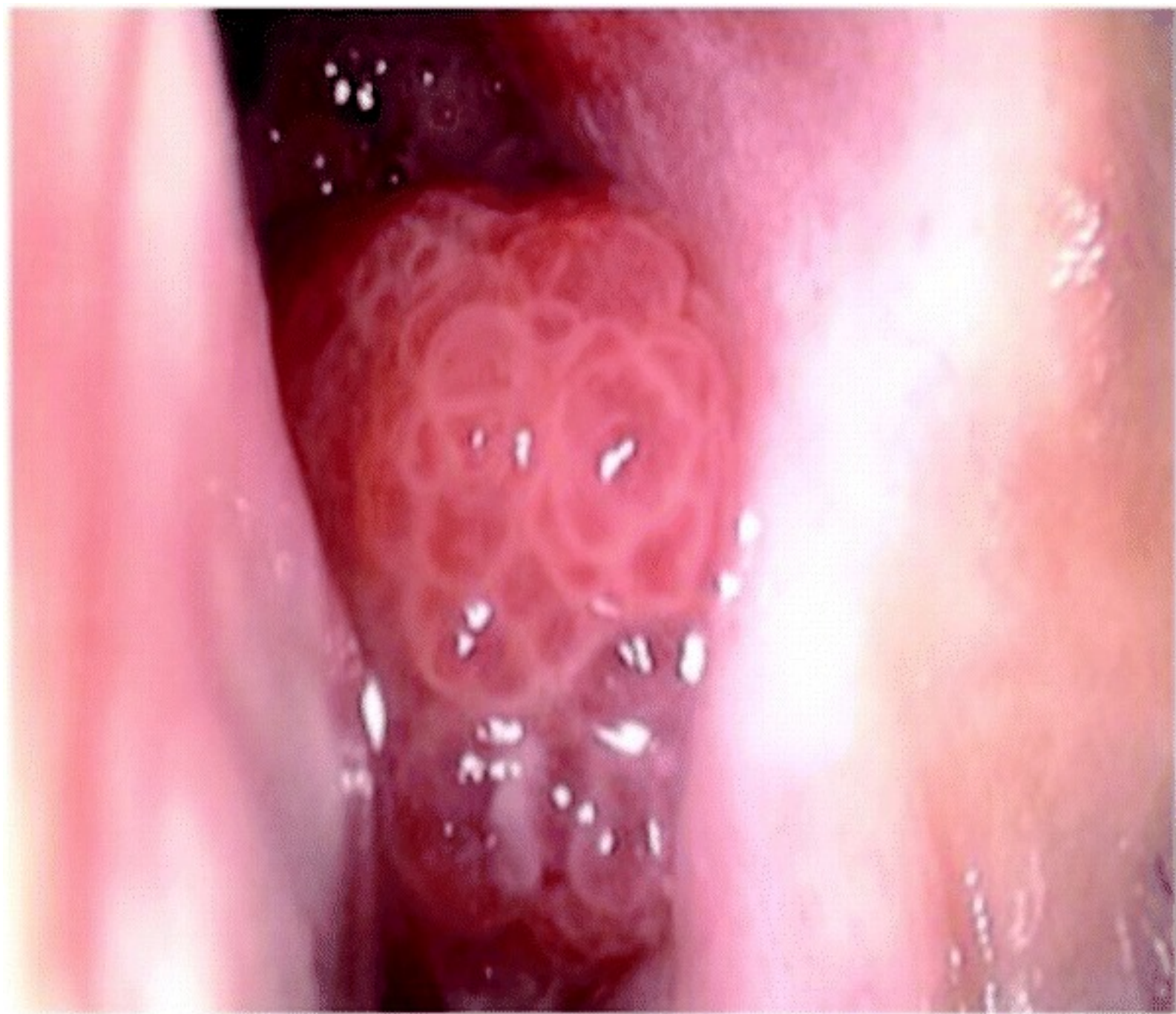


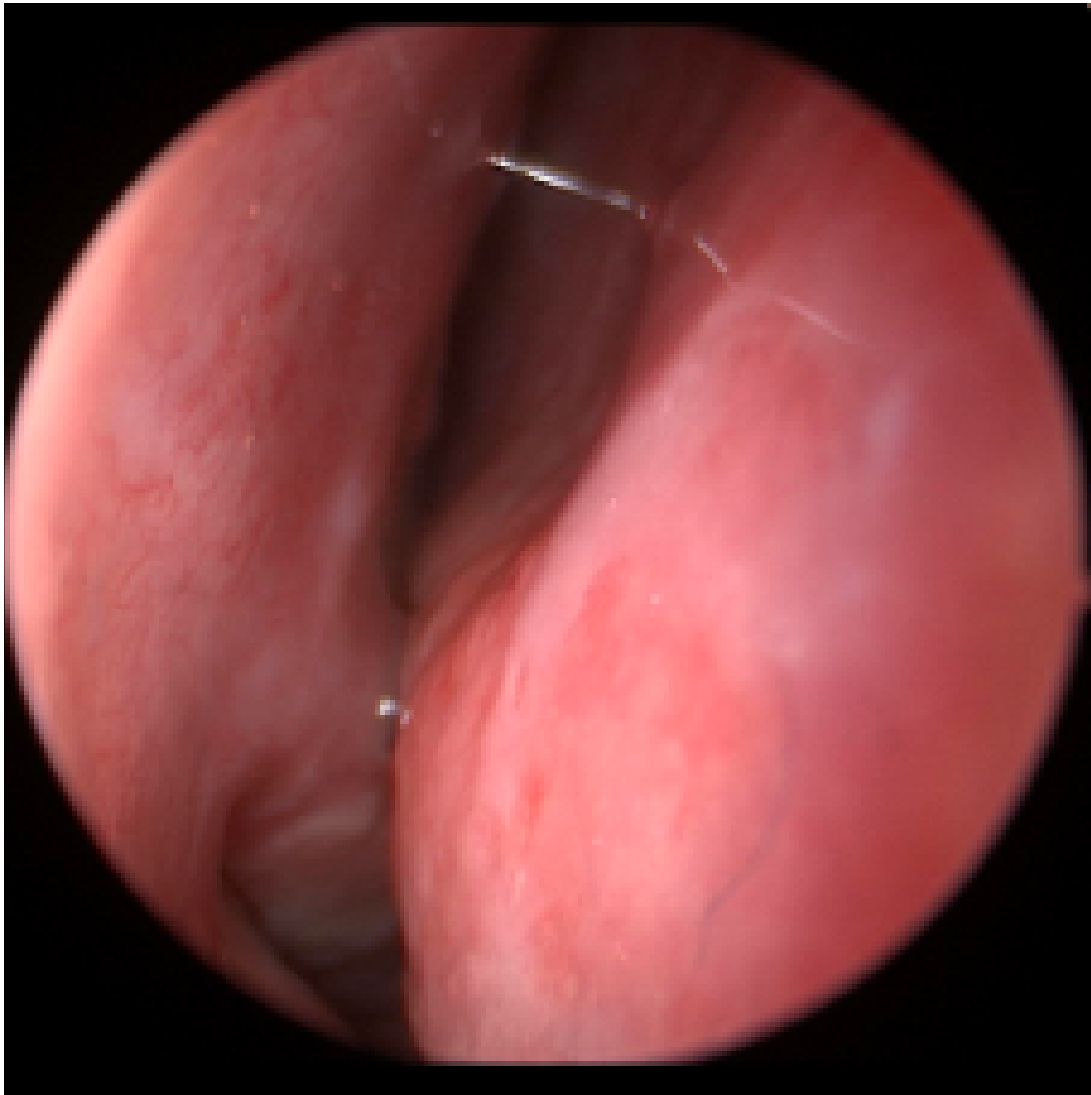




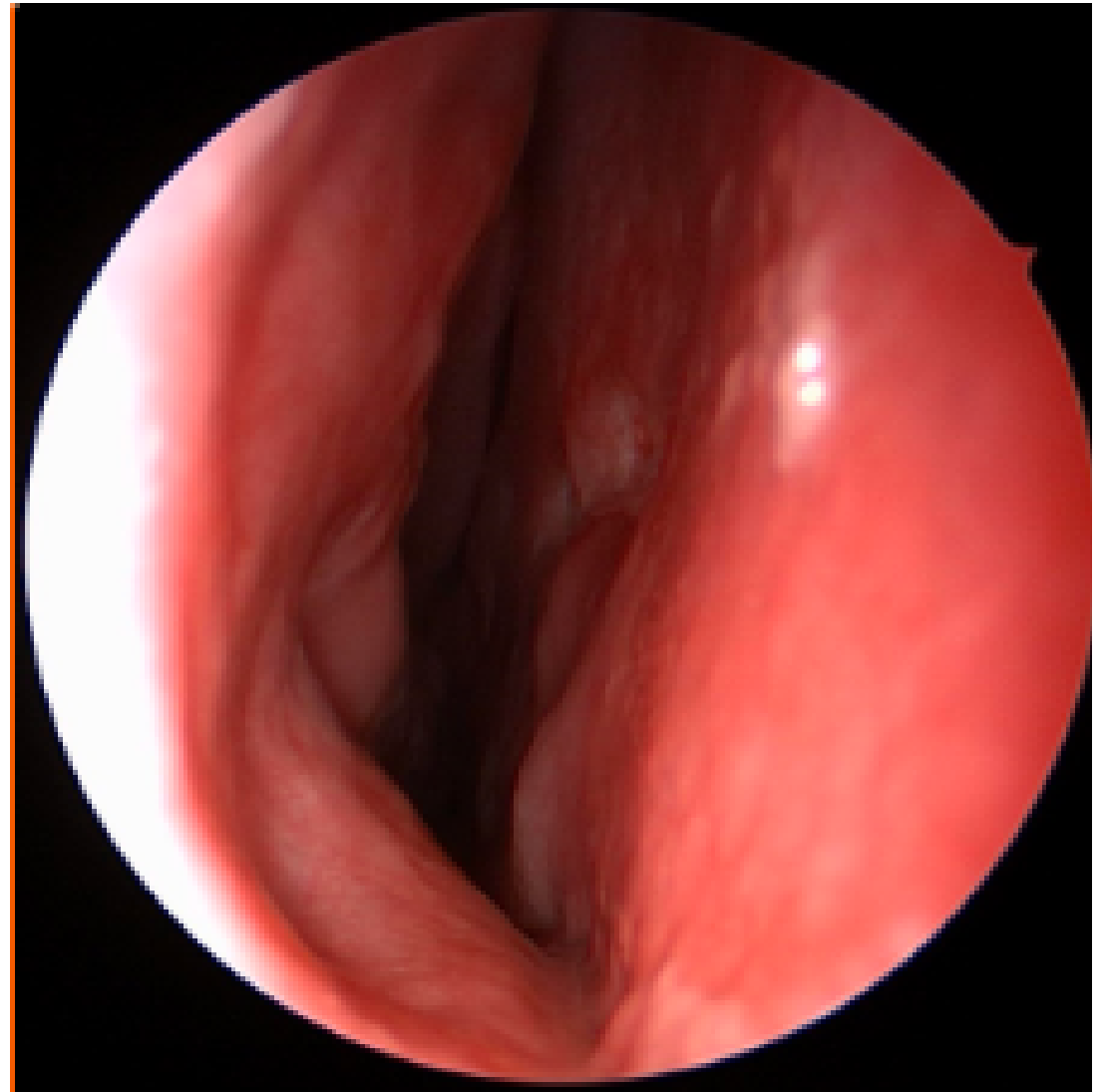




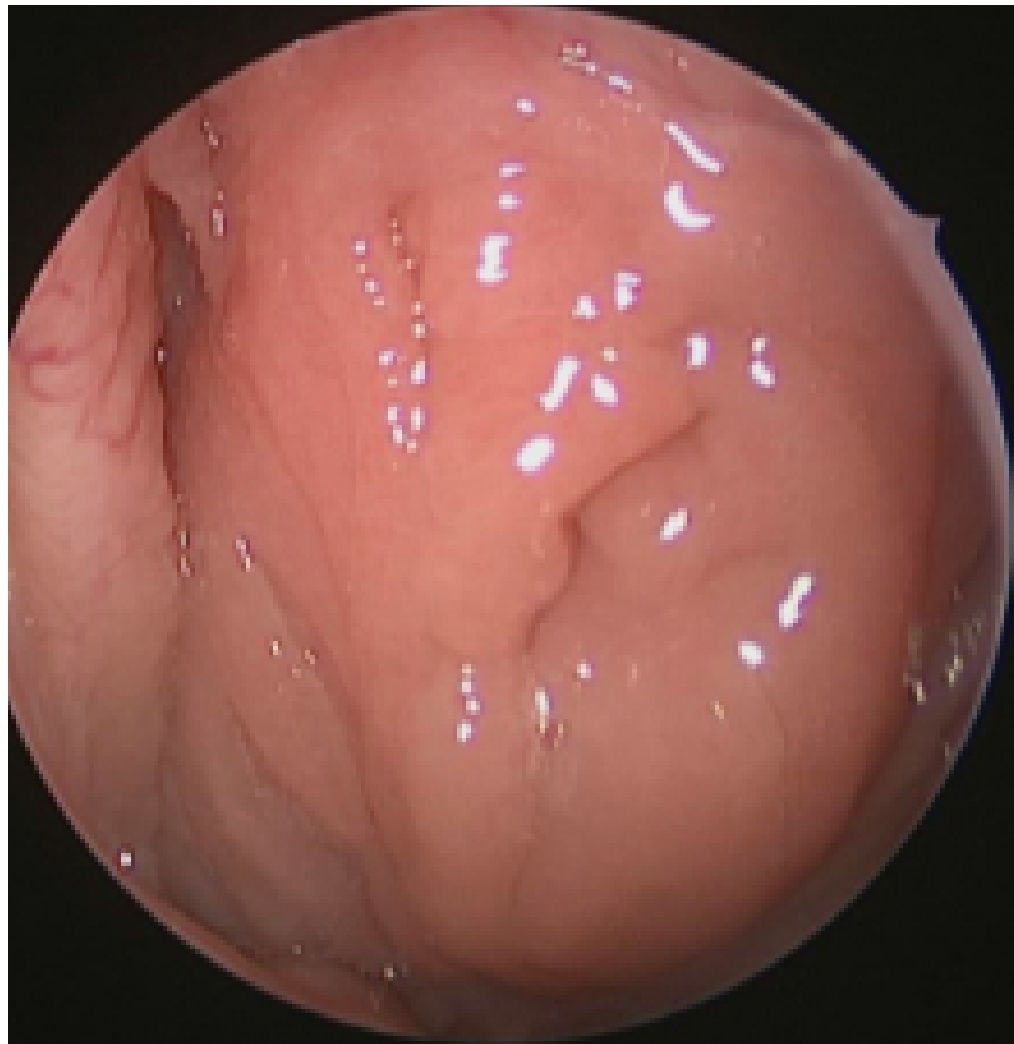




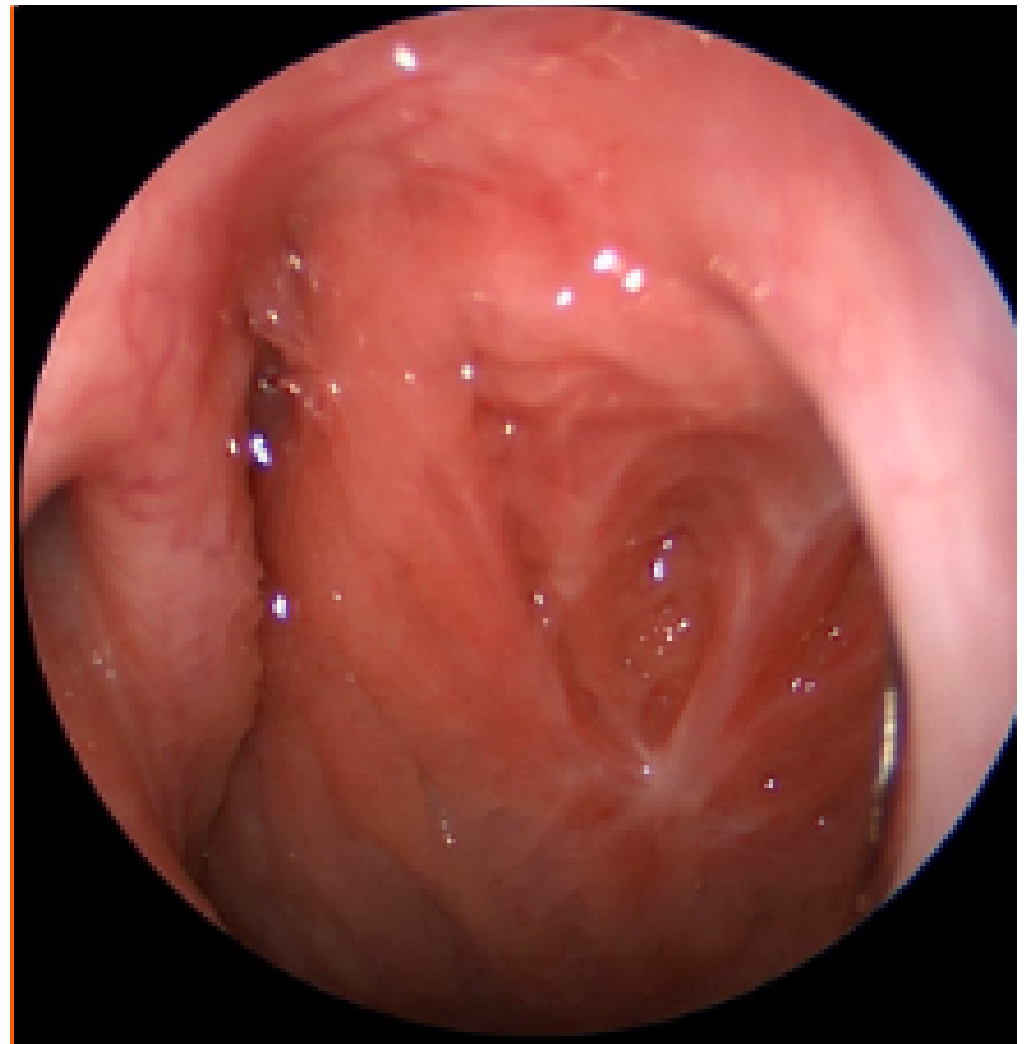
Deviated Nasal Septum



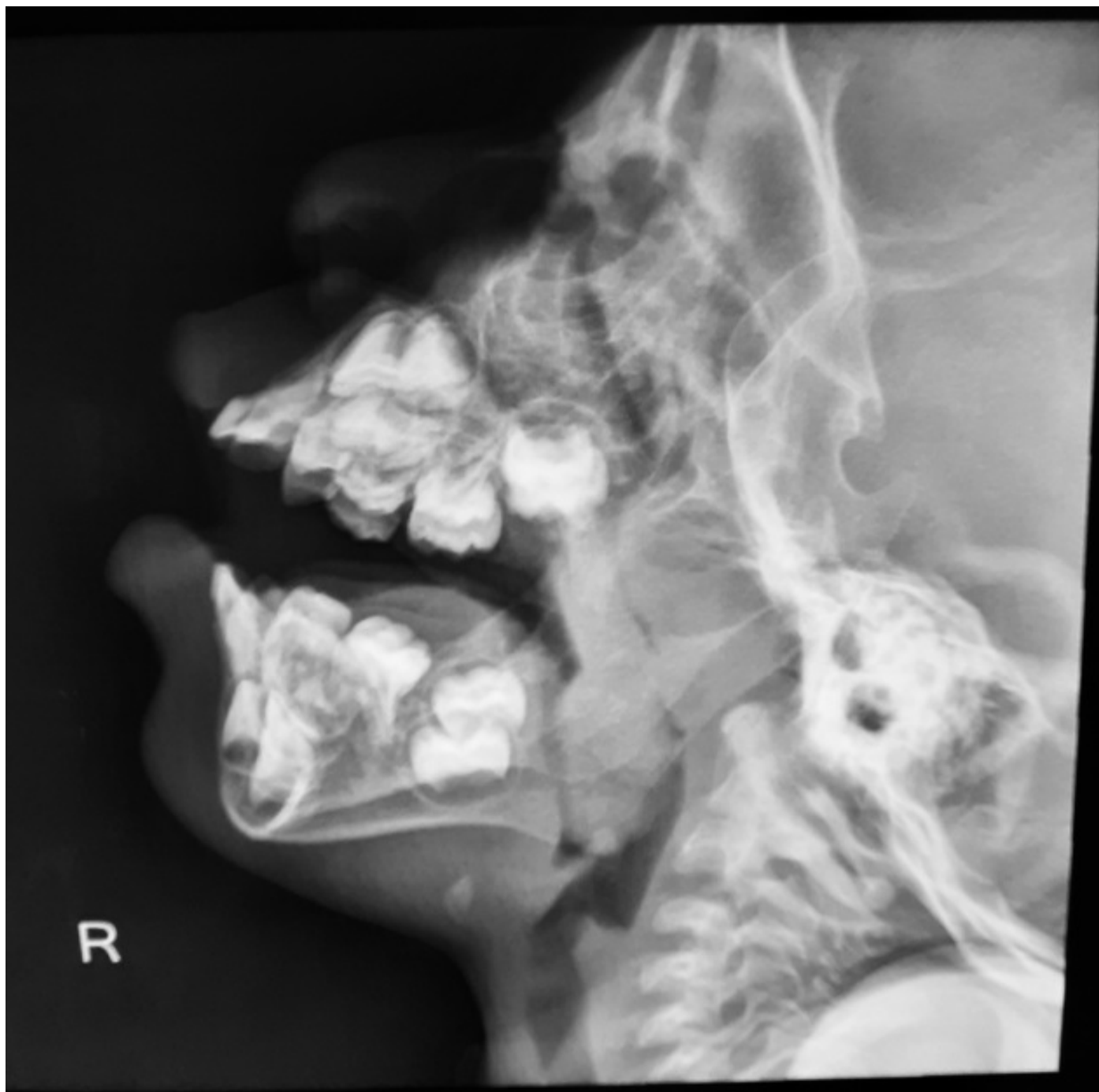Straight Septum



Adenoids Before  
Adenoidectomy



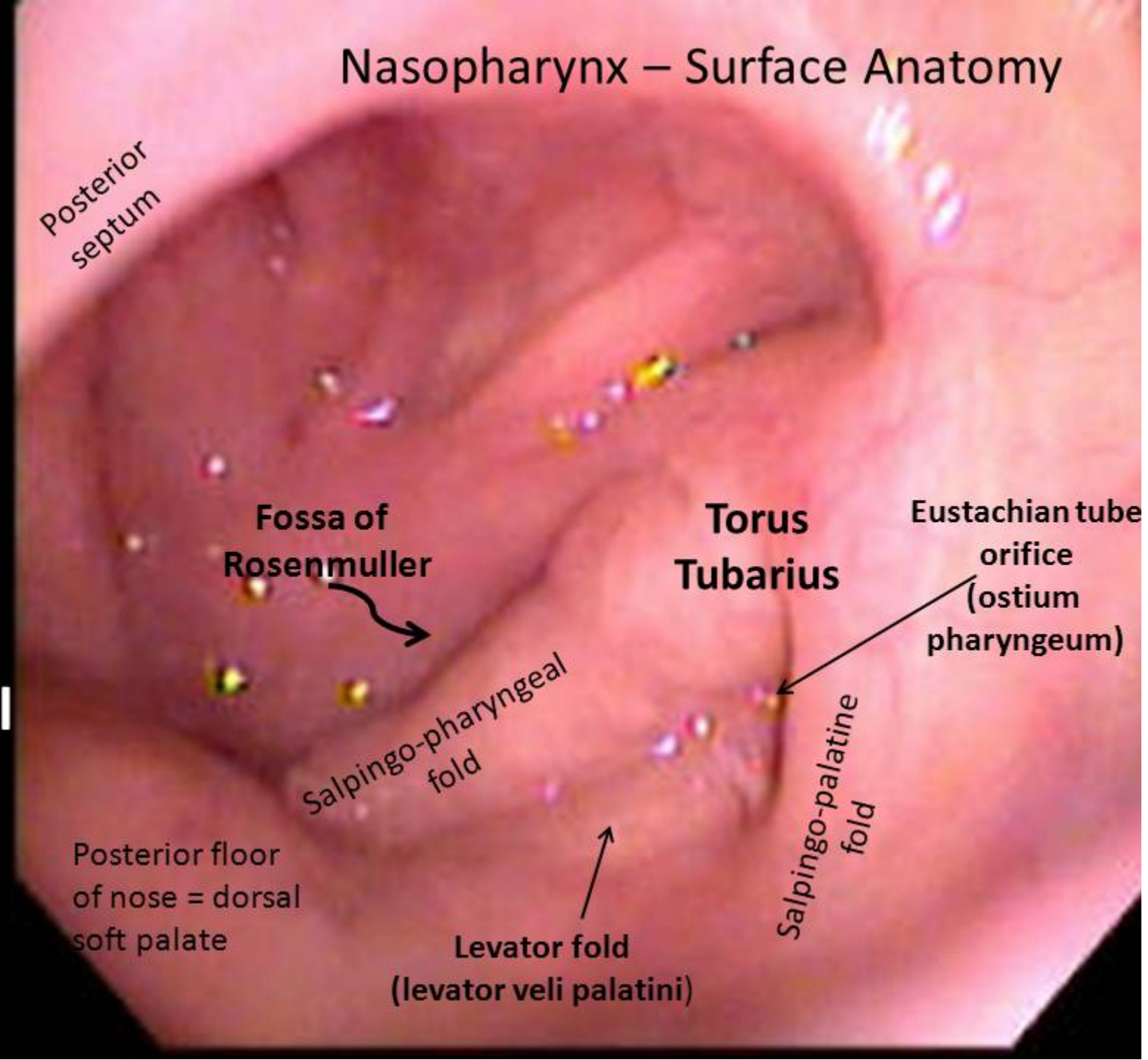
Adenoid Bed After  
Adenoidectomy

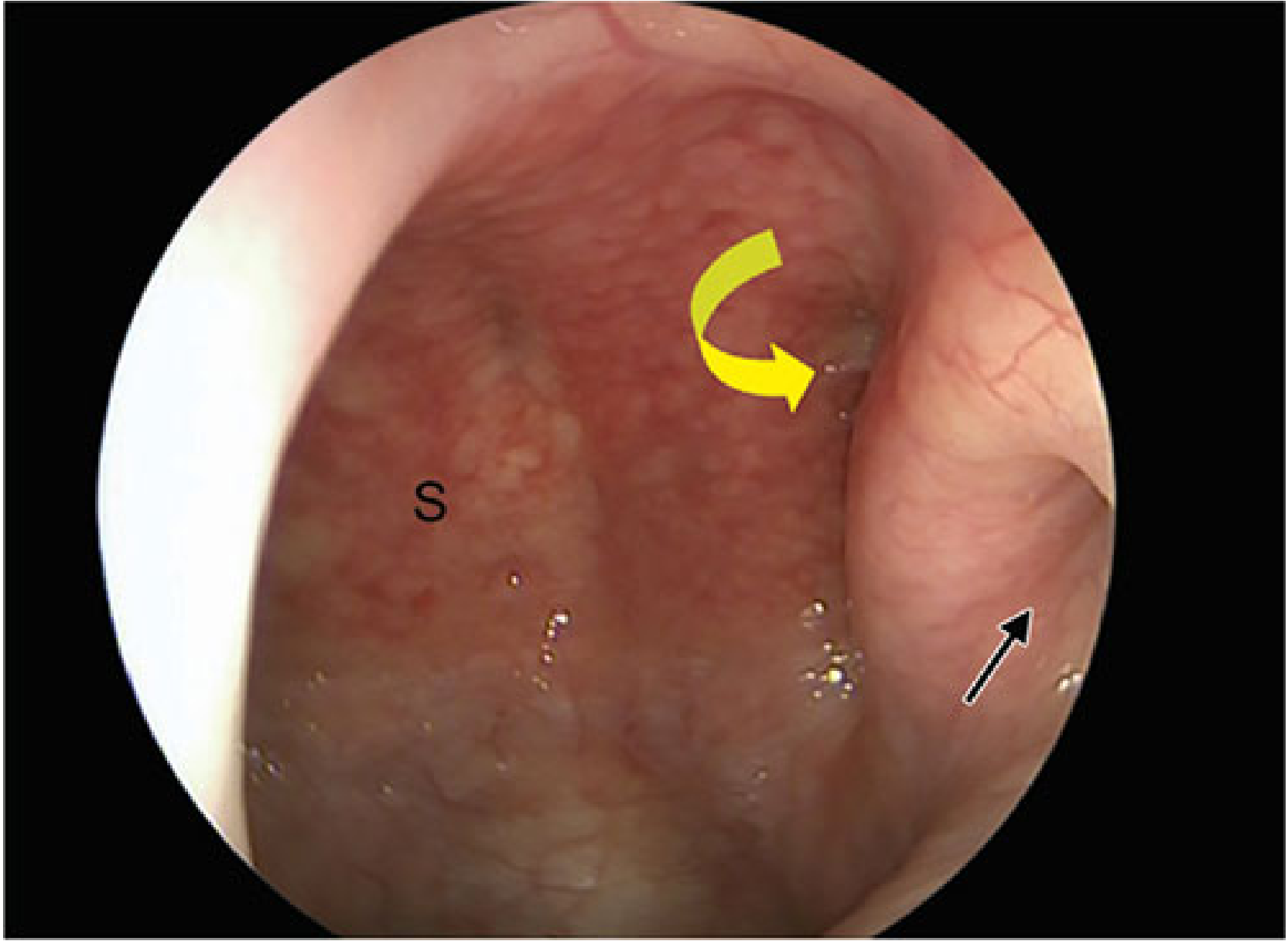


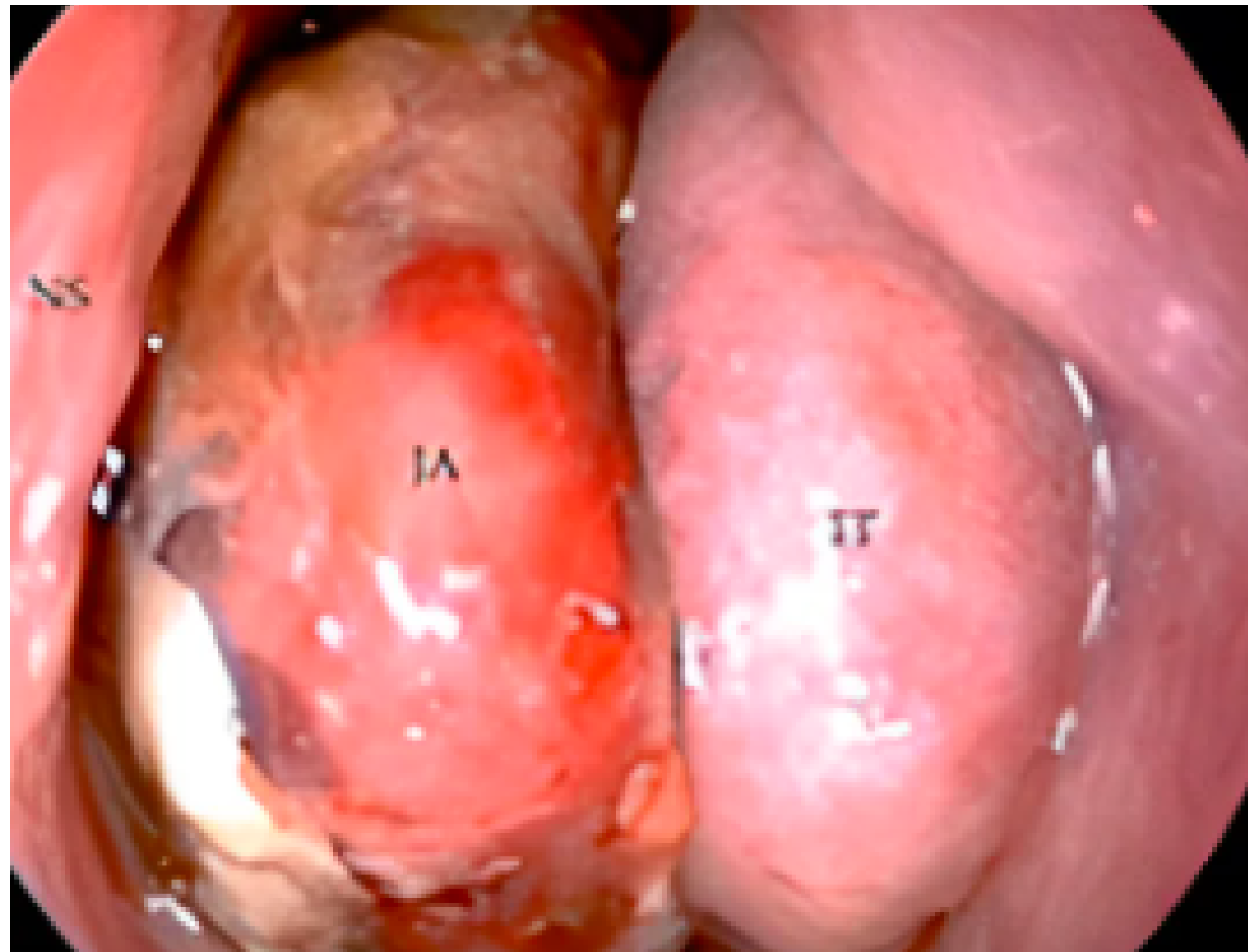


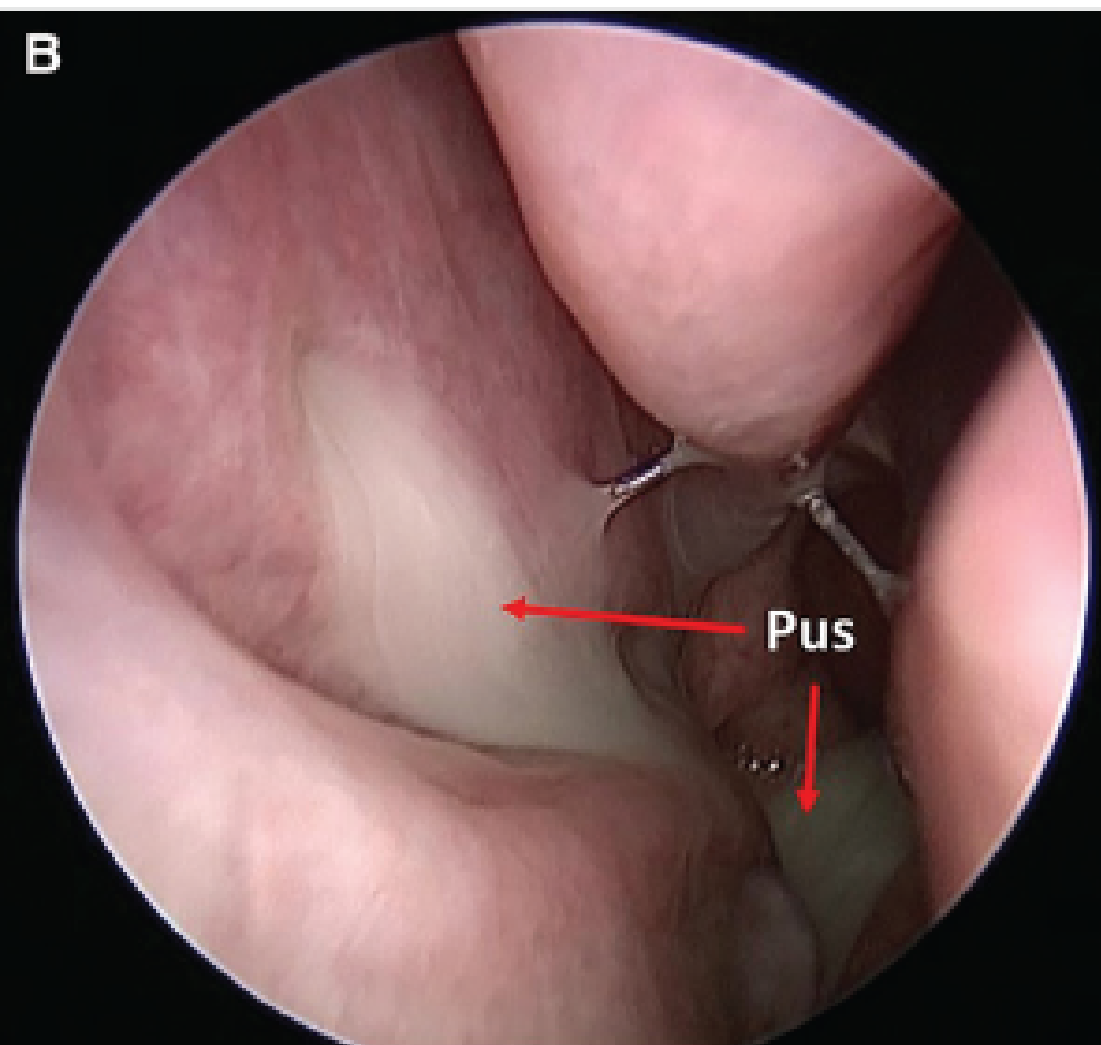
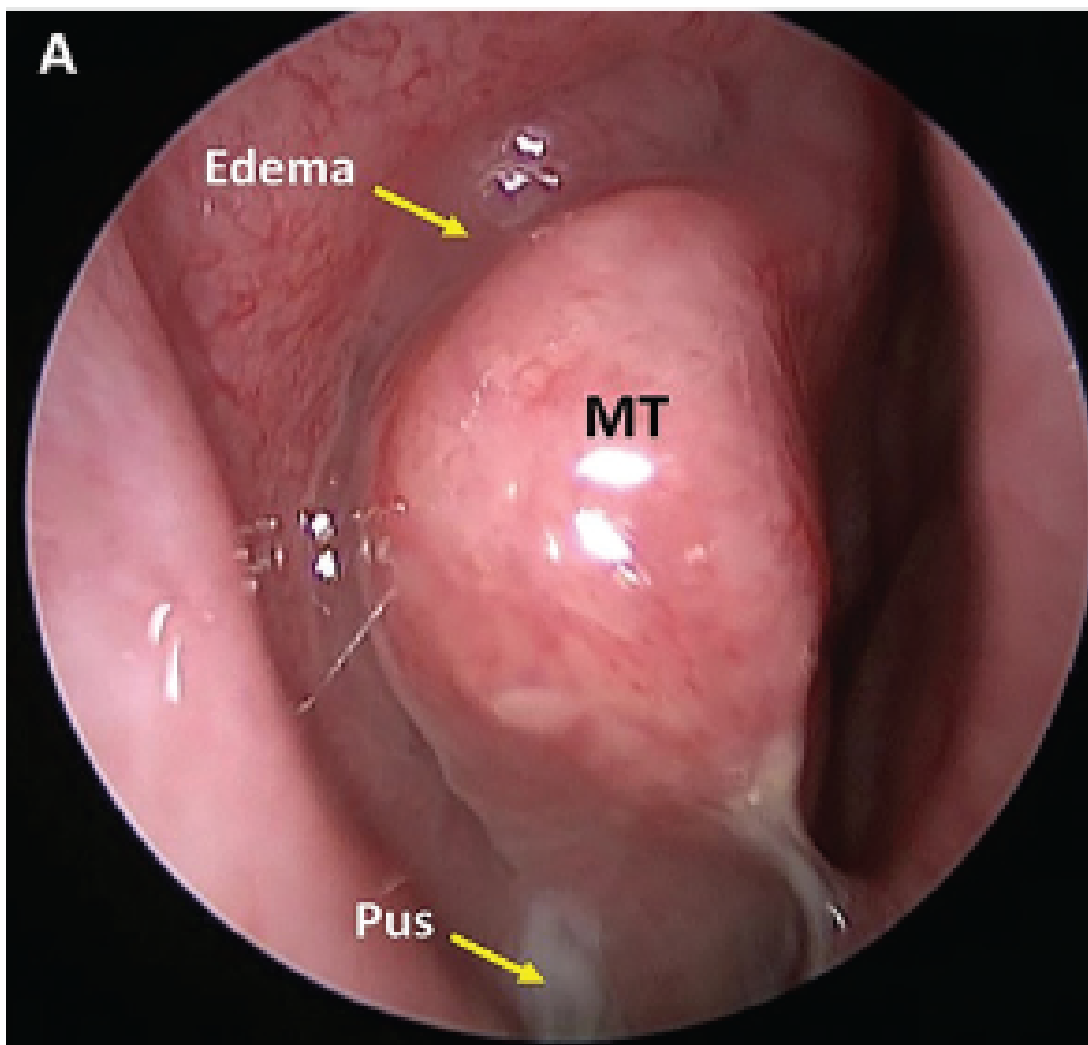
**View of  
naso-  
pharynx  
via scope  
placed  
through  
left nostril**

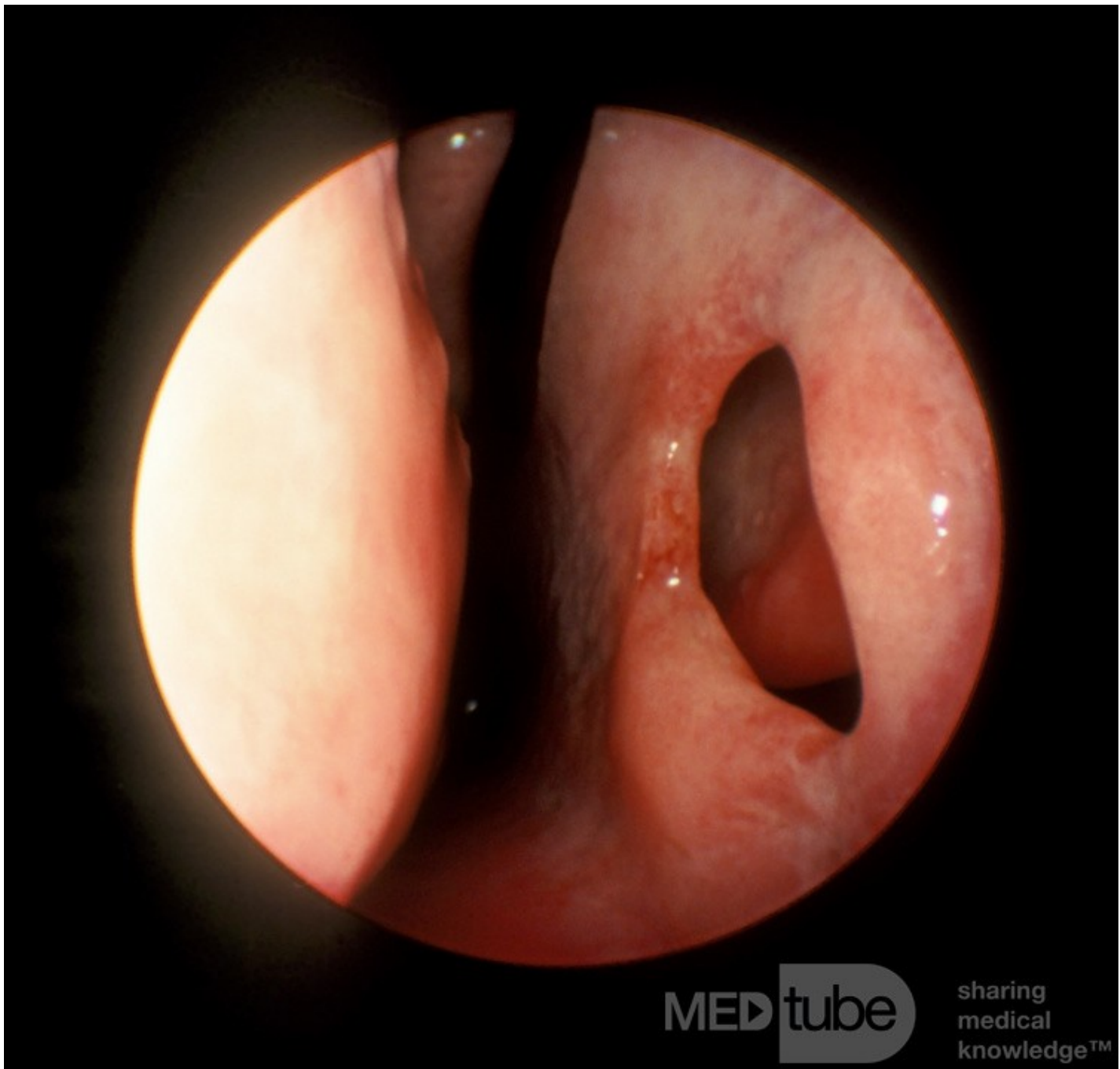
## Nasopharynx – Surface Anatomy



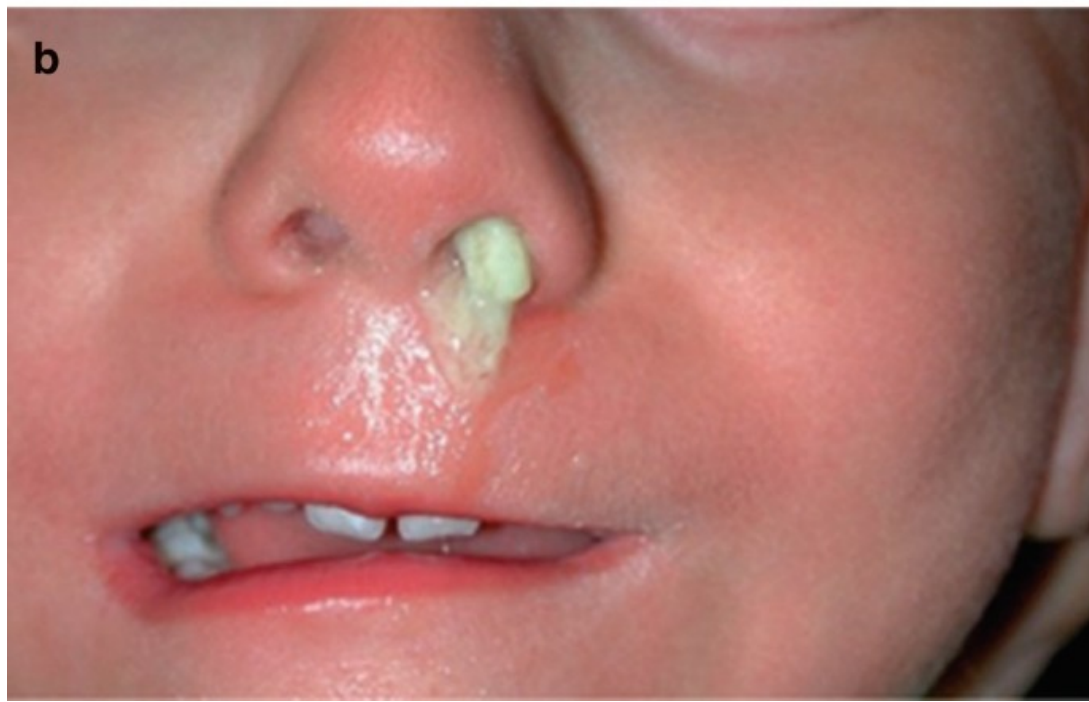
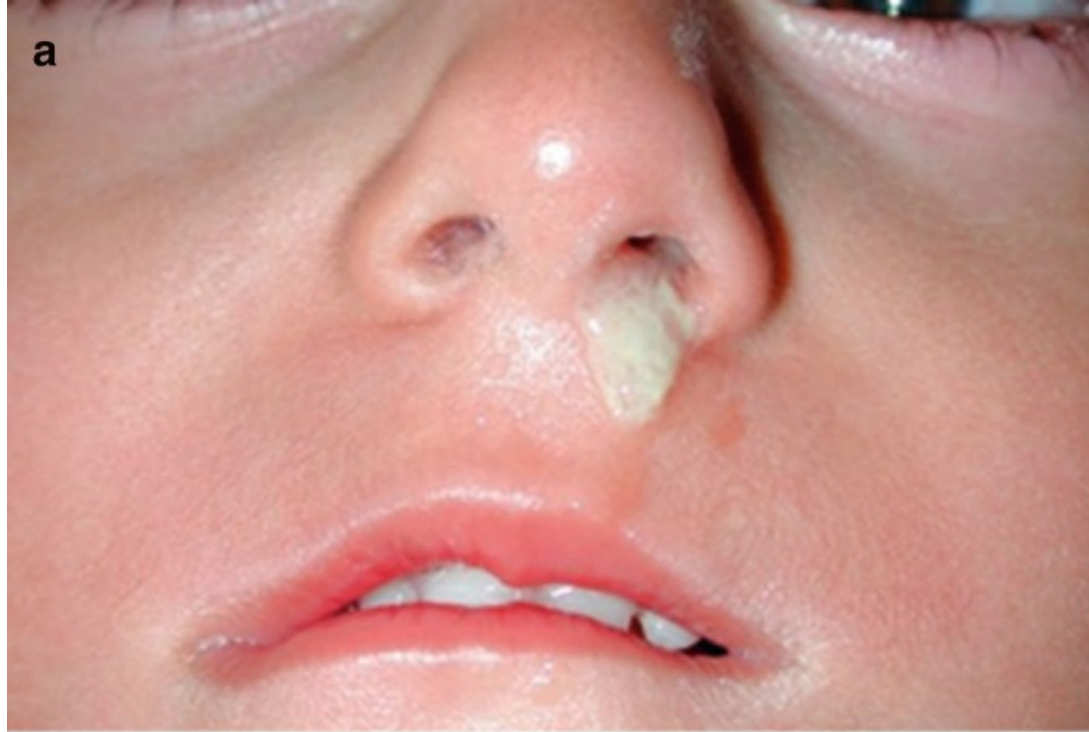


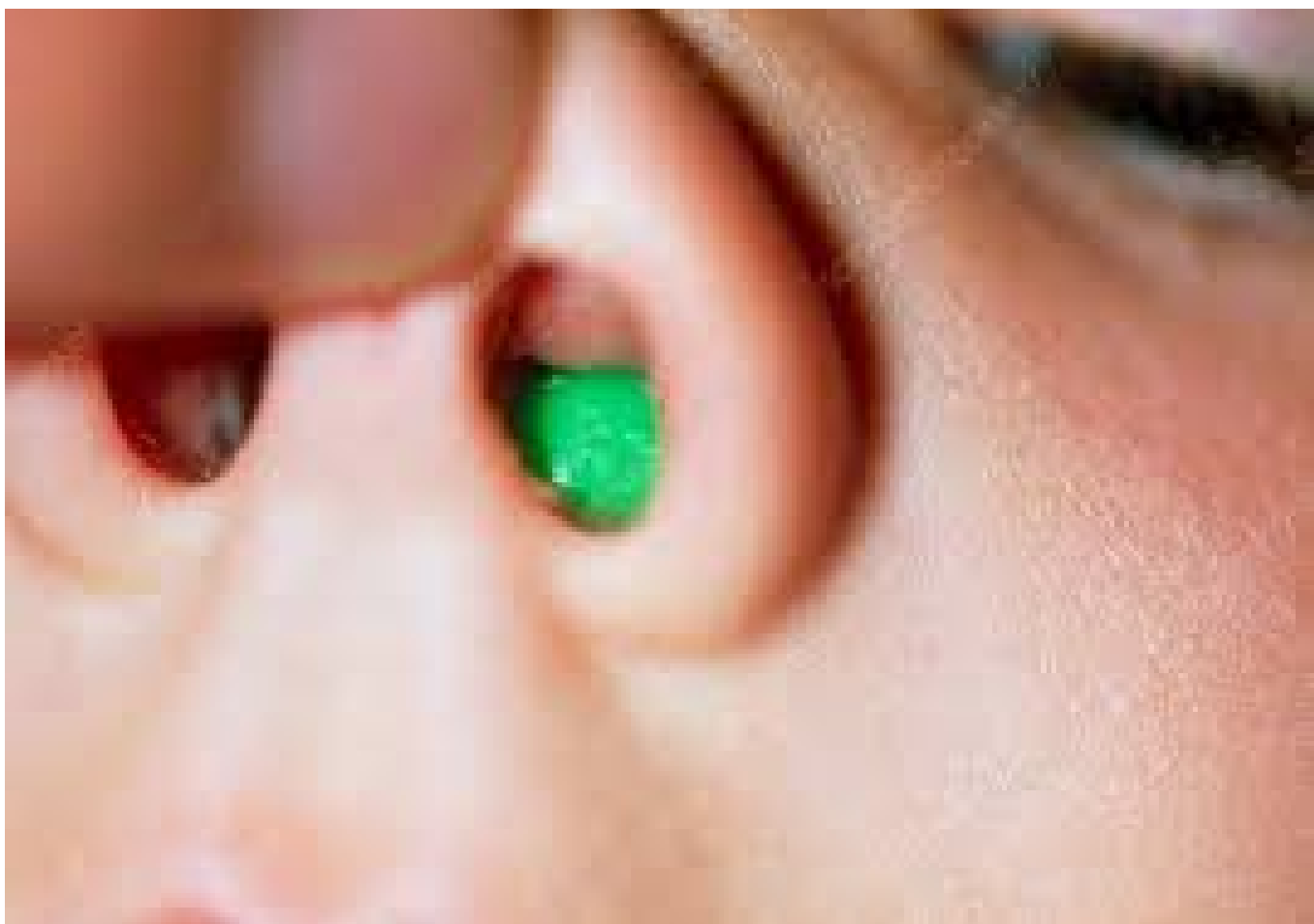









# Nasal Discharge



```
graph TD; A[Nasal Discharge] --> B[Unilateral]; A --> C[Bilateral]; B --> B1[FB (children)]; B --> B2[U/I Choanal atresia]; B --> B3[Antro-choanal polyp]; B --> B4[U/L Chronic sinusitis]; B --> B5[U/L Rhinosporidiosis]; B --> B6[Rhinolith , CSF Rhinorrhea]; B --> B7[Neoplasm Nose & PNS]; C --> C1[Enlarged Adenoids]; C --> C2[B/I Choanal atresia]; C --> C3[Ethmoidal polyp]; C --> C4[B/L Chronic sinusitis]; C --> C5[B/L Rhinosporidiosis]; C --> C6[AR, VMR];
```

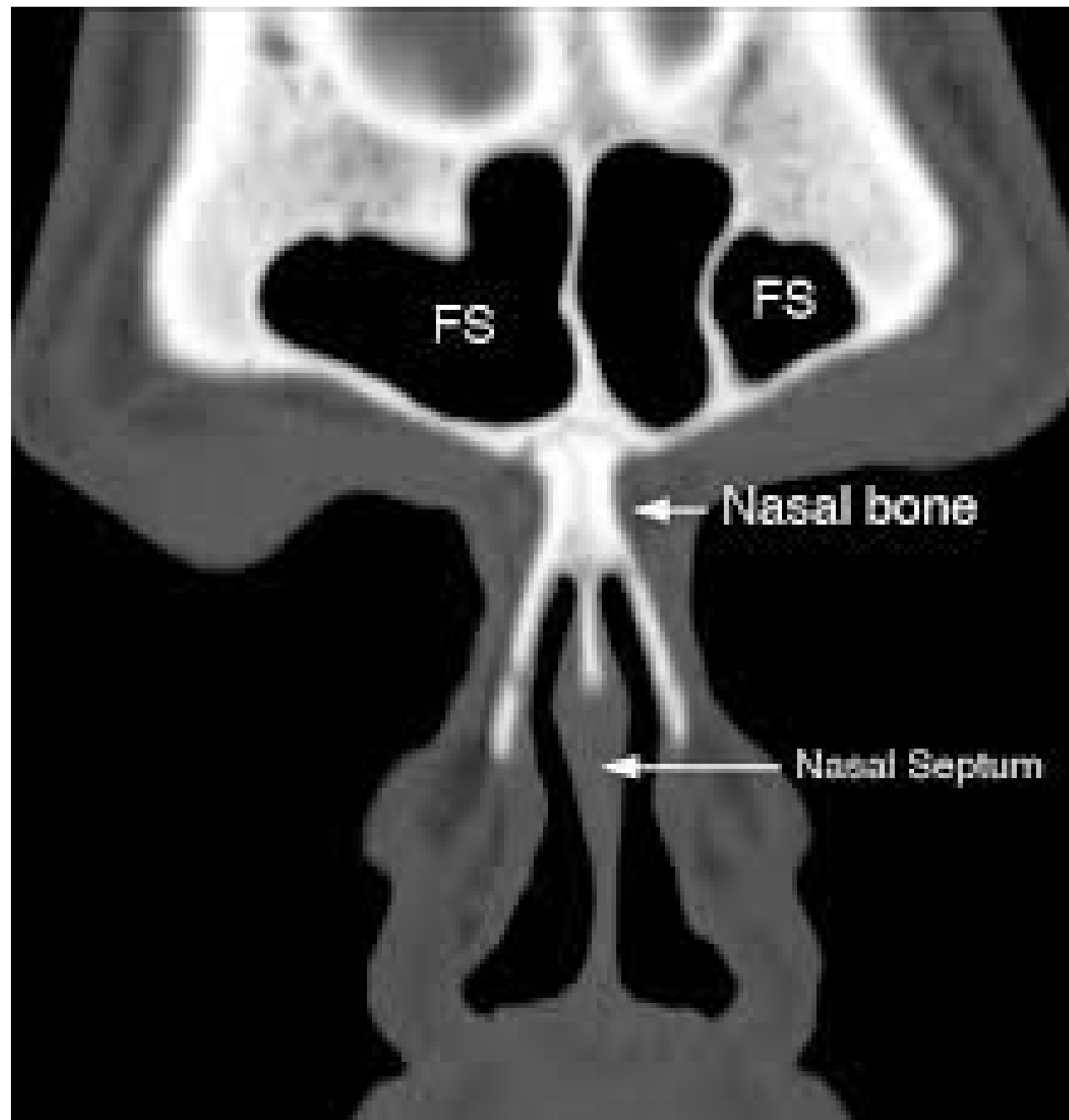
## Unilateral

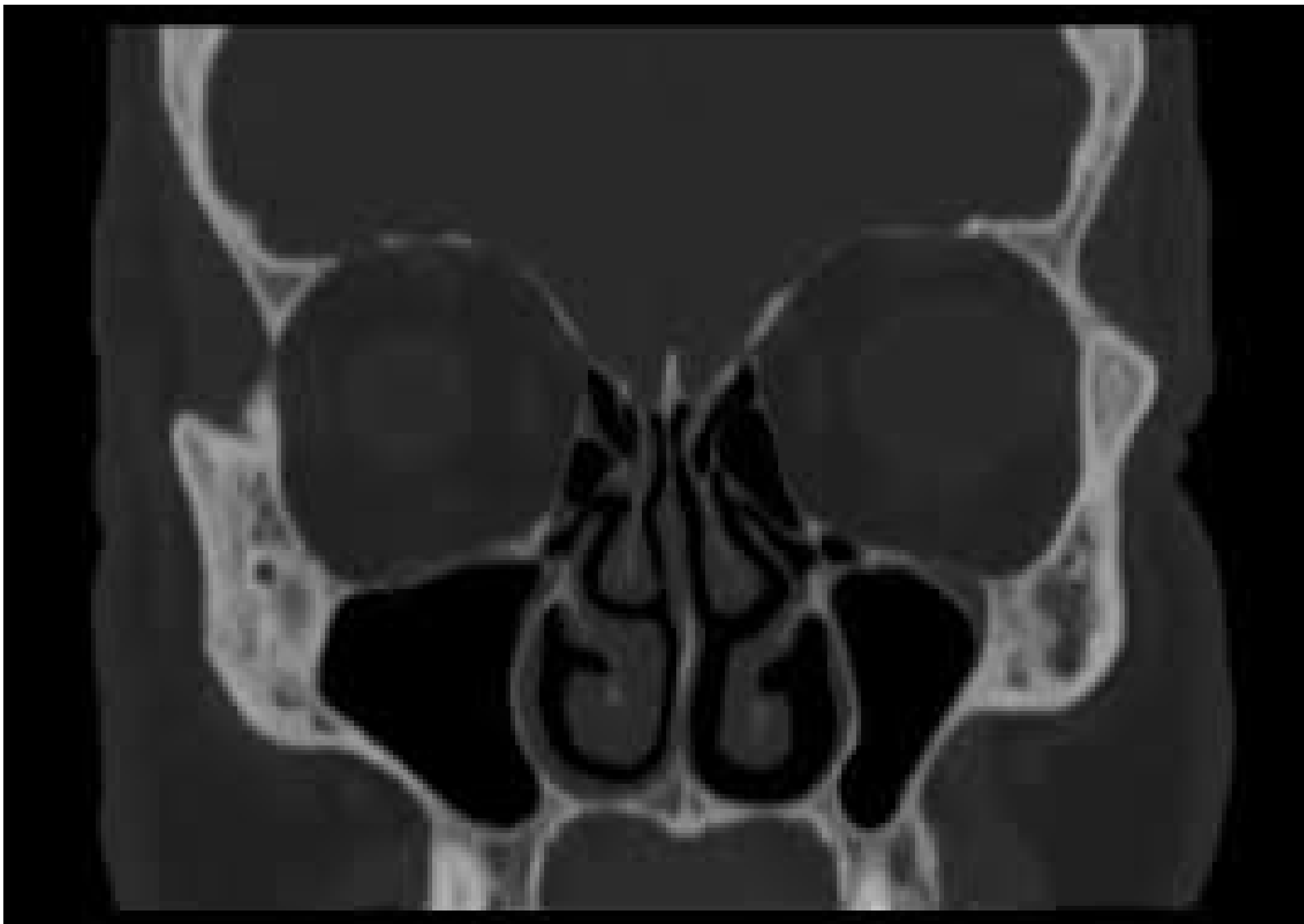
FB (children)  
U/I Choanal atresia  
Antro-choanal polyp  
U/L Chronic sinusitis  
U/L Rhinosporidiosis  
Rhinolith , CSF Rhinorrhea  
Neoplasm Nose & PNS

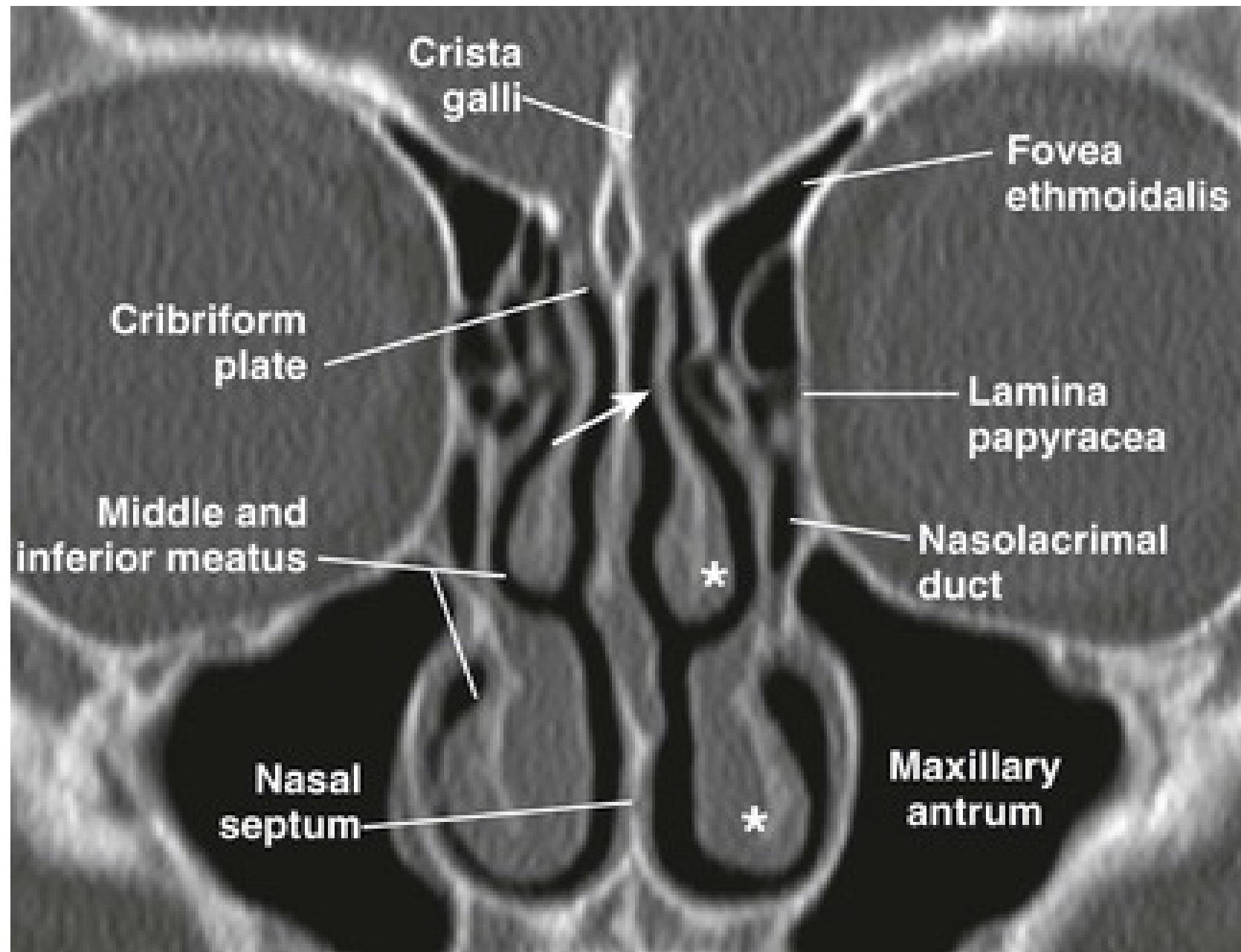
## Bilateral

Enlarged Adenoids  
B/I Choanal atresia  
Ethmoidal polyp  
B/L Chronic sinusitis  
B/L Rhinosporidiosis  
AR, VMR

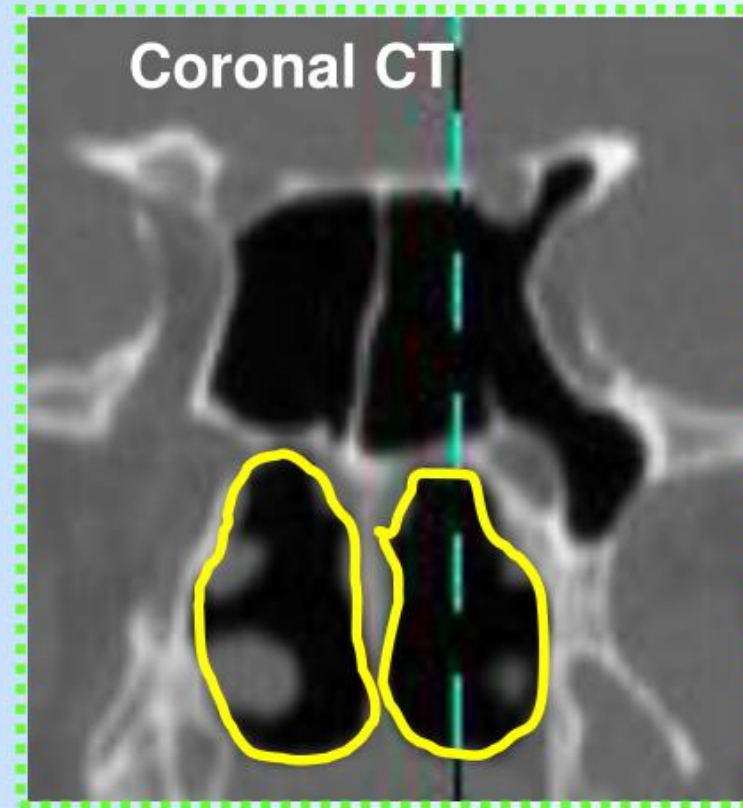
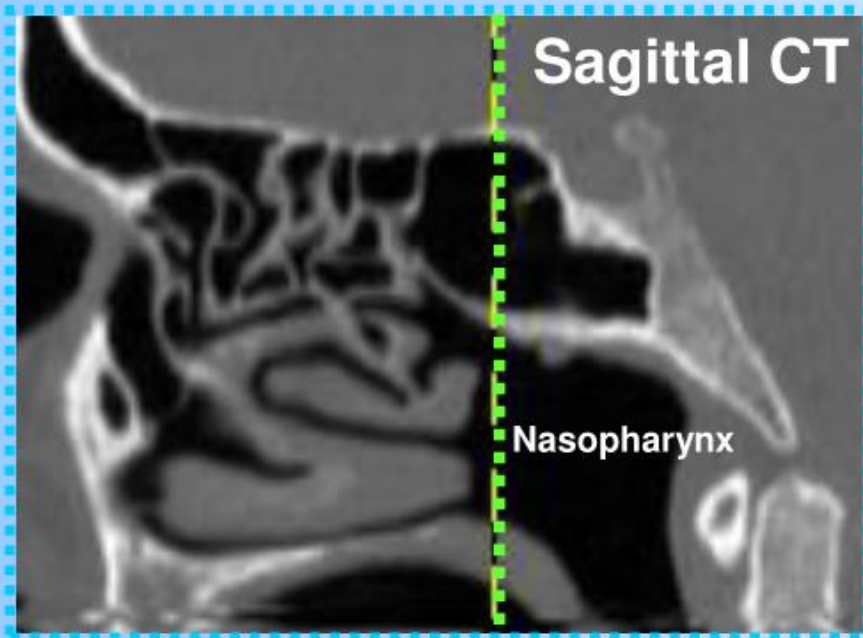


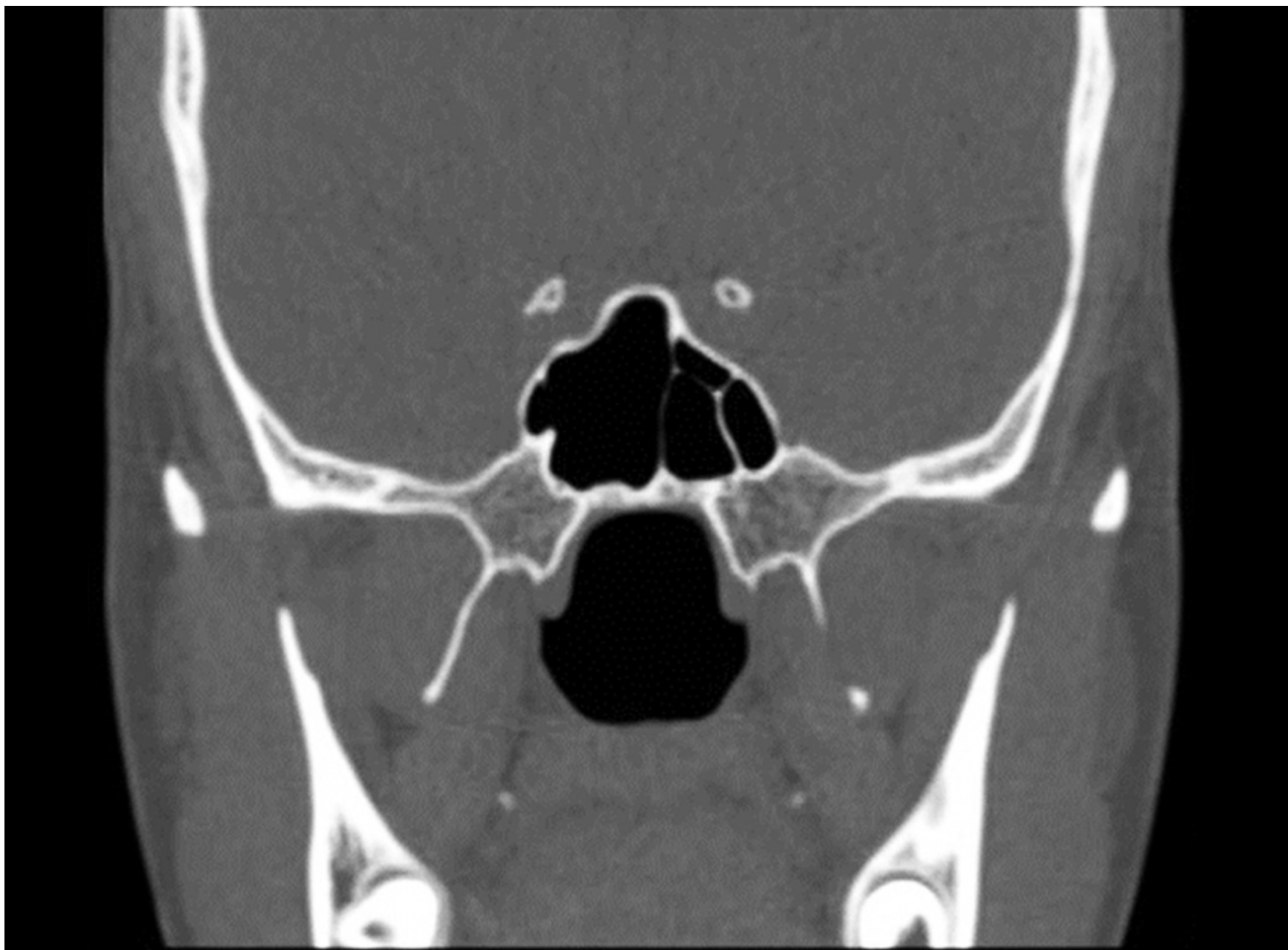


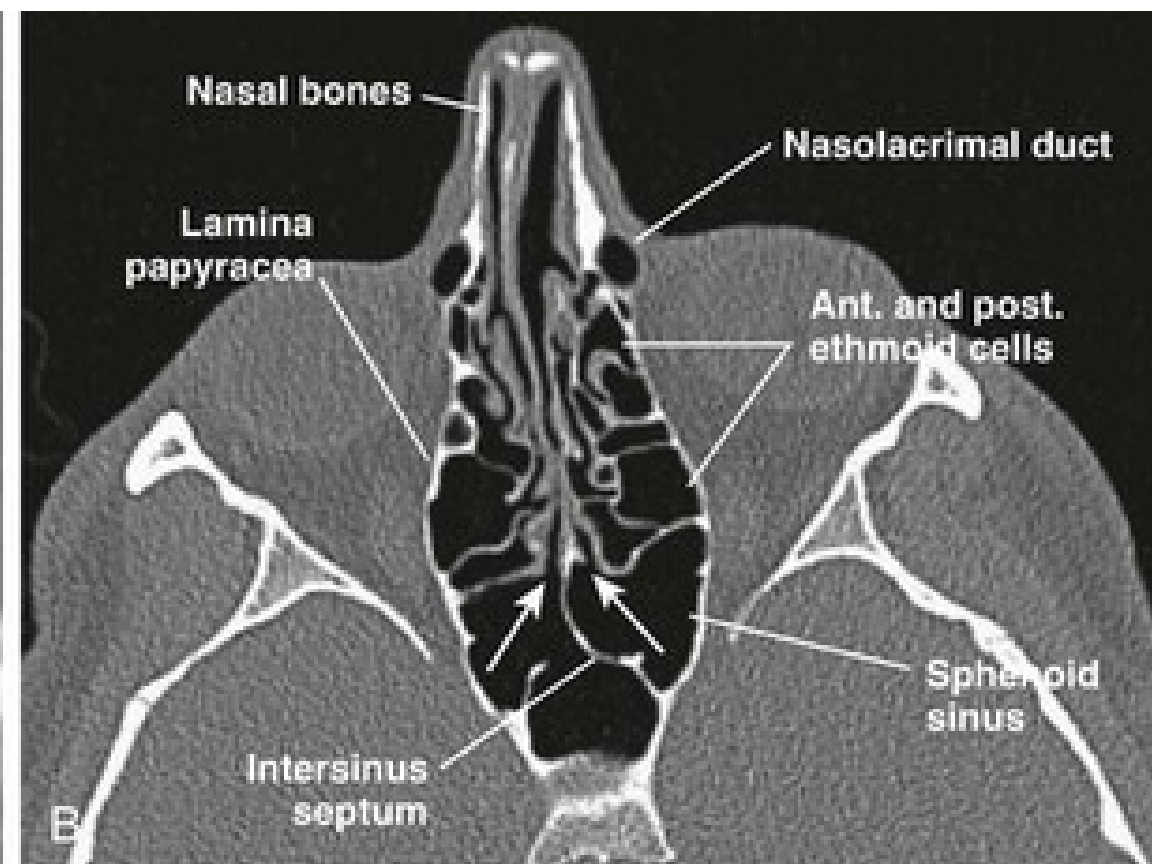
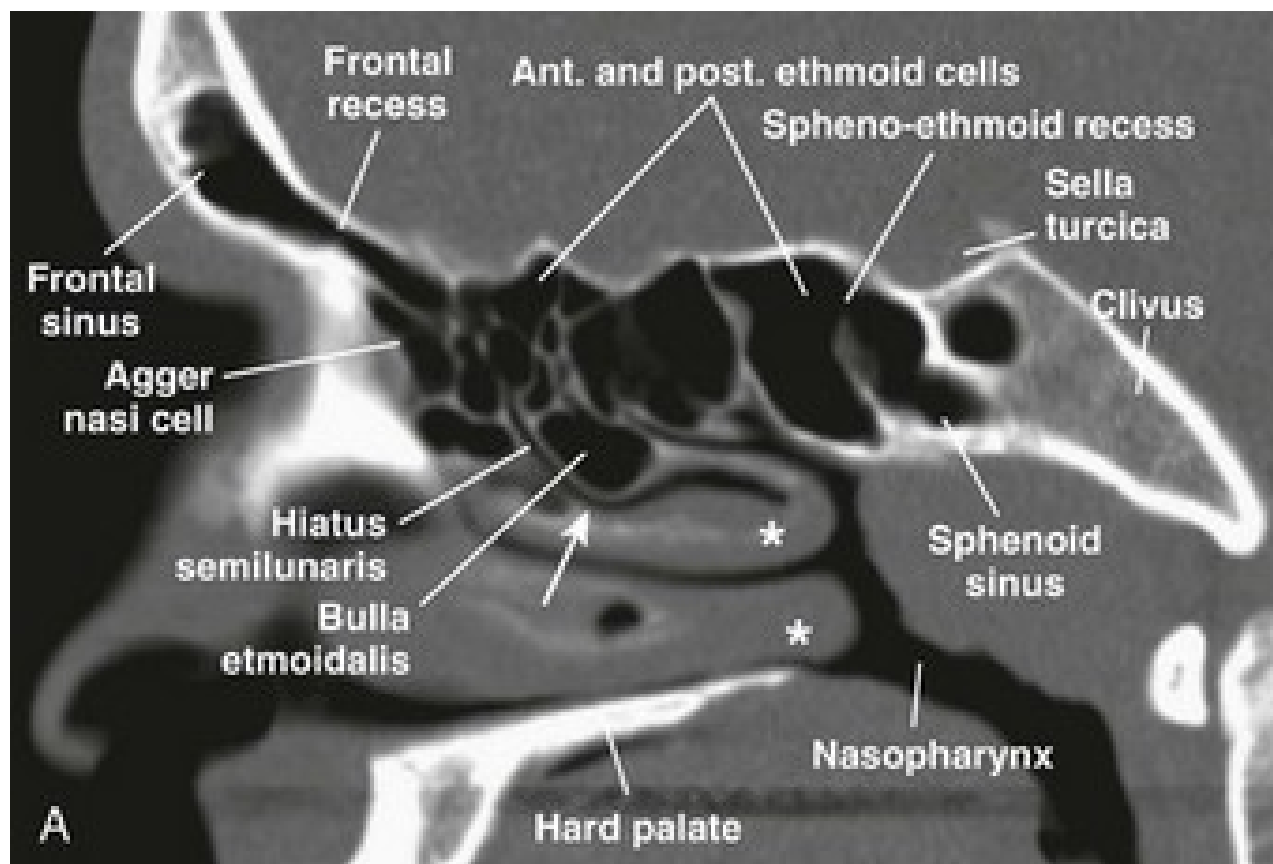


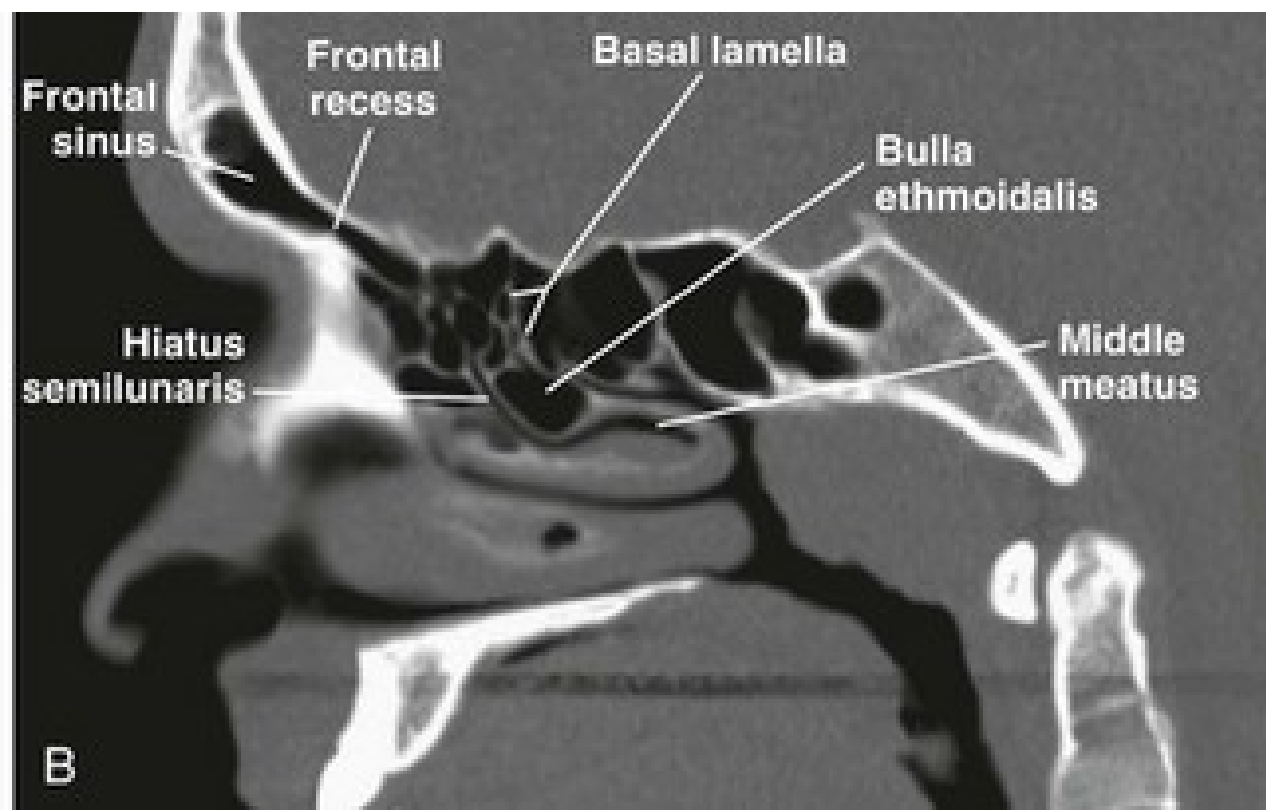
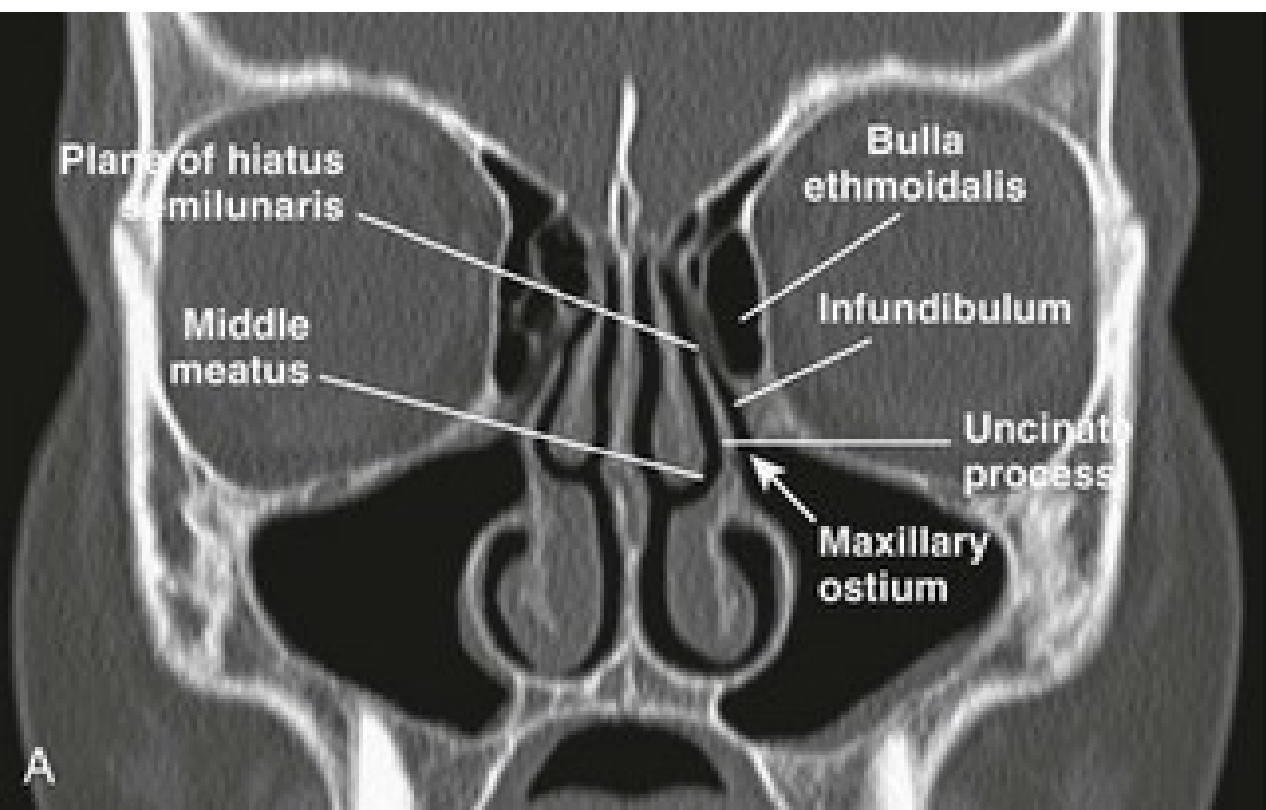


# Posterior choana

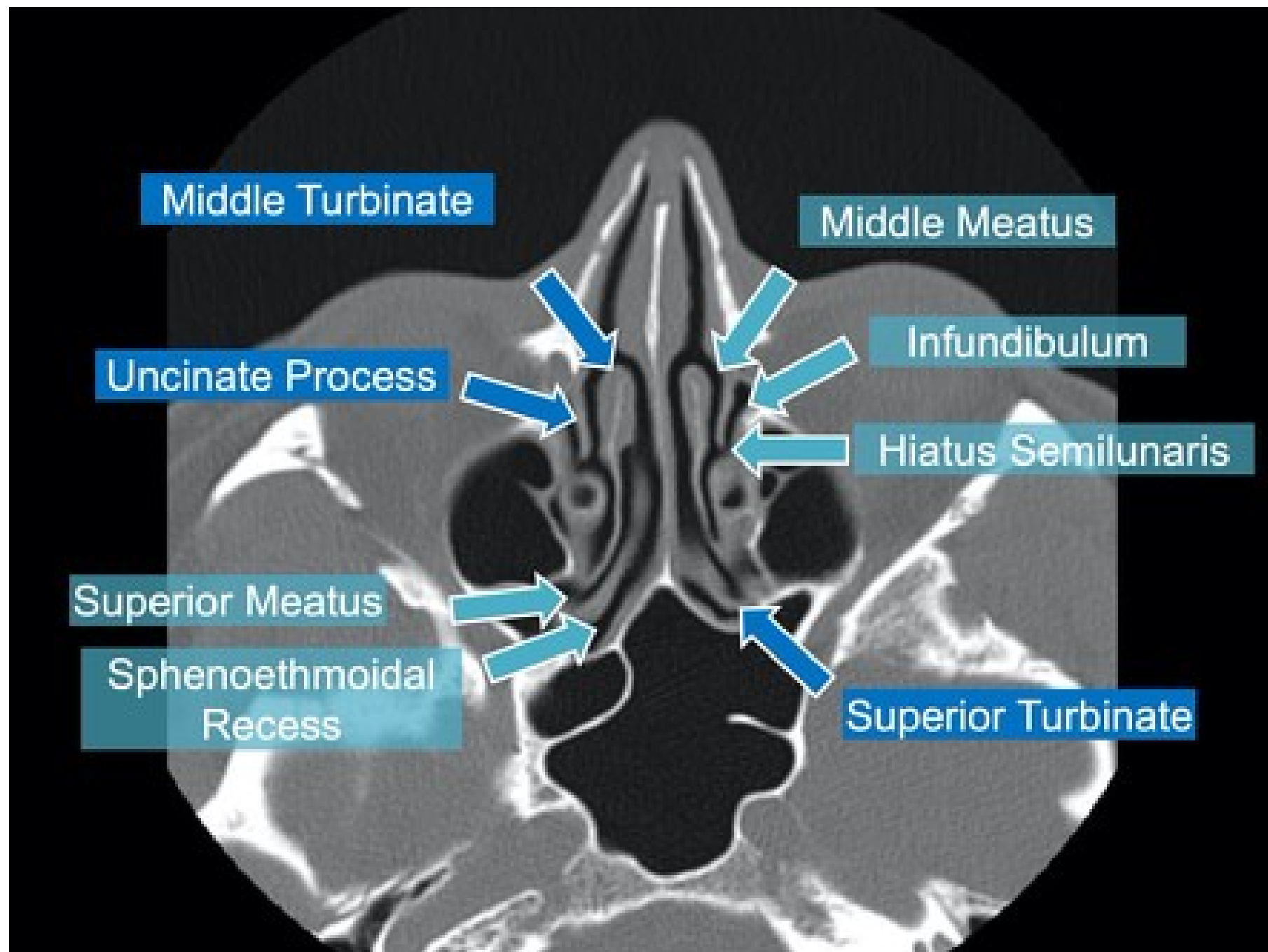


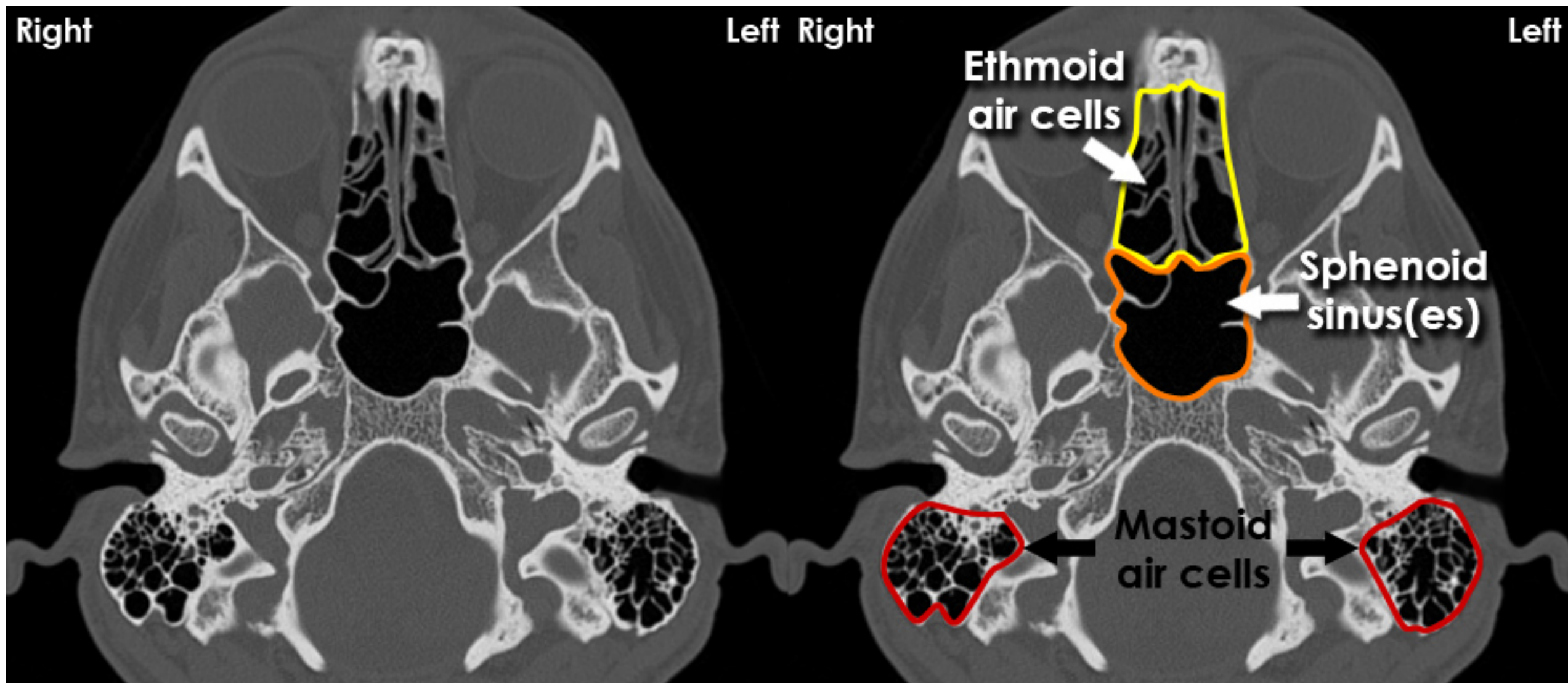


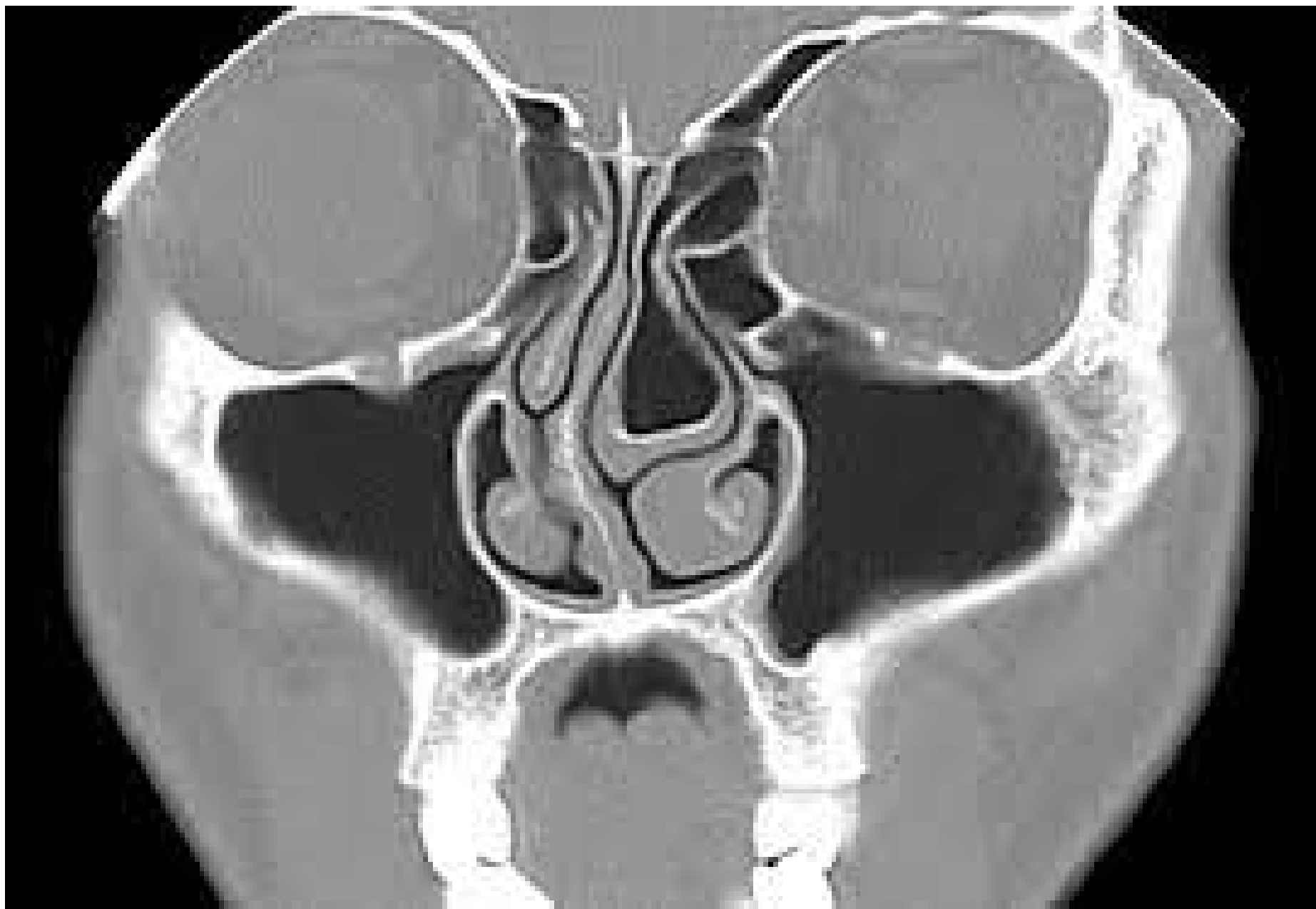

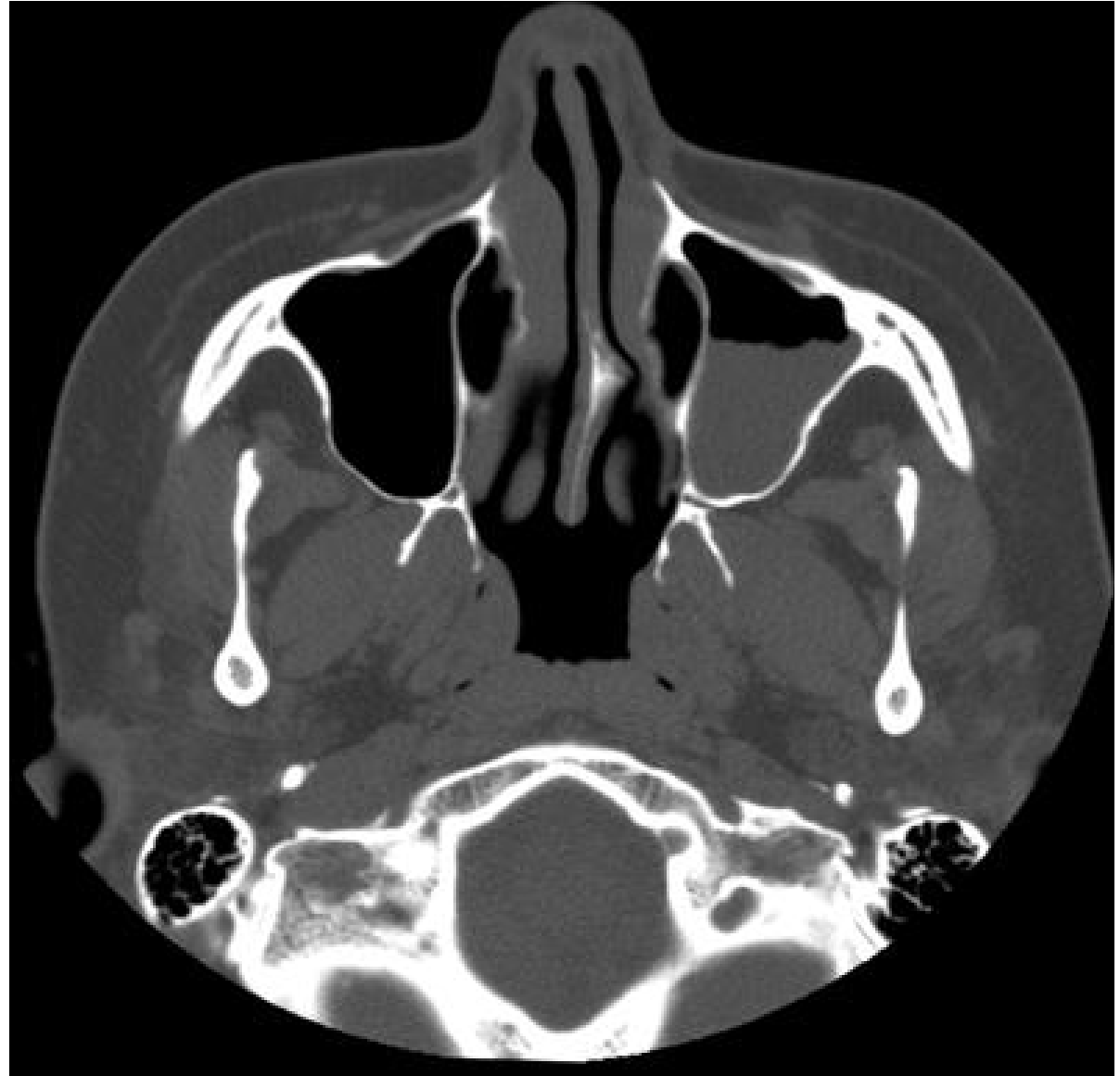
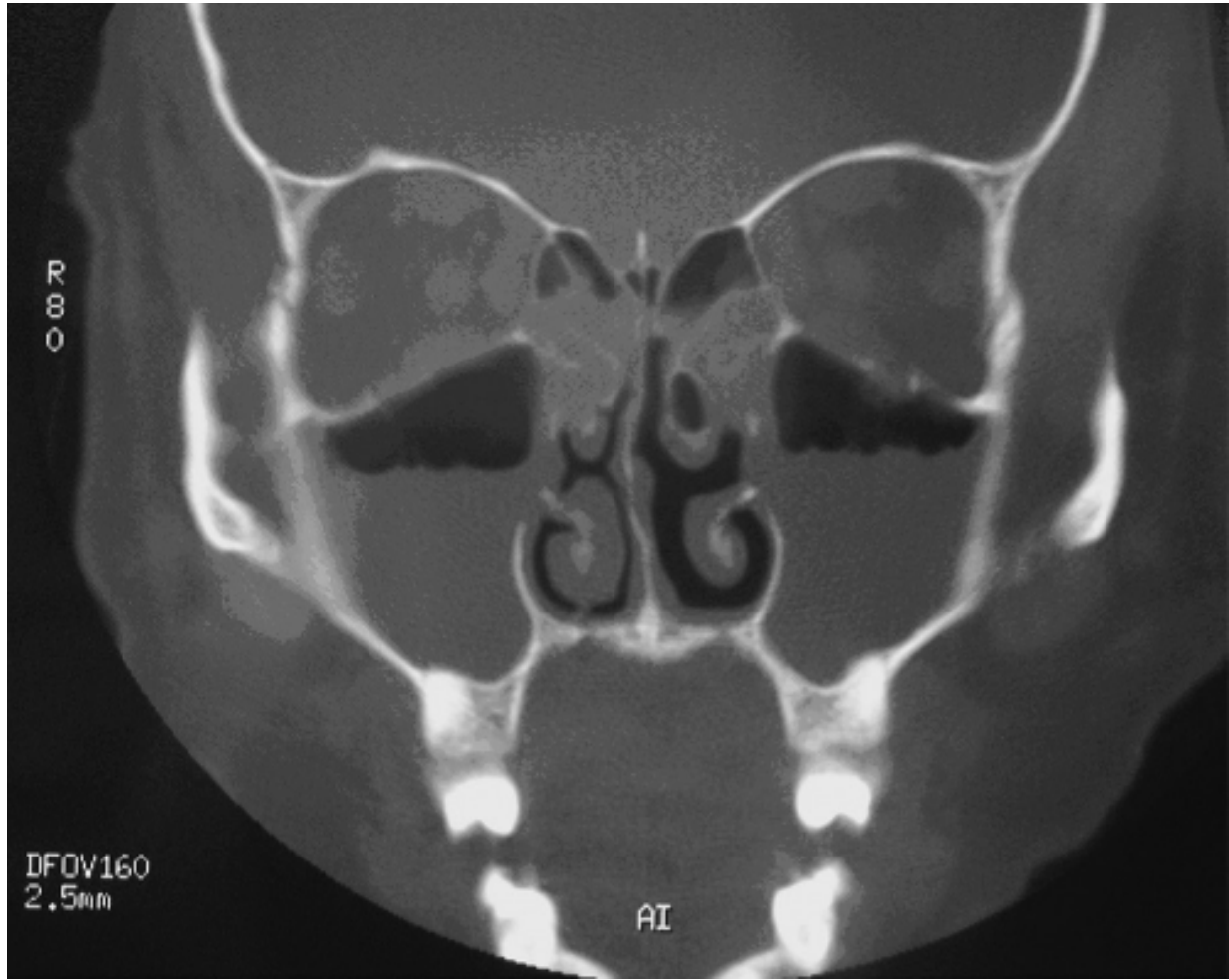


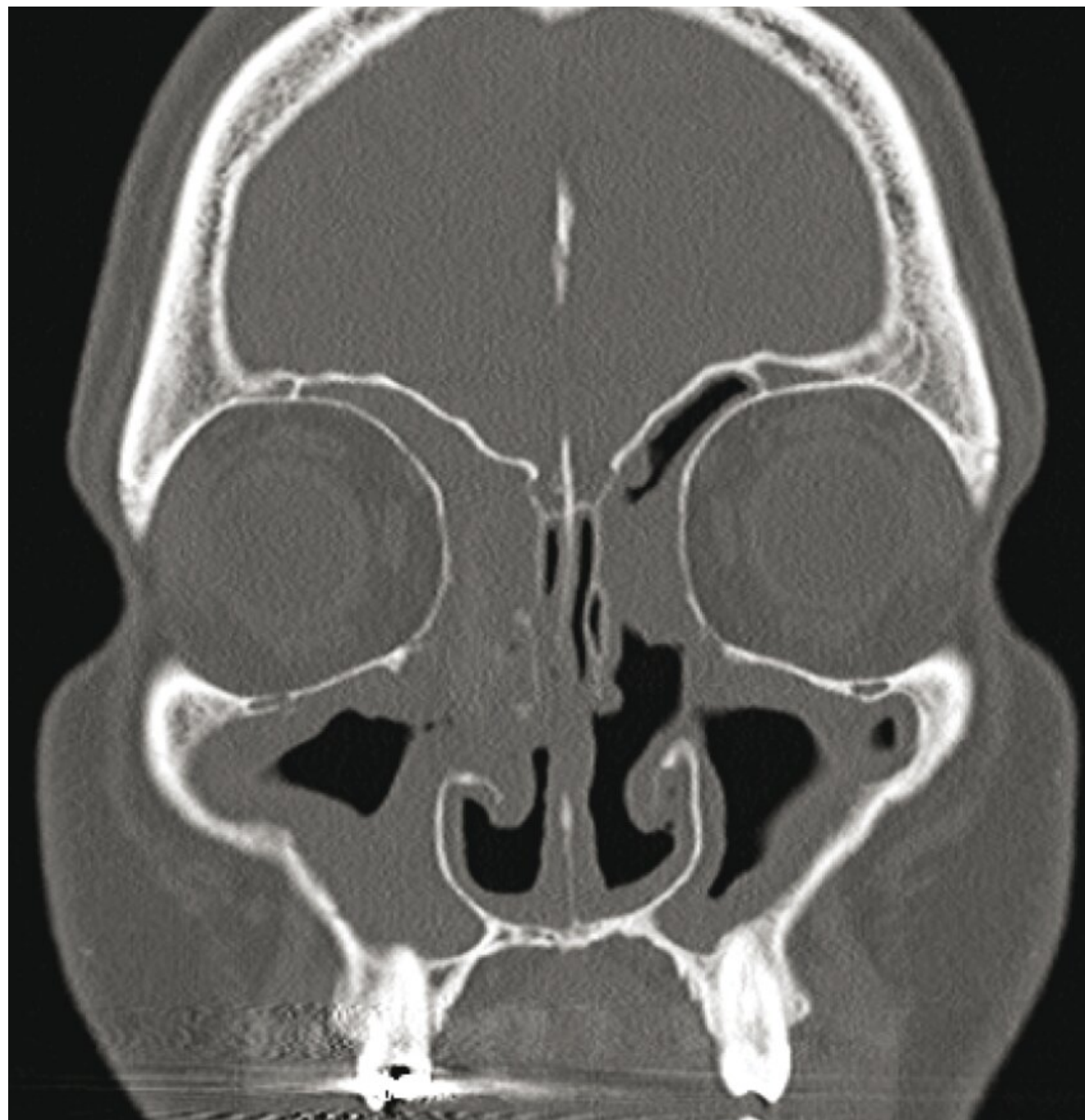



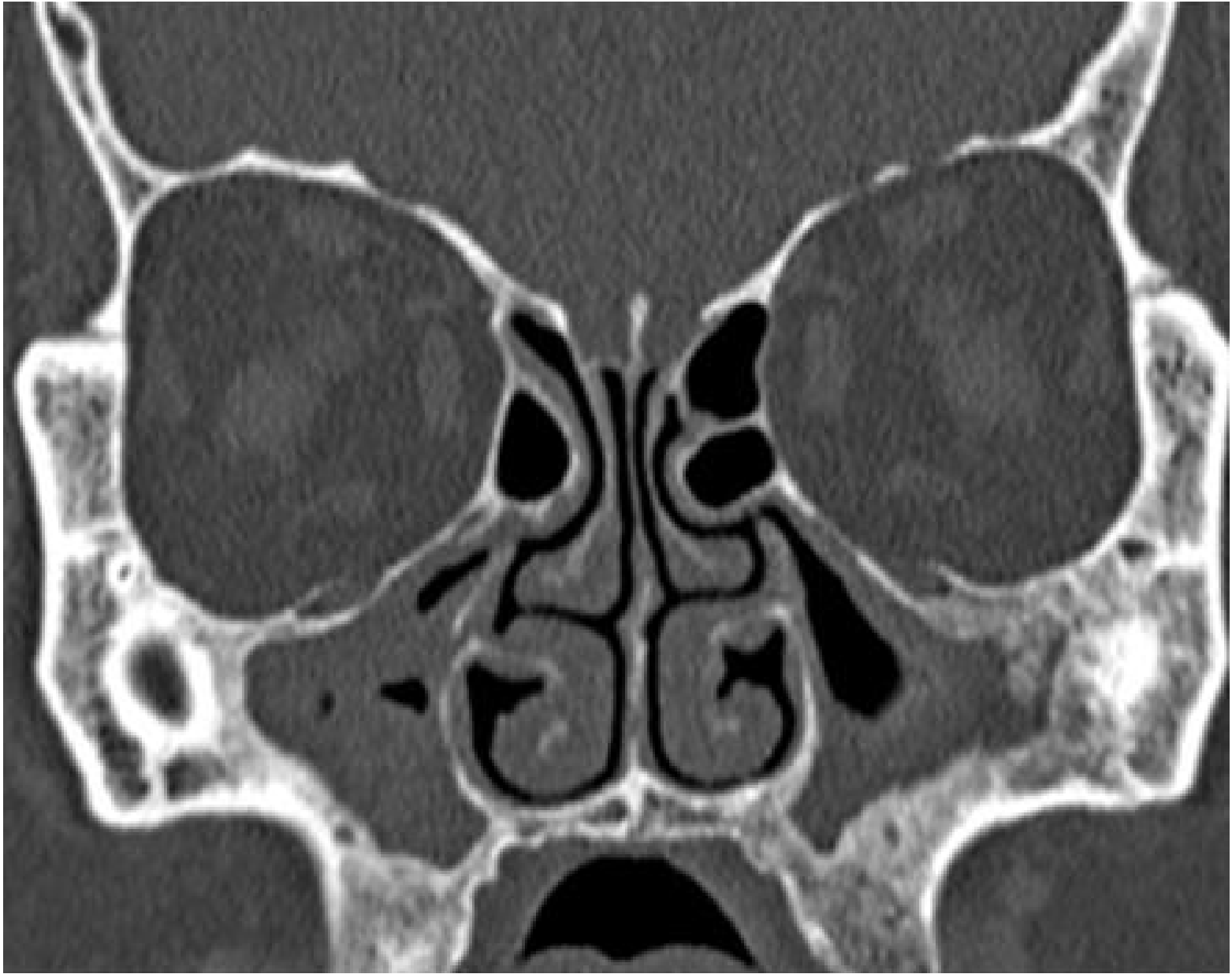


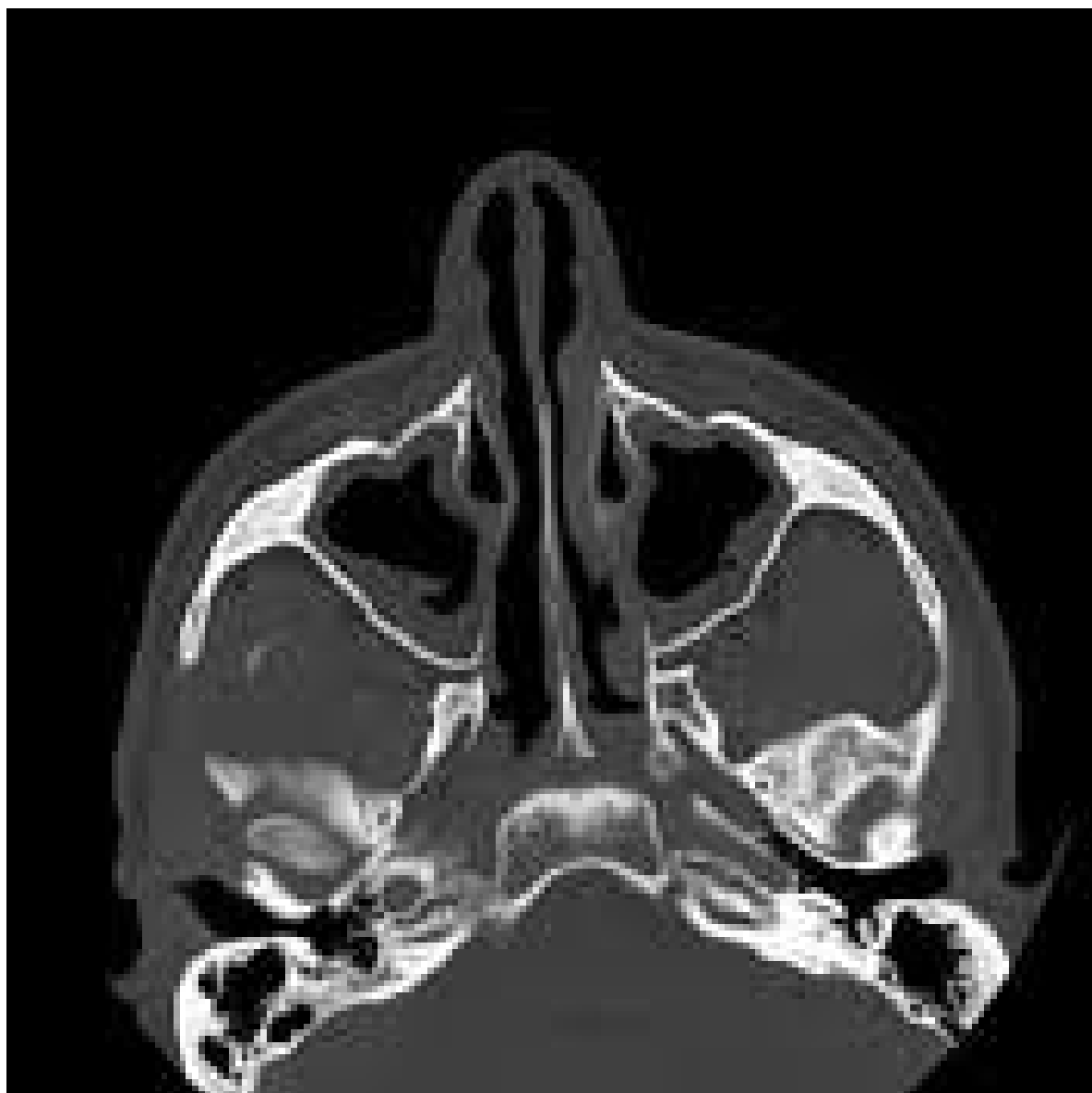

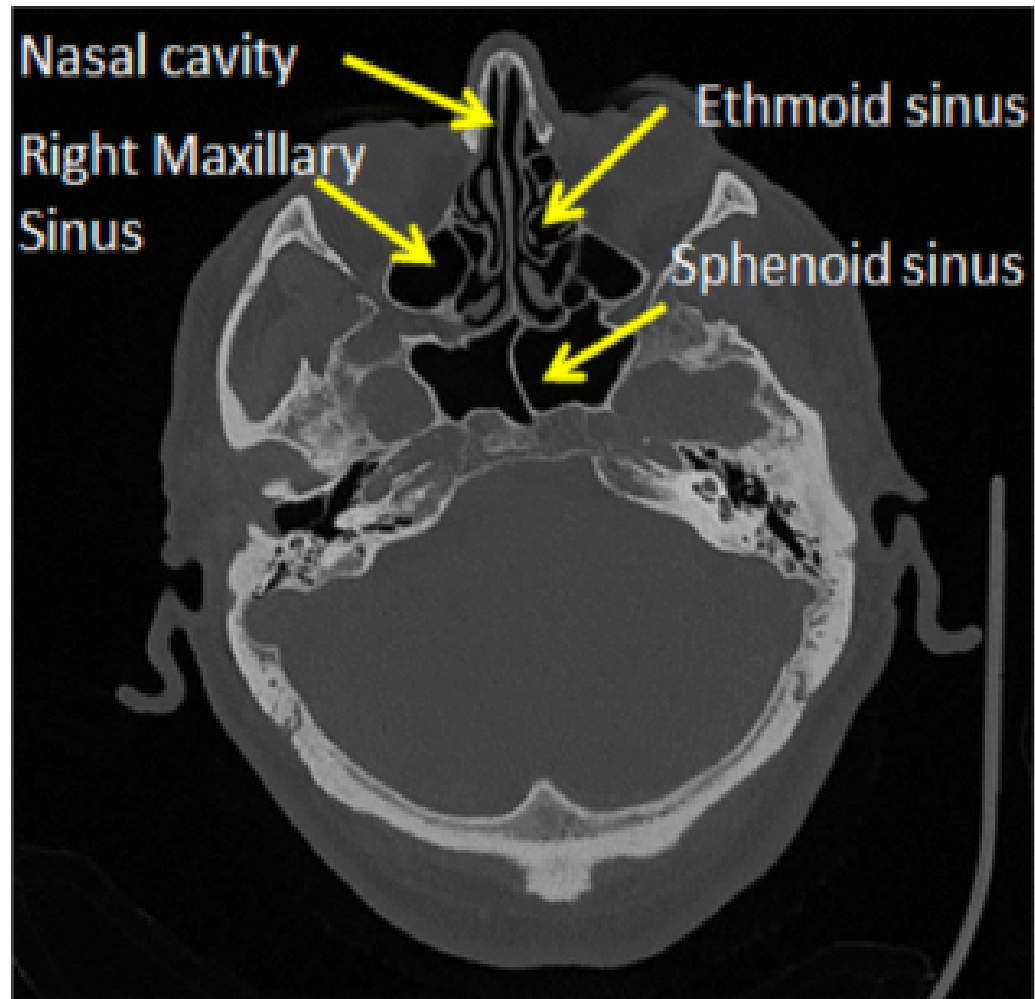




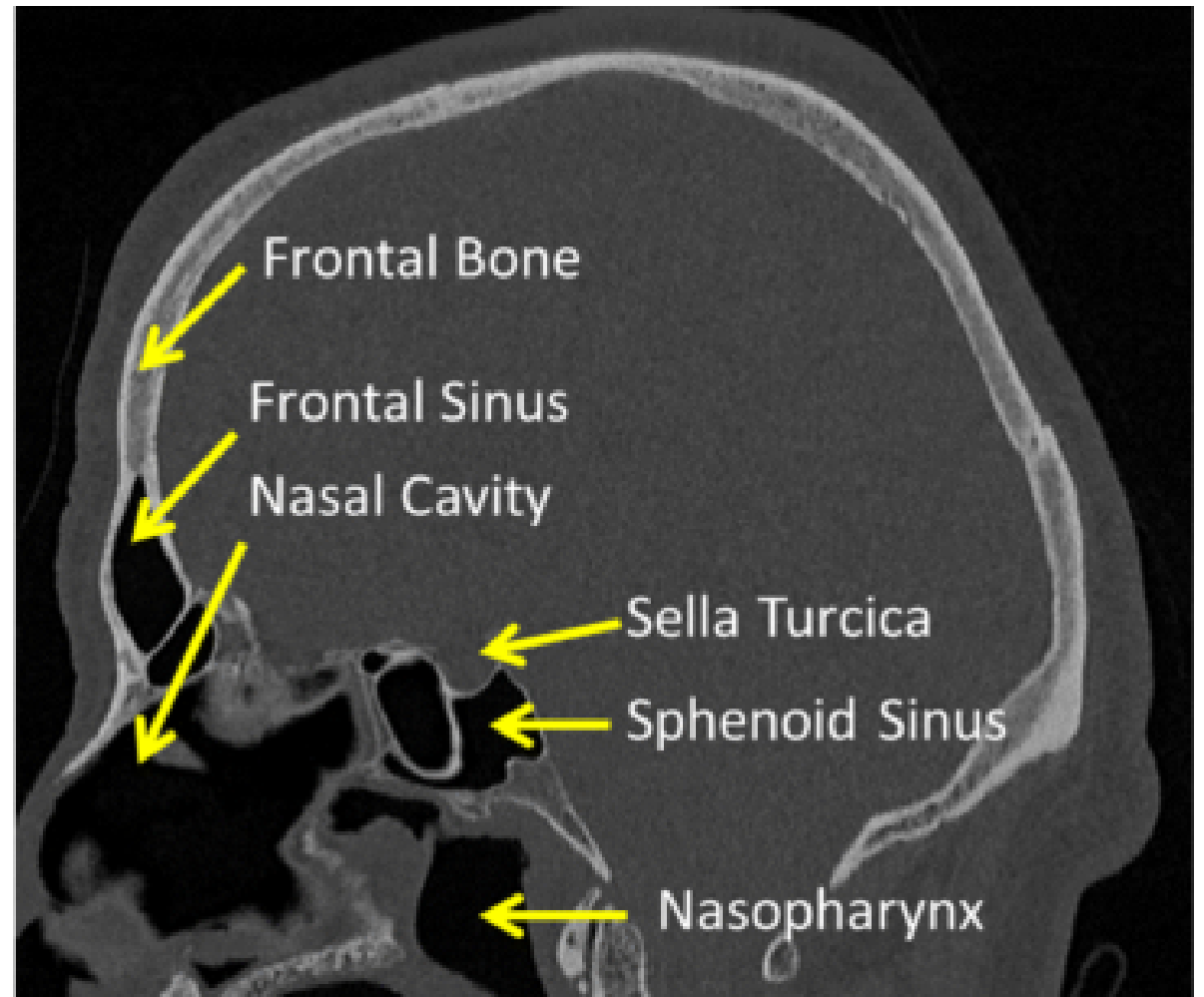




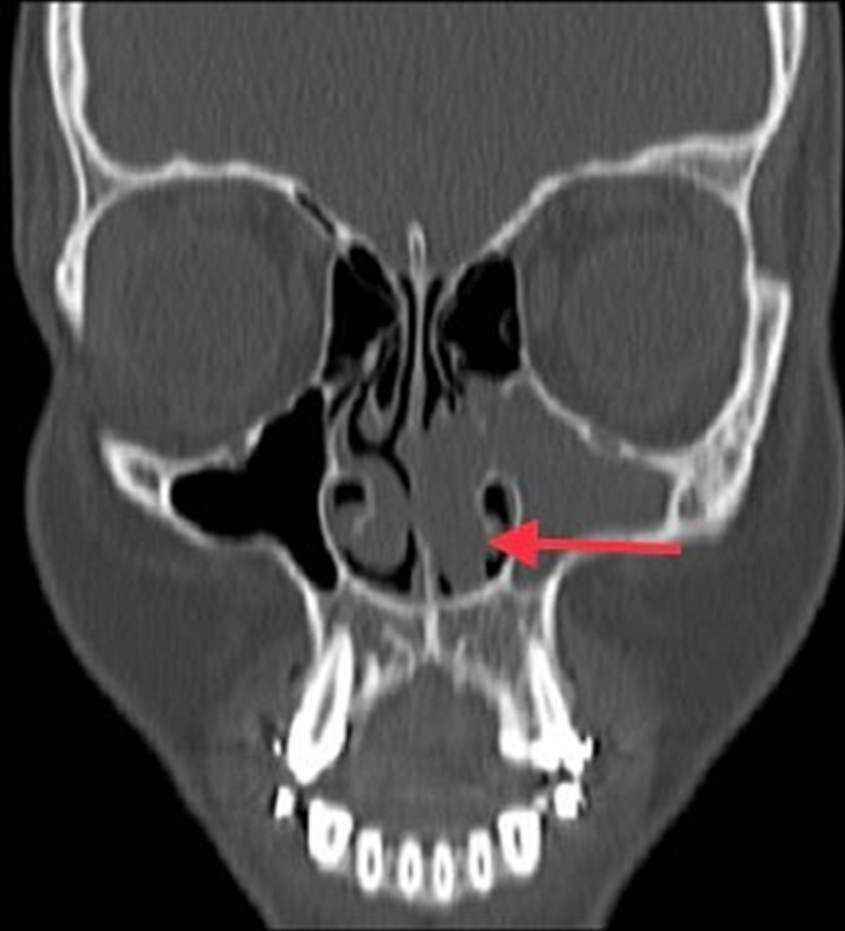




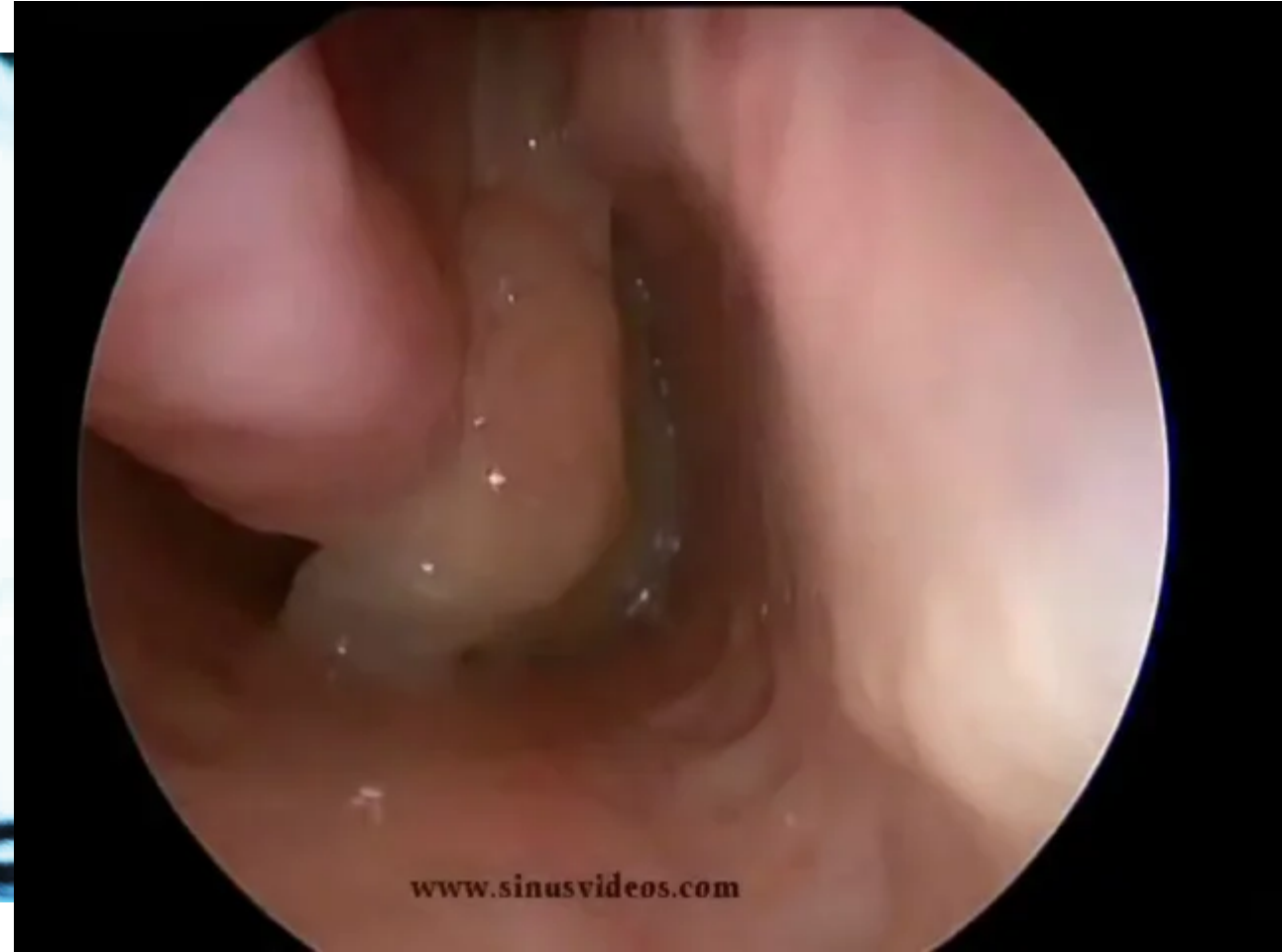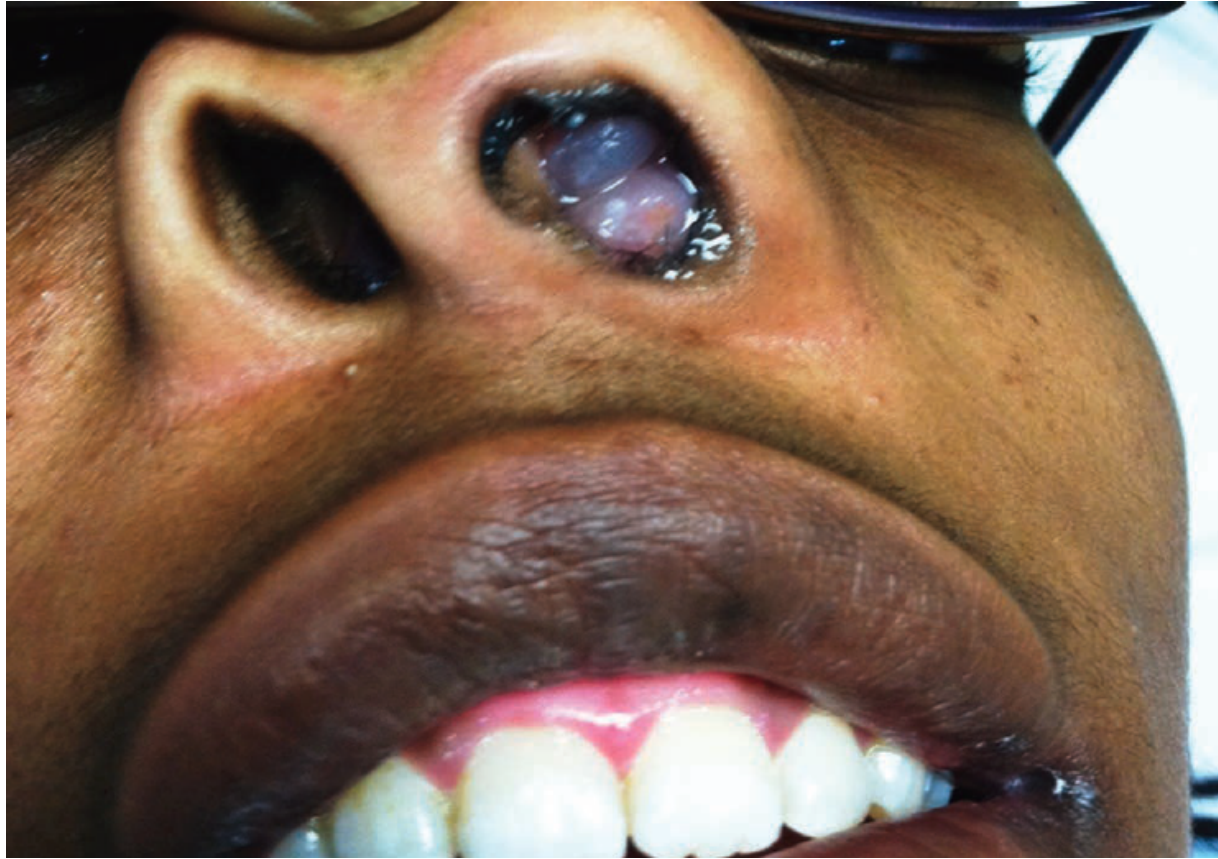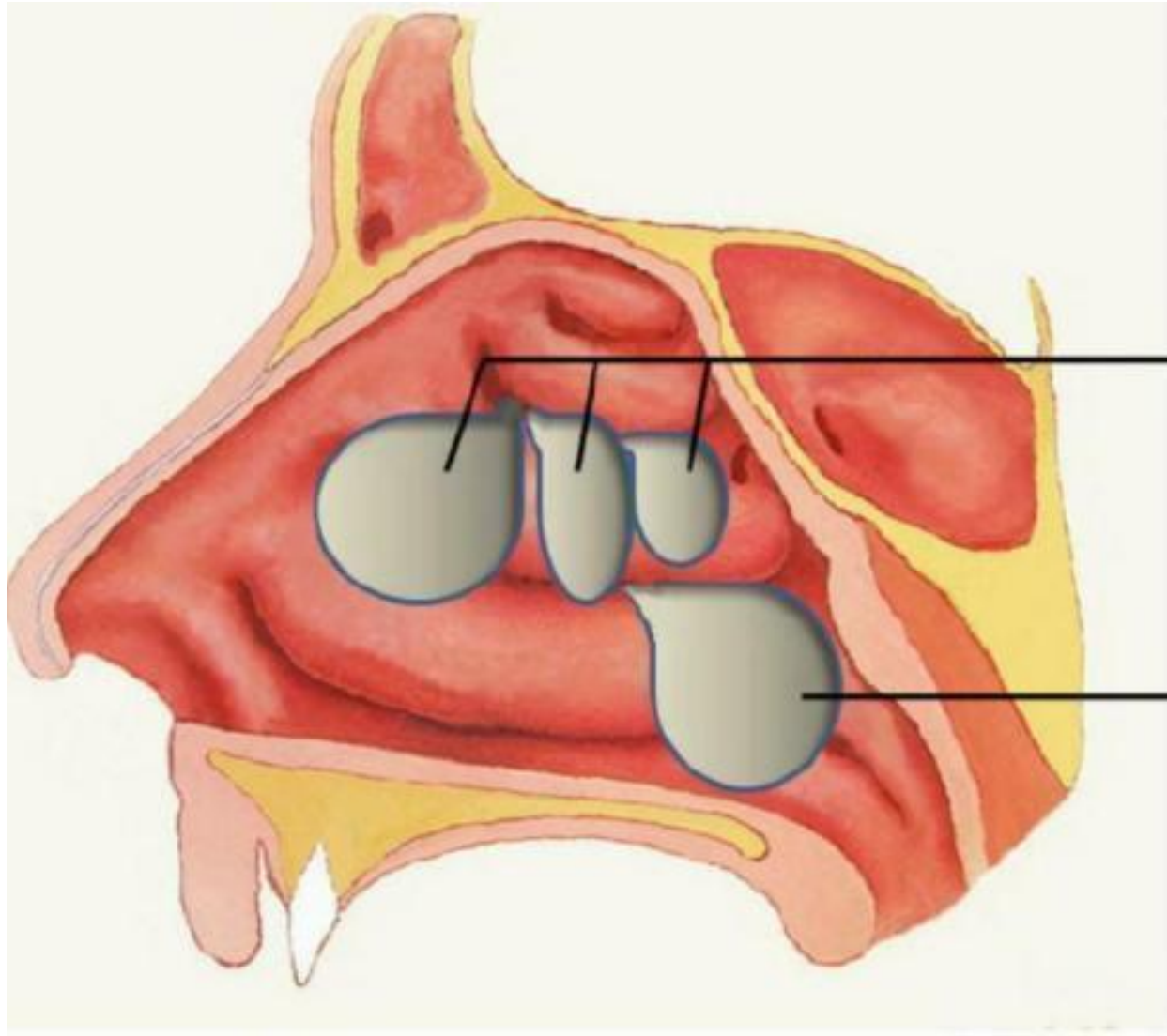
(a) Axial view



(b) Sagittal view



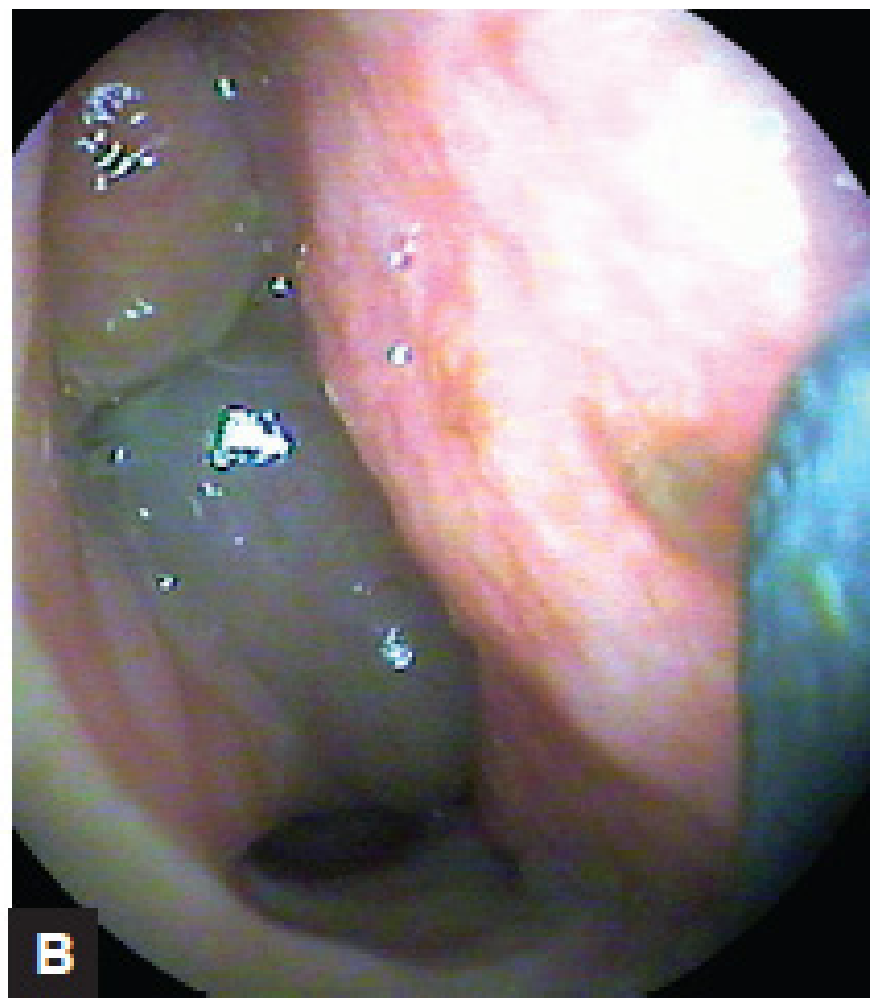
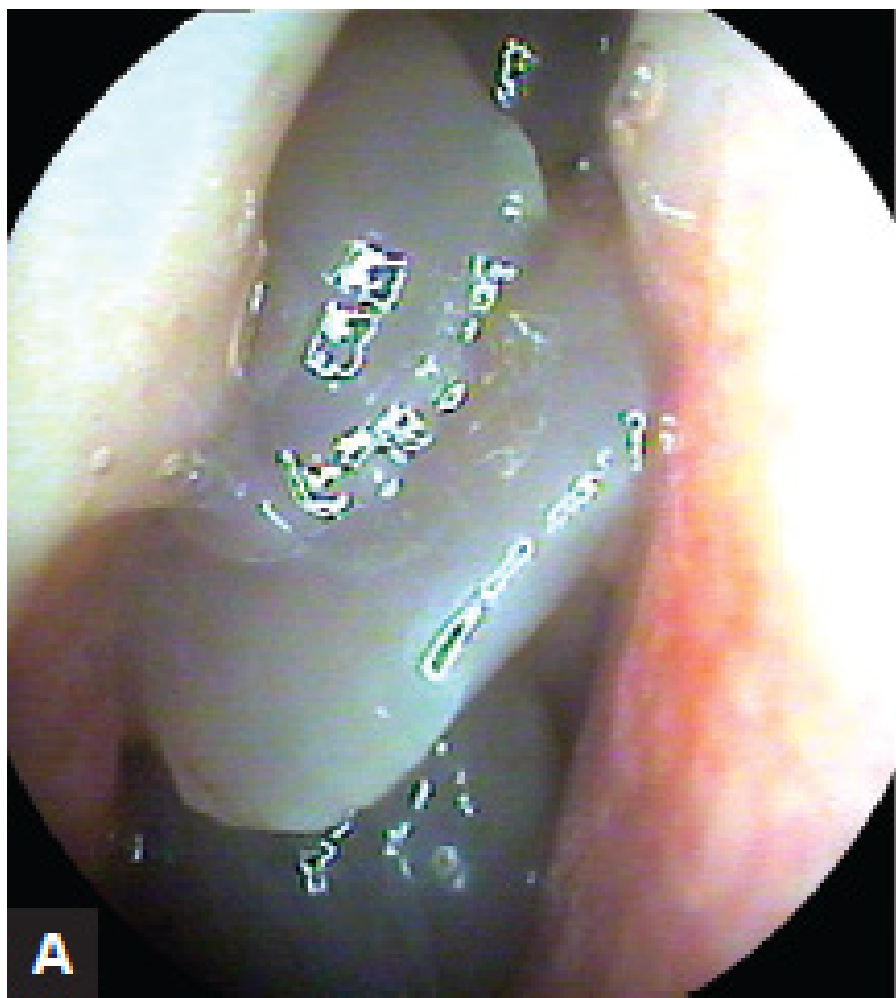

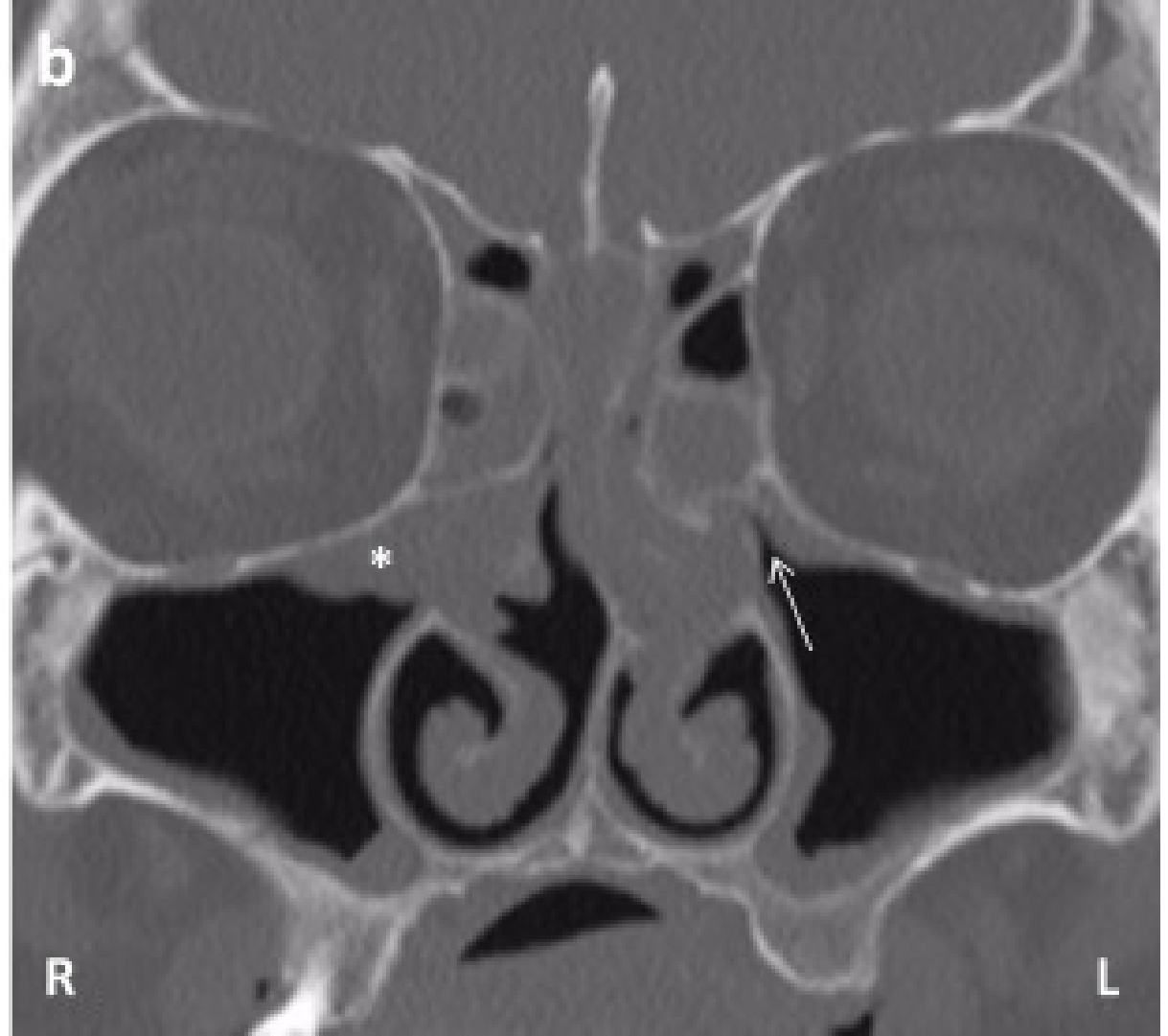

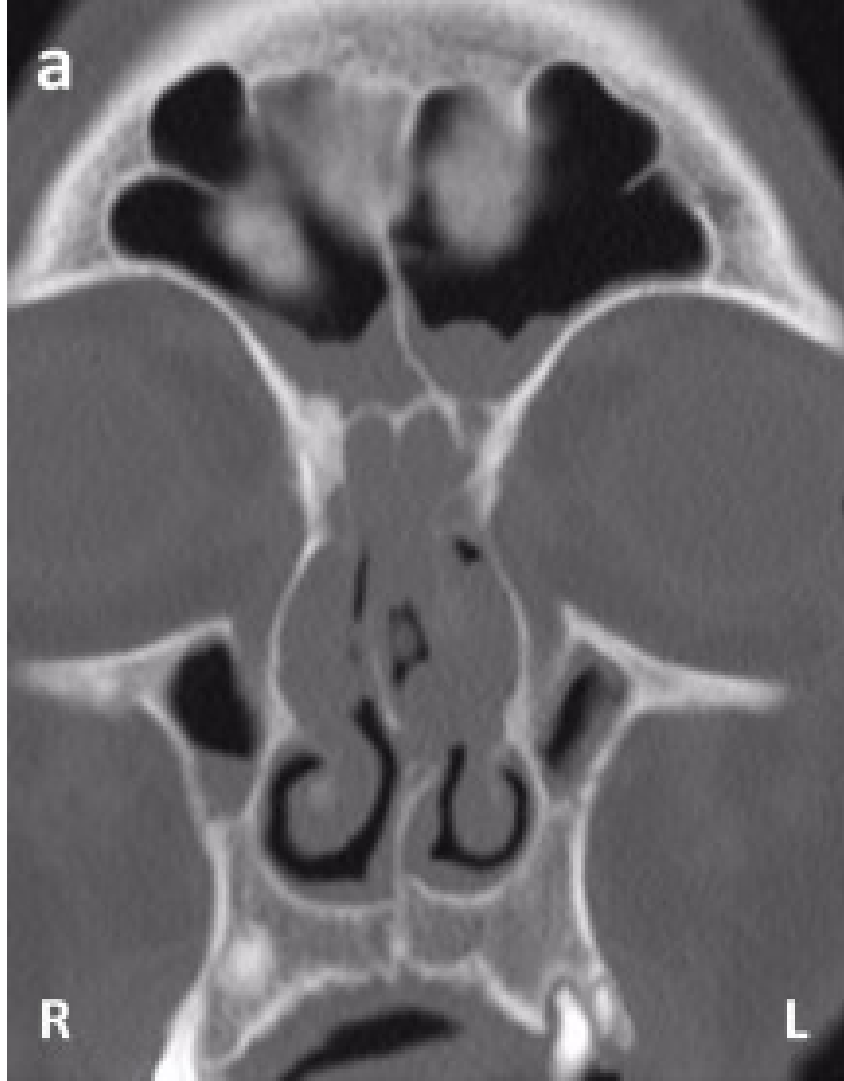
## Lateral Nasal View of Sinus Polyps

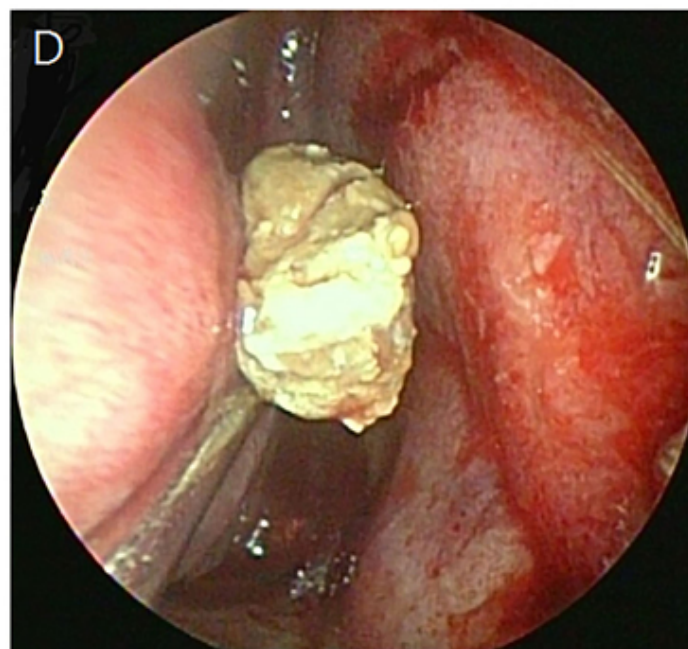
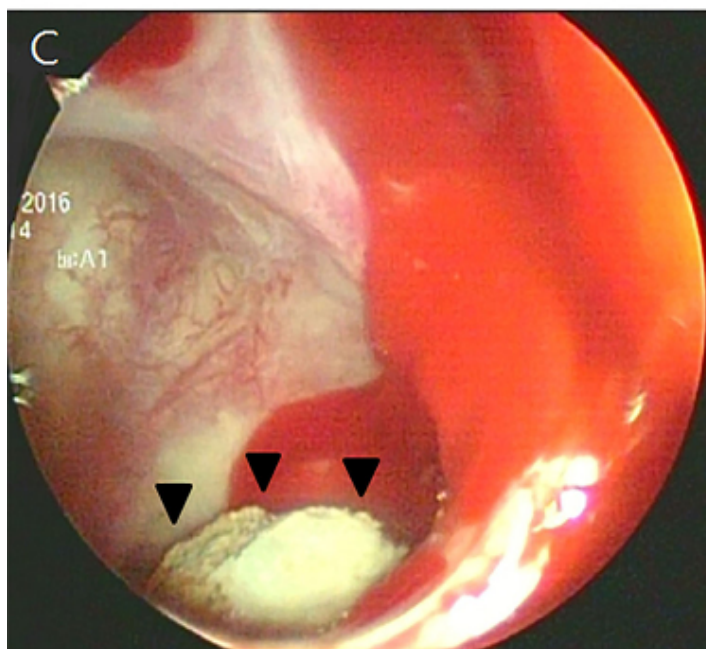
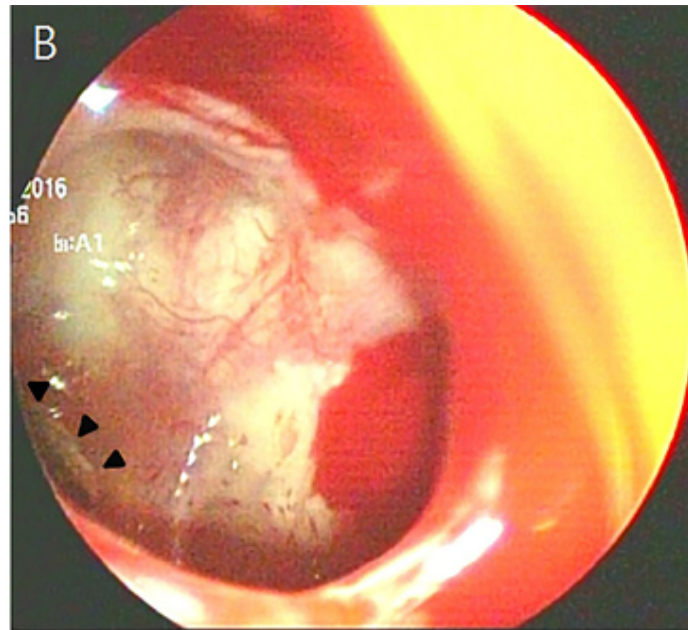
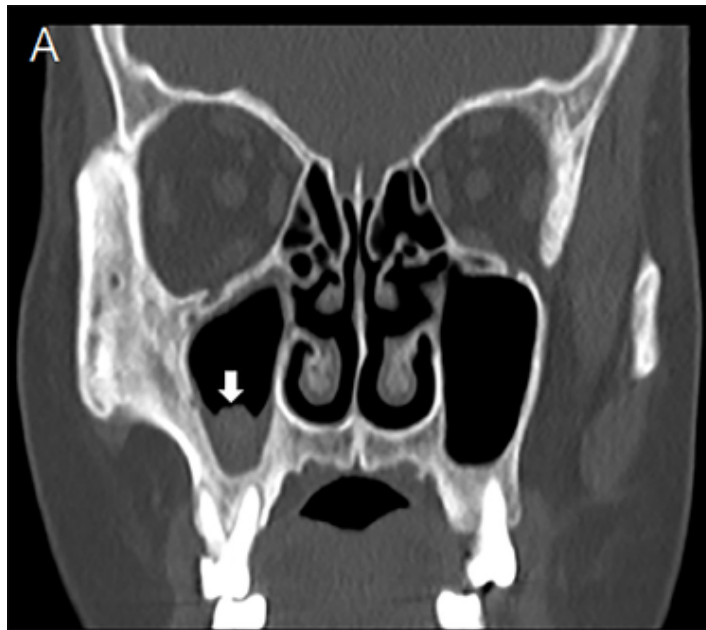
Ethmoid sinus polyps

Maxillary sinus polyp



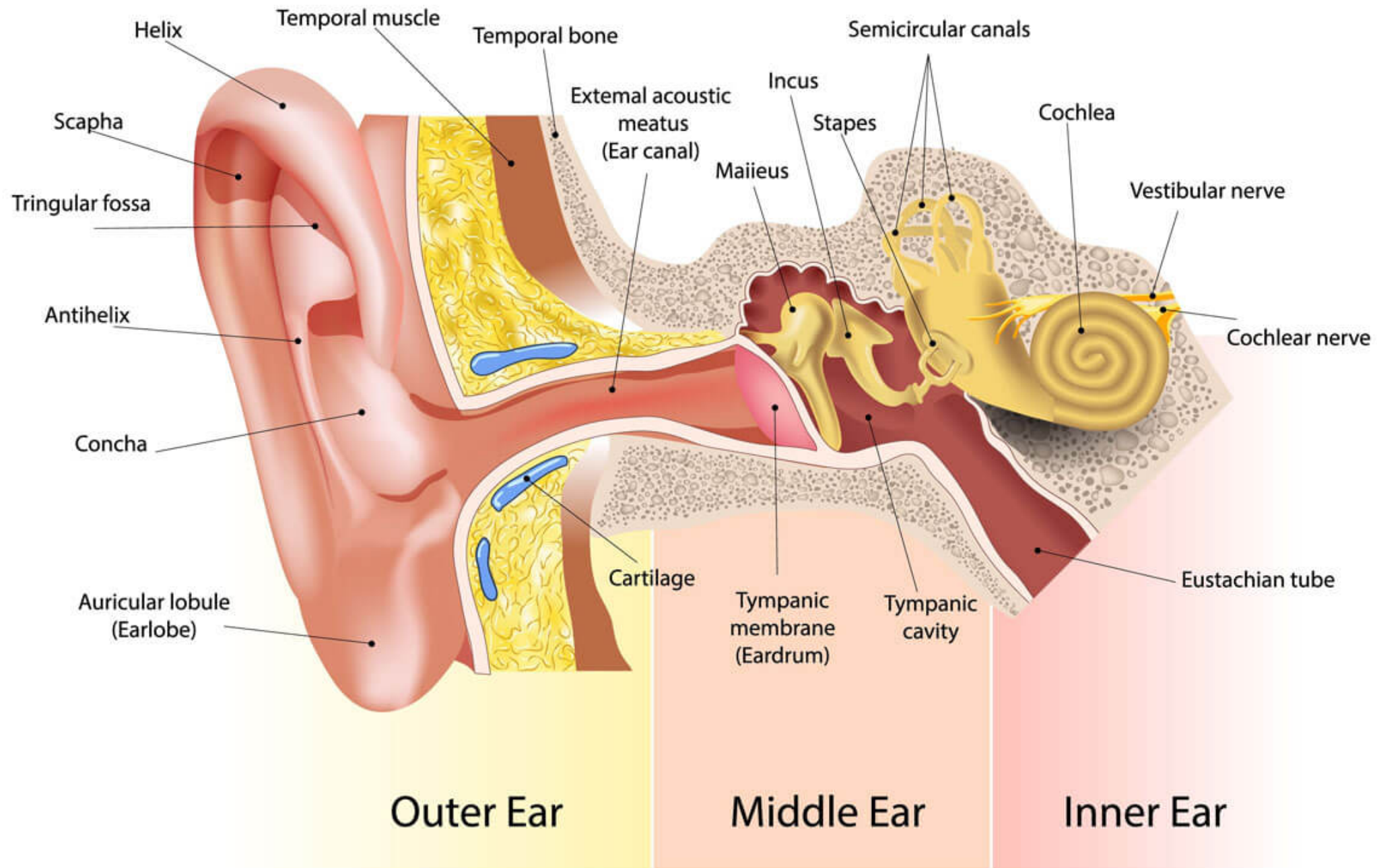


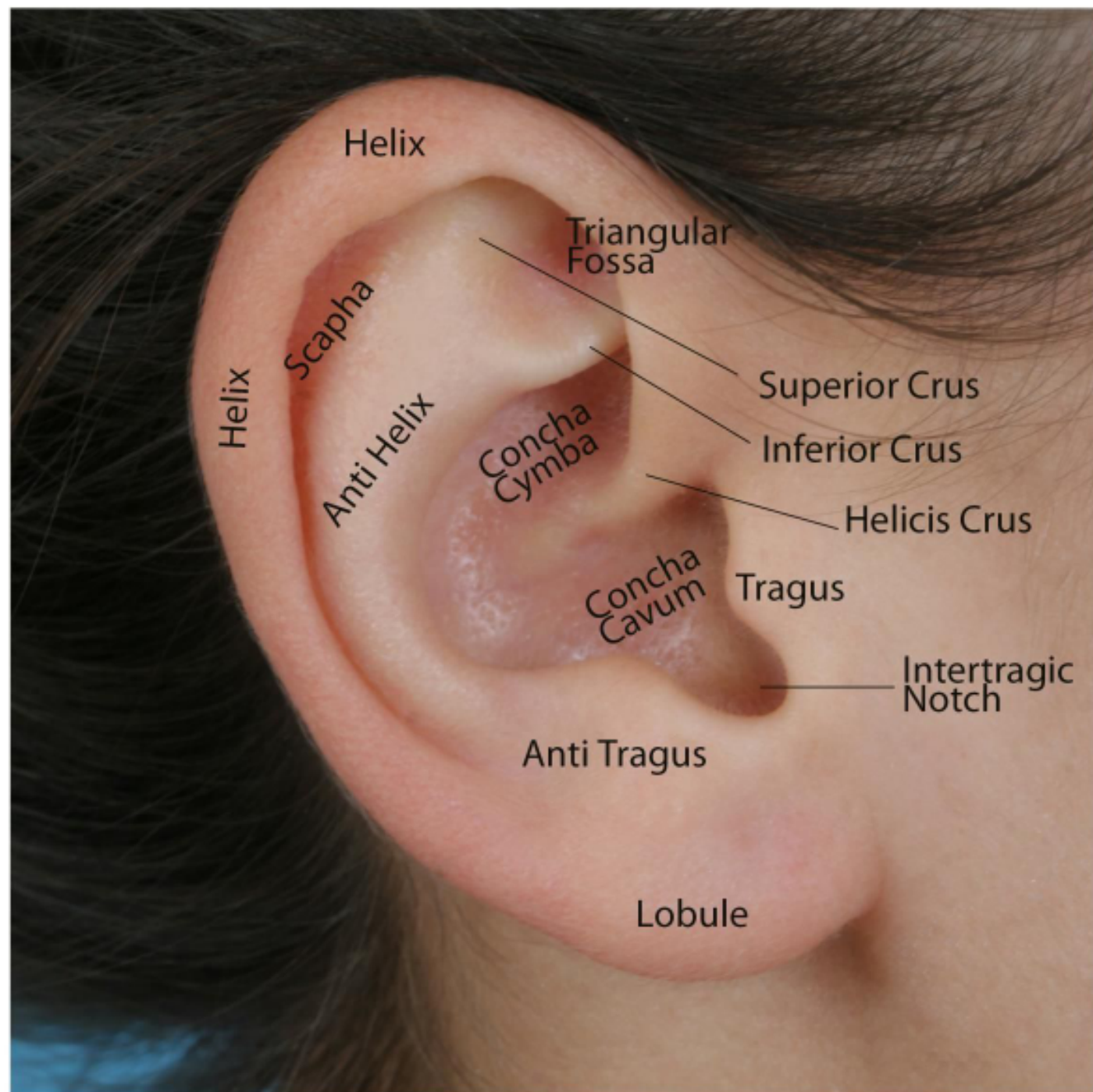

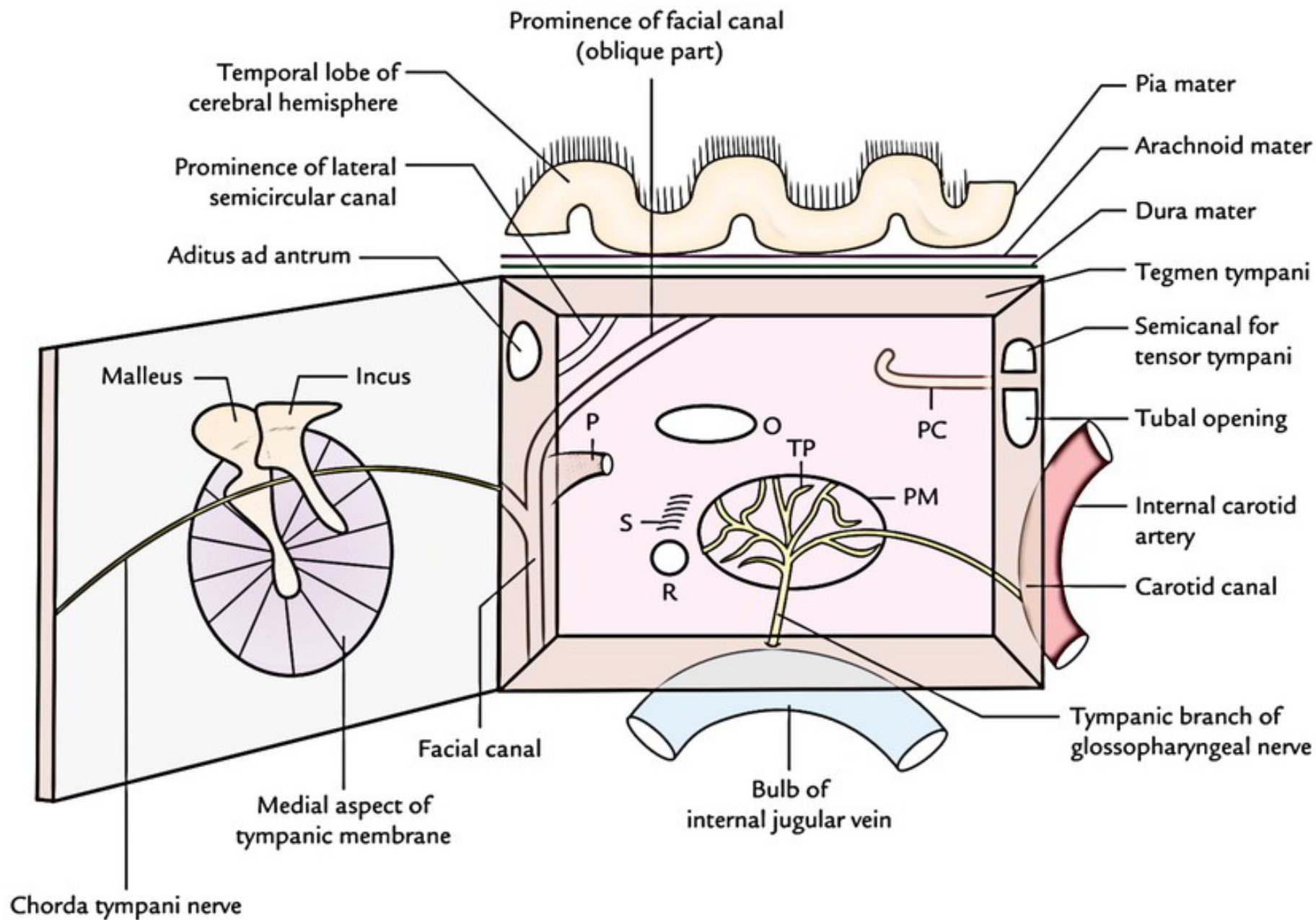




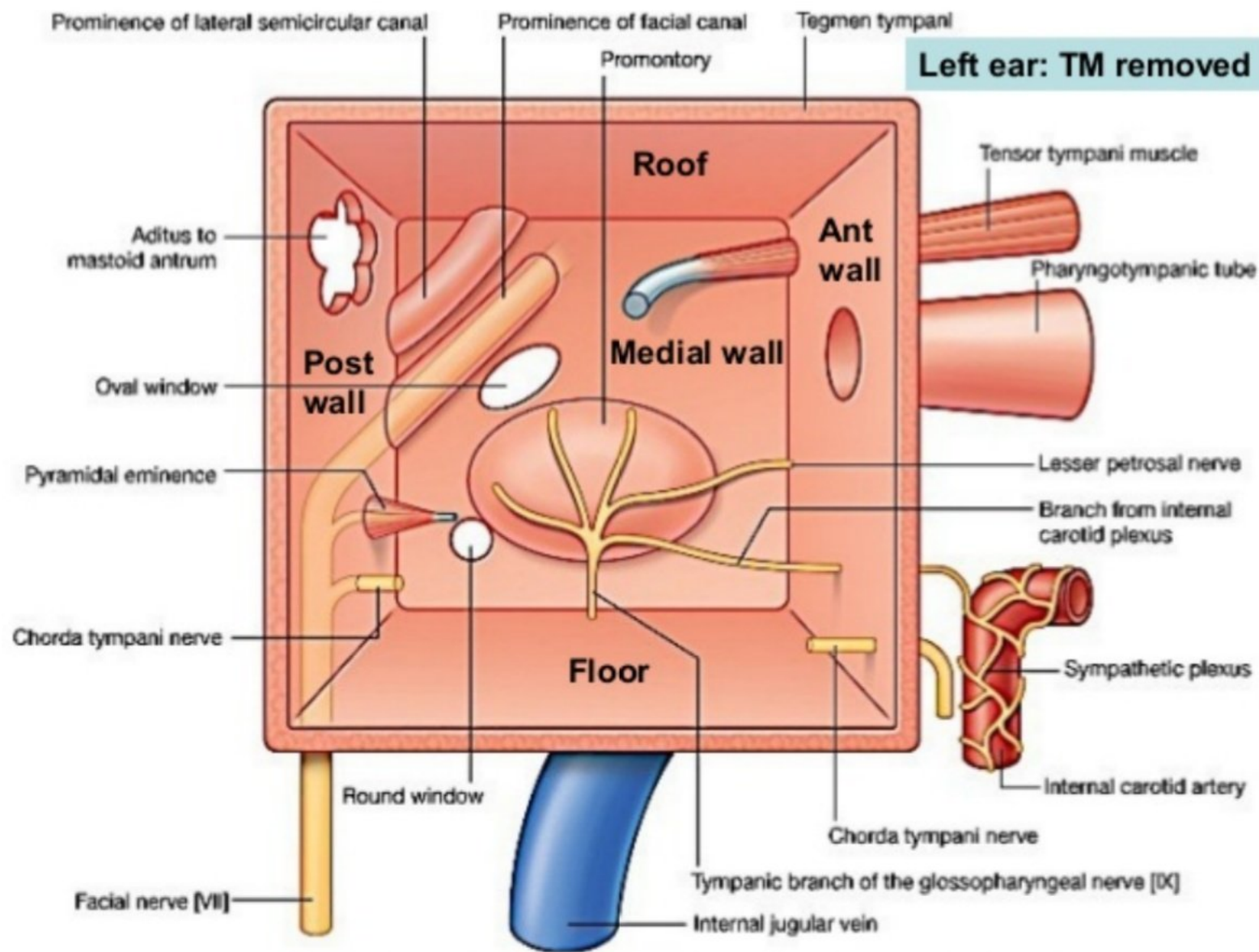
***Otology***



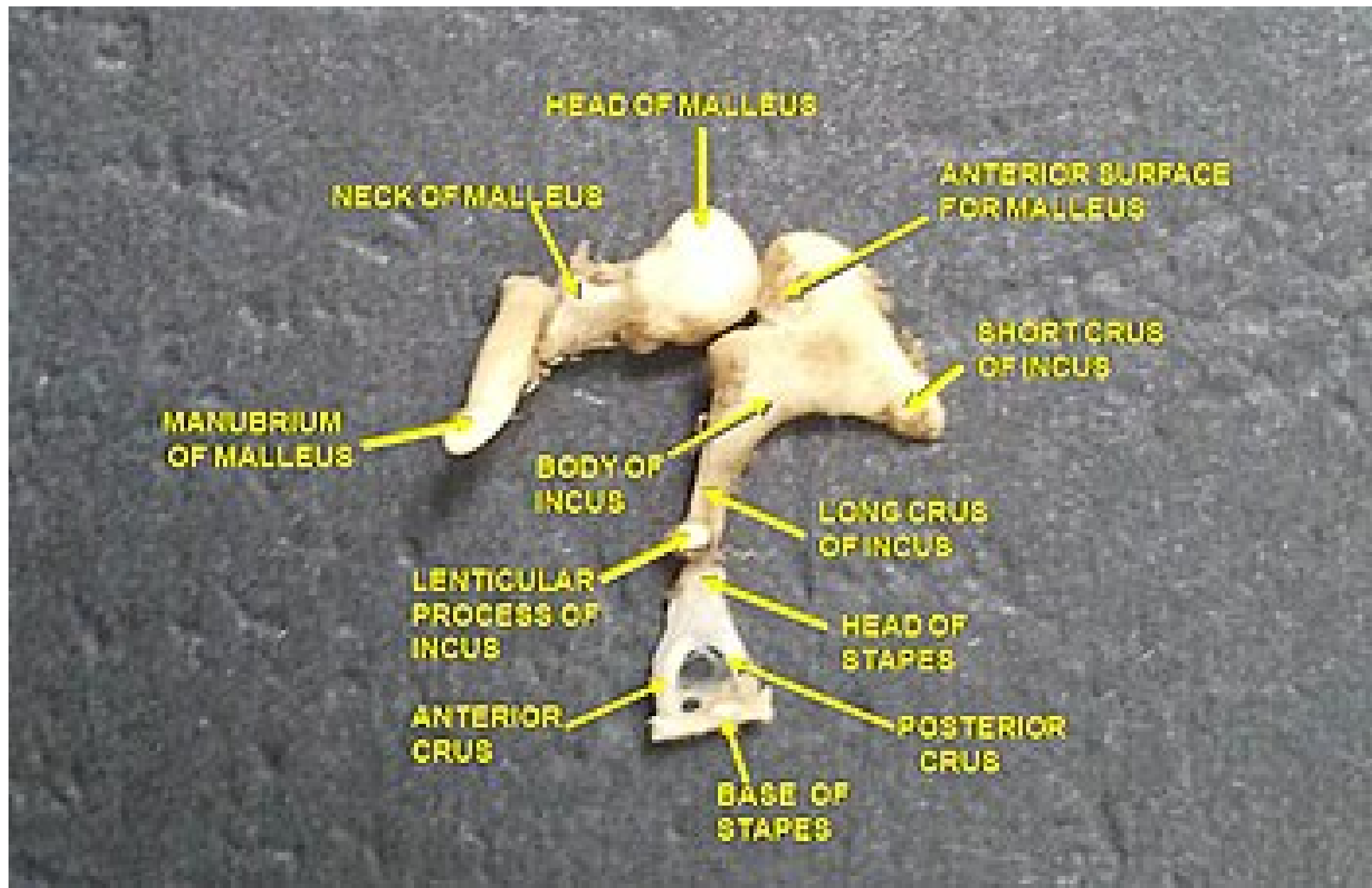




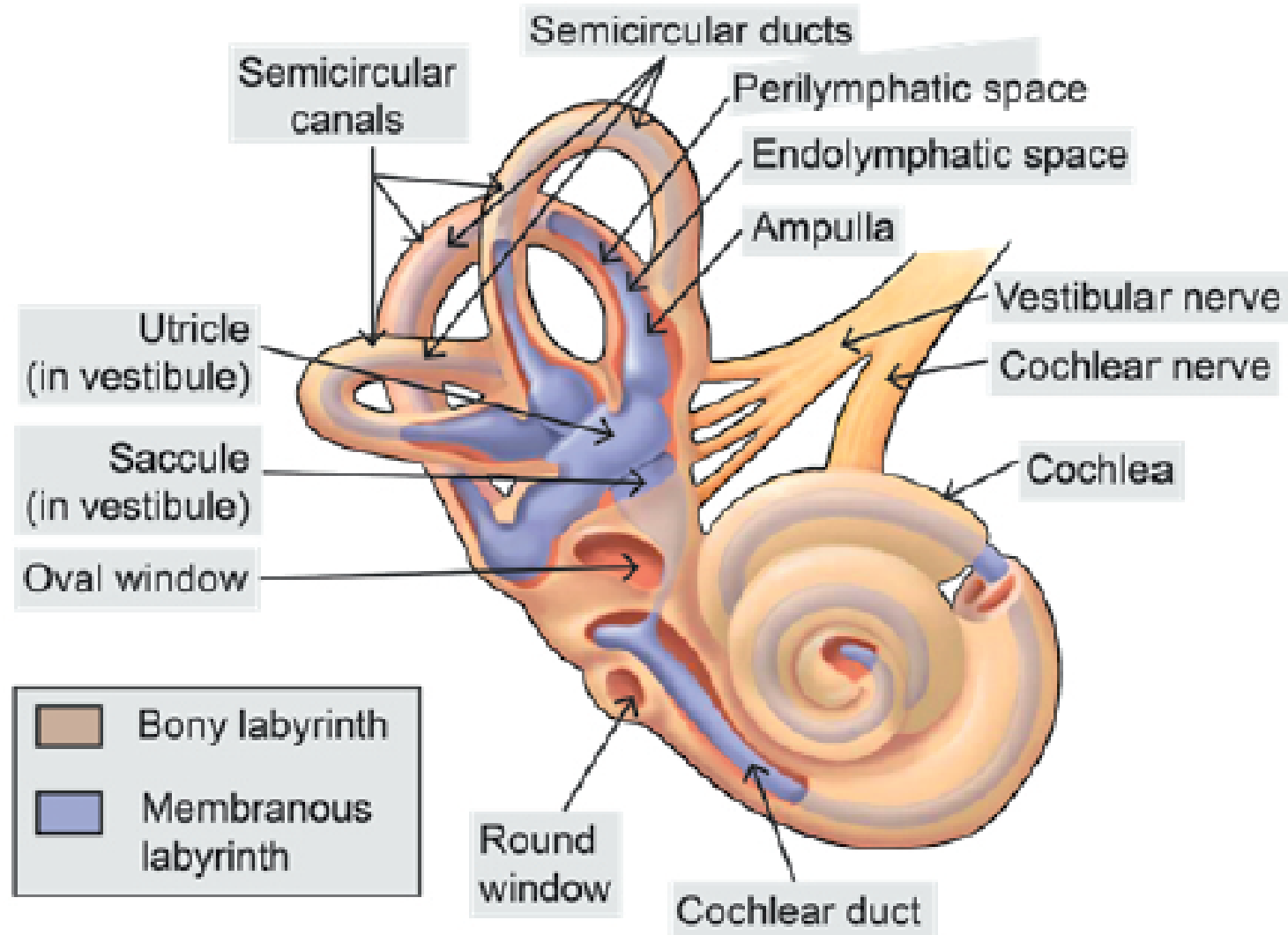


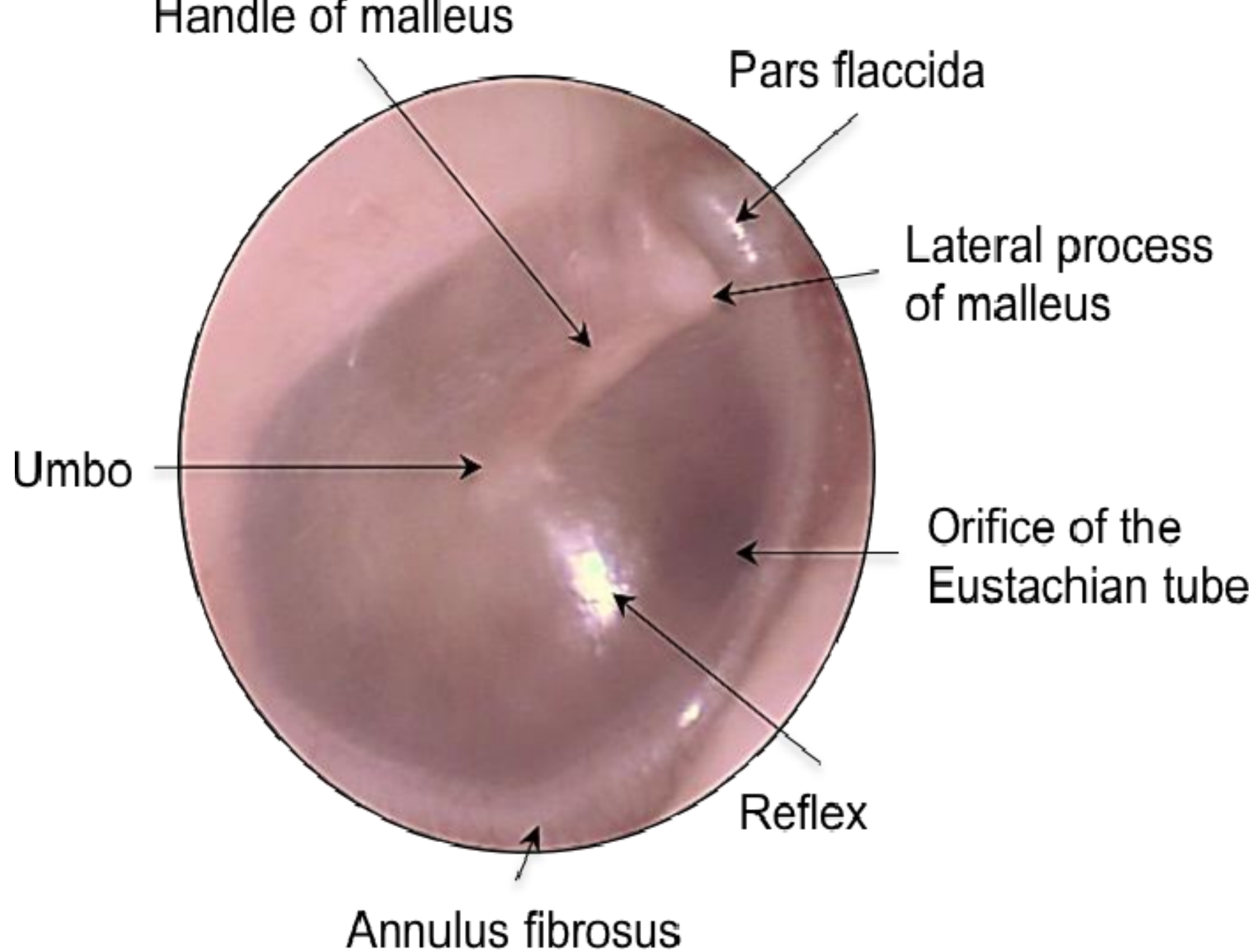


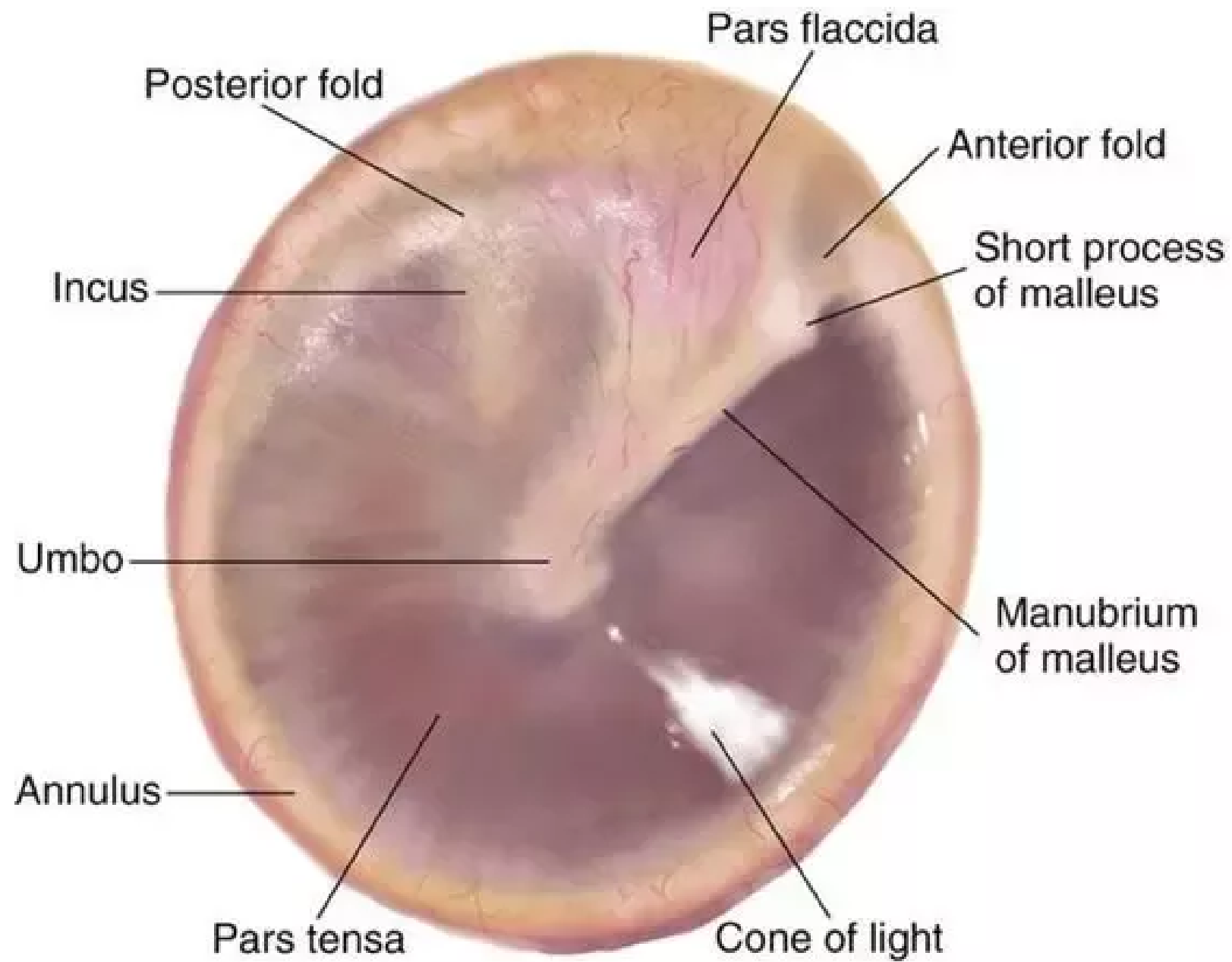












TYMPANIC MEMBRANE

Malleus



WiscMed

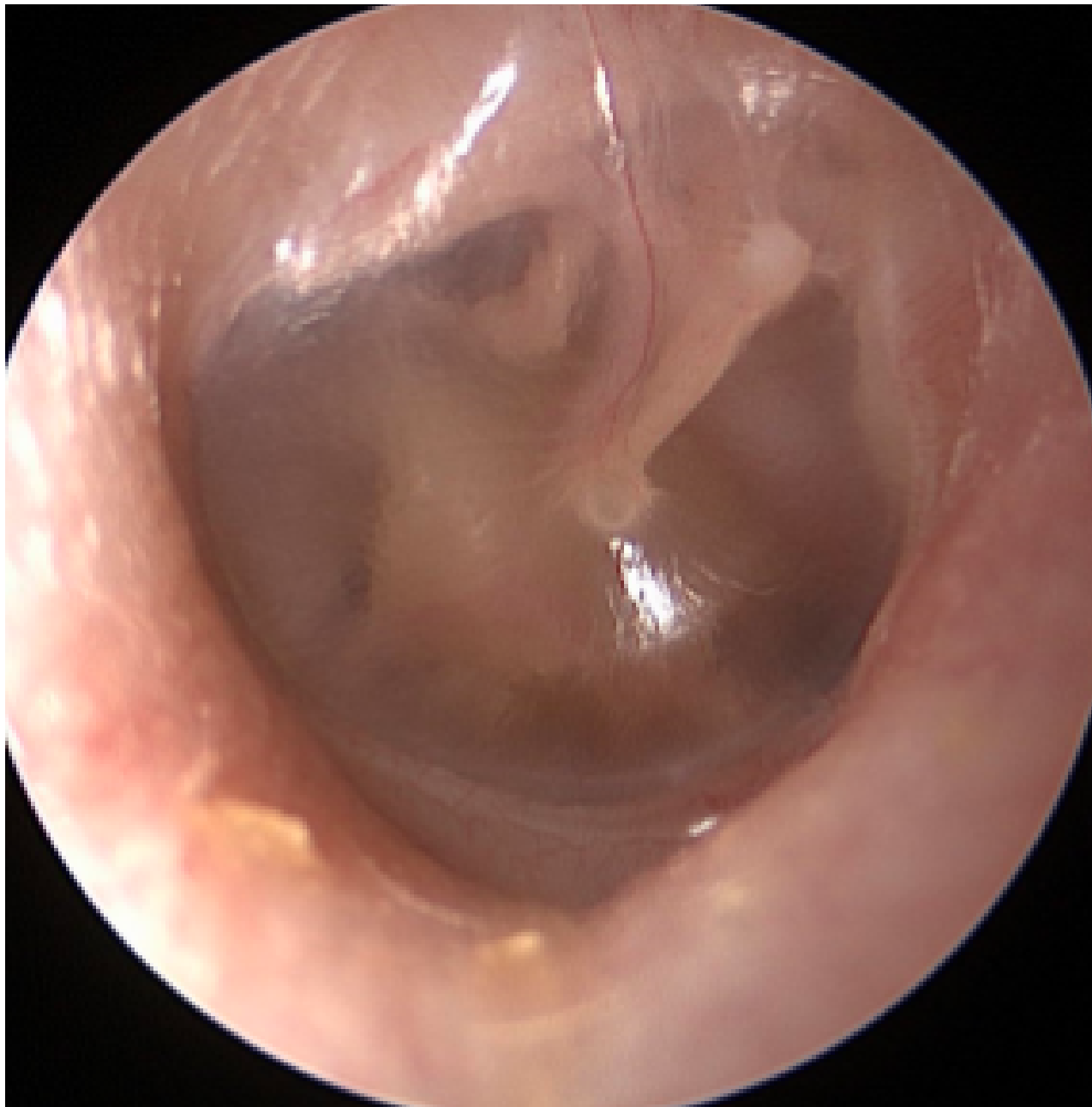Malleus points  
"towards" face

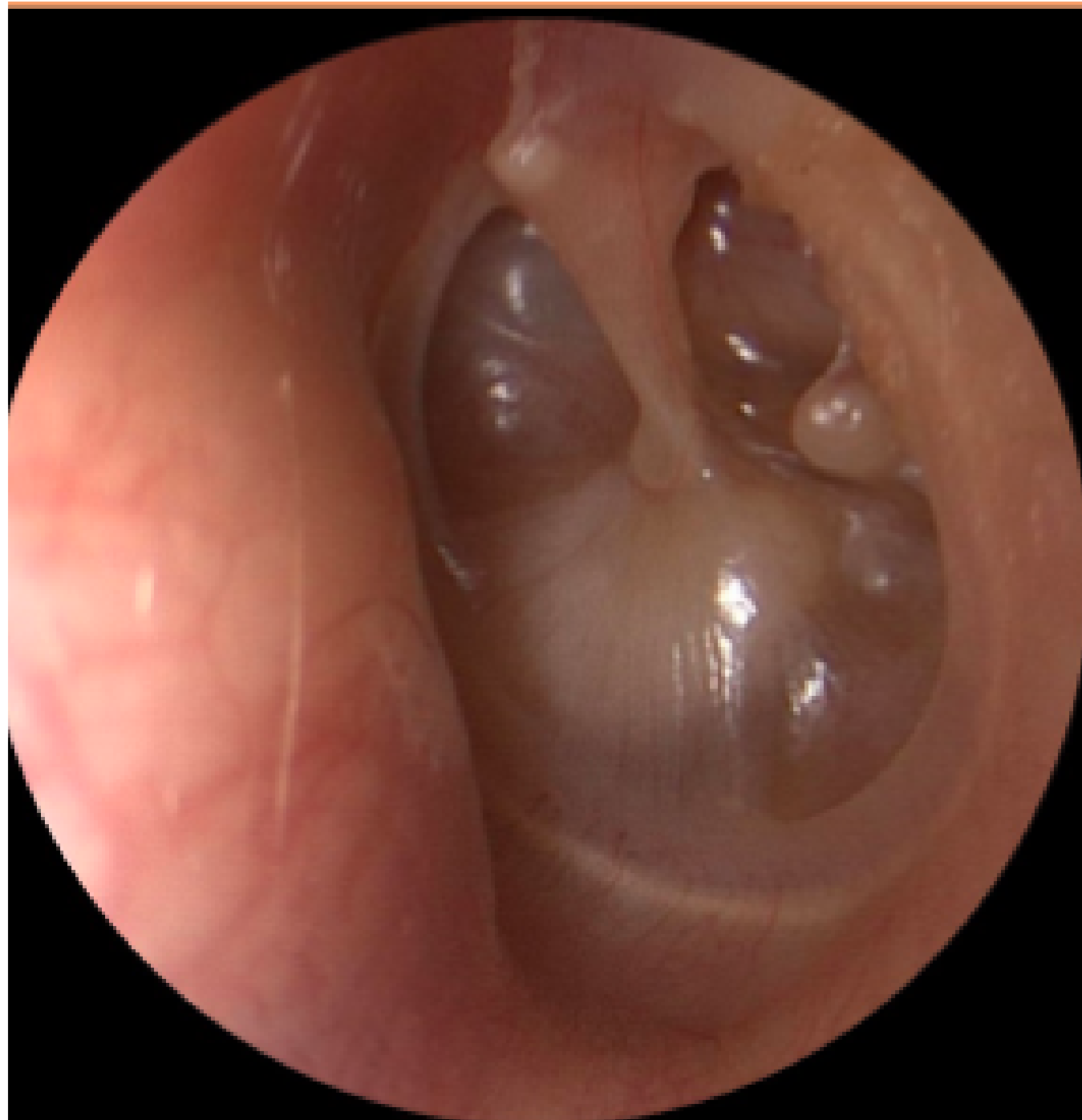

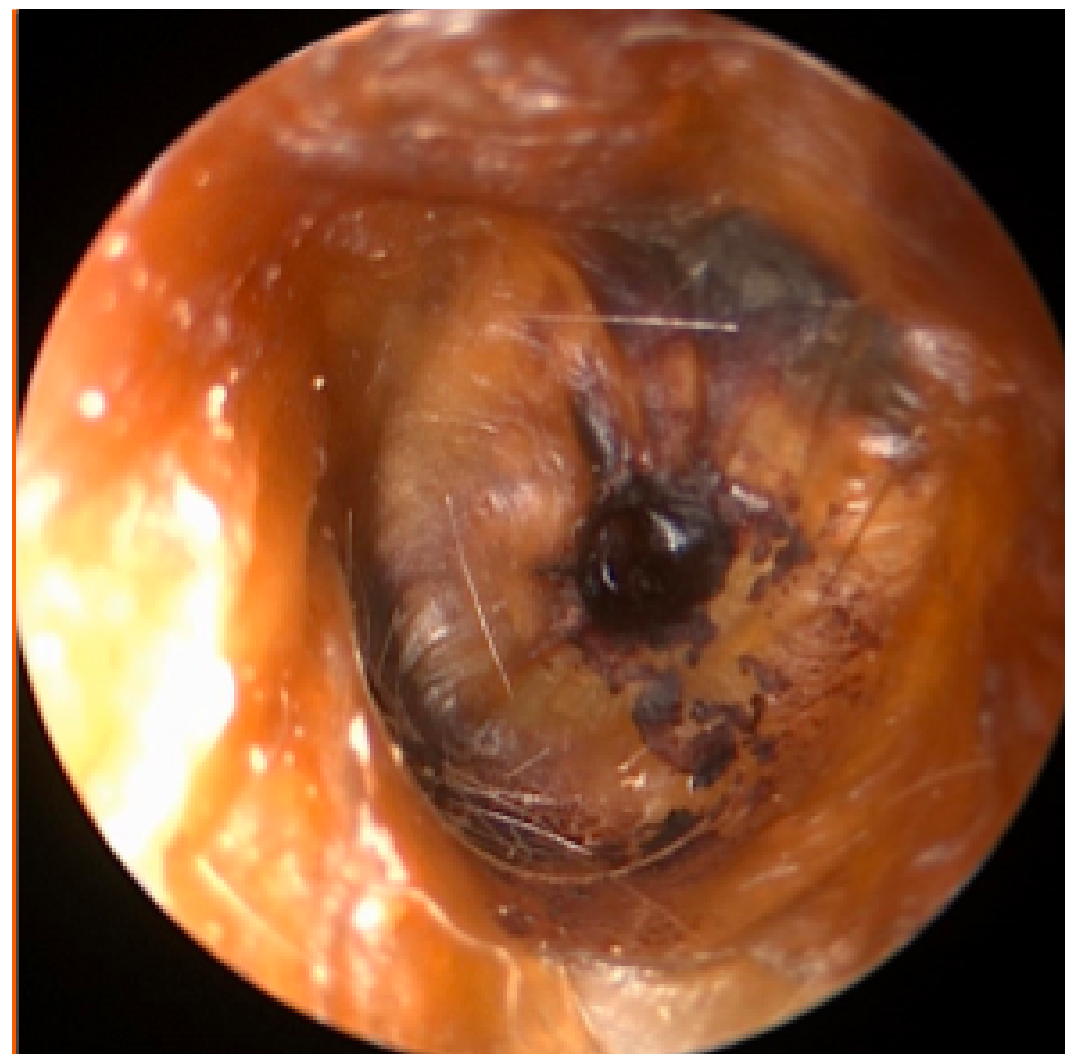
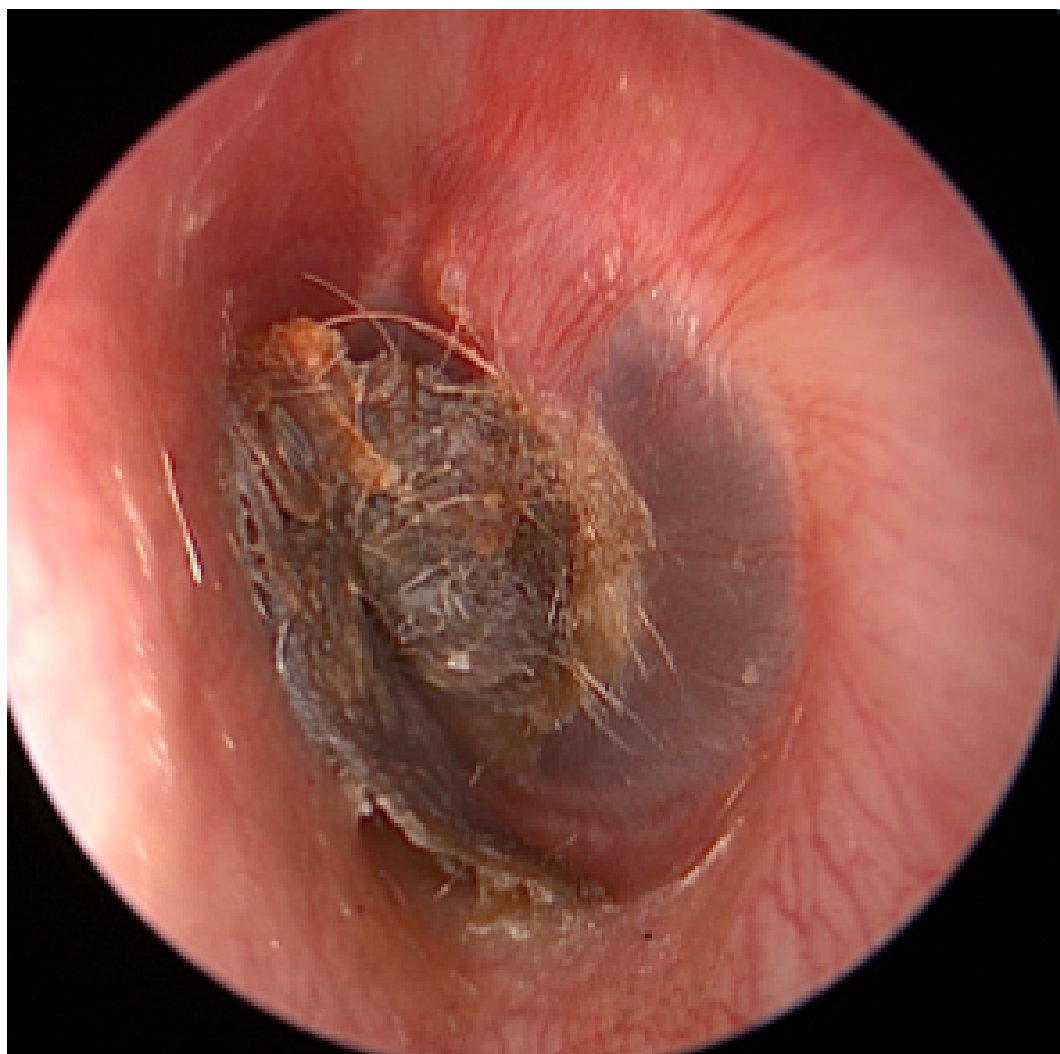This is the  
Left ear

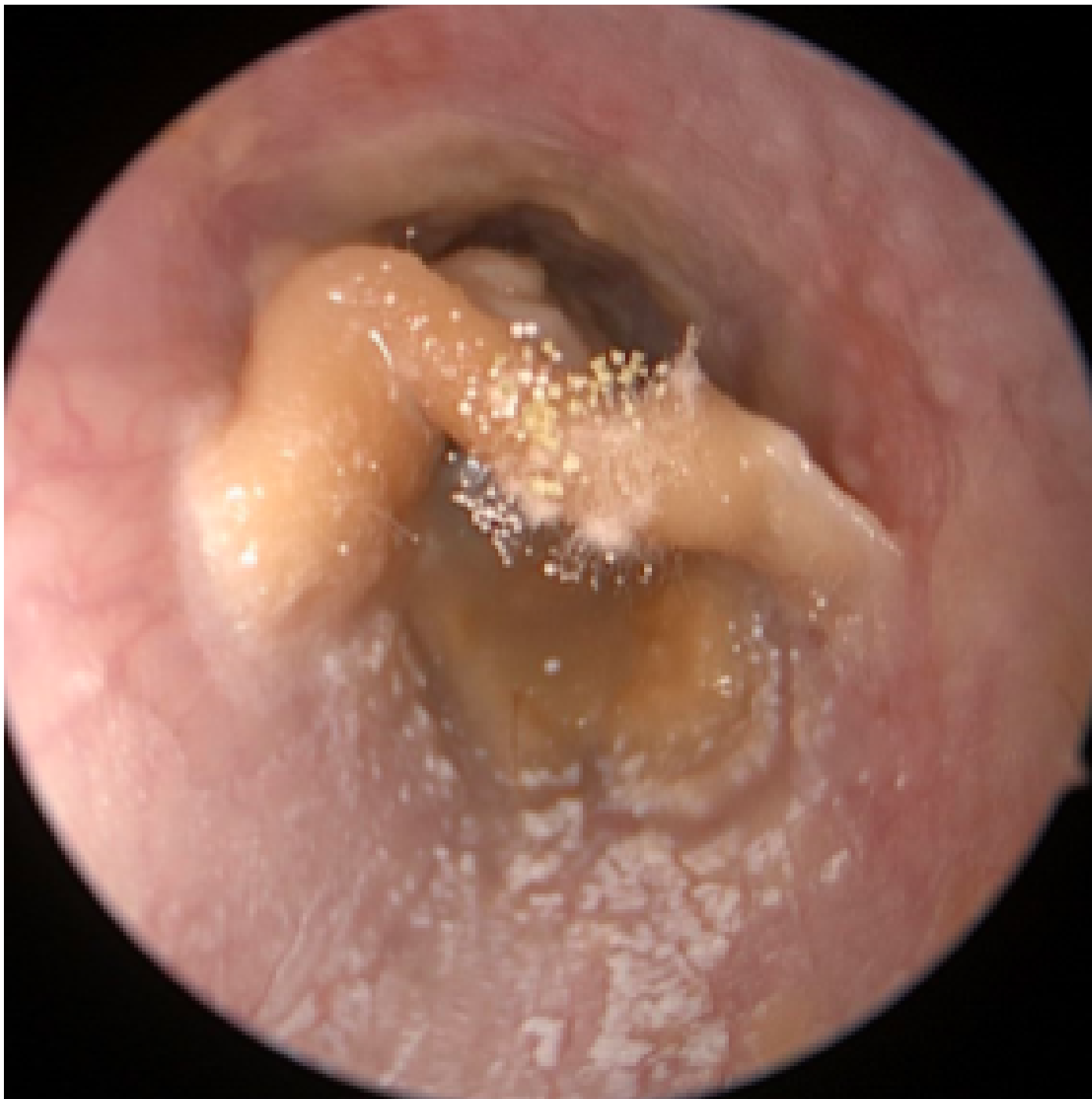WiscMed

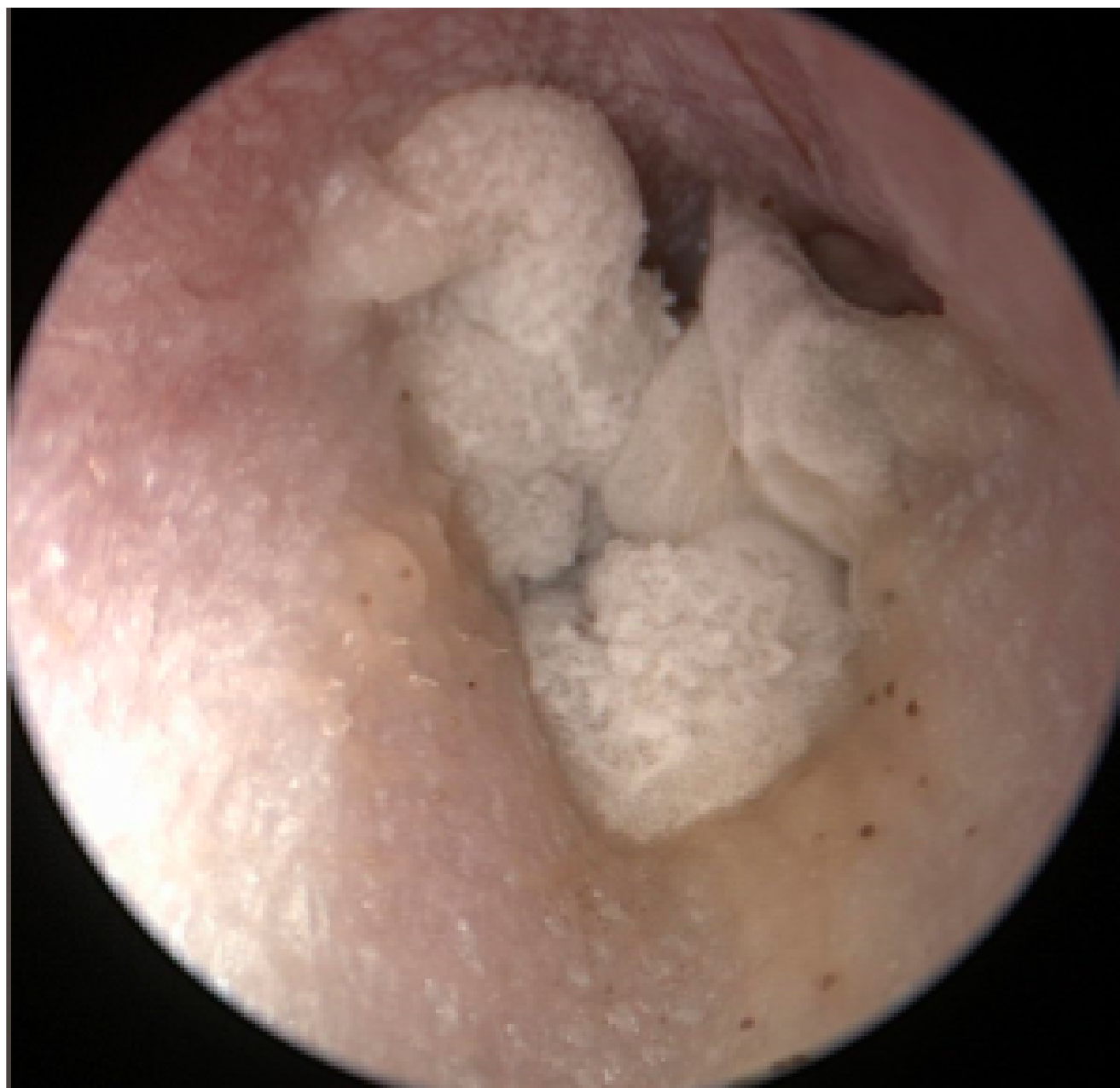











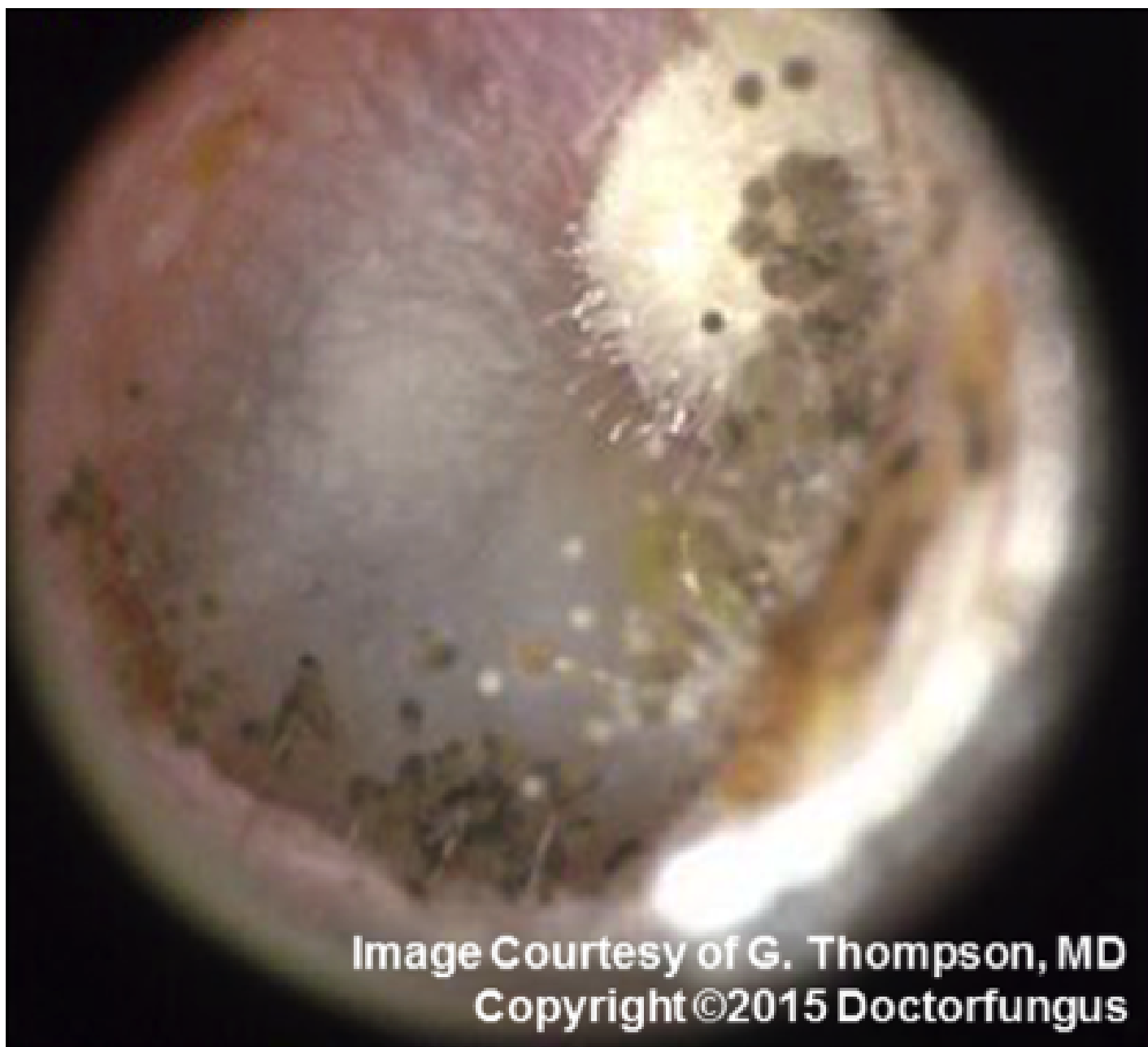
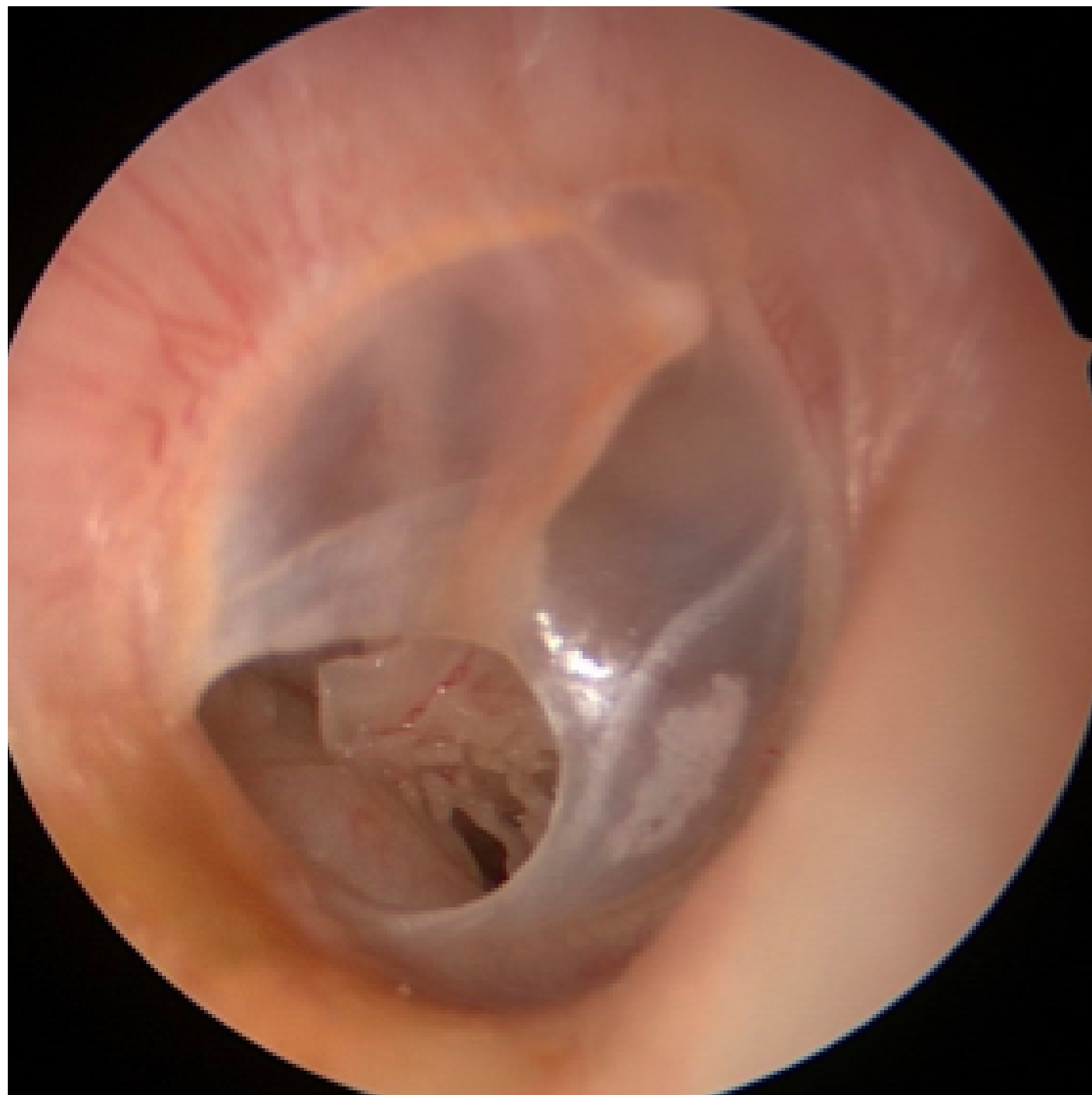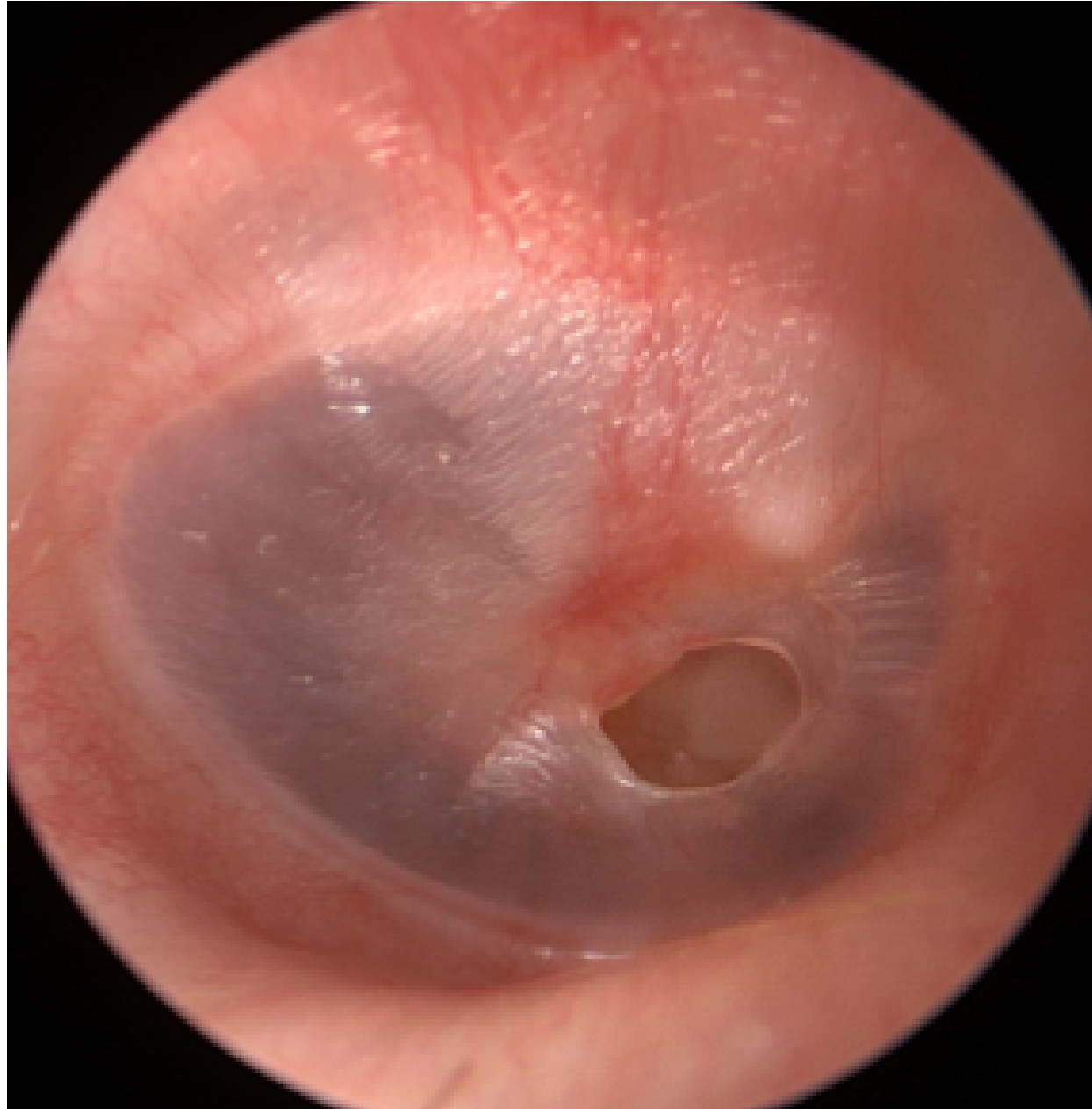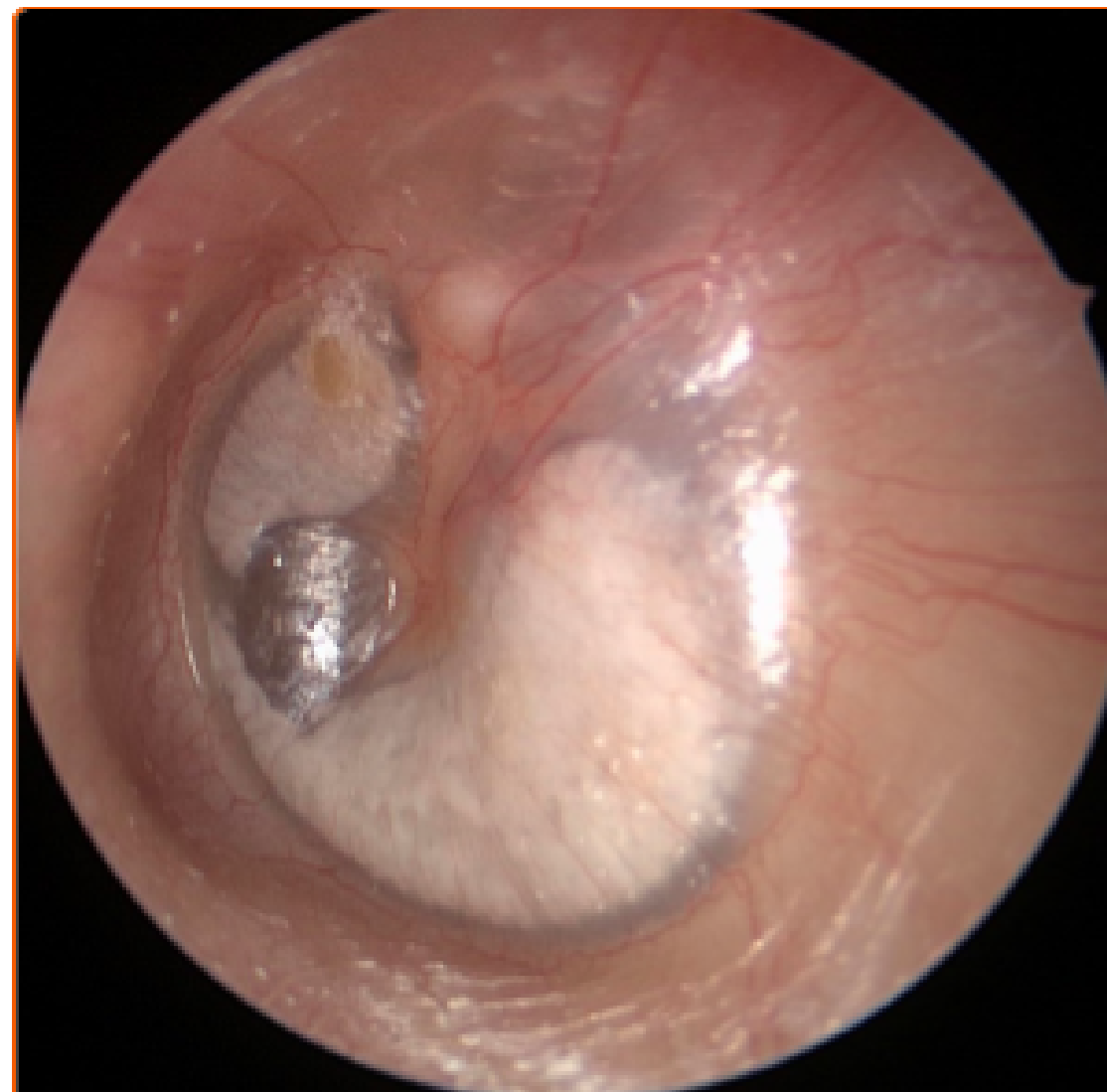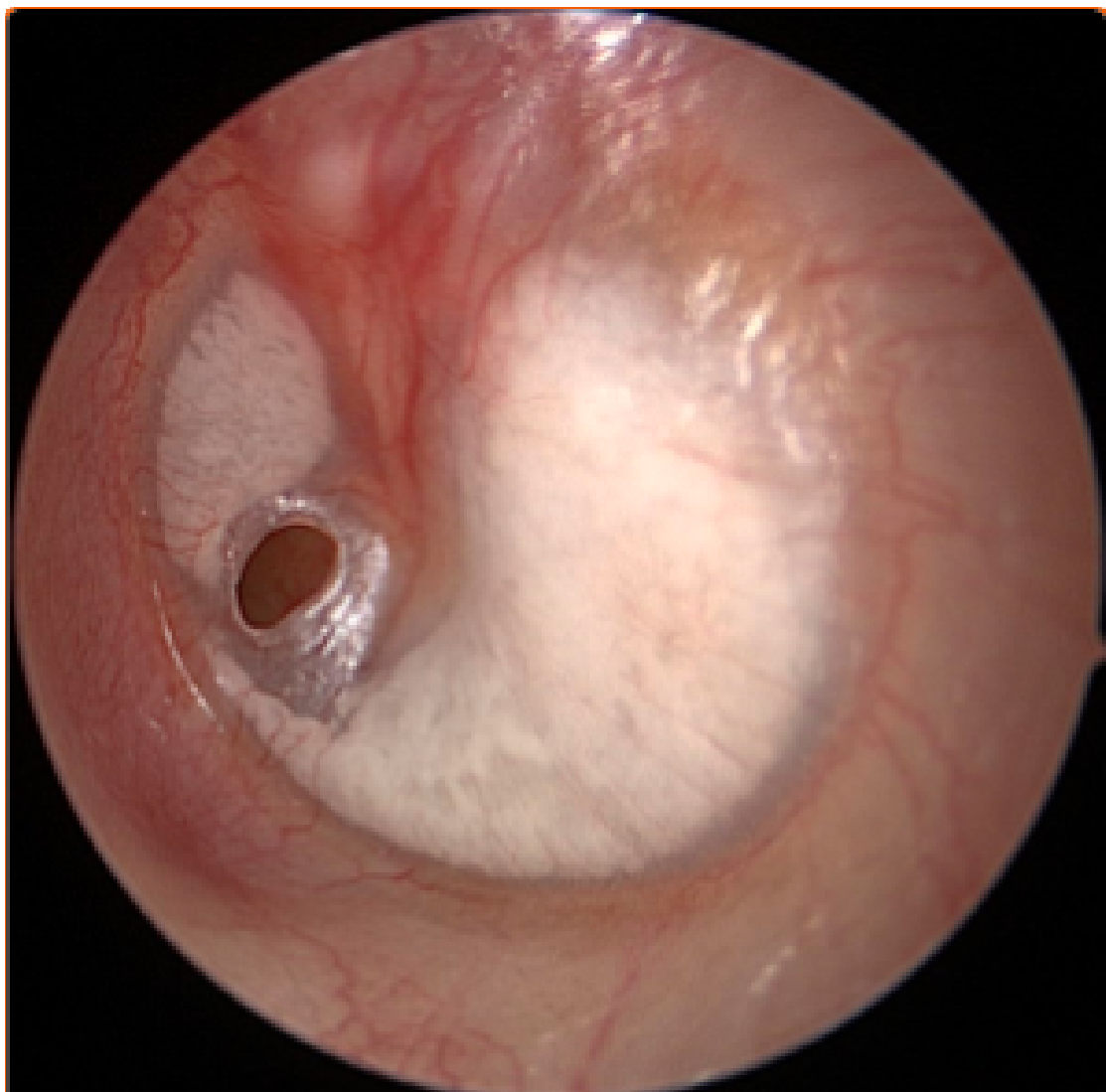


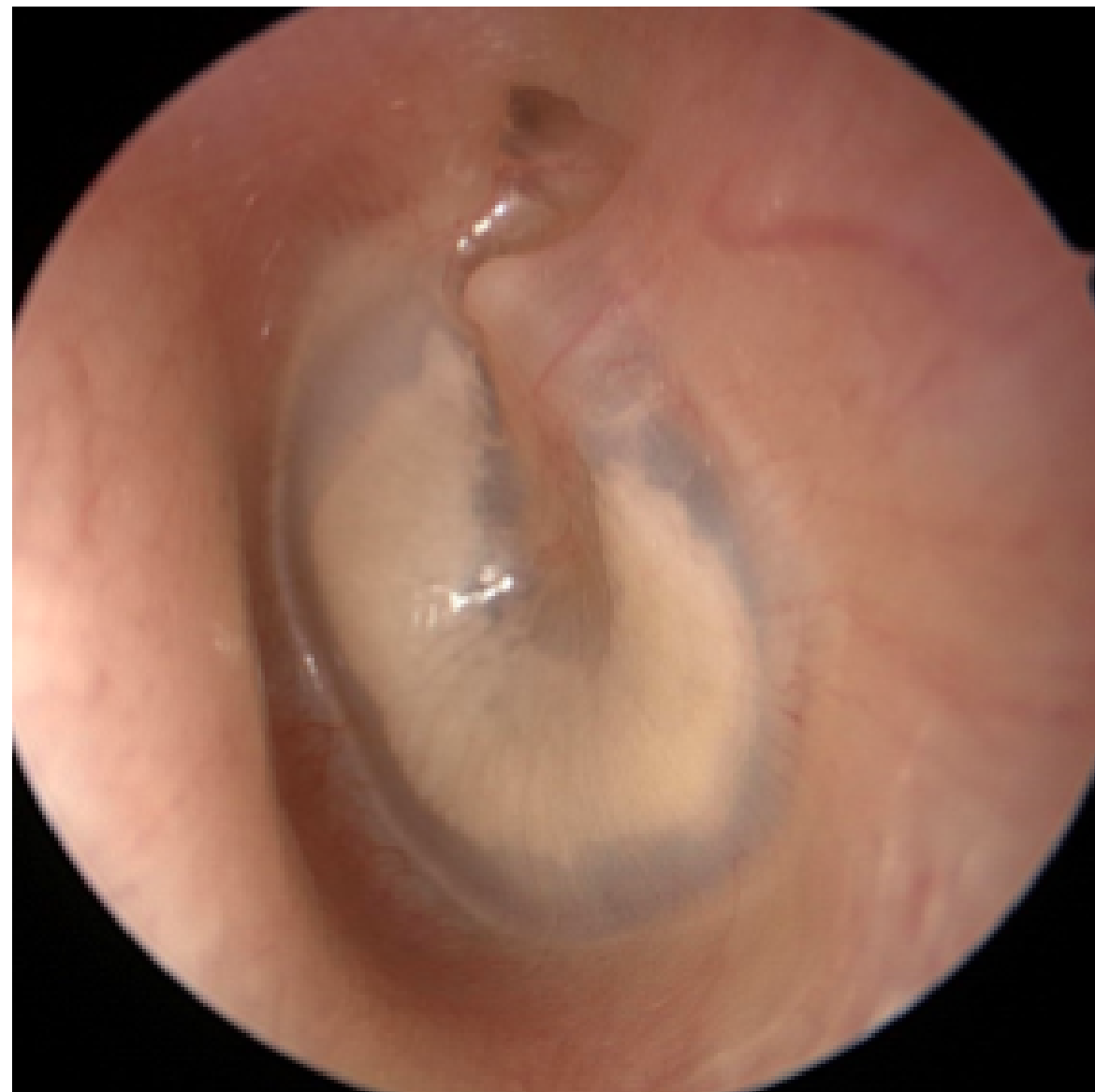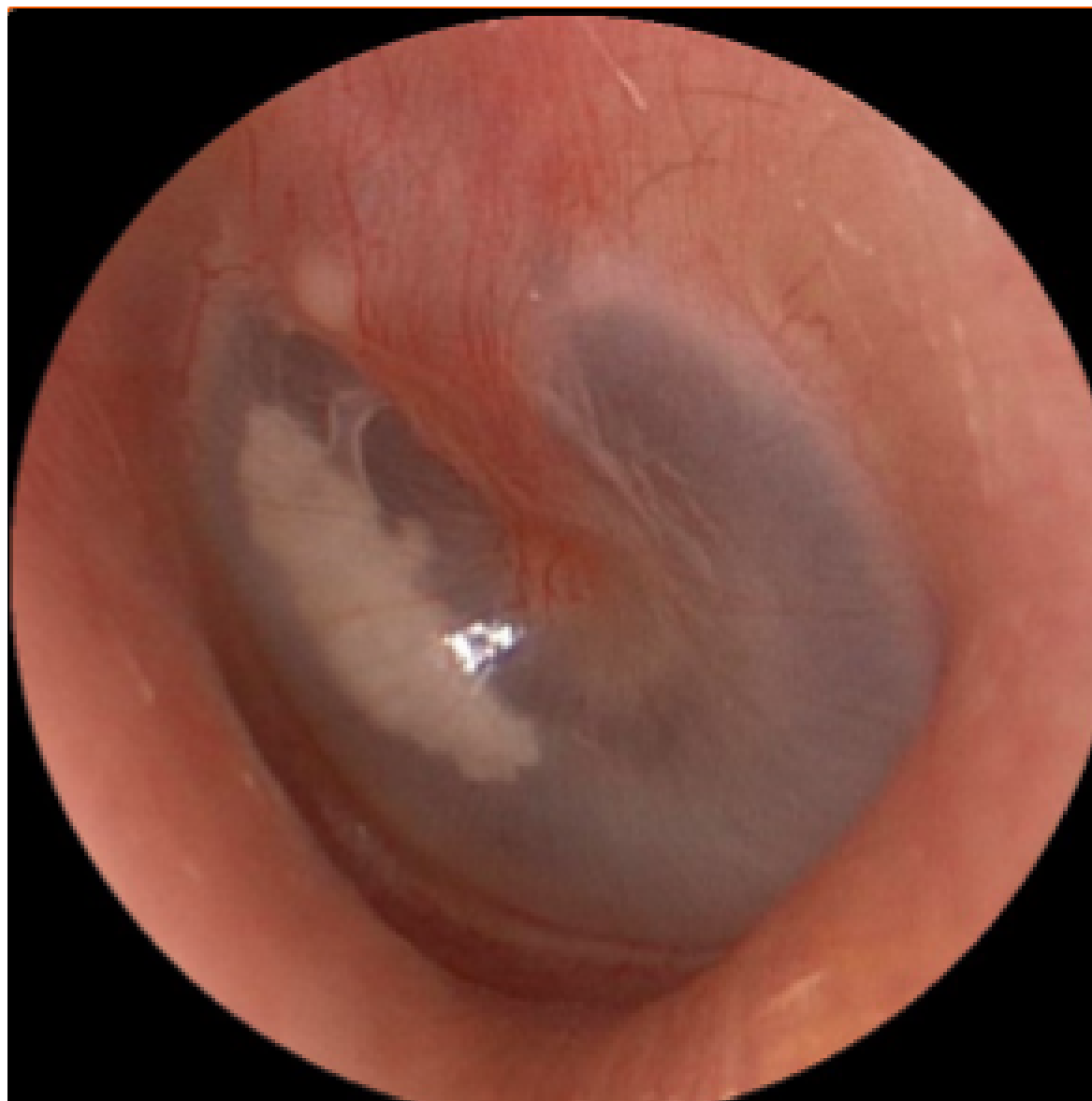
Image Courtesy of G. Thompson, MD  
Copyright ©2015 Doctorfungus

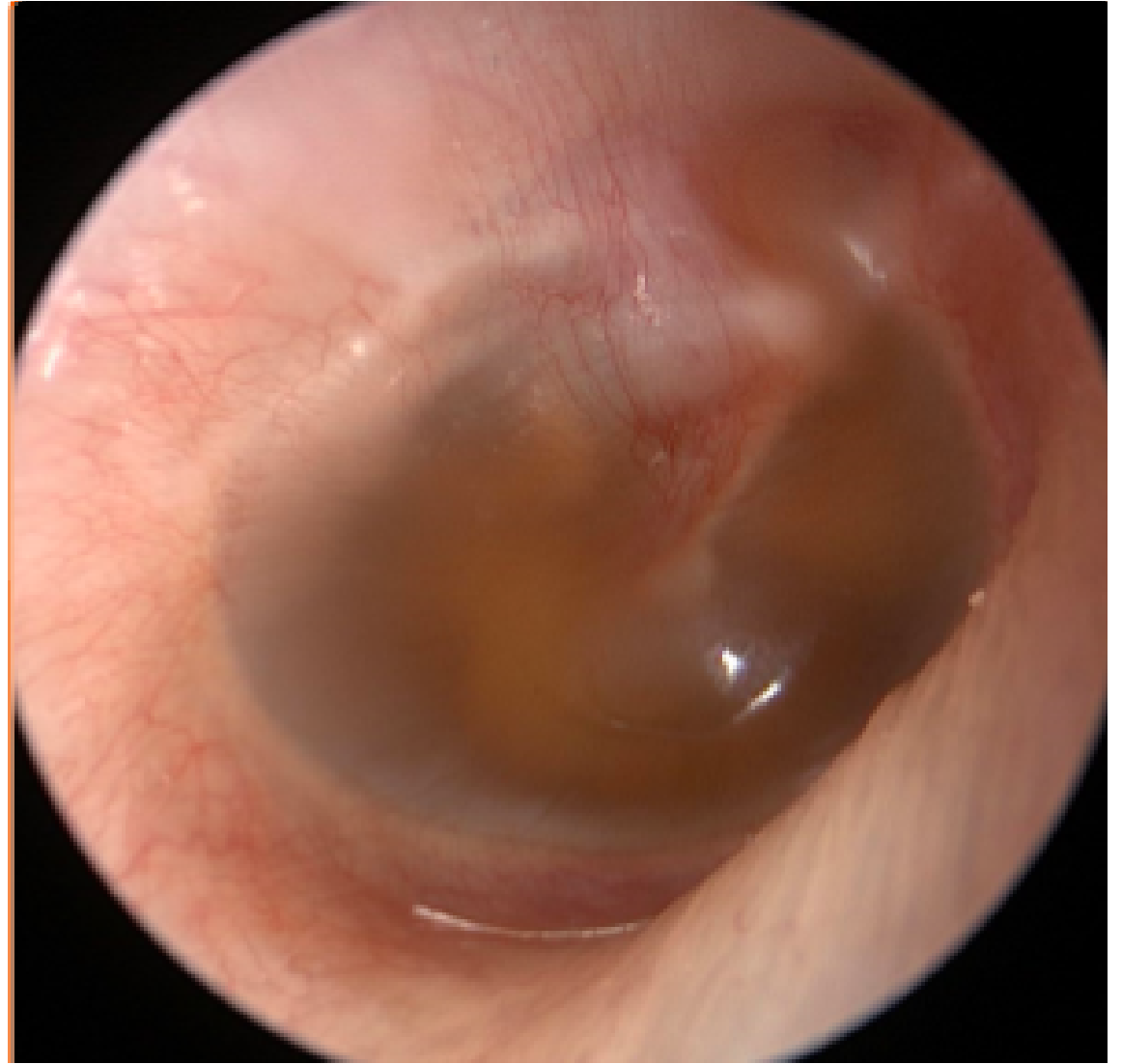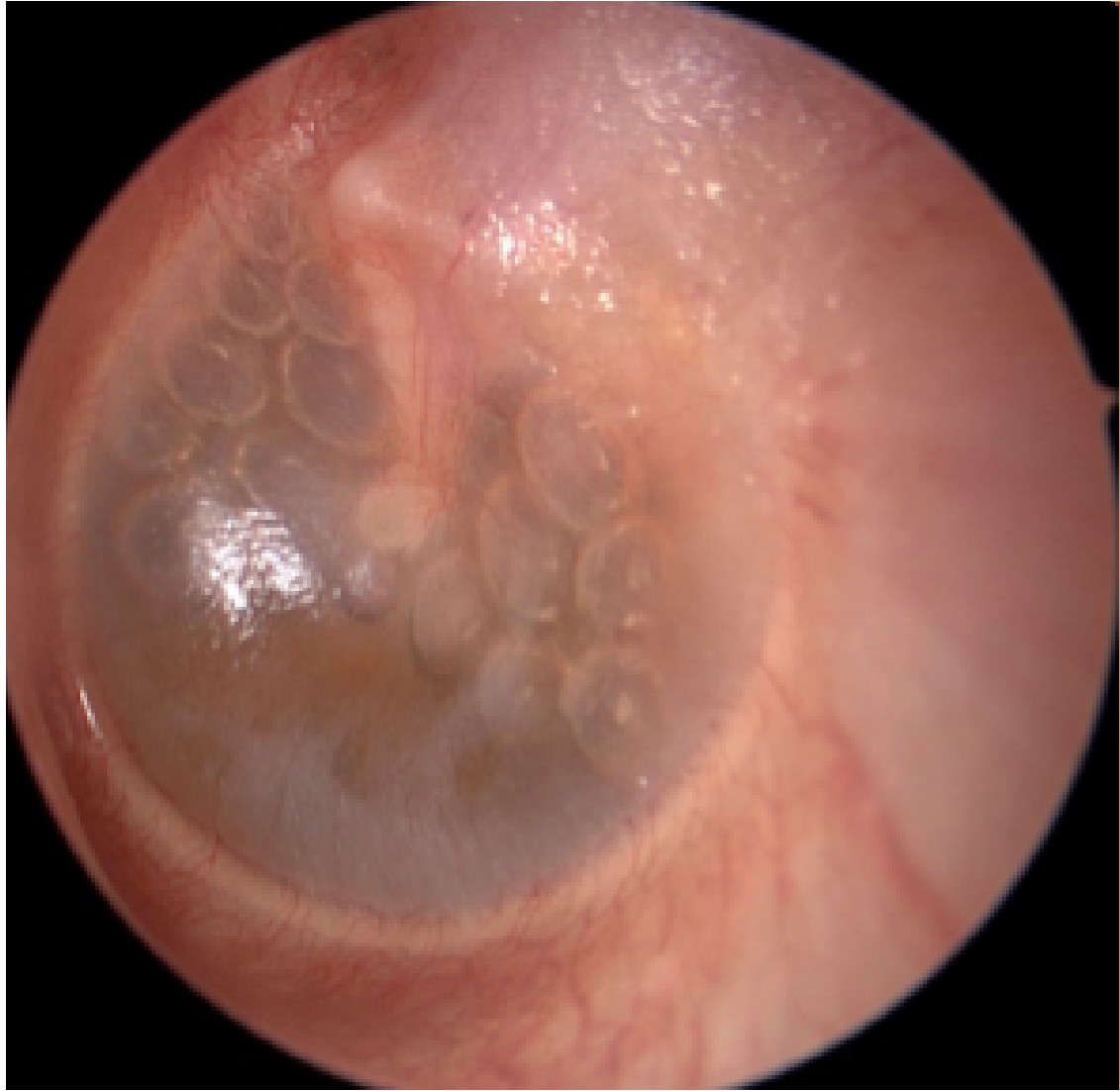


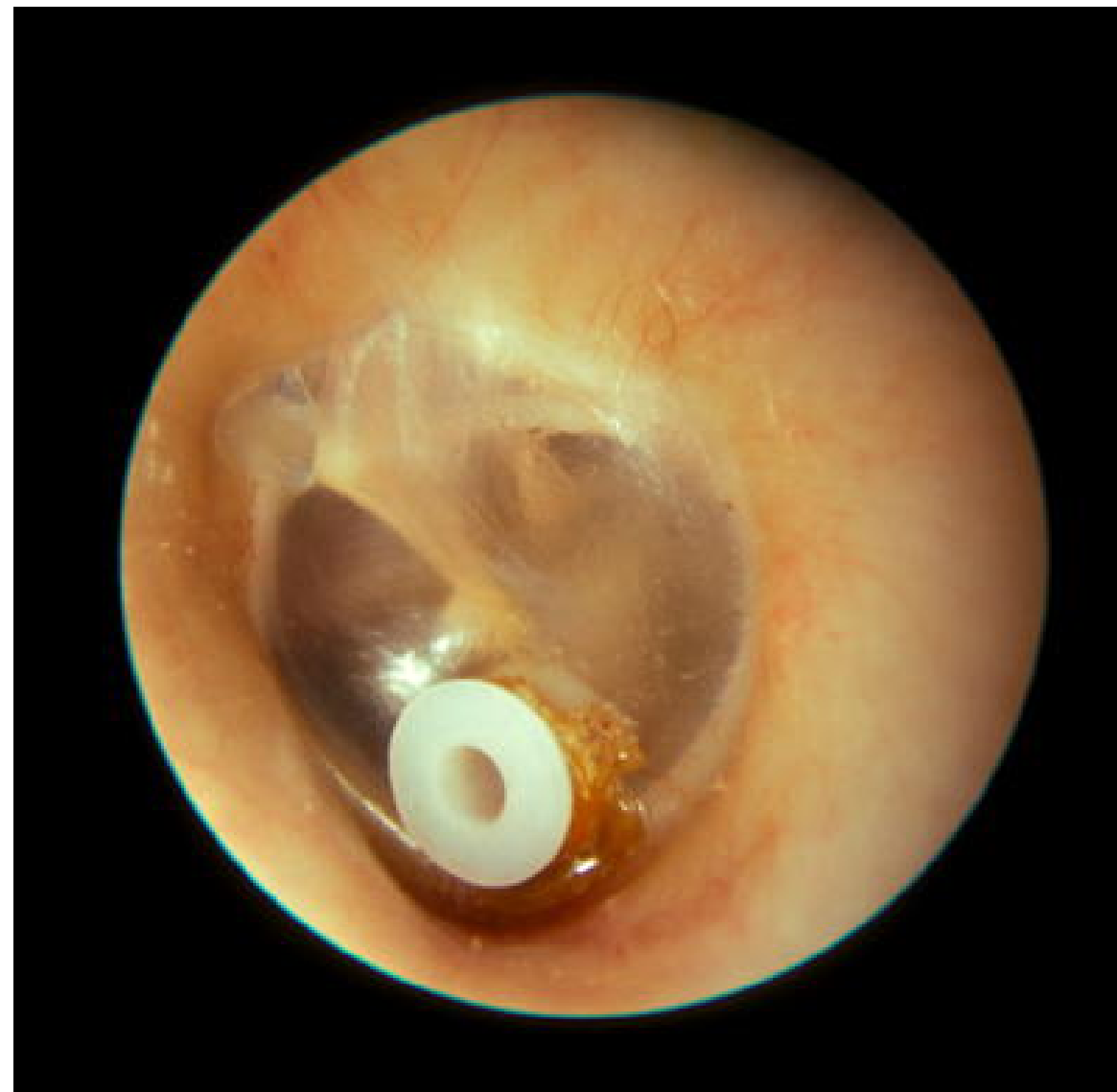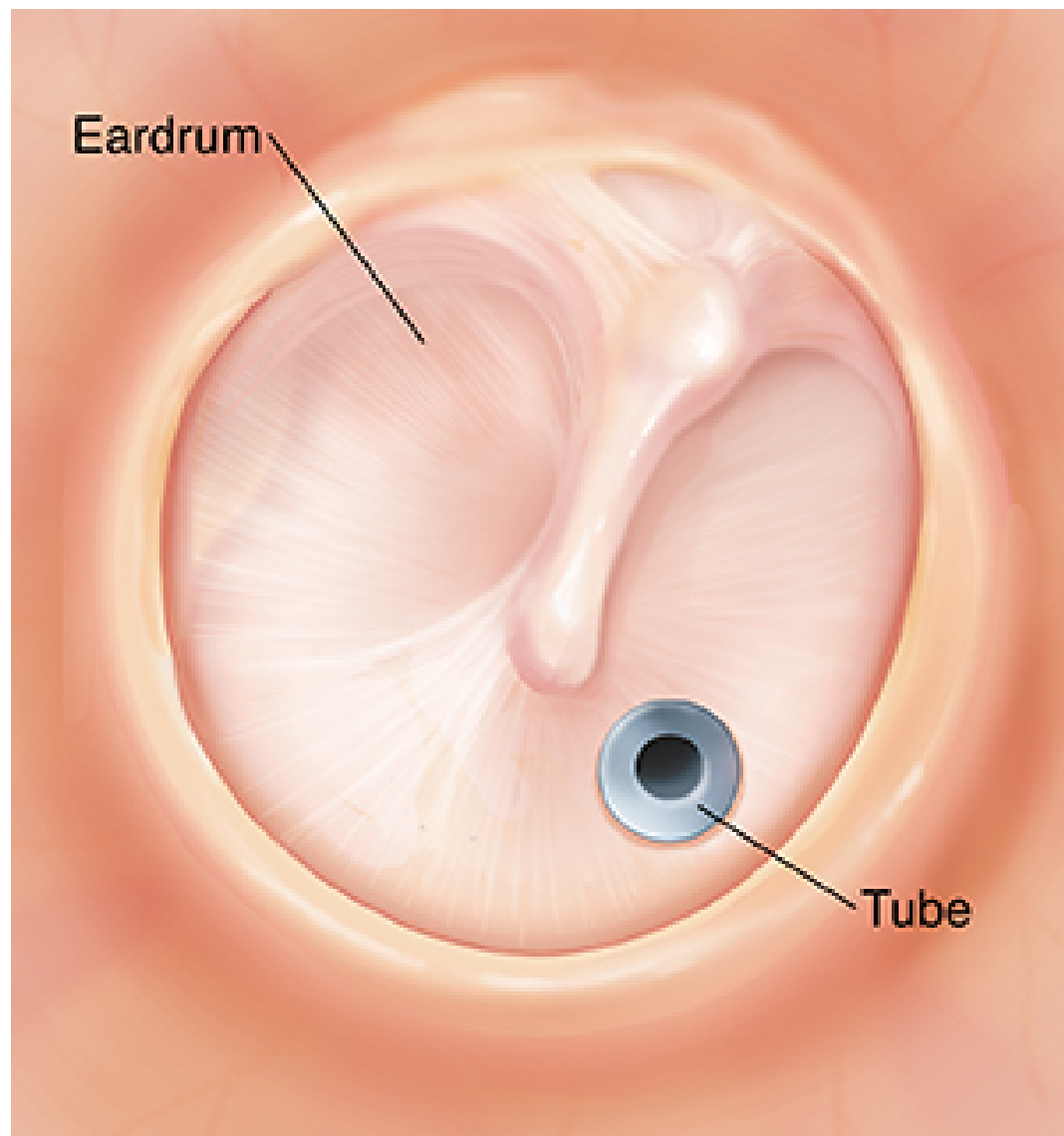




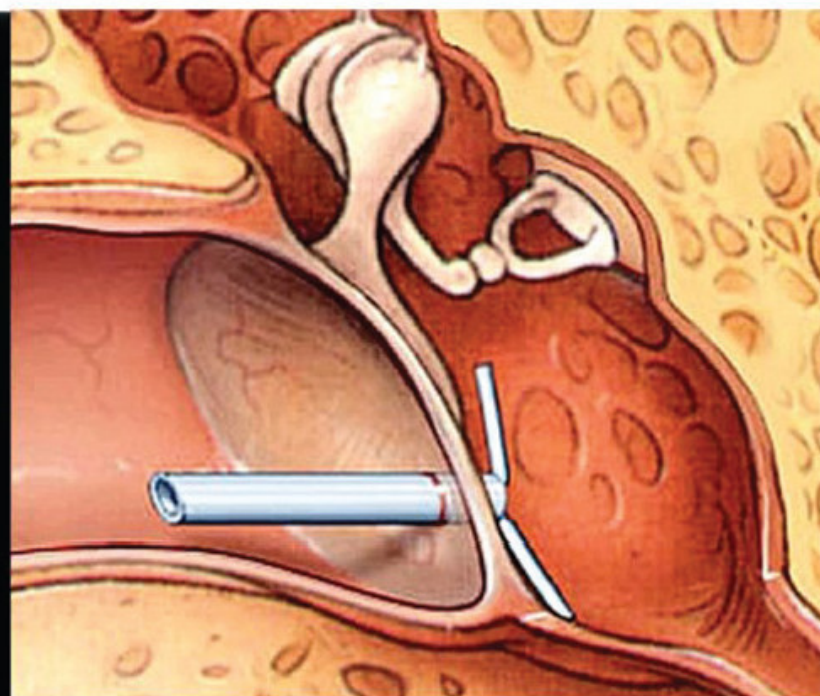
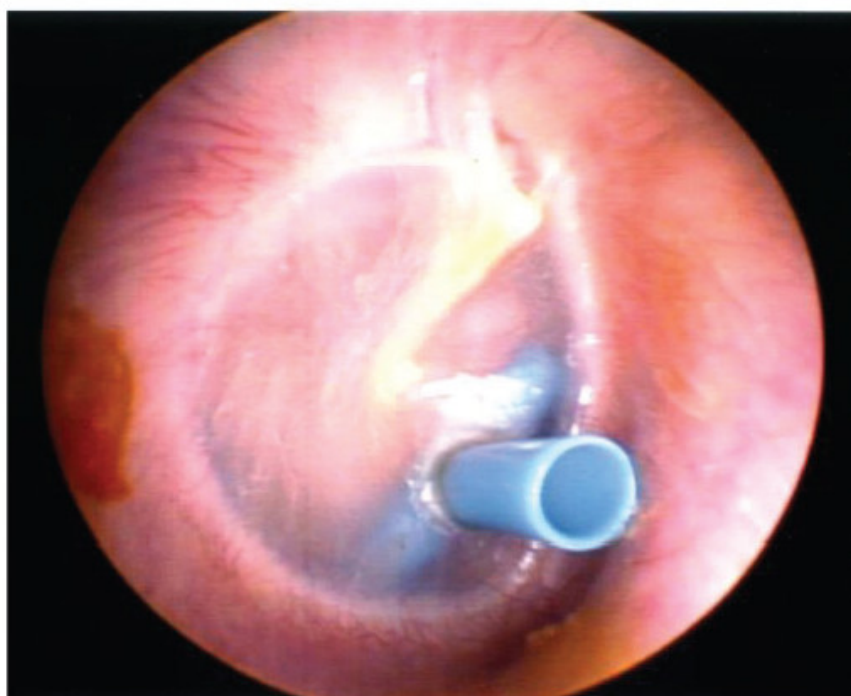
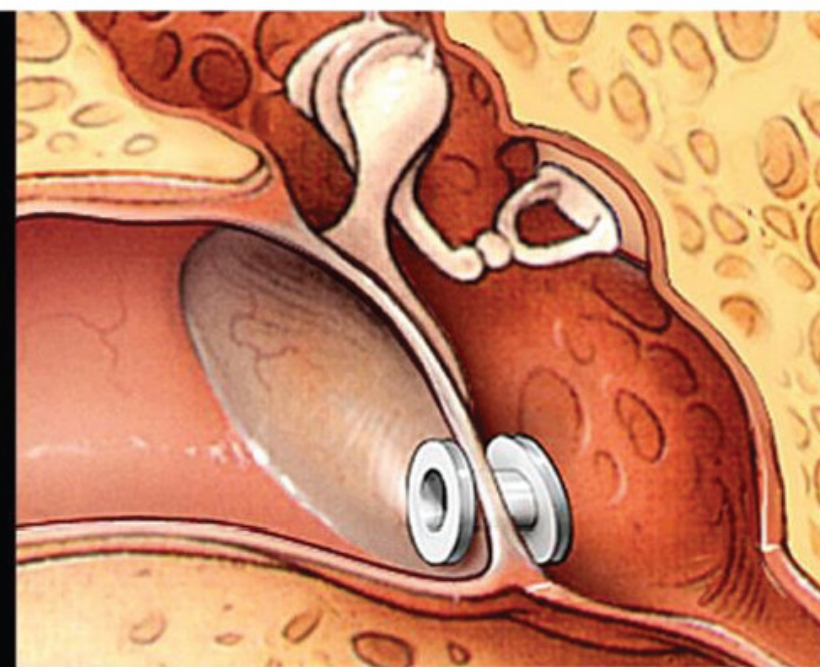
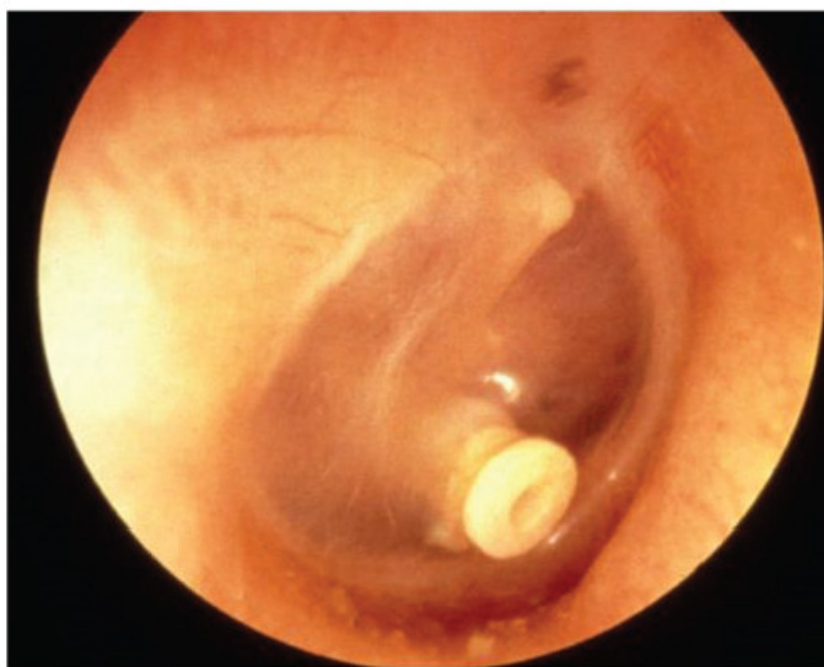












LATERAL PROCESS  
OF MALLEUS

PARS  
FLACCIDA

UMBO

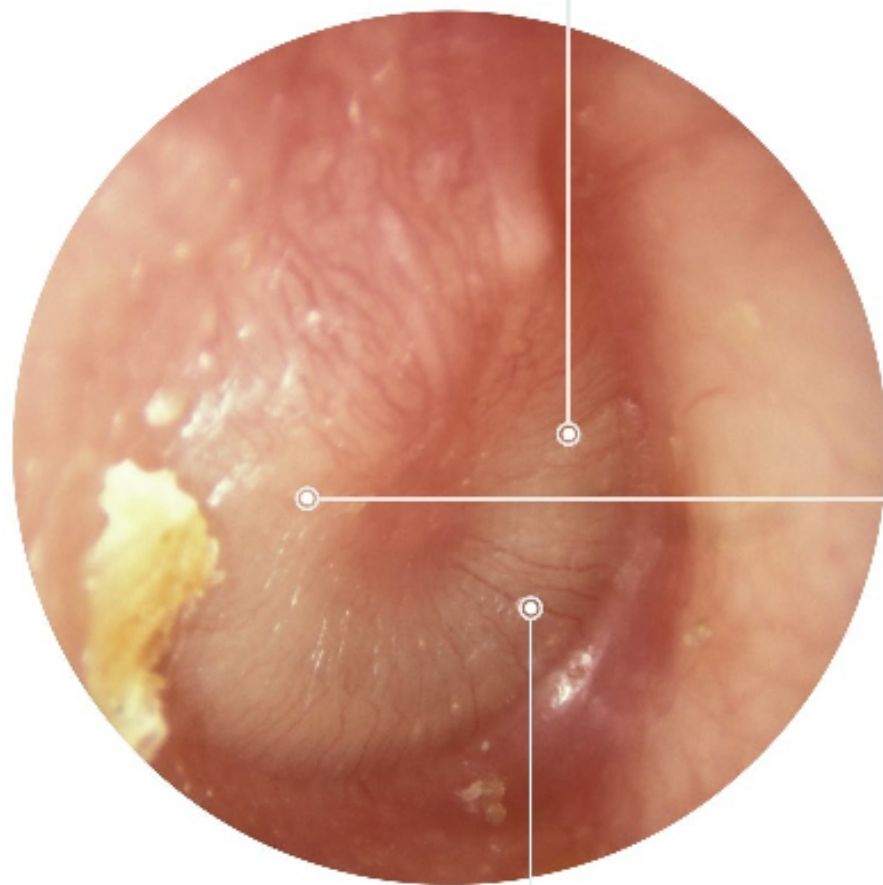
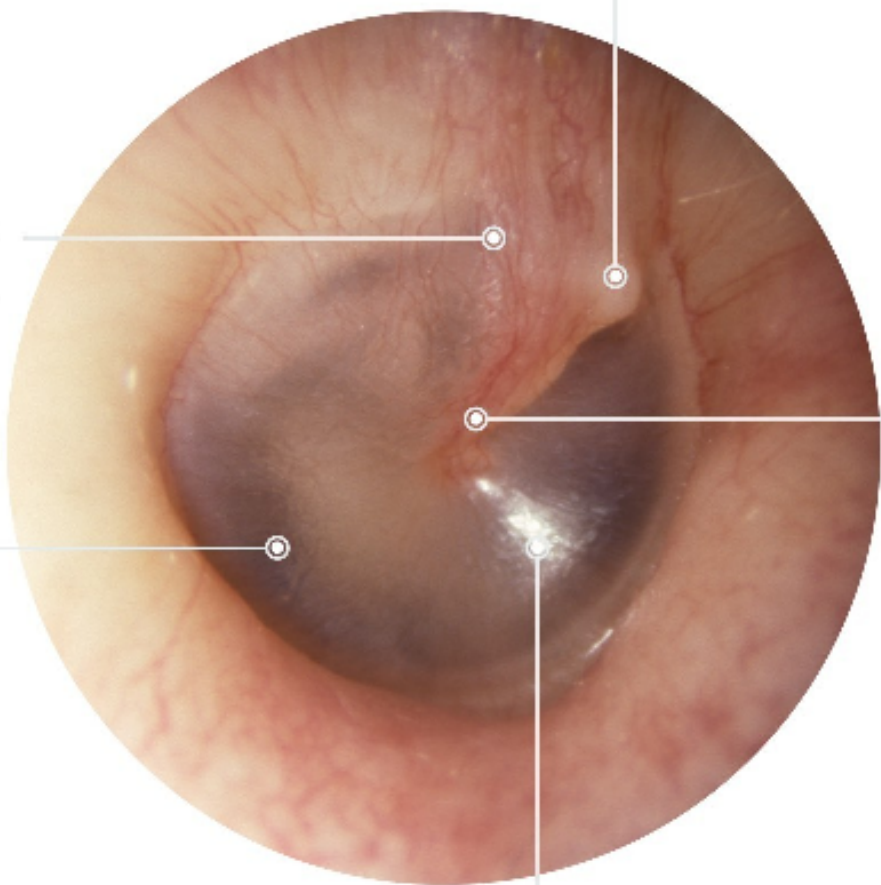
PARS  
TENZA

CONE OF  
LIGHT

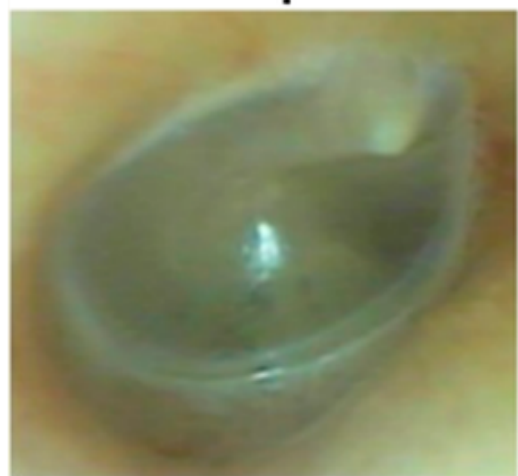OPACIFICATION  
OF MEMBRANE

BULGING  
MEMBRANE

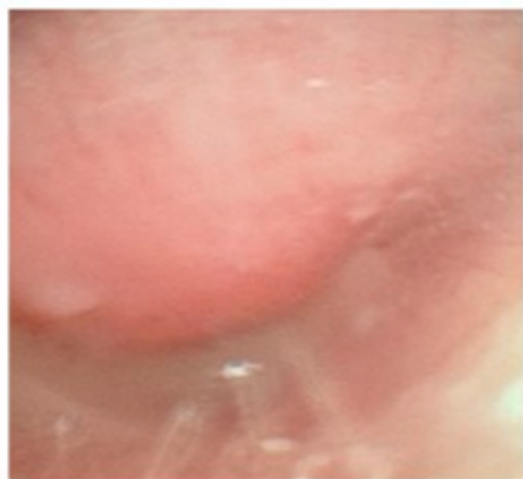PROMINENT DILATED  
VESSELS



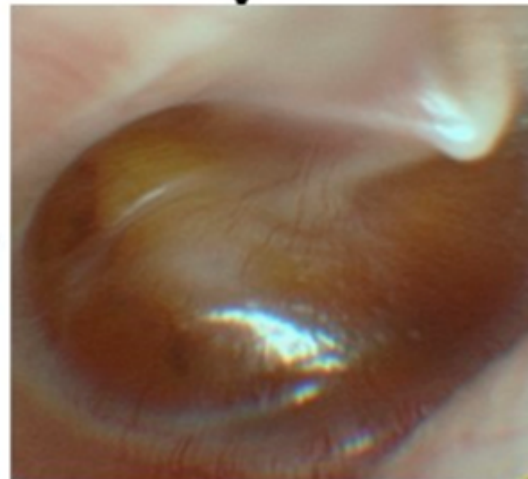




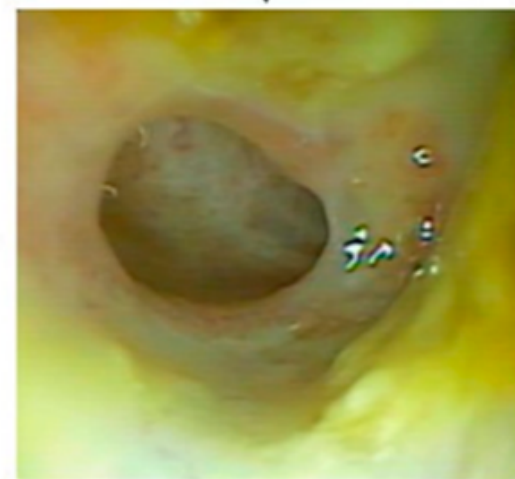**Normal**



**AOM**

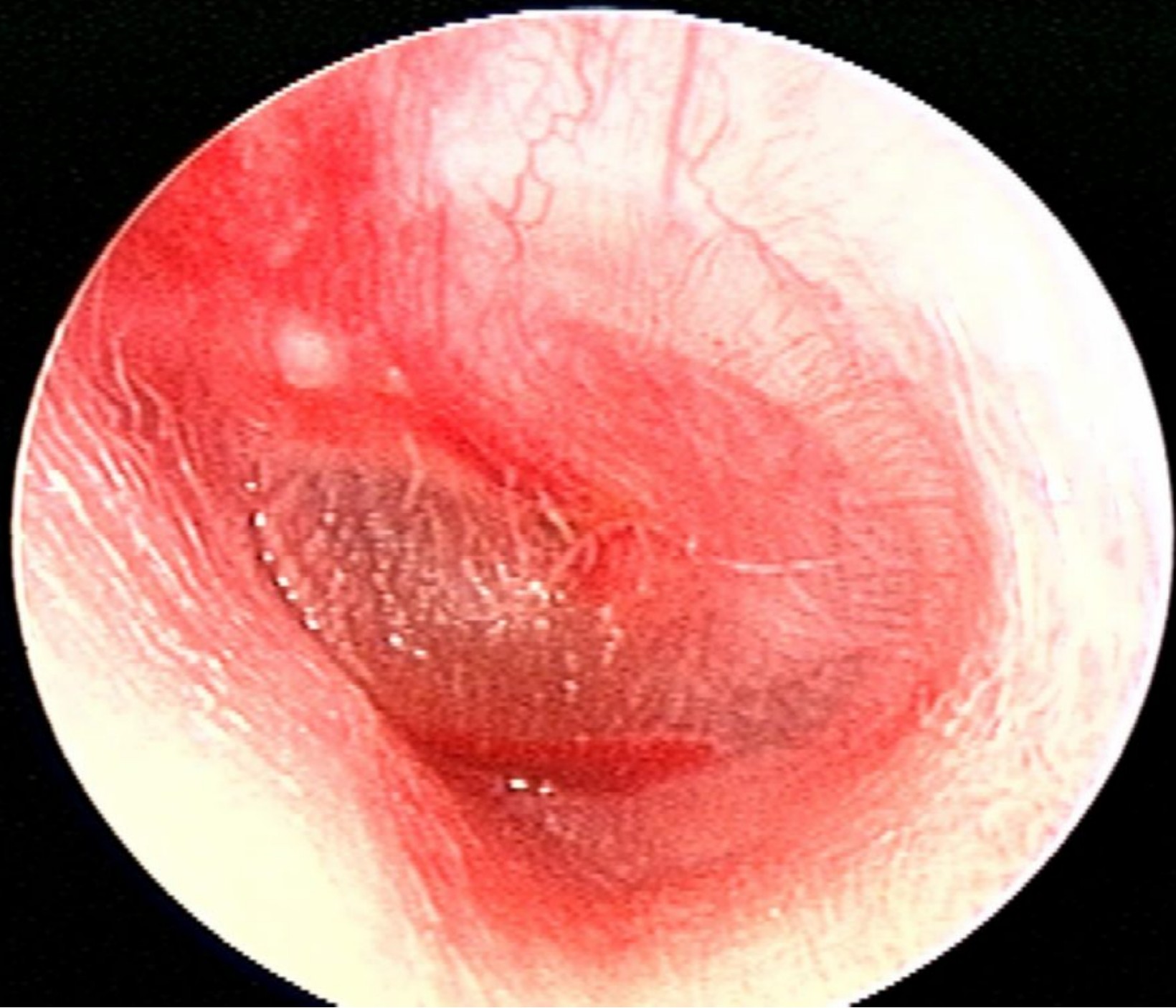


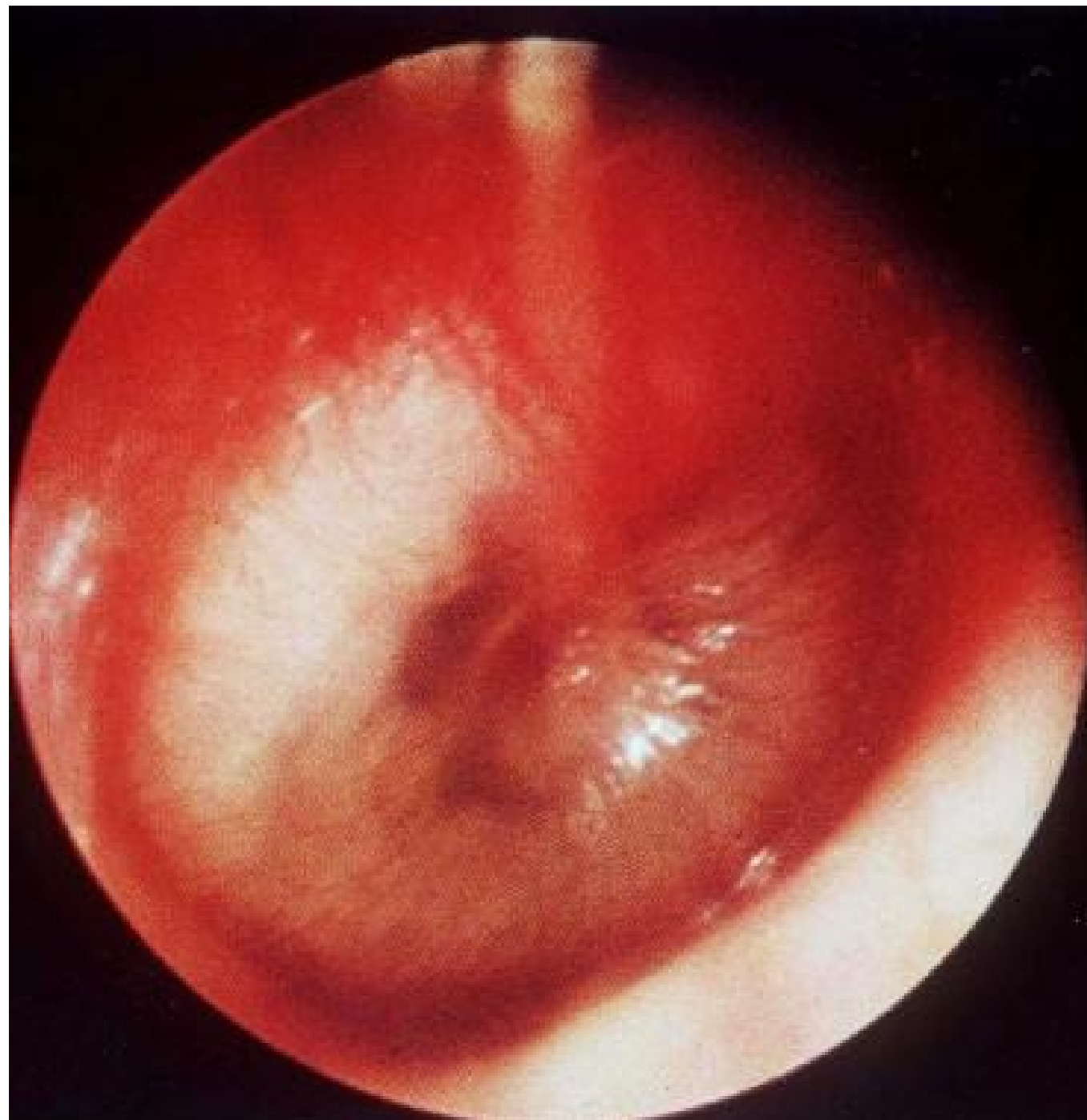**OME**

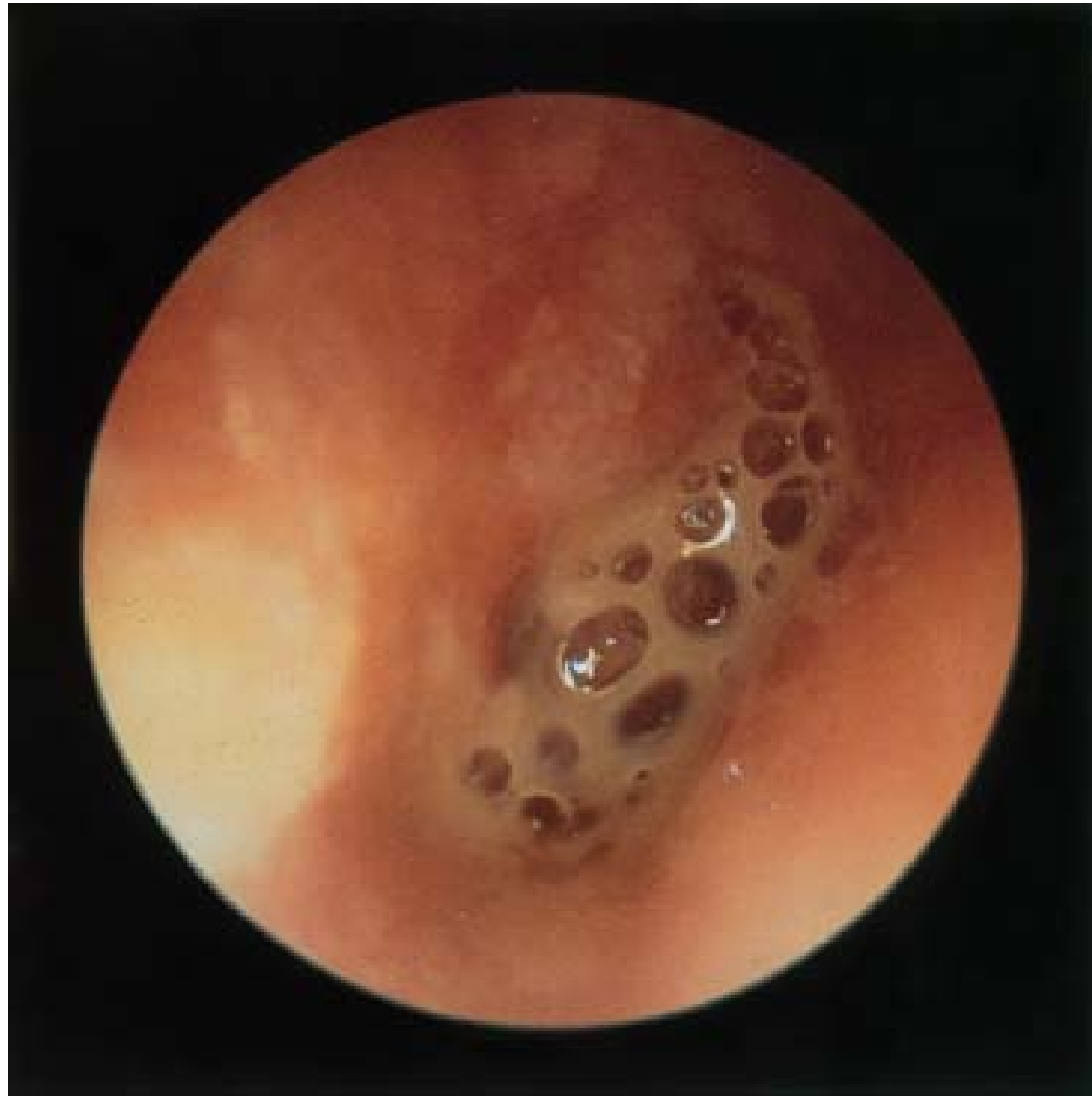

**COM**

Stage of hyperemia  
Stage of exudation  
Stage of suppuration  
Stage of coalescence  
Stage of complication

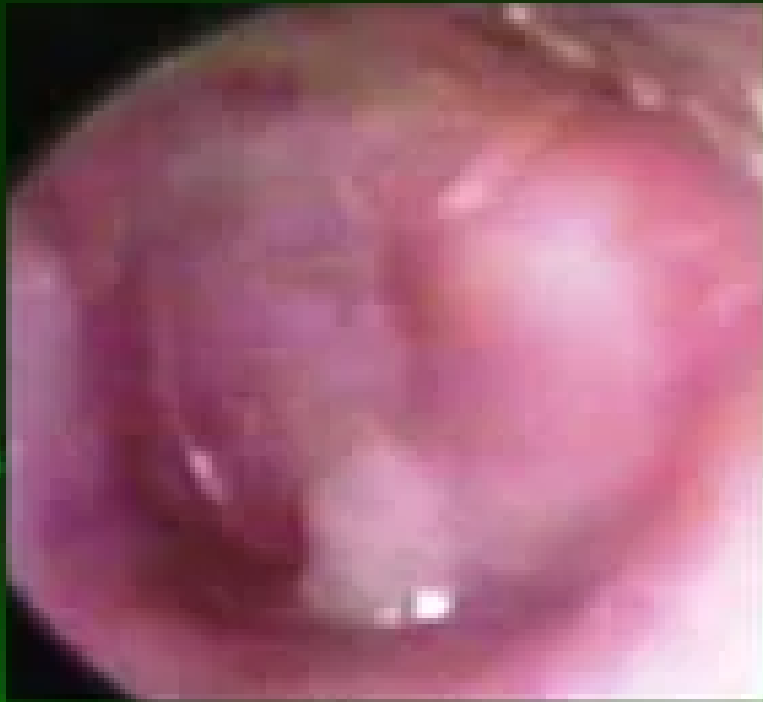




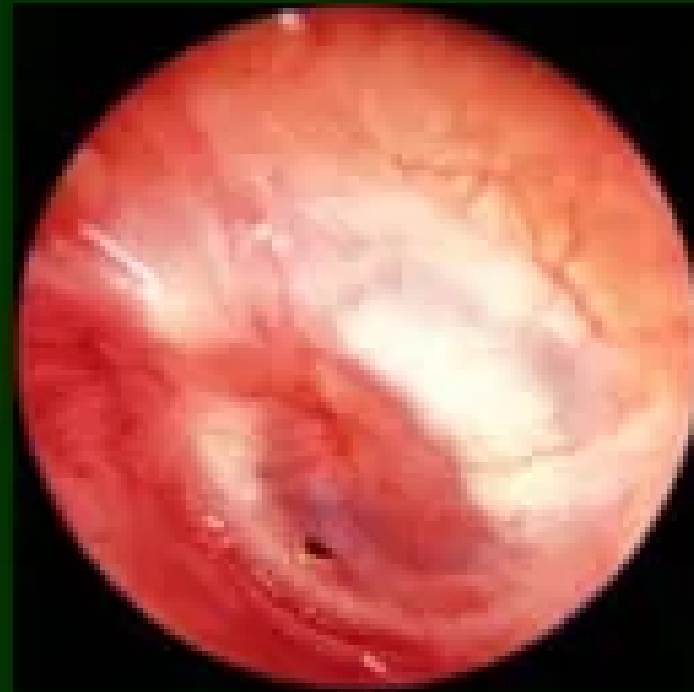
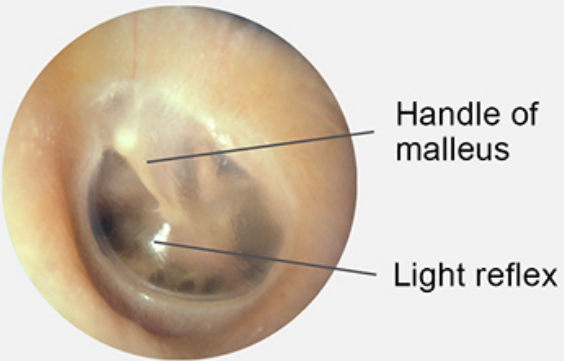


**Light House sign**

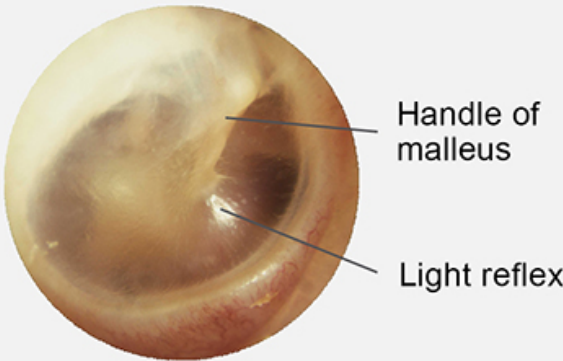


**Pinhole perforation**

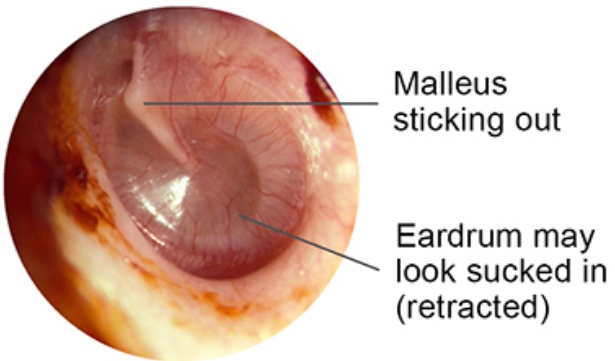




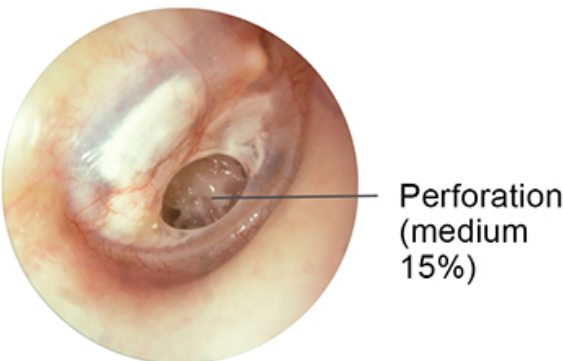
**Normal eardrum L**



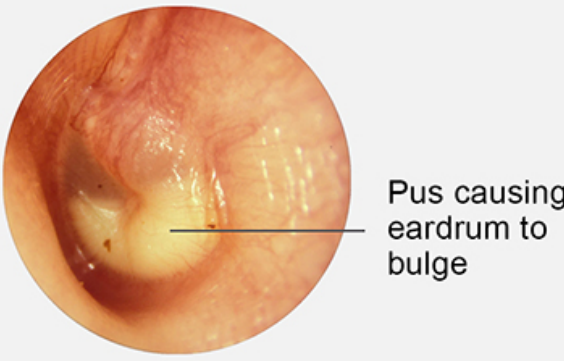
**Normal eardrum R**



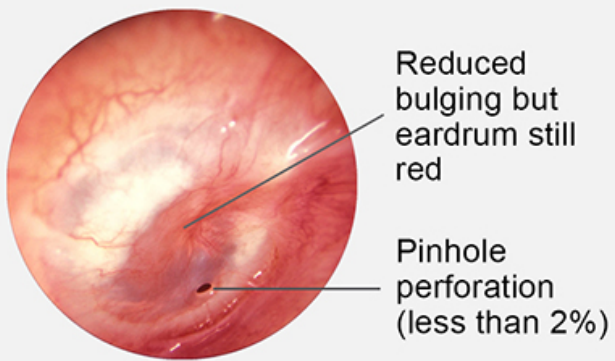
**Otitis media with effusion (OME) L**



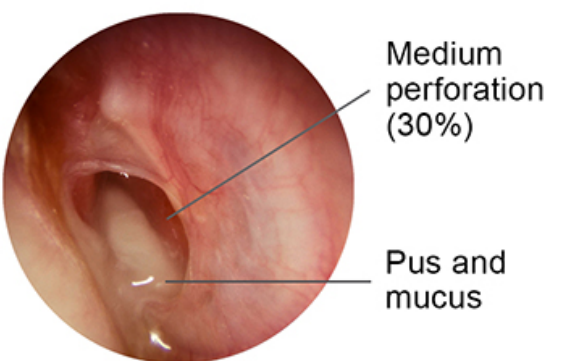
**Dry perforation R**



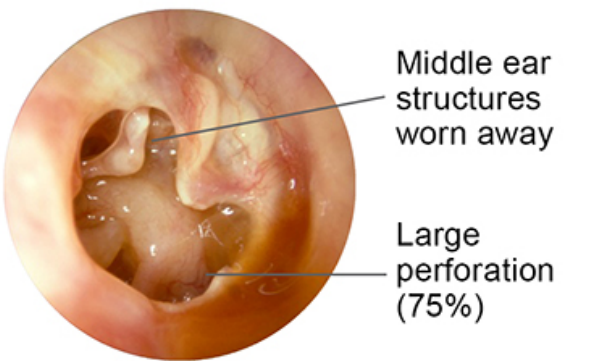
**Acute otitis media (AOM) L**



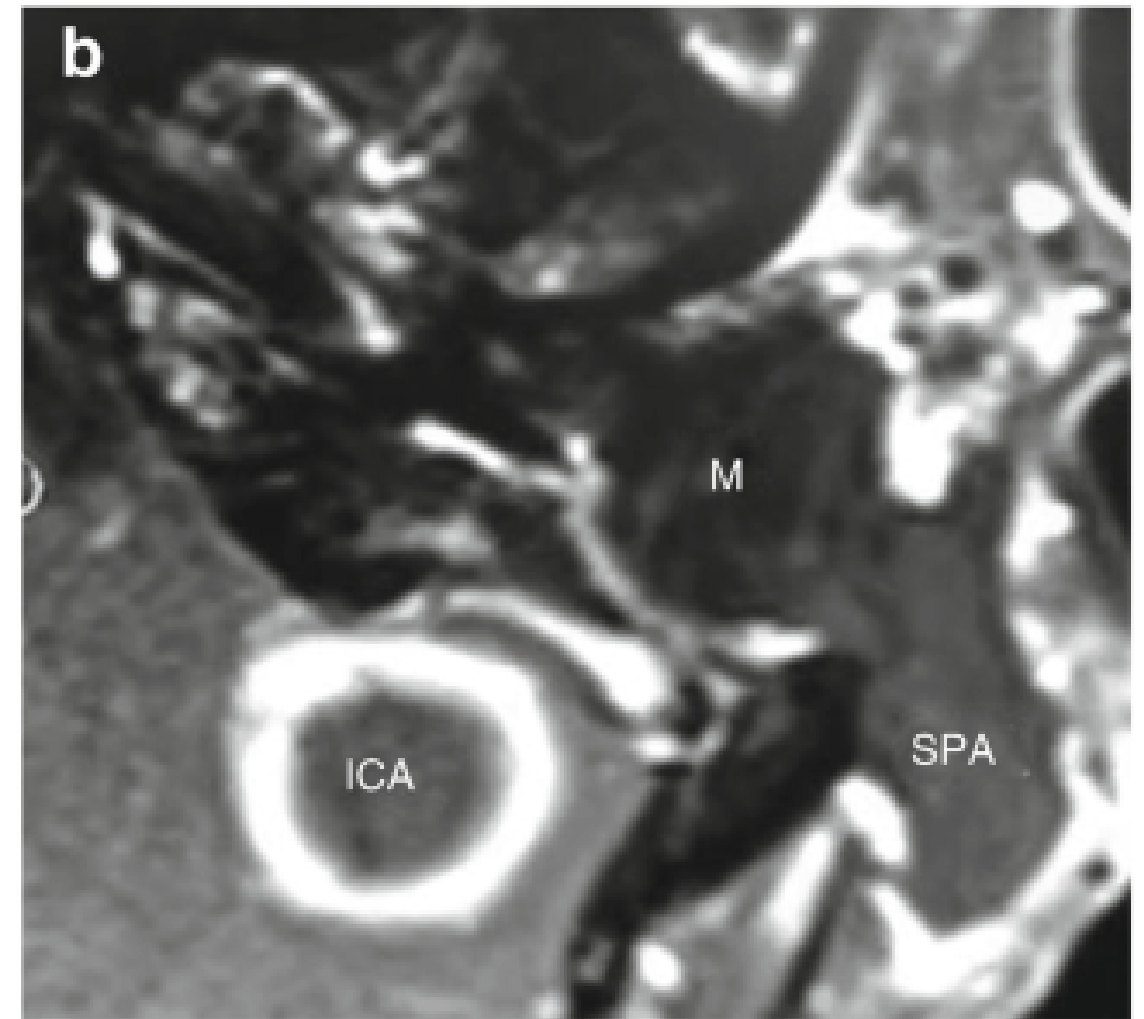
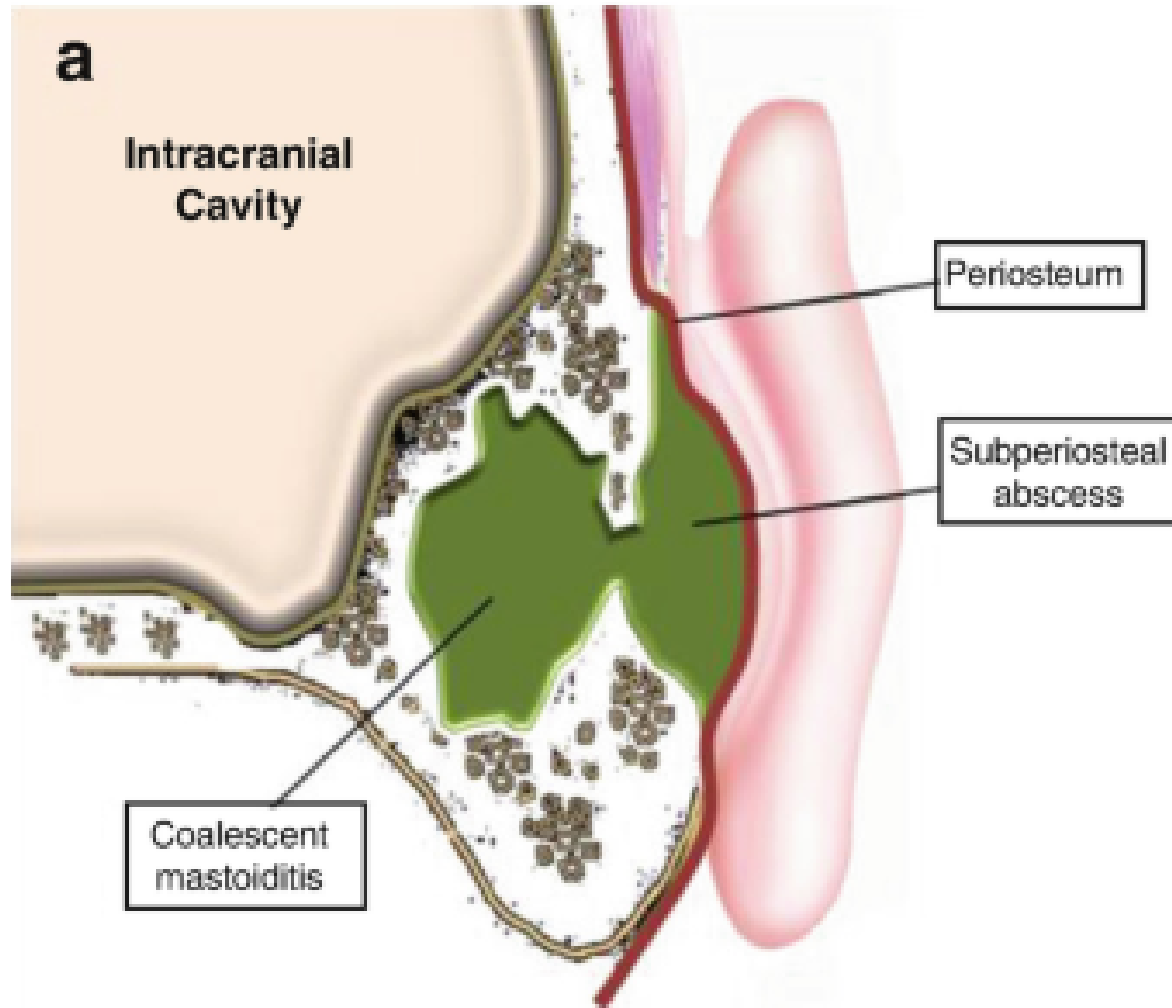
**Acute otitis media with small perforation (AOMwIP) R**

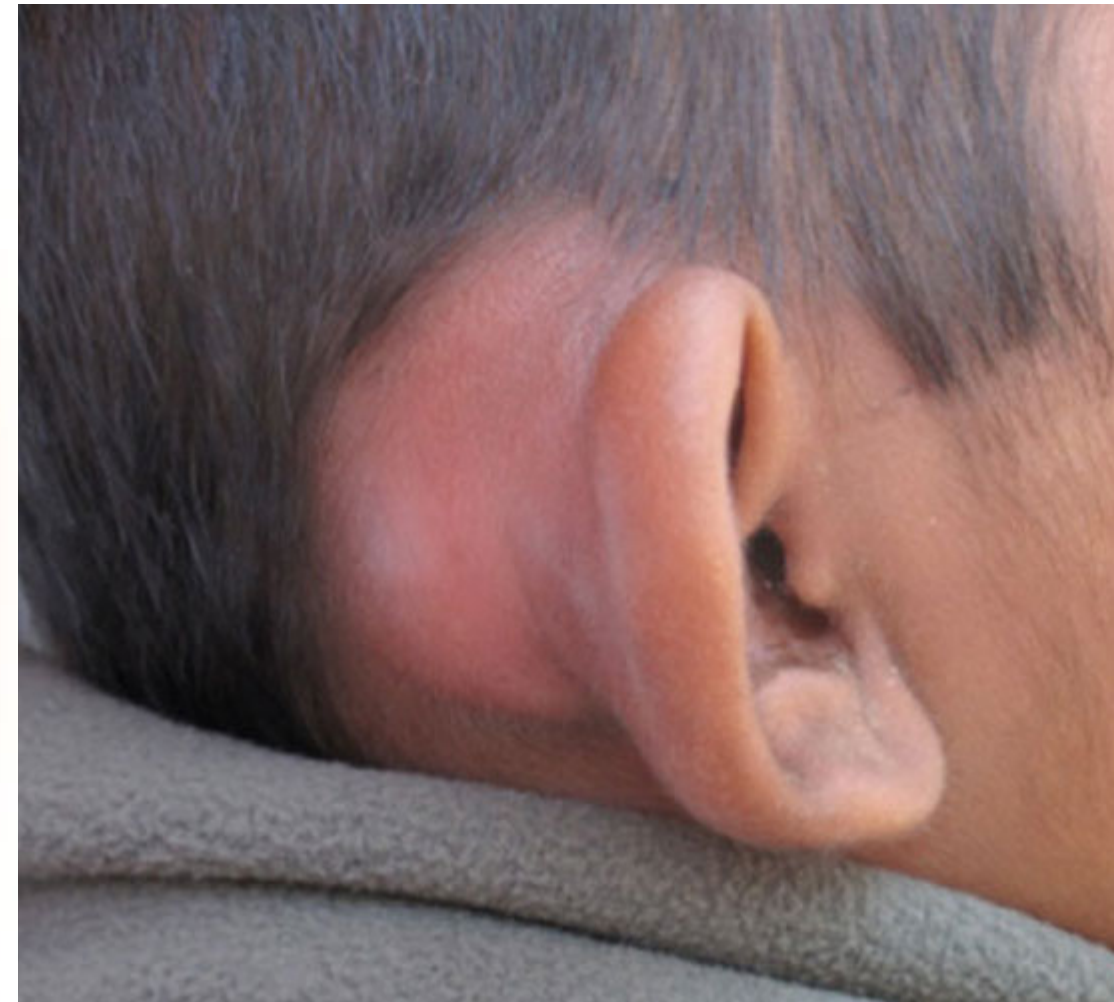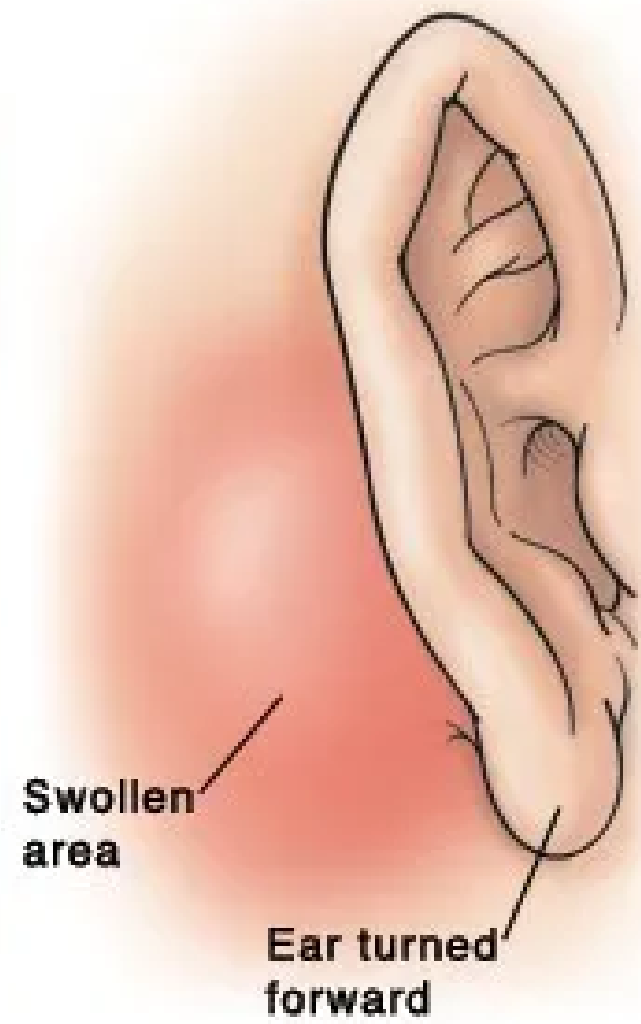
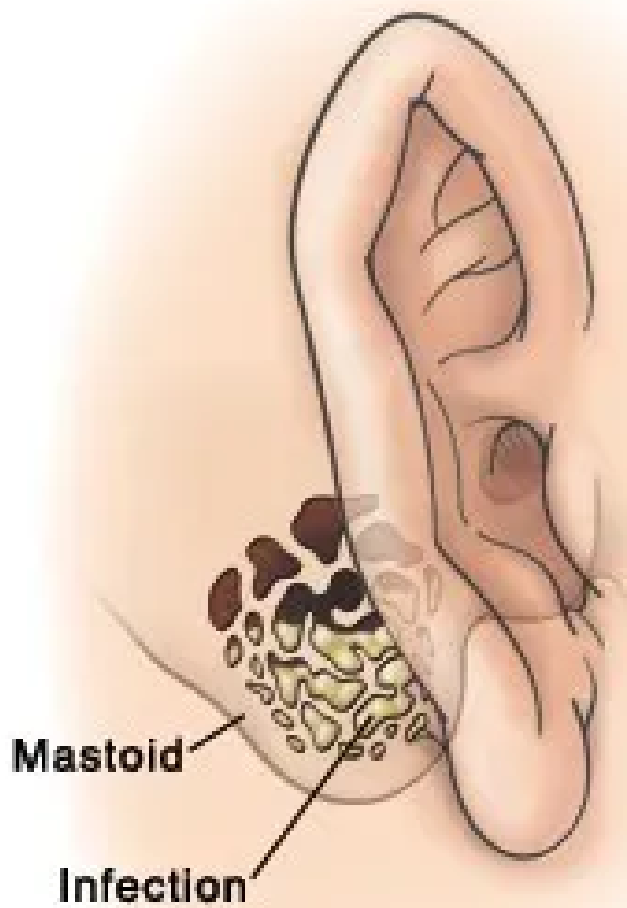


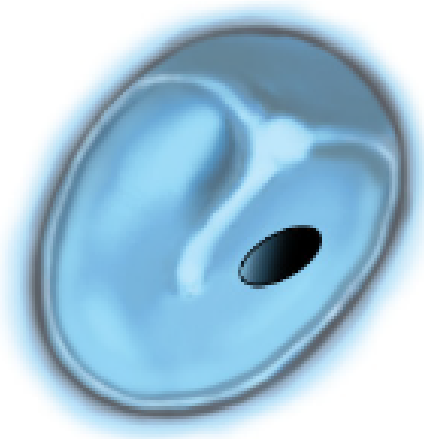**Chronic suppurative otitis media (CSOM) L**



**Chronic suppurative otitis media (CSOM) R**







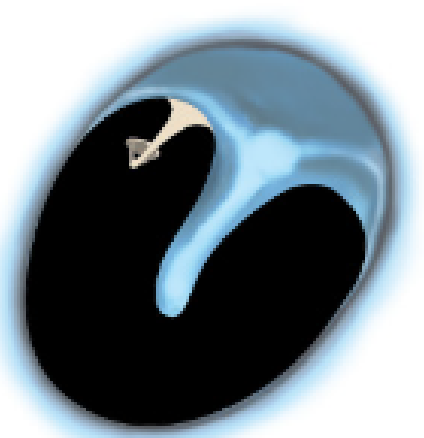Central perforation  
(anterior)



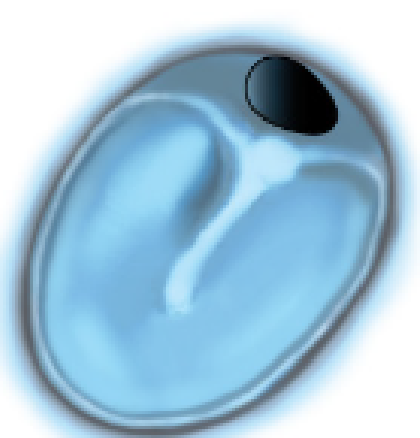Central perforation  
(medium sized)



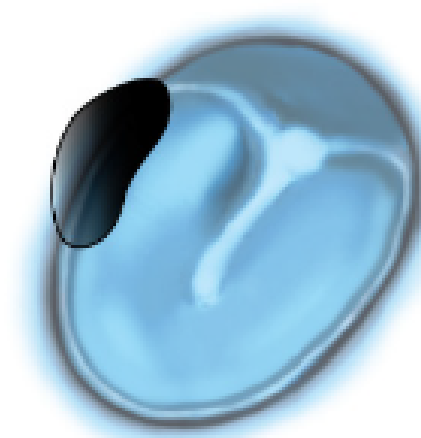Subtotal perforation



Total perforation with  
destruction of even  
the fibrous annulus

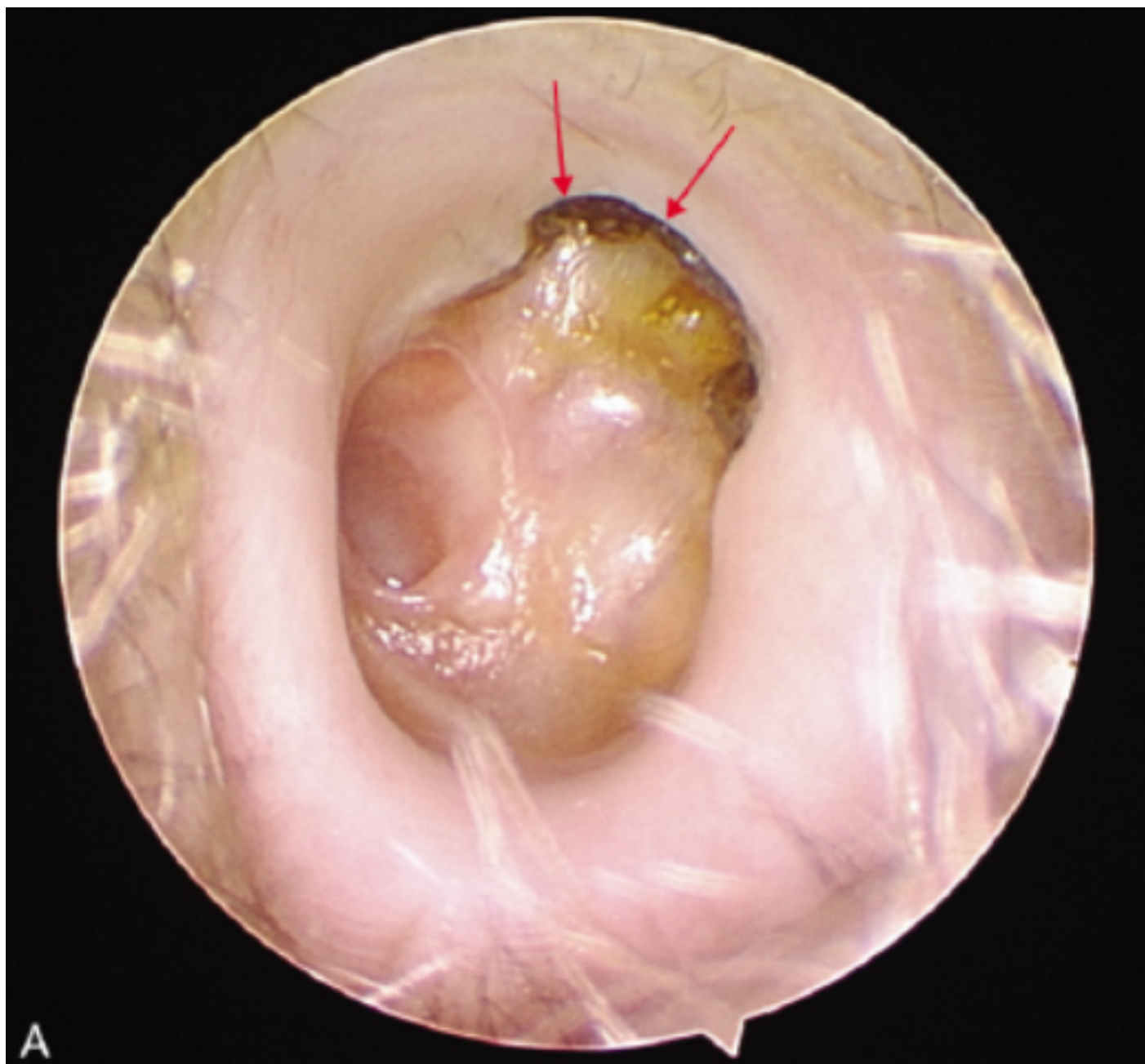


Attic perforation

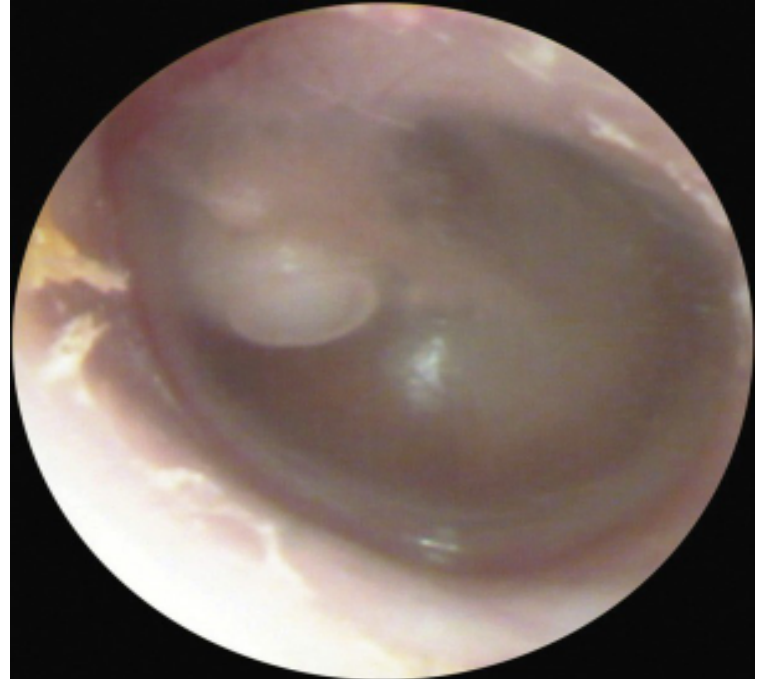
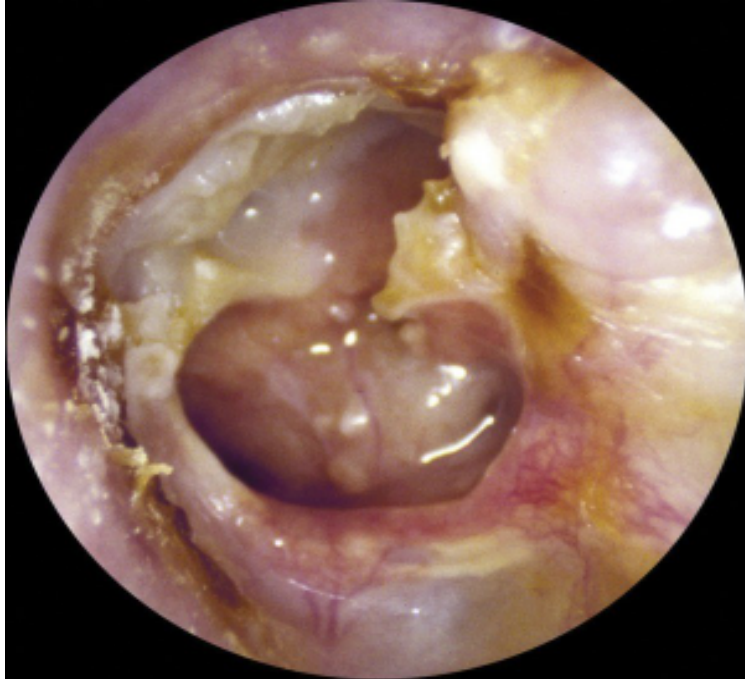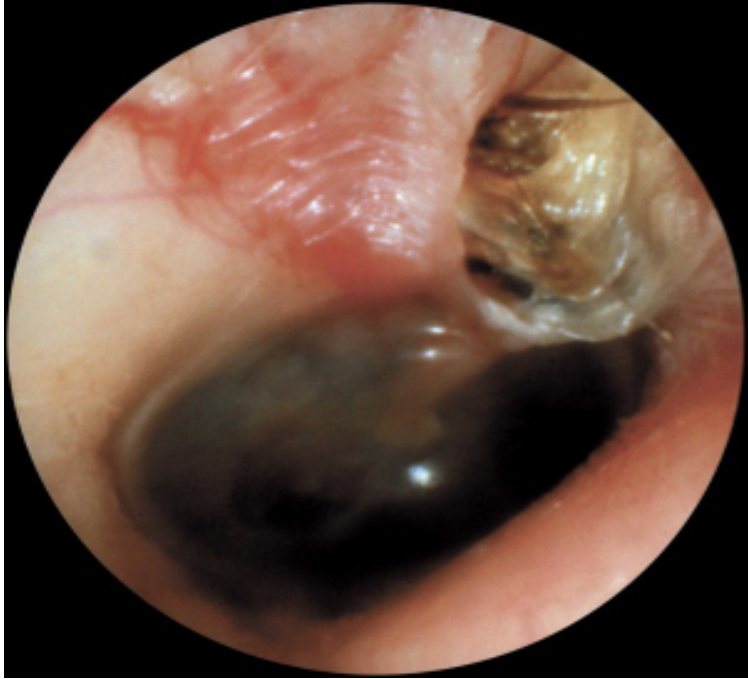


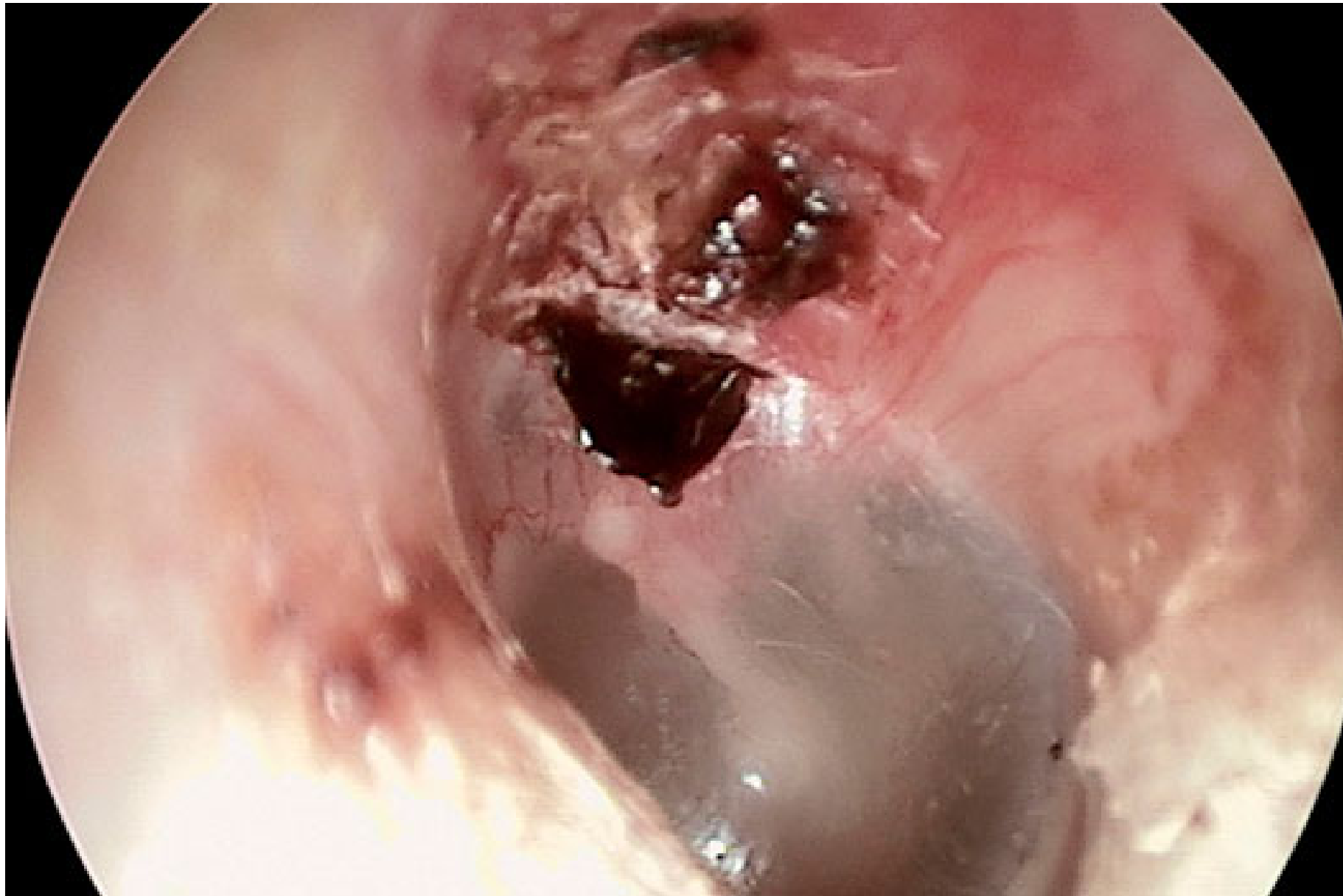
Posterosuperior marginal  
perforation

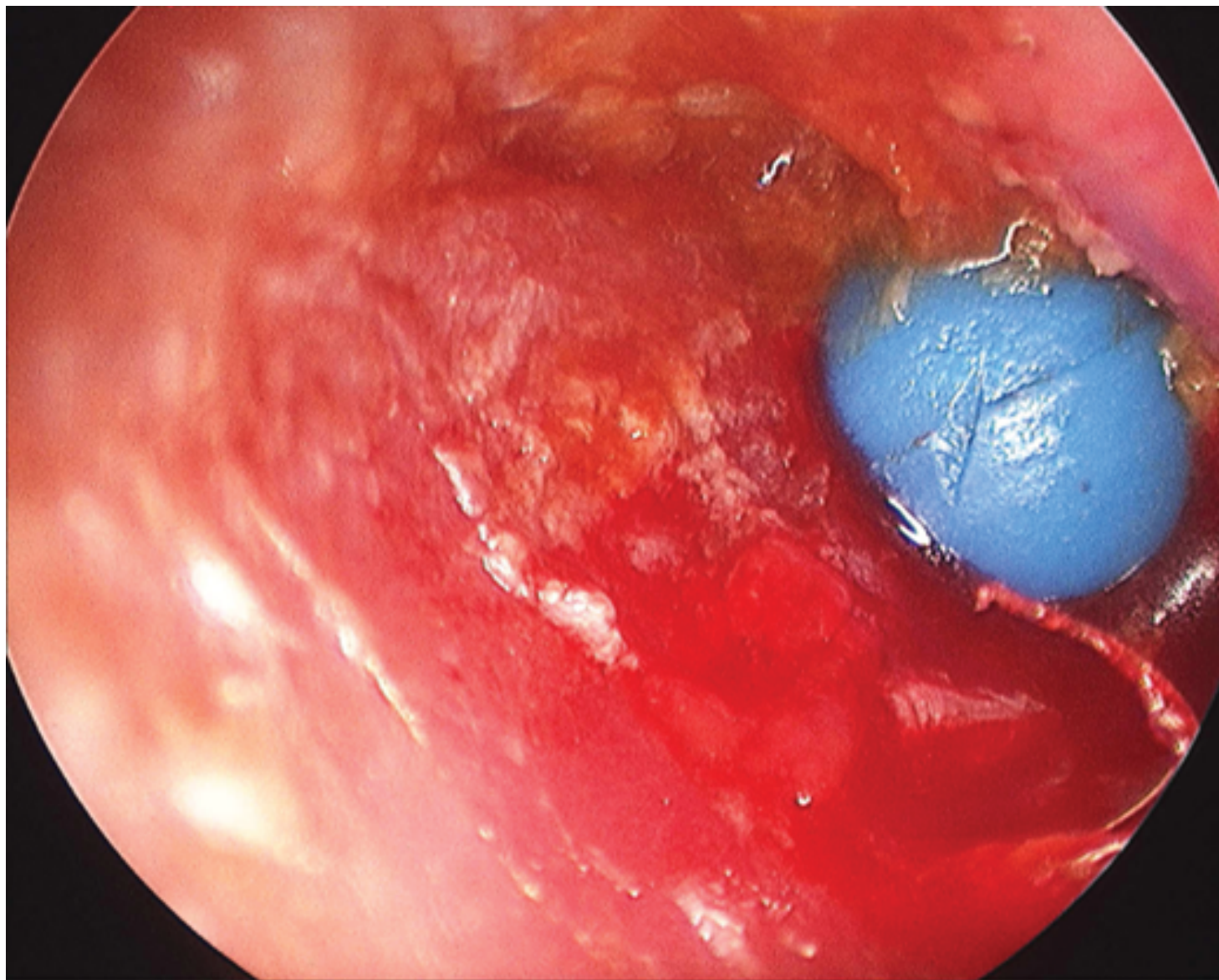






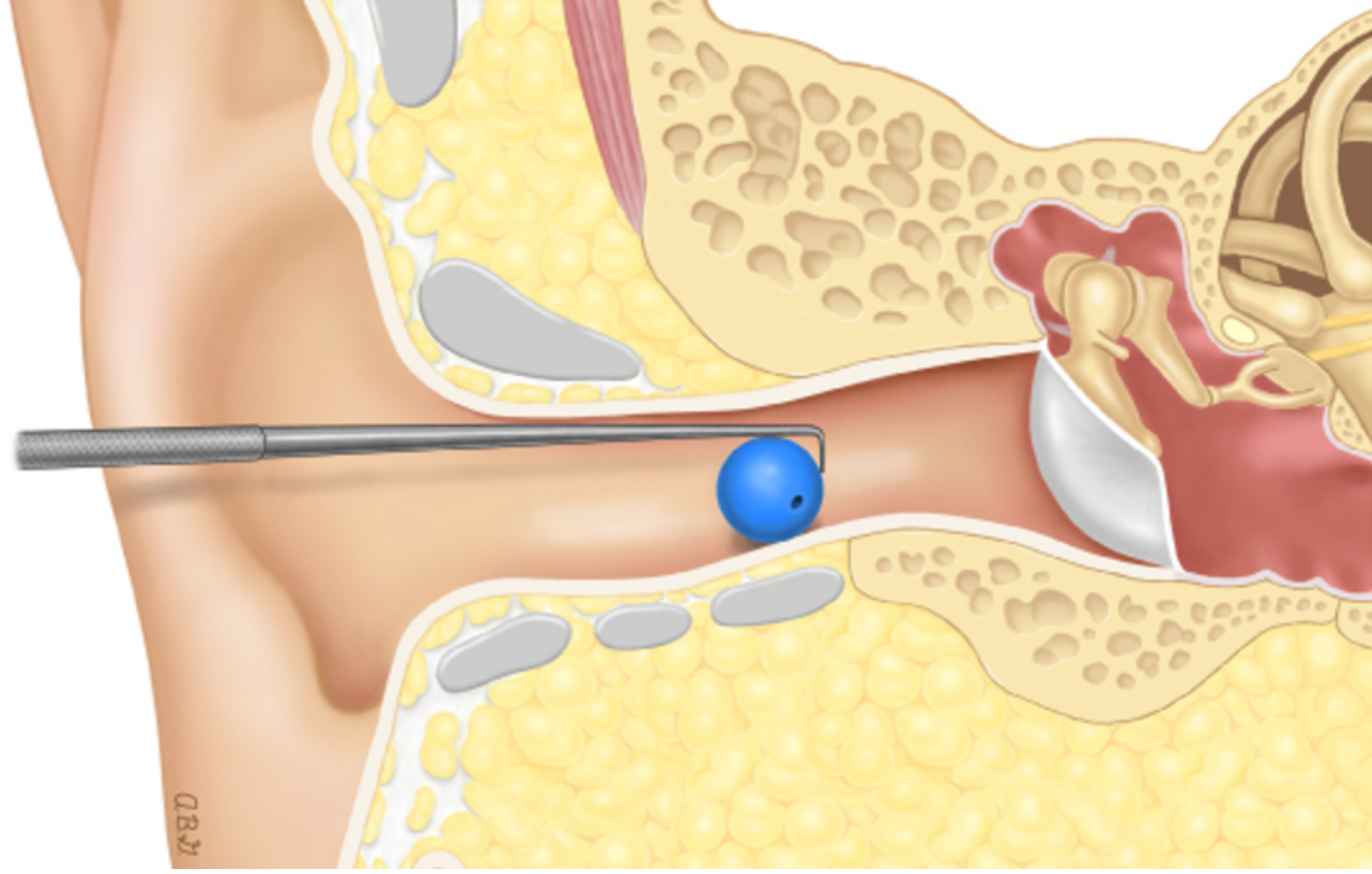


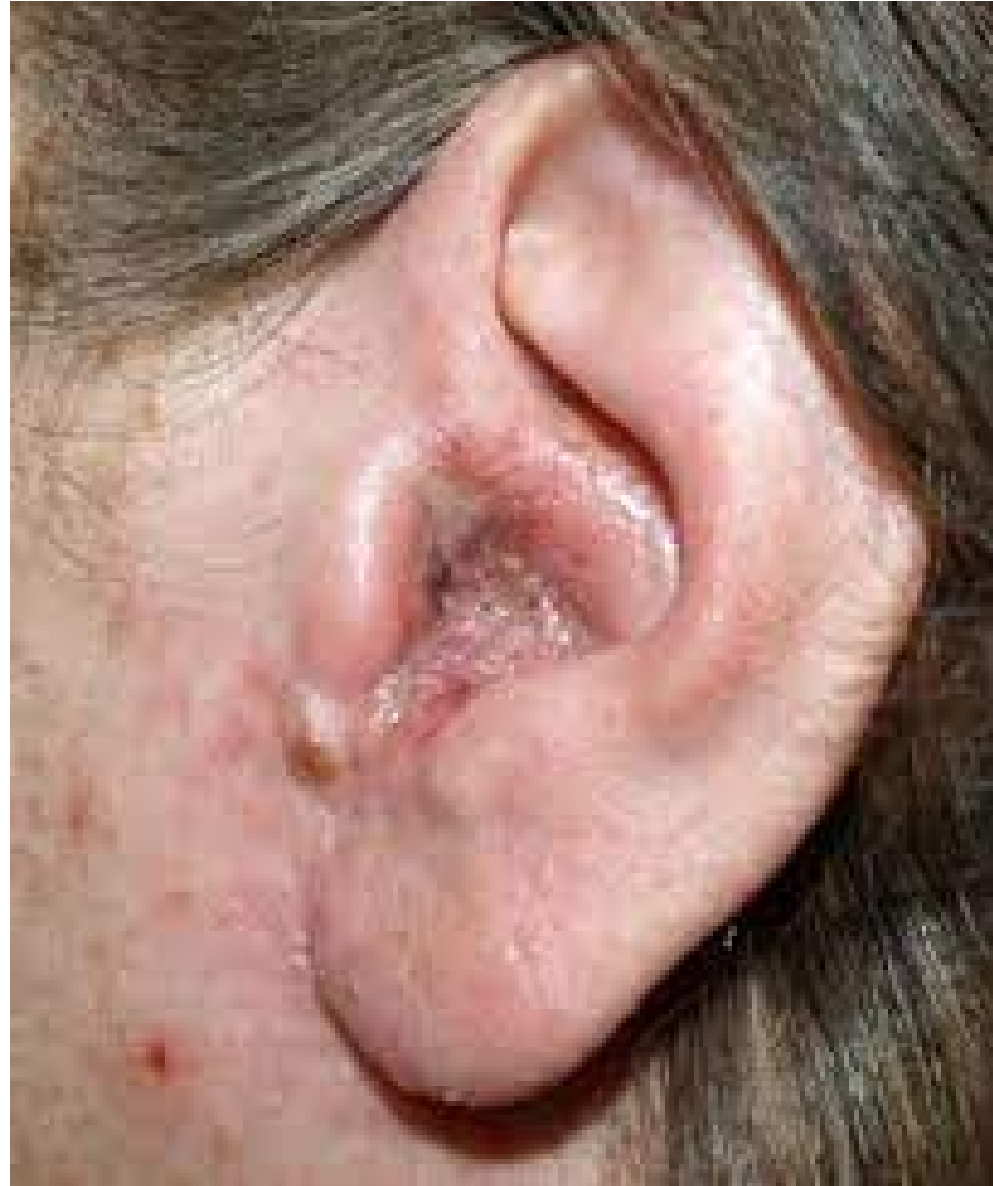



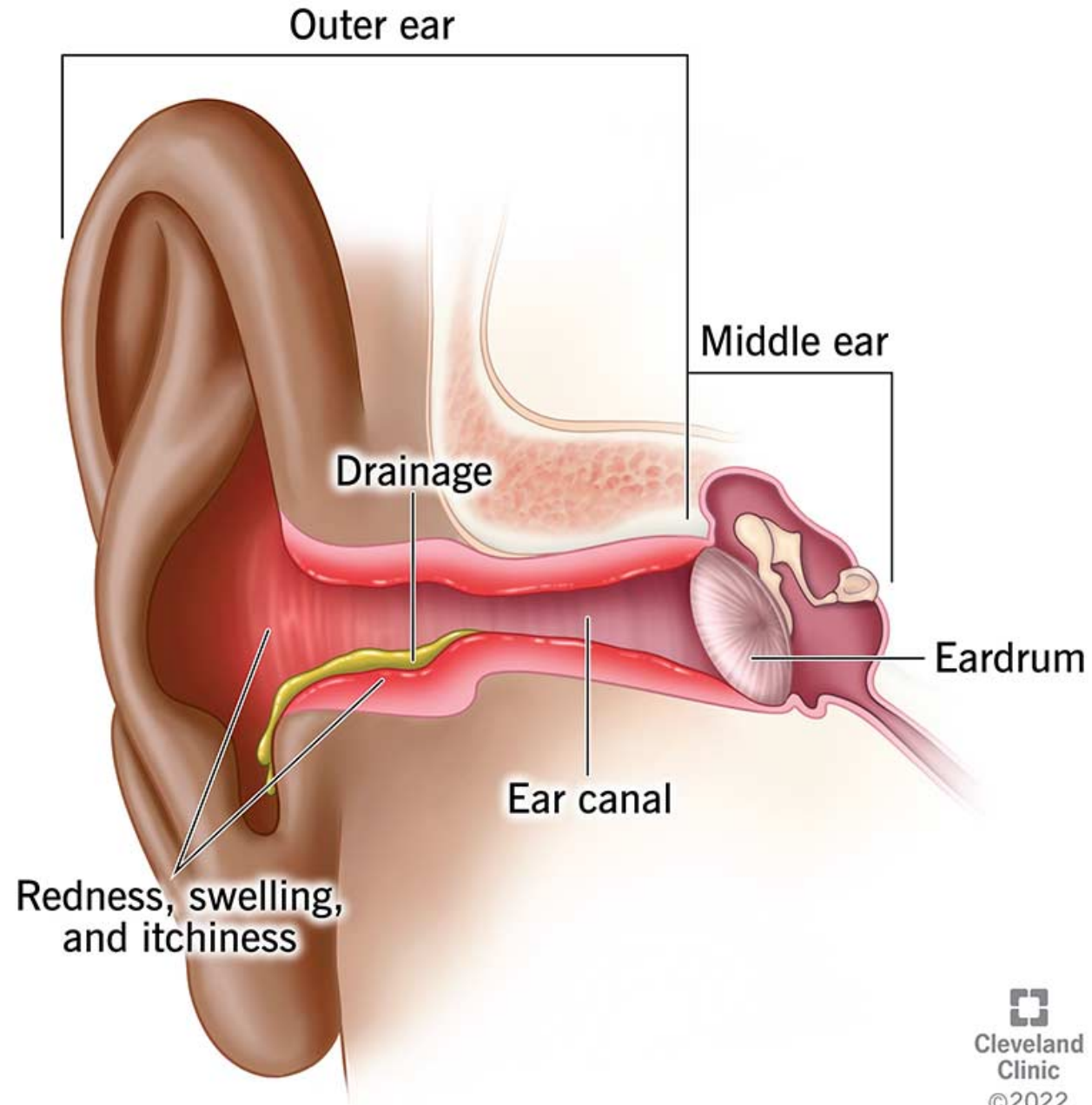
Source: Usatine RP, Smith MA, Mayeaux EJ, Chumley HS: *The Color Atlas of Family Medicine, Second Edition*: [www.accessmedicine.com](http://www.accessmedicine.com)  
Copyright © The McGraw-Hill Companies, Inc. All rights reserved.



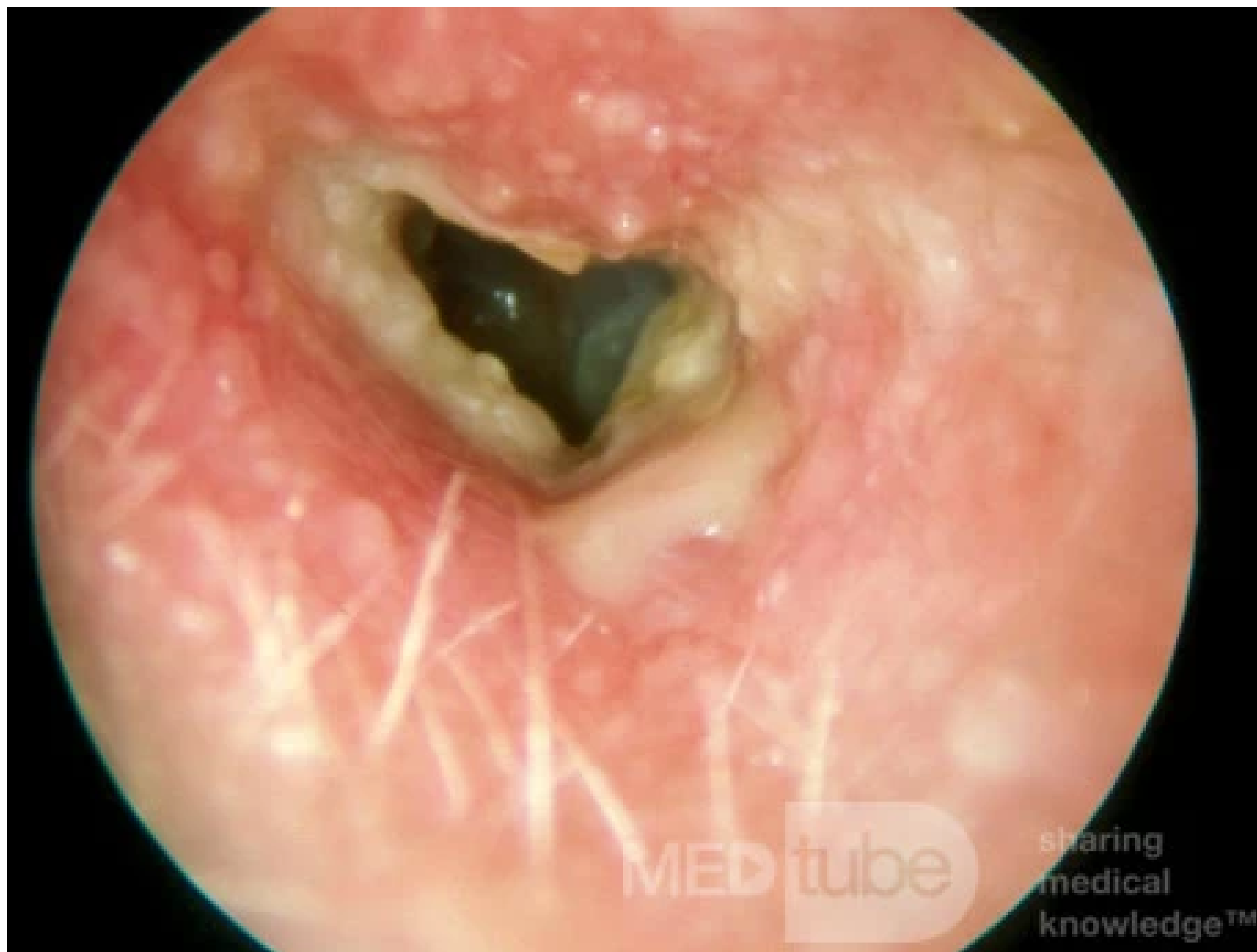


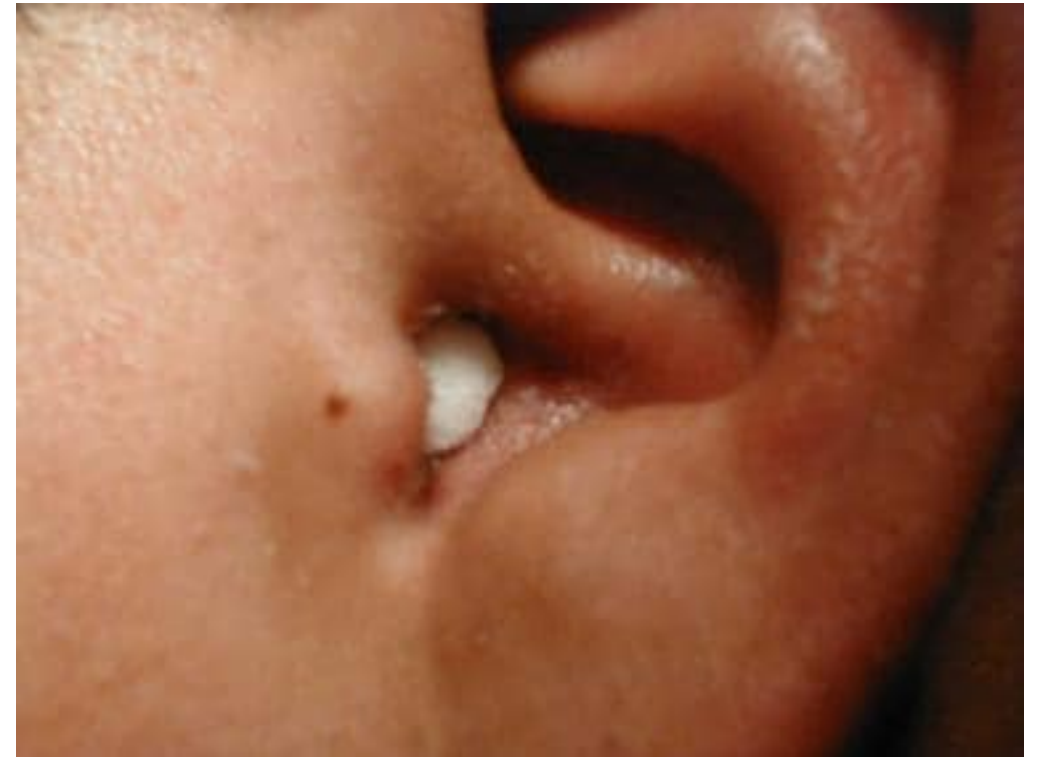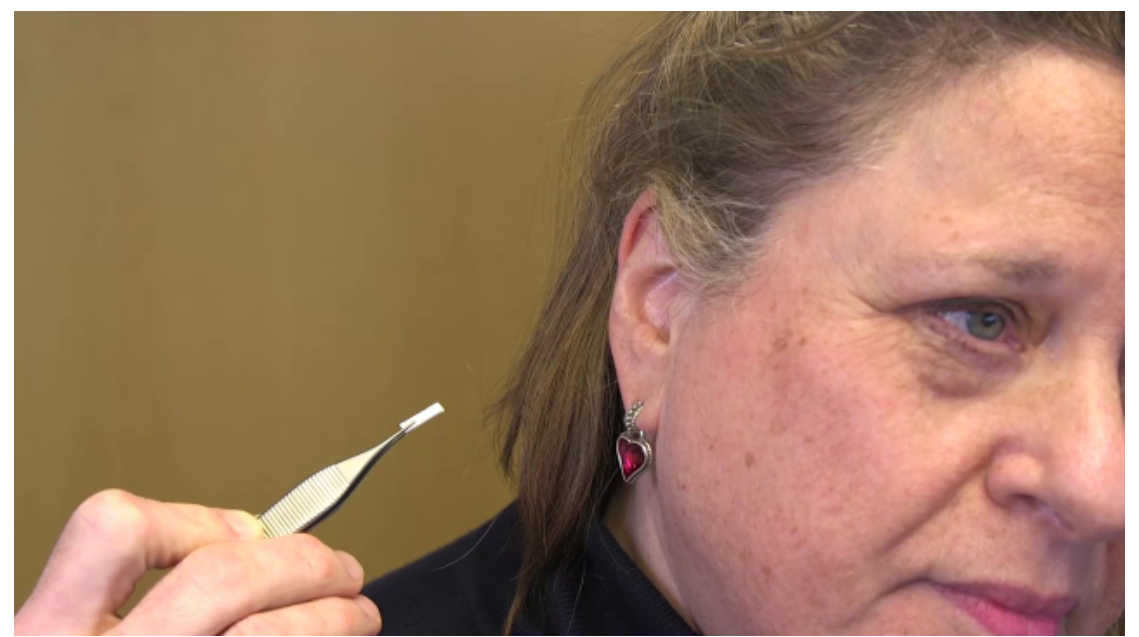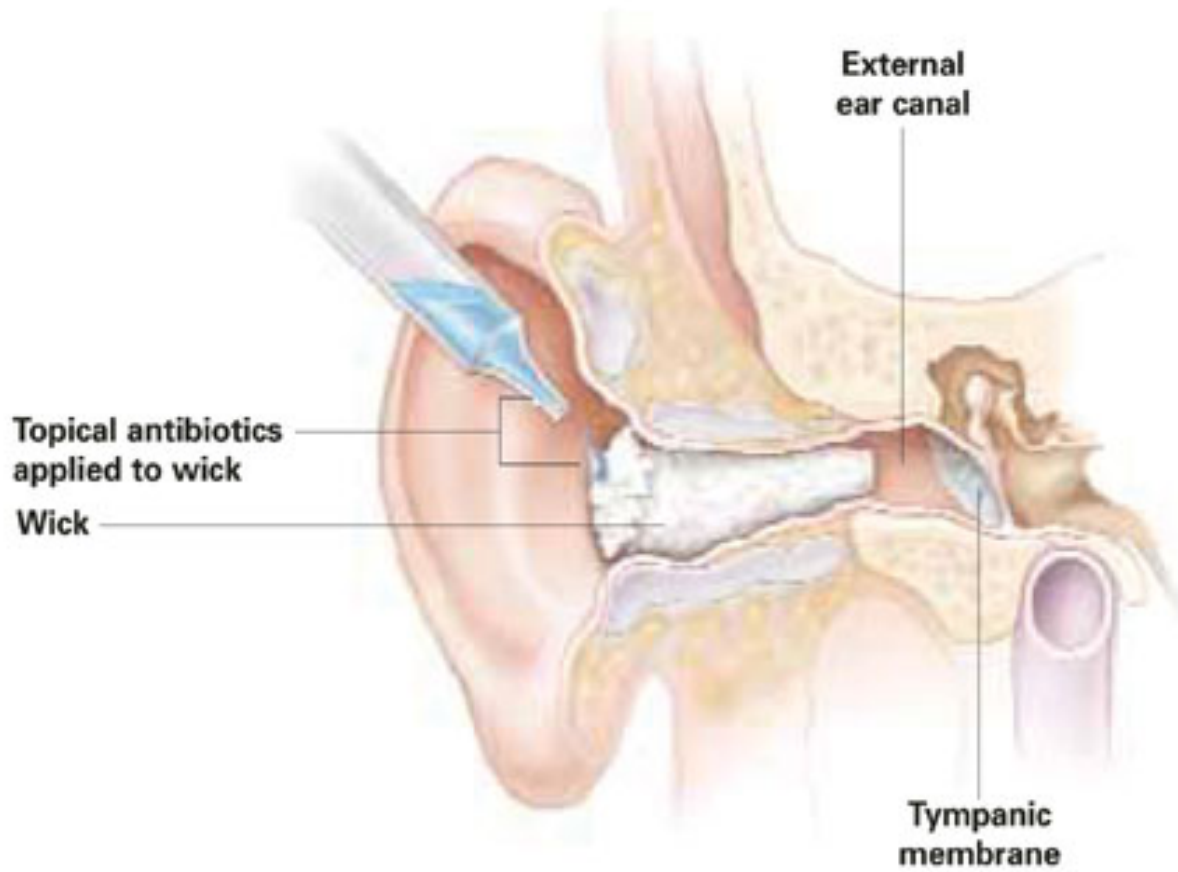


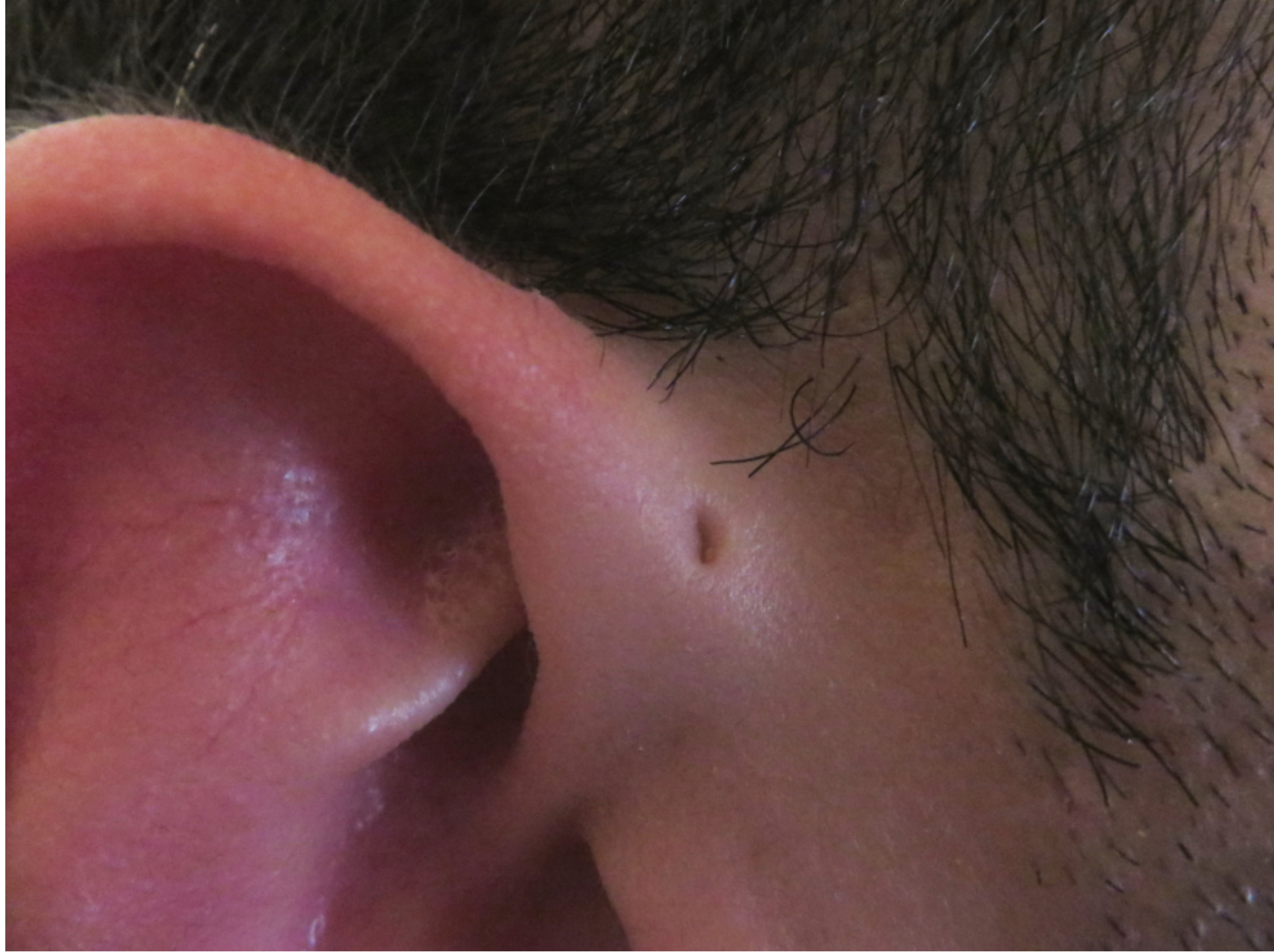# Swimmer's Ear









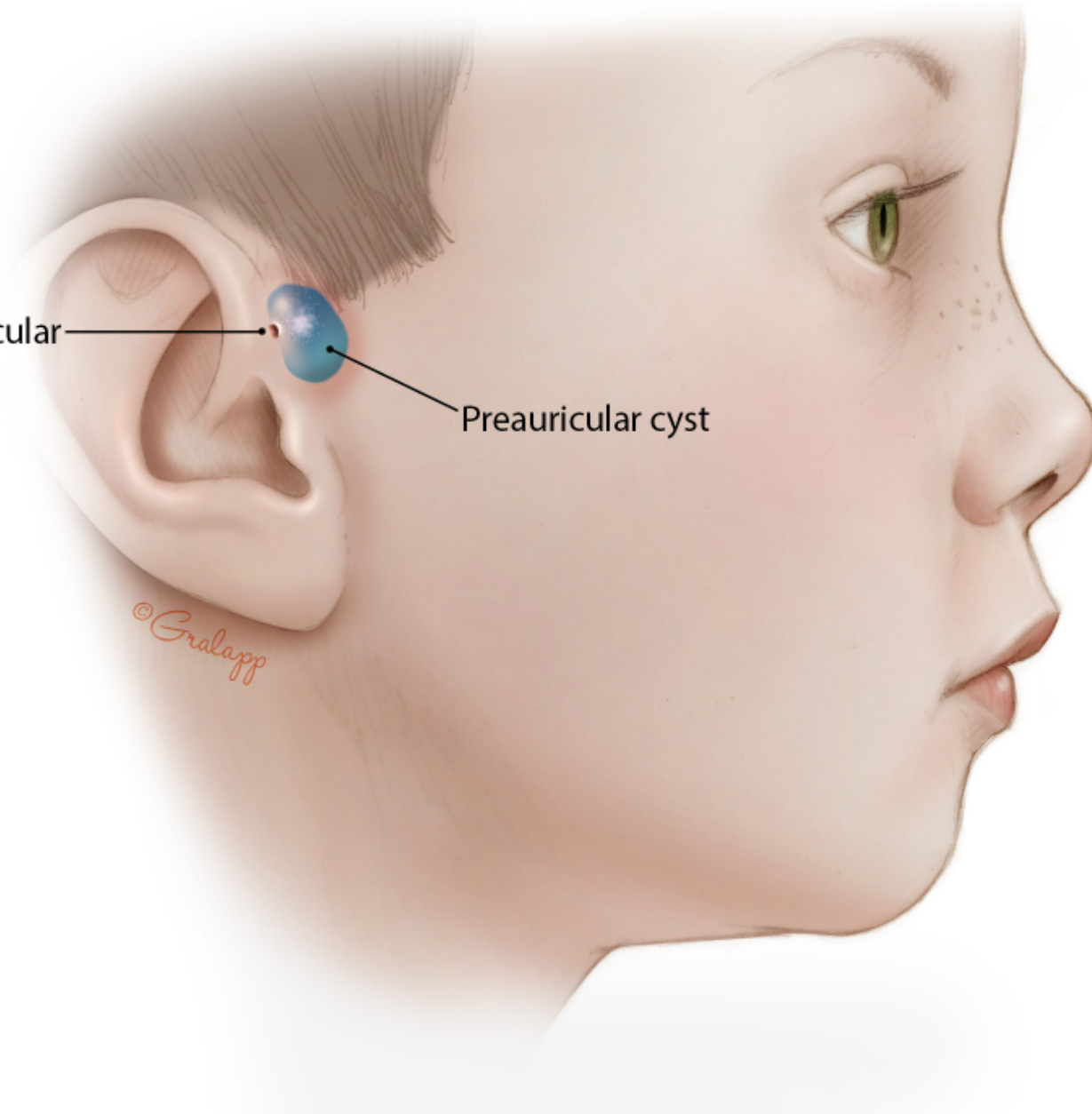




Preauricular  
pit

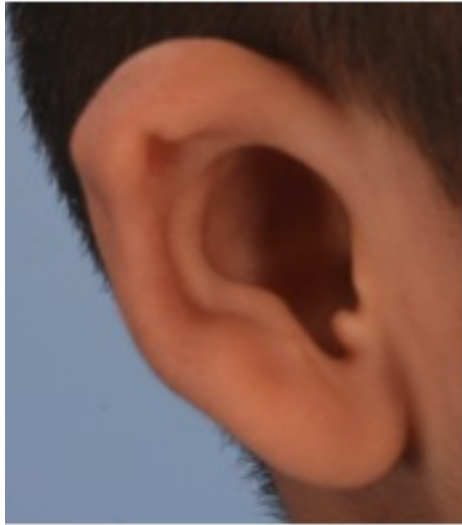Preauricular cyst

©Gralapp

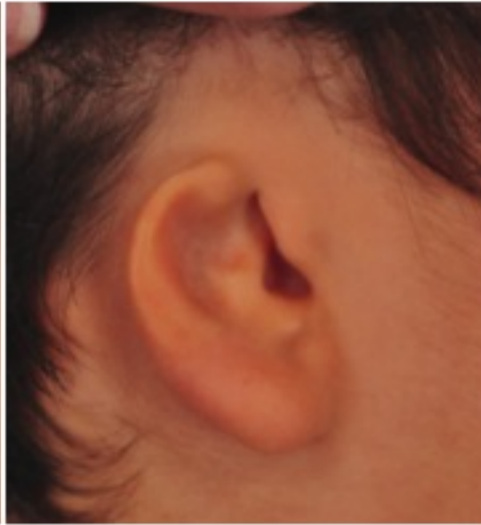

# Spectrum of Microtia Severity

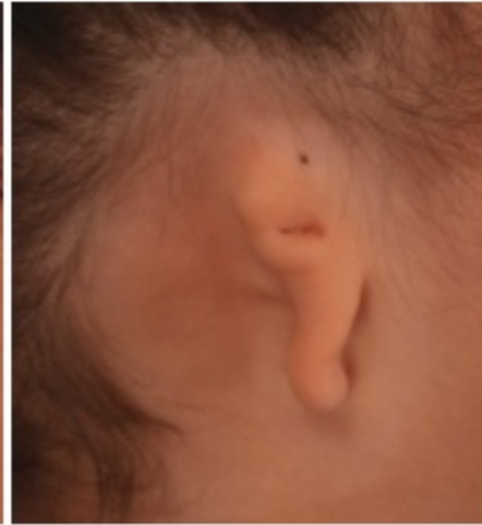Least Severe  Most Severe



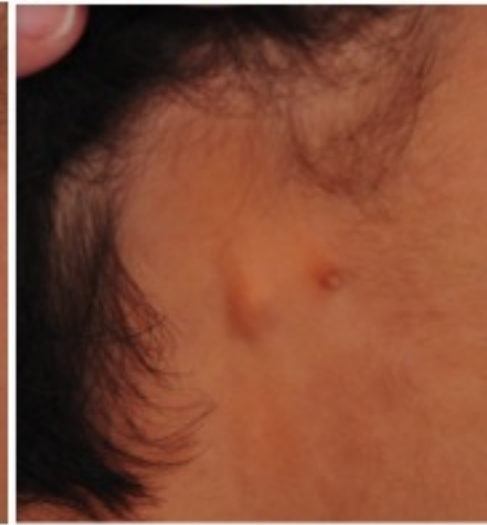The ear is smaller but still looks like an ear because most normal features are present



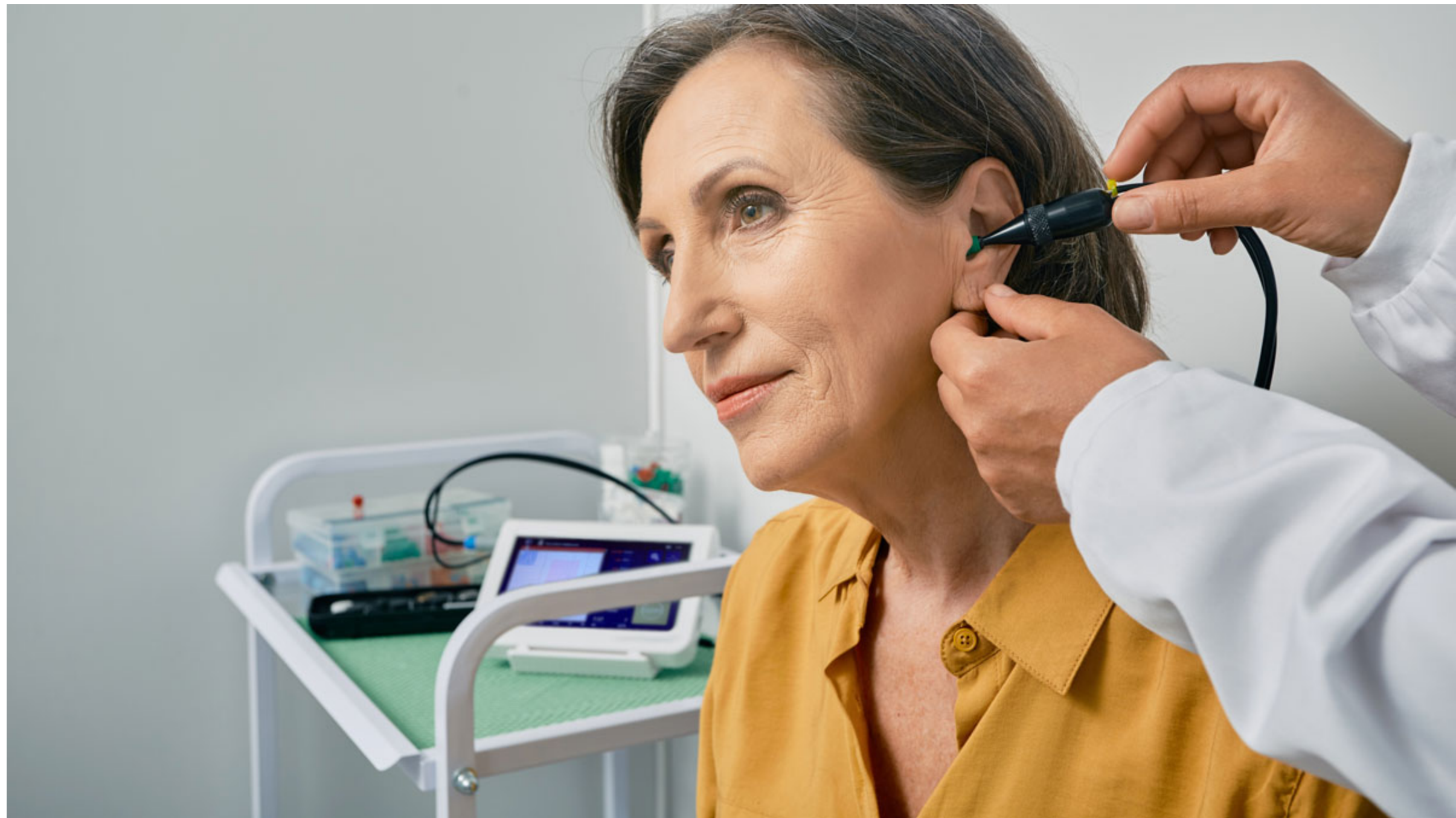Some normal features are present but the upper ear is severely deficient. The canal may be present or absent.



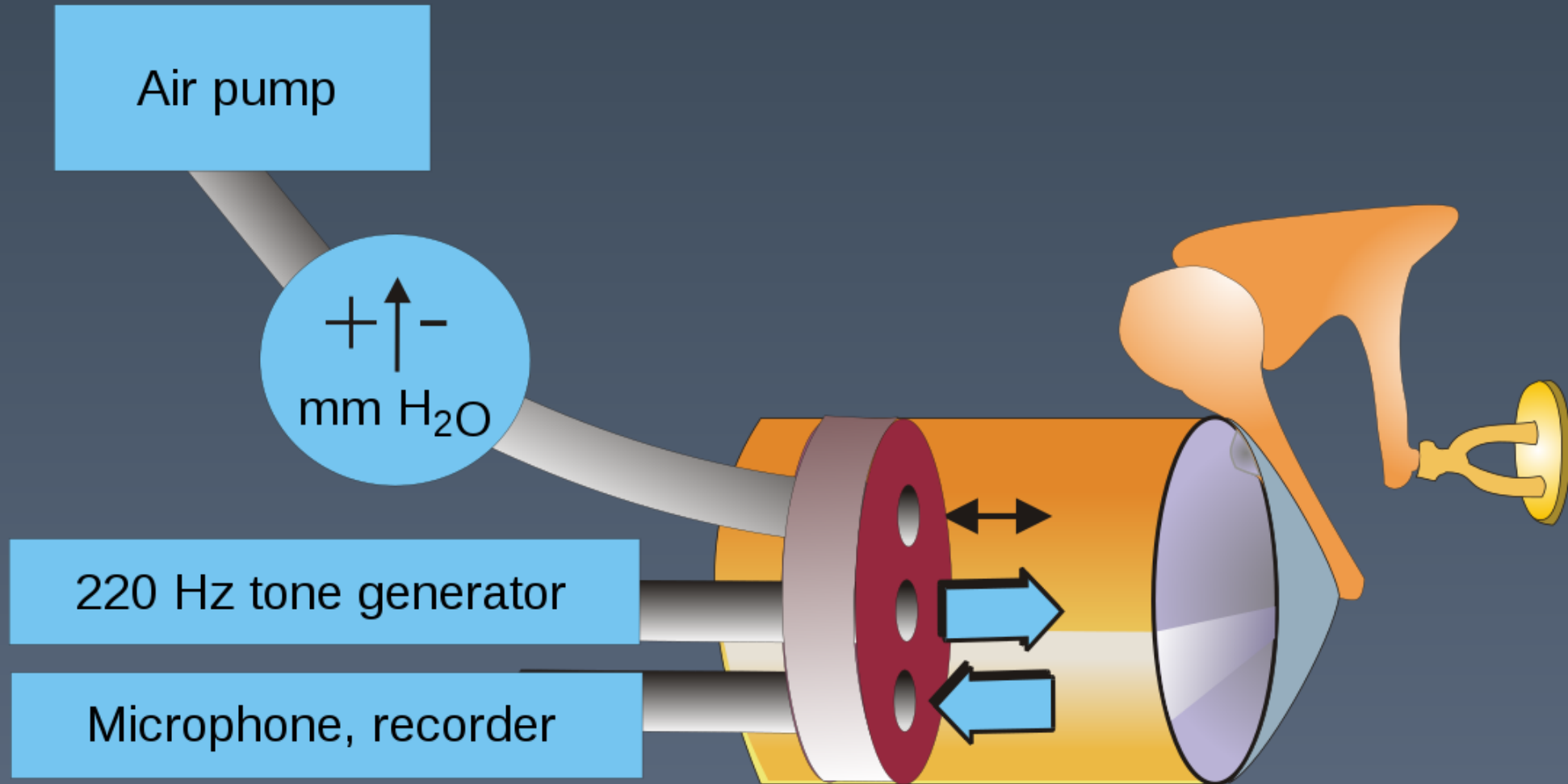
A small piece of cartilage is present just above the ear lobe which is displaced upward and forward. The canal is almost always absent.



Anotia is when there is a complete absence of the ear and canal.

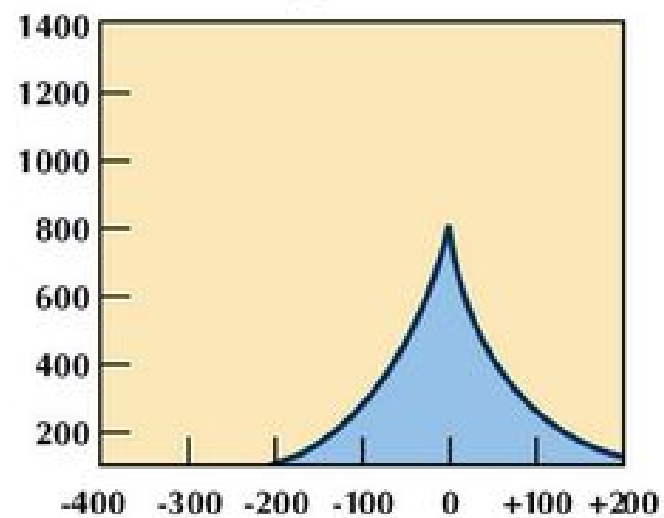


# Tympanometry

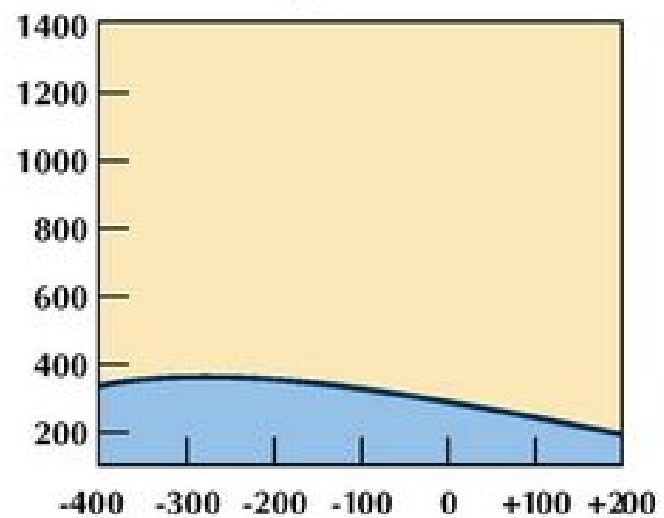




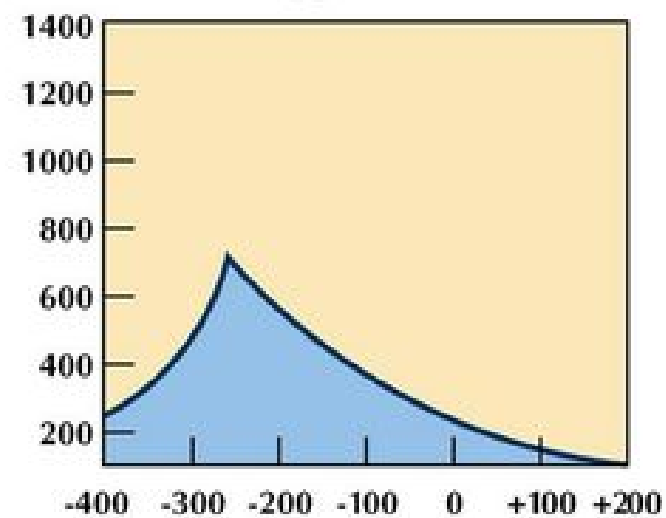
**Type A**



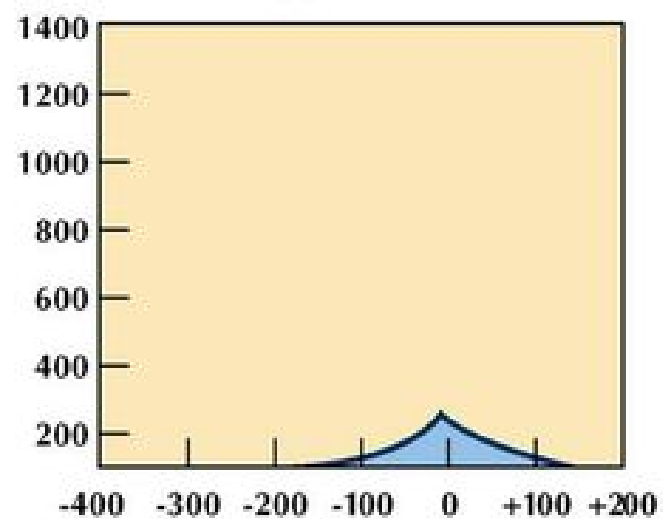
**Type B**



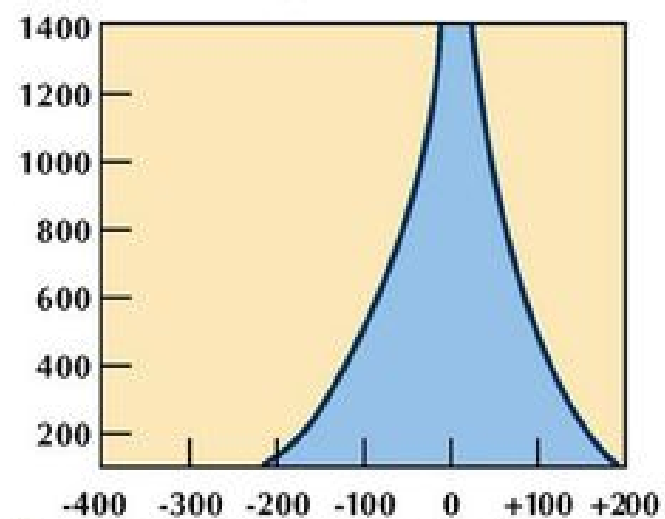
**Type C**



**Type As**

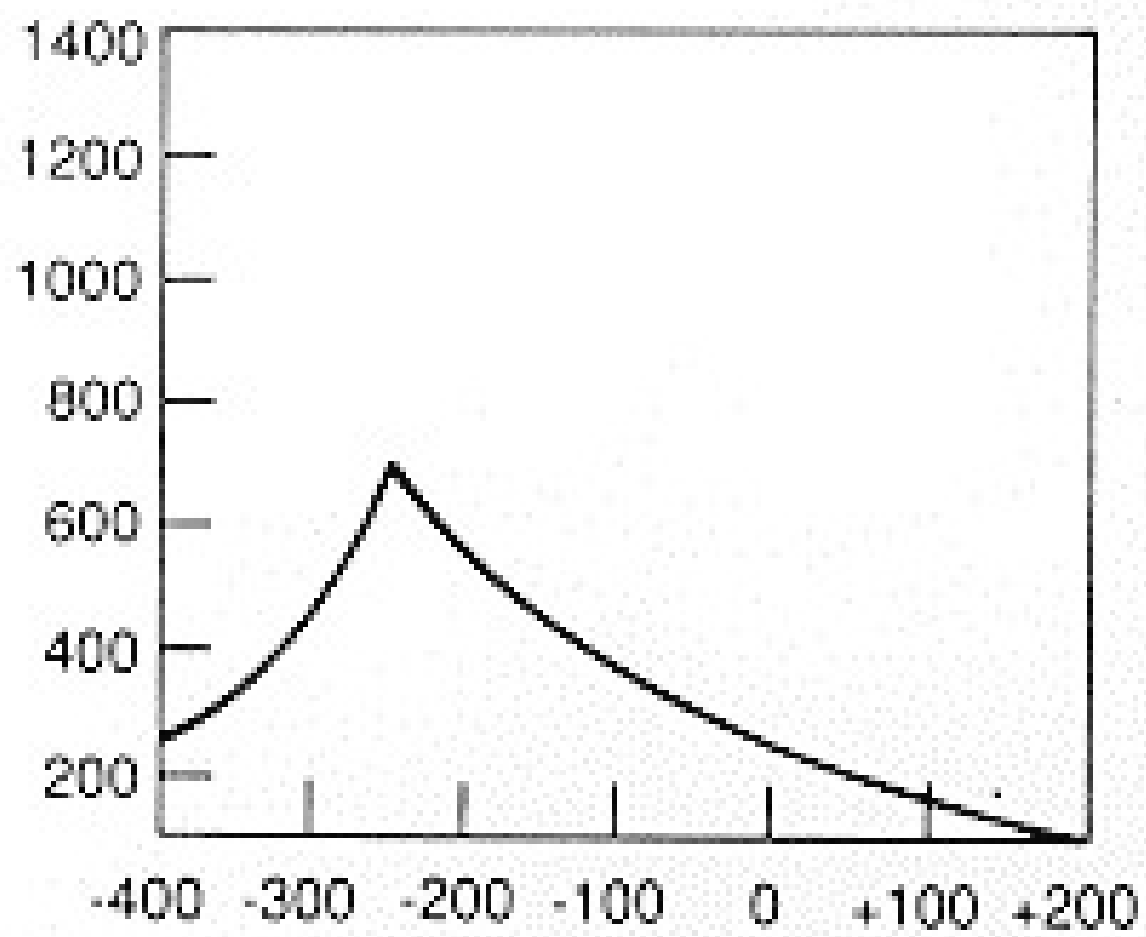


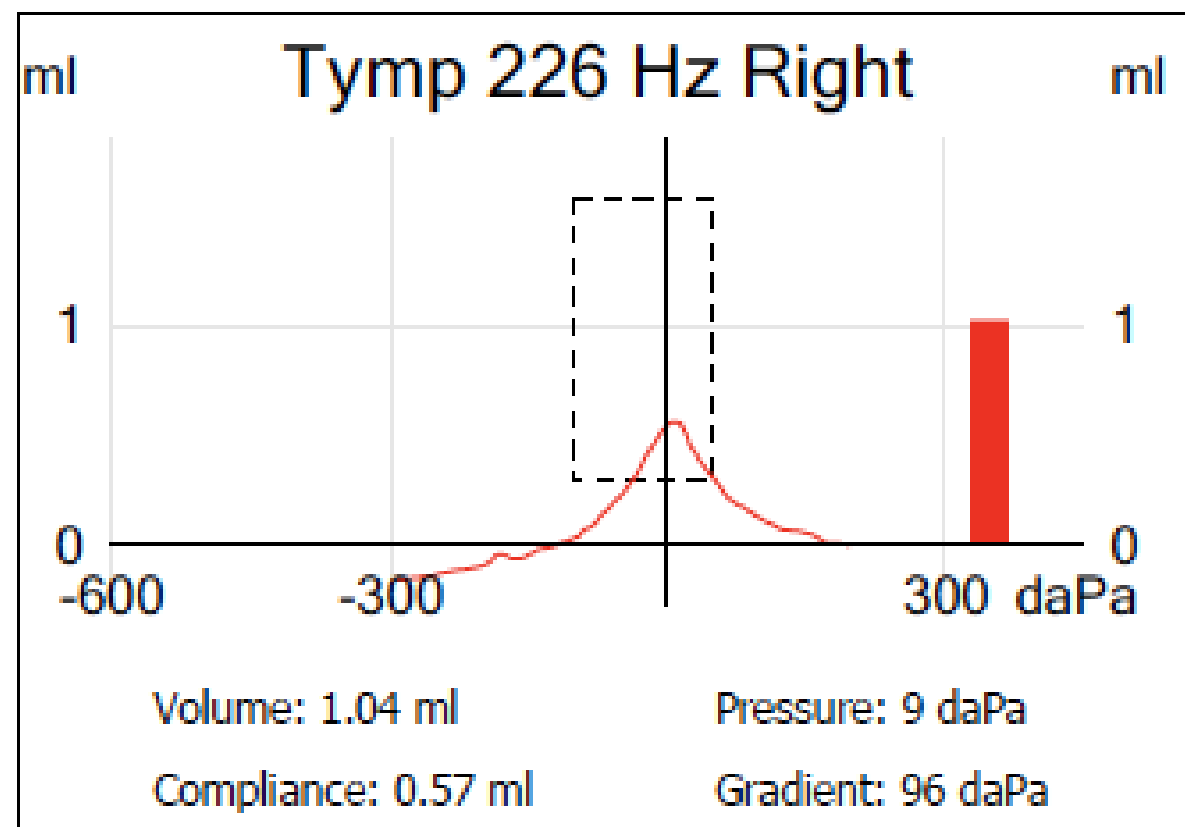
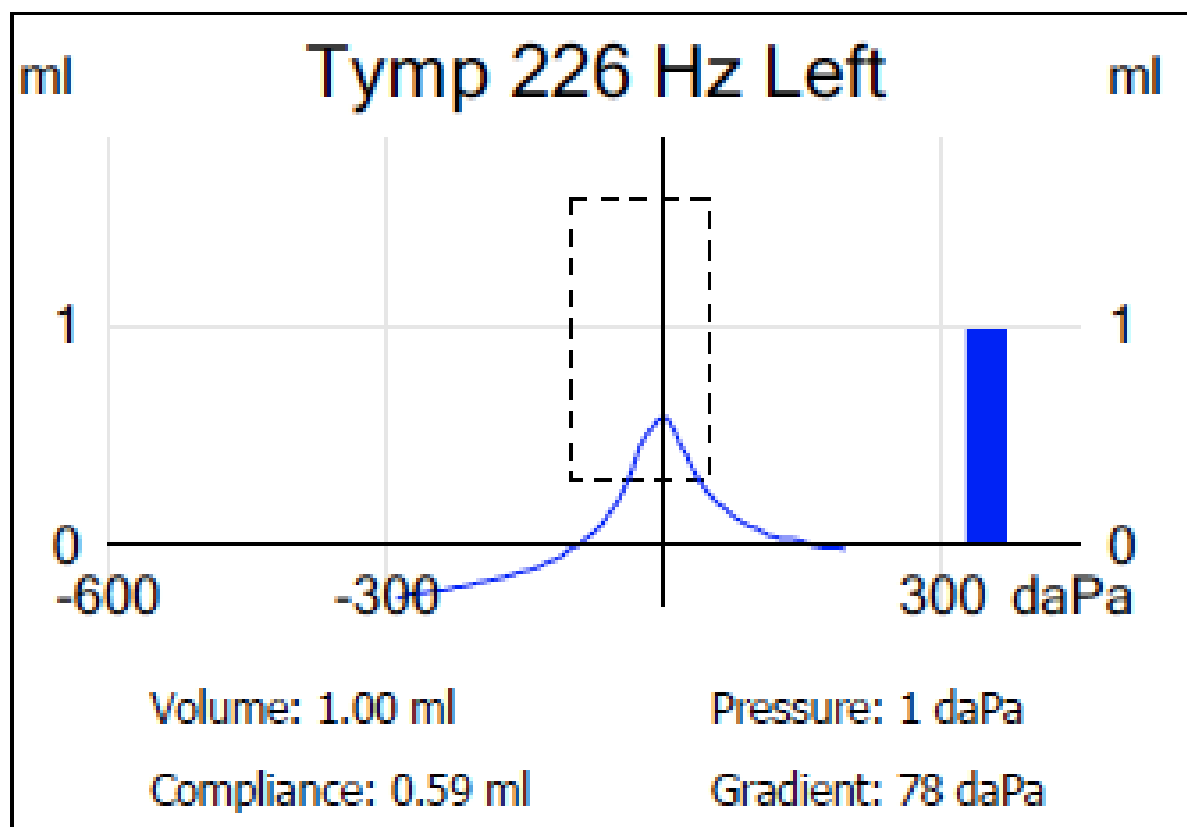
**Type Ad**

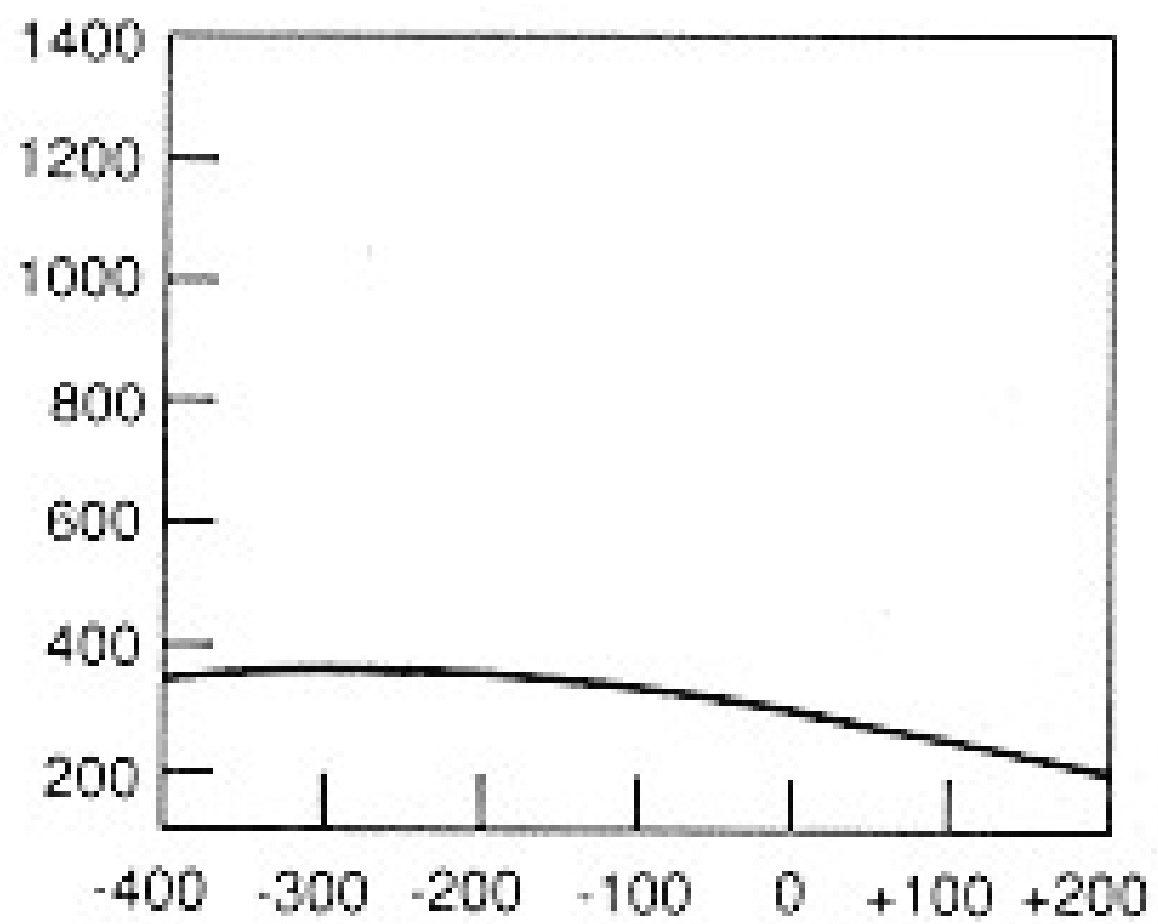


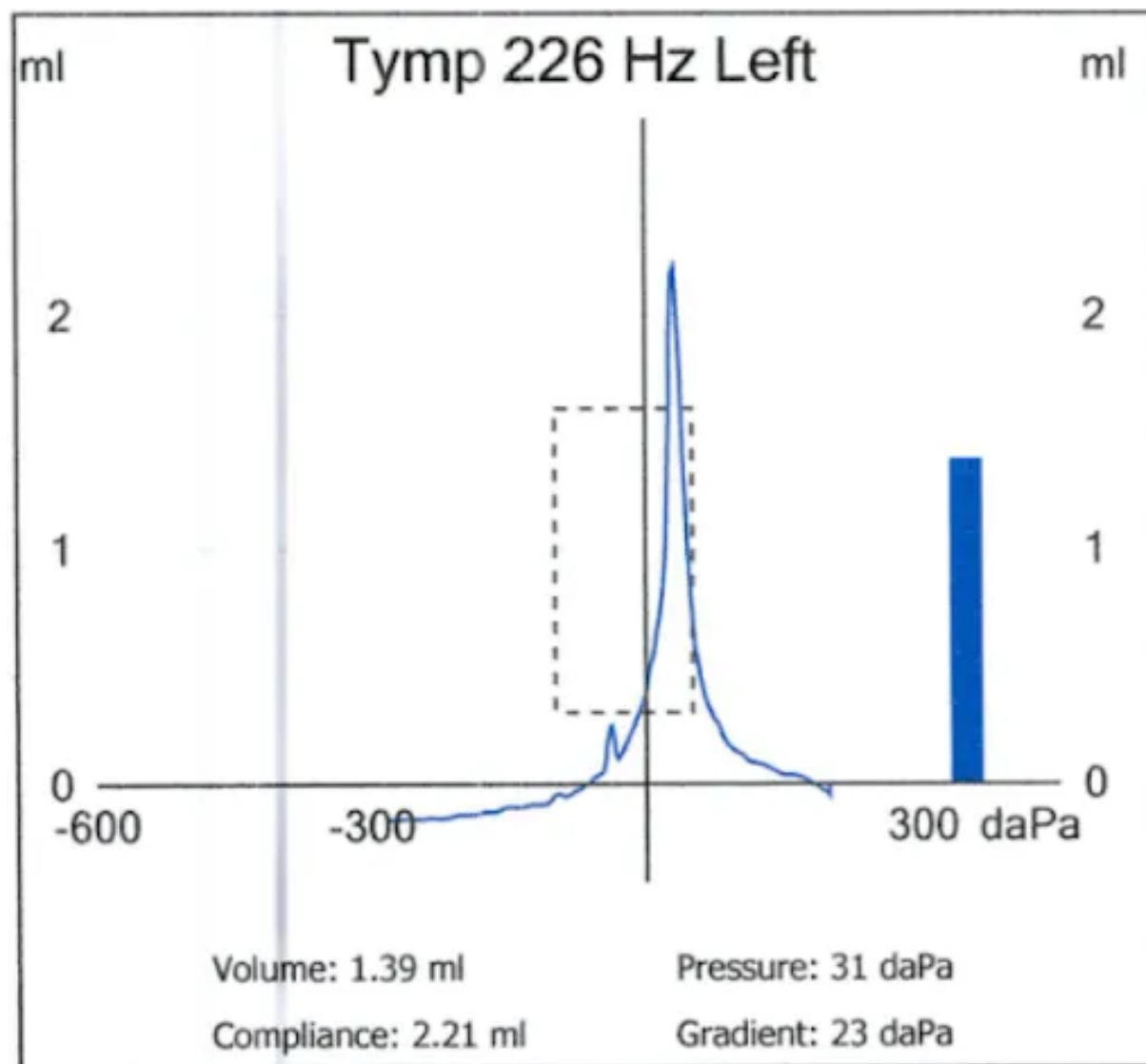
Type A	Indicative of normal middle-ear function
Type As	Indicates a less 'compliant' middle-ear system; can indicate otosclerosis
Type Ad	Indicates a highly 'compliant' middle-ear system; can indicate ossicular chain discontinuity
Type B	Consistent with middle-ear pathology such as fluid or infection (low volume) or perforation (if high volume)
Type C	Consistent with Eustachian tube dysfunction which is commonly associated with nasal conditions such as allergies or upper respiratory tract infection

Type C

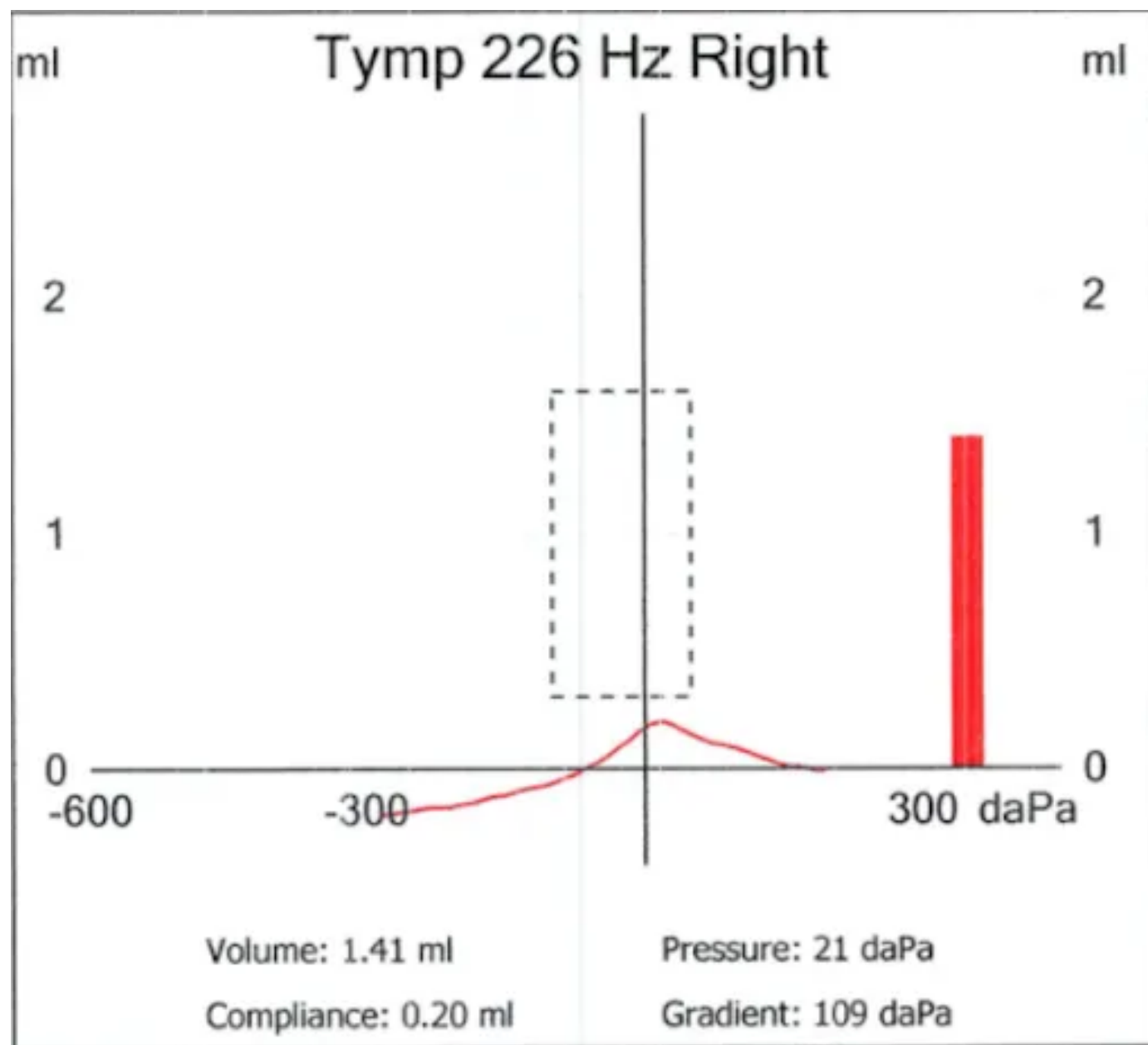


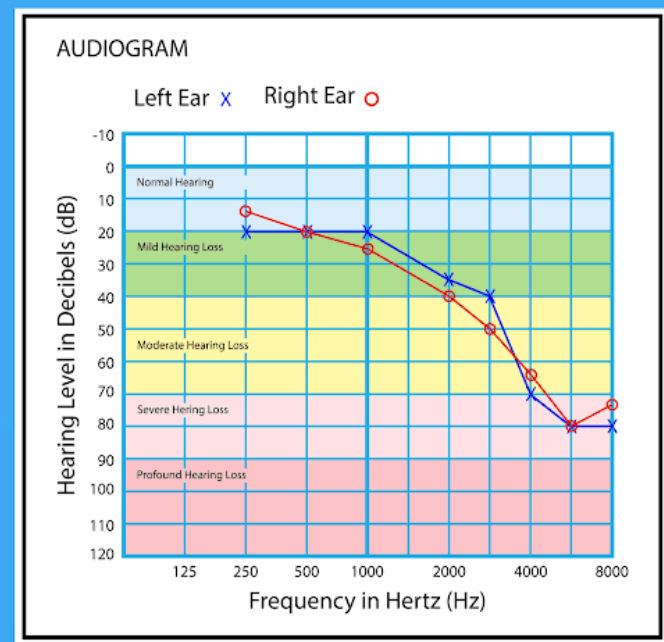


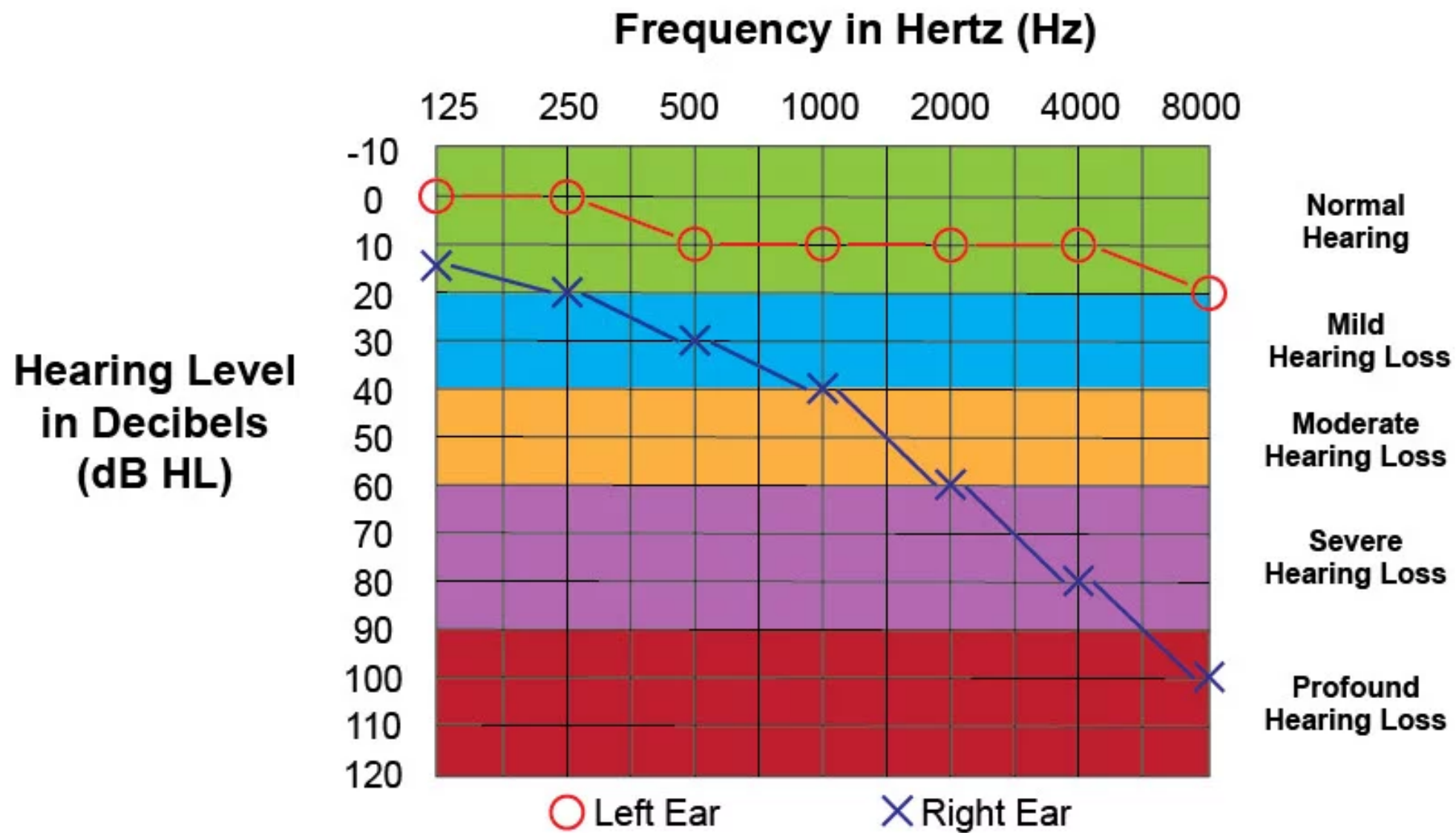




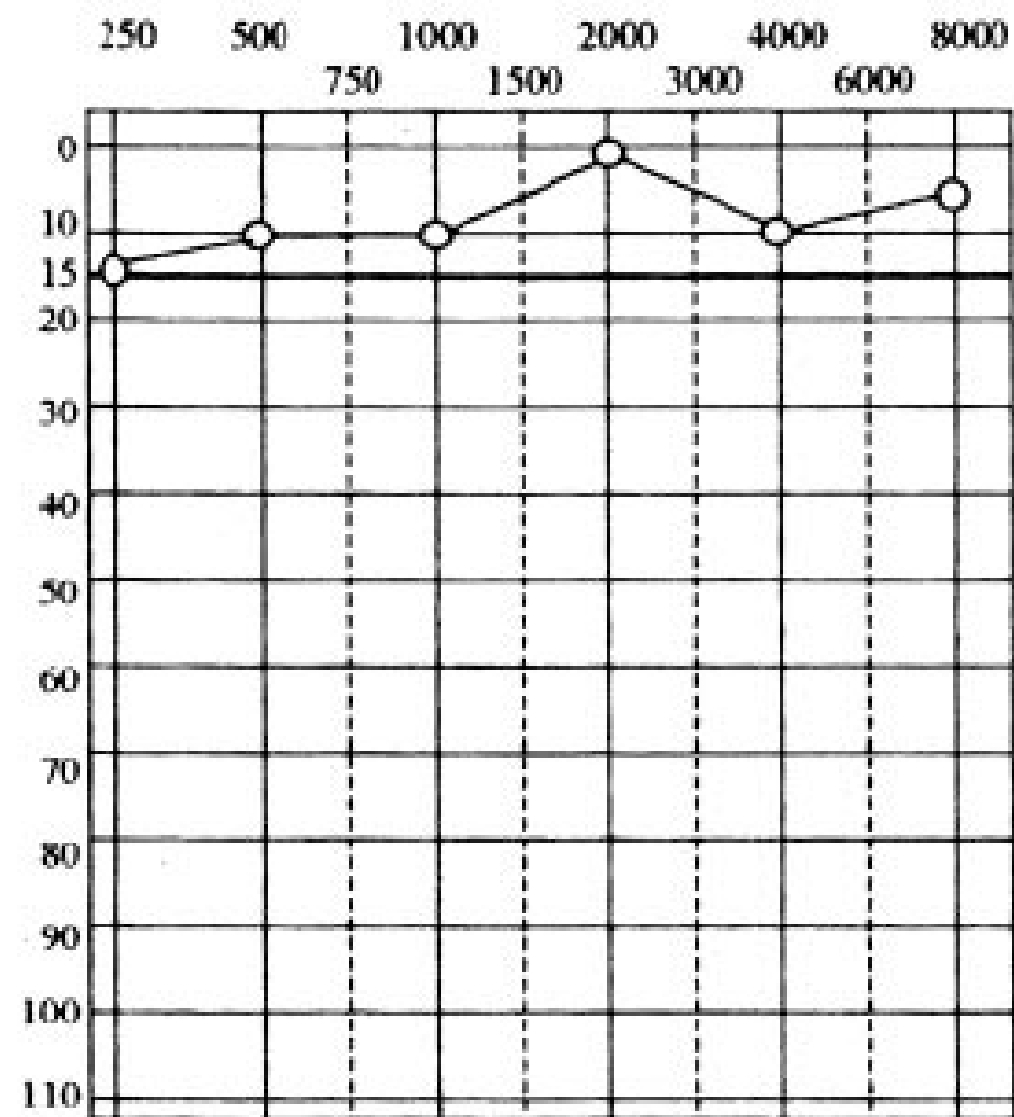




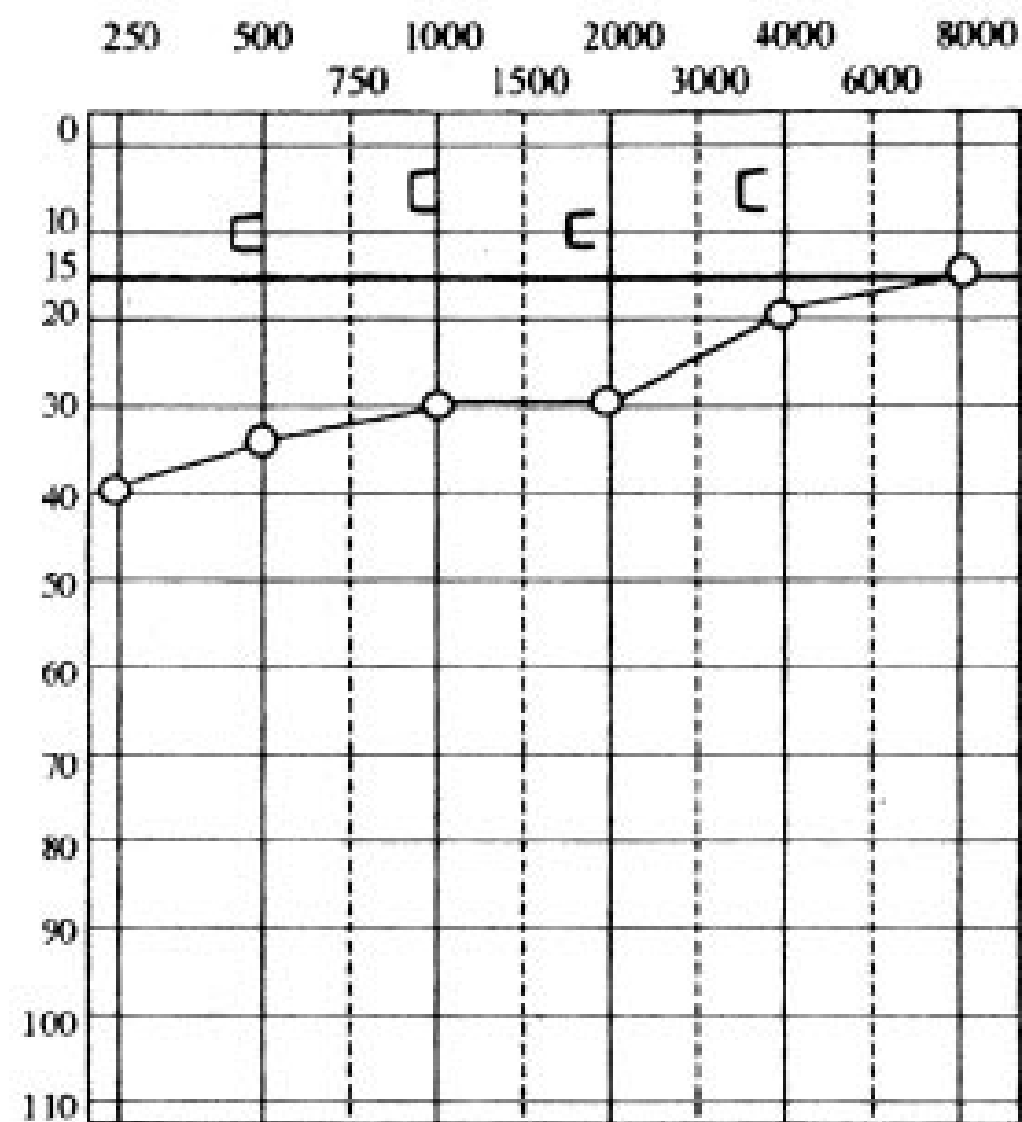




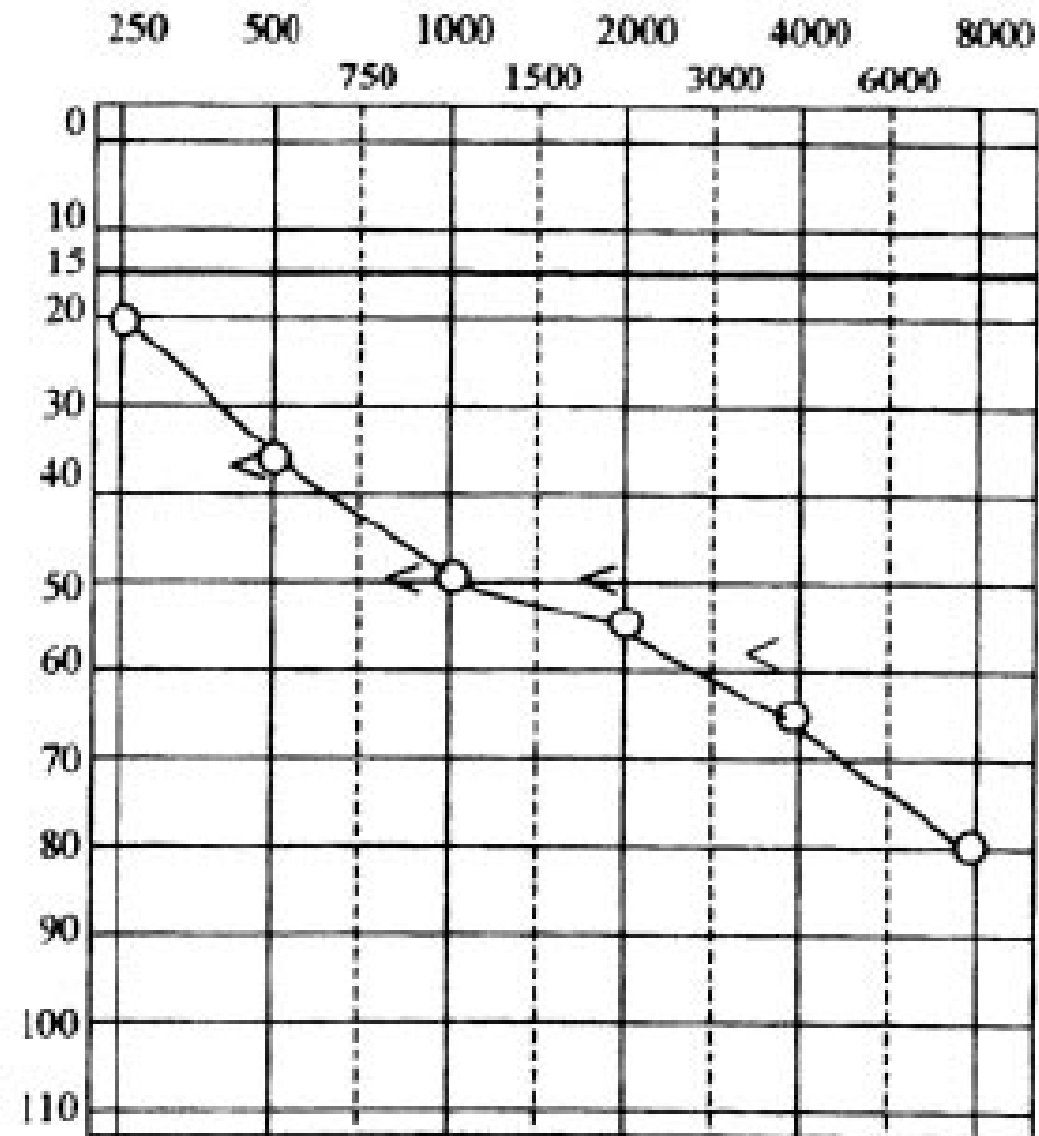
### A. Normal Hearing



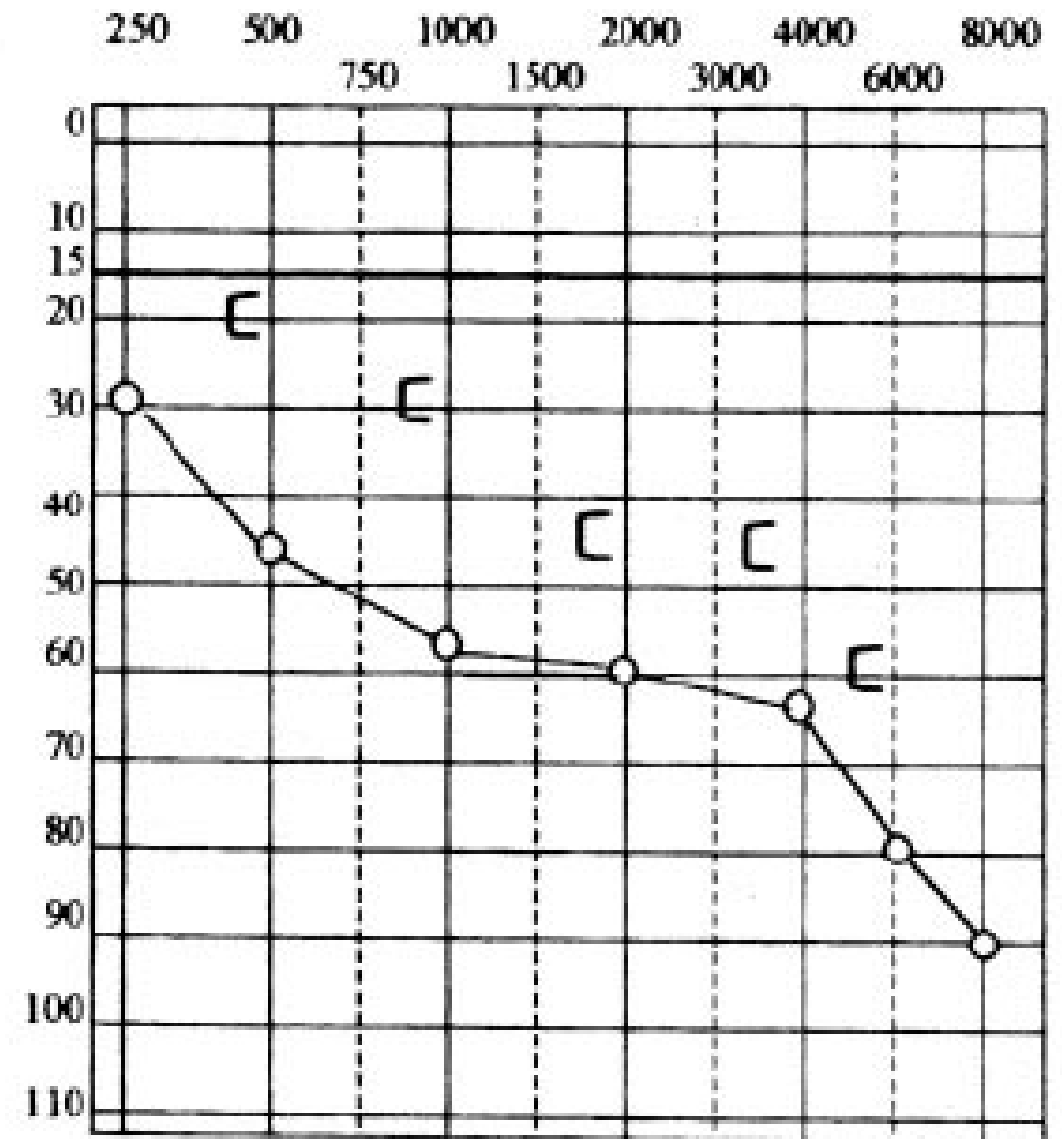
### B. Conductive hearing loss



### C. Sensorineural hearing loss

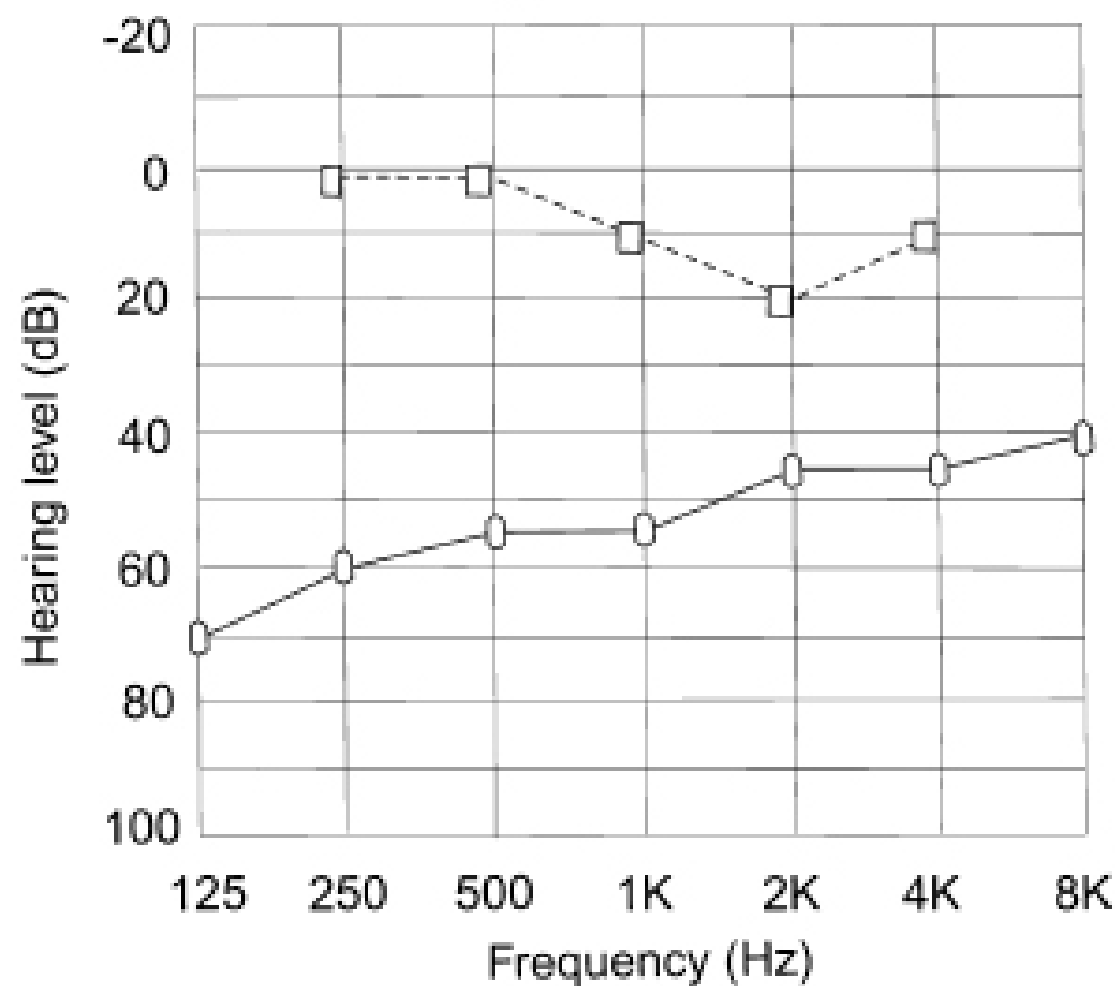


### D. Mixed hearing loss



## Otosclerosis

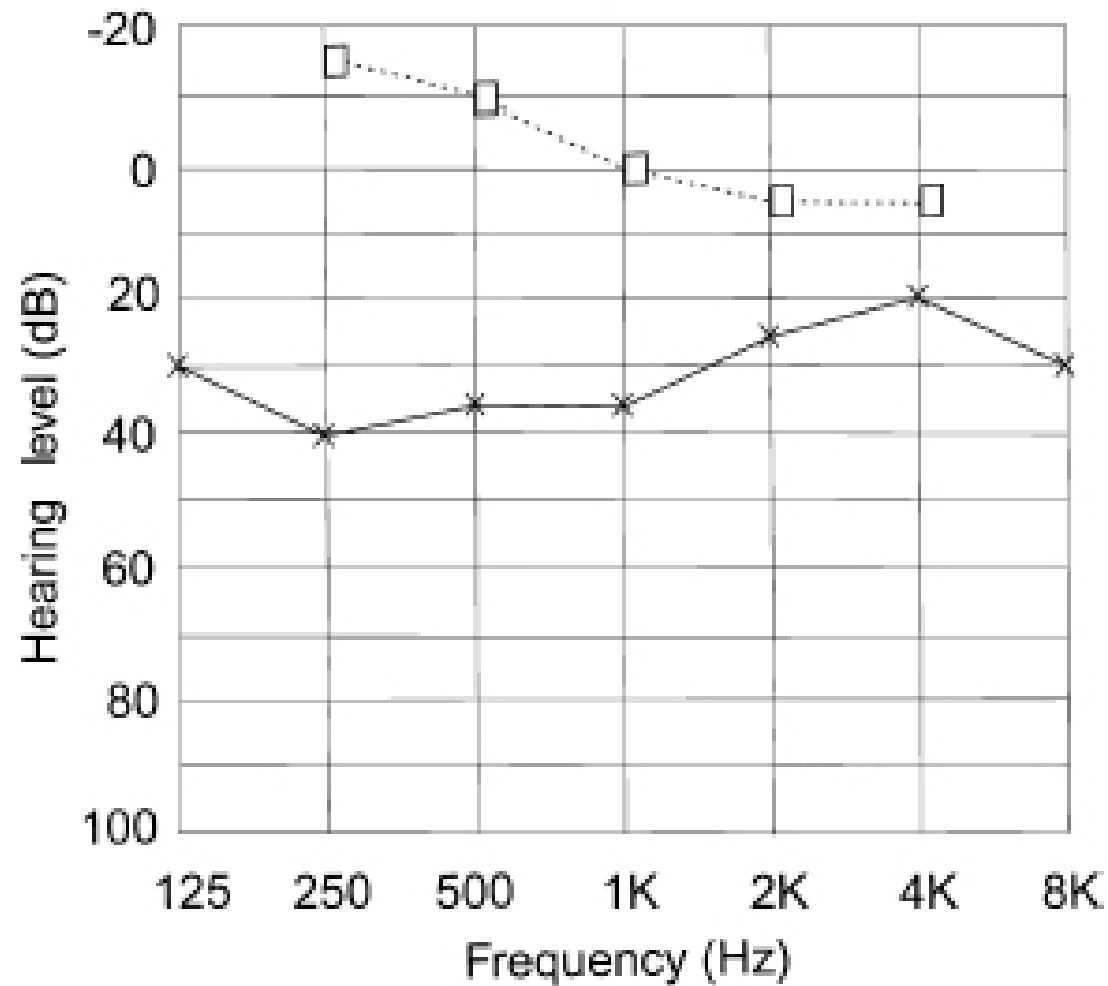
right ear



A

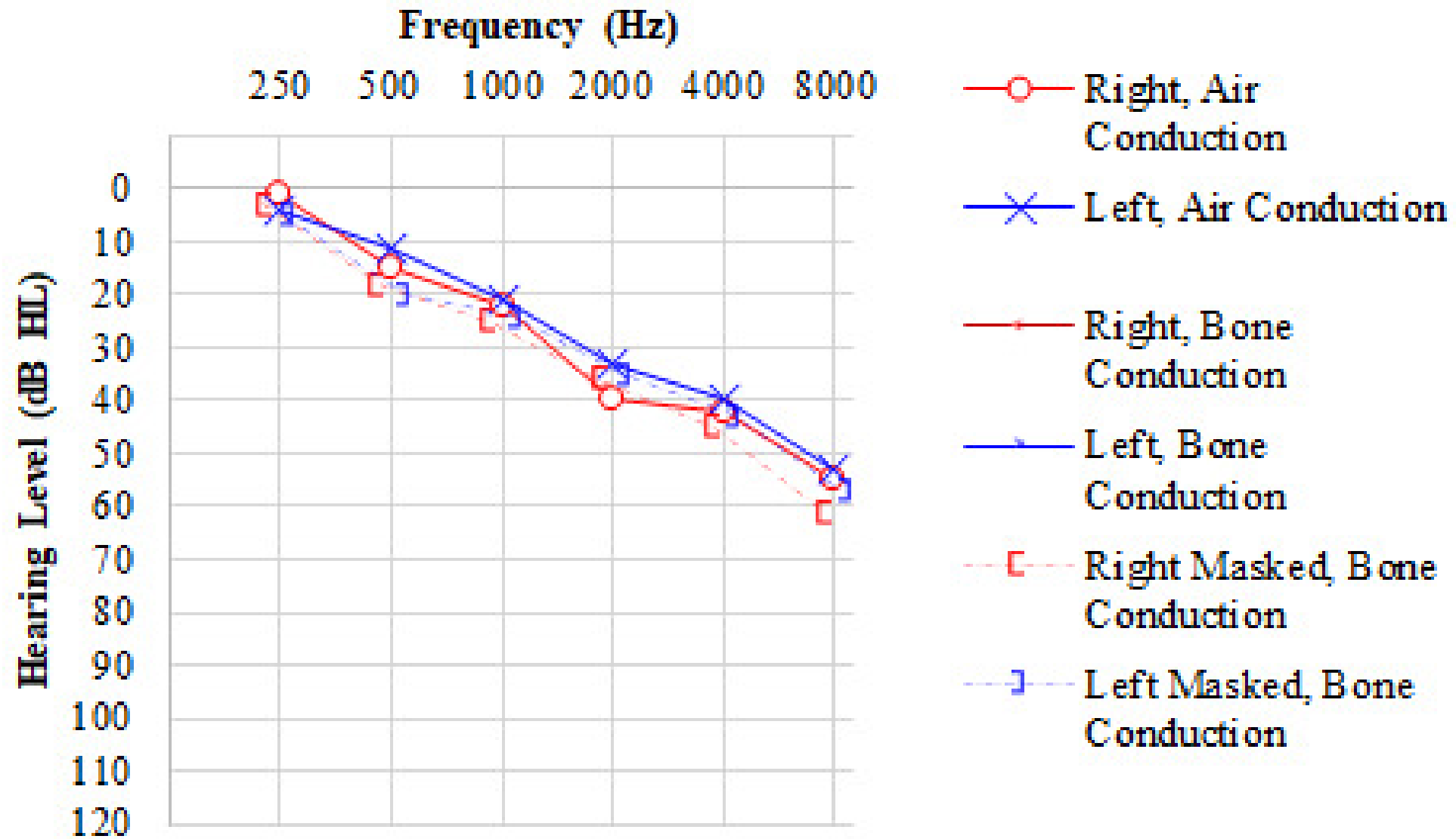
## Chronic otitis media

right ear

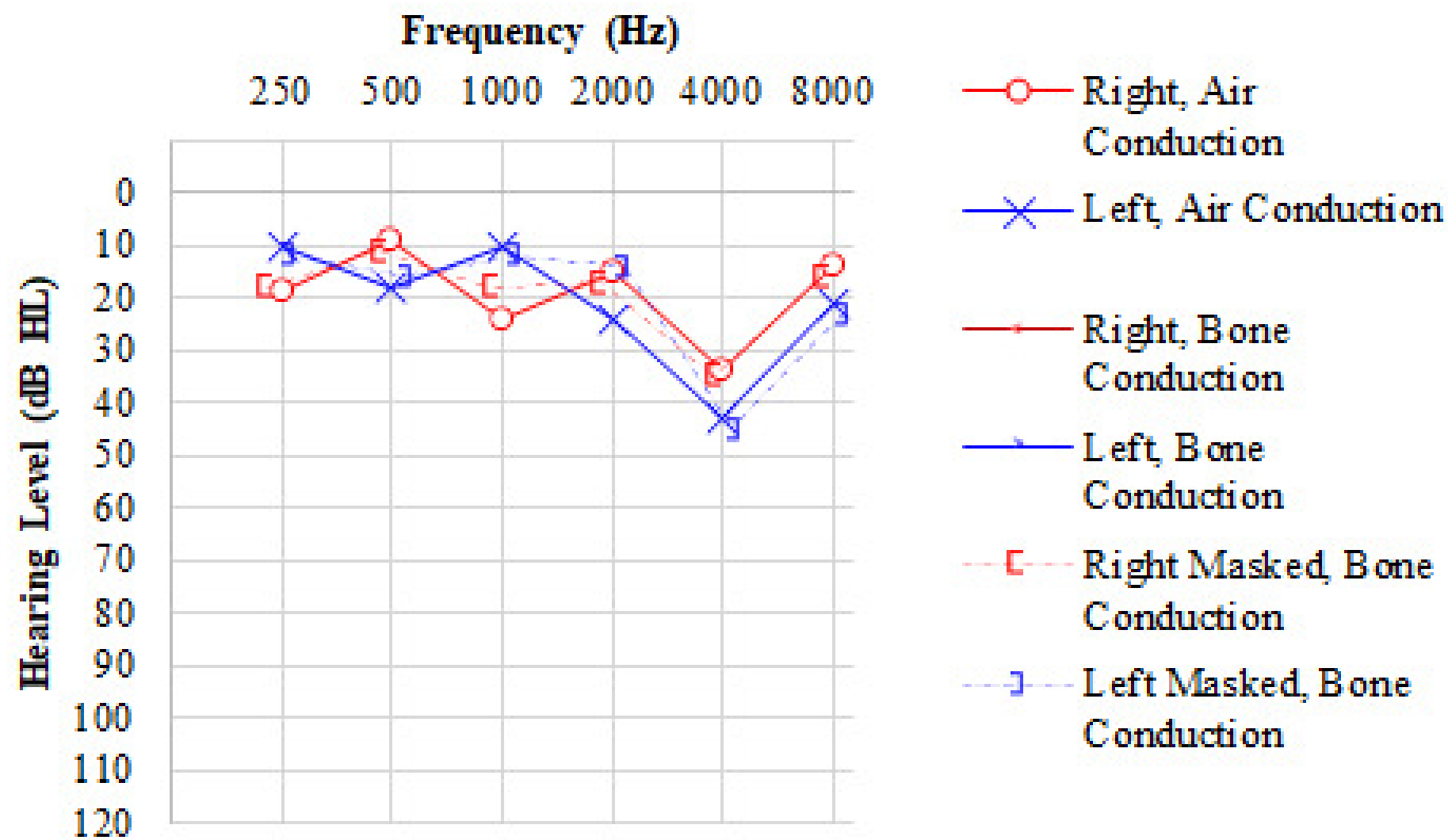


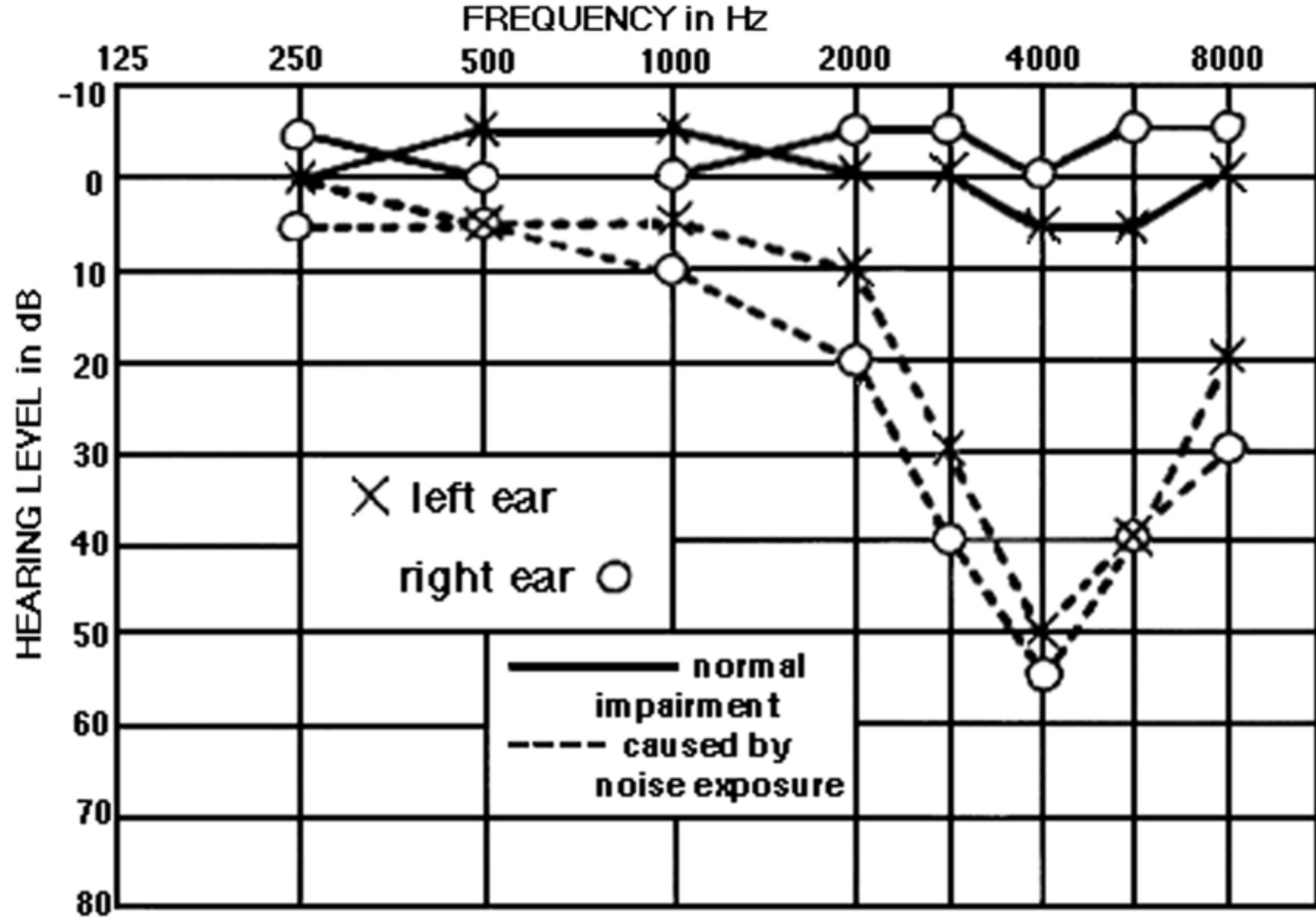
B

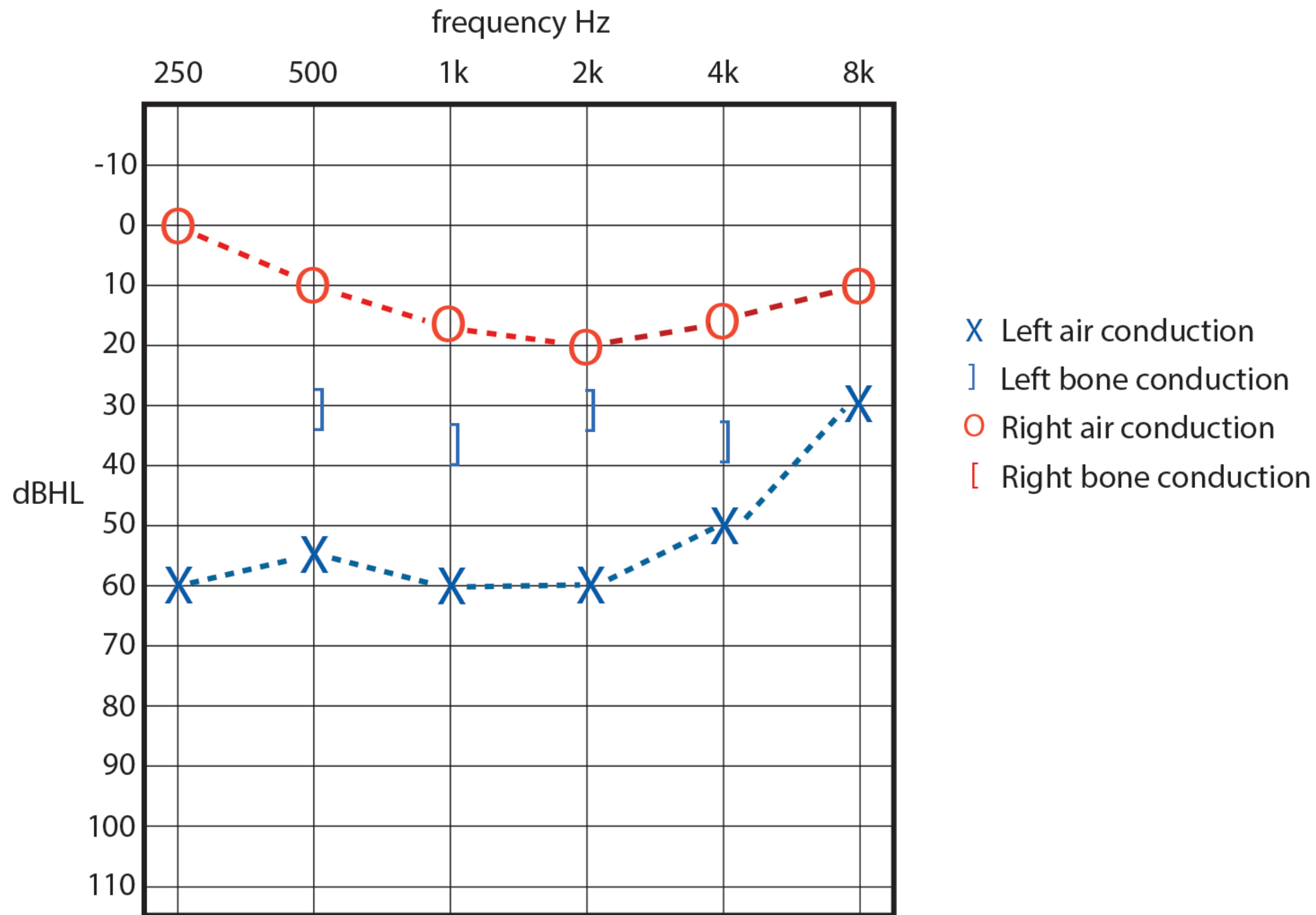


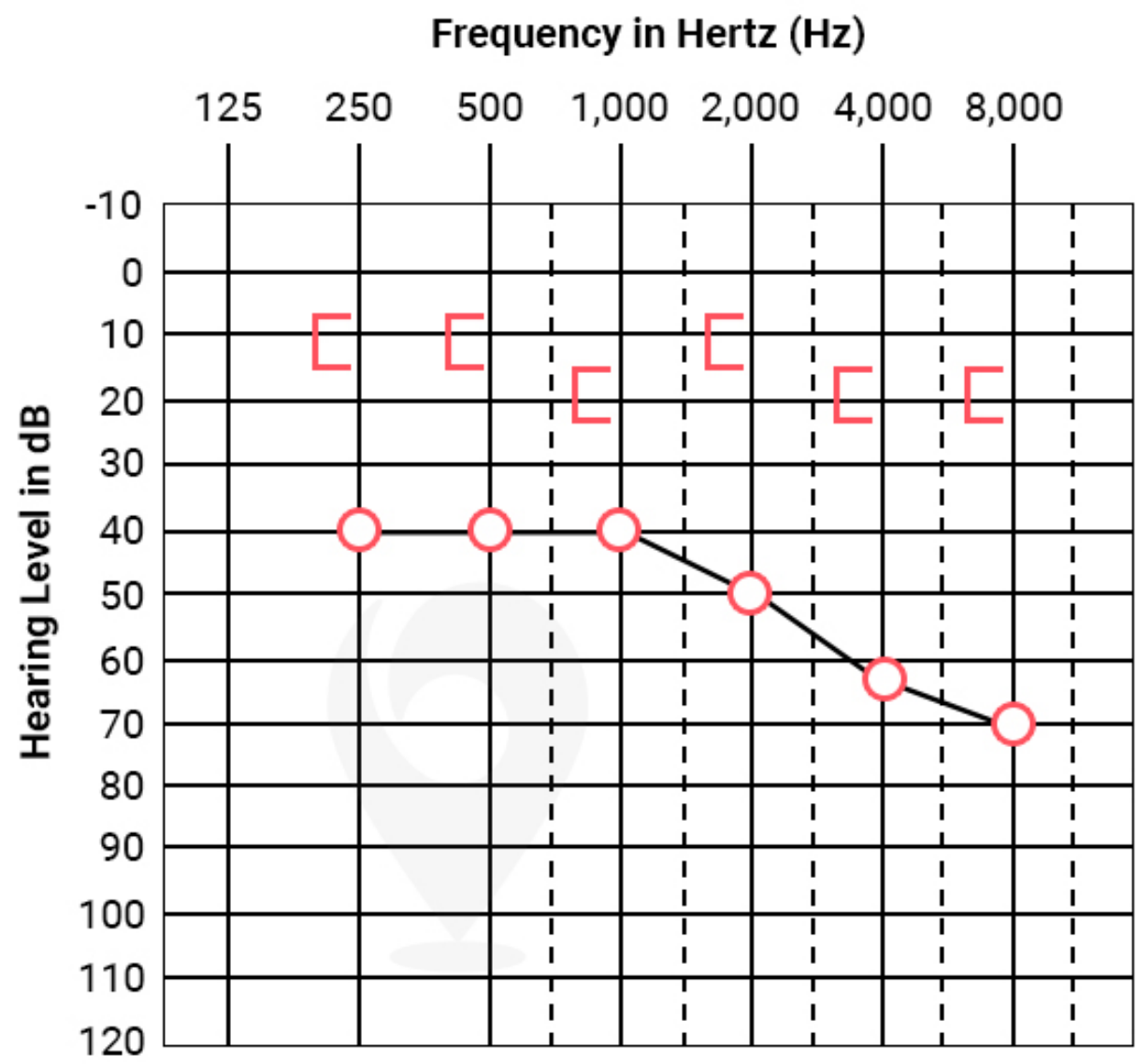




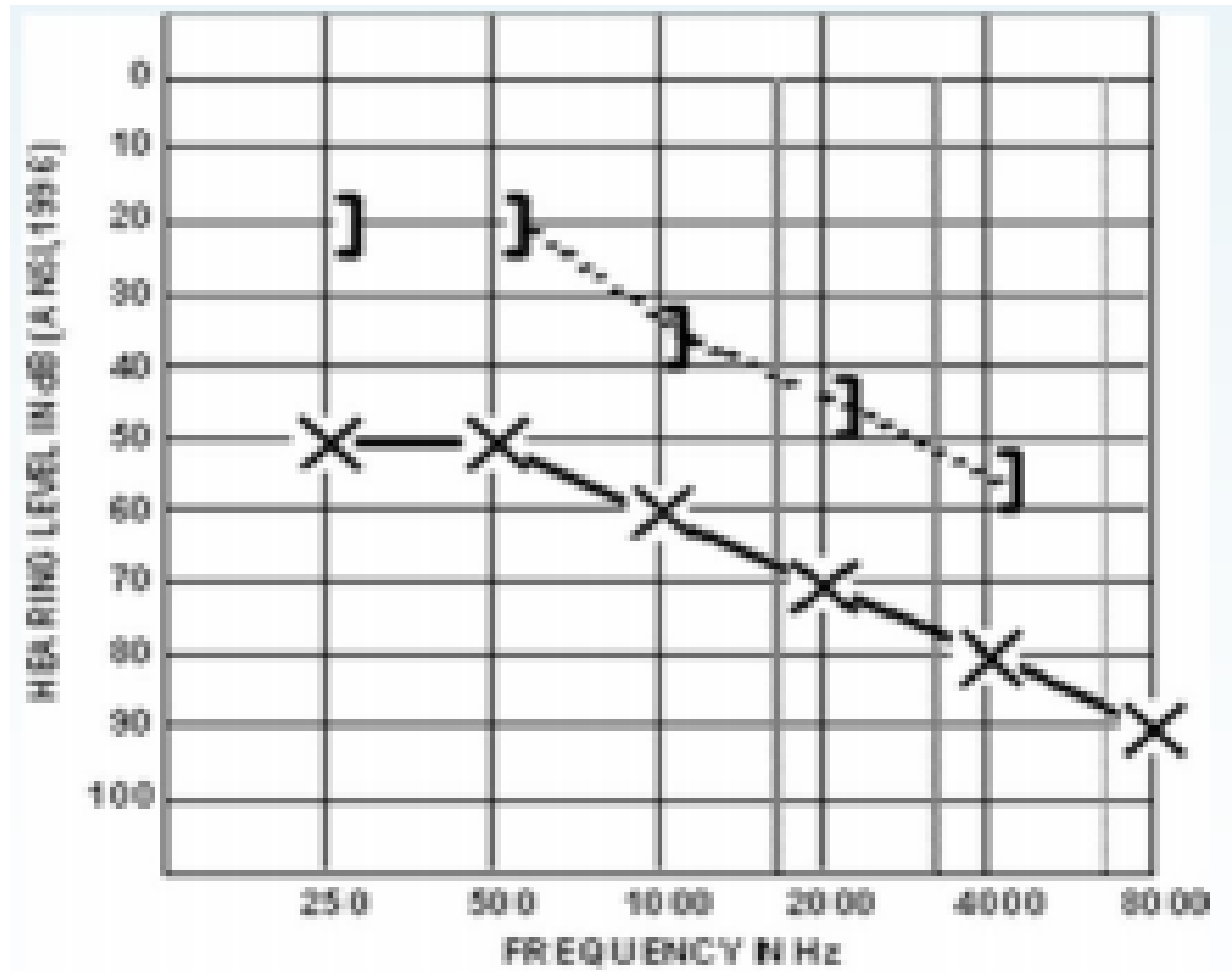


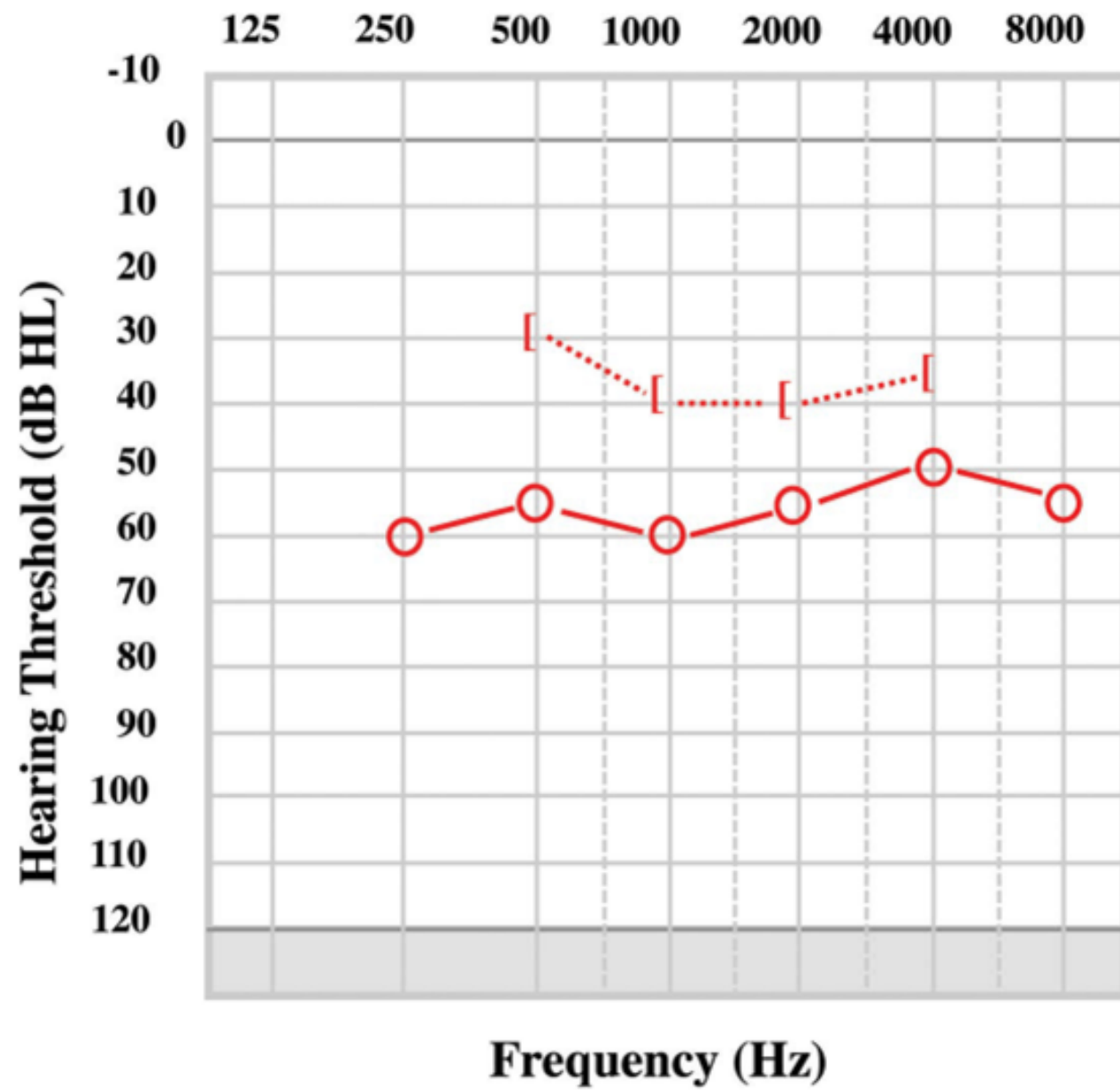




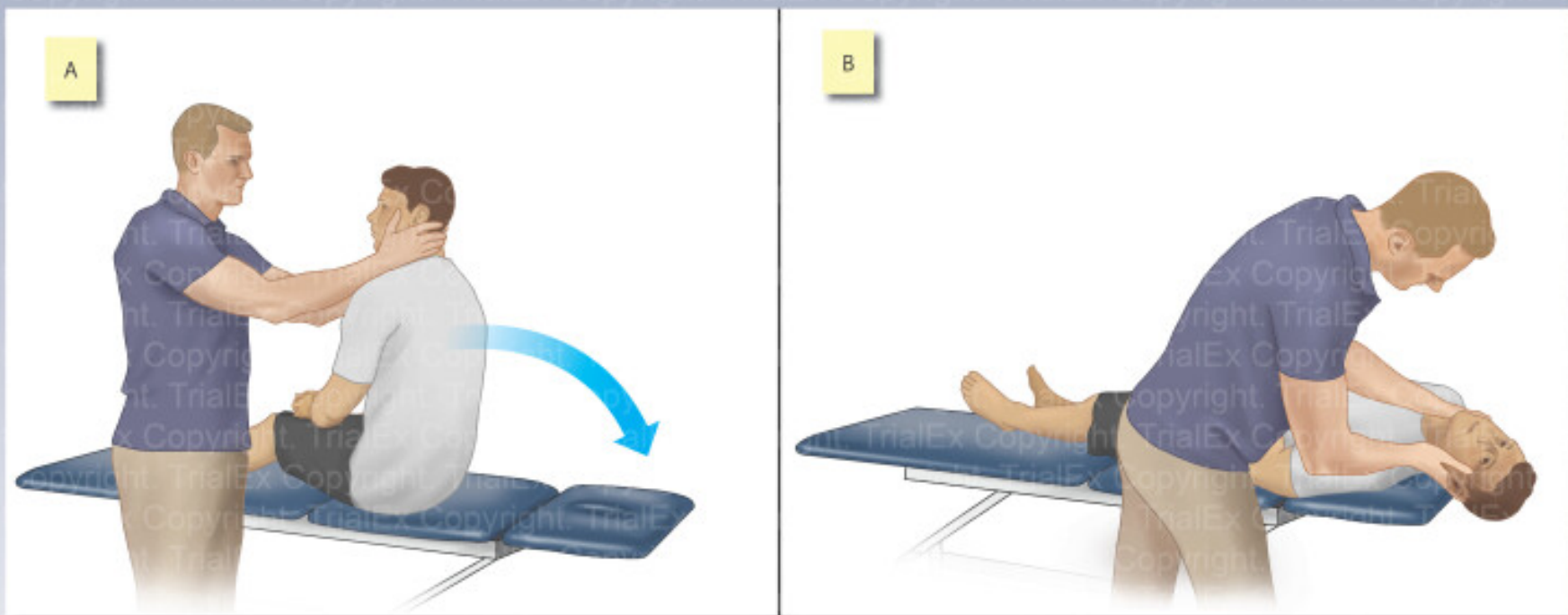


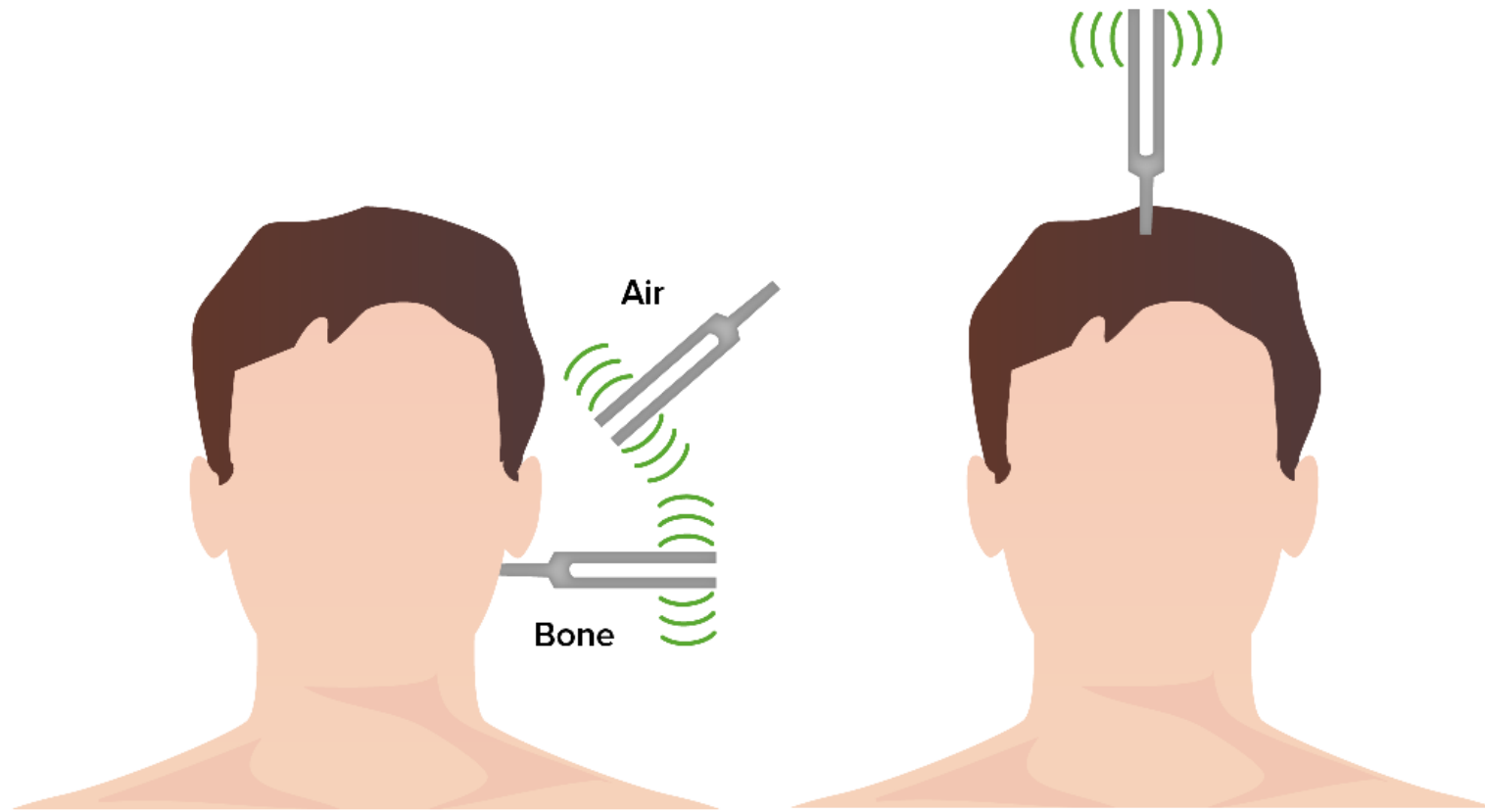













Rinne Test

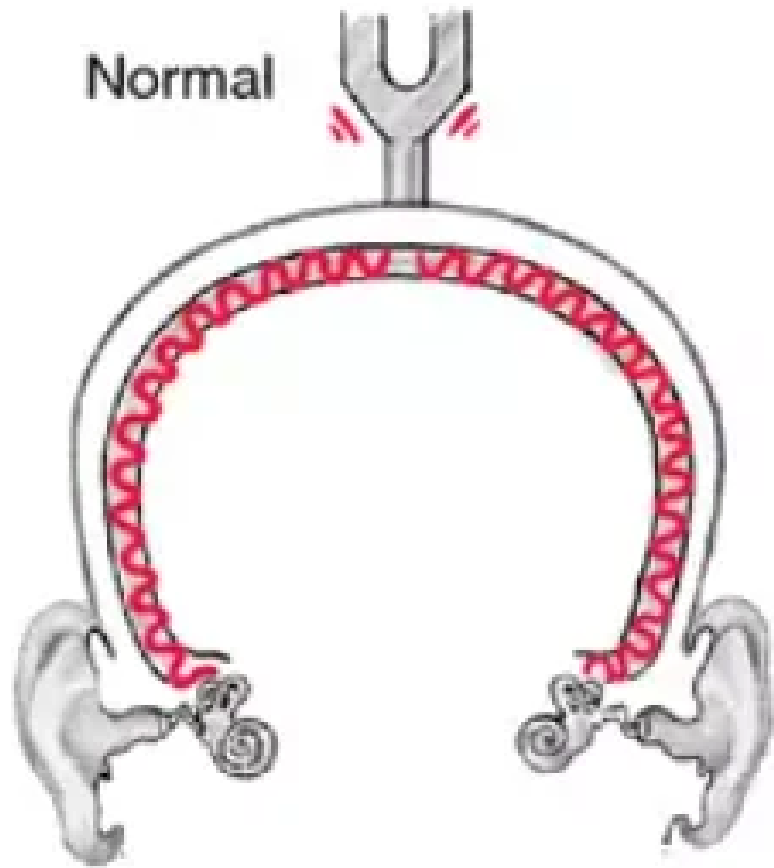
Weber Test

Hearing loss	Rinne test (Conduction)	Weber test (Localization)
None	Air > bone	Midline
Sensorineural		Normal ear
Conductive	Bone > air	Affected ear

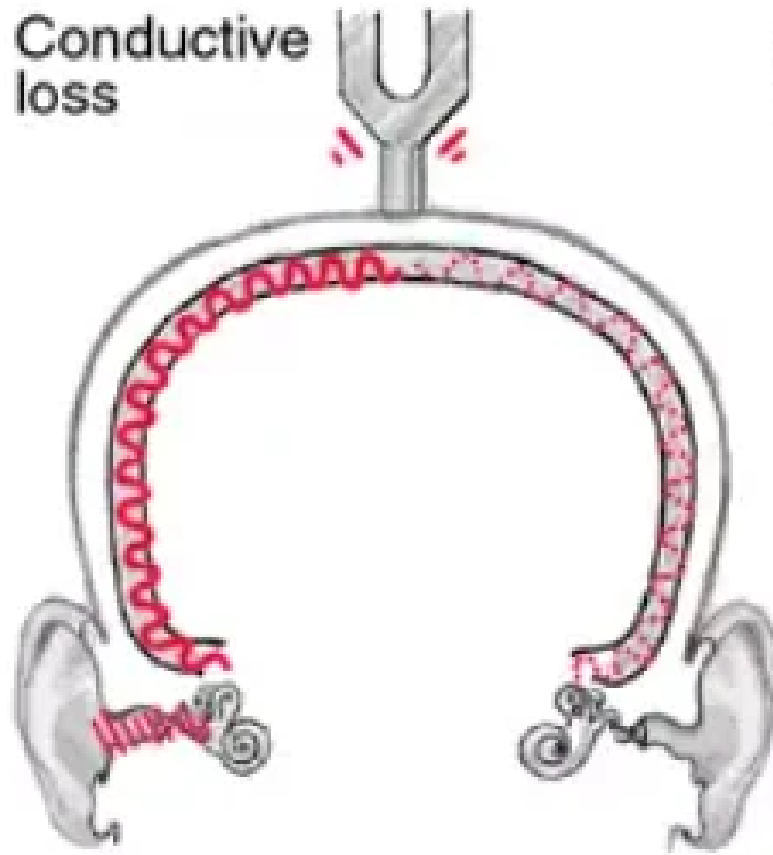




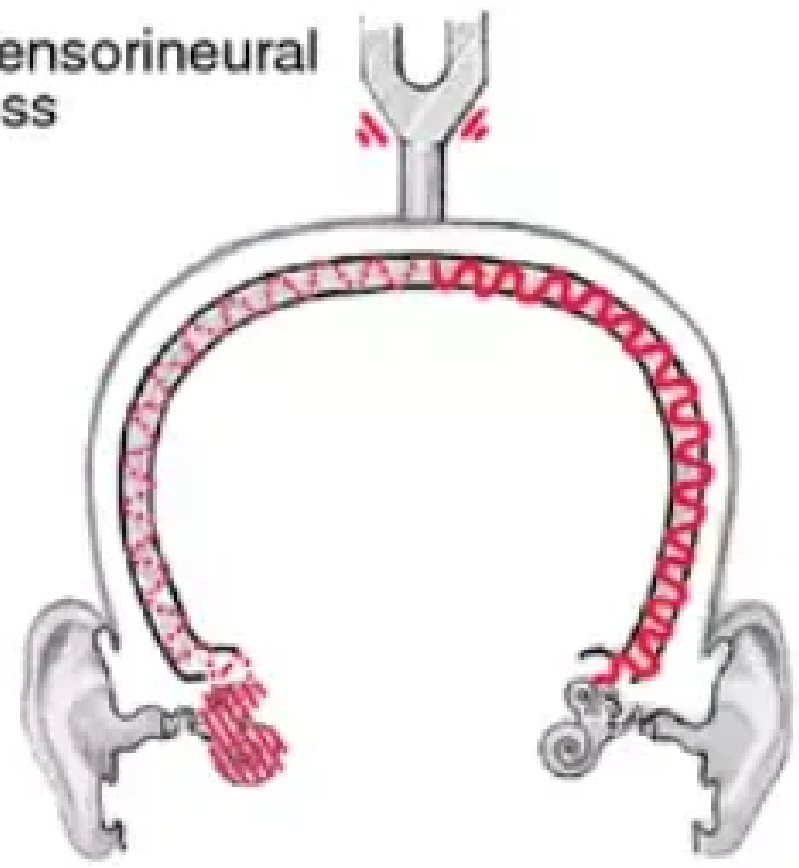
Normal

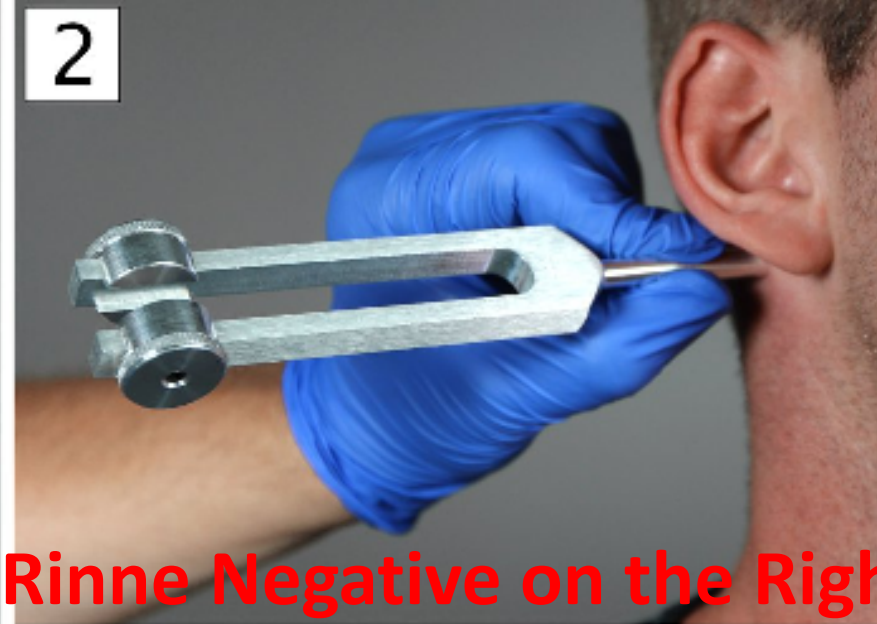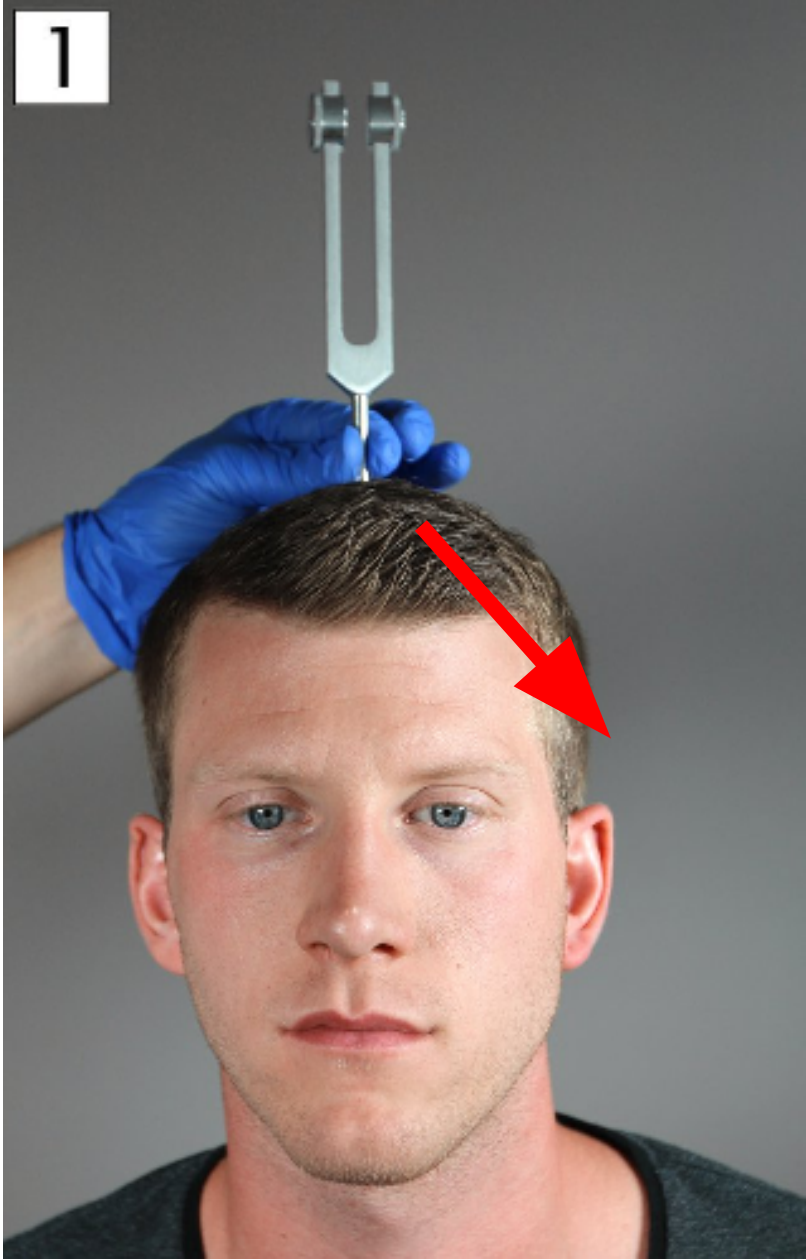


Conductive loss

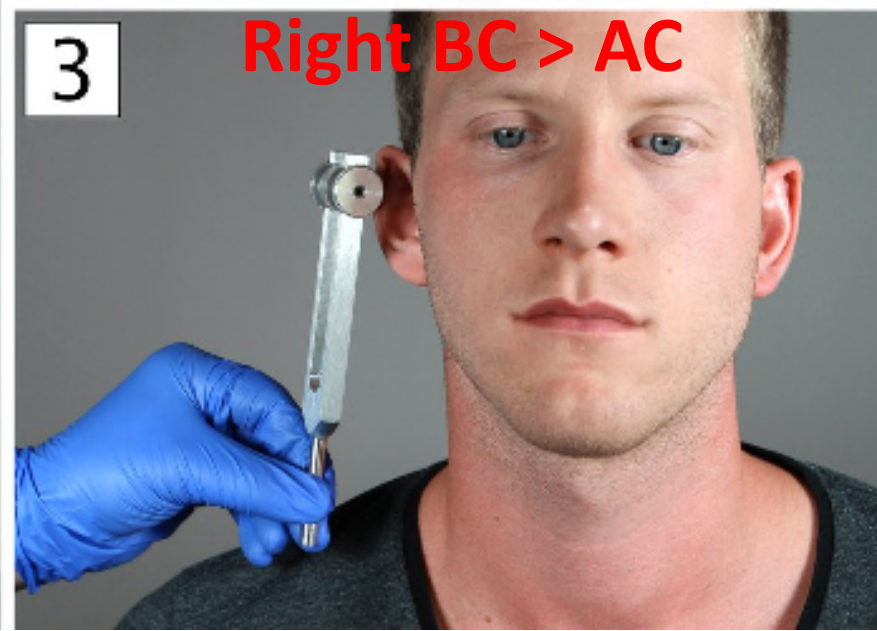

Sensorineural loss





Rinne Negative on the Right

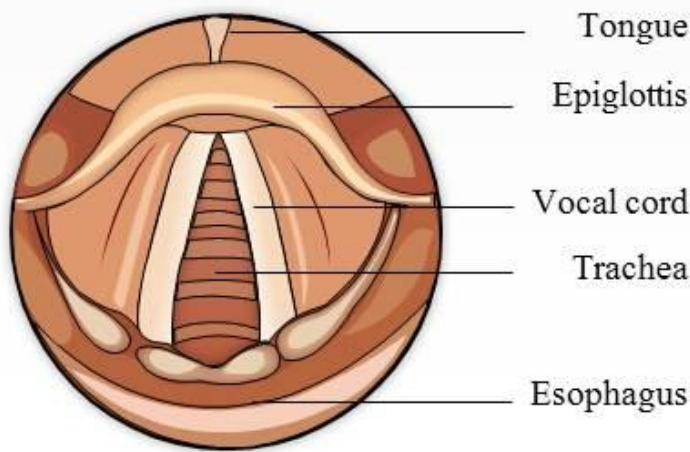
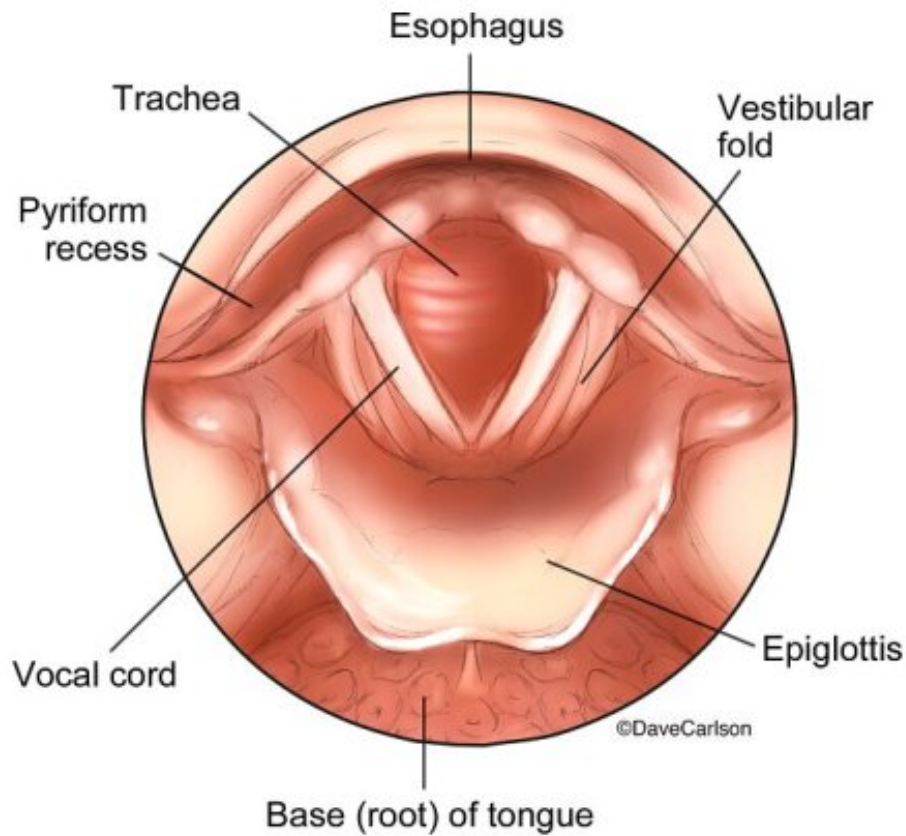
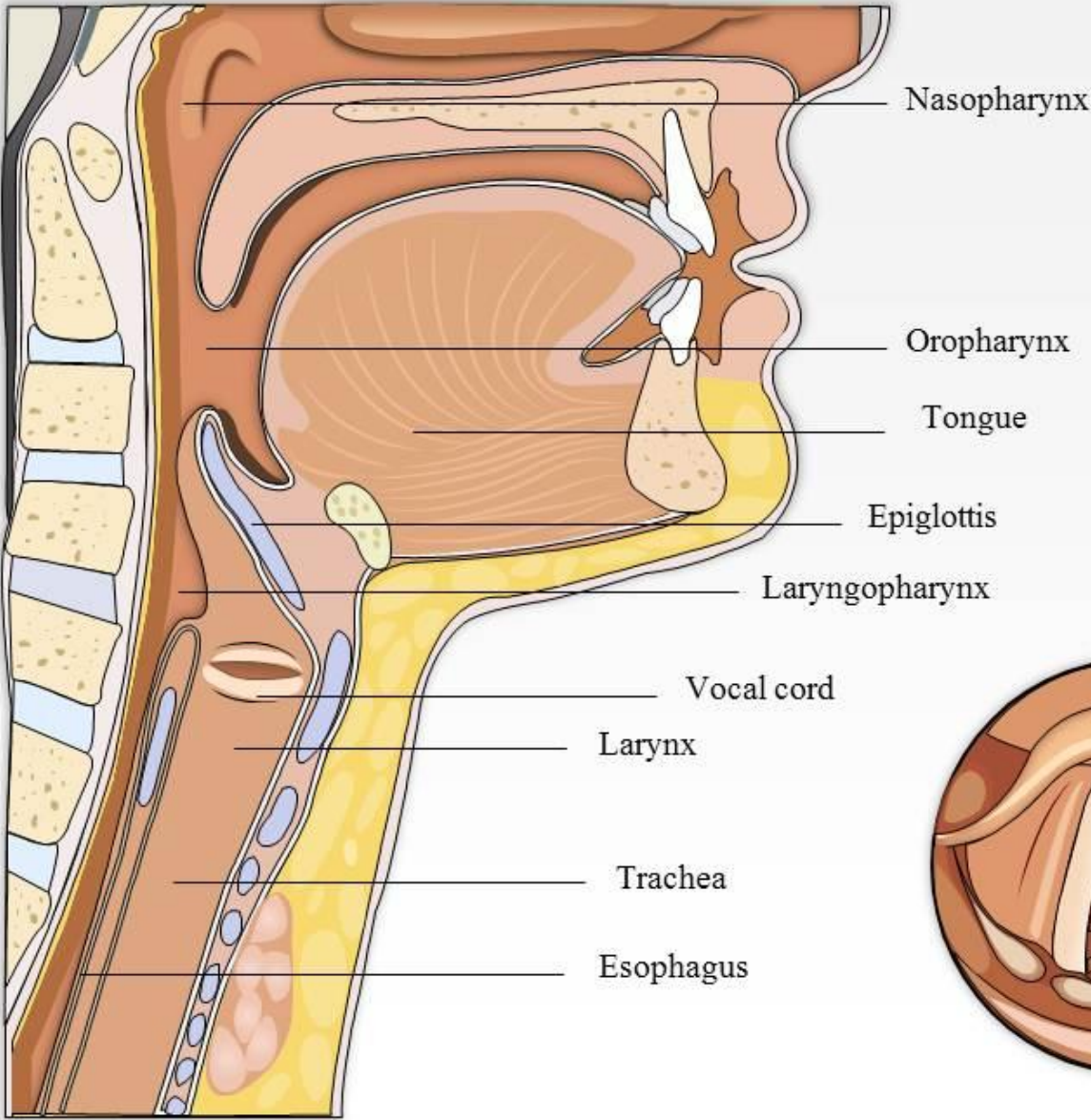


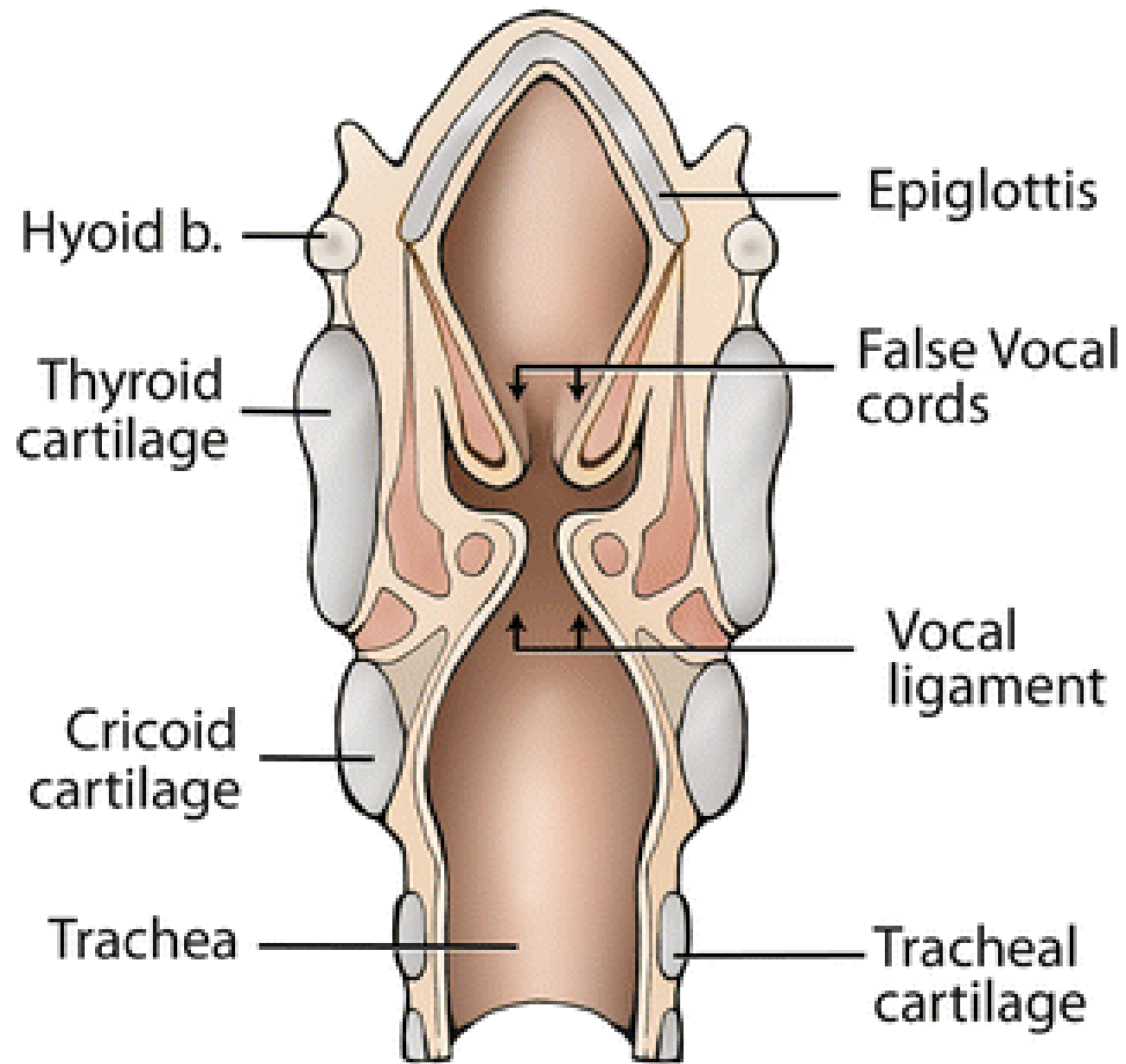
Right BC > AC

How would you interpret this result?  
What is the diagnosis?

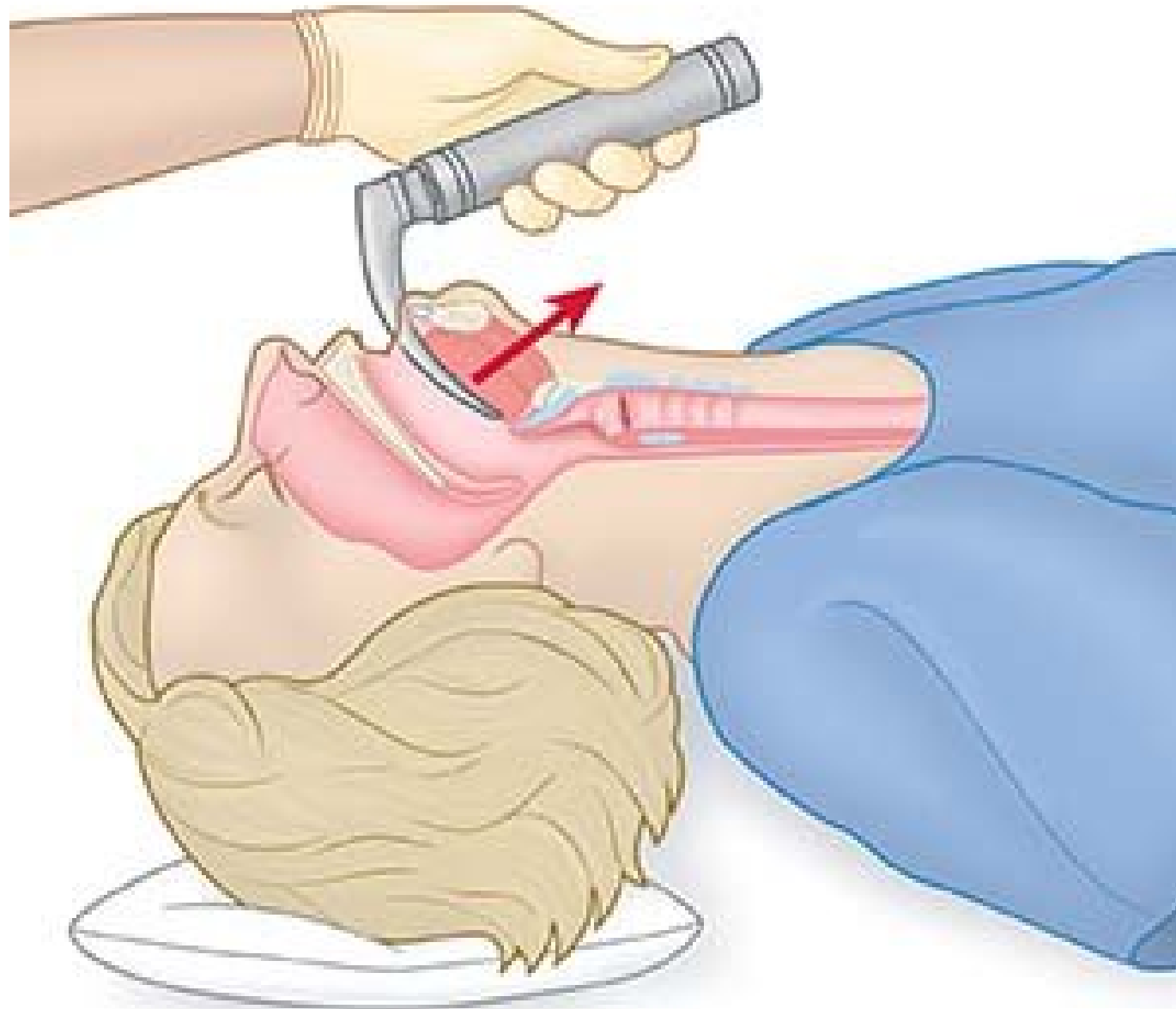
# ***Laryngology + Head & Neck***

# Anatomy Of Larynx

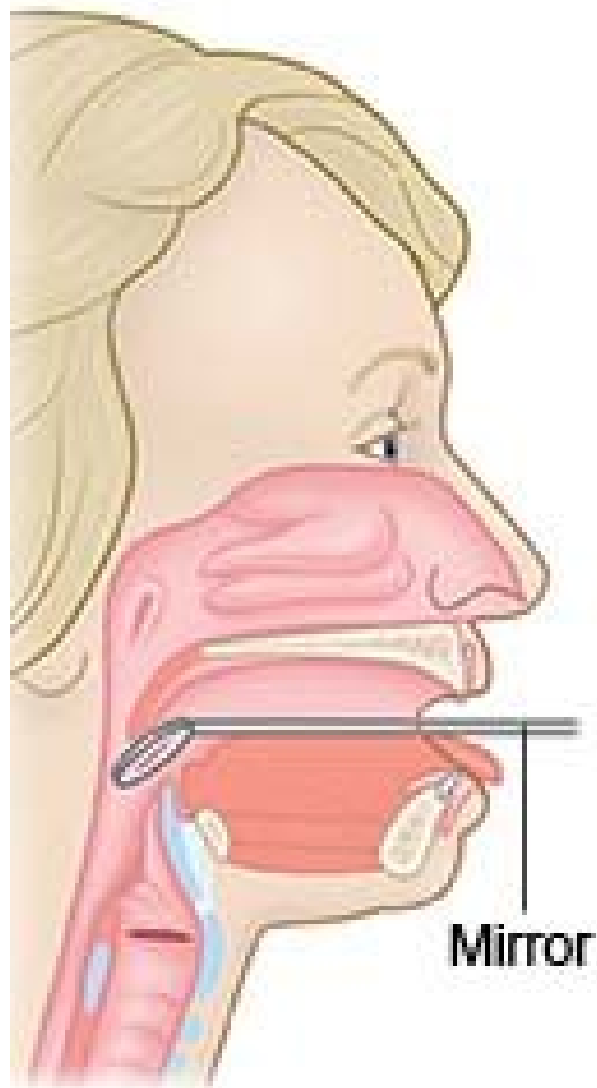




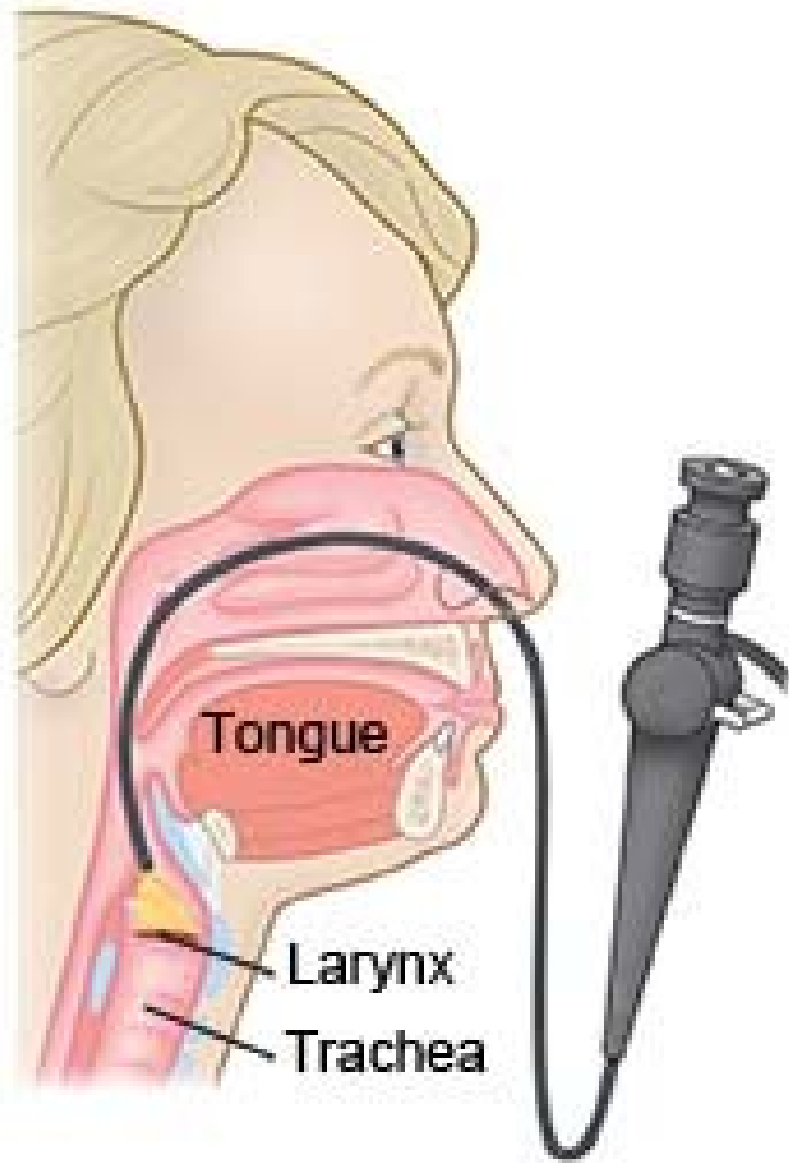
## Direct Laryngoscopy





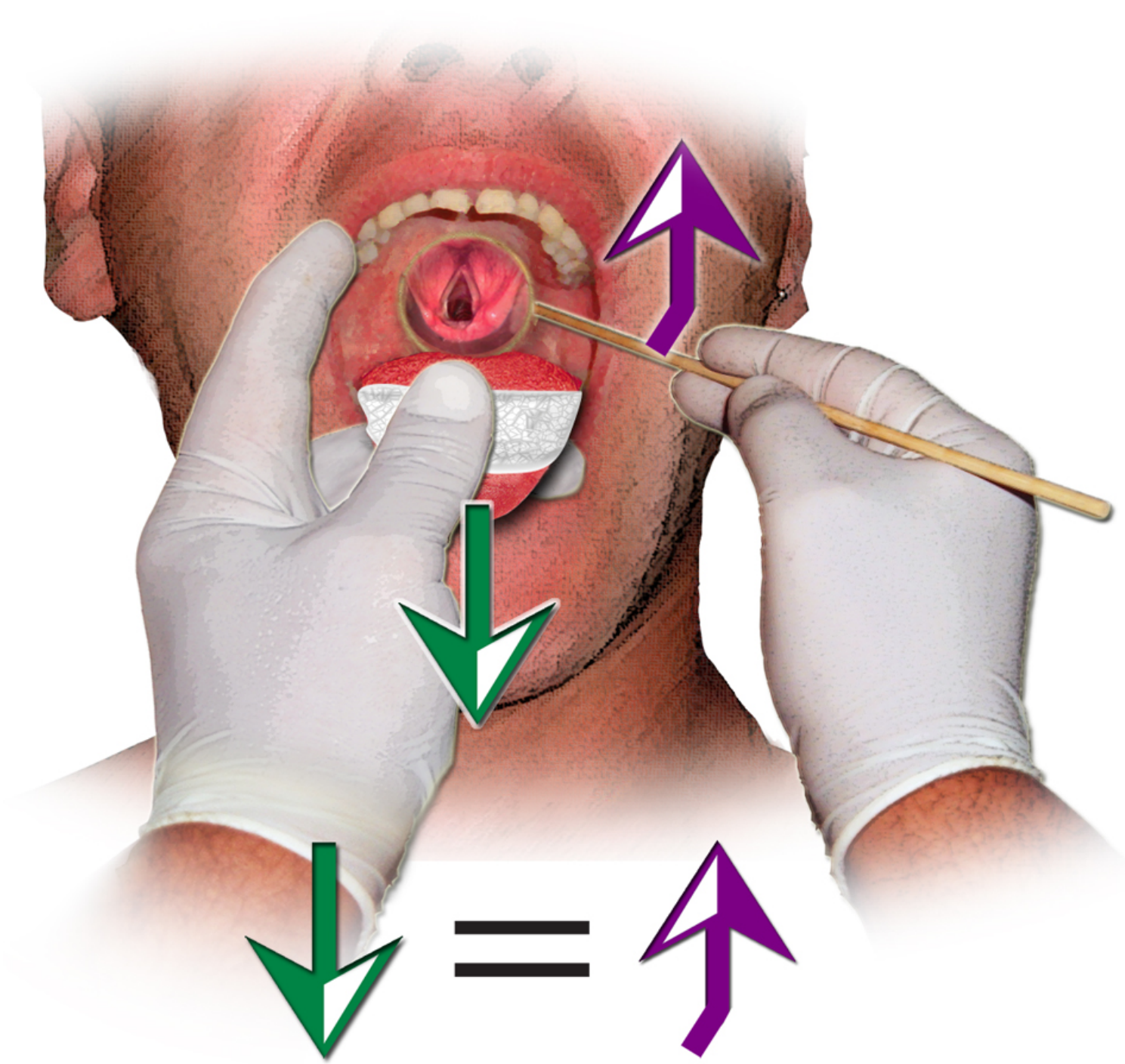


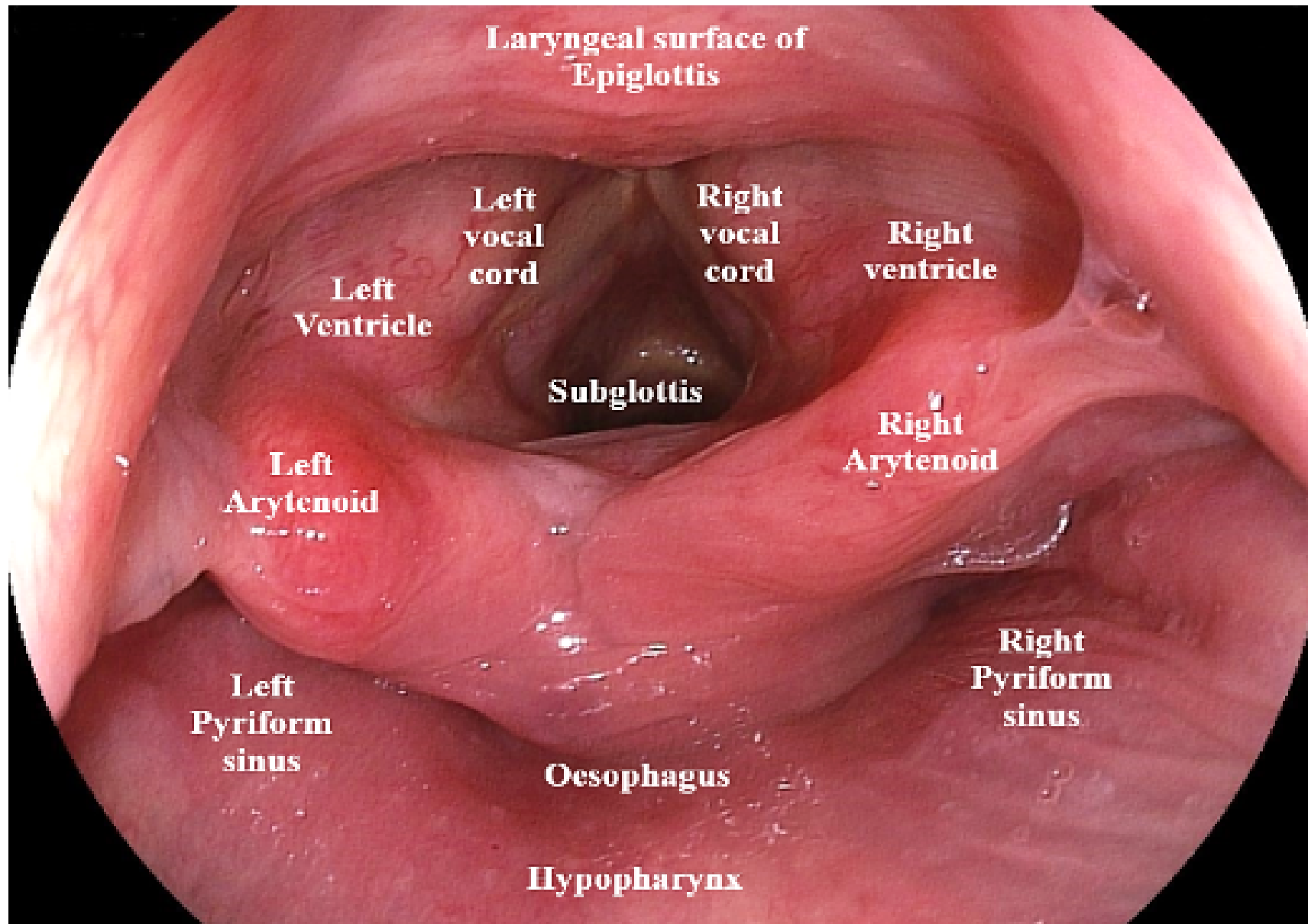
Indirect Oral  
Laryngoscopy

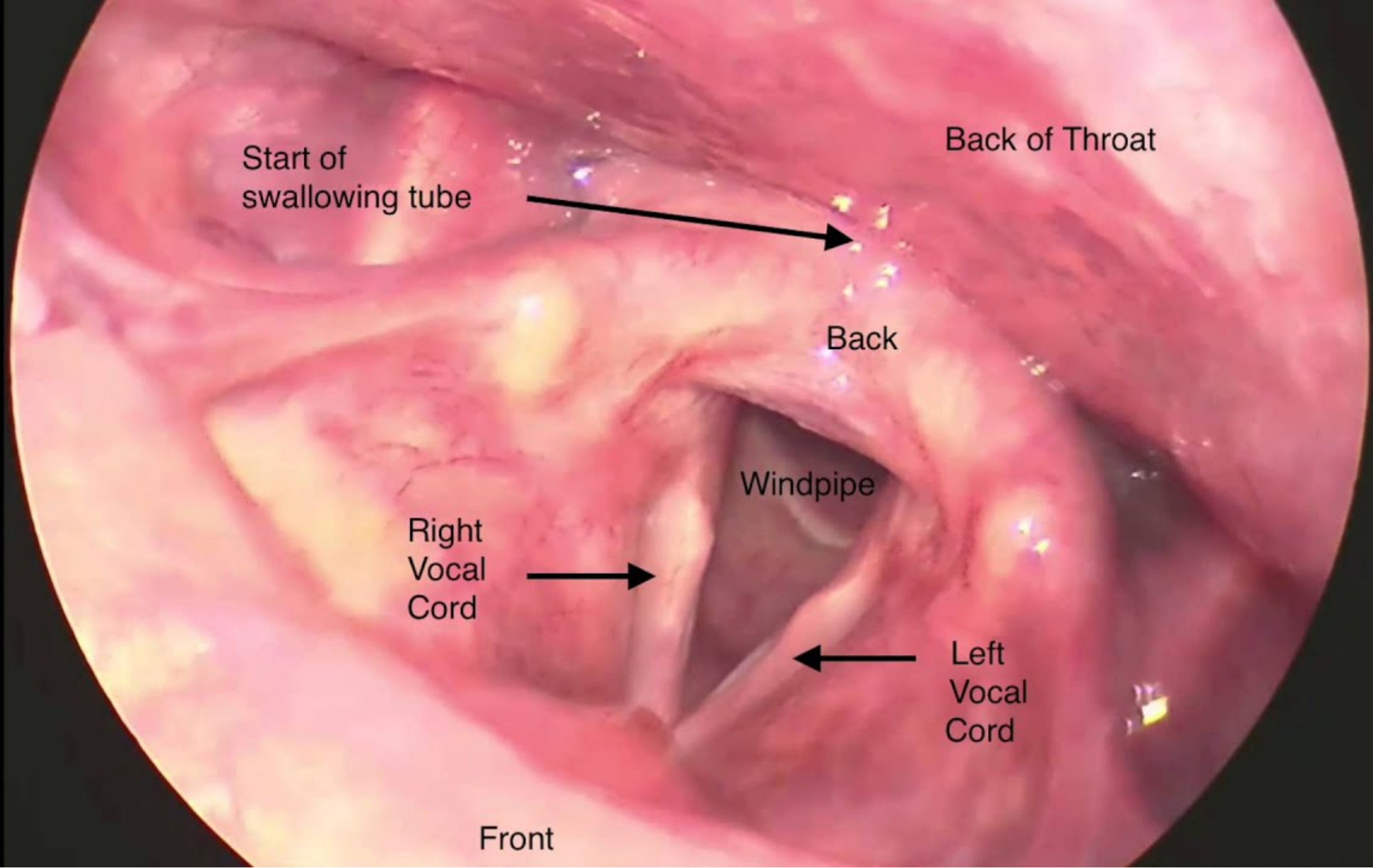


Indirect Nasal  
Laryngoscopy

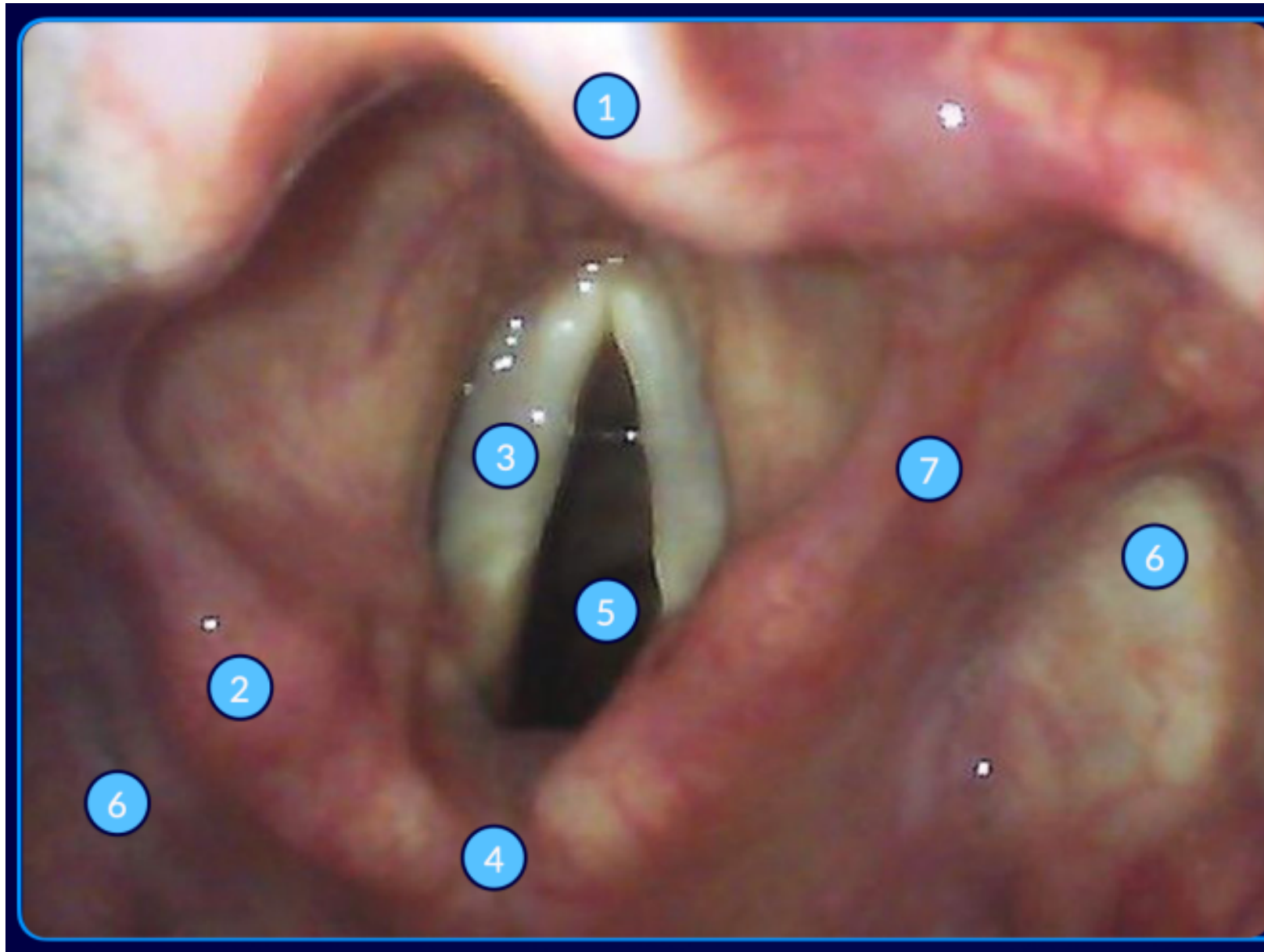


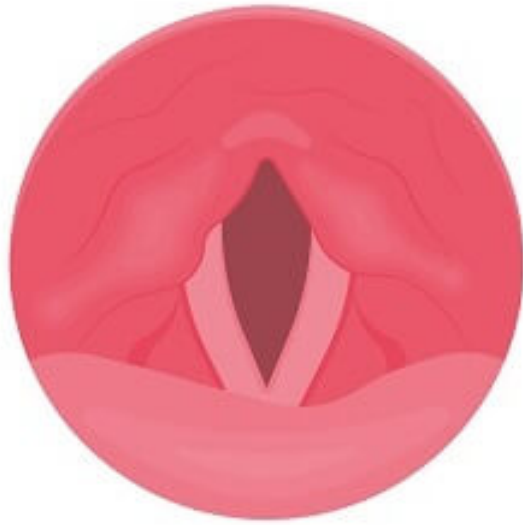




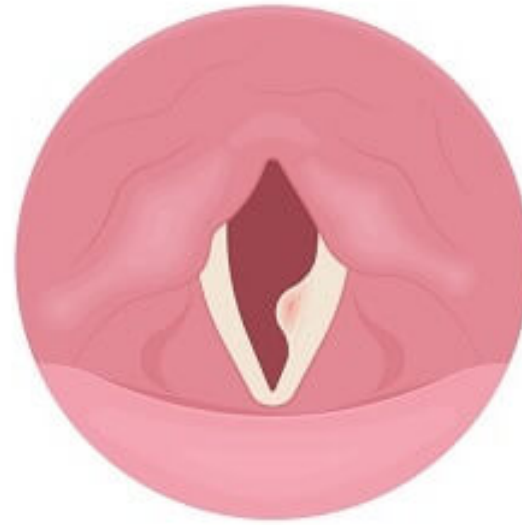


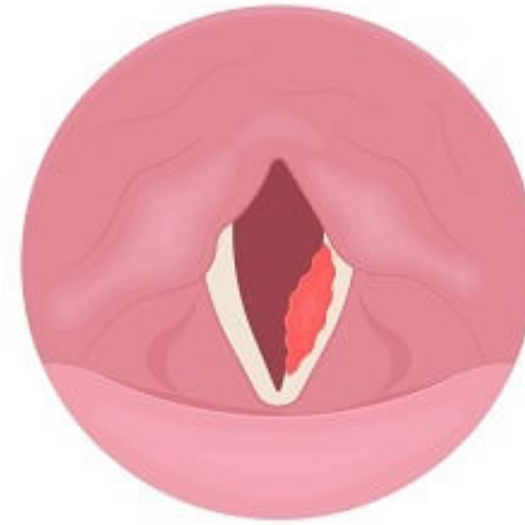




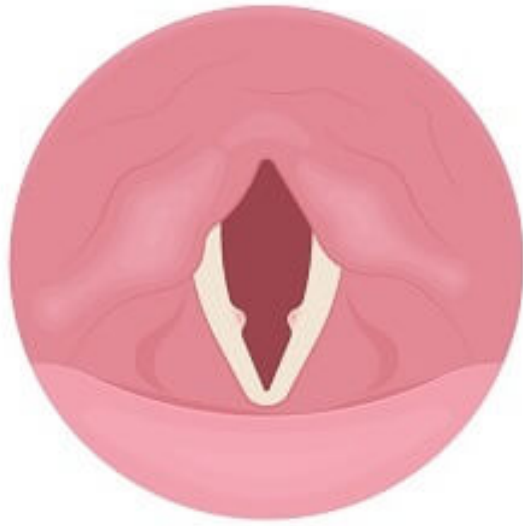
**LARYNGITIS**



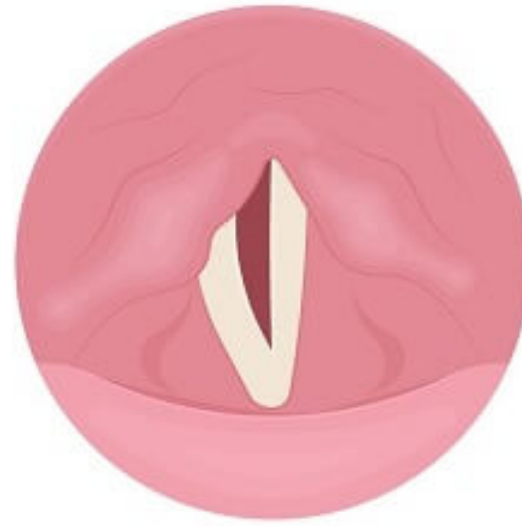**POLYP**



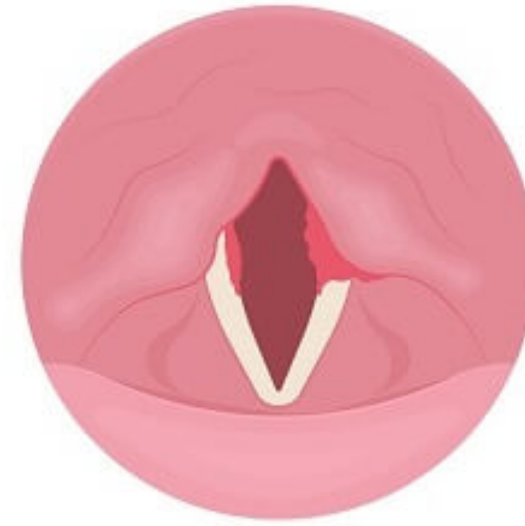
**CANCER**



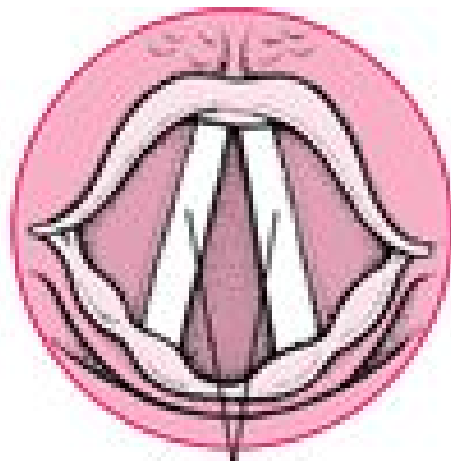
**NODULE**



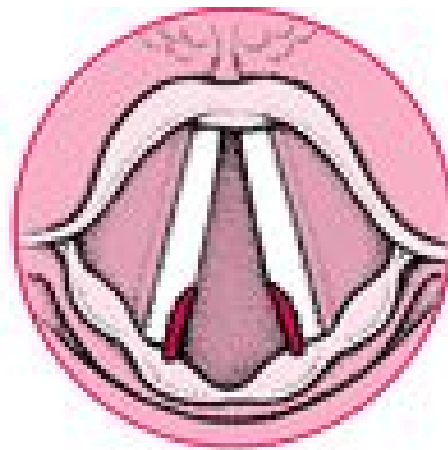
**PARALYSIS**



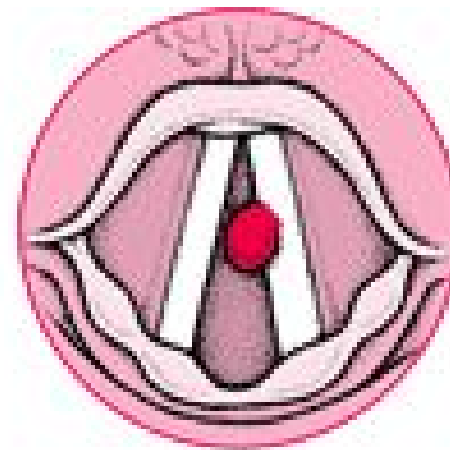
**CONTACT ULCERS**



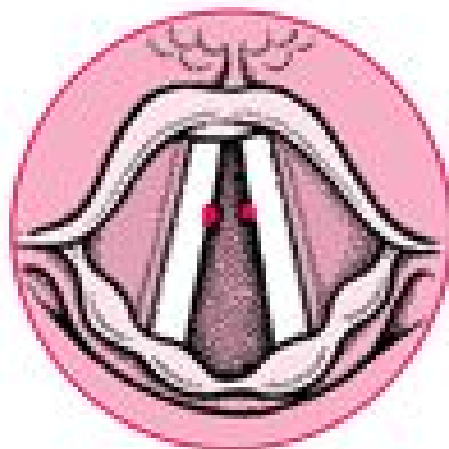Normal  
vocal cords



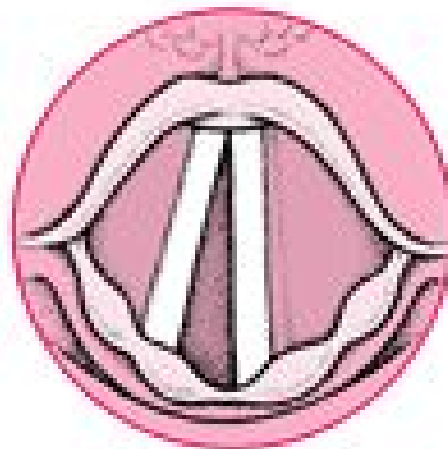Contact  
ulcers



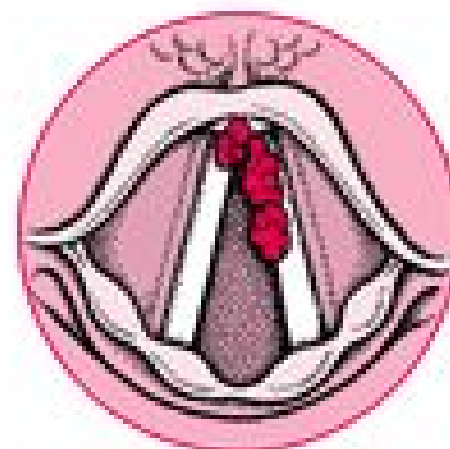Polyp



Nodules



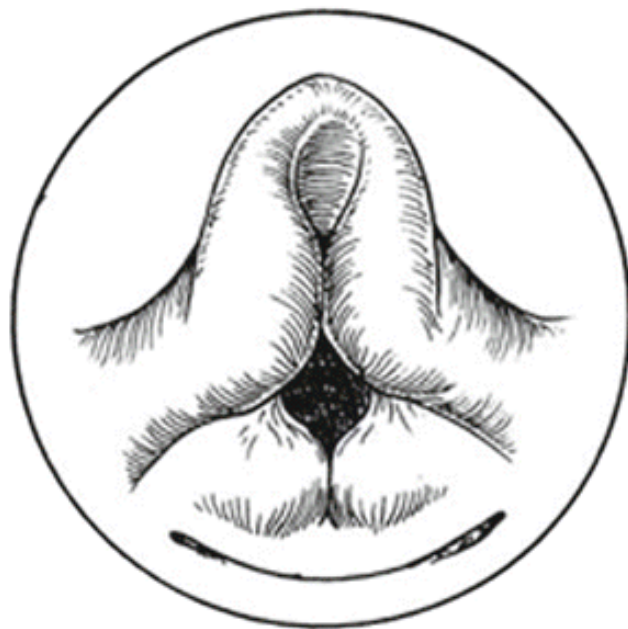Unilateral  
paralysis



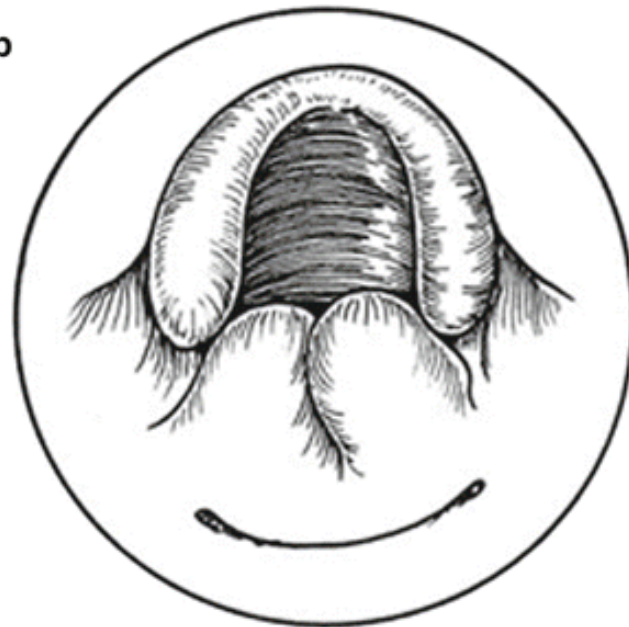
Cancer

### Examination Findings

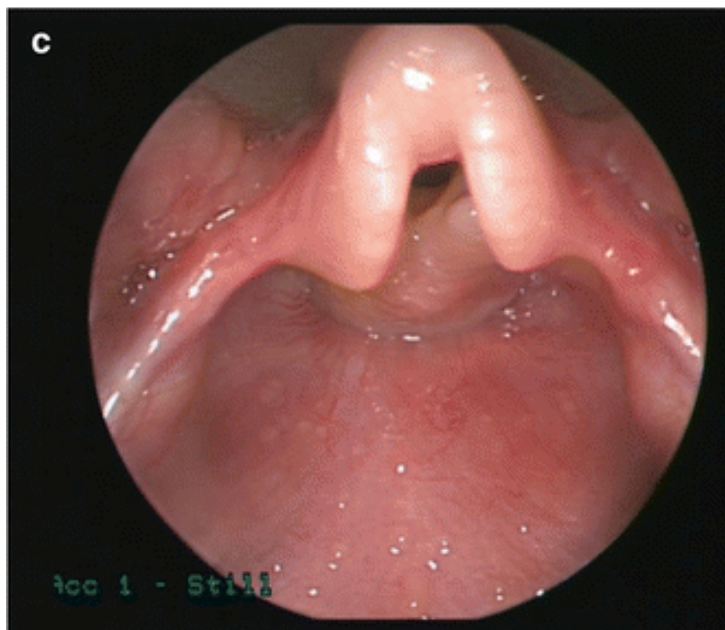
a



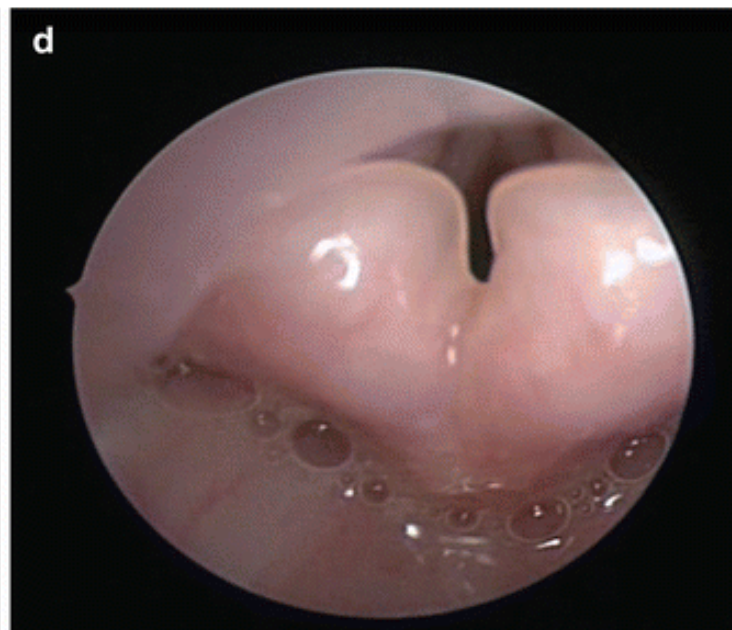b



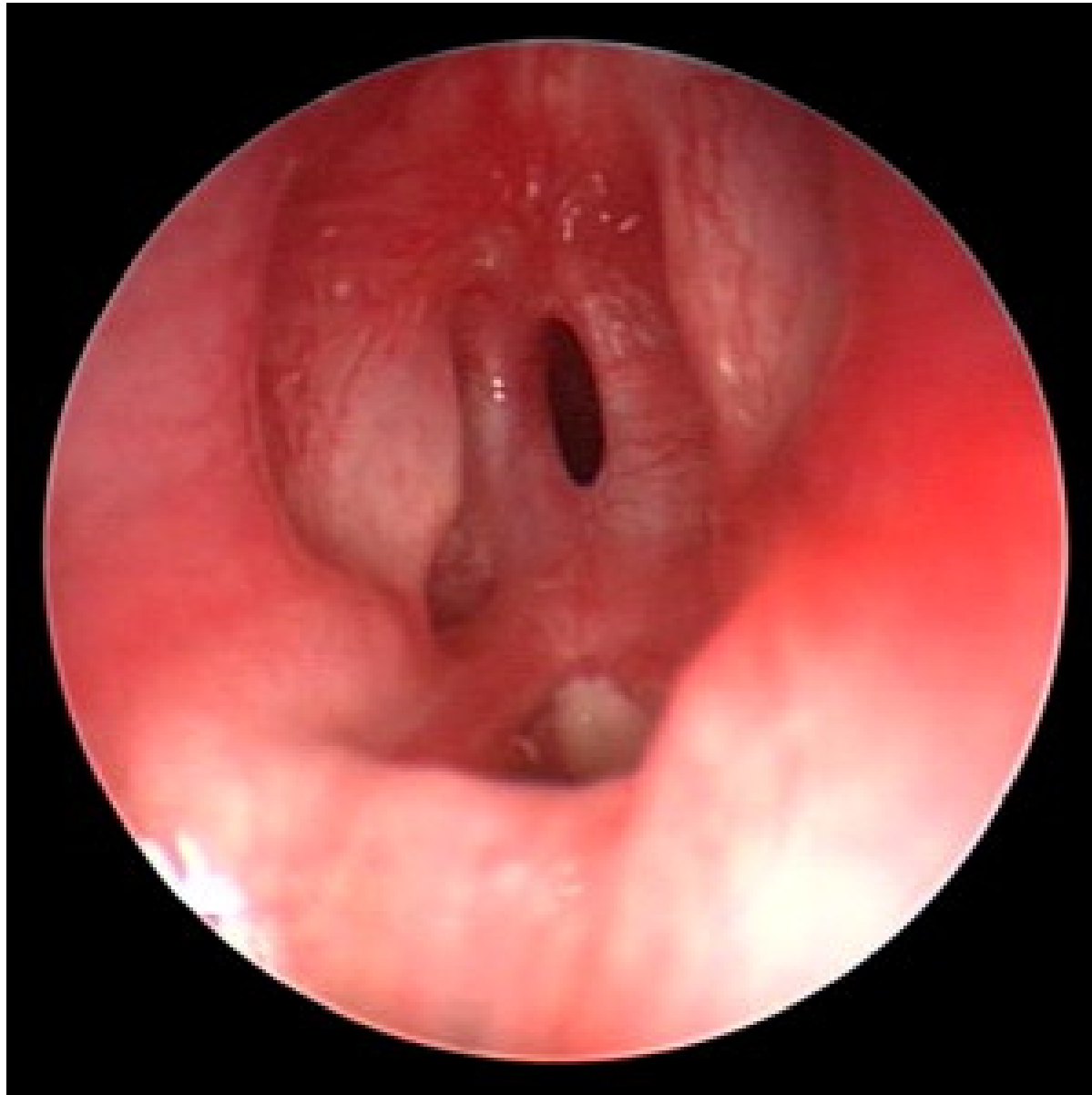c

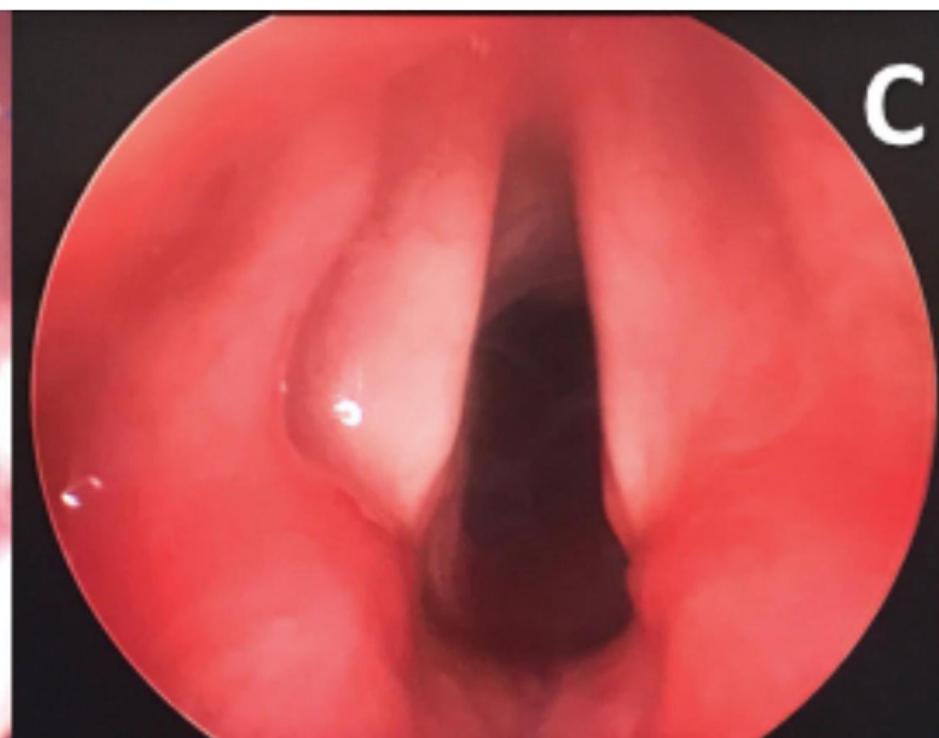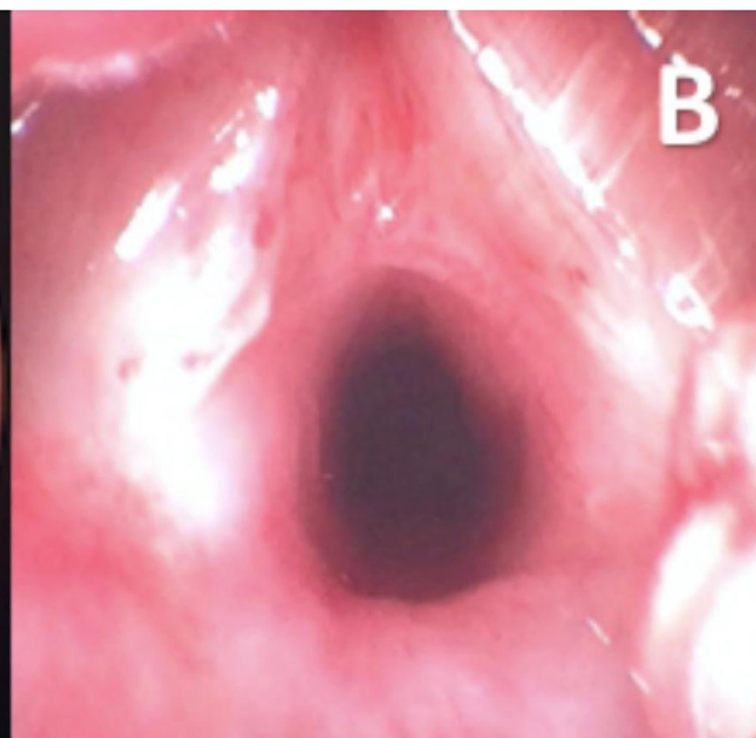
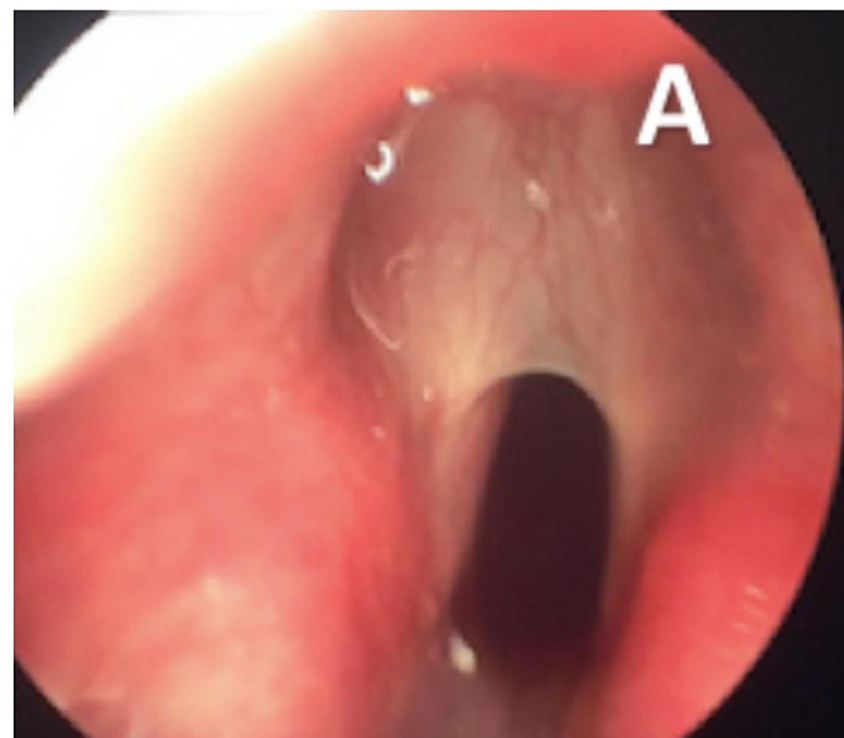


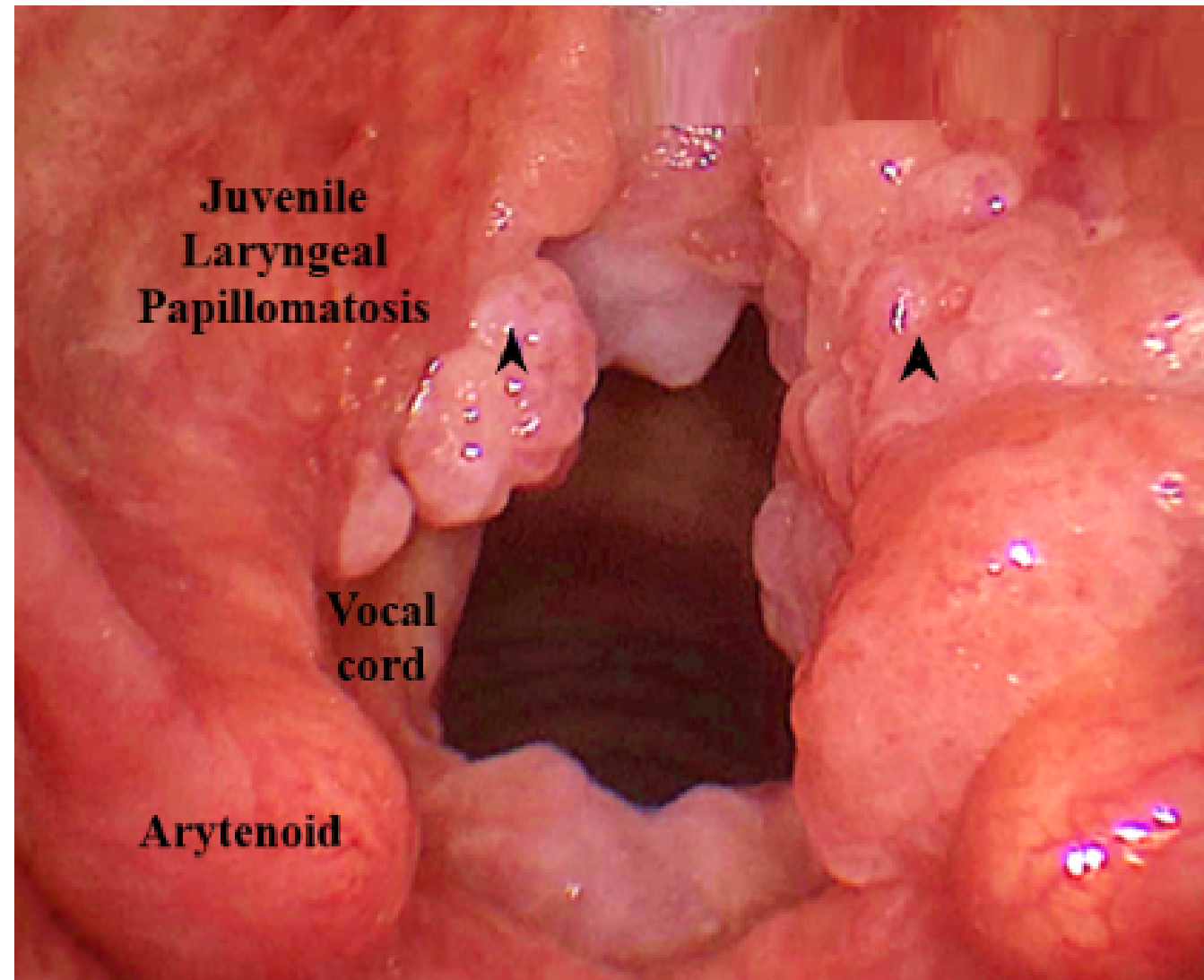
d

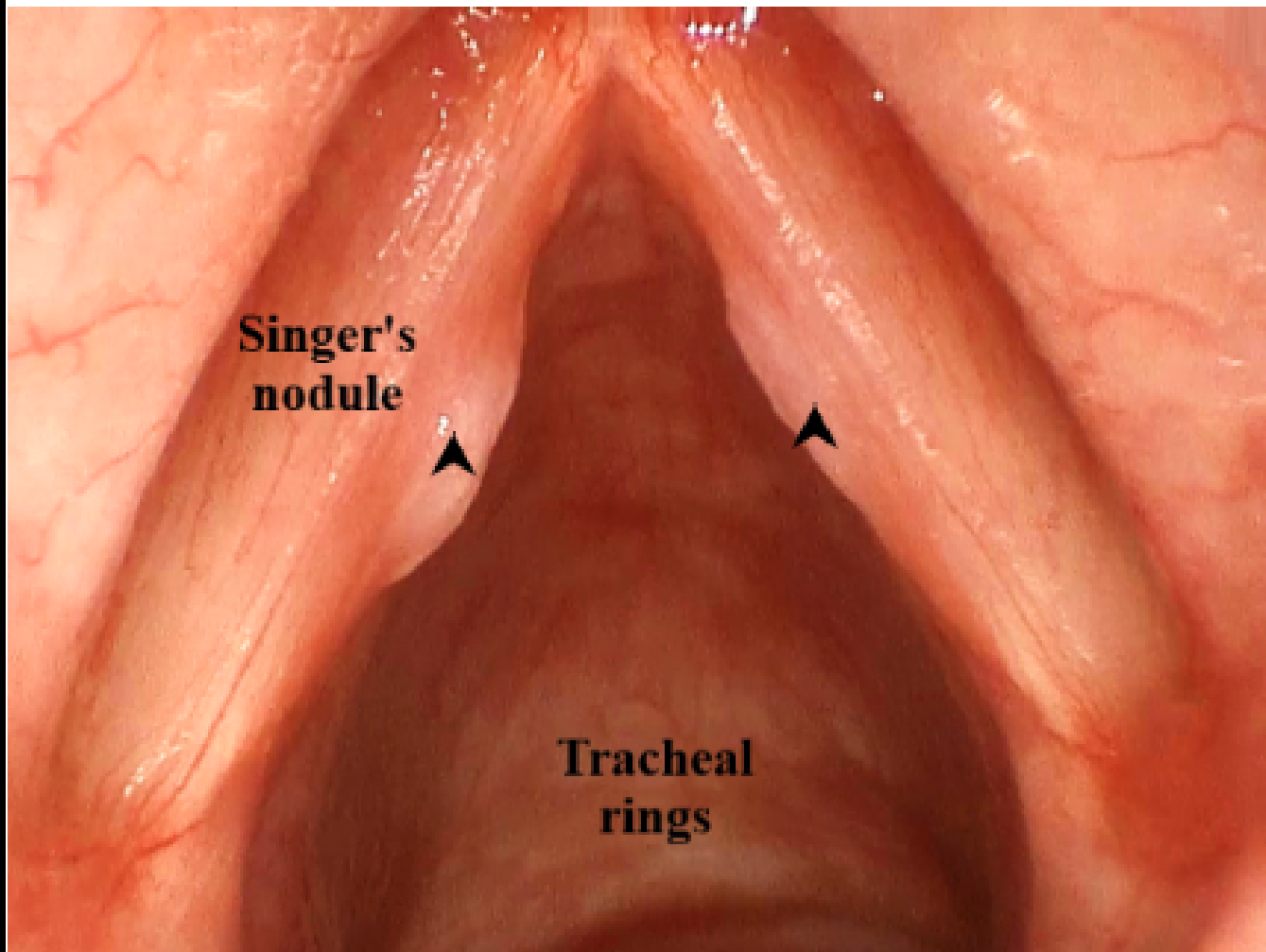
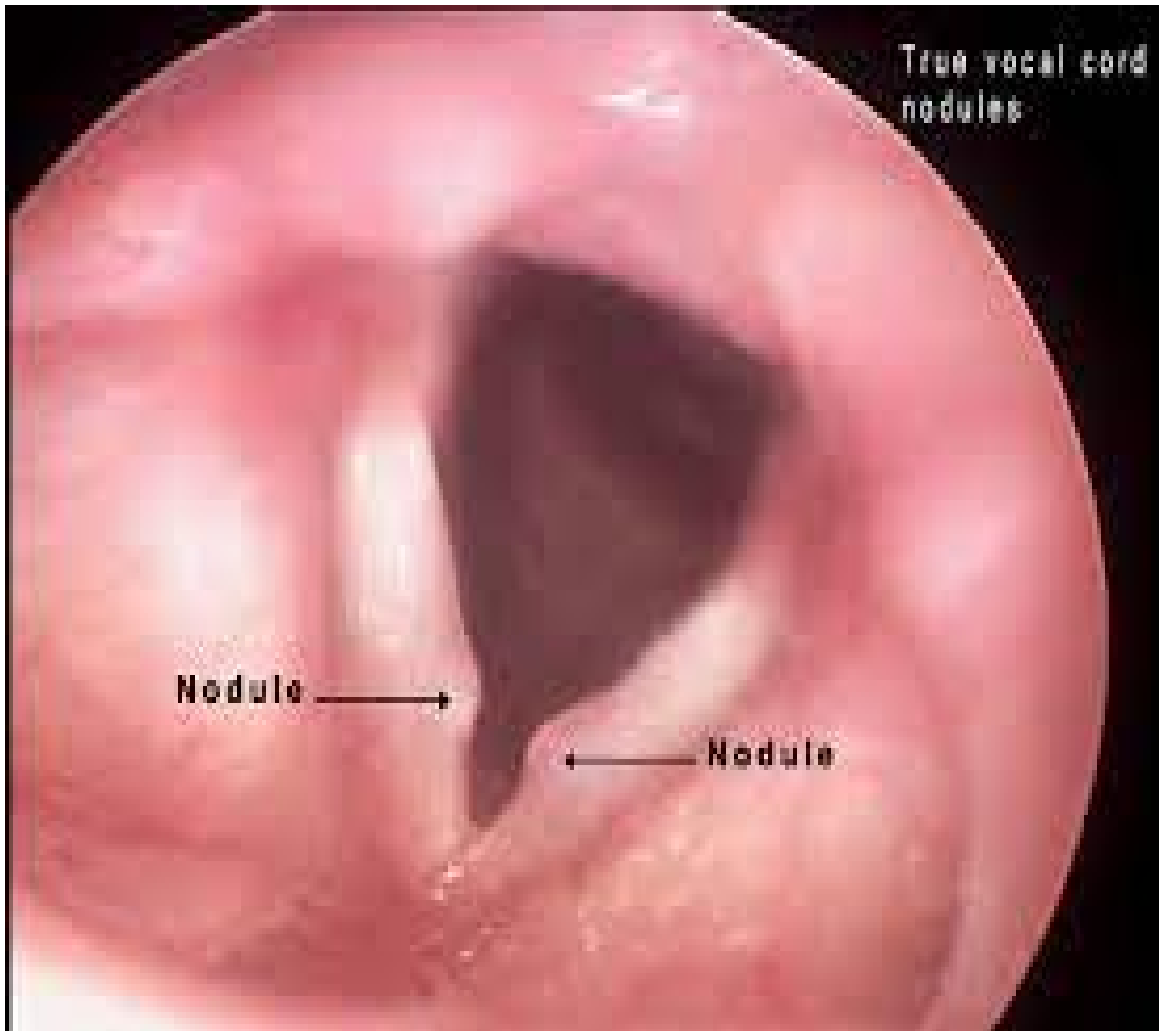



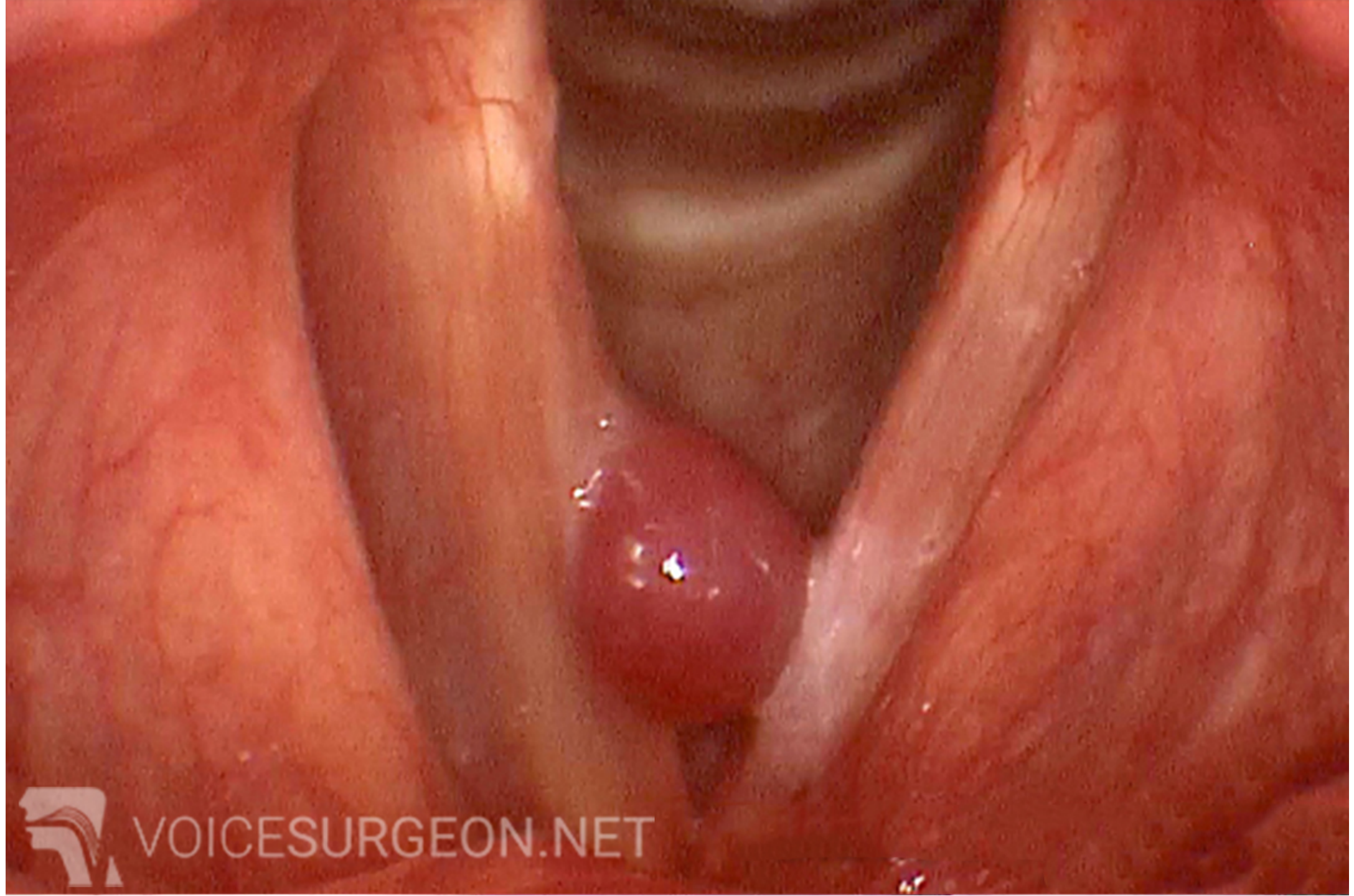





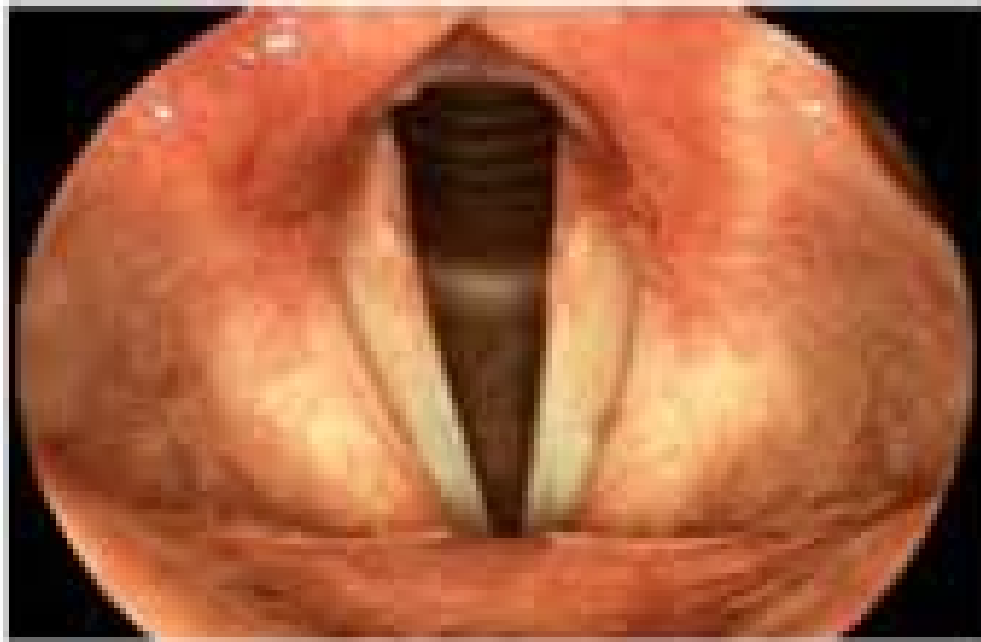




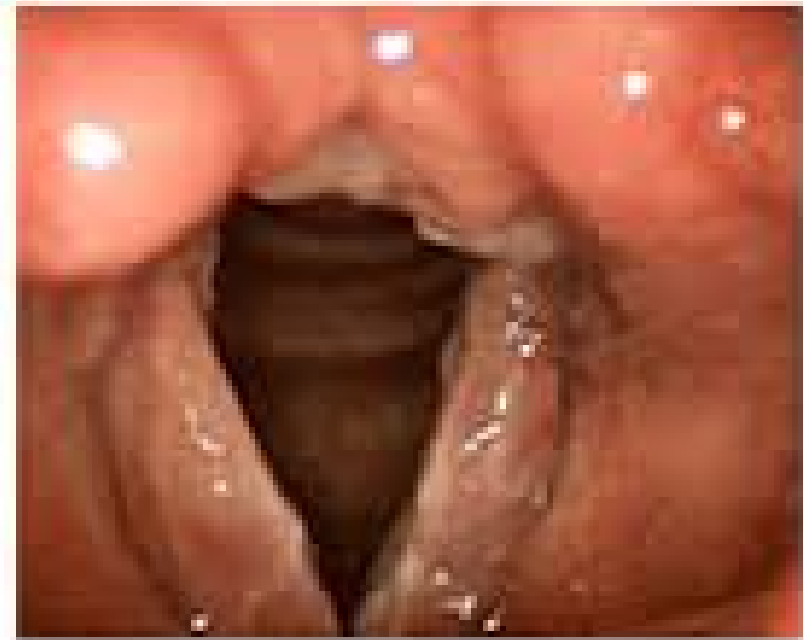

VOICESURGEON.NET

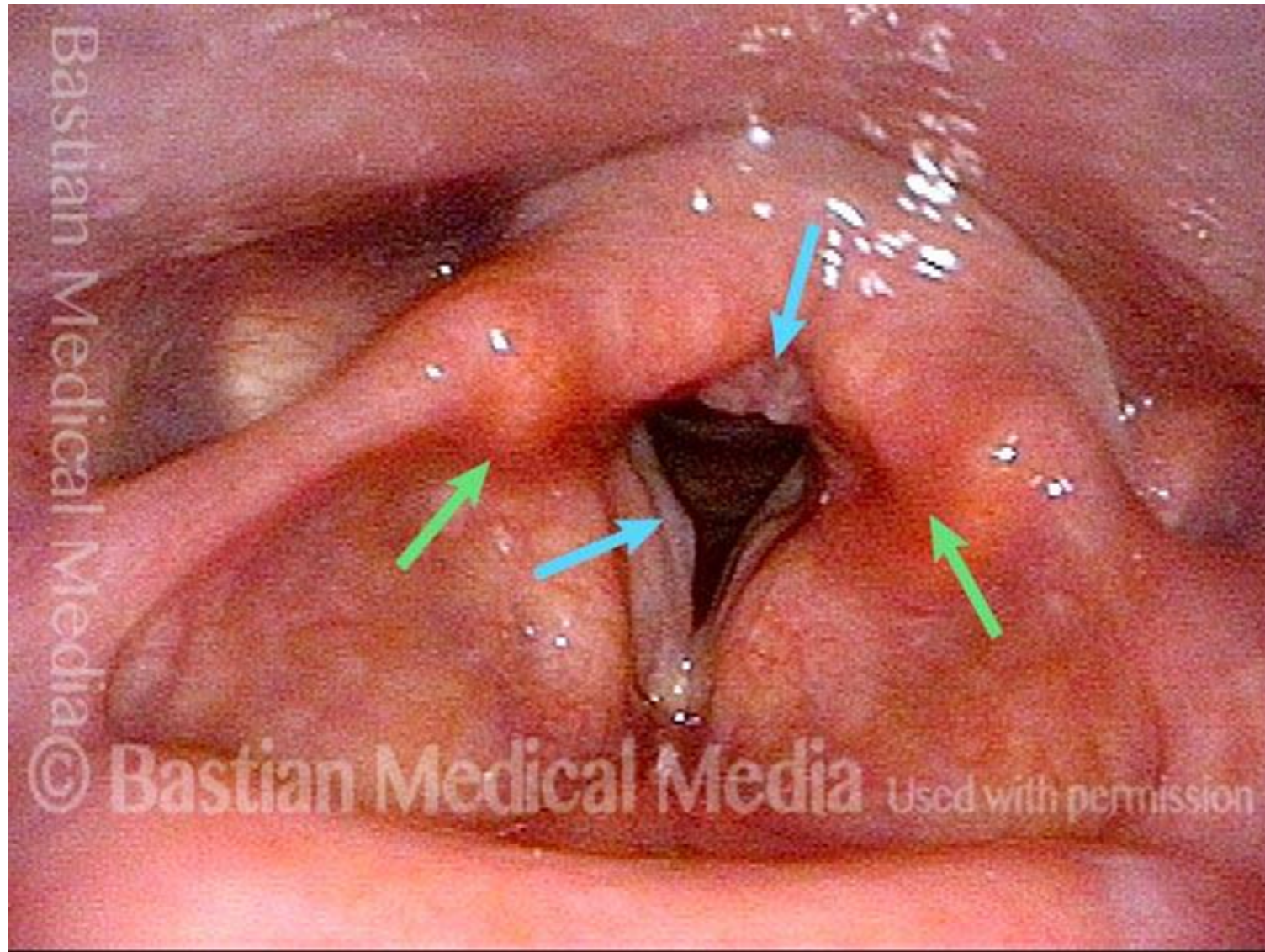


*Normal voice box*



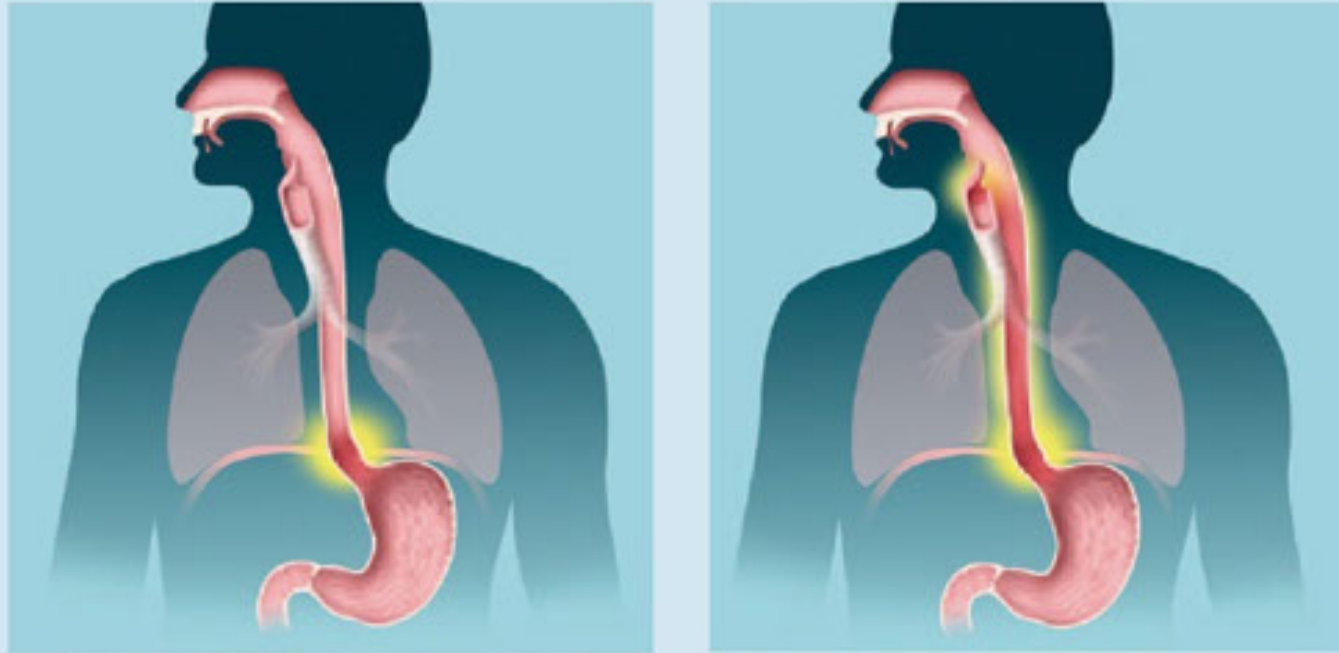*Non-smoker with severe reflux*





<b>GERD</b>	<b>LPR</b>
Accompanied by esophagitis and/or heartburn	Esophagitis or heartburn is rarely present
Reflux is nocturnal or in supine position	Reflux during daytime or in upright position
Abnormal esophageal motility and prolonged esophageal acid exposure	Intermittent episodes of reflux
Dysfunction of the lower esophageal sphincter	Dysfunction of the upper esophageal sphincter
Throat related symptoms are sometimes present	Leads to throat related symptoms and damage to the laryngopharyngeal epithelium

FIGURE 1



In patients with GERD (left), gastric contents back up into the esophagus, producing tissue damage or esophagitis and heartburn. In those with LPR (right), stomach acid comes up into the throat, causing irritation and changes in the larynx.

## GERD

- Heartburn
- Chest pain
- Sleep difficulty
- Stomach Bloating
- Tooth enamel decay

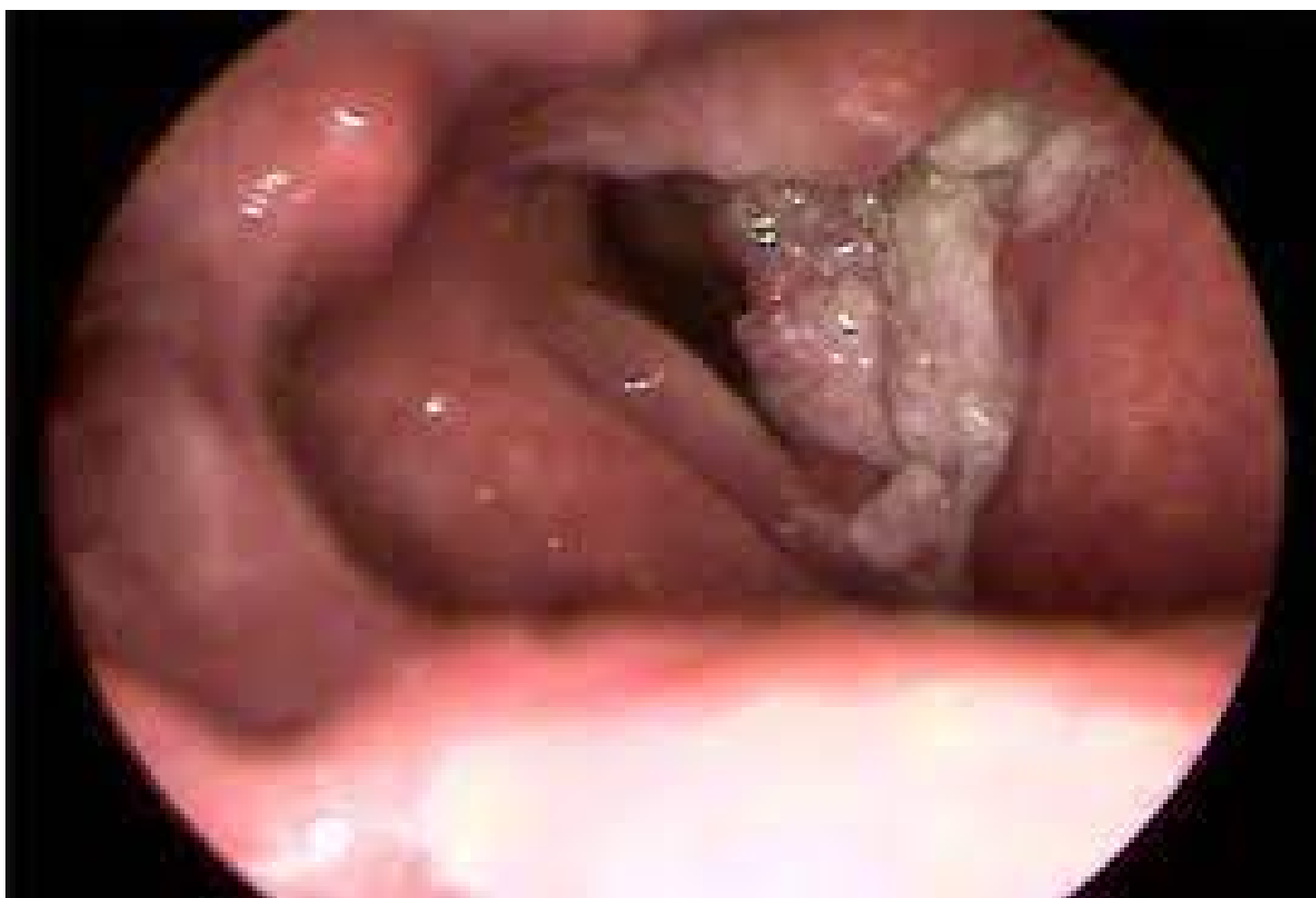Difficulty  
swallowing

Chronic cough

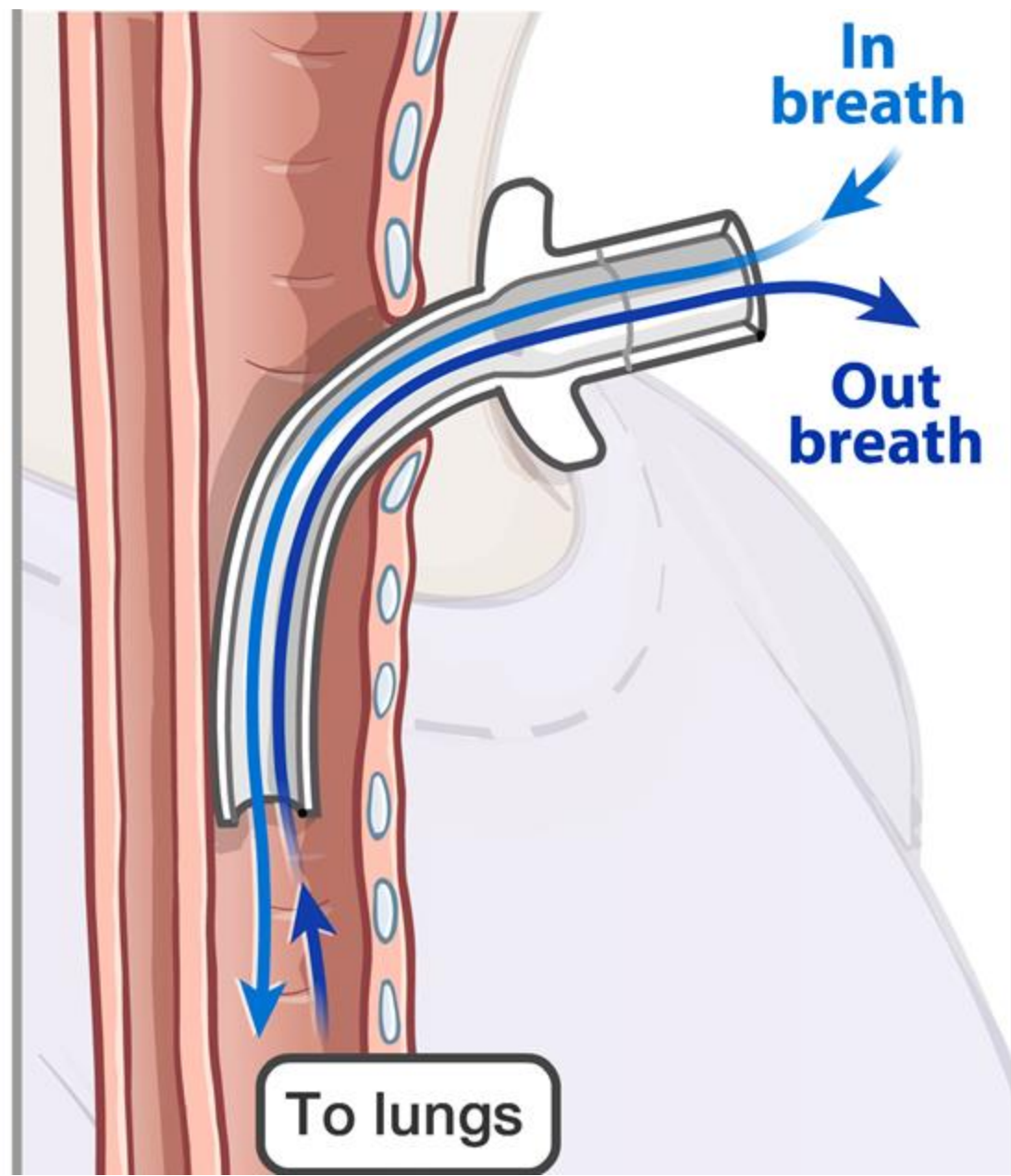
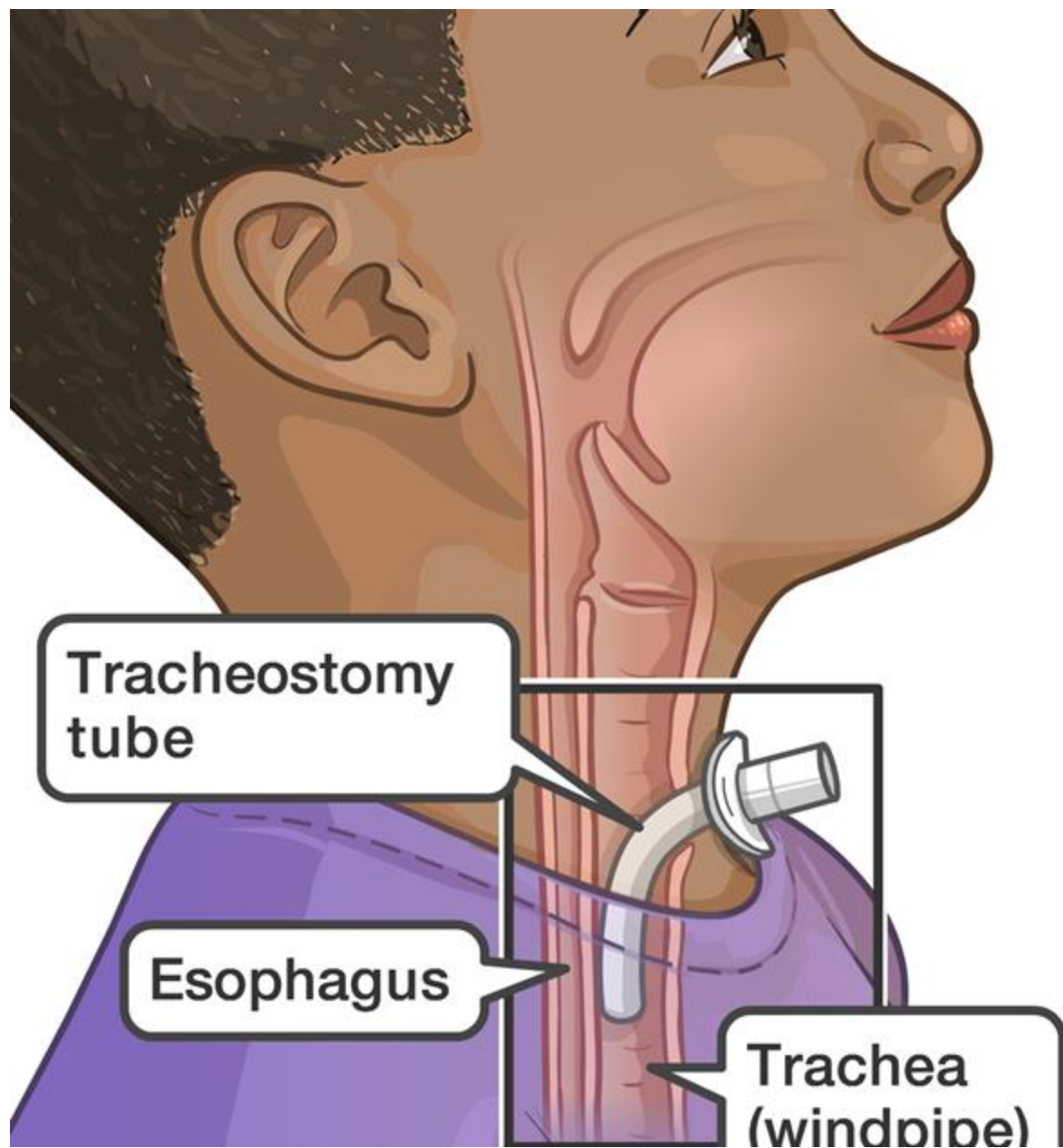
Regurgitation

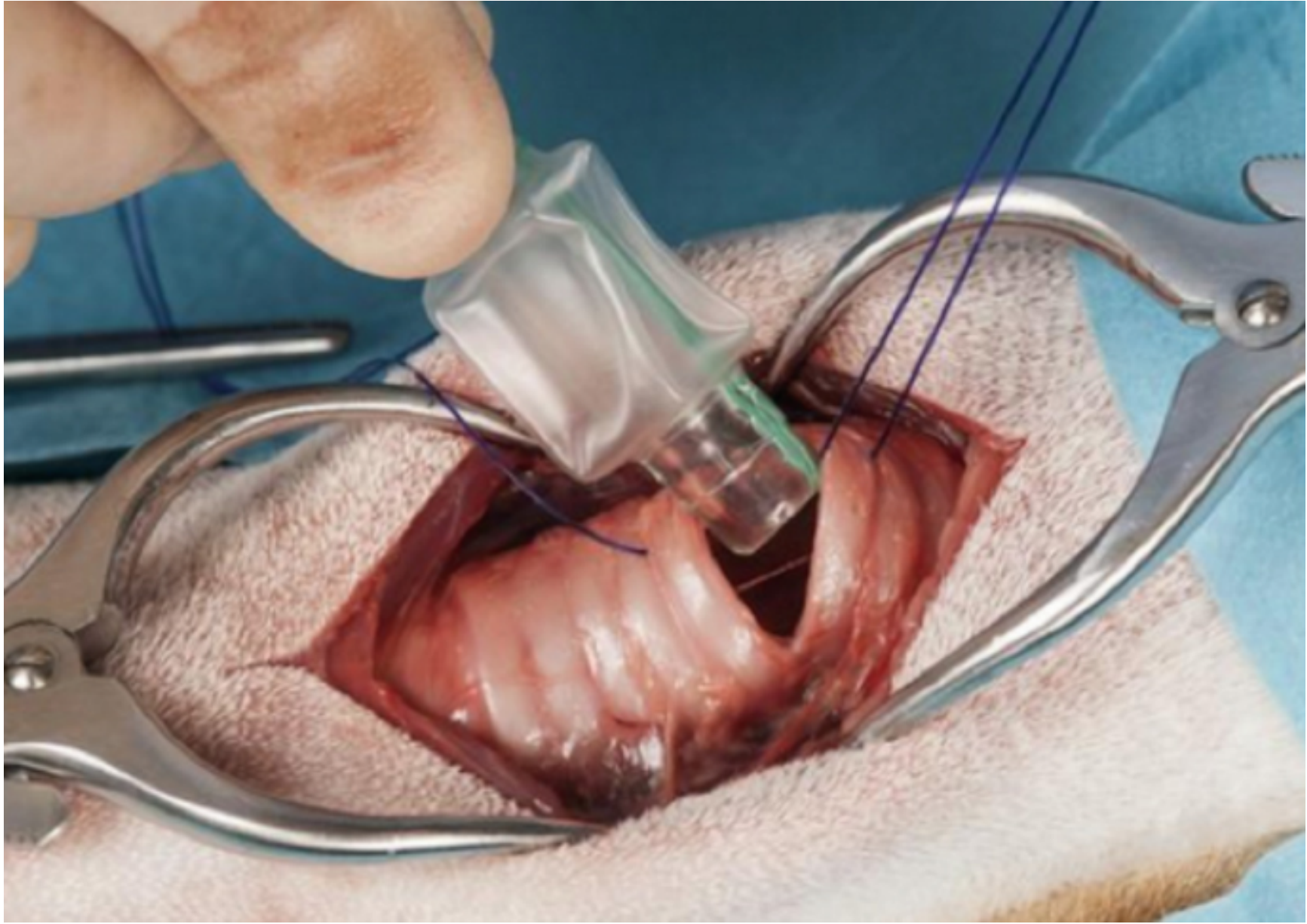
## LPR

- Hoarseness
- Post-nasal drip
- Sore/swollen voice box
- Shortness of breath

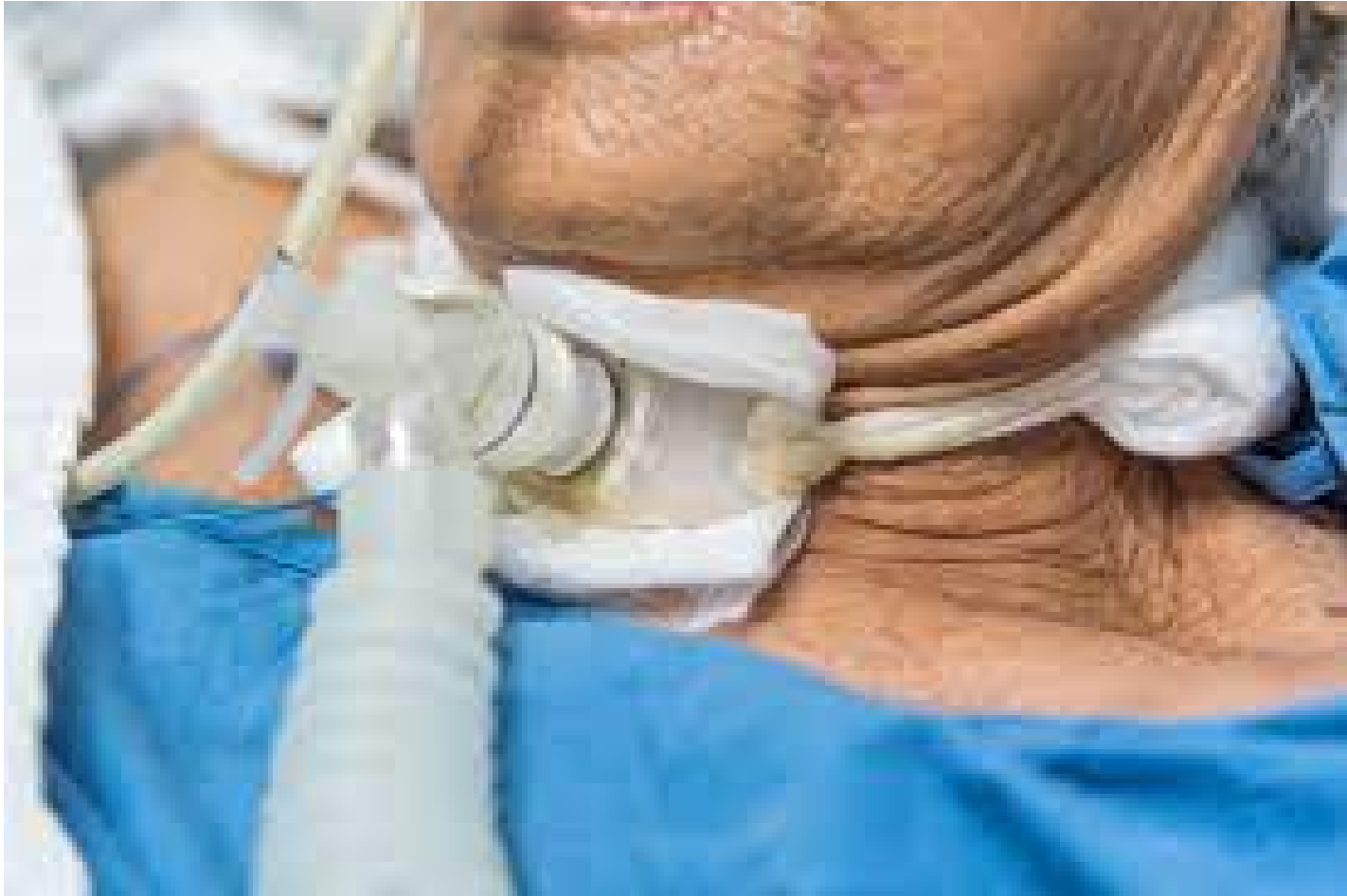

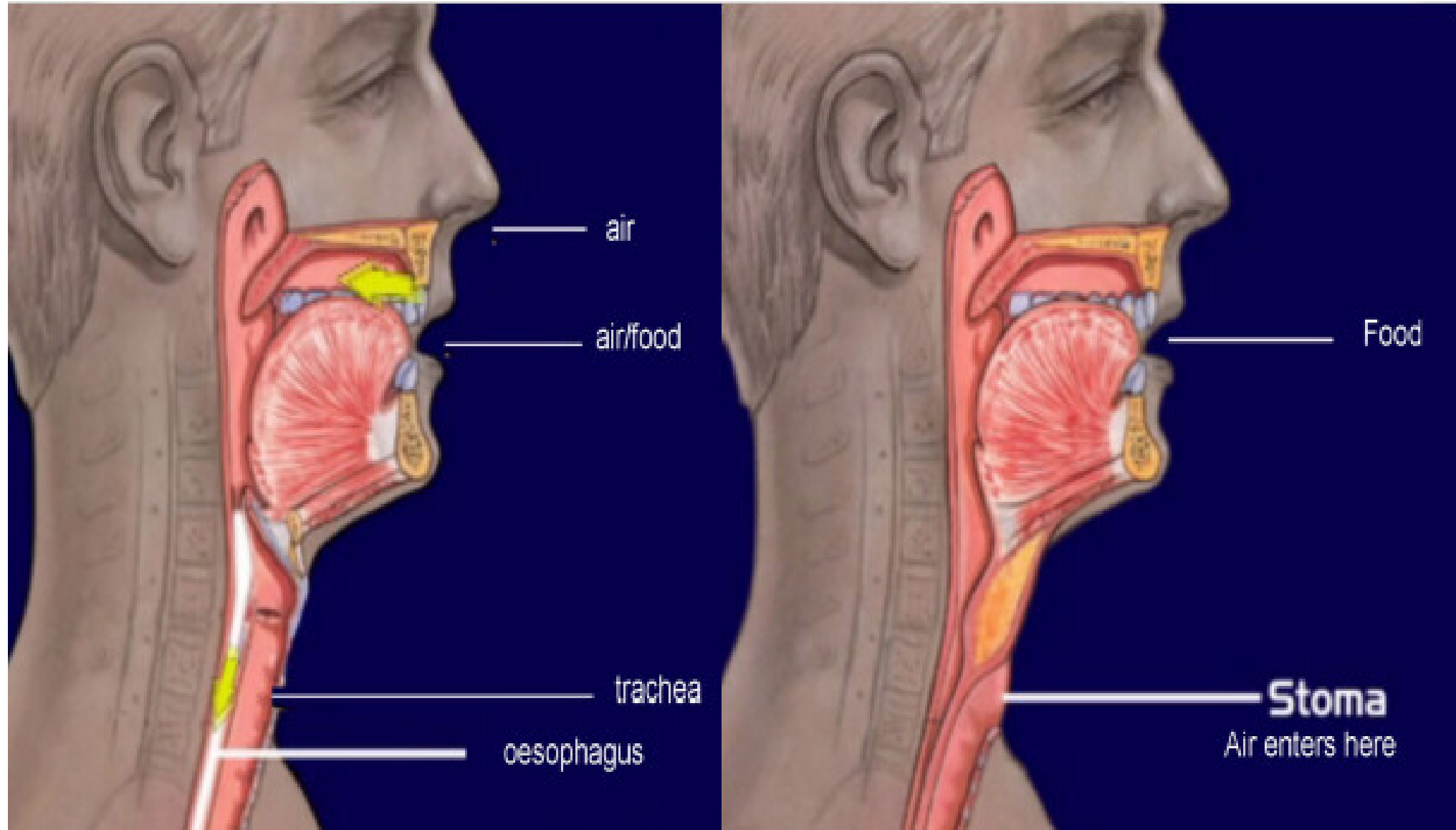



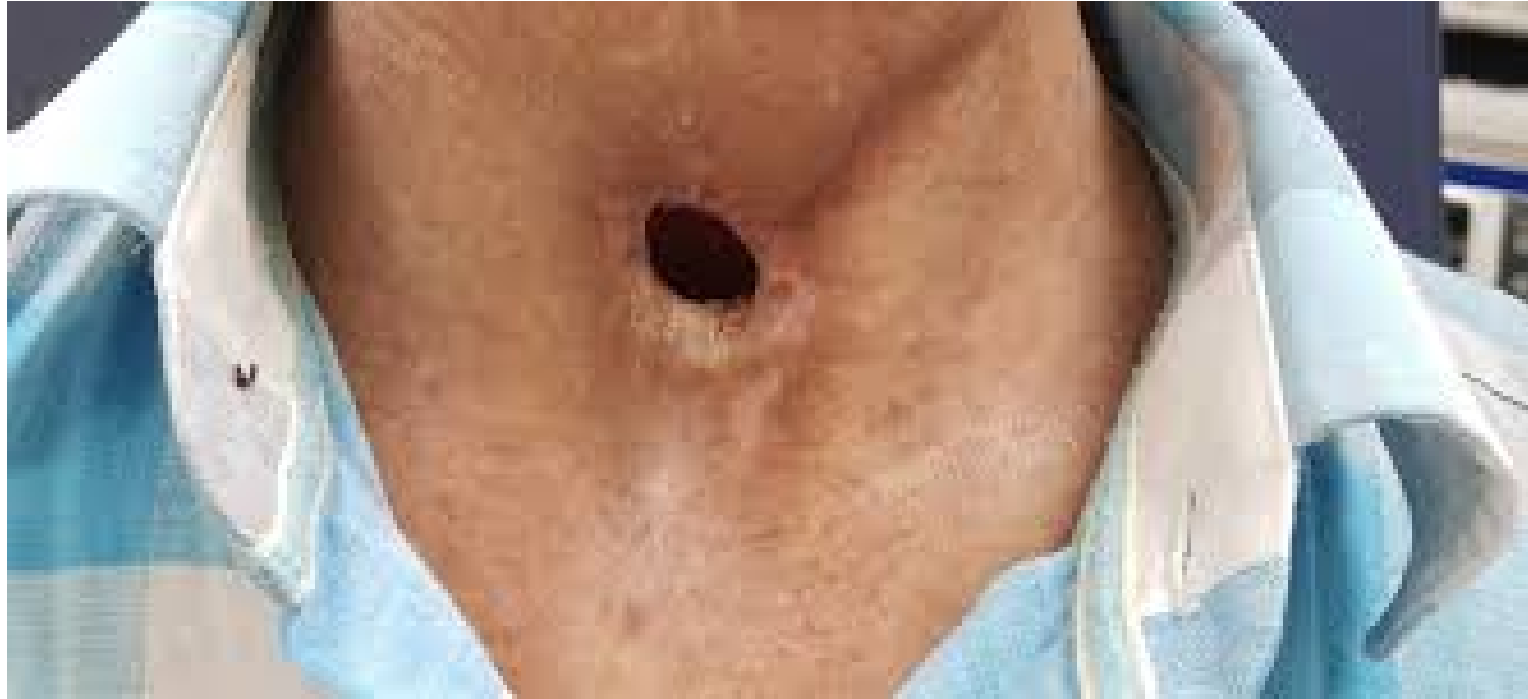


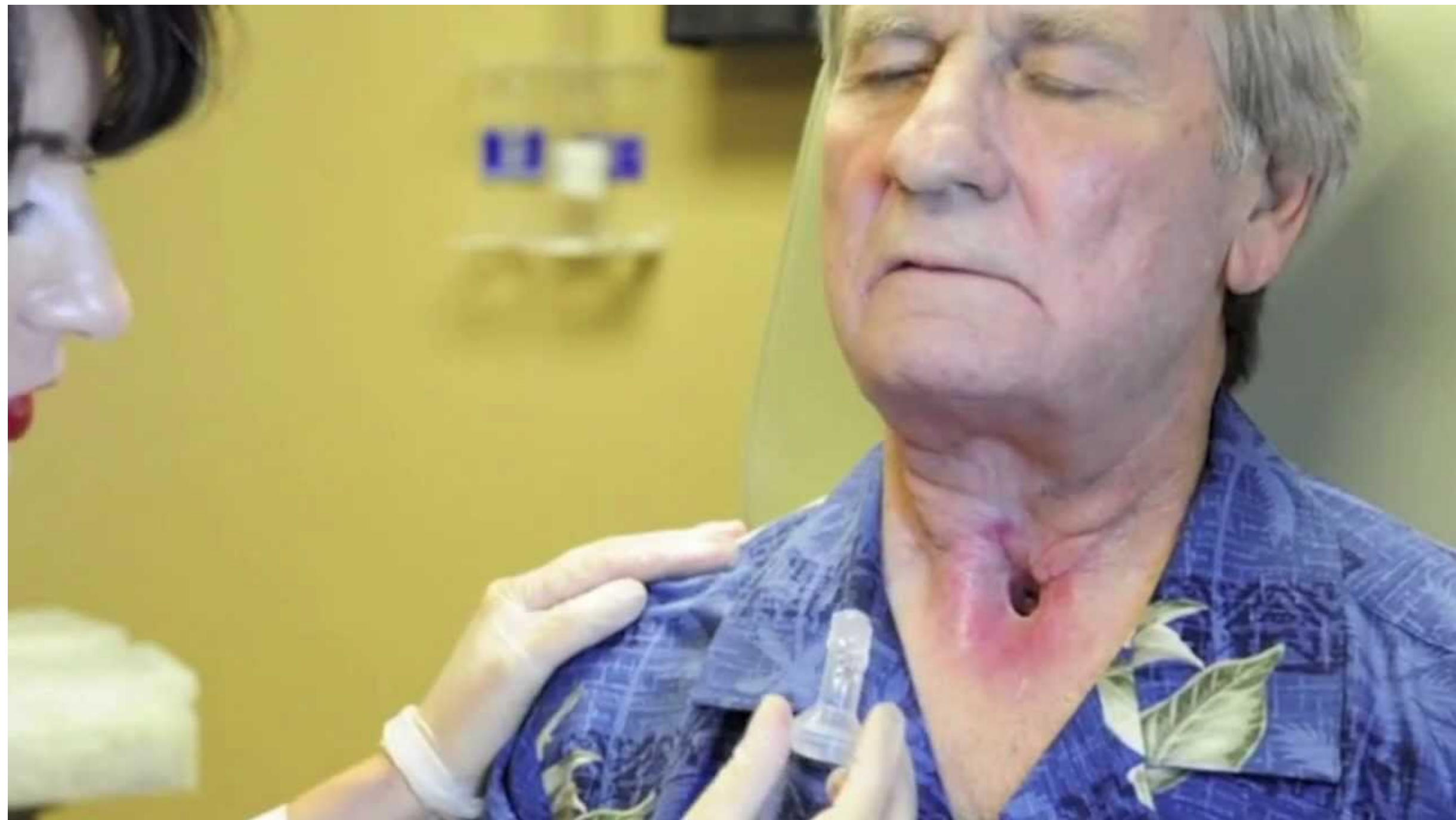


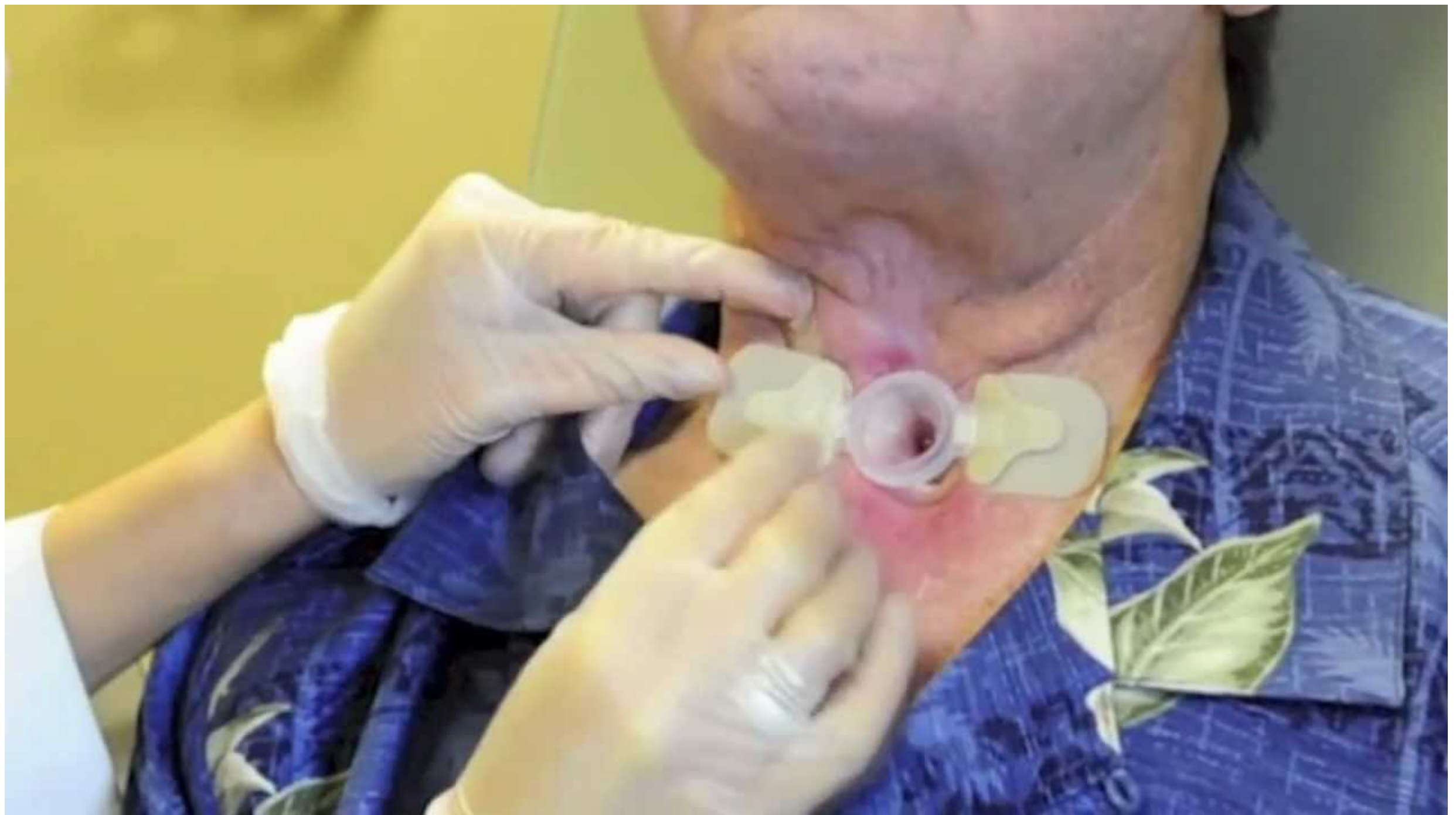






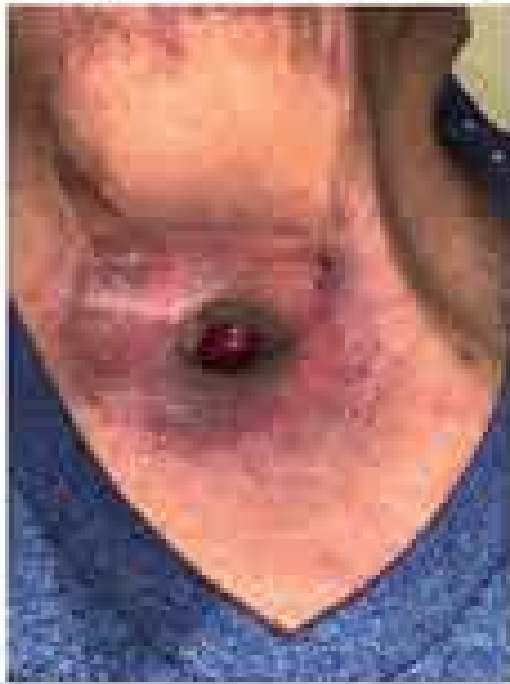

# Laryngectomy Airway Management

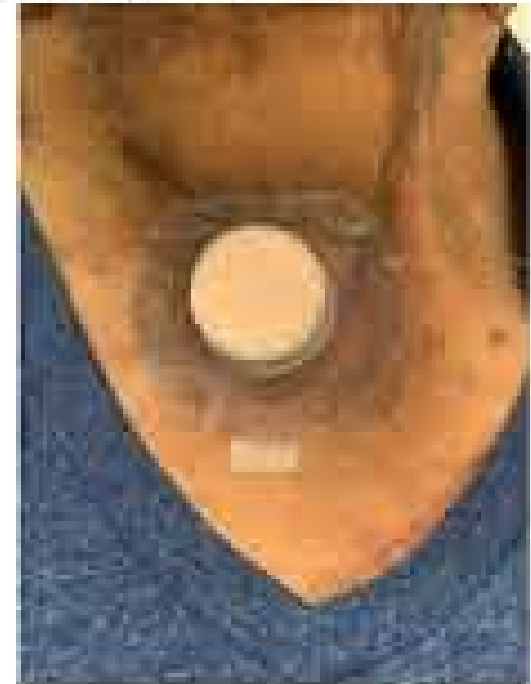- The stoma does not require a tube, but they are often used.
- May have a heat and moisture exchange (HME) in place.



Open Laryngectomy Stoma

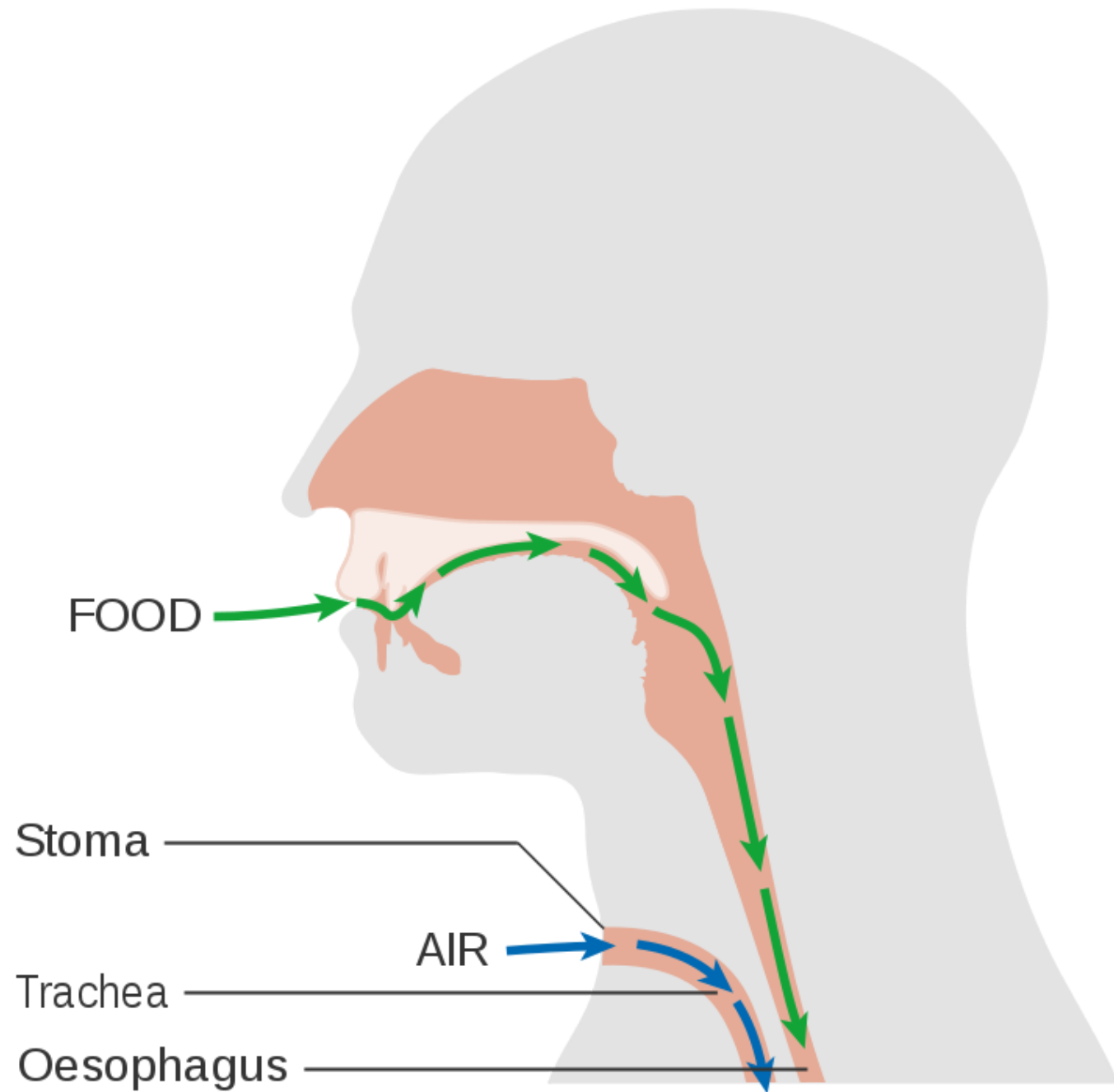


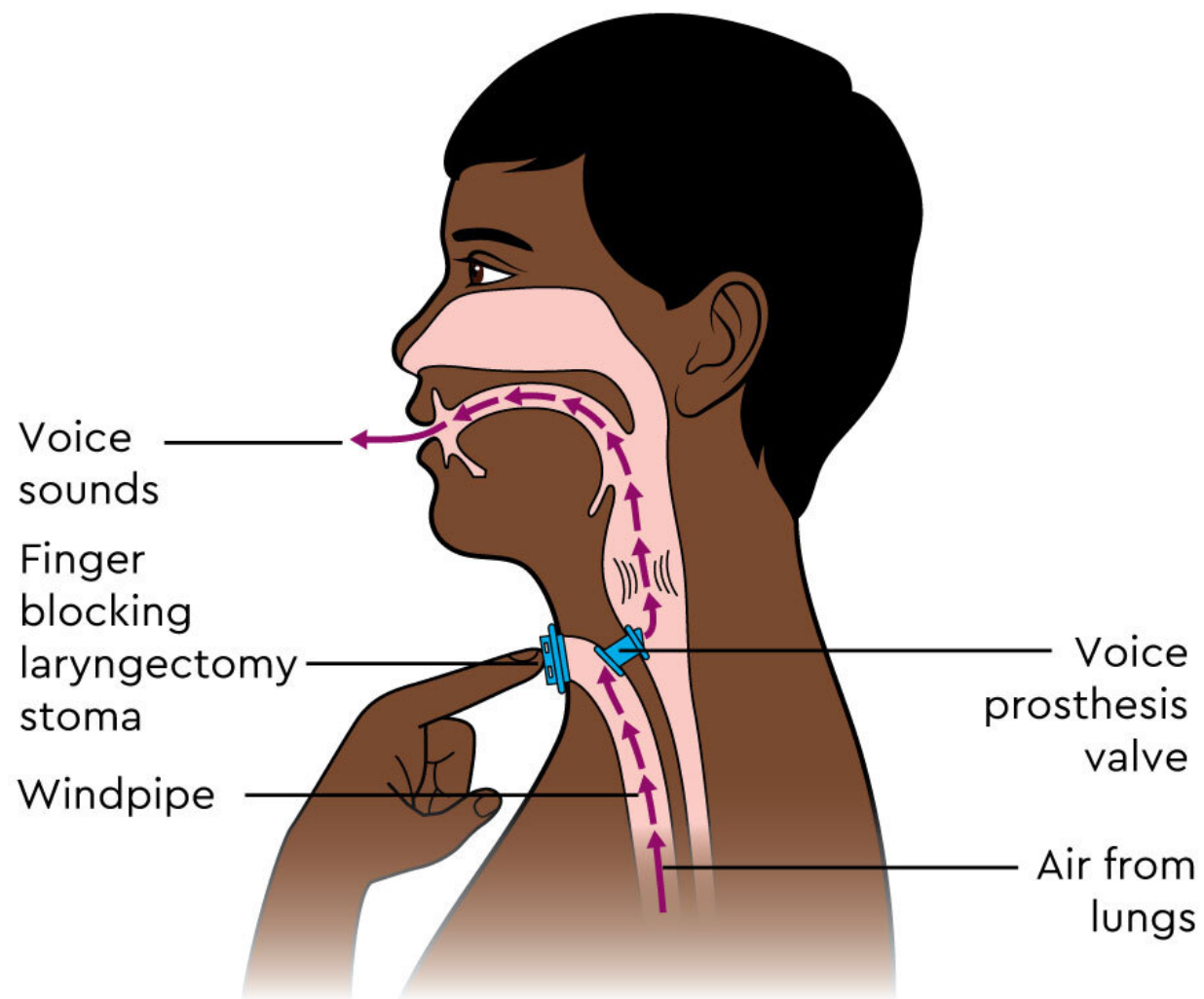
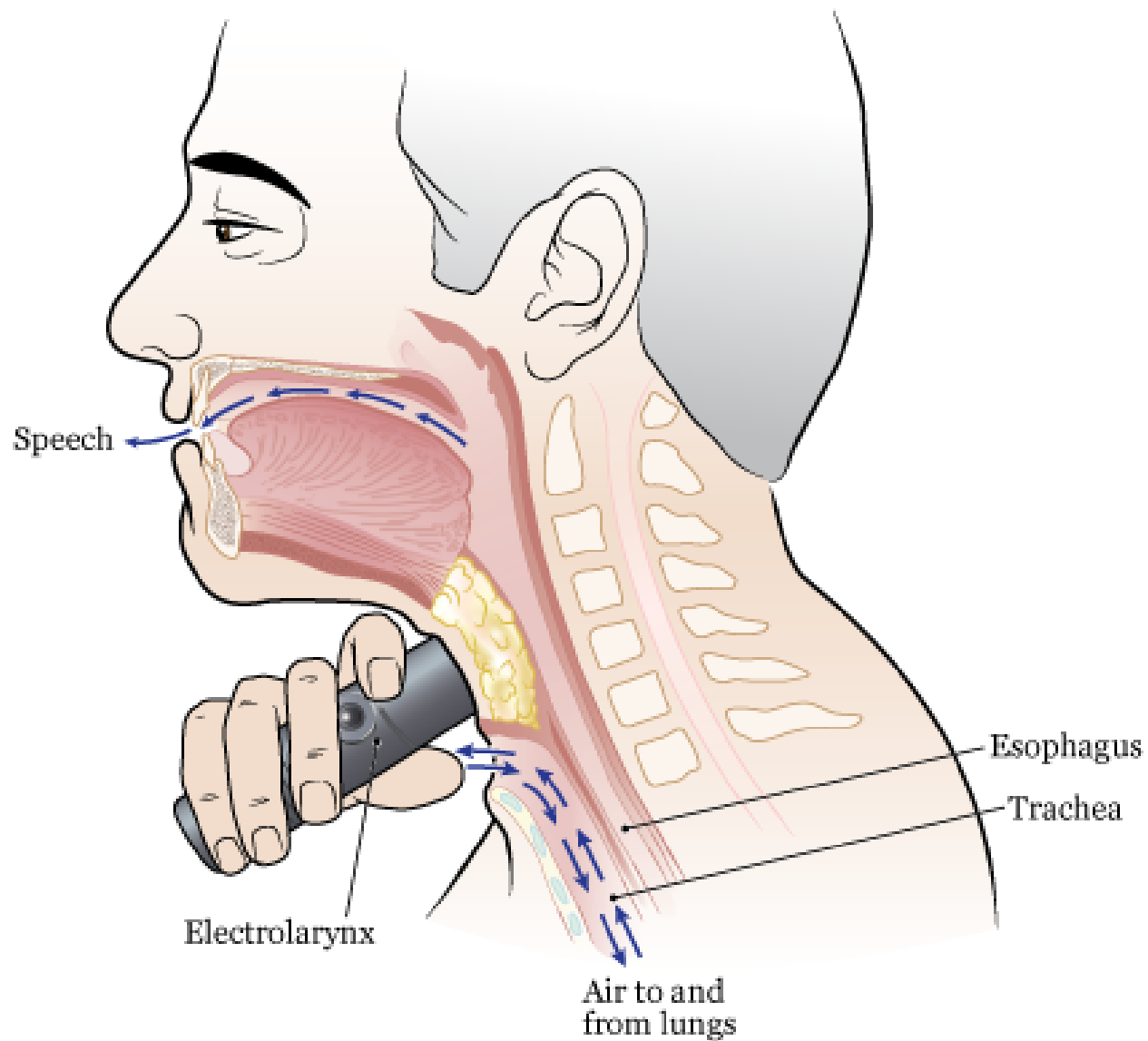
Laryngectomy with lary tube in place

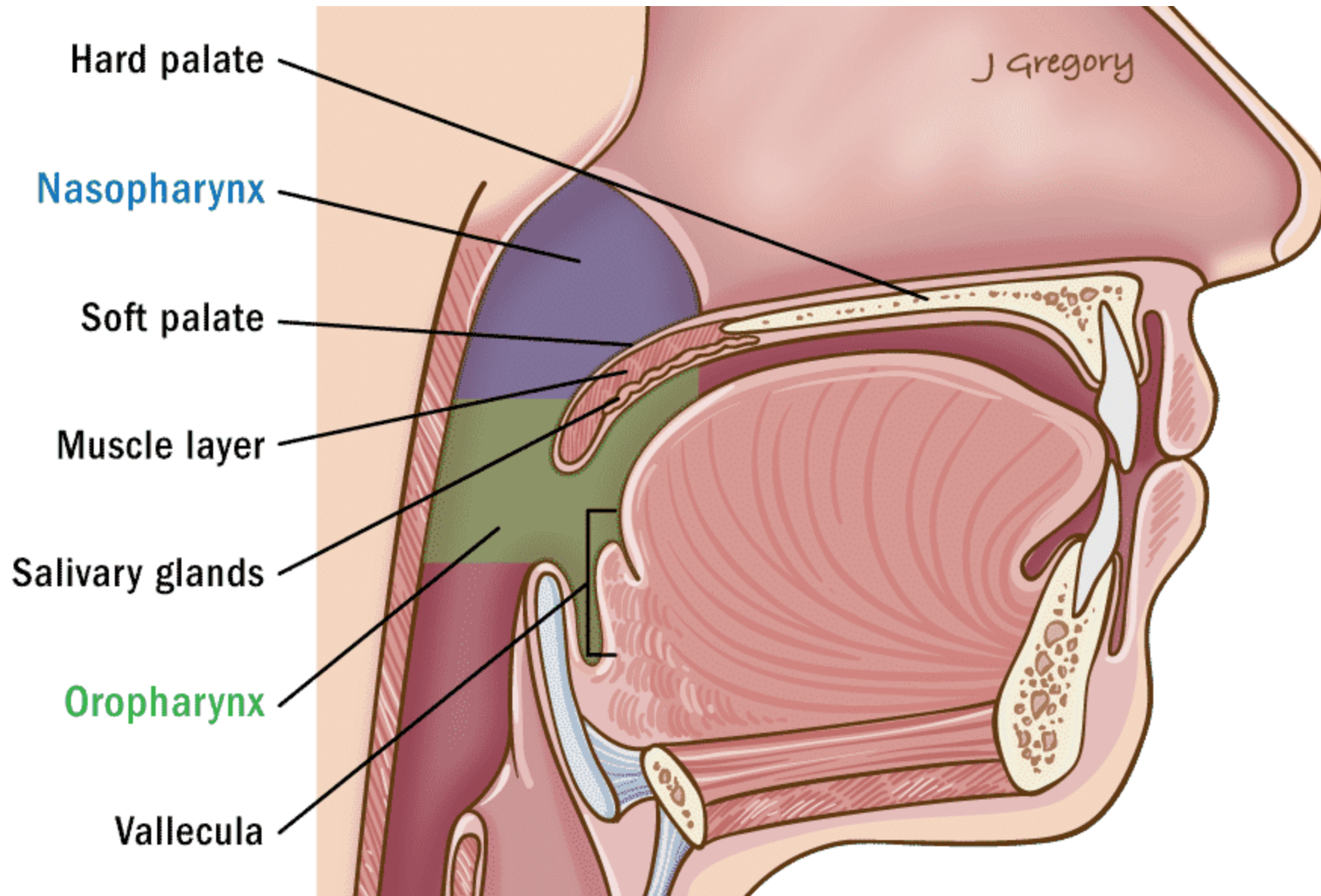


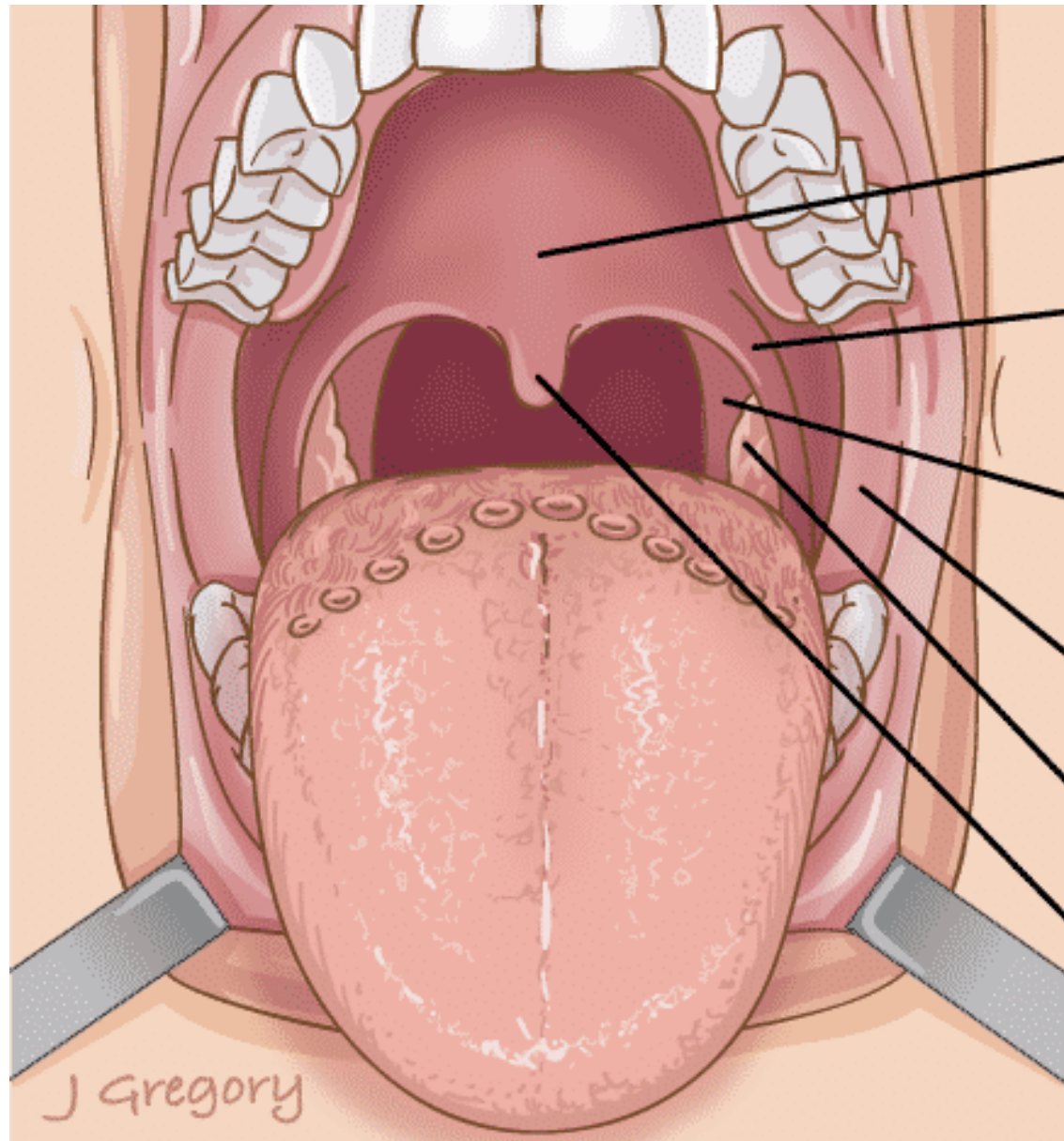
Laryngectomy with HME in place











Soft palate

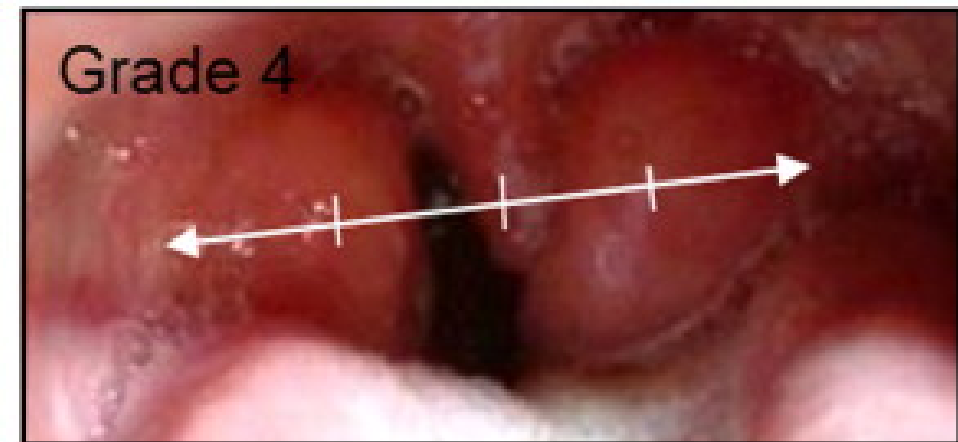
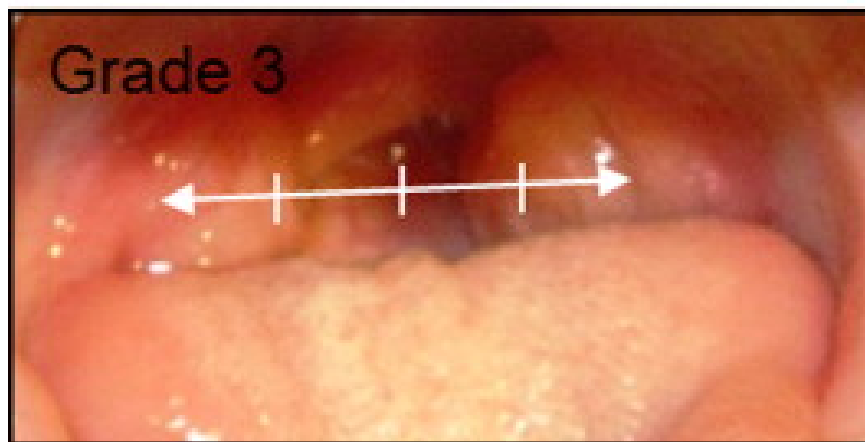
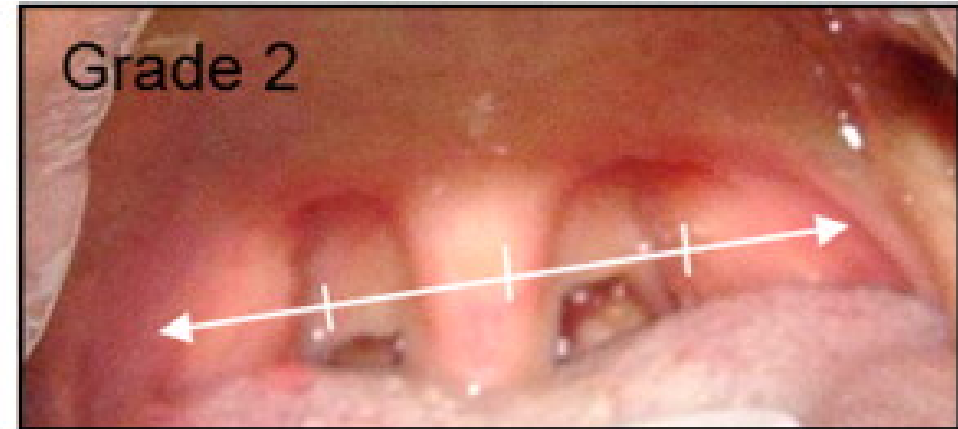
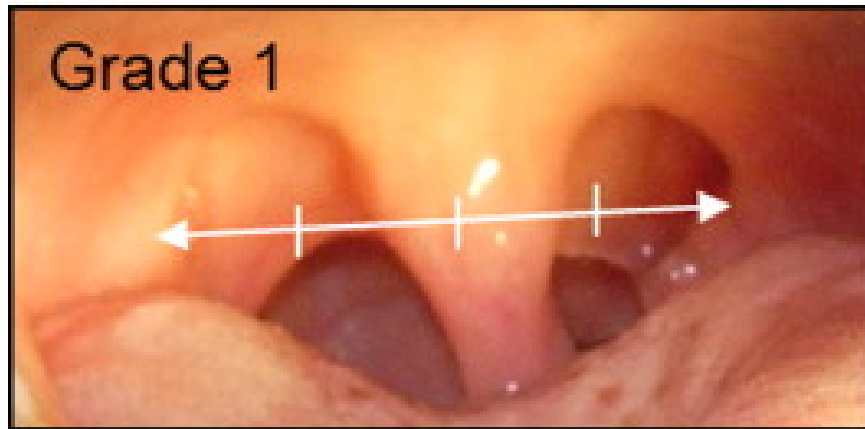
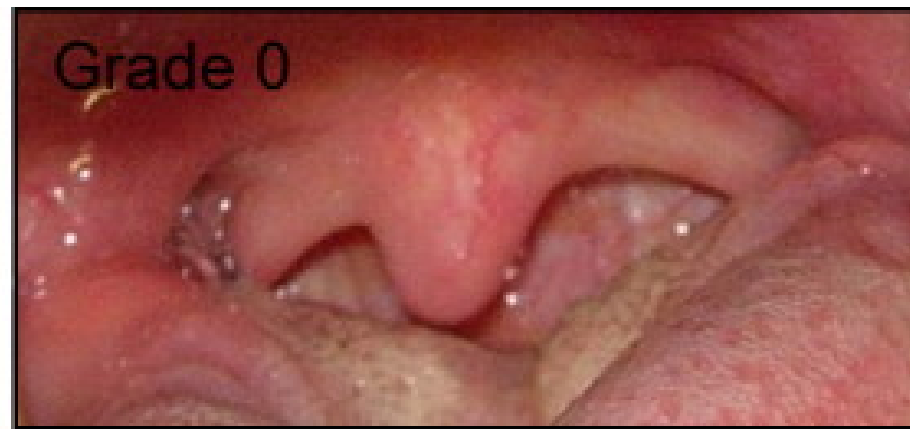Anterior tonsil pillar  
(palatoglossus)

Posterior tonsil pillar  
(palatopharyngeus)

Retromolar trigone

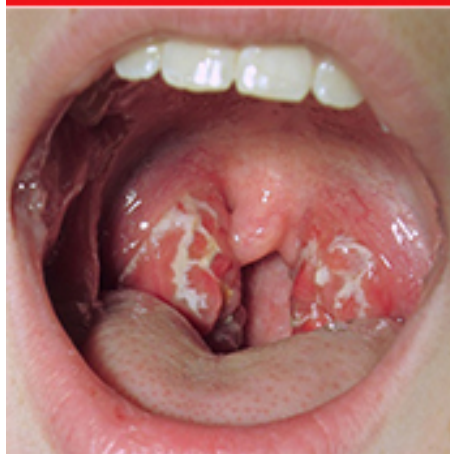Tonsillar fossa

Uvula

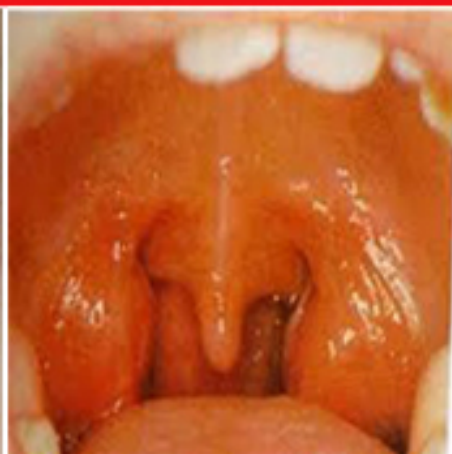



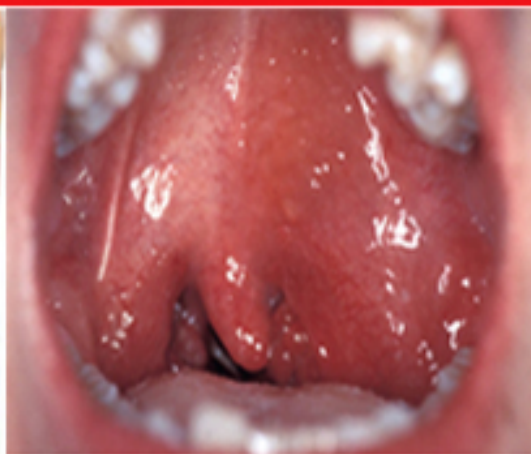# CONDITION OF TONSILLITIS



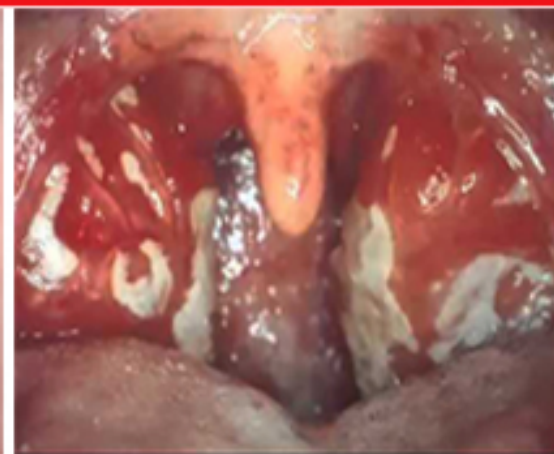1. Acute Tonsillitis



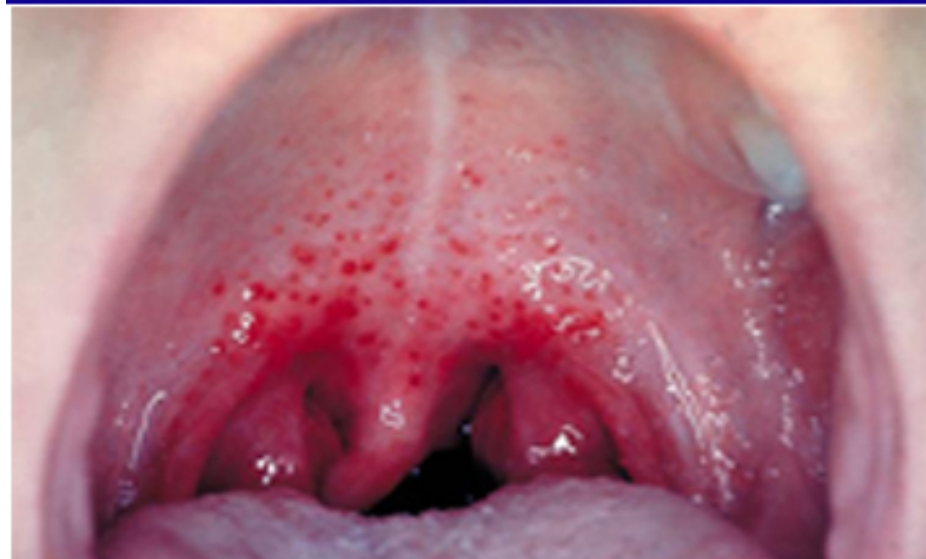2. Chronic Tonsillitis



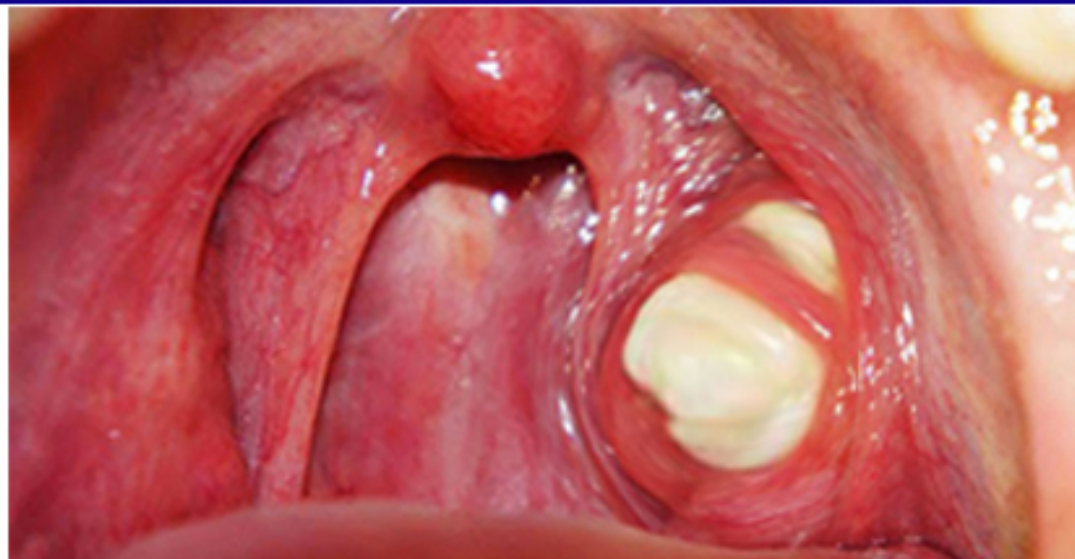3. Peritonsillar Abscess



4. Acute mononucleosis

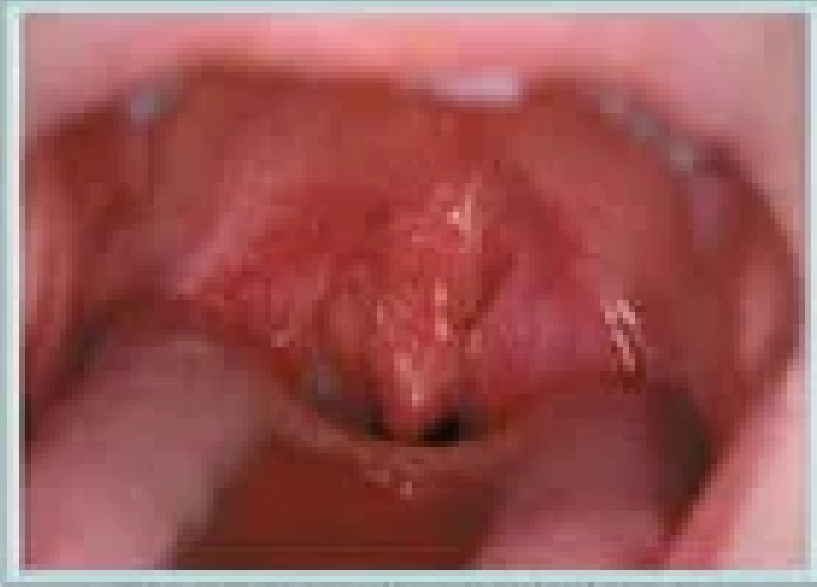

5. Strep throat

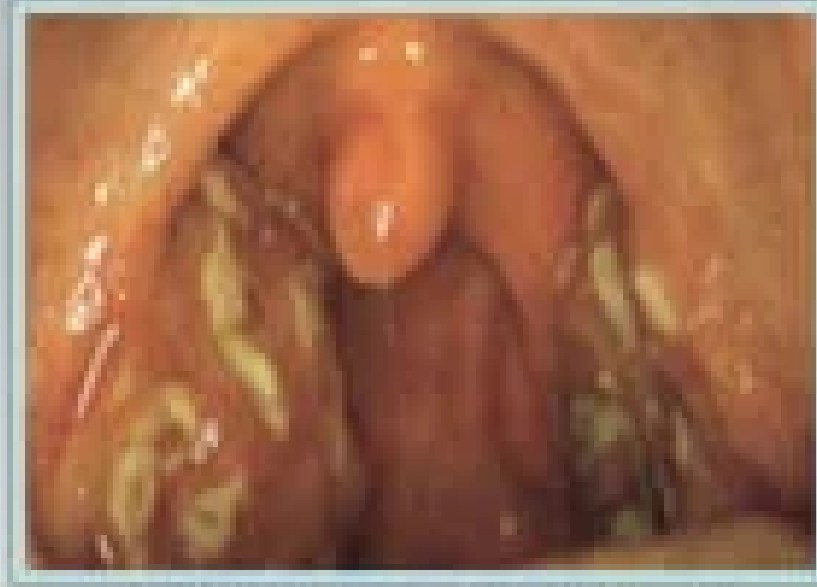

6. Tonsilloliths (Tonsil Stones)

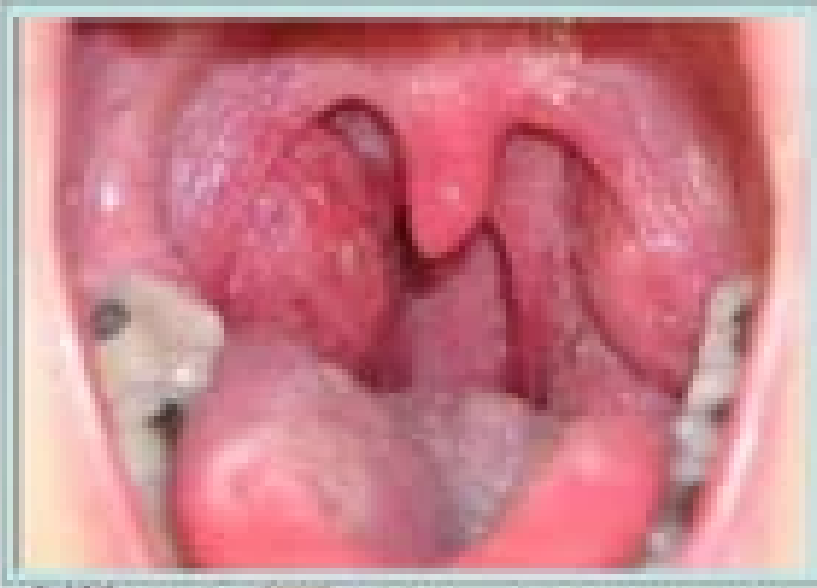



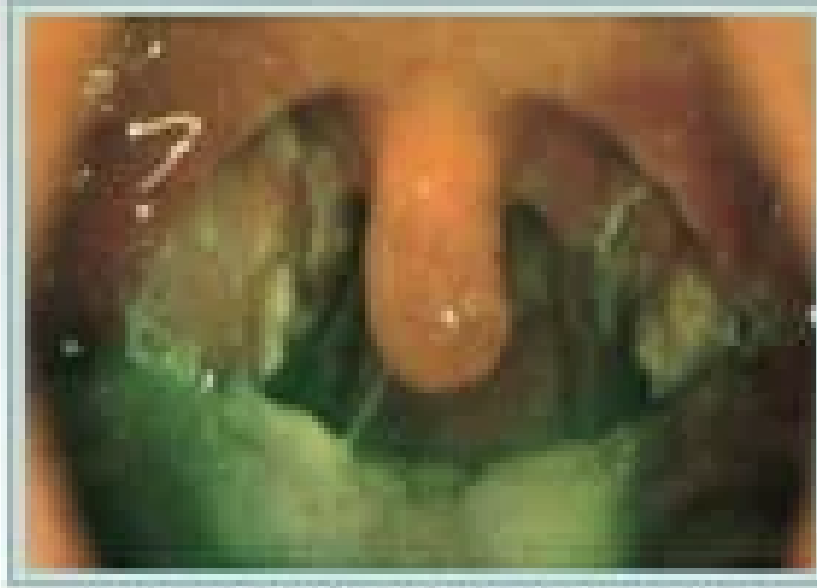**CATARRHAL TONSILLITIS**



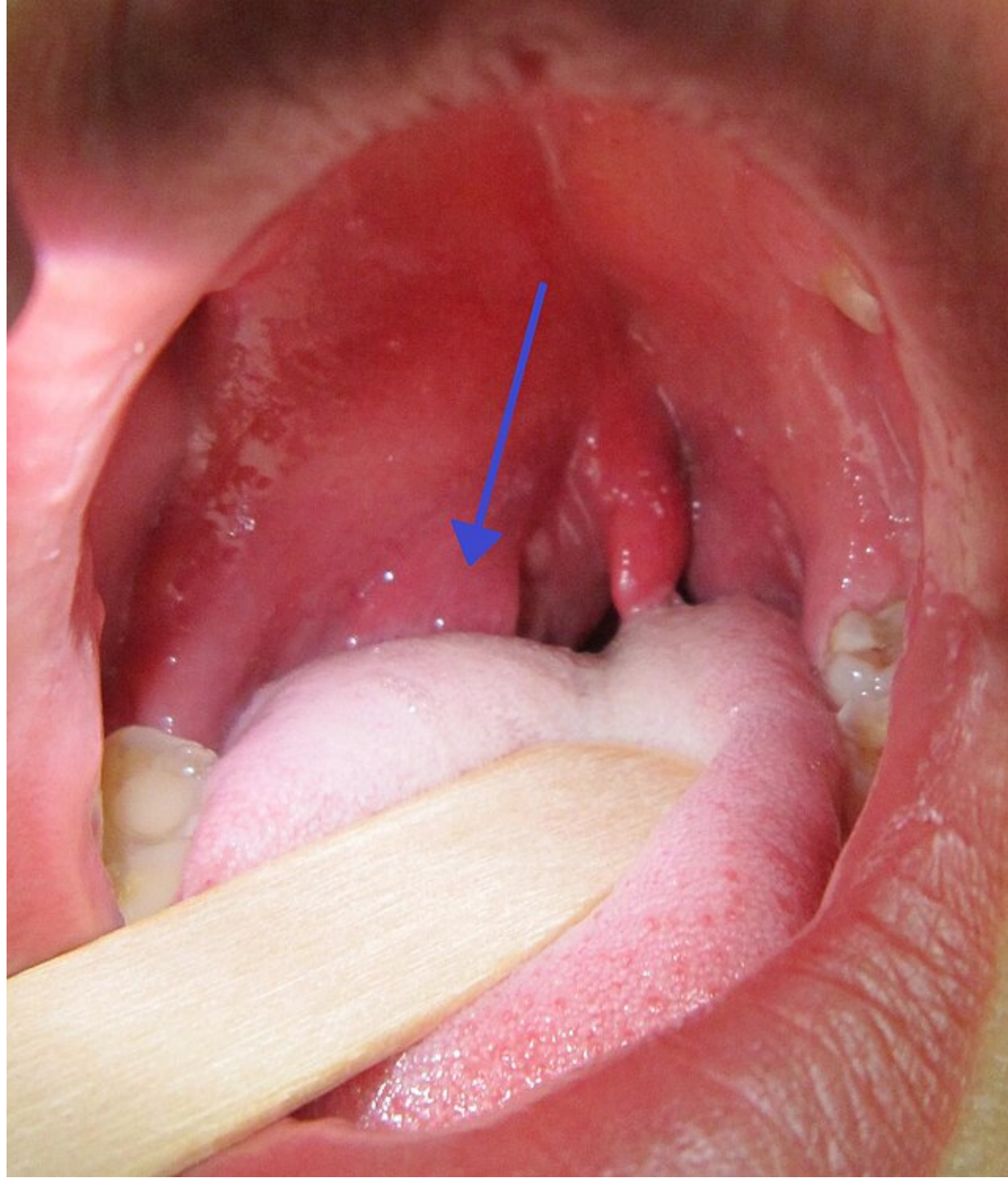
**FOLLICULAR TONSILLITIS**

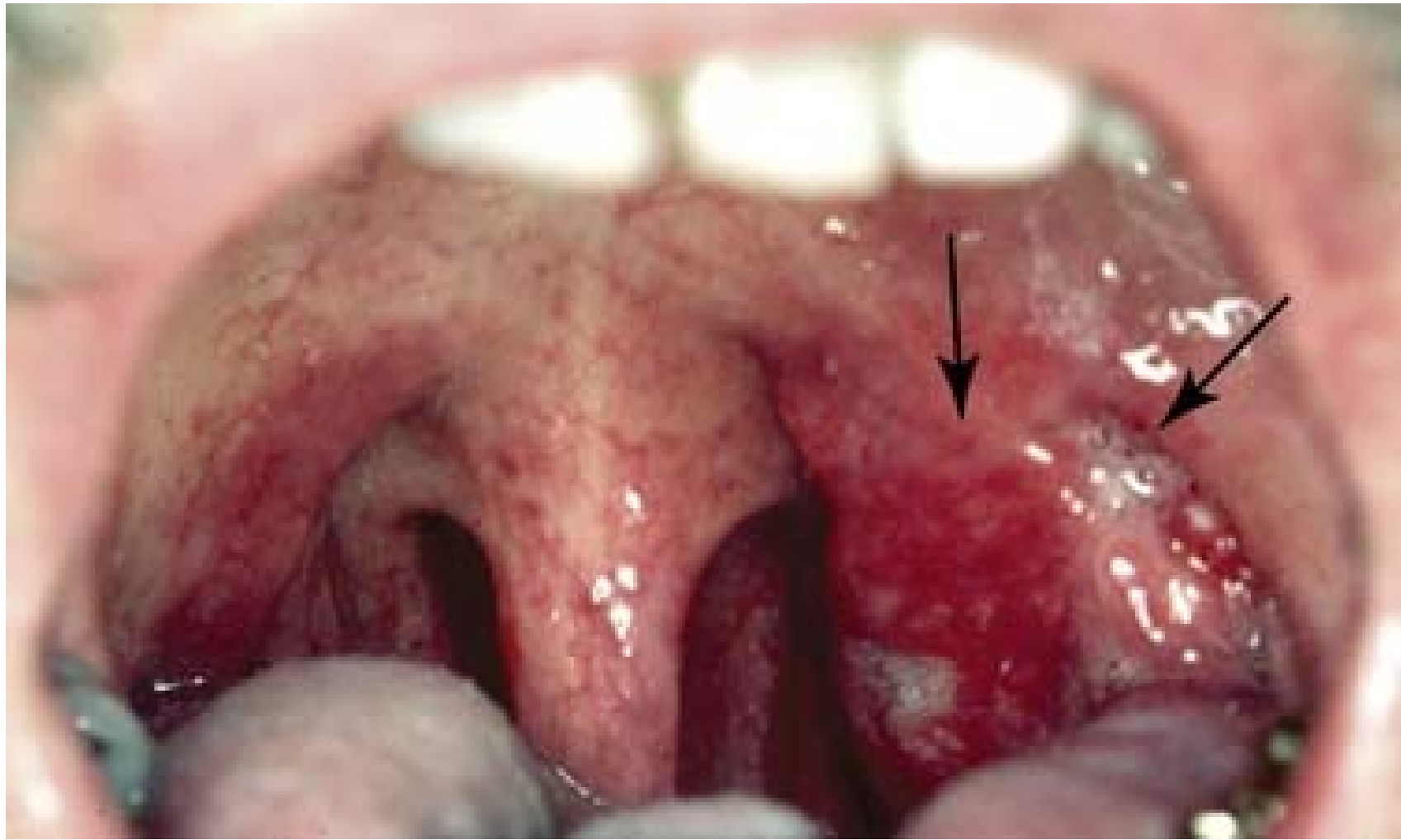

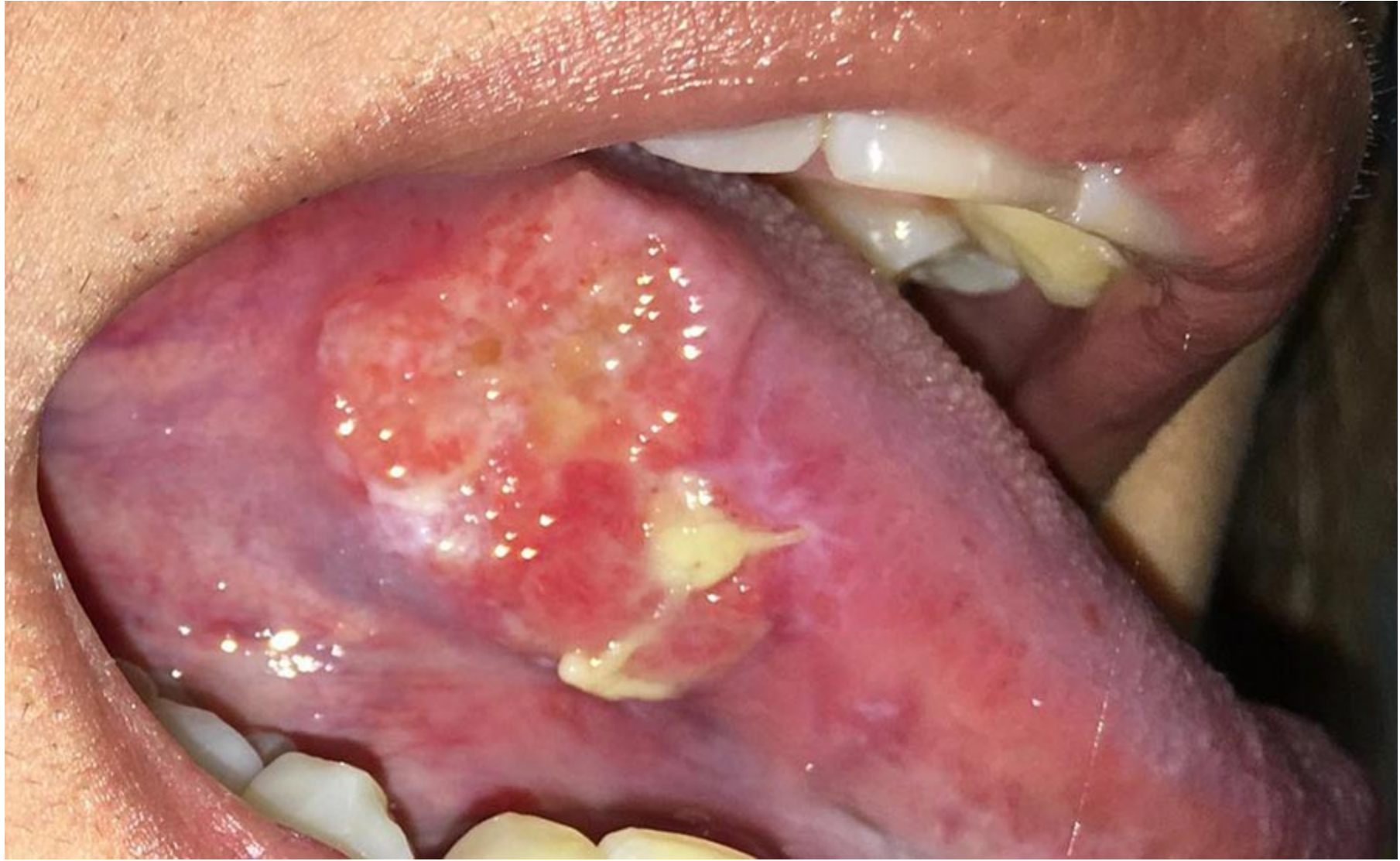**PARENCHYMATOUS TONSILLITIS**

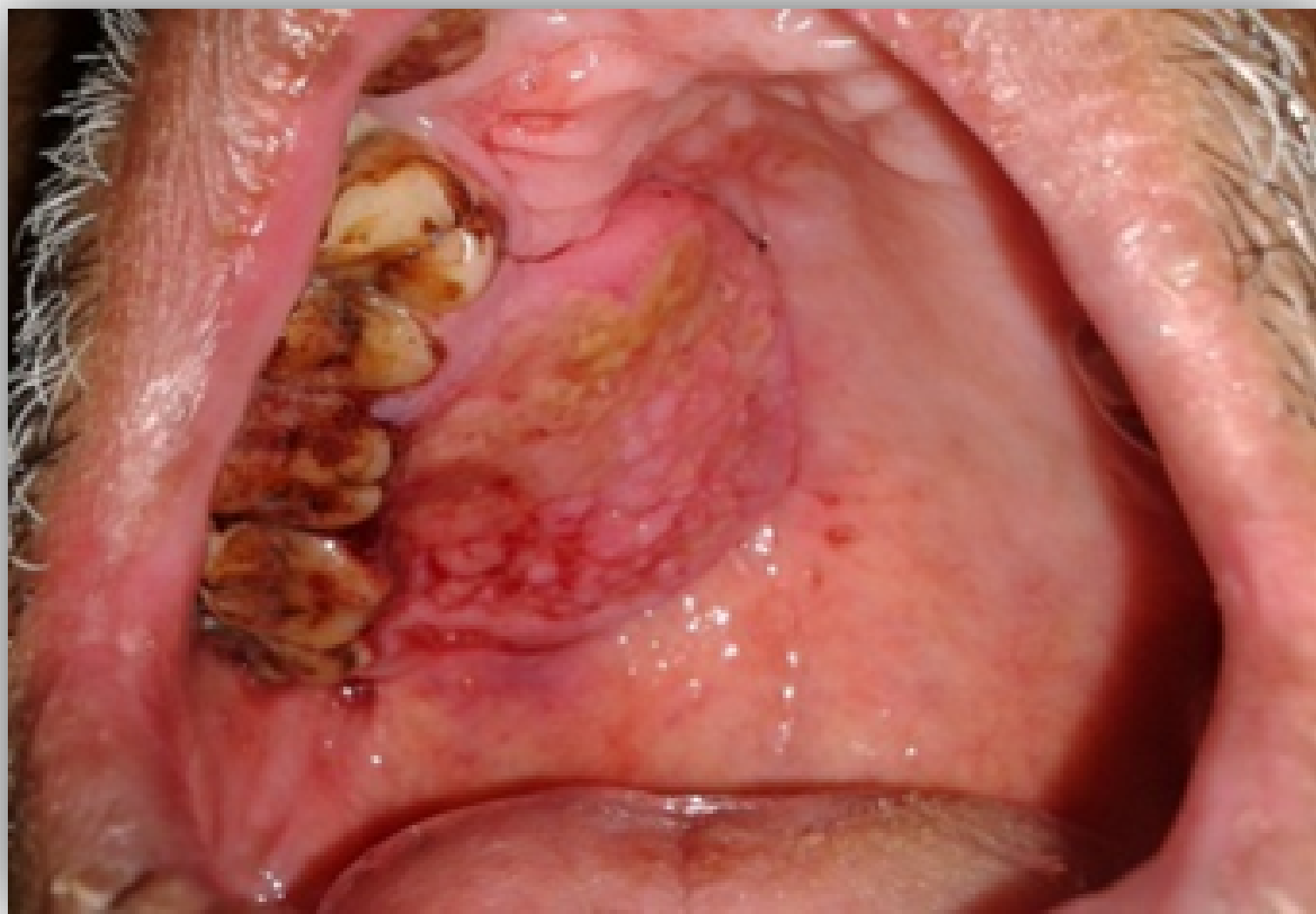

**MEMBRANOUS TONSILLITIS**



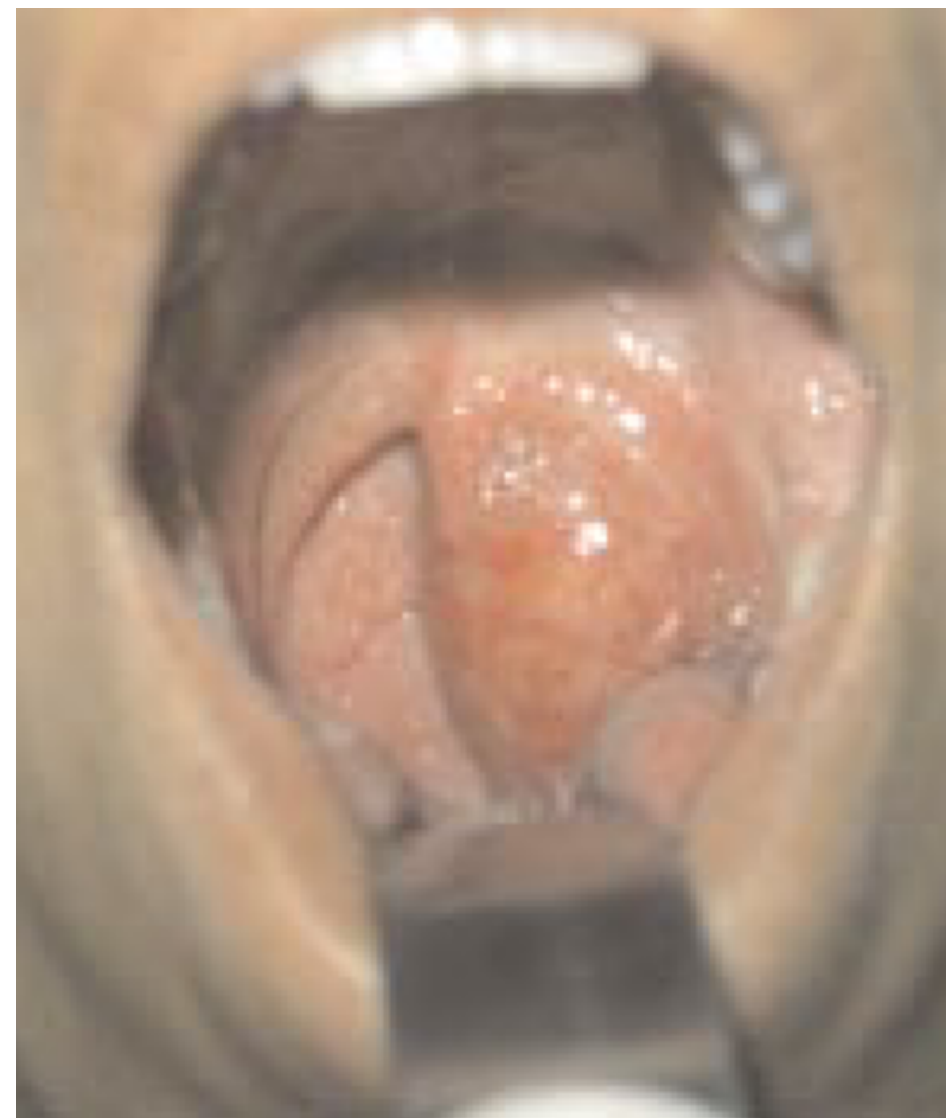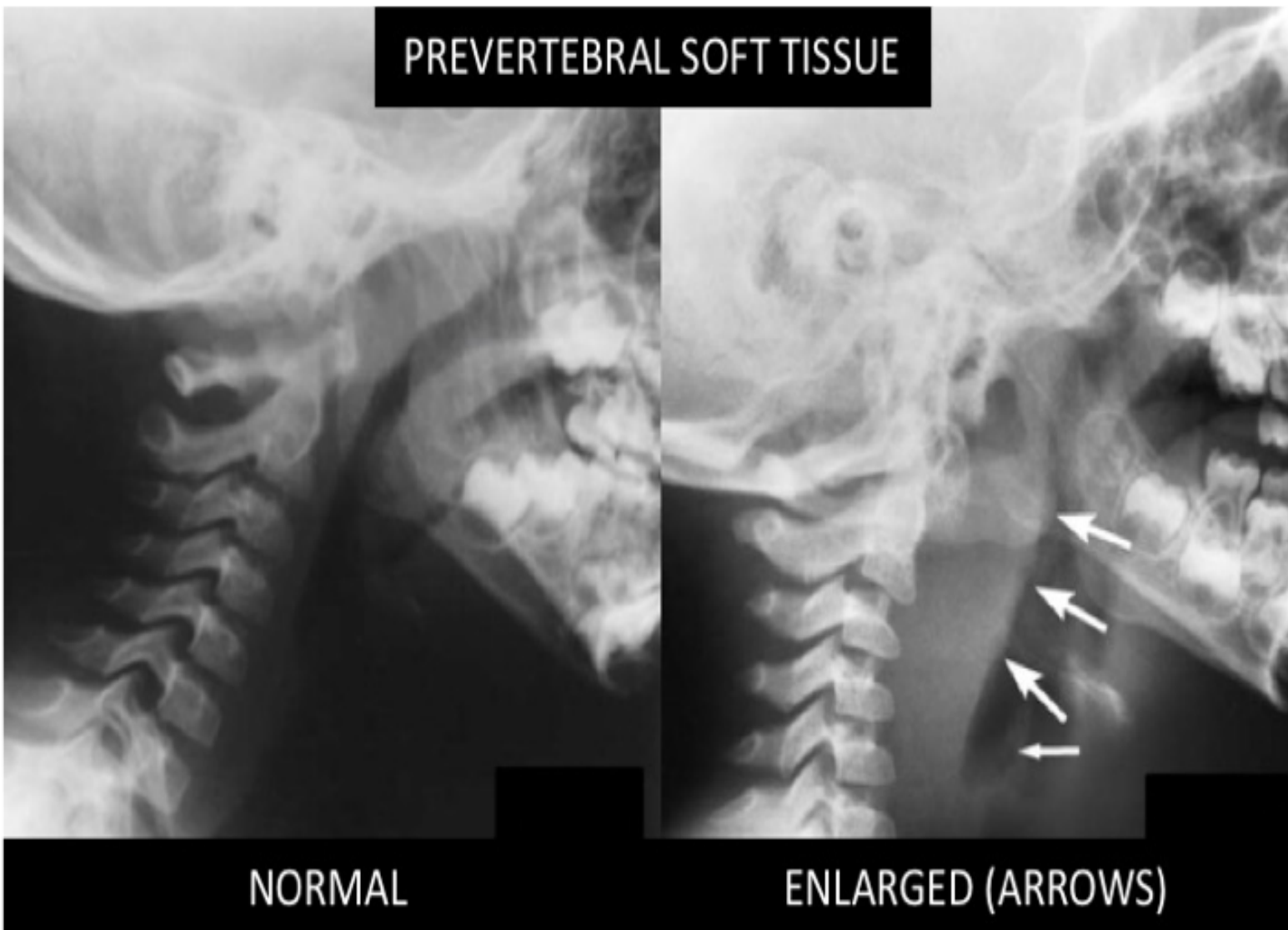




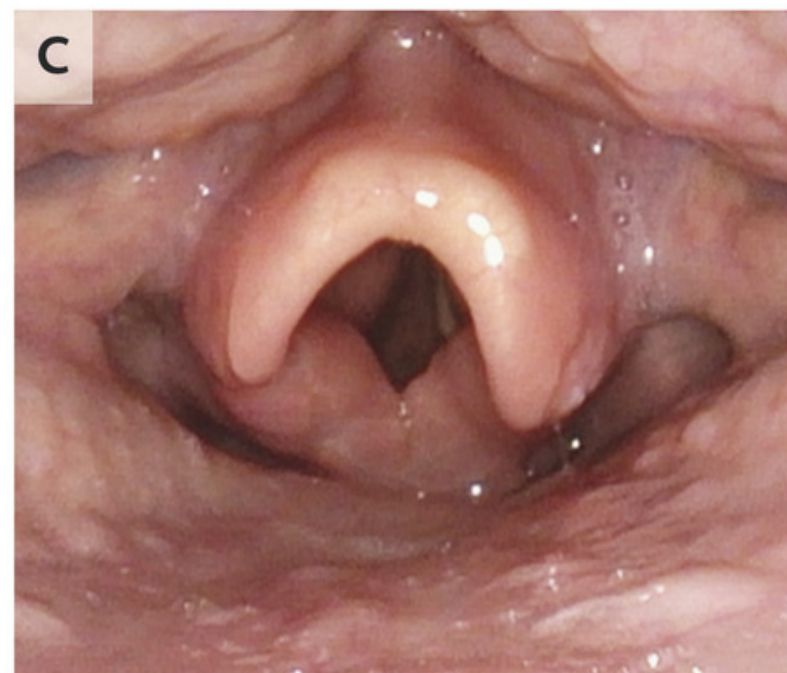
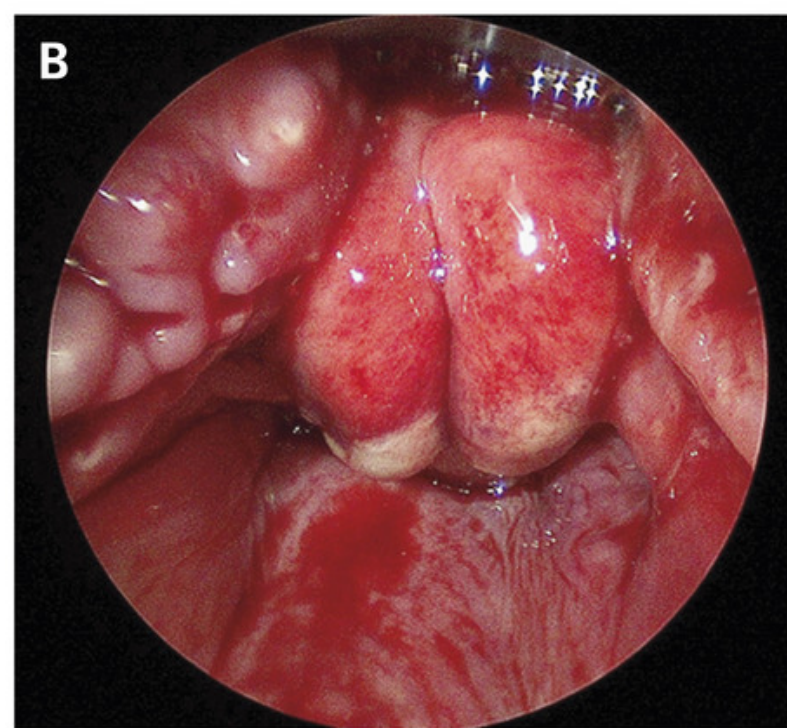

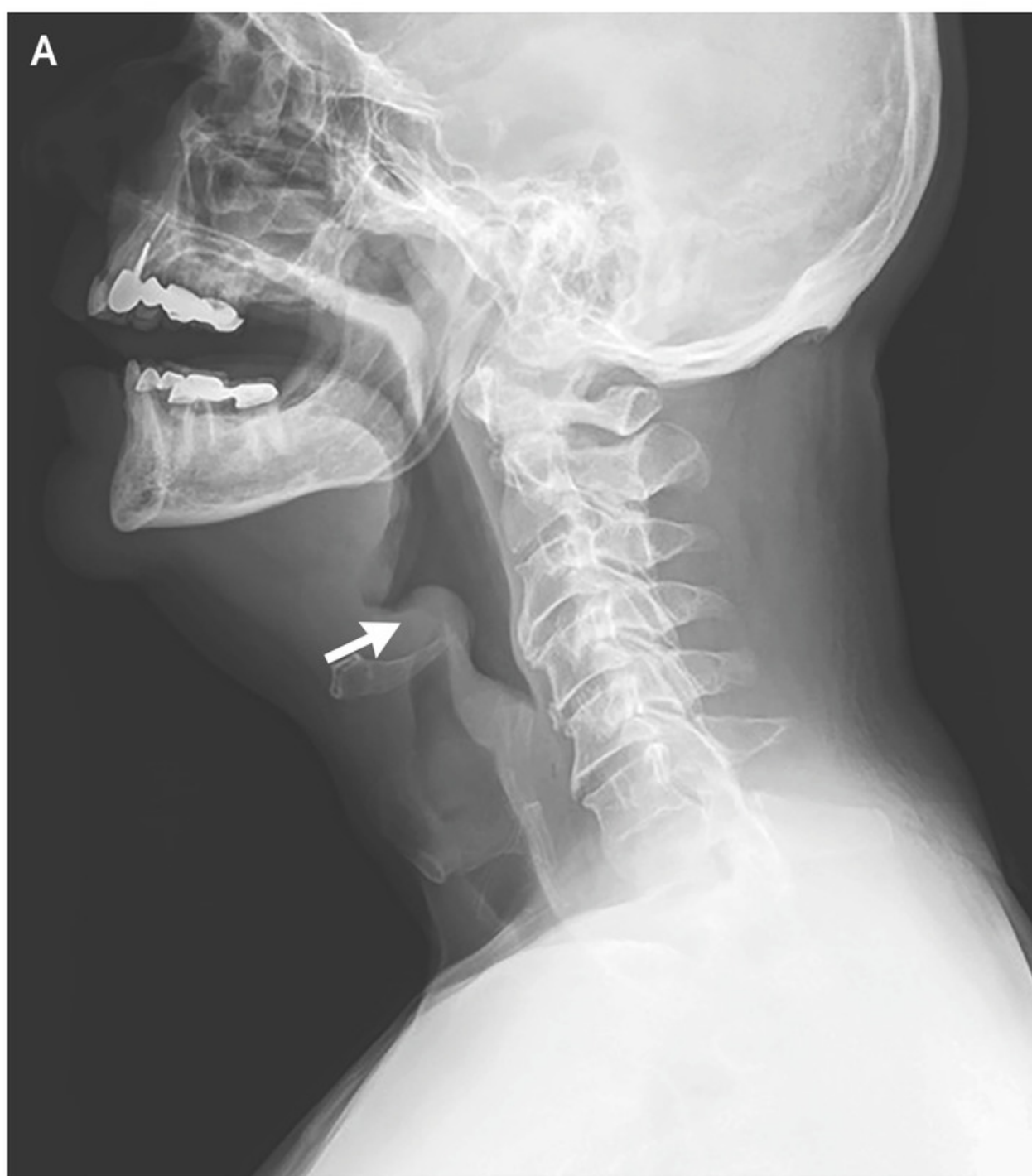
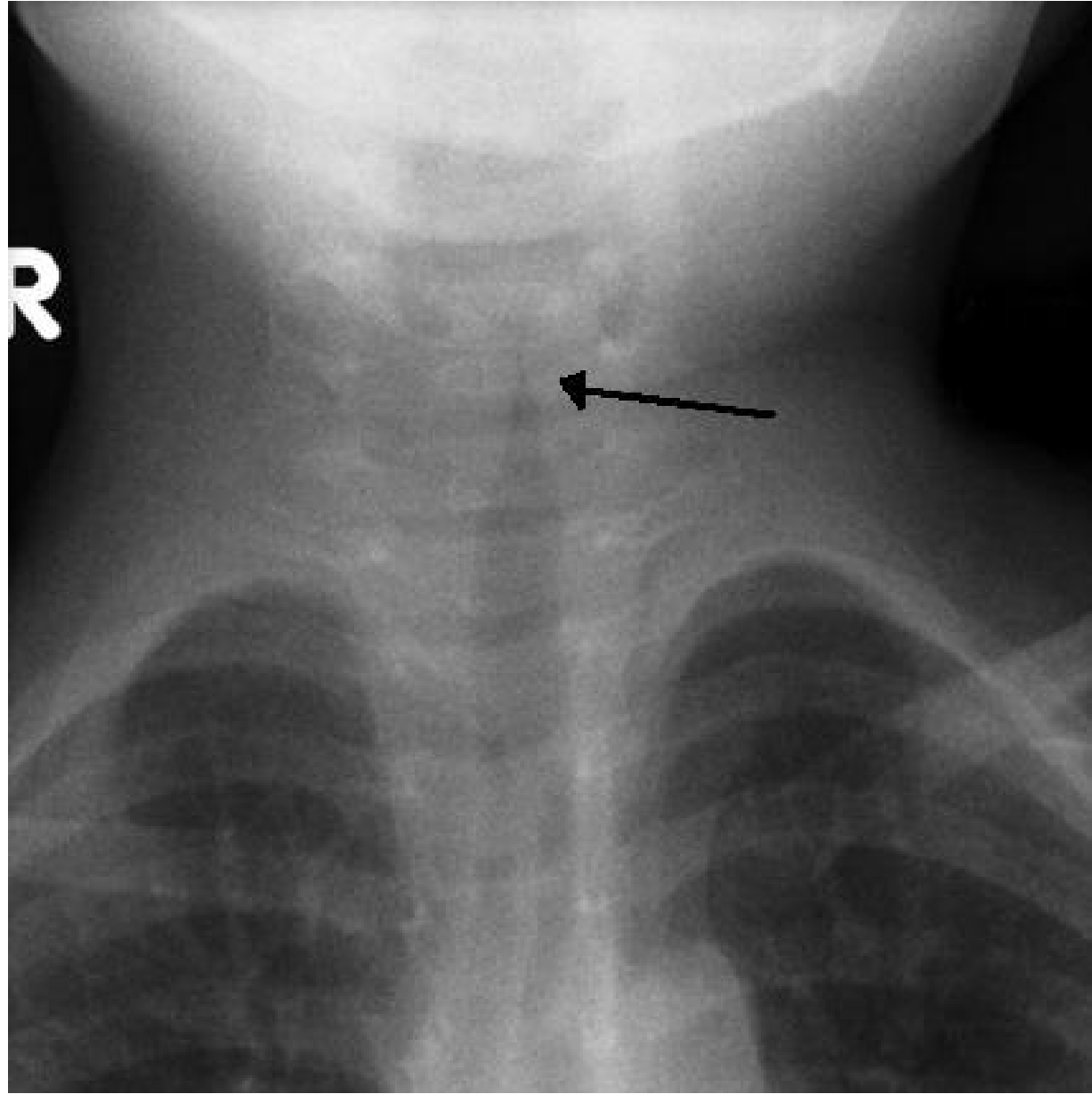


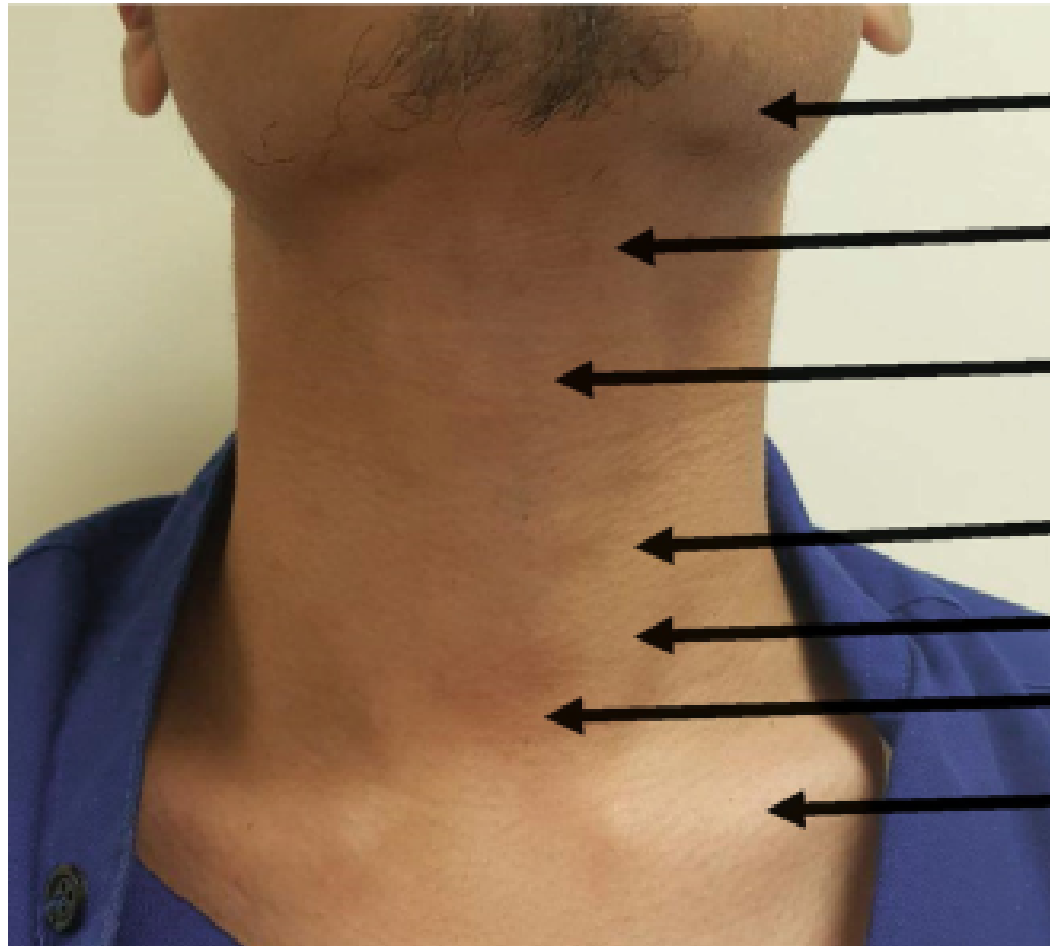
PREVERTEBRAL SOFT TISSUE











***Mandible***

***Hyoid bone***

***Thyroid cartilage***

***Thyroid***

***Sternocleidomastoid muscle***

***trachea***

***clavicle***



# ANTERIOR TRIANGLE

## BOUNDARIES:

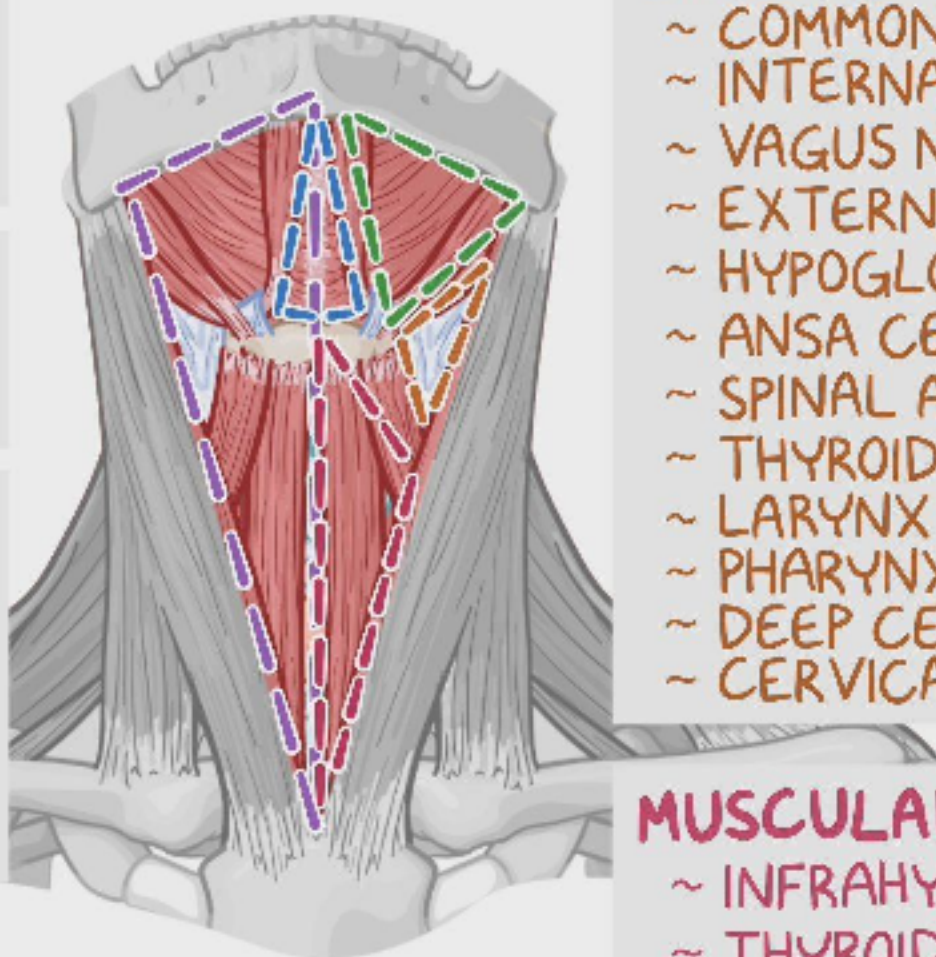
- ~ MEDIAN LINE of NECK
- ~ ANT. BORDER of SCM
- ~ INF. BORDER of MANDIBLE

## SUBMENTAL

- ~ SUBMENTAL LYMPH NODES
- ~ SMALL VEINS

## SUBMANDIBULAR

- ~ SUBMANDIBULAR GLAND
- ~ LYMPH NODES
- ~ HYPOGLOSSAL NERVE (CN XII)
- ~ MYLOHYOID NERVE
- ~ FACIAL ARTERY & VEIN

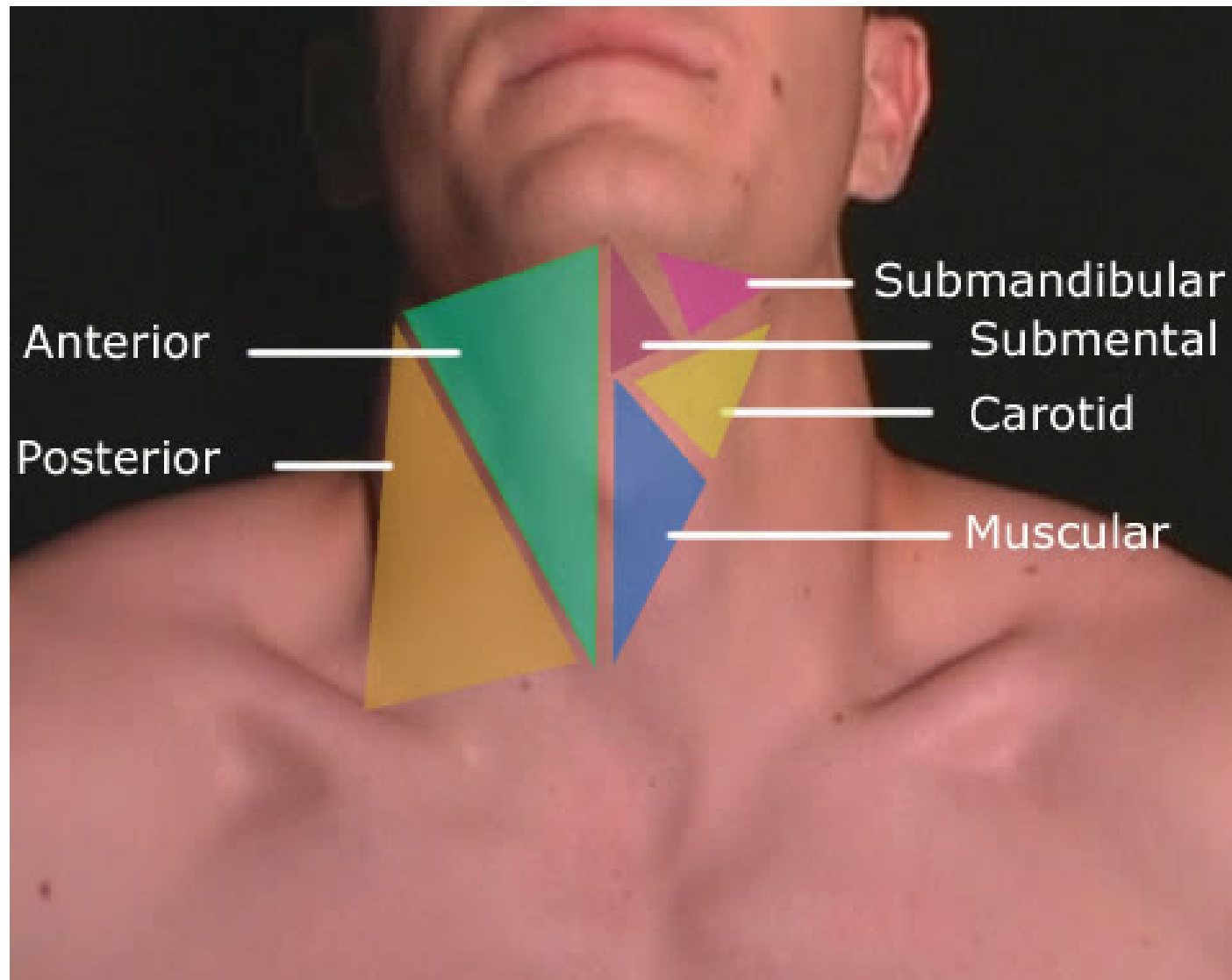


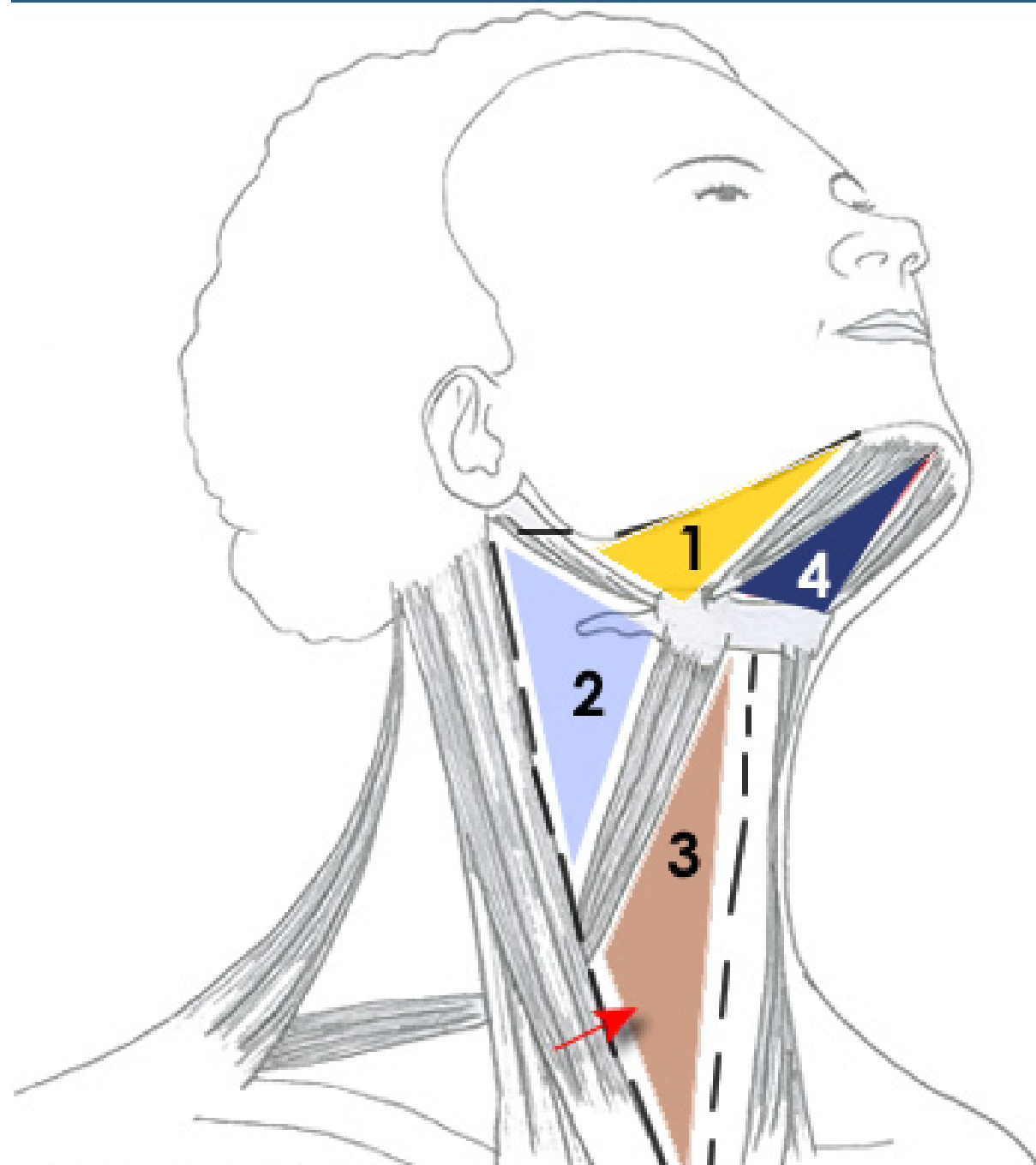
## CAROTID

- ~ COMMON CAROTID ARTERY
- ~ INTERNAL JUGULAR VEIN
- ~ VAGUS NERVE (CN X)
- ~ EXTERNAL CAROTID a.
- ~ HYPOGLOSSAL NERVE (CN XII)
- ~ ANSA CERVICALIS
- ~ SPINAL ACCESSORY n. (CN XI)
- ~ THYROID GLAND
- ~ LARYNX
- ~ PHARYNX
- ~ DEEP CERVICAL LYMPH NODES
- ~ CERVICAL PLEXUS

## MUSCULAR

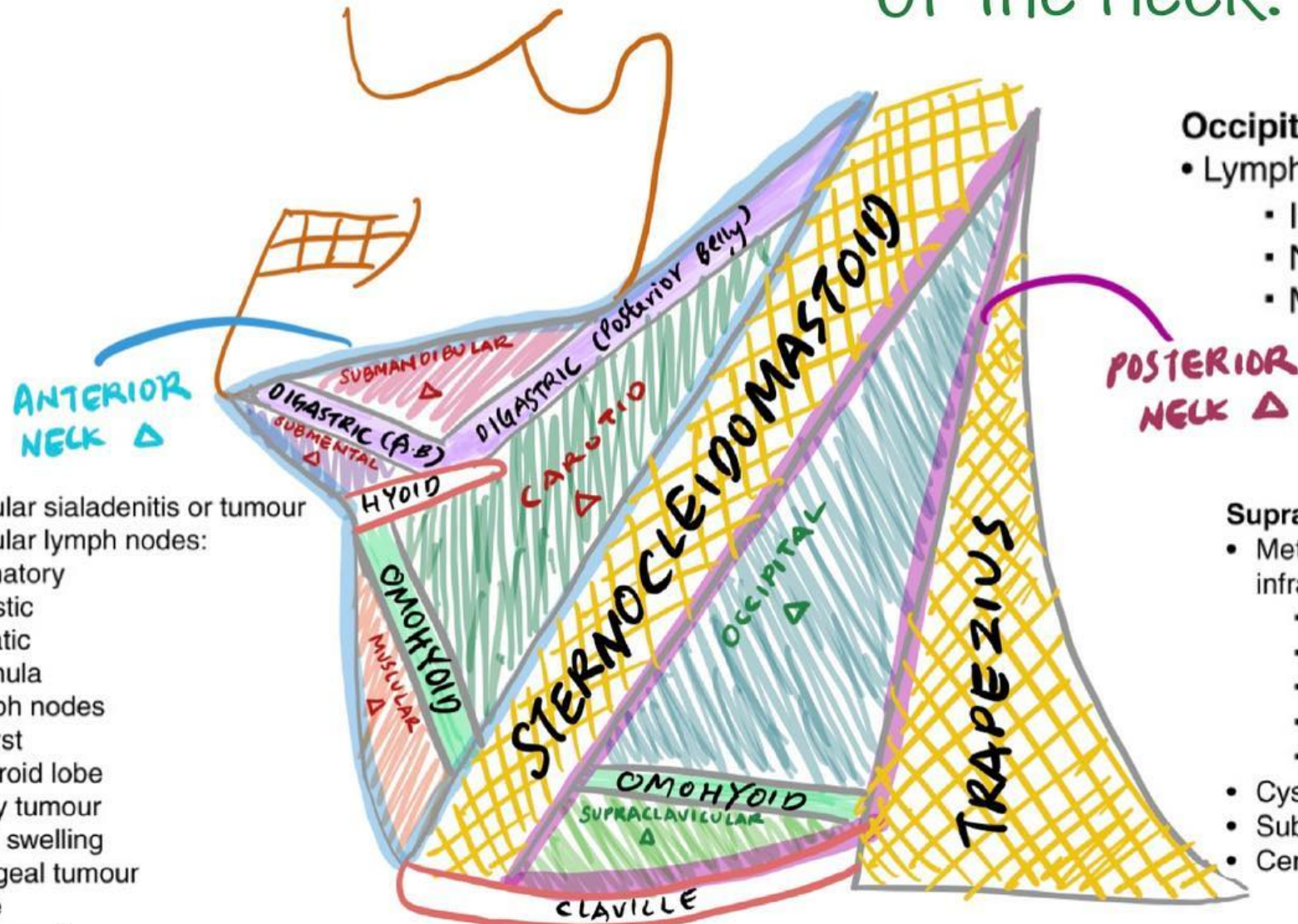
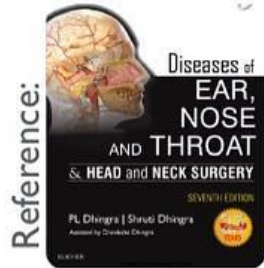
- ~ INFRAHYOID MUSCLES
- ~ THYROID & PARATHYROID GLANDS







# Lateral Swellings of the neck.



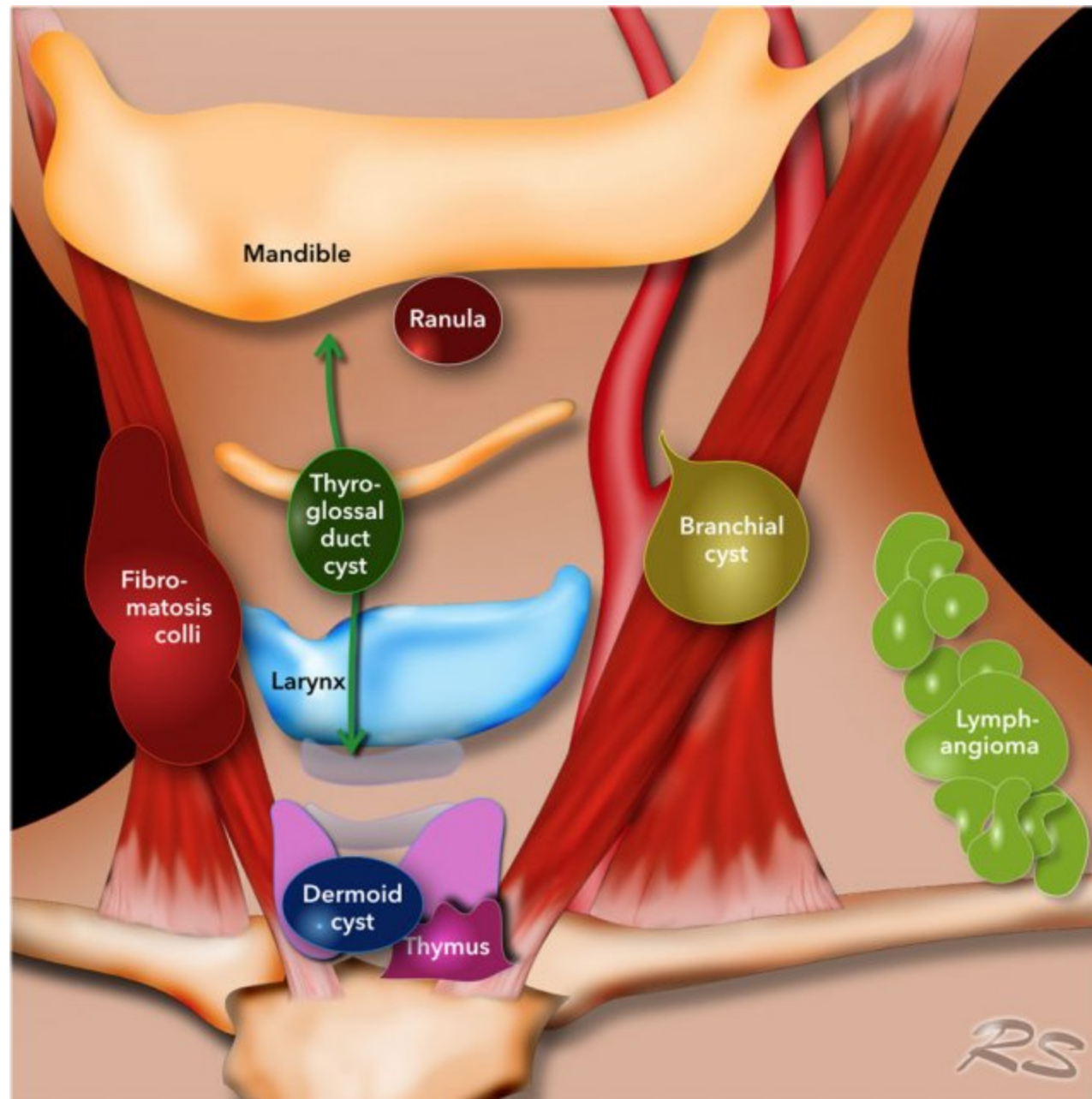
## Occipital triangle

- Lymph nodes:
  - Inflammatory
  - Neoplastic
  - Metastatic

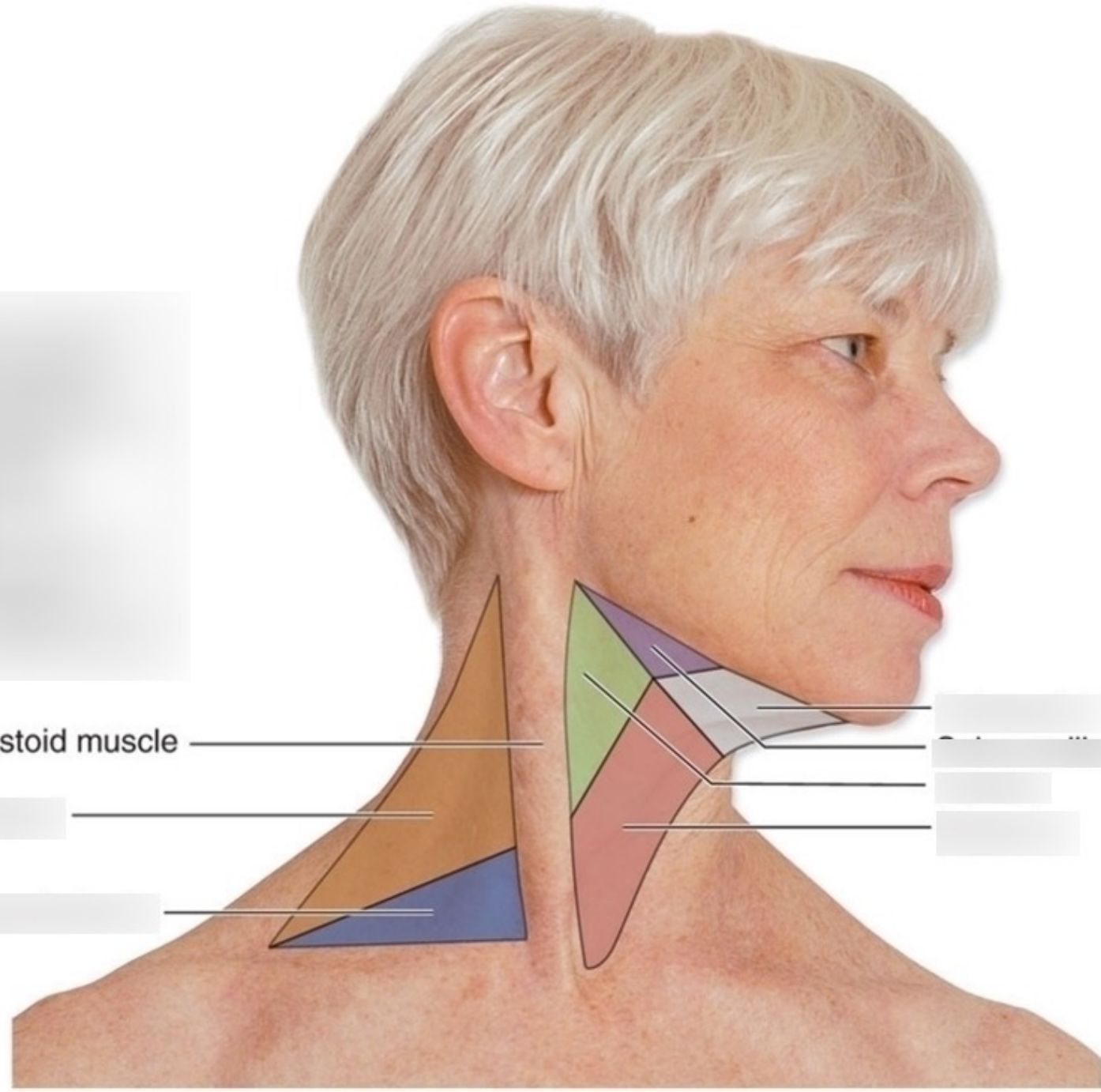
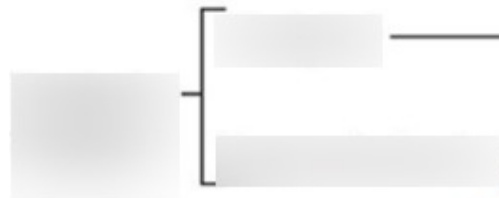- Submandibular sialadenitis or tumour
- Submandibular lymph nodes:
  - Inflammatory
  - Neoplastic
  - Metastatic
- Plunging ranula
- Jugular lymph nodes
- Branchial cyst
- Swelling thyroid lobe
- Carotid body tumour
- Parotid (tail) swelling
- Parapharyngeal tumour
- Laryngocele
- Pharyngeal pouch

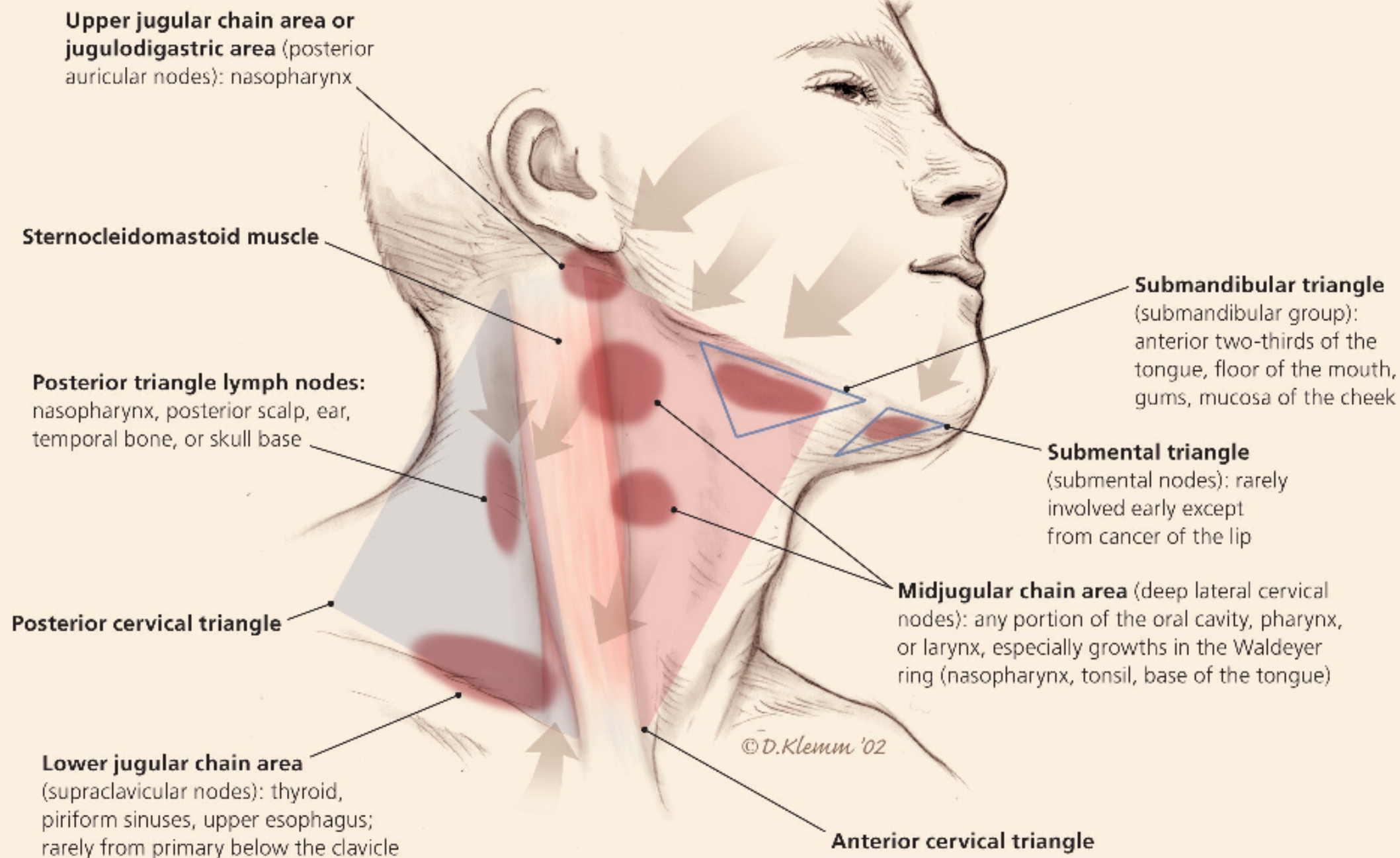
## Supraclavicular triangle

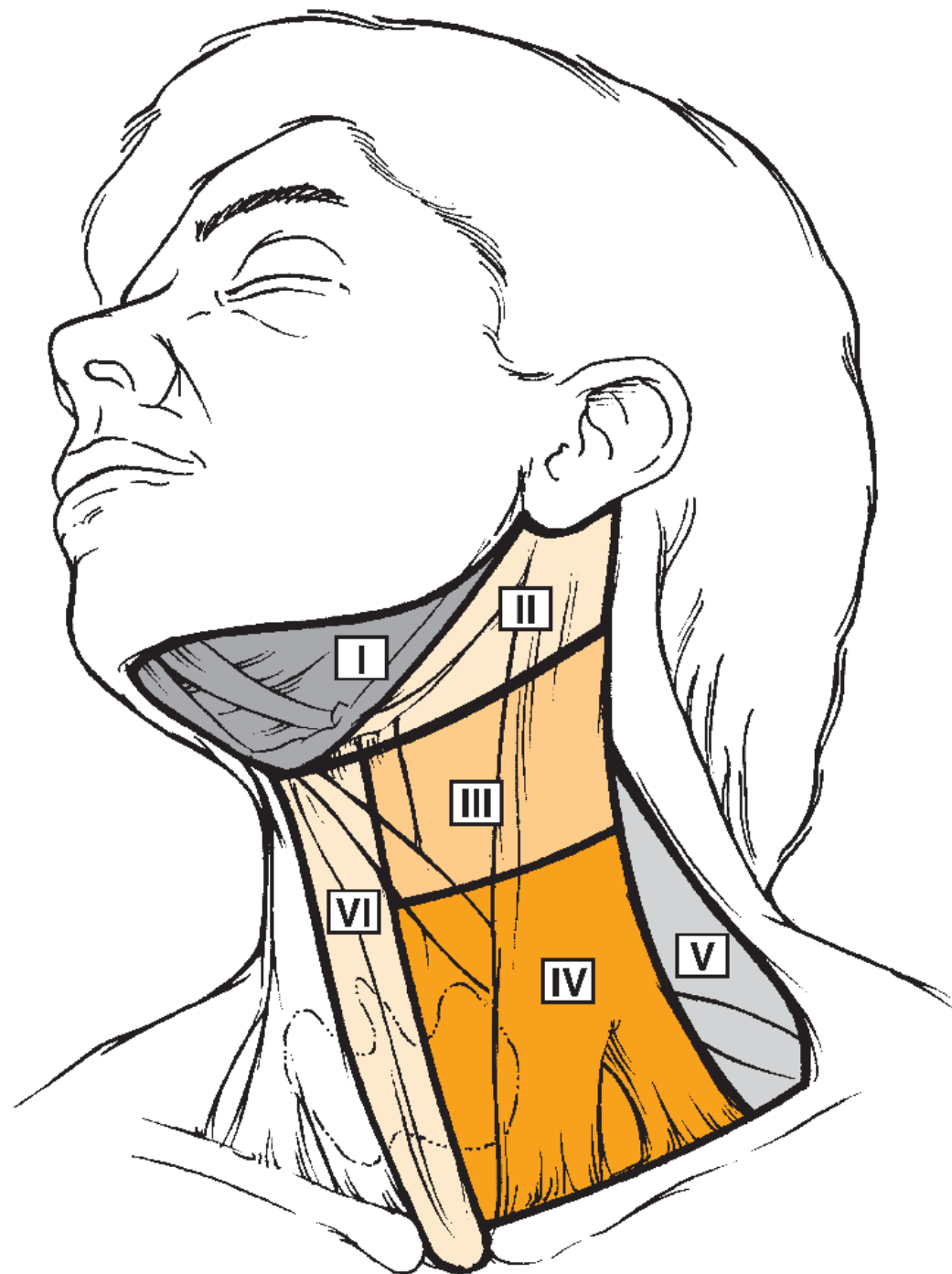
- Metastatic nodes from infraclavicular primaries:
  - Breast
  - Lung
  - GI tract
  - Kidney
  - Ovary, testis
- Cystic hygroma
- Subclavian aneurysm
- Cervical rib



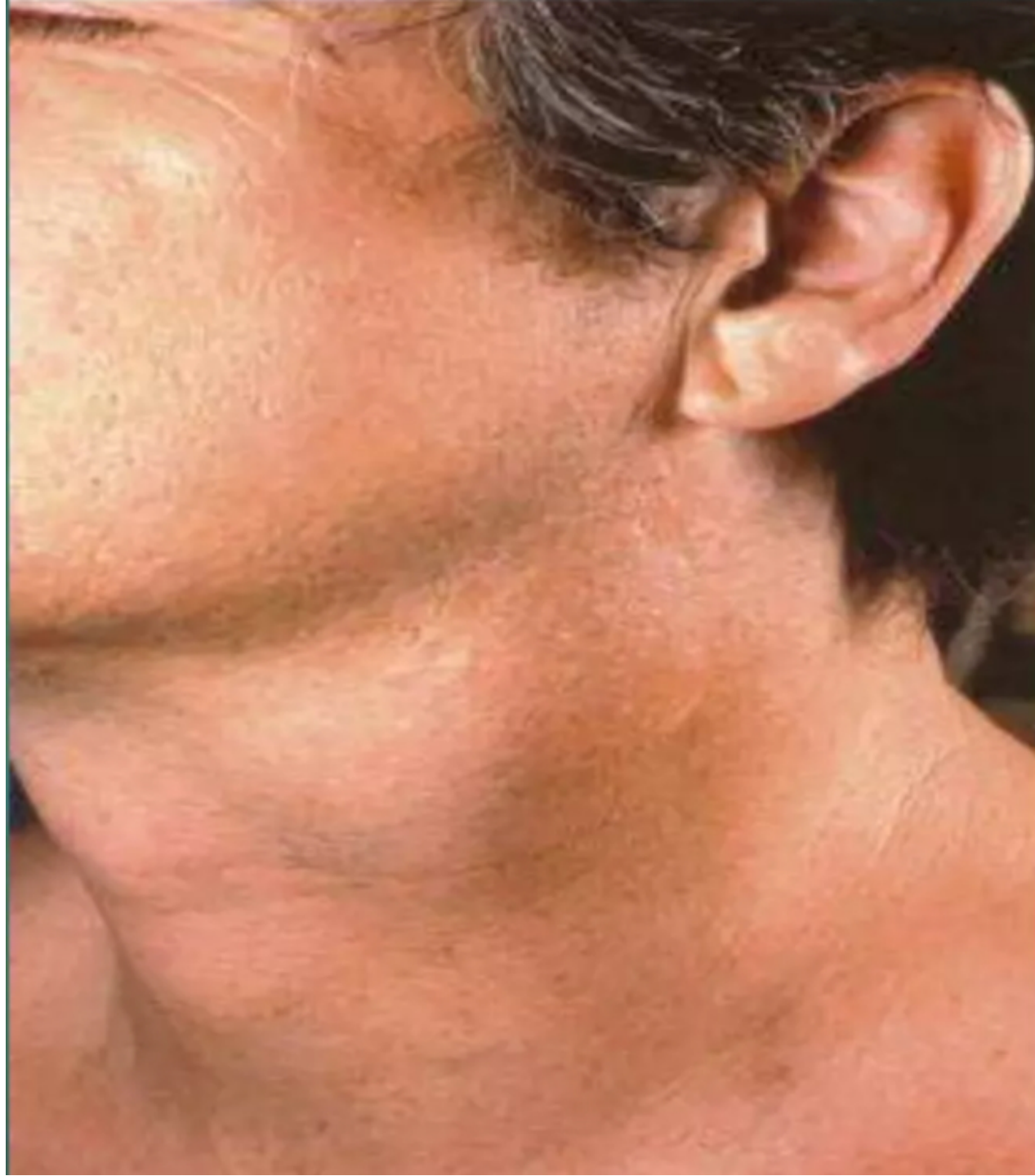



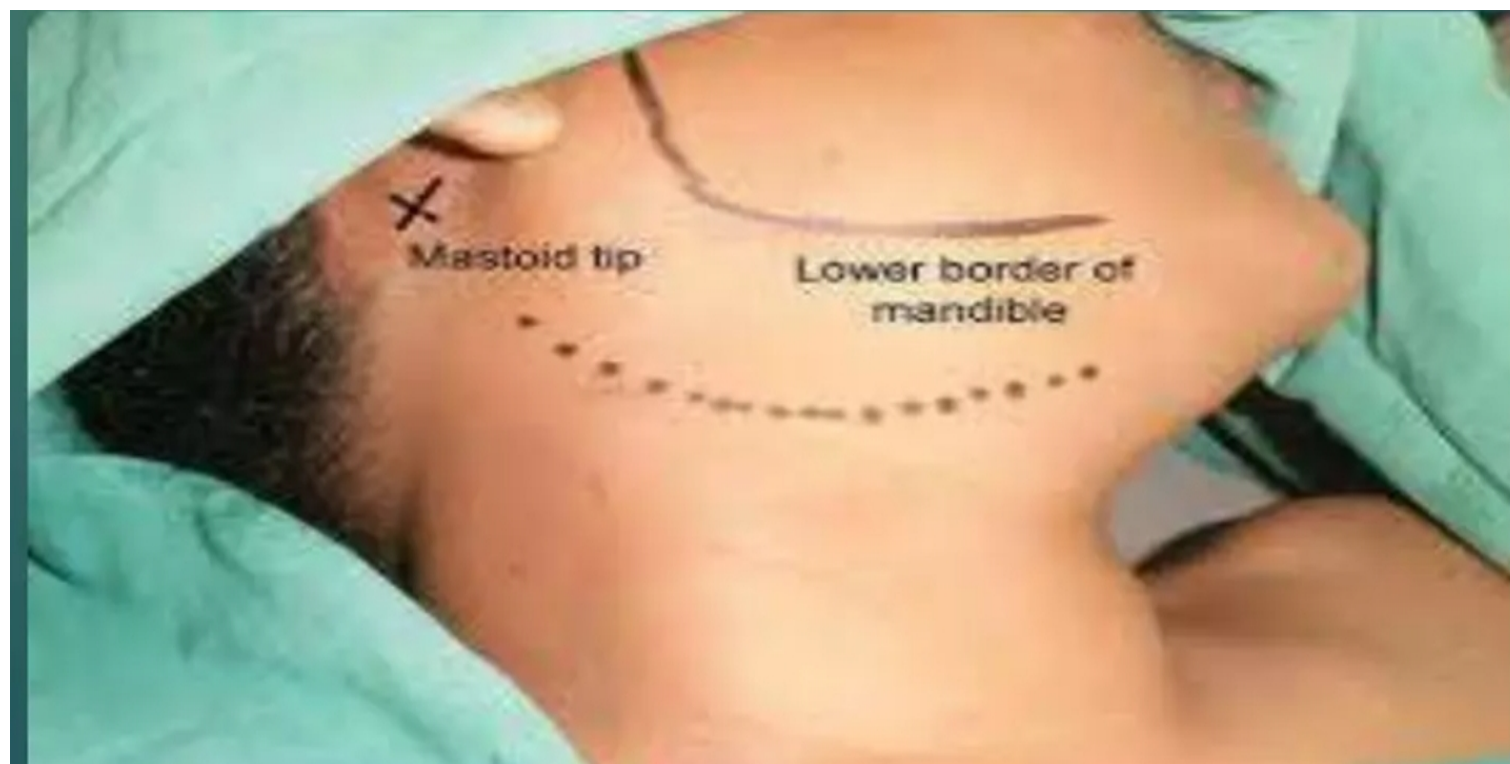
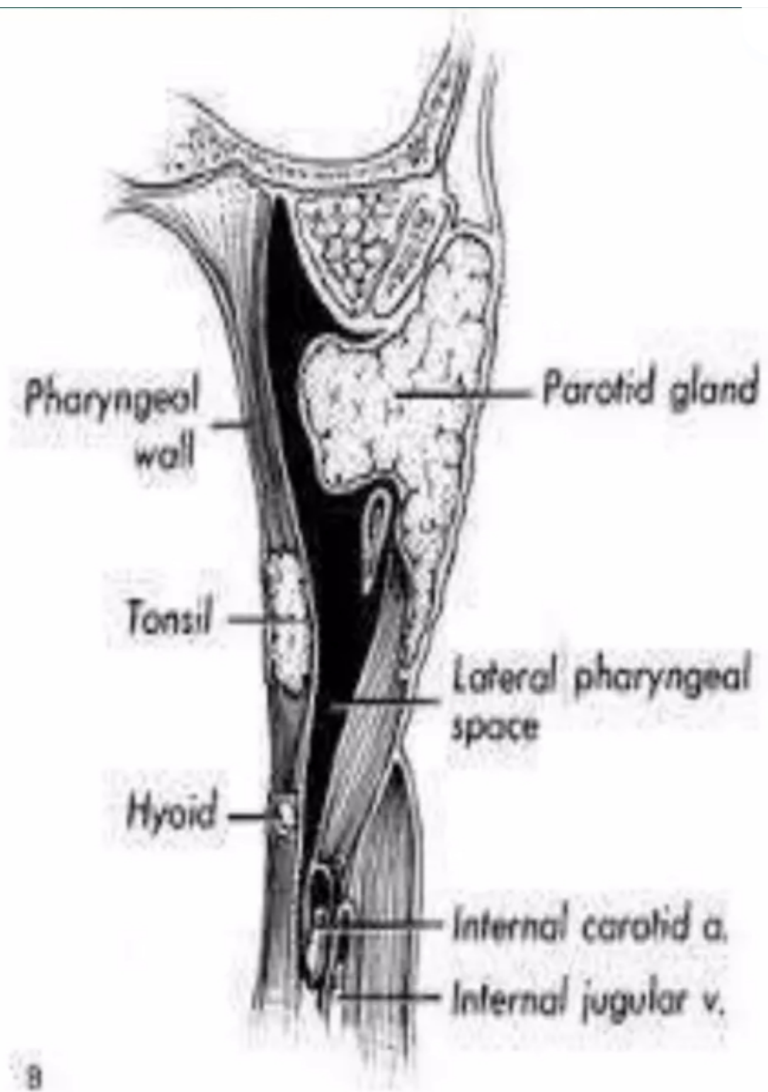



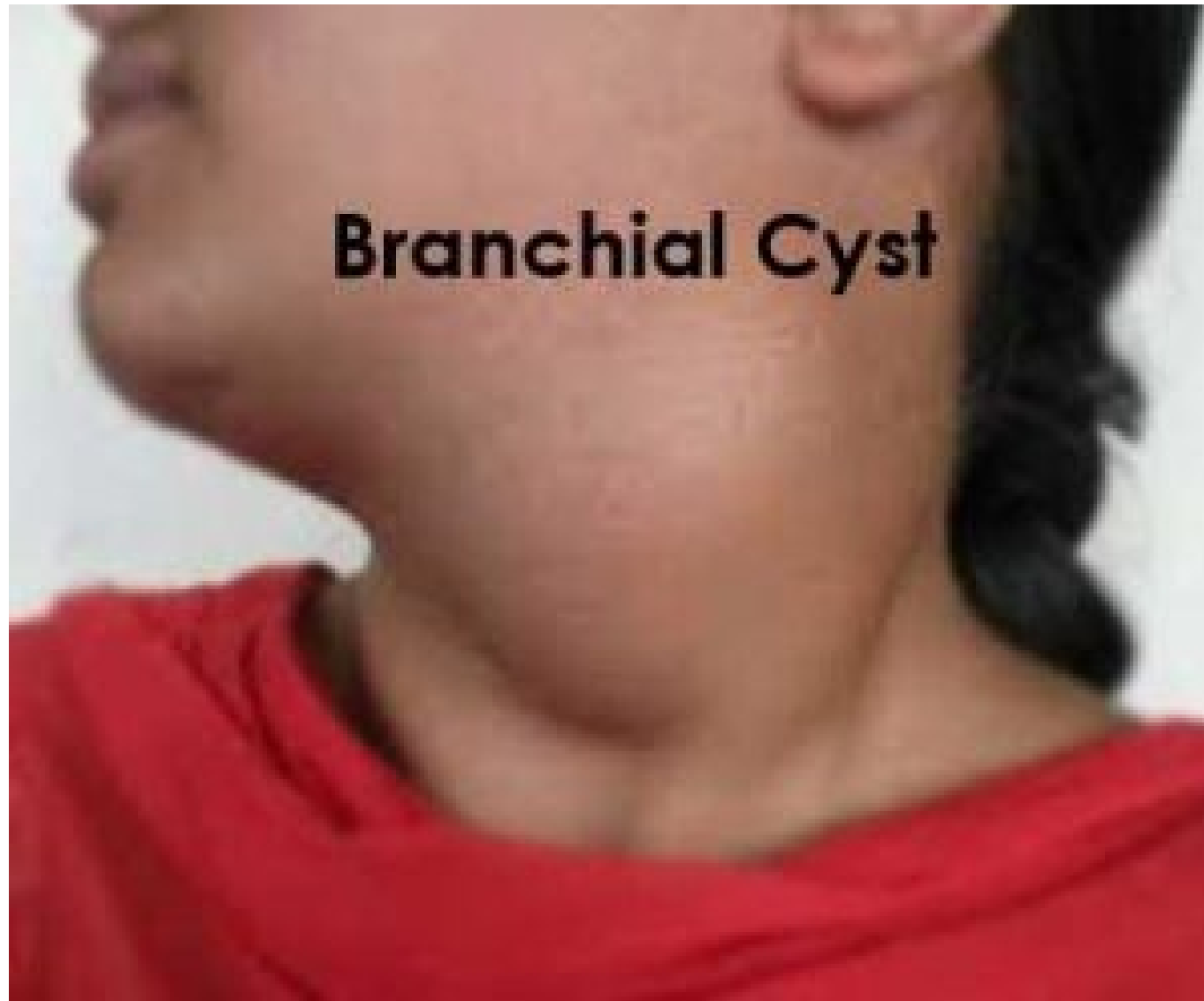


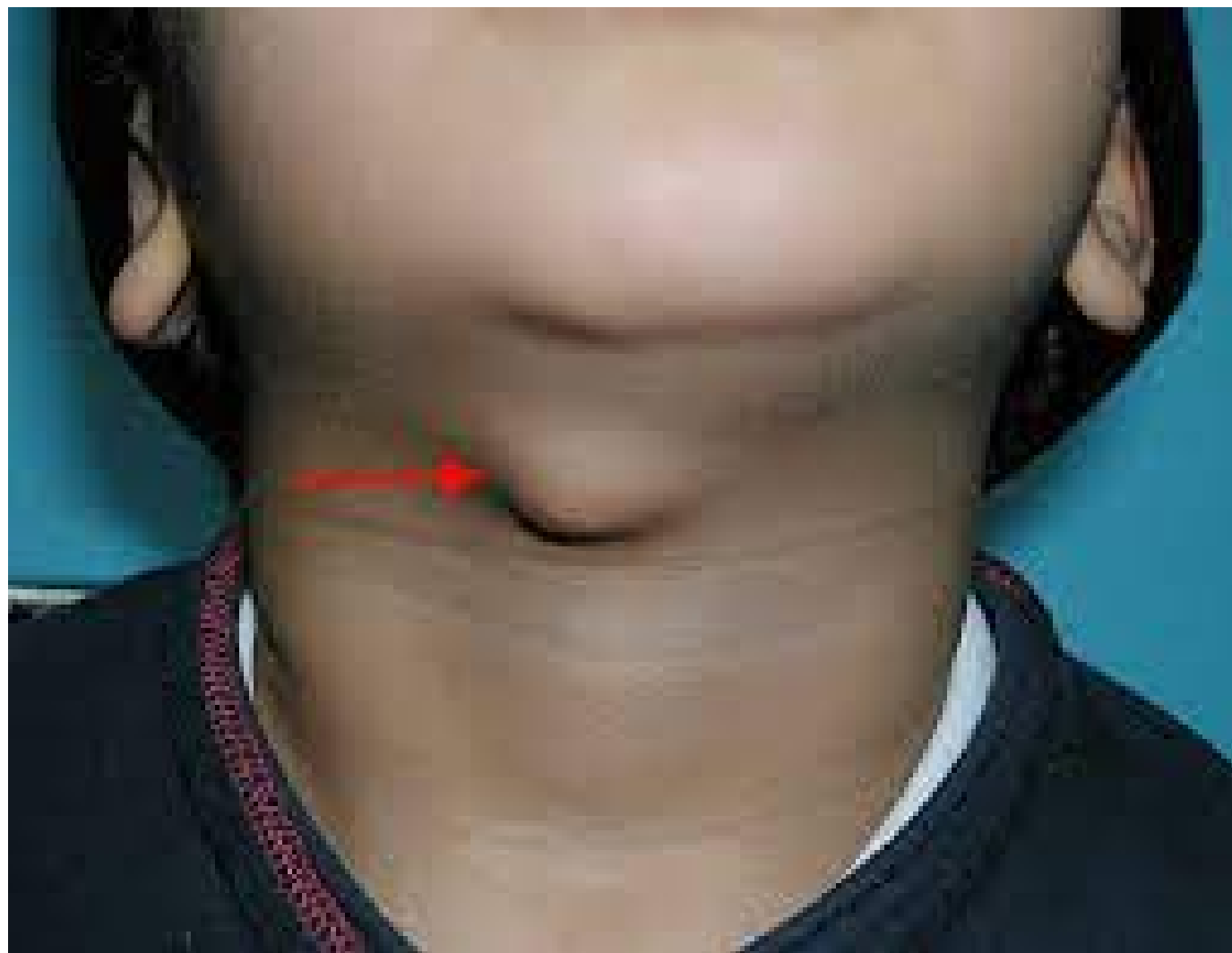


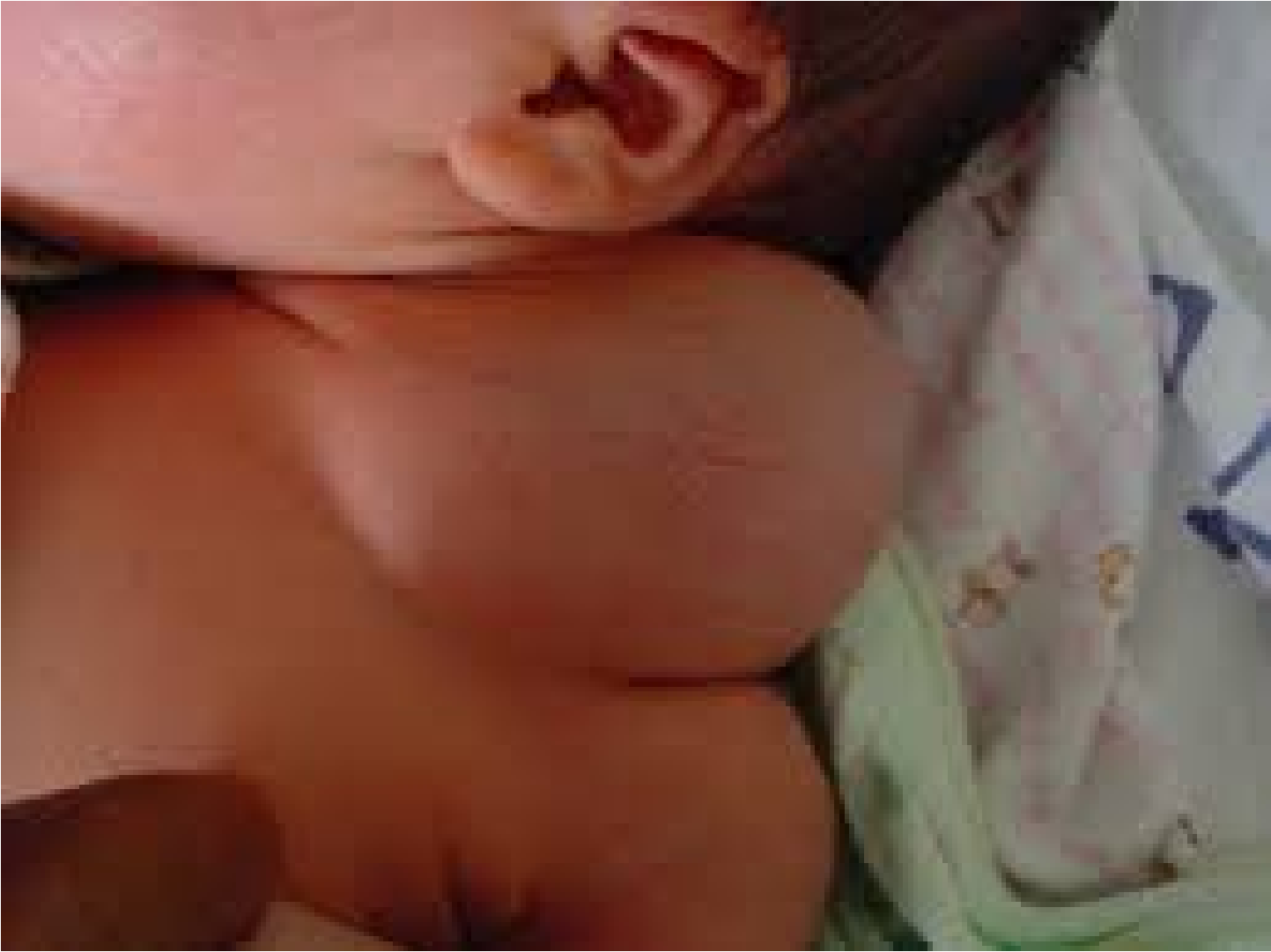




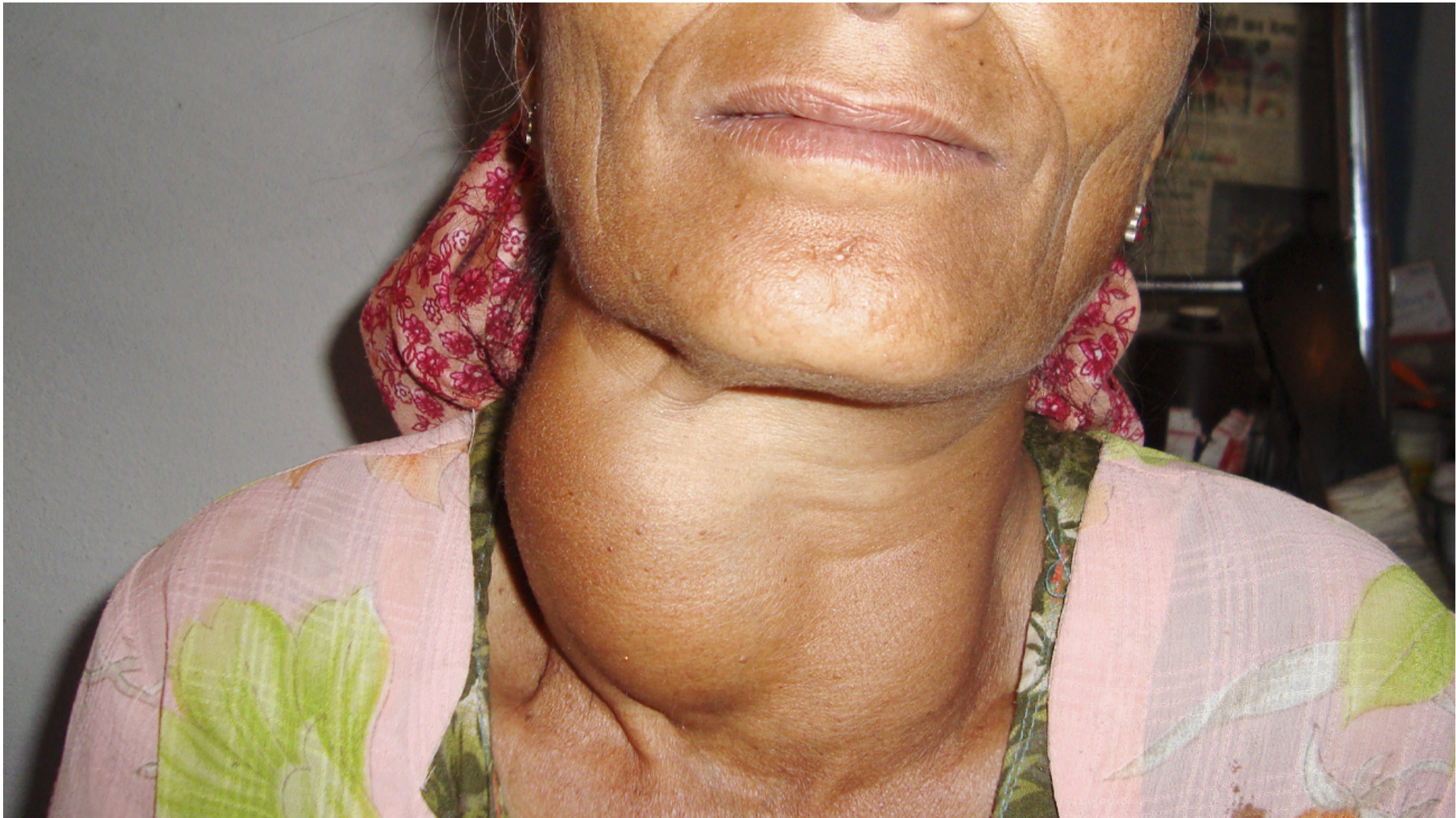







Thank you