



Chronic Diarrhea in Infants and Children

Eyad Altamimi, MD

Professor of Pediatrics

Pediatric Gastroenterologist, Hepatologist

Pediatric Department- Jordan University of Science and Technology



Introduction



- ▶ Defining diarrhea in children is challenging:
- ▶ Stool frequency vary with age and diet and from person to person
- ▶ In Breastfed infants Vs. Older Children
- ▶ Stool weight increases with age; however, stool water content remains constant



Definition:

- ▶ Diarrhea is defined by an increase in the volume and water content of stools
- ▶ An operative definition of diarrhea as proposed by World Health Organization refers to ***passage of three or more loose or liquid stools per day or more frequently than is normal for the individual***
- ▶ Frequent passing of formed stools is not diarrhea, nor is the passing of loose, 'pasty' stools by breastfed babies

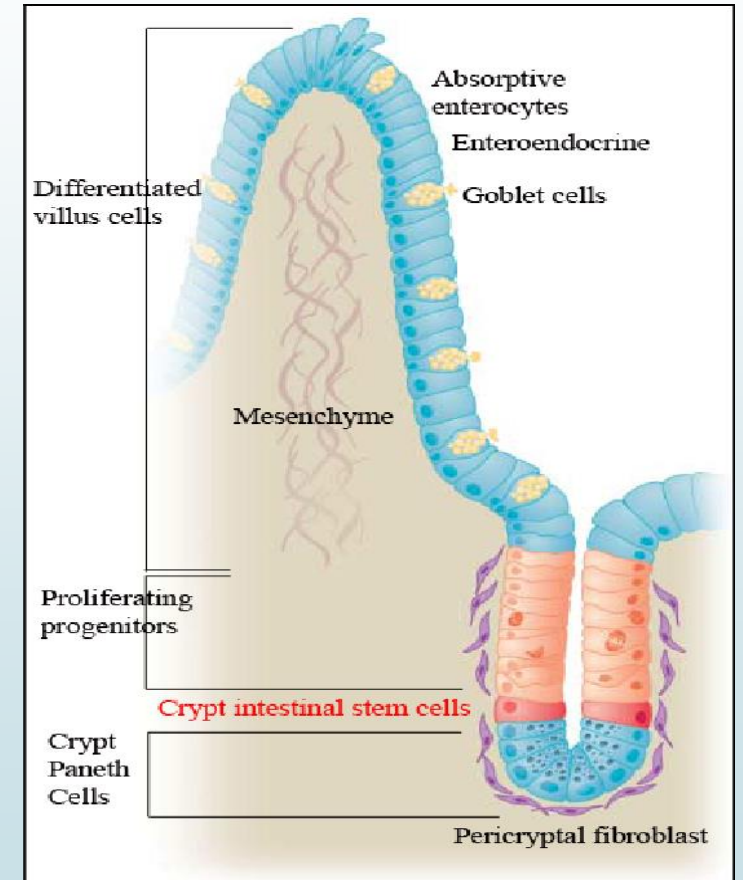
Acute Vs. Persistent Vs. Chronic

- ▶ **Acute diarrhea:** diarrhea episode lasts 7 days, not longer than 14 days and usually of infectious cause
- ▶ **Persistent diarrhea:** an episode lasting for more than 14 days, as a consequence of multiple simultaneous or sequential enteric infections which lead to mucosal injury resulting in a vicious cycle of further diarrhea, malnutrition and infections
- ▶ **Chronic diarrhea:** diarrhea without a demonstrable infectious etiology, lasting for more than 4 weeks, often associated with malabsorption and growth faltering



Pathophysiology

- The cells lining the villi are mostly **absorptive** cells
- Crypt cells are regarded as **secretory**
- Around 99% of fluid entering the midgut is reabsorbed by the small intestine and only 1.2 L of fluid enters the colon.
- Colonic reabsorption capacity (5-15 X the capacity of small intestine unit)
- In Adults: 200 ml / Day stool volume
- Diarrhea happen when the colonic capacity overcame





Pathophysiology:

► Most prominent mechanism for reclamation of fluid is through active transport of ions such as Na^+ , Cl^- and HCO_3^- across the enterocyte

► Intact epithelial barrier function is essential to prevent the back diffusion of electrolytes and thus water into the intestinal lumen

► Normal motility of gut to allow optimal contact time between absorbable solutes and a normal epithelium

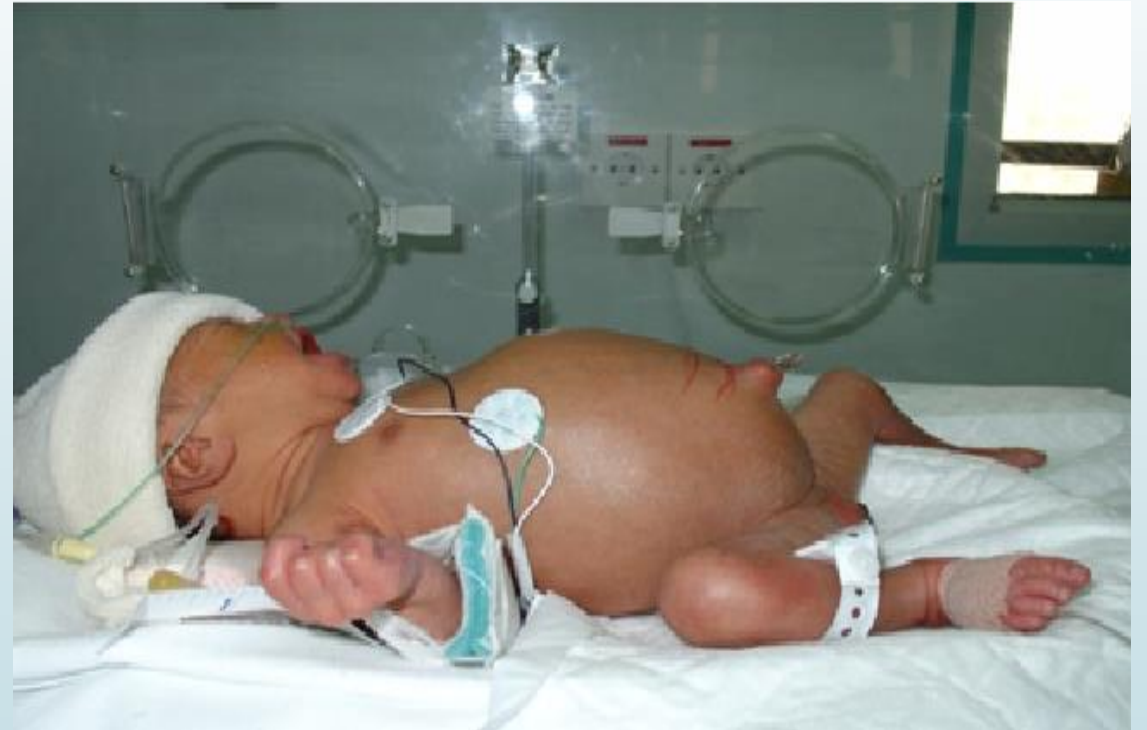History



Important features from history:

Onset:

- ▶ **Immediate Onset at Birth?**
 - Congenital enteropathies
 - NEC
 - Anatomical abnormalities
- ▶ **At Weaning?**
 - Celiac disease
- ▶ **After First Exposure to Specific Foods?**
 - Food induced colitis
 - CMPA





Stool volume and character

- ▶ Detailed description of stool and visualizing the stool if able, is vital.
- ▶ Classifying the stools:
 - **watery**: CHO malabsorption
 - **fatty**: Pancreatic insufficiency
 - **bloody**: Colitis (Infectious vs. Inflammatory)
- ▶ Accompanying symptoms :
 - flatulence, bloating
 - relationship of defecation to meals vs. fasting
 - fever, urgency, tenesmus and nocturnal awakening
 - Growth failure

Dietary History

- ▶ Breastfed or formula fed, type of formula (cows milk vs. others), time of introduction of solids and type of solids
- ▶ Temporal relationship with specific food introduction
- ▶ Emphasis on consumption of fruits, fruit juices and soft drinks which contain high concentrations of fructose or sorbitol and mannitol



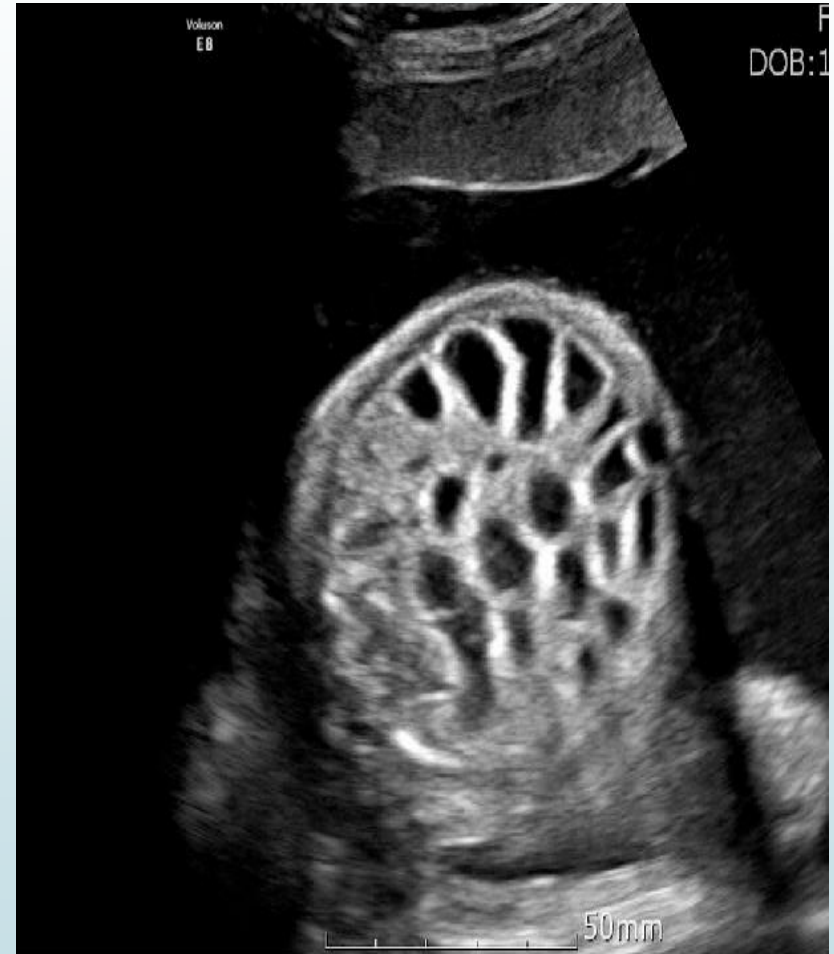
Family history and consanguinity

- ▶ Many of the congenital enteropathies are autosomal recessive disorders

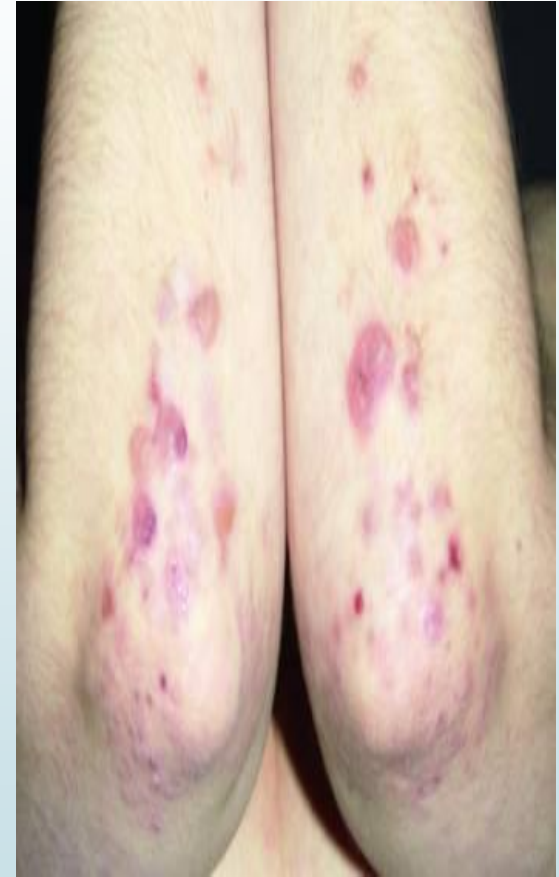
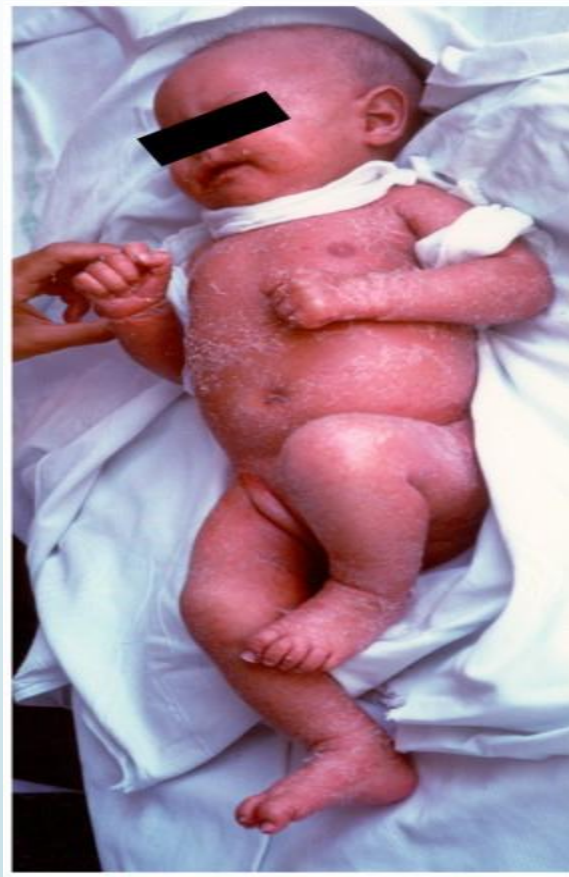
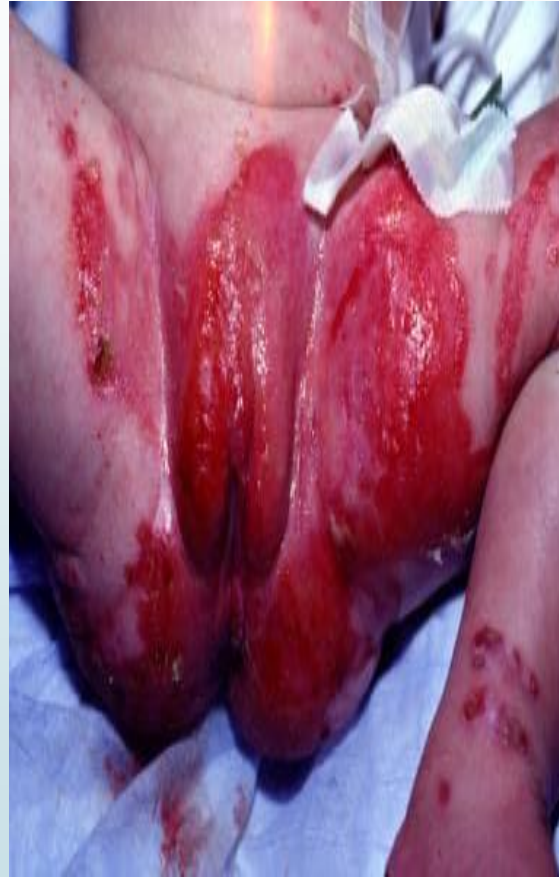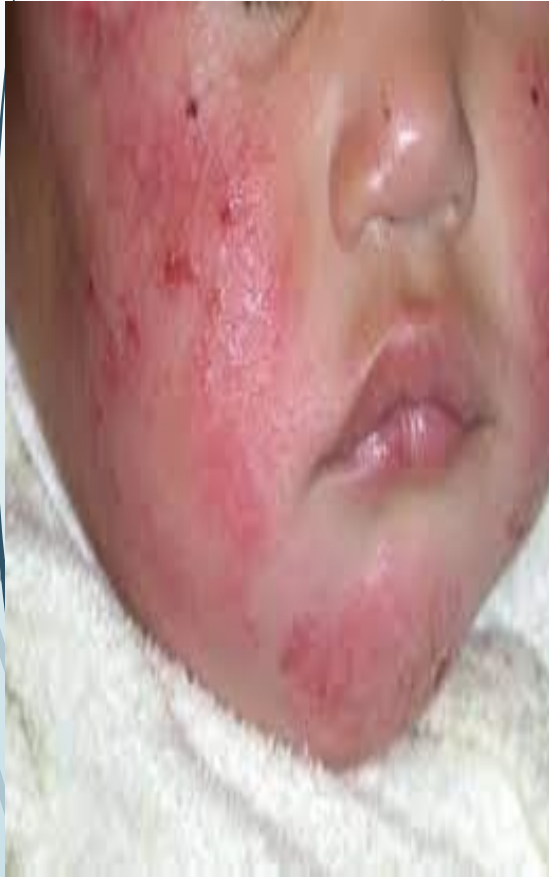Antenatal and Neonatal History

- ▶ Polyhydramnios:
 - Microvillus Inclusion Disease or Sodium/Chloride Transporter Defect
- ▶ Dilated bowel loops antenatal:
 - Chloride Transporter Defect
- ▶ Prematurity (NEC)
- ▶ Surgical History: resection – ileocecal valve present or removed

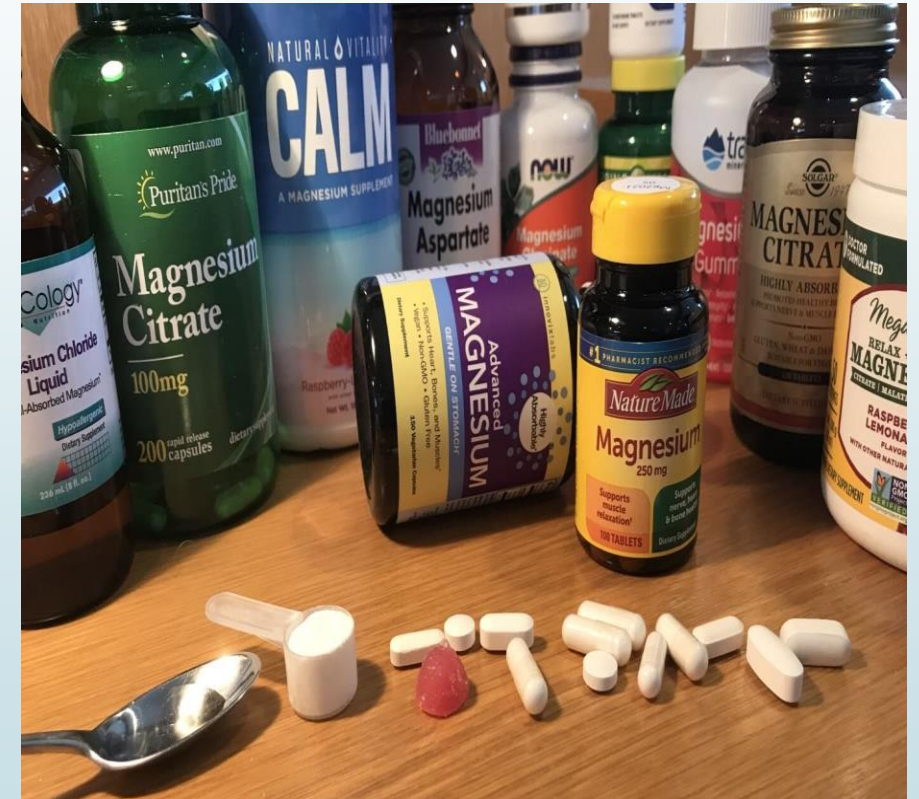

Skin rashes



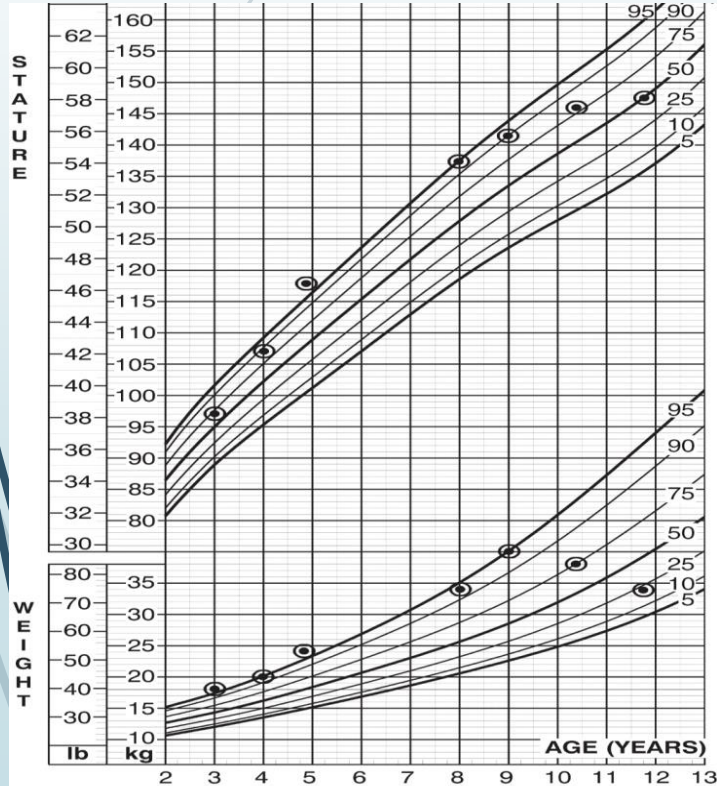
Drugs and Past history:

- Magnesium, Mycophenolate mofetil and laxative abuse
- Thyroid disorders
- Exposure to radiation and bowel resection

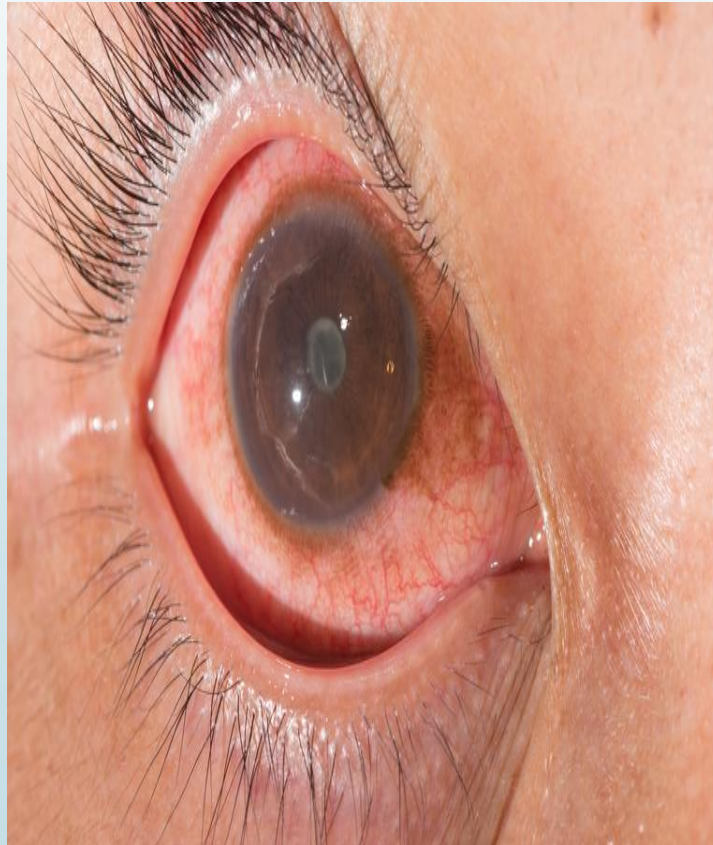

Physical Exam

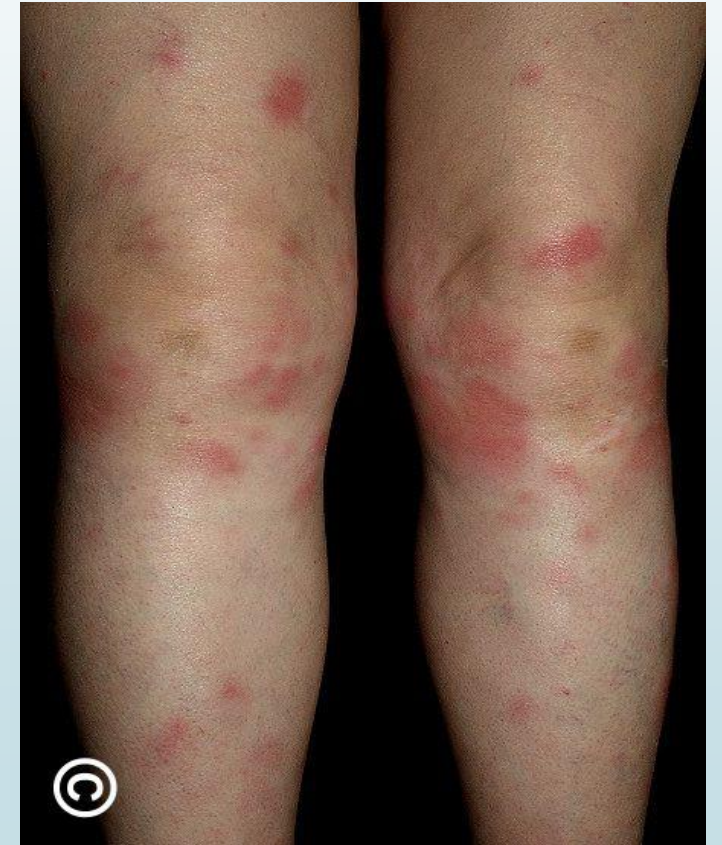Growth Failure / developmental delay / Pubertal delay



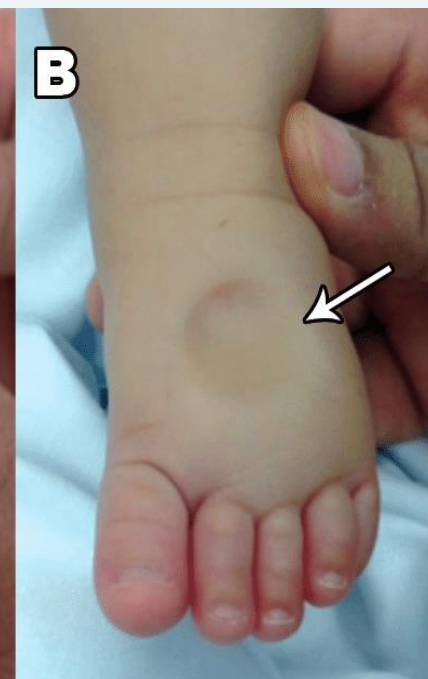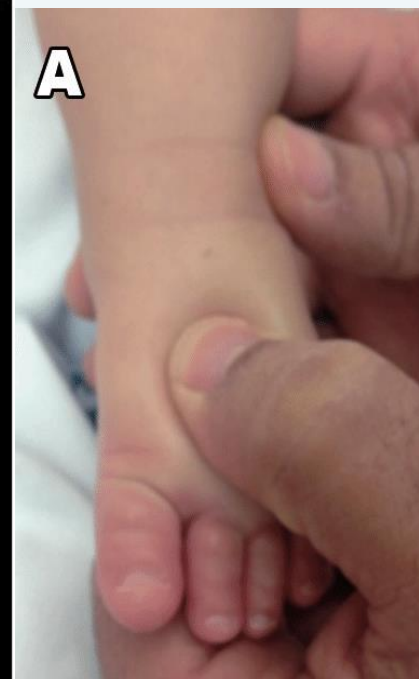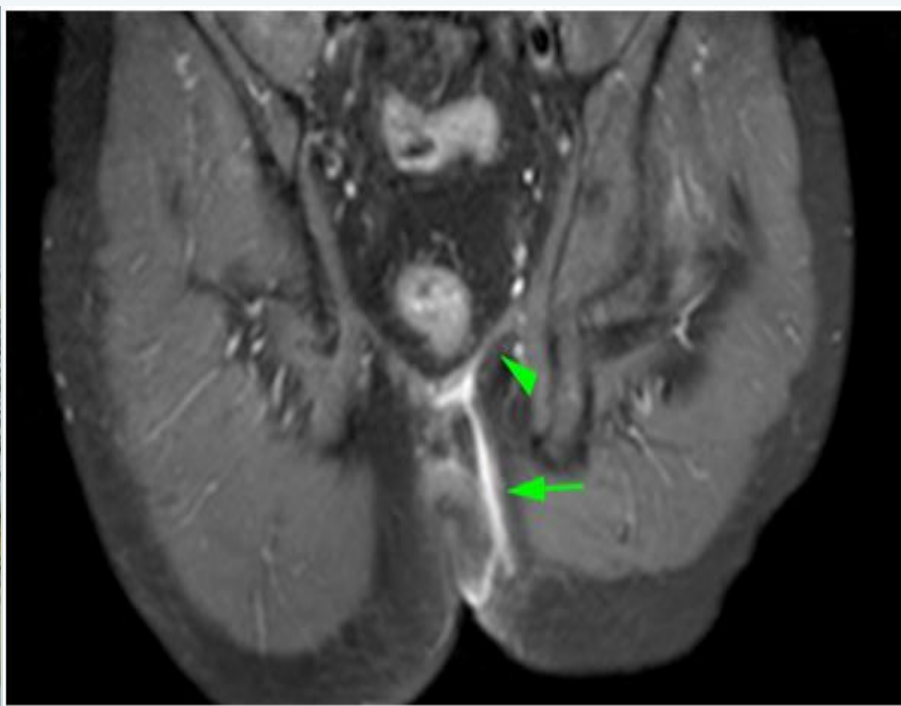
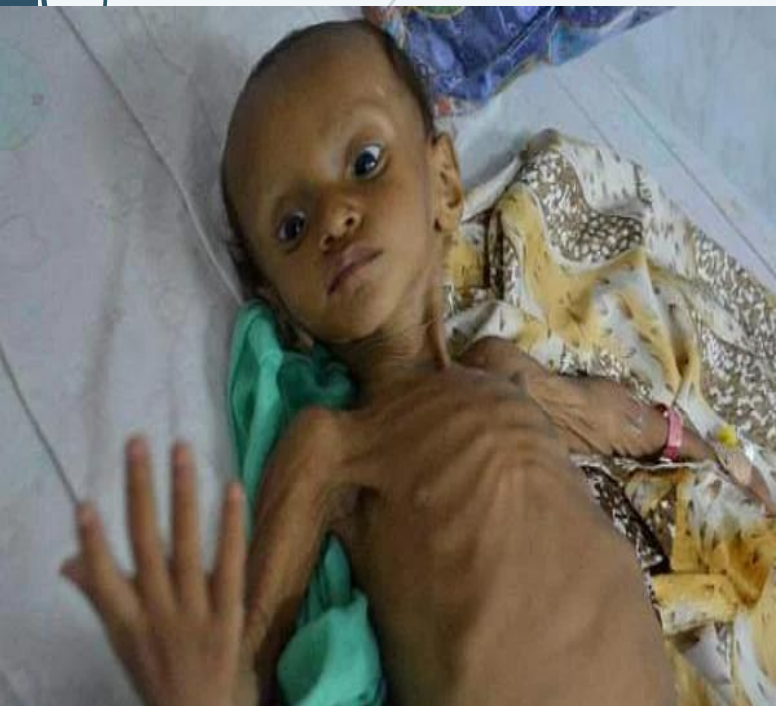Eye exam



Skin rash



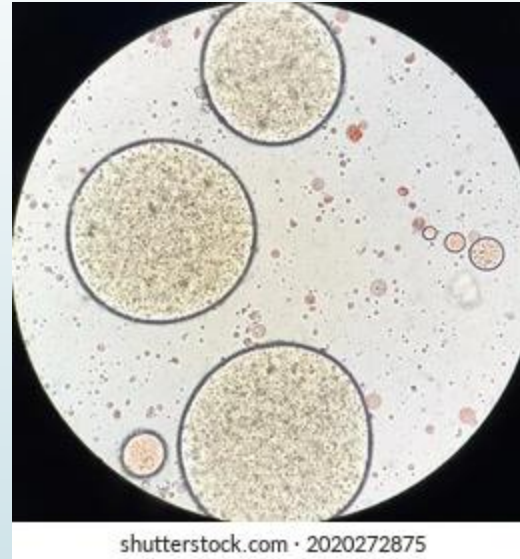
Other ...



Investigations:

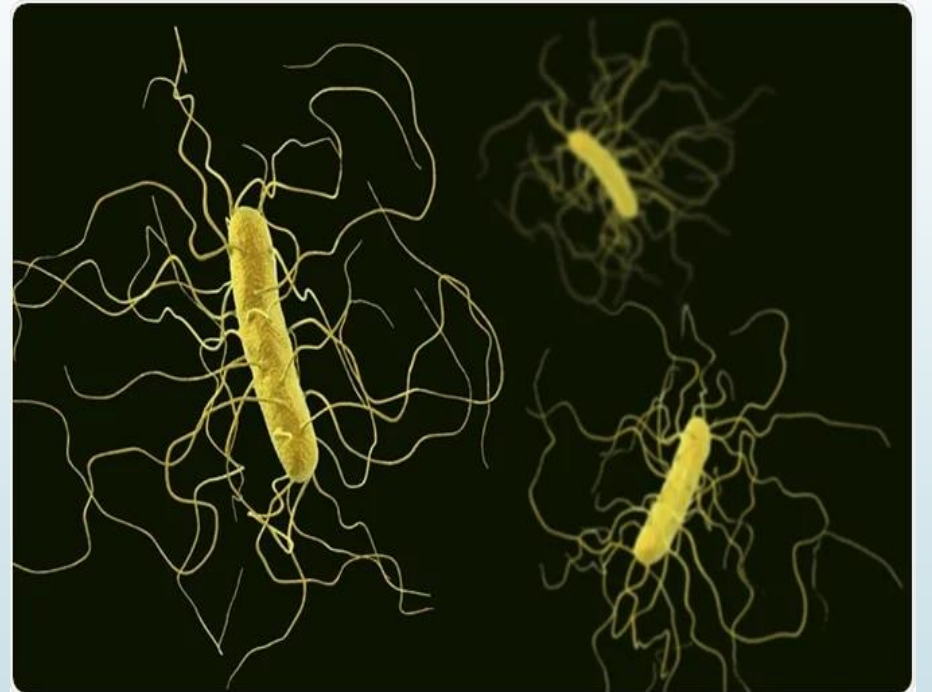
- ▶ Stool Microscopy and Culture:
 - Presence of white cells and red cells
 - Presence of fat globules and fatty acid crystals
 - Presence of ova, cysts or parasites or growth in culture is diagnostic of infectious cause

(An extended infectious screen is necessary in immunocompromised patients)



Stool tests


- ▶ Stool Clostridium difficile toxin:
 - Testing not recommended in children < 1 year
 - Risk factors



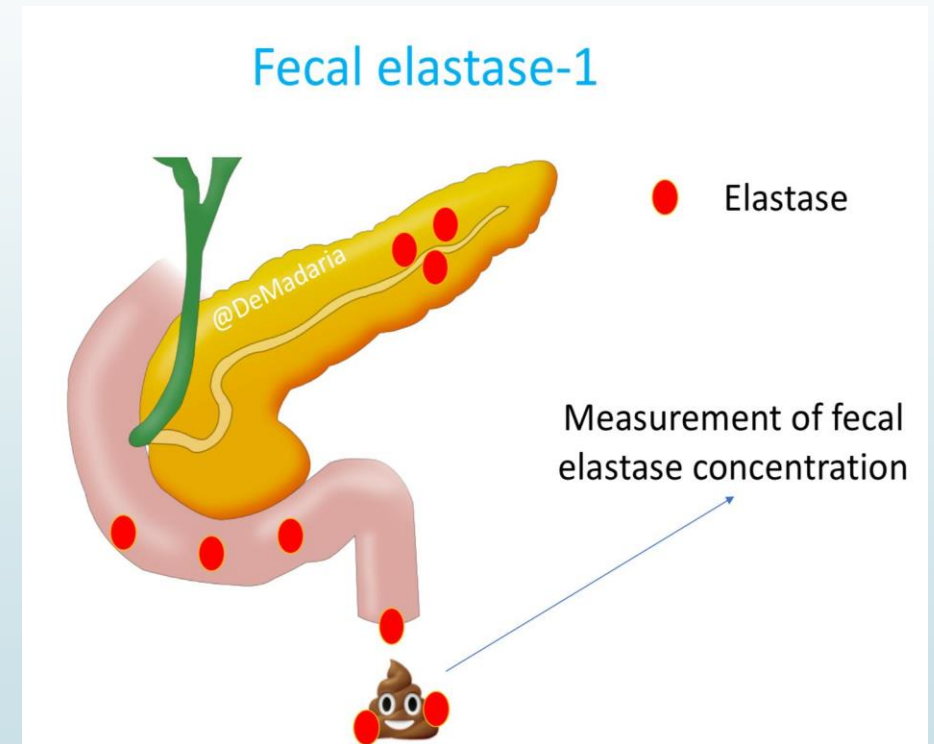
- Stool electrolytes:
 - differentiate osmotic and secretory diarrhea
 - Stool osmotic gap calculation = $290 - 2 \times (\text{Stool Na} + \text{K})$
 - Stool osmotic gap > 100 mOsm suggestive of osmotic diarrhea
 - Stool osmotic gap < 50 mOsm suggestive of secretory diarrhea



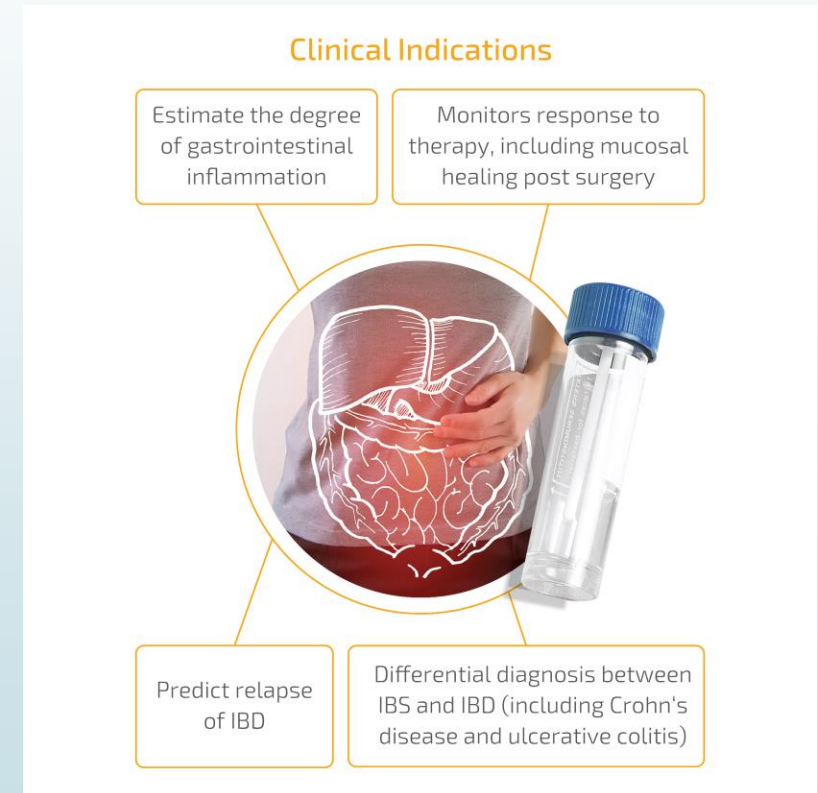
- Stool reducing substances and pH:
 - Positive reducing substances and low pH (<5.3)

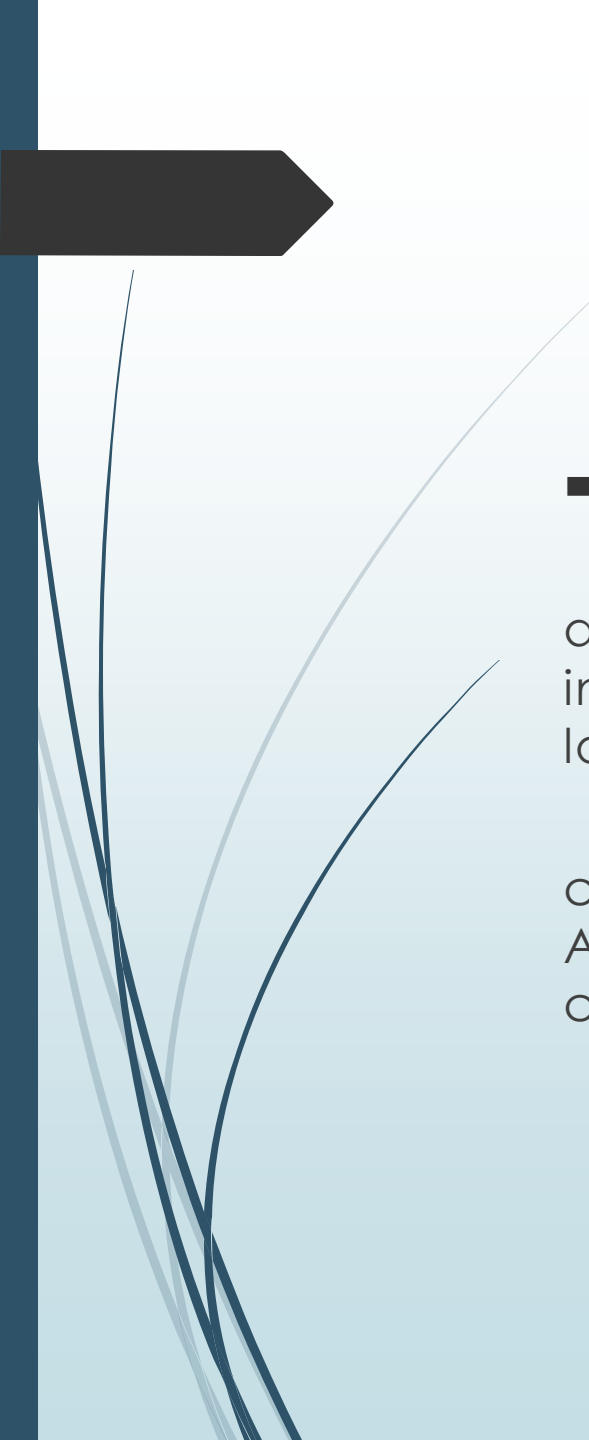


- ▶ Stool pancreatic elastase:
 - Pancreatic elastase is resistant to degradation by intestinal proteases
- It is low in pancreatic insufficiency, however can be falsely low due to dilution in high volume diarrhea



- ▶ Fecal calprotectin (FCP):
 - is a neutrophil-derived cytosolic protein
 - a non-invasive quantitative measure of neutrophil flux to the intestine and thus gut inflammation
 - FCP can be elevated in gastrointestinal infections, juvenile polyps, NSAID use and gastrointestinal bleeding





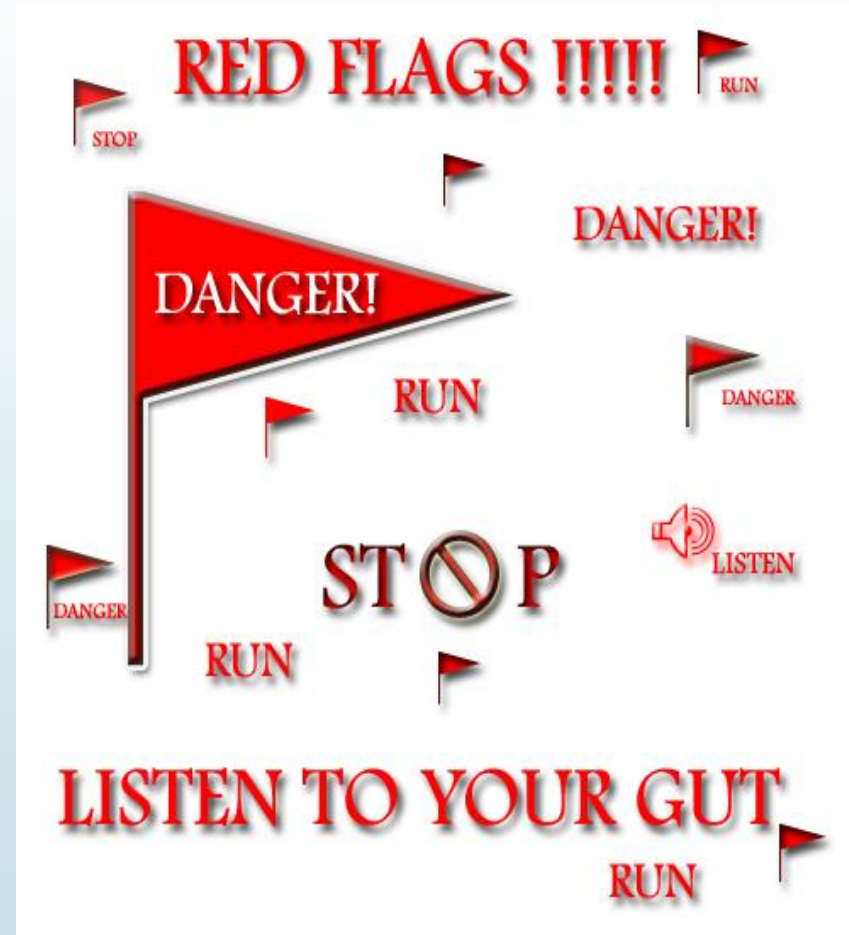► Stool alpha1-antitrypsin (a1-AT):

- a protein which is neither absorbed nor secreted by the intestine and is normally present in low concentrations in stool

- Protein-losing enteropathy (PLE) can be confirmed by quantifying a1-AT in stool and by measuring its clearance from plasma

Red-Flags

1. Hematochezia or melena
2. Weight loss or growth arrest
3. Anemia
4. Persistent Fever





Functional Diarrhea:

Toddler's diarrhea or chronic nonspecific diarrhea

- ▶ Important benign entity to recognize in children, as it is the leading cause of chronic diarrhea in an otherwise well child
- ▶ The diagnosis is based on history and physical examination findings
- ▶ Stools typically contain mucus and/or visible undigested food. There is no defect in small bowel transport of water or electrolytes
- ▶ Dietary factors such as overfeeding, excessive fruit juice or carbohydrate consumption with low fat intake, and excessive sorbitol intake have been reported
- ▶ Often, the primary care physician successfully offers reassurance without making a specific diagnosis, which is a good practice if no red-flags



Intractable Diarrhea of Infancy:

(post-enteritis enteropathy, protracted diarrhea of infancy, secondary disaccharides deficiency, global mucosal dysfunction, and “slick gut” syndrome)

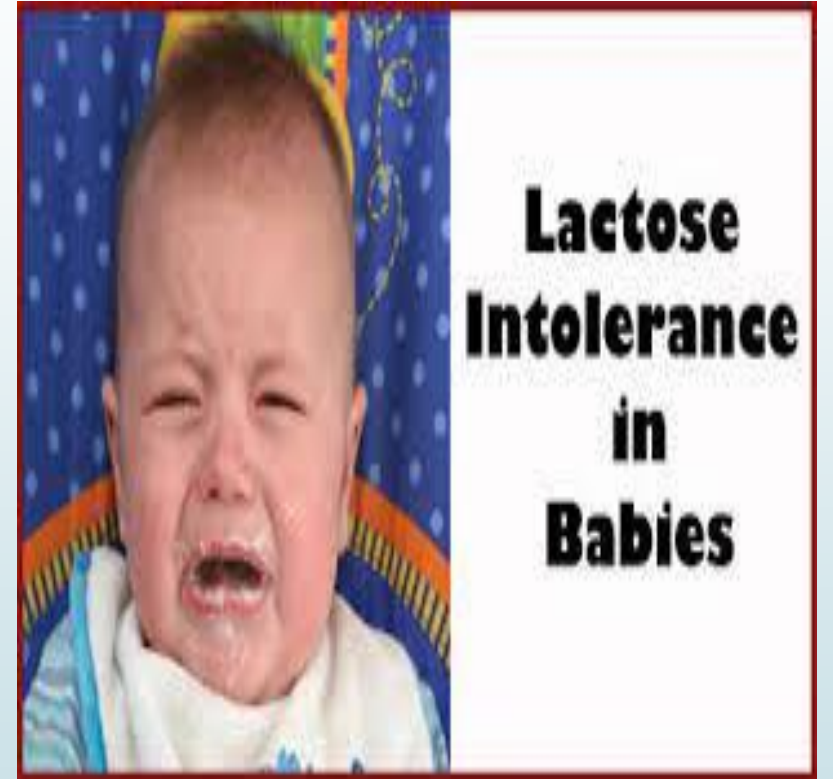Enteric infection and associated compromise of intake and absorption lead to a variable loss of digestive and absorptive capacity in infants

The mildest variant of this effect is transient lactose intolerance

Most severe form (IDI), even the least challenging feedings are not tolerated and, if parenteral nutrition is not possible, death occurs

Suspicion


1. Recurrent episodes of diarrhea
2. Failure to regain weight in an infant (usually 6 mo. old)
3. Absence of breastfeeding
4. Administration of diluted or clear liquid feedings, or restriction of intake (effort to reduce diarrhea or vomiting)



Diagnosis

Based on:

- Physician's awareness of the entity
- Reasonable exclusion of alternative diagnoses
- Patient's response to nutrition therapy and return to full health



Adherence to AAP guidelines for treatment of acute gastroenteritis





Milk and Soy Protein Intolerance-

not an IgE mediated illness

TWO syndromes:

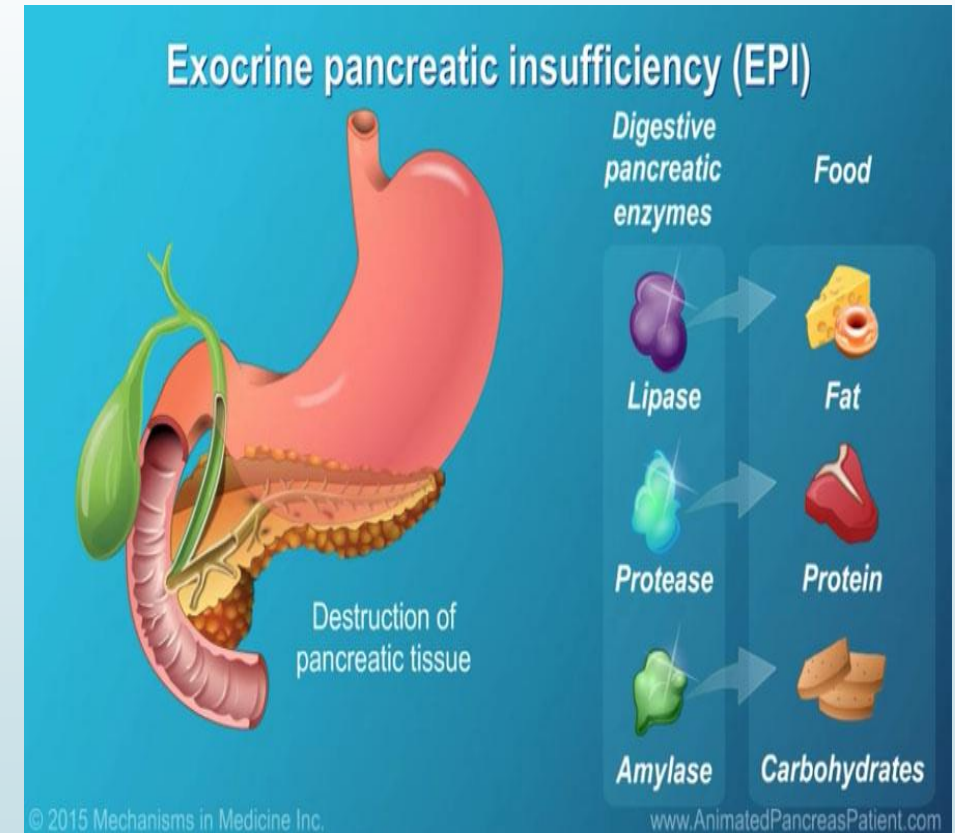
- Enterocolitis - bloody diarrhea in first 3 months of life
- Protein-losing enteropathy - occult blood loss and hypoproteinemia most often seen in infants > 6 months old

Treatment:

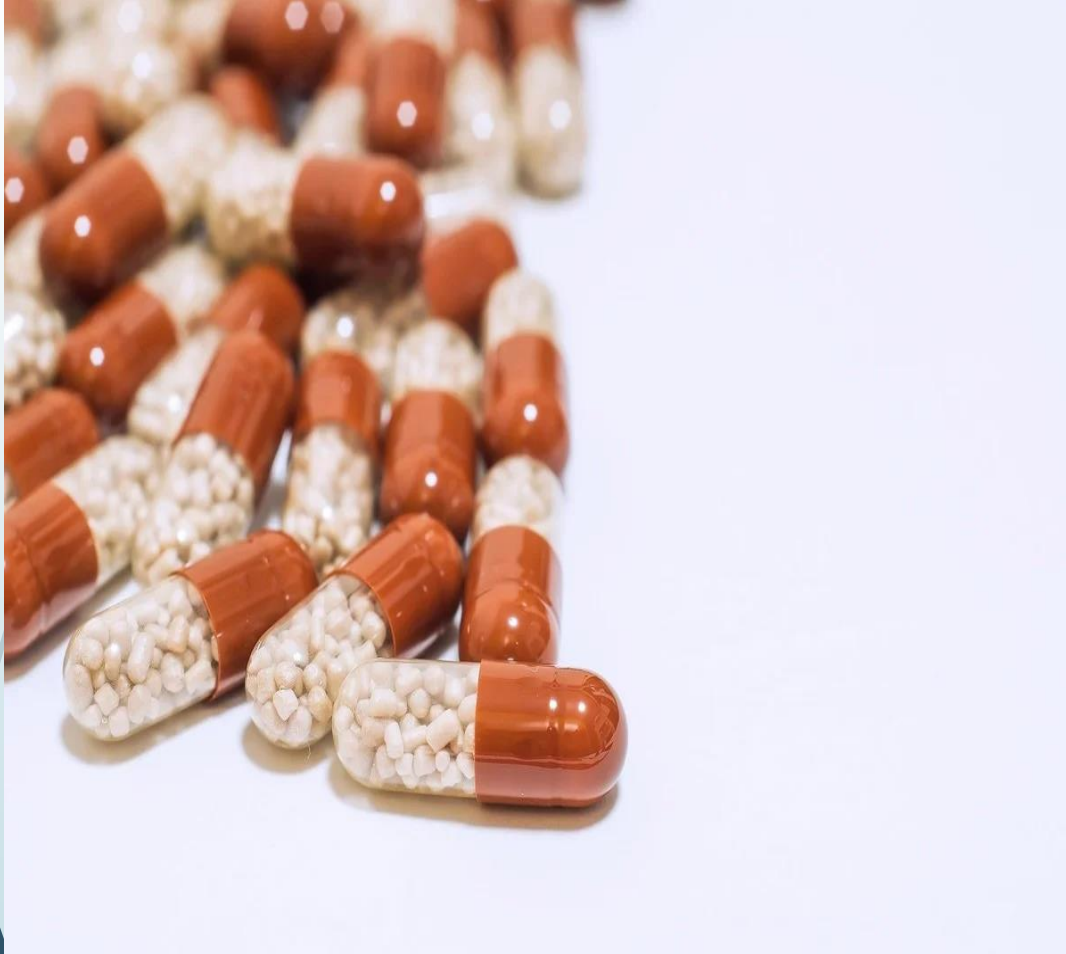- Protein-hydrolysate formula required (due to 20-40% cross reactivity of soy protein)

Fat Malabsorption caused by Pancreatic Insufficiency

- Greasy, foul smelling stool
- Most common is Cystic Fibrosis
 - Picked up on newborn screen usually
 - sweat test is confirming test for CF
- Evaluation
 - Fecal fat (72 hour fecal fat is not practical but better test)
 - Stool elastase (surrogate marker for pancreatic insufficiency)



Treatment

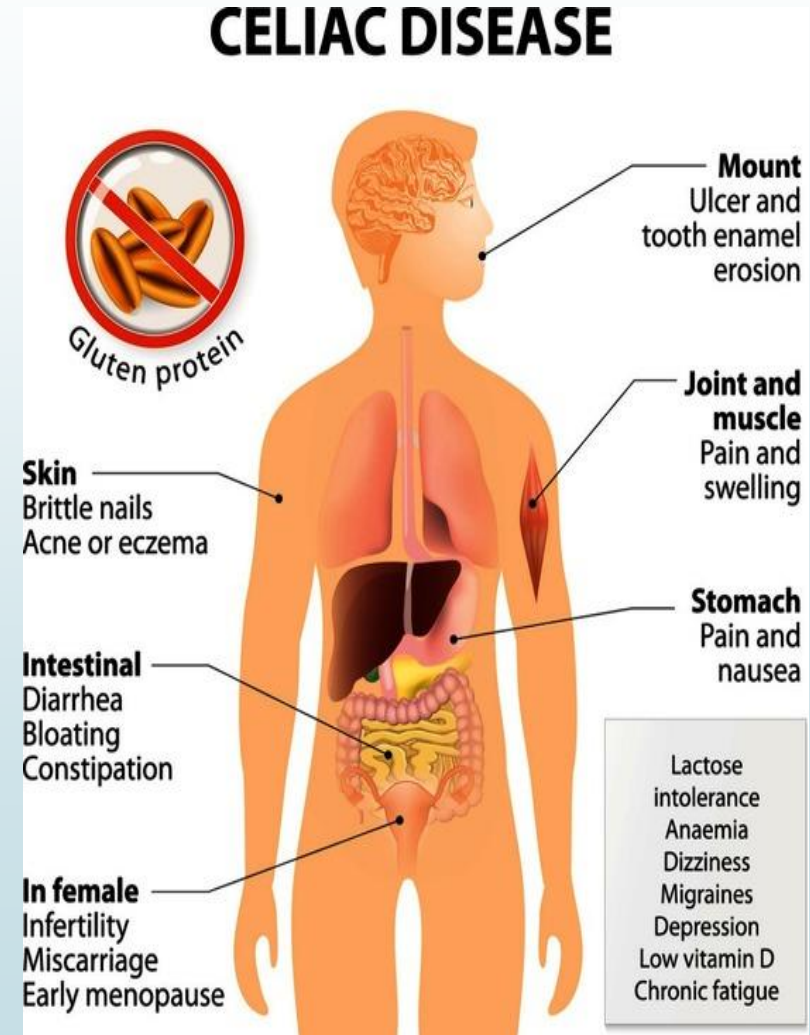


- ▶ Pancreatic enzyme supplementation

Celiac Disease

► Clinical Presentation & Evaluation

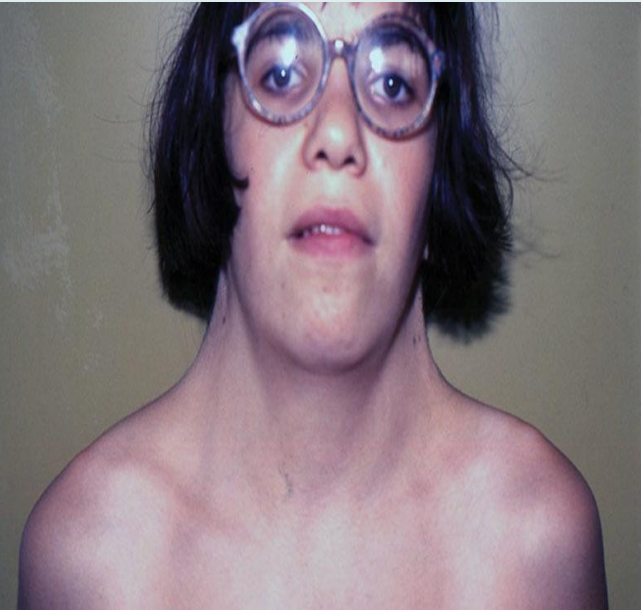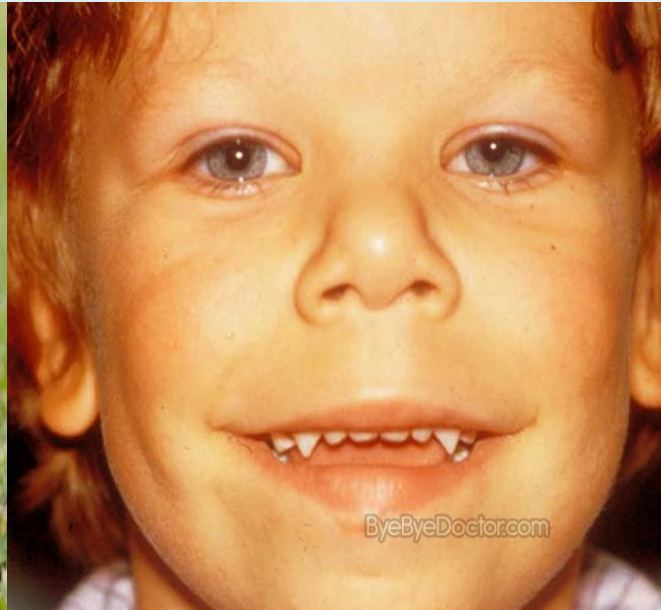- Variable presentation



Increase incidence with other autoimmune disorders:

1. Type 1 diabetes
2. Autoimmune thyroid disorders
3. Rheumatoid Arthritis, and other vasculitic disorders
4. Autoimmune liver disease

Other Syndromes:



Evaluation

- ▶ Screen with Celiac serologies
 - Tissue transglutaminase

- ▶ Confirm with upper endoscopy biopsies

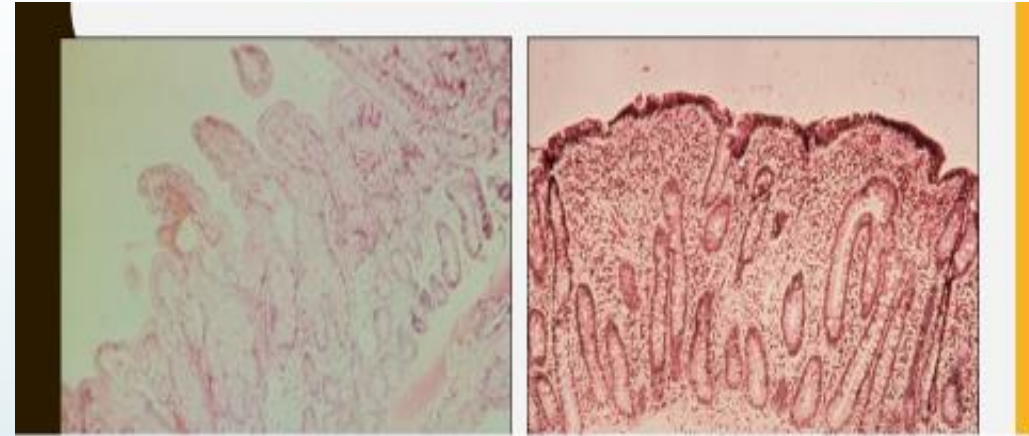


Table I. Histological classification for coeliac disease

	Marsh 0	Marsh I	Marsh II	Marsh IIIa	Marsh IIIb	Marsh IIIc
IEL/100 enterocytes	< 25/100EC	> 25/100 EC	> 25/100 EC	> 25/100 EC	> 25/100 EC	> 25/100 EC
Crypt hyperplasia	.	.	Hyper plastic	Hyper plastic	Hyper plastic	Hyper plastic
Villous atrophy	.	.	.	PVA	STVA	TVA
	Microscopic enteritis			Macroscopic enteritis		

EC: enterocytes; PVA: partial villous atrophy; STVA: subtotal villous atrophy; TVA: total villous atrophy.

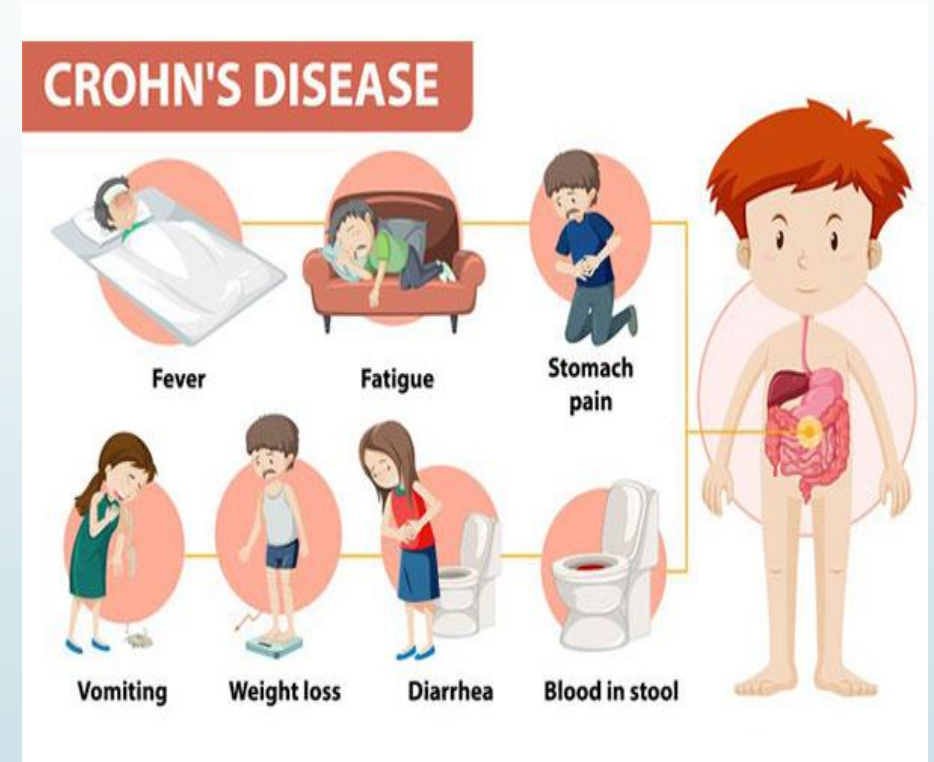
Treatment

- ▶ Gluten-free diet for life
- ▶ Adherence is a major issue
- ▶ Concerns of nutritional deficiencies, growth and pubertal delay, bone health



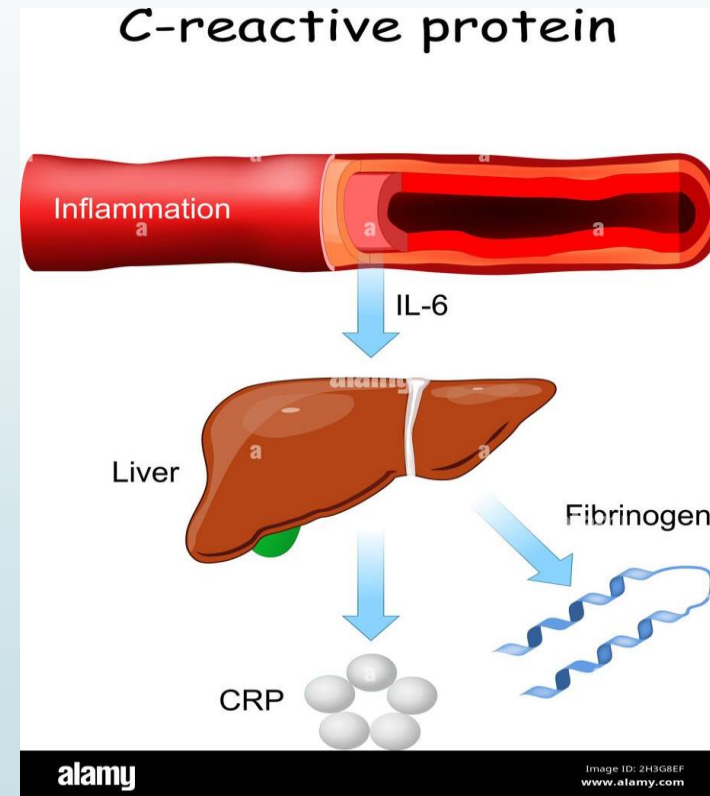
Inflammatory Bowel Disease

- General Clinical Characteristics
 - Weight loss, abdominal pain, diarrhea
 - Peri-anal involvement - anal tags/fistula (Crohn's)
 - Positive Family history



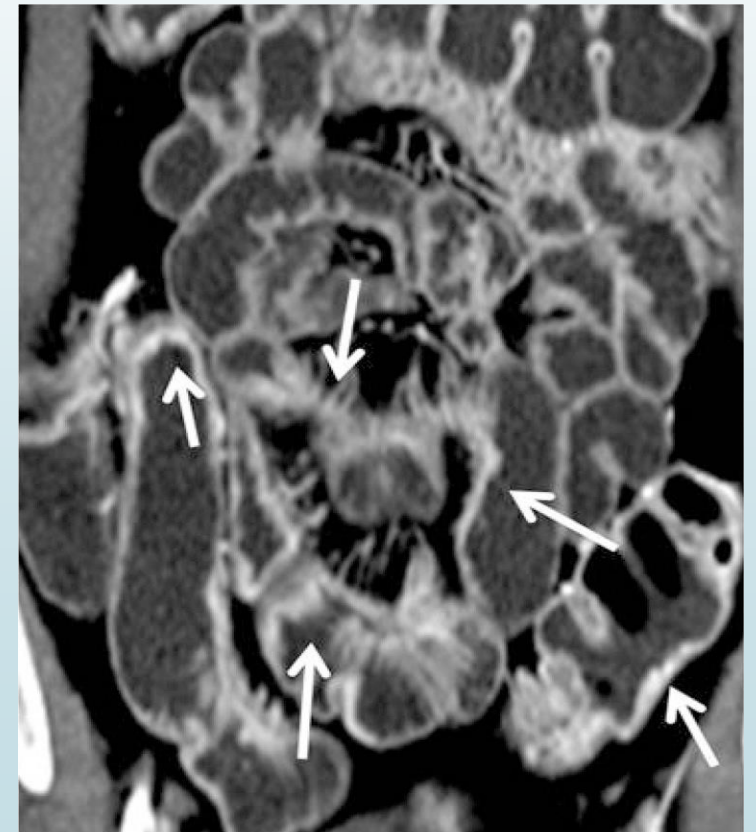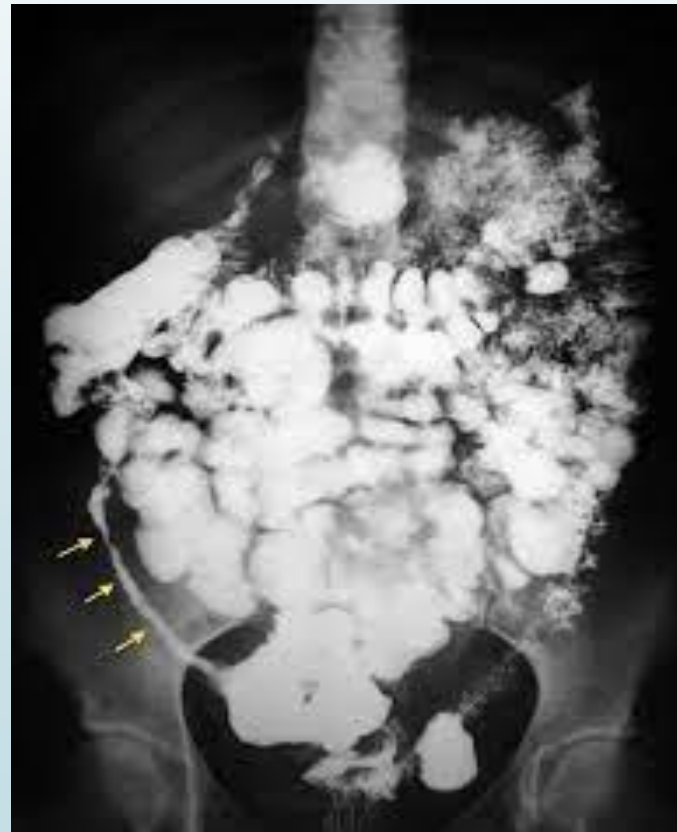
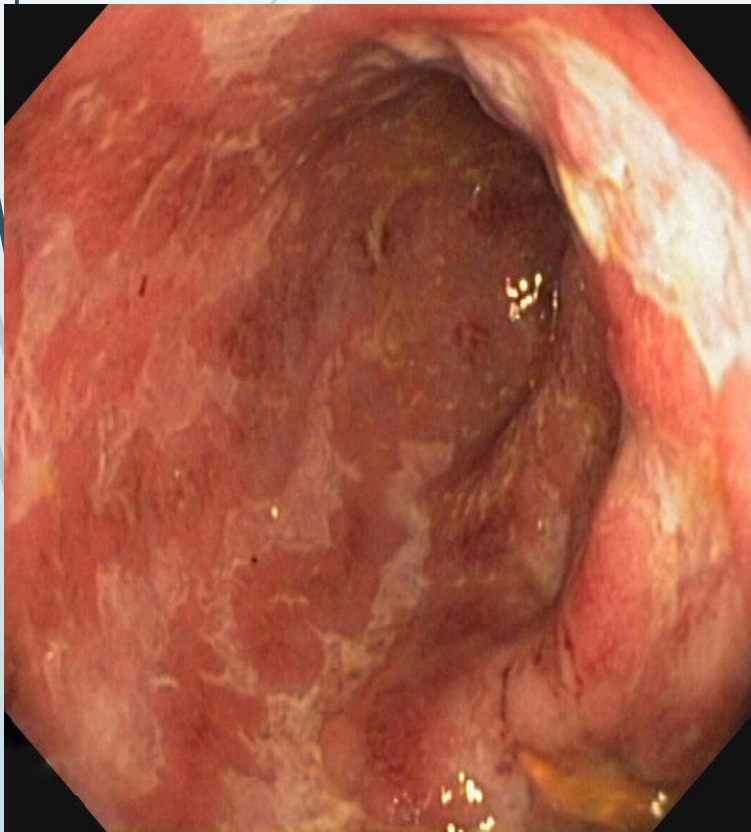
Laboratory findings

- ▶ Anemia
- ▶ Hypoalbuminemia
- ▶ Elevated CRP and ESR



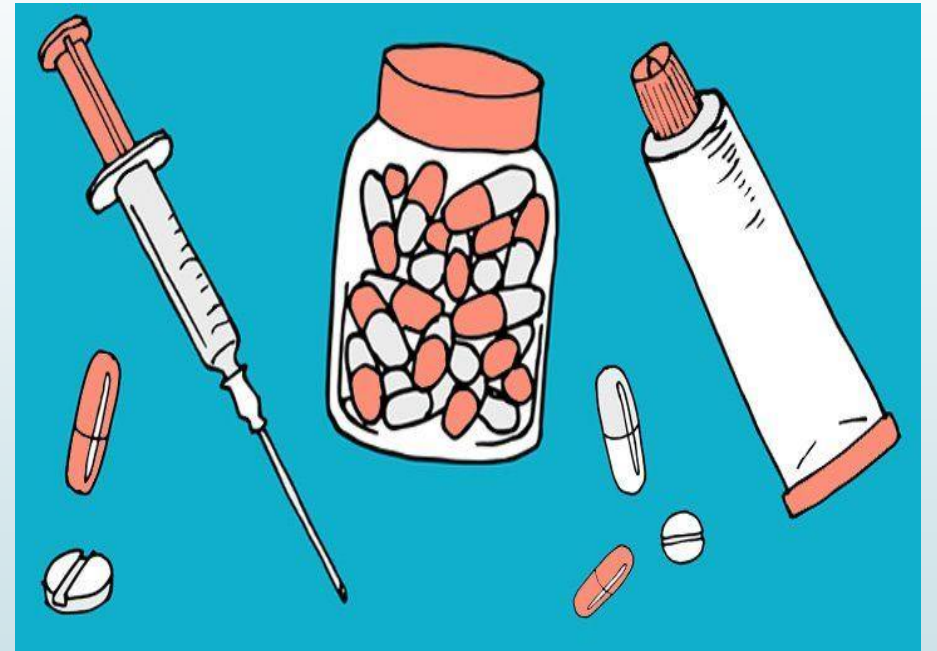Evaluation

- ▶ Upper endoscopy and colonoscopy for diagnosis
- ▶ Small bowel imaging with MRI or small bowel follow through



Treatment

- ▶ Anti-inflammatory medication
- ▶ Immunosuppressants
- ▶ Biologics
- ▶ Surgery



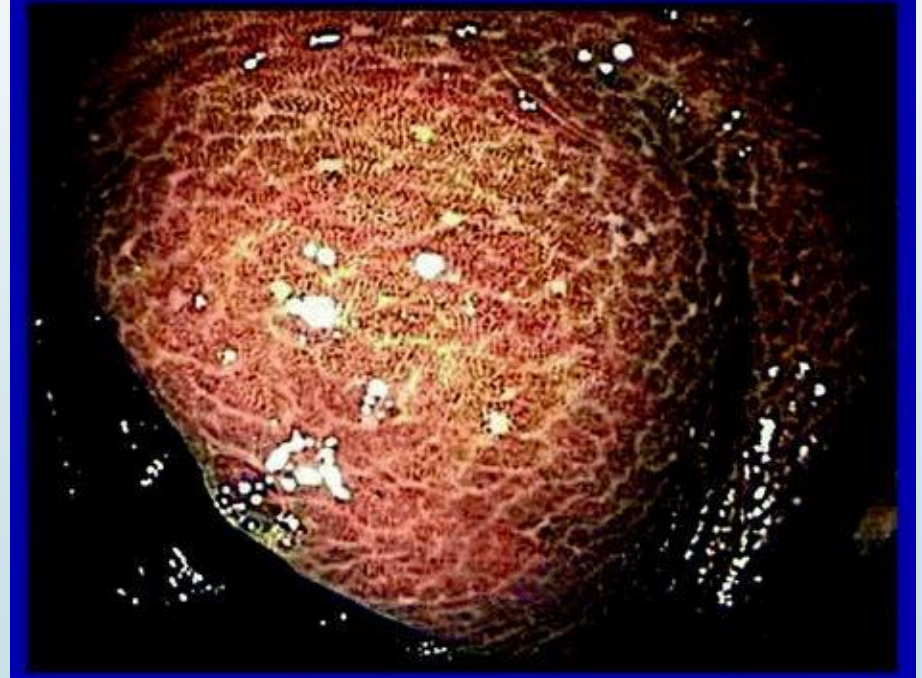
FACTITIOUS DIARRHEA

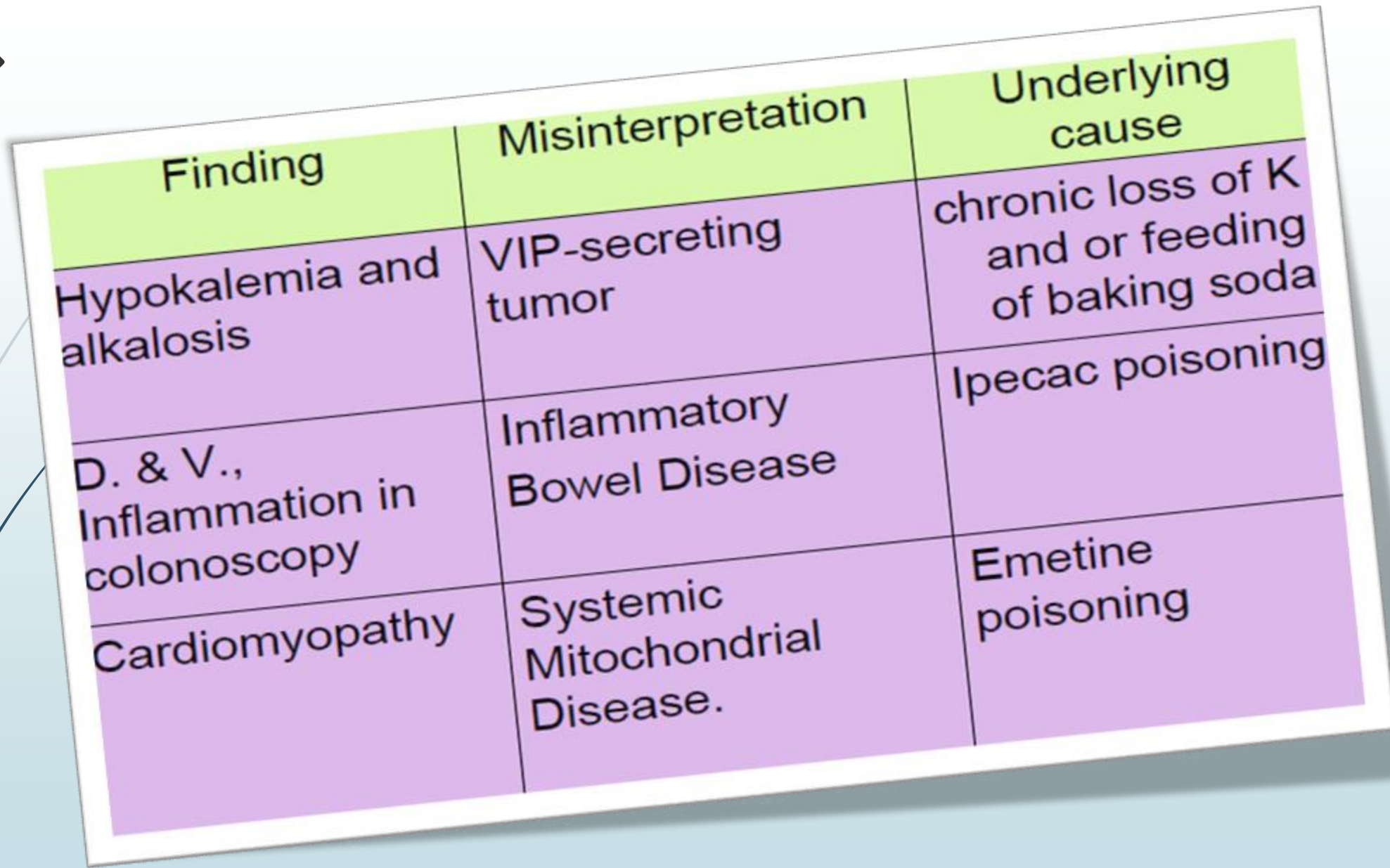
Intentional poisoning of infants and children with osmotic agents (Magnesium citrate, PEG) and irritants (ipecac, bisacodyl) can cause chronic diarrhea, growth arrest, and death

Clinically:

watery or bloody diarrhea that usually resolves when the patient is admitted to the hospital

Melanosis coli

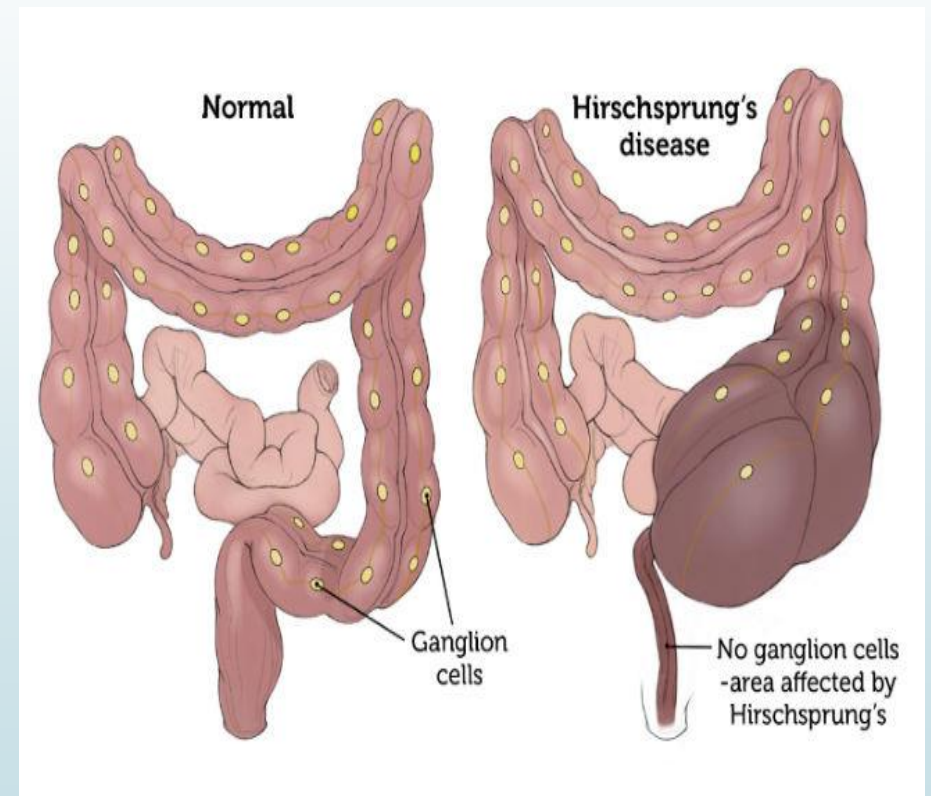




Finding	Misinterpretation	Underlying cause
Hypokalemia and alkalosis	VIP-secreting tumor	chronic loss of K and or feeding of baking soda
D. & V., Inflammation in colonoscopy	Inflammatory Bowel Disease	Ipecac poisoning
Cardiomyopathy	Systemic Mitochondrial Disease.	Emetine poisoning

Hirschsprung's disease

- ▶ May present enterocolitis and diarrhea, and may progress to life-threatening toxic megacolon
- ▶ Infant presents with history of delayed passage of meconium, constipation, failure to thrive
- ▶ Per rectal examination will reveal an empty rectum and gush of air and stool following withdrawal of finger



Evaluation:

