



# COLLECTED OSCE EXAMS

General surgery

Collected by:

Shahed Atiyat

Rahaf Turab

Insaf Ammouri

Rahaf Okashah

**Doctor 2021**

## 4th Year OSCE

### 📌 1st Semester, 1st Day:

#### 1. Hx. of rectal bleeding in old age patient.

- Investigation to do: colocoscopy
- Diagnosis: colon cancer

#### 2. PEx. of thyroid and lymph nodes

### 📌 1st Semester, 2nd Day:

#### 1. Hx. of PVD

#### 2. PEx. of patient with jaundice (specifically for obstructive jaundice)

### 📌 2nd Semester, 1st Day:

#### 1. Hx. of intestinal obstruction

#### 2. PEx: Diabetic Arterial incificency

### 📌 2nd Semester, 2nd Day:

#### 1. Hx. of breast lump

#### 2. PEx. of acute appendicitis

**Doctor 2020**

## 4th Year OSCE

### 📌 1st Semester, 1st Day:

#### 1. Hx. Peds: 9 months old baby complaining of abdominal pain, vomiting.

- Take FOCUSED history: 1 day duration + raises legs when crying + no stool discharge (obstipation) + billious vomit.
- What do you look for in PEx.: Sausage mass + dance sign (mention location)
- Give ddx: Intussusception
- What investigations do you do: Ultrasound (donut/ target sign and pseudokidney.
- What is the management: Hydration and IV fluid + NPO
- What is the treatment (name the procedure): Contrast enema.

#### 2. Hx. 70 years old with anemia and changed bowel habits (history of melena of 1 month duration, lower abdominal pain + abdominal distention, fatigue, constipation, no weight loss or anorexia).

- Name 1 specific investigation: CT?, CBC?, stool blood occult?
- DDx.: Colon cancer /Diverticulitis.

#### 3. PEx. Patient with colicky abdominal pain.

- Do abdomen PEx. (Mention PR exam and inguinal, mention bowel sounds in auscultation, mention hepatomegaly palpation test).

### 📌 1st Semester, 2nd Day:

#### 1. Plastic station: burned patient (hands, torso, head)

- Calculate surface: 45%
- Patient has inhalation burn, what caused it? edema
- Amount of fluid: (patient's weight is 45kg, so  $40 \times 45 \times 45$ )
- the patient complains of right upper limb pain and numbness, what is the diagnosis? How do we treat it? Compartment syndrome (tissue ischemia), escharotomy.

## **2. GI station:**

- Take history from a patient with RUQ pain: checklist included: pale stool, jaundice, itching, vomiting, fever, and SOCRATES obviously).
- Give DDx.: Acute cholecystitis, acute cholangitis, acute pancreatitis.
- Labs: CBC, amylase/ lipase.
- Imaging: Ultrasound
- Give definite diagnosis: Most probably cancer somewhere.

## **3. Endocrine station:**

- Focused thyroid PEx.

## **📌 2nd Semester, 1st Day:**

### **1. High voltage electrical burn for 2 hours duration**

- Give 5 complications? How to identify these complications? Compartment syndrome, bone fracture, myoglobinuria & myoglobinemia, head and peripheral nerve injury, arrhythmias
- How to determine the fluid resuscitation needed? What determines the outcome? Give the patient IV fluid with keep monitoring the vital, serial PCV and CVP, Determined mainly by urine output (0.5-1 ml/kg/hr).

### **2. 40 year old male patient presented with dysphagia, take a proper history and answer the following questions:**

- What is your diagnosis? GERD
- Give 4 investigations? Barium swallow, manometry, endoscopy, 24h ph monitoring

### **3. Physical examination peripheral vascular disease**

📌 **2nd Semester, 2nd Day:**

**1. 3 months years old baby came to emergency room crying with inguinal swelling look to the picture (inguino-scrotal swelling) and answer the following questions:**

- Take a focused history from the parents investigating the cause.
- What you will expect to see in physical examination?
- What is your diagnosis?

**2. 54 years old patient came to your clinic with 2 weeks of vomiting food content**

- Take a focused history investigating the cause
- Dx? Peptic ulcer disease (duodenal) with gastric outlet obstruction

**3. A 30 year old male came to emergency room with RLQ pain for 12 hours, do a focused abdominal examination to confirm the diagnosis with acute appendicitis.**

Inspection

Palpation: Superficial (RLQ tenderness, rigid abdomen) and deep palpation (RLQ tenderness)

Special signs psoas sign, obturator sign, Macburrnys tenderness, cough tenderness, rovsing's sign, rebound tenderness.

**Doctor 2019**

## 4th Year OSCE

### 📌 1st Semester, 1st Day:

1. **Thyroid.**
2. **Lower GI bleeding.**
3. **Foreign body ingestion. (Peds)**

### 📌 1st Semester, 2nd Day:

#### 1. **Breast lump, 55 years old female**

- Take focused Hx.: Malignant presentation; ask about signs and symptoms of metastasis.
- Investigations: US, mammogram, core biopsy.
- Diagnosis: Breast cancer.

#### 2. **Acute appendicitis, 20 year old, female complaints of abdominal pain and suspected appendicitis.**

- Take focused history.
- 4 specific signs related to appendicitis to confirm our suspicion: rebound tenderness, psoas sign, operator sign,....
- Labs: CBC, CRP, HCG.
- Images: US, CT.
- Differential diagnosis other than appendicitis (related to RIF): UTI, IBD, ruptured ectopic pregnancy, ovarian torsion.

#### 3. **Recurrent UTI in 3 years old female patient.**

- Take focused Hx.
- Images: MAG3, DMSA, MCUG
- Treatment in case the pt complain of low grade infection: Antibiotics
- Diagnosis: VUR.

**📌 2nd Semester, 1st Day:**

- 1. Hemangioma (plastic)**
- 2. Neuroblastoma (peds)**
- 3. Intestinal obstruction**

**📌 2nd Semester, 2nd Day:**

- 1. Burns (plastic)**
- 2. Hydronephrosis (peds)**
- 3. Cholecystitis**

# 6th Year OSCE

## 📌 1st rotation:

### 1. Hx/oral: Thyroid mass

- Take a focused history assessing functional status of the thyroid.
- When do we run a thyroid scan on a patient with a thyroid mass?
- Scenarios where we don't do FNA for a thyroid mass.
- When do we choose/prefer total thyroidectomy over hemi-thyroidectomy when the mass has a birad score of 6?

### 2. Hx/oral: SBO

**A 60 y.o lady presented to the ER with her 4 boys and 3 girls with acute abdominal pain and vomiting**

- Take a focused history.
- After analyzing chief complaints and assessing risk factors give a diagnosis: Obstructed umbilical hernia
- X-ray (erect vs supine, small vs large bowel, abnormal radiological findings)
- Management
- Possible Complications
- Do we perform a trial of manual reduction for this kinda hernia? Explain.

### 3. PEx: Left inguinal swelling

Assess bilaterally

Inspection, palpation, percussion (bowel vs omentum), auscultation (femoral bruit), how to end the examination (DRE, LNs, external genitalia)

Management and approach to management.

## 📌 2nd rotation:

### 1. Bariatric History: 40-year-old woman with a BMI of 50.

#### A. Take history regarding her obesity.

- When did the weight gain begin?
- Has she tried any diets or weight reduction medications?
- What does she believe is the cause of her obesity? Ask about symptoms of Cushing's syndrome and whether she has been diagnosed with it.
- Ask about any history of diabetes mellitus (DM) and her most recent HbA1c level.
- Assess for comorbidities such as obstructive sleep apnea (OSA), osteoporosis, hyperlipidemia, and hypertension.
- Determine if she has a preference for sweet foods.
- Ask if she experiences GERD or heartburn symptoms.

#### B. What is the preferred bariatric surgery for her: sleeve gastrectomy or Roux-en-Y gastric bypass? Provide two reasons for your choice.

#### C. Where should the patient be referred for further evaluation and management?

Psychiatry

### 2. Neck Lump Examination to Assess Thyroid Function

Here are key points in the checklist, though there are additional points not listed here:

- Ask the patient to open their mouth to check for a thyroglossal cyst.
- Request the patient to swallow.
- Instruct the patient to perform neck flexion while palpating.
- Ensure a thorough examination of the lymph nodes.
- Auscultate for a carotid bruit.
- Ask the patient to drink water while palpating the thyroid gland.

### **3. Oral, burn station:**

- What are the causes of her inhalation injury?
- Calculate the surface area that is affected.
- What are the indications for admitting this patient?
- Provide two signs of carbon monoxide poisoning.
- How can we test for carbon monoxide poisoning?
- Based on the provided image, what is the degree of the burn? What information led you to this conclusion? (The image shows a hand with thrombosed veins.)
- What could be the cause of right arm pain, and what is the appropriate treatment? Consider compartment syndrome and escharotomy.

### **📌 3rd rotation:**

#### **1. Hx: 40 year old male, previously healthy complains of dysphagia of 4 weeks duration.**

- Take a focused history.
- What are the investigations you are going to order and what are the expected findings?
- What is the diagnosis?

#### **2. Hx: 54 year old lady, presented with left upper lateral quadrant breast mass, a biopsy was performed and it was confirmed that she has a breast cancer.**

- Take a history to assess the local and systemic extension of the disease.

#### **3. PEx: Examine a patient with lower limb varicose veins**

## 📌 4<sup>th</sup> rotation

### 1. 10 week year old with imperforate anus did surgery (Pic of stoma).

- Type? Double loop
- Other investigation? Rule out VACTERL so Echo, X-ray & abdominal US.
- 4 complication?
- What to do now? Cross table x-ray, Colostogram.
- What you see in this picture? rectourthral fistula.

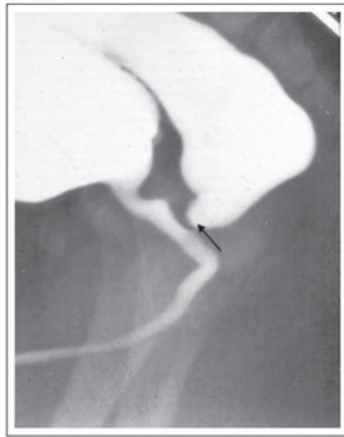
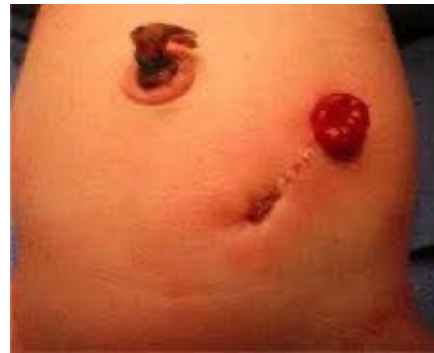

FIGURE 9: Lateral radiograph during high-pressure distal colostogram showing a recto-prostatic fistula (arrow).



### 2. 60 year old female with DM complaint of painless foot swelling

- Take a history.
- Investigation? X-ray or MRI
- Joint that are effected in Charcot joint?
- Treatment? Total contact cast

### 3. Patient complain of vomiting and pain do focused abdominal exam.

## 5<sup>th</sup> rotation

### **1. Melanoma or pigmented basal cell History with picture**

- Describe the lesion (shape site size border, etc).
- Risk factors? (Sun exposure, immune suppression drugs, etc).
- How to diagnose and stage (biopsy, CT with contrast for mets, idk what else)
- Staging system names?

### **2. Parotid gland swelling/mass physical exam.**

### **3. Gastric cancer oral**

- 7 Risk factors (H-Pylori, Smoking, Alcohol, Radiation, Smoked meat/red meat, Asian ethnicity, foods rich in nitrosamines, ...).
- 6 Symptoms (Epigastric pain, internal bleeding, peptic ulcer?, hematemesis, melena, fever, weight loss, anorexia, perforation??).
- How to diagnose and stage? (4 tests, EGD, Biopsy, CT Contrast (or mri) and endoscopic ultrasound).
- Treatment (name surgery and indication) (depends on the location of the tumor, so either partial gastrectomy with roux en y or complete).

**Doctor 2018**

## 6th Year OSCE

### 📌 1st rotation

#### 1. 50 year old male with reducible abdominal mass

- Take focused history
- What is the diagnosis? Reducible incisional hernia

#### 2. 6 week old baby has vomiting

- Take focused history (included risk factors)
- What is the pertinent sign you see in physical exam?
- What are the investigations?
- What are the management options?

#### 3. Patient has crampy calf pain since 3 months after walking 300 m , that relieved by rest , patient denied trauma , no rest pain

- Diagnosis?
- Risk factors?
- Management?
- Indication for revascularization ?
- Risk of limb loss in this case?

### 📌 2nd rotation

#### 1. Third degree burn

- Percentage?
- Signs of obstruction?
- Indication for escharotomy in chest and neck?
- Advantages of early escharectomy?
- Percentage of fluid resuscitation in adult an child?
- Symptoms indicate compartment syndrome?
- What is the optimal fluid resuscitation?

**2. 48 yo female , inferior neck mass 3 cm for 2 years duration**

- Focused history (mention the risk factors )
- Two physical signs that indicate malignancy
- Two investigations
- Types of surgeries

**3. 60 yo male with no medical history complaining of bleeding per rectum**

- Take focused history
- Physical signs on general abdomen, neck and DRE
- If the DRE showed a mass that is hard, 5 cm from the anal verge what is the diagnosis
- What is the diagnostic tool

**📌 3rd rotation:**

**1. 85 years old male patient, they mentioned brief history goes with pancreatic cancer. Hb11 (another general labs I forgot them) and on CT scan was found to have an abdominal mass**

- Do physical examination
- What other investigations do you want to order? CEA, CA 19-9, LFT, amylase lipase, imaging for staging?
- Tell the patient's family about the prognosis? Poor prognosis
- Describe what you see in the abdominal X ray
- Management

#### 📌 4th rotation

##### **1. 61 yr old male with sudden localized lower left quadrant abdominal pain came to the emergency.**

- Take focused history: Don't forget to cover colorectal cancer as a ddx. Ask about IDA, distention, blood in stool etc"
- Diagnosis? Acute diverticulitis
- Diagnostic test? CT with IV contrast
- Complications? Perforation/peritonitis, abscess
- Treatment - uncomplicated? IV antibiotics
- What to do on follow up? Colonoscopy (screening for colon cancer)

##### **2. 73 yo male smoker with a history of DM and HTN came with leg pain.**

- Do focused physical examination and mention what you're doing with findings.

##### **3. A picture of basal cell carcinoma on the forehead/scalp of an old man. With another picture of where the donor site was taken (postauricular)**

- Type of graft? Full thickness skin graft
- What to do to the donor area? Close approximation / direct closure
- Two drawbacks? Less available, more difficult to take.
- Benefits over STSG? better texture, less pigmentation, more durable, better cosmetic..
- Factors affecting graft take? Vascularity, barrier, infection, mobility
- Signs of graft take? Adherent, pink, blanchable

## **5th rotation:**

### **1. Patient referred to you for concern of gastric CA**

- 6 symptoms of gastric ca: Dyspepsia, indigestion, Dysphagia, Odynophagia, Hematemesis, Early satiety/anorexia, Abdominal pain (was mentioned), Abdominal distention, Ascites / jaundice
- 6 Risk factors: Smoking, Alcohol, H. pylori, Increased age, Ethnicity (east/south asian), Foods containing nitrosamines, Low fiber high fat diet, Blood A group, Pernicious anemia
- Tx: Subtotal gastrectomy if distal, Total gastrectomy if proximal
- Prognosis: Stage, grade and something else
- Investigations needed for Dx and staging:
  1. EGD with biopsy +/- US
  2. Abdominal and thoracic CT
  3. PET?
  4. Brain MRI?

### **2. Parotid gland examination**

### **3. 8 days old newborn with abdominal distention with x ray image showing soap bubble appearance.**

- Take history: There was no delayed meconium and diagnosis was NEC. Ask about risk factors (prematurity, bottle feeding, birth asphyxia, maternal diseases as PET and sepsis).
- What are the x ray findings? Pneumatosis intestinalis, n they asked for others I guess they wanted extravisceral free air and portal venous gas
- What is the management? IV fluids, Oxygenation, NPO, NG tube, Broad spectrum abx.
- What are the indications for surgery? Perforation, Peritonitis ..etc as in slides

**Doctor 2017**

# 6th Year OSCE

## 📌 1st rotation

### 1. Neck mass

- Focused history for thyroid CA
- Investigations
- 2 modalities of treatment

### 2. 80 kg patient with burn (head/neck first degree, right upper limb second degree, left upper limb third degree)

- What is the percentage of burn? 18%
- Measure the amount of fluid we need to give the patient? ( $4 \times \text{weight} \times \text{percentage}$ )
- Do we give prophylactic antibiotics? No, why? Increase the incidence of fungal infections /increase bacterial resistance /no proven evidence of decreasing the incidence of sepsis.
- Which area will need skin grafting? The third degree burn (left UL), why? Because it will heal by fibrosis.
- The patient complains of left upper limb pain and paresthesia, what is the diagnosis? Compartment syndrome (tissue ischemia), how do we treat? Escharotomy
- The patient complains of headache and confusion, what's the diagnosis? CO poisoning, how to diagnose? Carboxyhemoglobin level

### 3. 65 year old with dark urine and yellow sclera

- Focused history
- Physical
- labs
- Imaging

## 📌 2nd rotation

### **1. Patient presented with breast lump,**

- Take detailed history to know the cause.
- Give 3 differentials.
- Then questions about diagnostics management.

### **2. Patient presented with acute constipation, image shown for abdominal x-ray indicating bowel obstruction.**

- Take detailed history to know the cause.
- Then questions about diagnostics management.

### **3. Pregnant lady presented with chronic lower limb pain and swelling, take detailed history to know the cause (chronic venous insufficiency)**

## 📌 3rd rotation

### **1. Painless obstructive jaundice: pancreatic CA (history, symptoms, labs, imaging) there was an MRCP pic asking what these structures are: pancreas and bile duct and what is the obstruction sign name called?**

### **2. Peripheral arterial disease history, bilateral lower limb pain 63 year old diabetic and with dyslipidemia: don't forget to include disc prolapse in the DDx there was a mark on it**

### **3. Electrical burn:**

- Give 5 complications : brain injury, fracture, compartment syndrome, AKI, Arrhythmia
- Clinical signs for each one of the complications: dark red urine for myoglobinurea, loss of range motion, pain, deformity... etc.
- How to assess the fluids needed? Can't use the formula of burns percentage so instead we calculate deficit and maintenance and check urine output and vitals

#### **4th rotation**

##### **1. 50 year old male with reducible abdominal mass**

- Take focused history
- What is the diagnosis? Reducible incisional hernia

##### **2. 6 week old baby present with vomiting**

- Take focused history (include risk factors)
- What is the pertinent sign you see in physical exam?
- What are the investigations?
- What are the management options?

##### **3. Patient has crampy calf pain since 3 months after walking 300 m, it was relieved by rest, patient denied trauma, no pain while rest**

- What is the diagnosis?
- Risk factors?
- Management?
- Indication for revascularization?
- Risk of limb loss in this case?

#### **5th rotation**

##### **1. Case of 3rd degree inhalational burn**

- Percentage
- Signs of obstruction
- Indication for escharotomy in chest and neck
- Advantages of early escharotomy
- Percentage of fluid resuscitation in adults and children
- Symptoms that indicate compartment syndrome
- What is the optimal fluid resuscitation

**2. 48 year old female, presented with inferior central neck mass 3 cm in size of 2 years duration.**

- Take focused history (mention risk factors)
- Mention 2 physical signs that indicate malignancy
- 2 further investigations
- Types of surgeries that could be done

**3. 60 year old male with no medical history complaining of bleeding per rectum**

- Take focused history
- Physical signs on general, abdominal, neck , & DRE
- If the DRE shows a mass that is hard, 5 cm from the anal verge, what is the diagnosis?
- What is the diagnostic tool?

### **6th rotation**

**1. Gastric CA, mention:**

- Risk factors
- Surgery type
- Signs and symptoms
- What is radical gastrectomy?

**2. Case of primary spontaneous pneumothorax (PSP) due to bullae in a tall thin man, mention causes, steps of Management, safe triangle borders?**

**3. Cleft lip and palate (oral questions from the handout)**

### **7th rotation**

**1. Perforated peptic ulcer**

**2. skin tumor**

**3. Intussusception**

**Doctor 2016**

## 6th Year OSCE (016 batch)

### 📌 1st Rotation

- 1.oral: Burn + acute cholecystitis
2. Hx. chronic arterial insufficiency
3. PEx. cecal tumor

### 📌 2nd Rotation

1. Oral: acute limb ischemia
2. Oral: Inguinal hernia in pediatric patient
3. Hx. of SBO
4. PEx. Thyroid

### 📌 3rd Rotation

1. Oral: facial burn
2. Oral: Inguinal hernia (adult)
3. Hx. Thyroid cancer
4. PEx. Focused abdominal exam for RIF pain

### 📌 4th Rotation

1. Oral: RIF pain (DDx., how to differentiate and management)
- 2.Oral: 7 year old boy RTA-> (approach in the ER/ primary and secondary survey.
3. Hx. 65 year old female with a breast lump (focused)
4. PEx. Examine the lower limb to rule out peripheral arterial disease

## Other OSCE stations

### 📌 **Cardiothoracic:**

1. **Chronic Arterial insufficiency.**
2. **Chronic Venous insufficiency.**
3. **Pneumothorax (Twice).**
4. **lung cancer.**

### 📌 **GI:**

1. **Colon CA (3 times).**
2. **Diverticulitis.**
3. **Acute pancreatitis (twice).**
4. **Intestinal obstruction (twice).**
5. **Hemoptysis.**

### 📌 **Breast:**

- **Breast lump history.**
- **Mammogram Pictures.**
- **Pictures (Breast cancer, Abscess, Axillary breast, Fistula , True cut biopsy).**

### 📌 **Endocrine:**

- **Diabetic foot.**
- **Parotid exam (twice).**

### 📌 **Plastic:**

- **Syndactly.**
- **Hairy nevus.**
- **Skin cancer pictures.**
- **Cutaneous squamous cell carcinoma.**

### 📌 **Pediatric:**

- **Neuroblastoma.**
- **Pyloric stenosis.**
- **Hirschsprung's disease.**
- **Tracheoesophageal fistula.**

*Best of luck* 