



NEUROMEDICINE MINI-OSCE

Doctor 2020

Collected by:

Alaa BanyAmer

Shahed Atiyat

Bayan Shiekh Ali

Lana Khabbas

Rahaf Turab

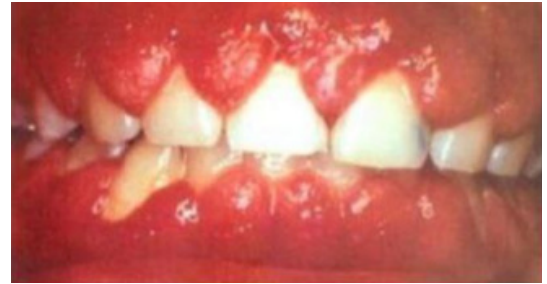Jana Zaidan

Mohammad Noor Amr

Roa'Abuarab

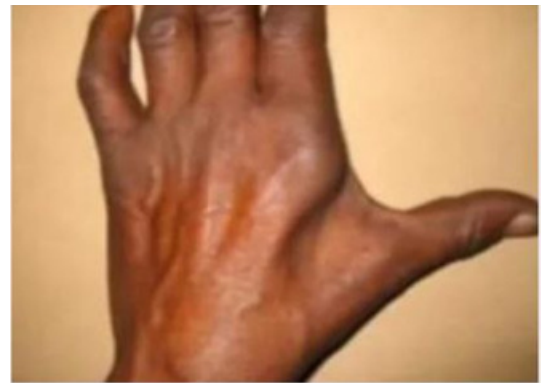Neuromedicine mini-OSCE 1st semester/ 1st month

1. Which antiseizure drug causes the side effect in the picture?



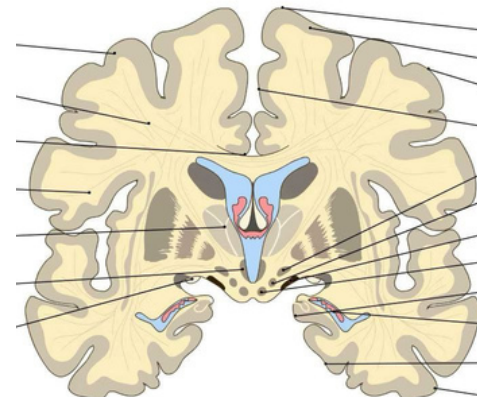
Answer: Phenytoin

2. Which nerve is affected in the following picture?



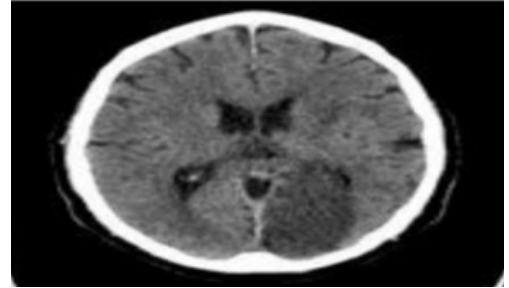
Answer: Ulnar nerve

3. The dopaminergic neurons get degenerated in parkinson's disease in which area of the brain



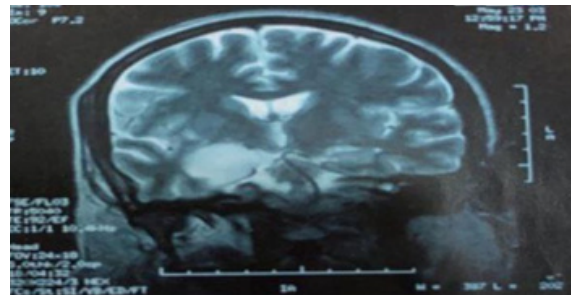
Answer: substantia nigra

4. The following CT shows left occipital lobe infarction, what visual disturbances would happen?



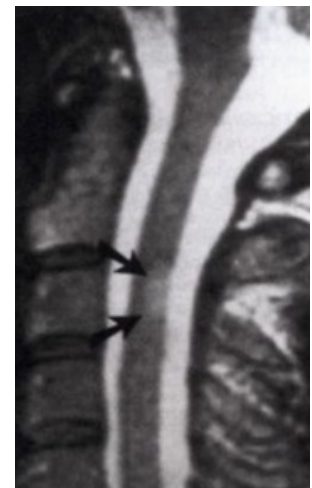
Answer: Right lateral hemianopia

5. The following brain MRI is for a 58 year old patient with headache, fever and altered level of consciousness, what is the diagnosis?



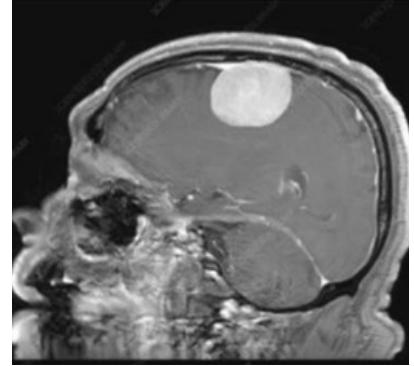
Answer: Herpes encephalitis

6. Lady had symptoms of optic neurotosis a year ago, now presents with spinal cord symptoms with the following spinal cord MRI, what is the diagnosis?



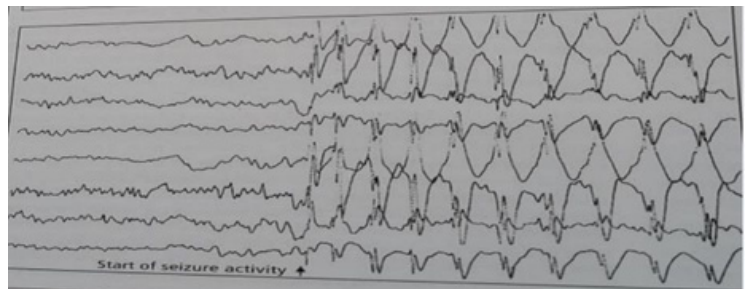
Answer: Multiple sclerosis

7. A 55 year old woman presents to the ER complaining of headache ,weakness in arms and legs and episodes of seizure, based on the following figure what is the diagnosis?



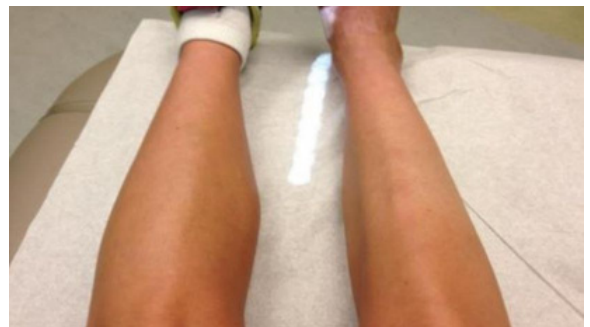Answer: Meningioma

8. Young kid with multiple attacks of " inattentiveness " with the following EEG, what is the diagnosis?



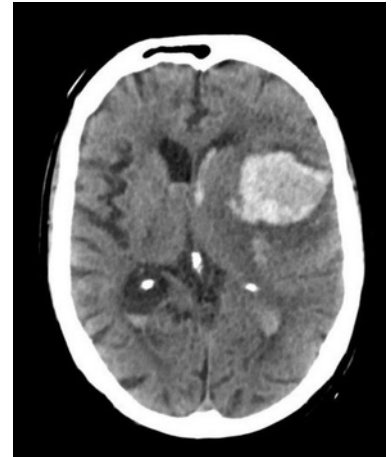
Answer: Absence seizure

9. Damage to which nerve causes the atrophy in the following picture?



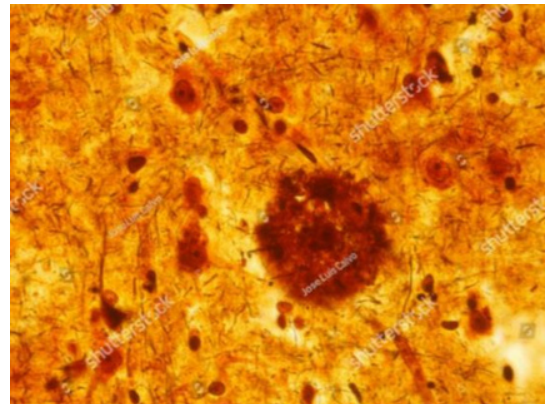
Answer: Right common peroneal

10. A 65 years old hypertensive patient came with stroke. CT scan showed this pic (close to the one in exam). What is the most probable cause?



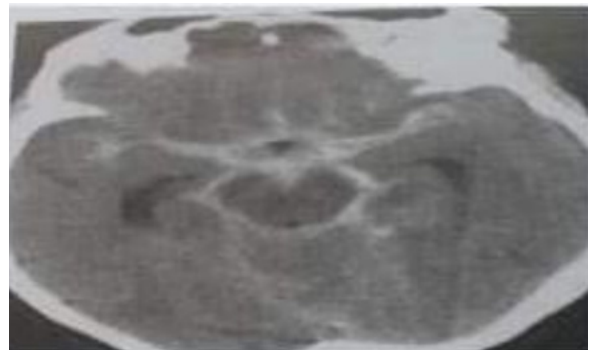
Answer: Charcot-Bouchard aneurysm

11. A patient with Alzheimer's disease with the following autopsy ,what are these plaques called?



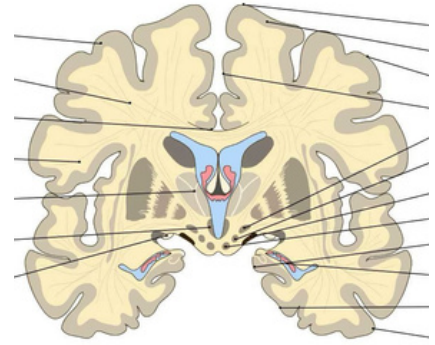
Answer: Amyloid plaque

12. A pic of subarachnoid hemorrhage ,What is the most common cause ?



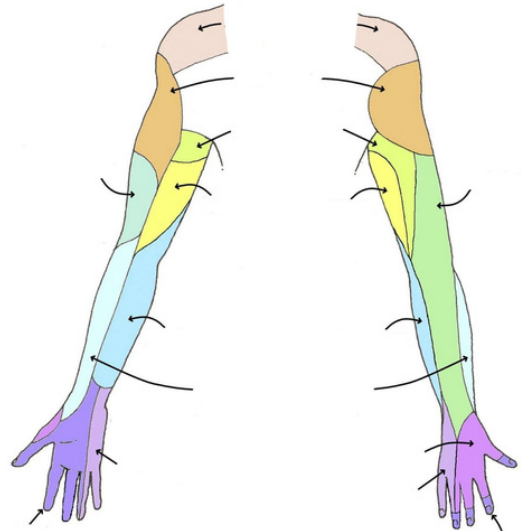
Answer: Rupture of berry aneurysm

13. Which of the following causes hemiballismus?




Answer: subthalamic nucleus

14. Which of the following muscles supplied by median nerve?



Answer: flexor carpi radialis

15. 45 year old man with headache as in the following picture ,what is the proper treatment ?



Answer: sumatriptan

OR

15. What is the proper abortive treatment for the following type of headache?



Answer: Oxygen

16. (Picture of cluster headache presentation) what is the Tx of it?

Answer: Verapamil

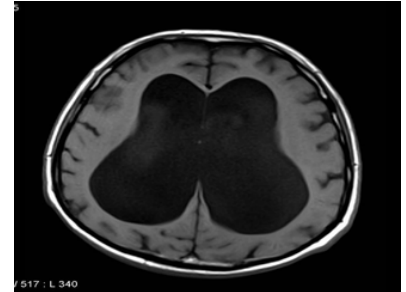
17. Root of radial nerve?

Answer: C7

Neuromedicine mini-OSCE

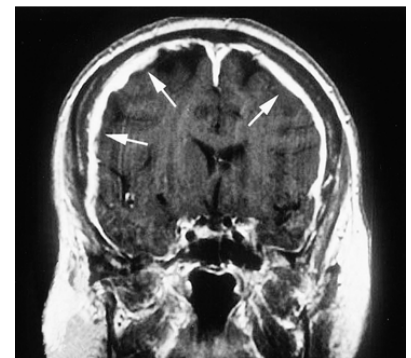
1st semester/ 2nd month

1. patient with cognitive impairment present with the following CT. What do you expect to find in him?



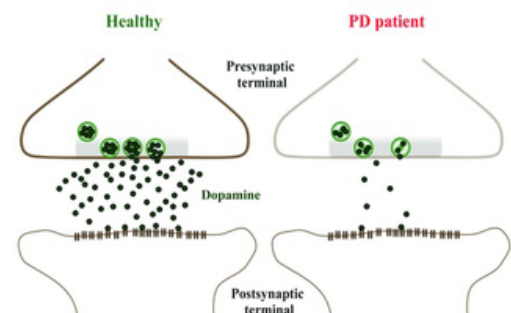
Answer: Gait and sphincter disturbance

2. Female with headache that increases upon standing up and decreases upon lying down, undergone LP sometime ago, what does she have?



Answer: Intracranial hypotension

3. What part of the basal ganglia have degenerated dopaminergic neurons in Parkinson?



Answer: Substantia nigra

4. What is the type of the drugs in the table below?

Medication

Donepezil (Aricept)

Rivastigmine (Exelon)

Answer: Anticholinesterases

5. What muscle is used in knee flexion?

Hip abduction

Hip adduction

Hip extension

Knee flexion

Knee extension

Plantar flexion

Answer: Hamstrings

6. What's the most common cause of atherosclerosis from the table?

Risk Factor

Hypertension

Cardiac disease

Atrial fibrillation

Diabetes mellitus

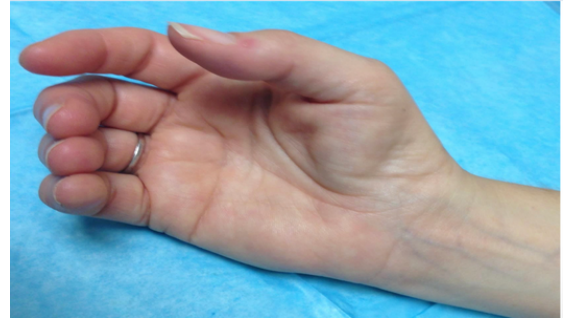
Smoking

Alcohol abuse

Hyperlipidemia

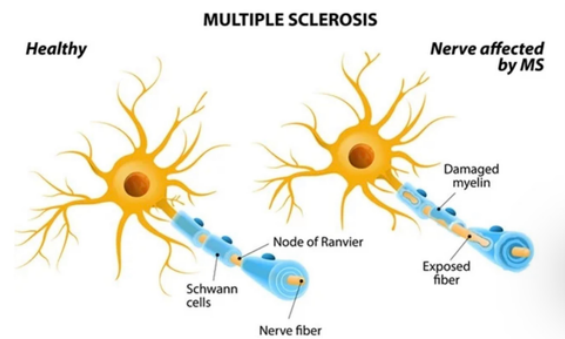
Answer: High blood pressure

7. What's the name of the muscle atrophied in this photo?



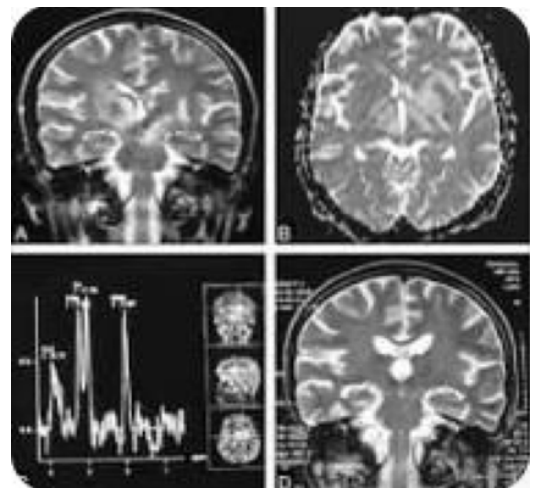
Answer: Abductor pollicis brevis

8. What cell is responsible for myelination of CNS neurons?



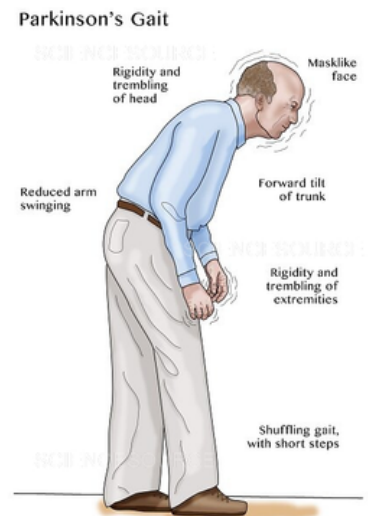Answer: OLIGODENDROCYTE

9. 40-year-old man suffered from acute loss of vision one year ago and now presents with two week history of bilateral weakness. He also had history of arthritis and oral ulcers. What is your diagnosis?



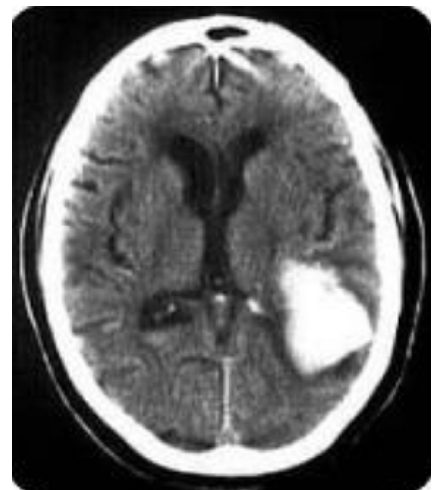
Answer: Neuro-behcet

10. What is the name of this gait?



Answer: Shuffling gait

11. 45 year old, female, perfectly healthy (no history of DM or HTN), came with headache. The following CT scan suggests ...?



Answer: Arteriovenous malformation

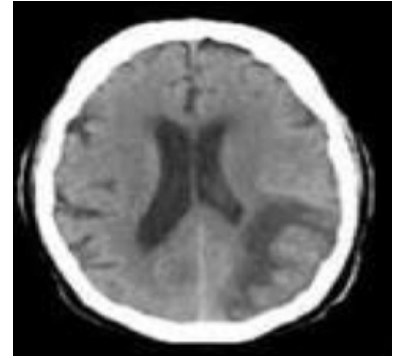
12. What type of meningitis is presented with these features?

Opening pressure	Elevated
WBC	≥ 100 cells/ μ L
Cell type	<i>Polymorphonucleocytes</i>
Glucose	Low
Protein	Elevated

Answer: Bacterial meningitis

13. Patient to the following CT, what do you expect to find in him?

- A. Left hemianopia
- B. Broca's aphasia
- C. Wernicke's aphasia
- D. Neglect of other the part of the body



Answer: C

14. What is the nerve root of brachioradialis reflex?

- A. C4
- B. C5
- C. C6
- D. C7
- E. C8

Reflex

Biceps

Brachioradialis

Triceps

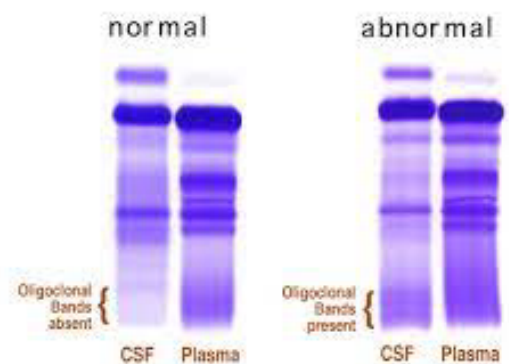
Finger flexor

Answer: C

15. Patient found to have a oligoclonal bands in CSF, what's their cause?

- A. B lymphocytes in CSF
- B. T lymphocytes in CSF
- C. Intrathecal IgG production

Oligoclonal Bands in CSF



Answer: C

16. What nerve innervates deltoid muscle for shoulder abduction?

Shoulder abduction

Elbow flexion

Elbow extension

Wrist extension

Finger flexion

Finger extension

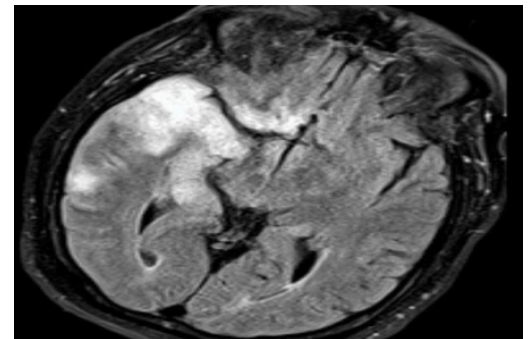
Finger abduction

Answer: Axillary nerve

17. Patient with headache, fever, known to have viral encephalitis. what's the most common cause?

A. Herpes simplex virus 1

B. Herpes simplex virus 2



Answer: A

18. Which drug is contraindicated to be given with this type of seizure?

Childhood and adolescence	Absence; sometimes, generalized tonic-clonic seizures	Hyperventilation as trigger	3-per-second generalized spike-and-wave
---------------------------	---	-----------------------------	---

Answer: Carbamazepine

19. One of the following antiepileptic drugs causes tremor as side-effect?

Carbamazepine
(Tegretol)

Valproic acid (Depakote)

Phenobarbital

Ethosuximide (Zarontin)

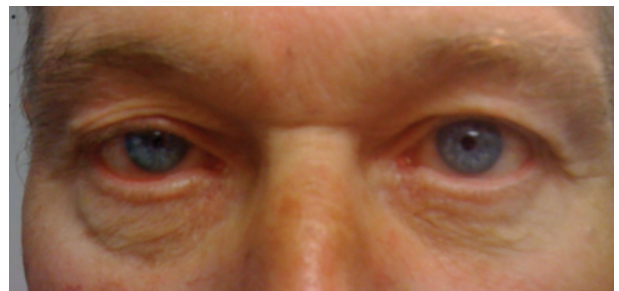Gabapentin (Neurontin)

Lamotrigine (Lamictal)

Topiramate (Topamax)

Answer: Valproic acid

20. Male patient with recurrent headache attacks that last for 3 hours and wakes him up from sleep. presented with a symptom seen in the photo. What is the cause?



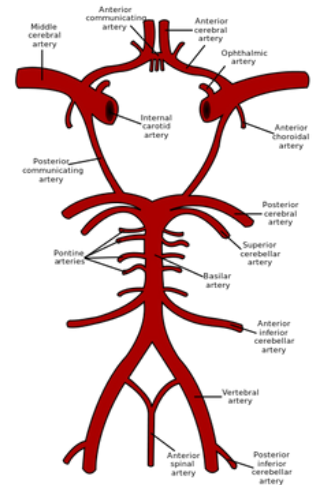
Answer: Cluster headache

Neuromedicine mini-OSCE

1st semester/ 3rd month

1. Which of the following arteries is involved in wallenberg syndrome?

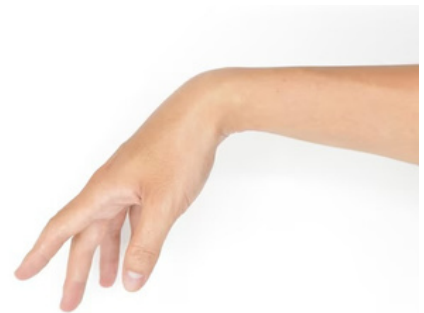- A. Anterior cerebral artery
- B. Posterior inferior cerebellar artery
- C. Basilar artery



Answer: B

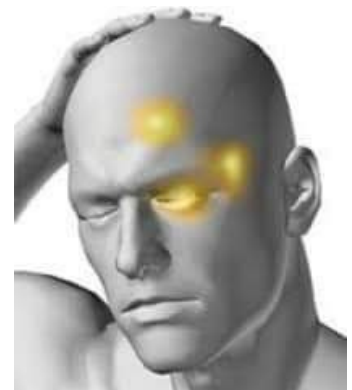2. Upon examination, a patient was found to have this abnormality in her upper limb. Which nerve is affected ?

- A. Radial nerve
- B. Median nerve
- C. Ulnar nerve



Answer: A

3. Which of the following is the best preventative treatment in this type of headache?



Answer: Verapamil

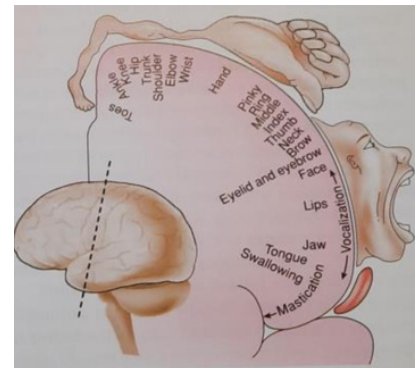
4. What is the best treatment for this type of headache?

Sex	Female > male
Location	Unilateral > bilateral
Quality	Throbbing, pulsatile
Severity	Moderate to severe
Attack duration	4–72 h
Attack frequency	Variable
Autonomic features	No

Answer: Sumatriptan

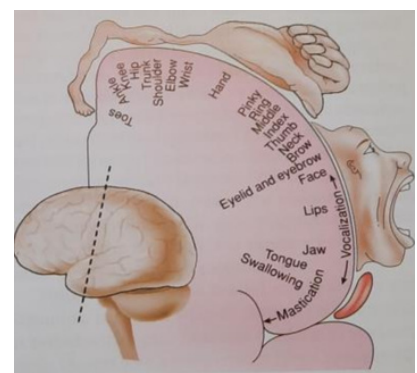
5. Which artery supplies the leg region in the motor homunculus?

- A. Anterior communicating artery
- B. Posterior cerebral artery
- C. Middle cerebral artery
- D. Anterior cerebral artery



Answer: D

6. Which type of seizures spread with the motor strip of the homunculus?

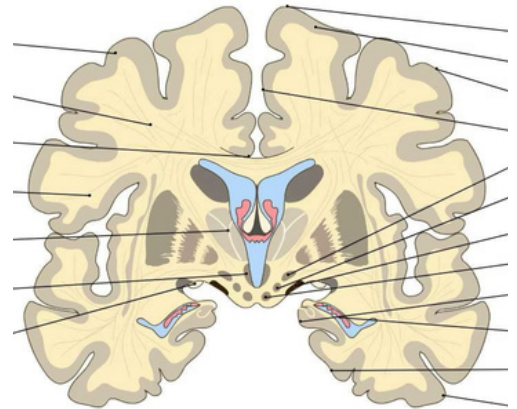


Answer: Jacksonian march

7. Which part of brain is affected in Huntington's disease chorea?

- A. Subthalamic nucleus
- B. Caudate nucleus
- C. Globus pallidus
- D. Putamen

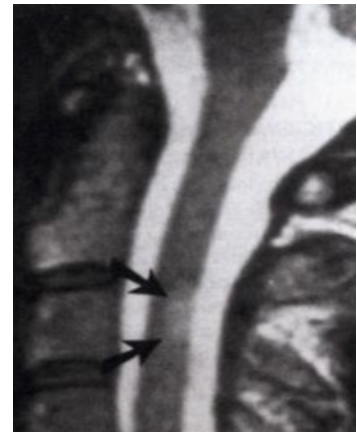
Answer: B



8. Which of the following symptoms isn't caused by the following lesion?

- A. Cape like loss of sensation
- B. Bilateral Babinski sign
- C. Sphincter dysfunction

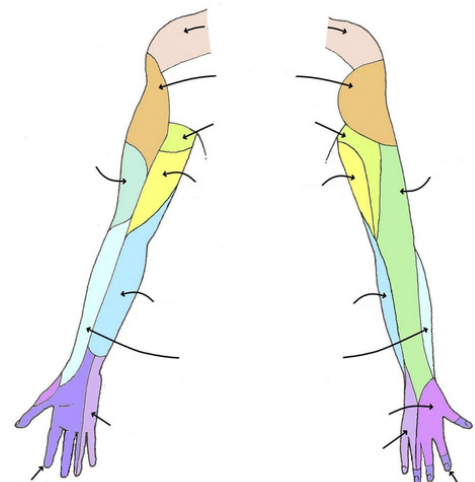
Answer: A



9. What is the nerve supply of brachioradialis muscle?

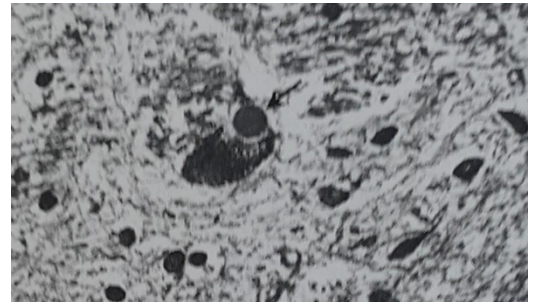
- A. Musculocutaneous nerve
- B. Radial nerve
- C. Axillary nerve
- D. Median nerve

Answer: B



10. All of these signs will be seen in this case except?

- A. Cerebellar signs
- B. Visual hallucination
- C. Extrapyrarnidal symptoms
- D. Fluctuation of alertness



Answer: A

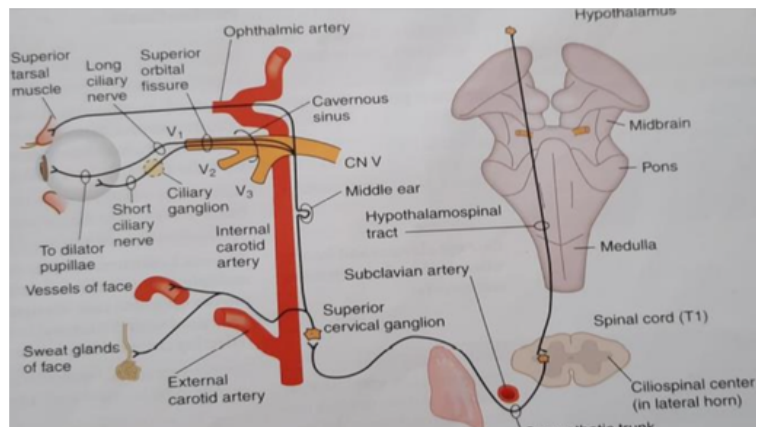
11. According to these CSF findings which of the following is the most suspected disease?

- A. Viral meningitis/ encephalitis
- B. Bacterial meningitis
- C. Guillain-Barré syndrome
- D. Tuberculosis meningitis

Cells (pleocytosis)	Protein	Glucose	Other
Polymorphs	High	Low	Culture and Gram stain may be positive

Answer: B

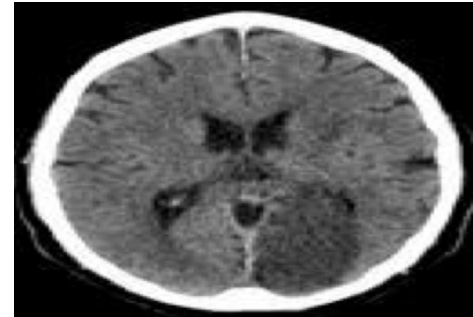12. Which of these lesions doesn't lead to Horner syndrome?



Answer: Pontine infarction

13. What visual disturbance would happen if a stroke happened in the occipital lobe as in the following figure ?

- A. Left inferior quadrantanopia
- B. Right lateral hemianopia
- C. Left lateral hemianopia
- D. Right inferior quadrantanopia



Answer: B

14. What is the type of this aphasia?

- A. Broca
- B. Wernicke
- C. Conduction
- D. Transcortical motor

Fluency	Repetition	Comprehension	Associated Signs	Location
Impaired	Impaired	Relatively preserved	Right hemiparesis (especially face)	Broca's area

Answer: A

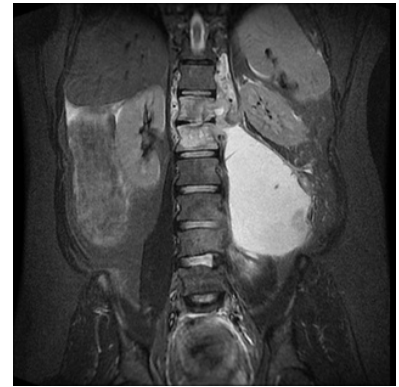15. Which disease cause increased albumin and low cells in CSF (albuminocytological dissociation) ?

Disease
Bacterial meningitis
Viral meningitis/encephalitis
Tuberculous meningitis
Guillain-Barré syndrome
MS
ADEM

Answer: Guillain-Barré syndrome

16. Patient presented with 3 week history of night sweats, weight loss, fever and cough. 2 days later, he had lower limb weakness . Spine MRI was done, what's the disease?

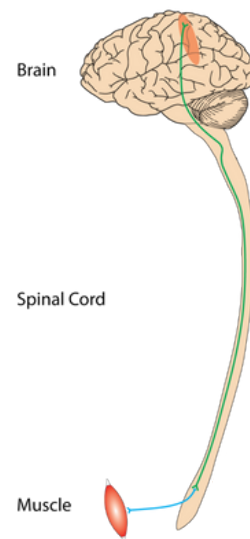
- A. Bone metastasis
- B. Bone fracture
- C. Pott's disease
- D. Osteomyelitis
- E. Osteomalacia



Answer: C

17. All of the following are features of LMN except?

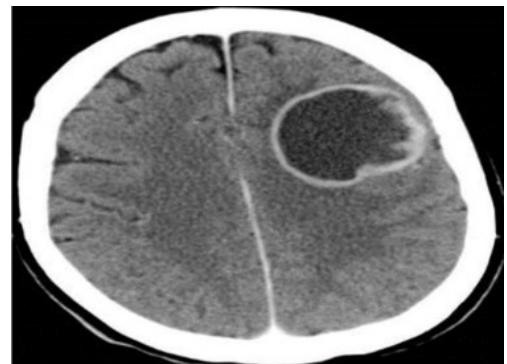- A. Fasciculation
- B. Hypotonia
- C. Areflexia
- D. Planter extension reflex
- E. Muscle atrophy



Answer: D

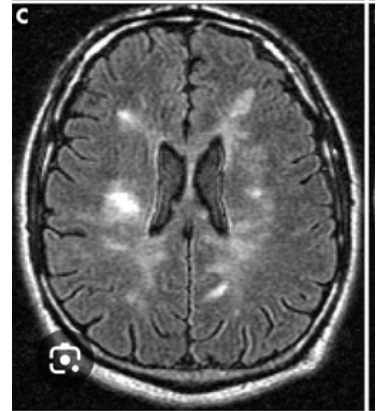
18. 65 years old male patient with fever, headache m, blurred vision and decrease in concentration, Which of the following doesn't cause the disease shown in the following CT?

- A. Dental infection
- B. Otitis
- C. Sinusitis
- D. Bronchiectasis
- E. Cyanotic congenital heart diseases



Answer: E


19. Patient with blurred vision, he has a history of muscle weakness one year ago that resolved spontaneously 3 weeks later, what is the diagnosis?



Answer: MS

20. What is the type of headache shown in the following figure?

- A. Migraine
- B. Tension headache
- C. Cluster headache
- D. Sinus headache



Answer: C

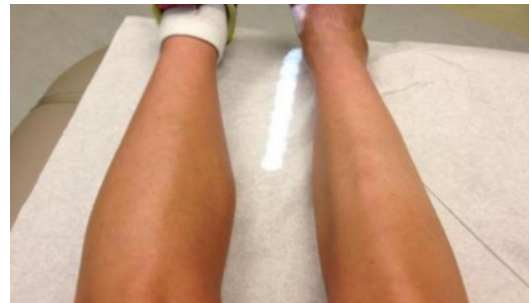Neuromedicine mini-OSCE

1st semester/ 4th month

1. Which of the following nerve root values is responsible for the triceps reflex?

Answer: C7

2. Which of the following nerves innervates the tibialis anterior muscle?



Answer: Deep peroneal nerve

3. Which of the following nerves innervates the extensor carpi ulnaris muscle?

Answer: Radial nerve

4. These CSF findings are for a patient with:

Color clear PMN cells

Nil Mononuclear cells < 5 (mm³ idk)

Glucose 2/3 > 1/2 blood glucose (40-80 gm/ dL)

Protein 50 mg (2-4 g)

- A. Normal CSF
- B. Viral meningitis
- C. Bacterial meningitis
- D. TB meningitis
- E. Fungal meningitis

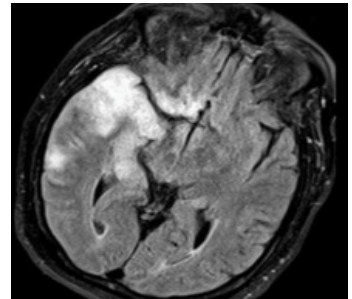
Answer: A

5. Which of the following is the environmental factor most associated with MS ?

- 1. Vitamin D deficiency
- 2. Low exposure to sunlight
- 3. EBV
- 4. Smoking
- 5. Idk

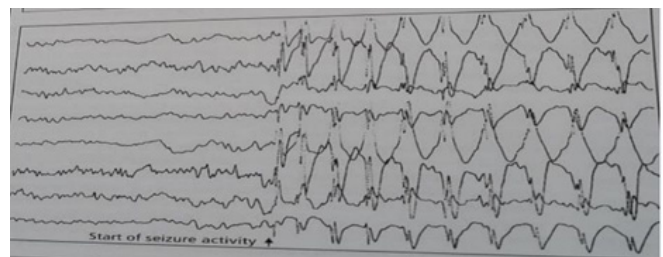
Answer: EBV

6. History of fever + altered mental state + without meningeal irritation signs



Answer: Herpes encephalitis

7. A 7 years old patient with atonic seizure name its type:



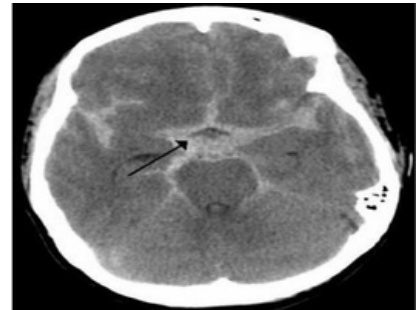
Answer: Petit mal absence seizure

8. Sumatriptan is a :

- A. 5HT_{1D} antagonist
- B. 5HT_{1B/D} agonist
- C. 5HT_{2B} agonist

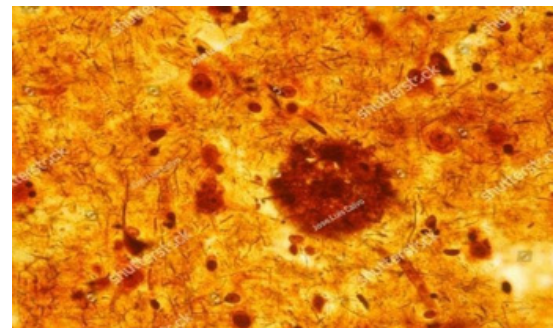
Answer: A

9. What is the most common cause ?



Answer: Rupture of berry aneurysm

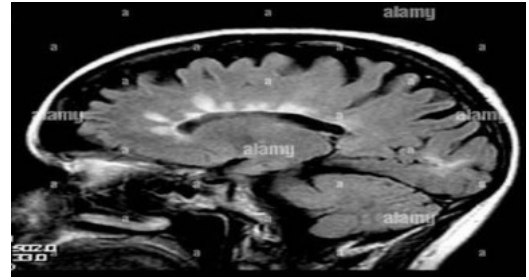
10. A patient with Alzheimers disease with the following autopsy, what are these plaques called



Answer: Amyloid plaque

11. A 45 year old patient presented with decrease in visual activity that lasted for two weeks then faded away, and after a couple of months, he complained of lower limb weakness or so that lasted for 3 months, What is the diagnosis ?

Answer: MS



12. Right-handed patient presented with a right hemisphere anterior ischemic Lesion, all of the following can be a result of this ischemic injury except ?

- A. Sensory loss**
- B. Hemiplegia**
- C. Upper motor neurons pattern of facial weakness**
- D. Broca aphasia**

Answer: Broca aphasia

13. What is the role of carbidopa in the levodopa - carbidopa regimen?

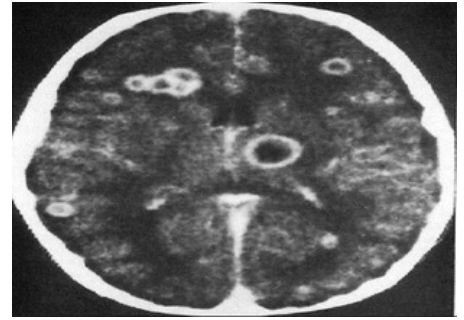
Answer: Inhibits the peripheral dopa decarboxylase

14. Which of the following isn't a characteristic of Parkinson's?



Answer: Action tremor

15. Patient presented with high fever and this MRI, What is the cause?

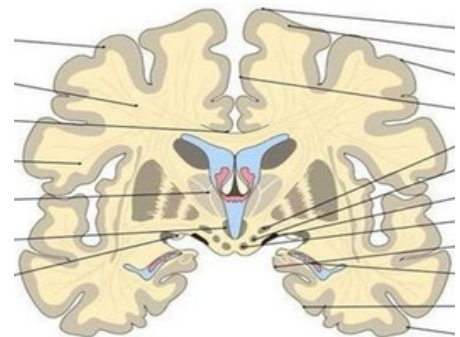


Answer: Bacterial infective endocarditis

16. Drug of choice to treat absence seizure

Answer: Ethoximide

17. The dopaminergic neurons get degenerated in Parkinson's disease in which area of the brain ?



Answer: Substantia nigra

18. A 34 man with unilateral headache eyelid edema lacrimation and runny nose, what is the first line treatment?

(the picture was include these symptoms)

Answer: oxygen inhalation

19. The most common cause of cardioembolic stroke ?

Answer: A fib

20. A dementia diagnosis can be established with mini-mental examination score of less than ?

A. 27

B. 23

C. 20

D. 28

E. 25

Answer: E

Neuromedicine mini-OSCE 2nd semester/ 5th month

1. An ECG showing atrial fibrillation with a brain CT showing huge right hemisphere stroke with midline shift, next step?

- a. Consult neurosurgery
- b. Full dose anticoagulation
- c. Antibiotics

Answer: b

2. Type of Gait?

- a. Waddling
- b. Paraplegic
- c. Parkinson
- d. Hemiplegic



Answer: a

3. Patient with left hemianopia, which structure was damaged?

- a. Right optic nerve
- b. Optic chiasm
- c. Right optic tract



Answer: c

4. Which of the following is not a feature of Parkinson disease?

- a. Postural tremor
- b. Head tremor

- d. Hypomimia
- b. Sleep disturbance

Answer: b

5. Patient came with severeright retroorbital headache, most probable cause?

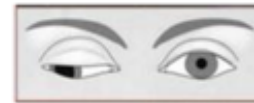- a. Cluster headache
- b. Migraine
- c. Right posterior communicating artery aneurysm rupture



Answer: c

Posterior Communicating Artery Aneurysm

- Unilateral headache, eye pain
- CN III palsy
 - Eye: "down and out"
 - Ptosis
 - Pupil dilation - nonreactive to light



BoardsBeyond

6. Myasthenia Gravis patient on corticosteroids developed fever, ataxia, headache (other symptoms) from 3days ,which empirical drug is your choice

- a. Ceftriaxone with Vancomycin
- b. Ampicillin with Gentamicin
- c. Acyclovir with Ceftriaxone

Answer:

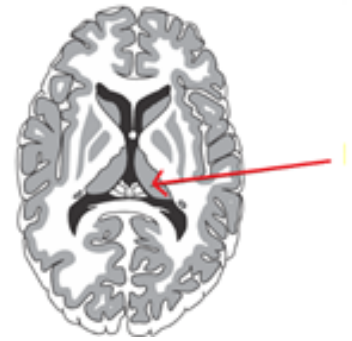
7. Patient with broca's aphasia, what you don't expect to find in him

- a. Right hemiplegia
- b. Non fluent aphasia
- c. Rt upper Quadrantopia

Answer: c

8. The function of the pointed structure :

- a. Motor coordination
- b. Sensory processing
- c. Pyramidal function
- d. Extra-pyramidal function
- e. Temperature



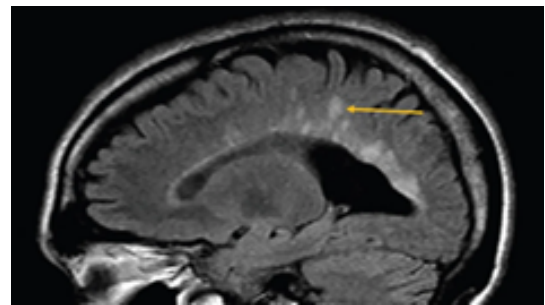
Answer: b

9. Defect in which muscle causes foot drop?

Answer: Tibialis anterior

10. Patient MRI is as following, what do you expect to find in his CSF analysis?

- a. Matched serum-CFF oligoclonal bands
- b. Elevated neutrophils
- c. Normal protein



Answer: a

11. A woman was diagnosed with essential tremor bilaterally. Her brother has a history of asthma, what's the best treatment?(There was a picture of drugs list)

Answer: mostly it's Primidone (the options for essential tremor are Propranolol and Primidone, but since there is a history of asthma, we can't give beta blocker to her)

12. 18 years old patient came with sudden jerking involuntary movements bilaterally in the morning without loss of consciousness. Which drug is contraindicated? (with a picture showing a list of antiseizure drugs)

Answer: carbamezipine

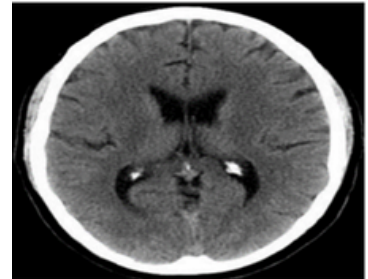
13. Patient was diagnosed with cluster headache. What's the 1st line drug in prevention therapy?

Answer: verapamil

14. A patient came with signs and symptoms of encephalitis and he's suspected to have viral encephalitis with CT/MRI picture. Which virus is the most common cause?

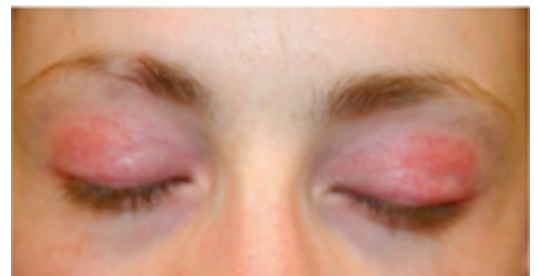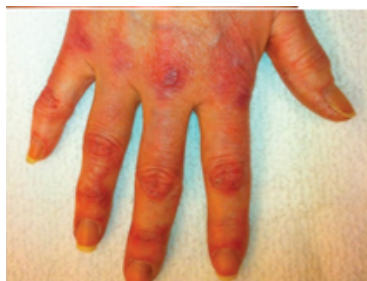Answer: Herpes simplex virus

15. Elderly patient came with right side hemiparesis and some other symptoms and signs of stroke. This CT was shown. What does it describe?



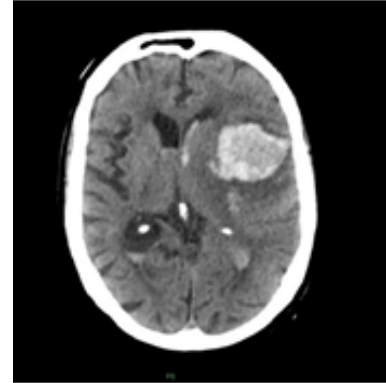
Answer: possibly normal CT scan (there's calcified choroid plexus)

16. Female patient came with these 2 findings in the pictures and other neurologic abnormalities. What can you also find in this patient?



Answer: proximal muscle weakness (mostly the patient is a case of dermatomyositis)

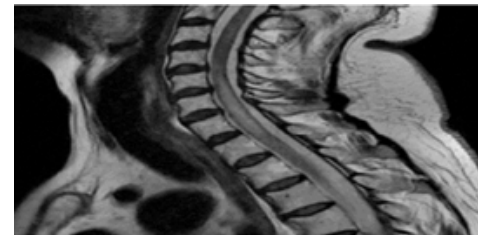
17. A 65 years old hypertensive patient came with stroke CT scan showed this pic (close to the one in exam). What is the most probable cause?



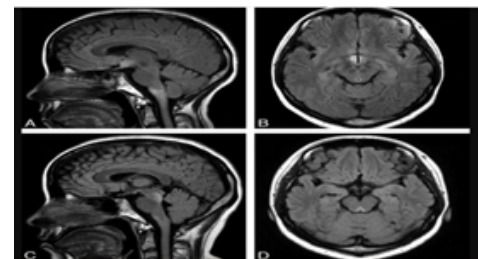
Answer: Charcot- Bouchard aneurysm

18. A 30 years old female pt presented with upper and lower limb weakness, 1 year ago she had an attack of impaired vision, what is your diagnosis ?

- a. Multiple sclerosis
- b. Neuromyelitis optica



Answer: b



19. A picture showing this MRI scan and asking what type of dementia is seen here?

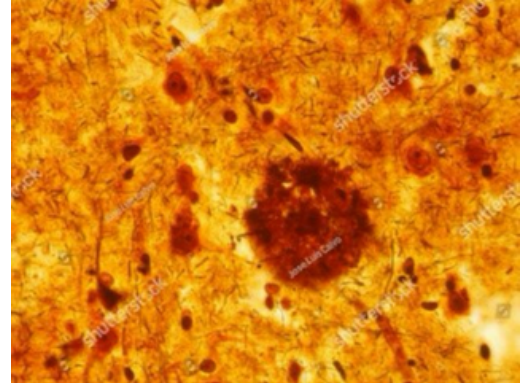
Answer: vascular dementia

20. A picture showing a list of stroke risk factors, asking which is the most important modifiable risk factor for stroke?

Answer: hypertention

Neuromedicine mini-OSCE 2nd semester/ 6th month

1. A patient with Alzheimer's disease with the following autopsy, what are these plaques called?




Answer: Amyloid plaque

2. which of the following drugs the most common cause steven Johnsen syndrome (lamotrigine, Tiagabine, Levetiracetam and Brivaracetam)

Answer: lamotrigine

3. What is the nerve root for the movement



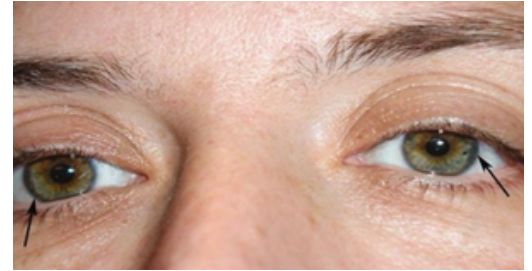Answer: L5, S1

4. What is the nerve root for triceps reflex?

Answer: C7

5. Patient presented with hereditary disorder of dystonia and tremor , which of the following is false:

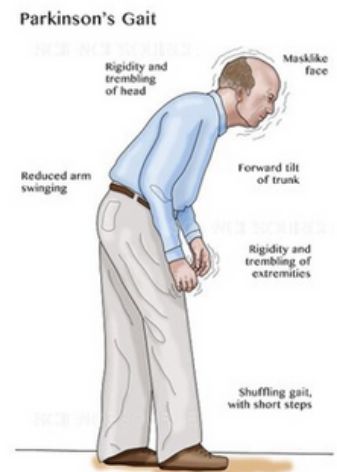- A. Low ceruloplasmin in the serum
- B. Serum copper is not useful in the diagnosis
- C. Urinary copper will be elevated
- D. The disease is autosomal recessive condition.
- E. Tics are a common feature.



Answer: E

6. Which of the following is not a feature of parkinson:

- A. Postural tremor
- B. Head temor
- C. Decreased arm swinging on walking
- D. Festinant gait
- E. hypomimia



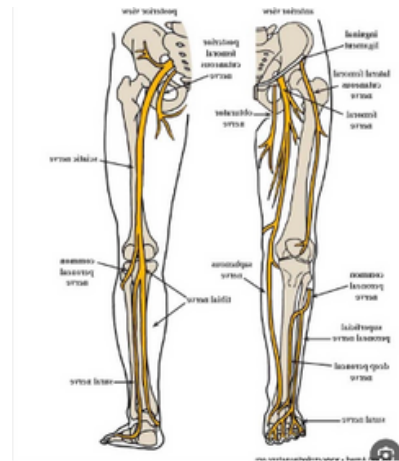
Answer: B

7. Which of these is the most common vascular risk factor of ischemic stroke?

- A. Hypertension.
- B. Diabetes.
- C. Age
- D. Smoking
- E. Hyperlipidemia

Answer: A

8. Tibialis posterior nerve supply:



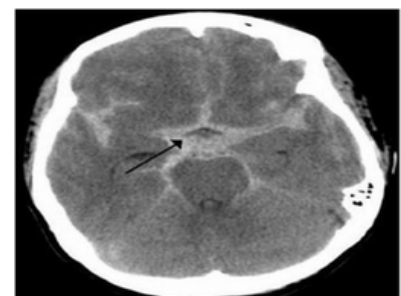Answer: tibial nerve

9. Unresponsive patient with cognitive impairment, slight response to tactile stimulation but responsive to continuous noxious stimulation

Answer: stupor

10. A woman had severe headache with nausea and vomiting following an emotional stress, brain MRI was done, Most common cause:

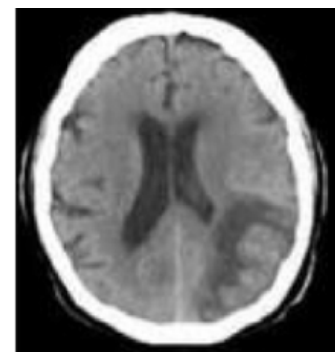
- A. Rupture of charcot bouchard aneurysm
- B. Rupture of berry aneurysm
- C. Telangiectasias



Answer: B

11. Patient to the following CT, what do you expect to find in him?

- A. Left hemianopia
- B. Broca's aphasia
- C. Wernicke's aphasia
- D. Neglect of other the part of the body

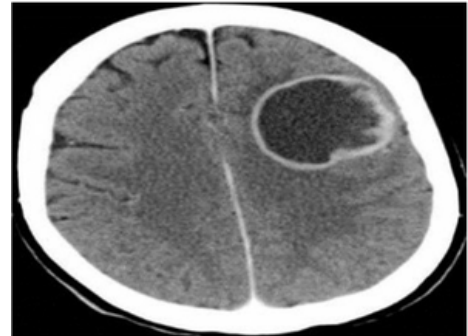

Answer: C

12. 45 year old man presented to the ER with headache and seizures, fever and confusion, he has a history of frontal sinusitis, brain MRI was done. Which of the following is the most important initial step in management:

- A. surgery
- B. Steroids
- C. Intravenous antibiotics
- D. Intravenous acyclovir

Answer: C



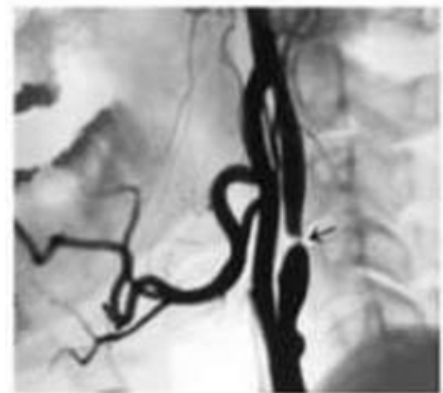13. Severe headache not responsive to simple analgesics, diagnosis:

Answer: giant cell arteritis.

14. Patient presented with an episode of right sided weakness and language disturbance, which artery is the most likely to be stenosed:

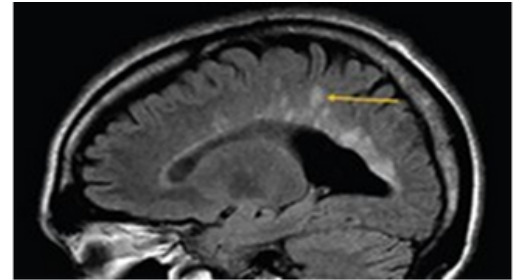
- A. Left ICA
- B. Left MCA
- C. Left ACA
- D. basilar artery
- E. Vertebral artery

Answer: A



15. A 23-year-old woman presented with 2 or 3 weeks of pain in her eye and decreased visual acuity, brain MRI was done, the diagnosis is MS. Which of the following is likely to be seen in multiple sclerosis:

- A. Normal protein level
- B. Matched CSF and serum Immunoglobulin IgG
- C. Low glucose level
- D. High lactate level



Answer: B

16. What structure is affected:

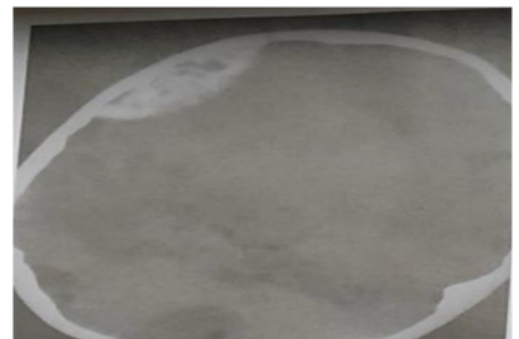
- A. Optic chiasm
- B. Both optic nerves
- C. Right optic nerve
- D. Right optic tract
- E. Right optic radiation of the parietal lobe



Answer: D

17. Dignosis?

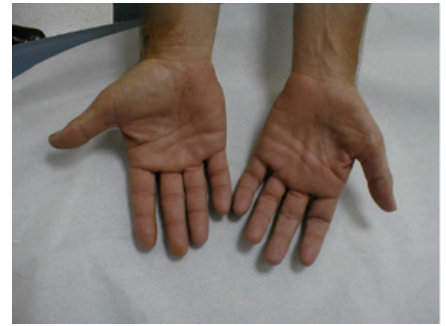- A. Meningioma
- B. Brain metastases
- C. Right intracerebral hemorrhage
- D. Right subdural hemorrhage
- E. Right epidural hemorrhage



Answer: E

18. What is the nerve injury that leads to this disorder?

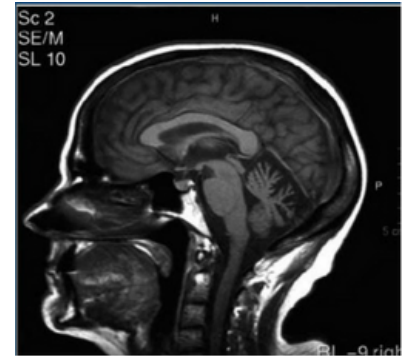
- A. Anterior interosseous nerve
- B. Posterior interosseous nerve
- C. Median nerve
- D. Radial nerve
- E. Ulnar nerve



Answer: C

19. Which of the following is not a feature of this presentation?

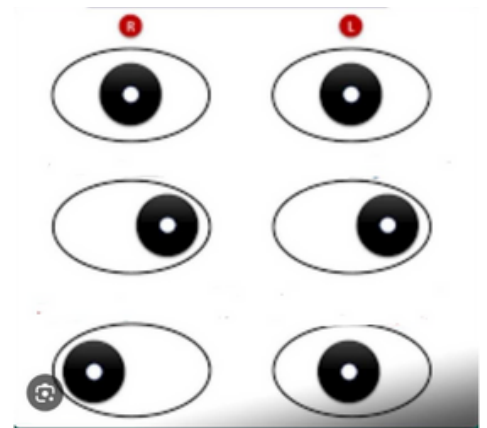
- A. Wide based gait
- B. Pendular knee reflexes
- C. Decreased rapid alternating hand movement
- D. Positive romberg test
- E. Dysarthria



Answer: D

20. Dignosis?

- A. Right internuclear ophthalmoplegia
- B. Left internuclear ophthalmoplegia
- C. Left oculomotor nerve injury
- D. Left trochlear nerve injury



Answer: B