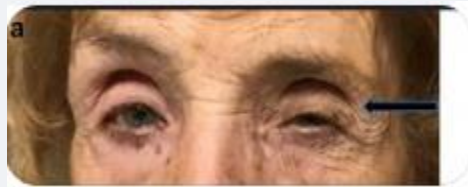

## 1<sup>st</sup> month

**1-Nerve responsible for shoulder abduction?**

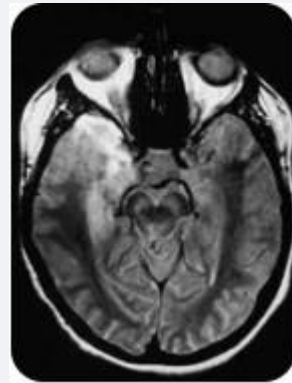
ANS: Axillary

**2-Patient with headache that wakes him up from sleep (stays for 3 hours) and presents like the following picture?**



ANS: Cluster headache

**3-Patient with headache ,fever known to have 'viral encephalitis' what's the most common cause?**



ANS: HSV-1

**4-Description of juvenile myoclonic epilepsy , what drug is contraindicated?**

ANS: Carbamazepine

**5-What anti epileptic drug causes tremor?**

ANS: Valproic acid

**6-What are the cells responsible for myelinating CNS neurons?**

ANS: Oligodendrocytes

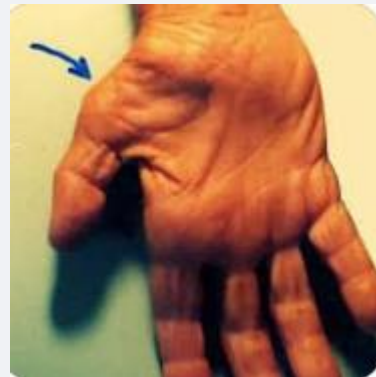**7-What's the most common cause of atherosclerosis?**

ANS: Hypertension

**8-What's the Muscle that flexes the knee?**

ANS: Hamstrings

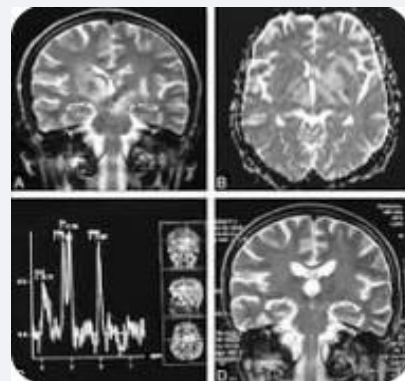
**9-What's the name of the muscle atrophied in this photo?**



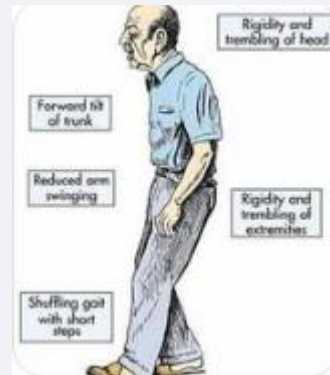ANS: Abductor policis brevis

**10-40 year old man suffered acute loss of vision 1 year ago and now presents with 2 week history of bilateral weakness , also history of arthritis and oral ulcers ,diagnosis?**

ANS :Neuro-behcet

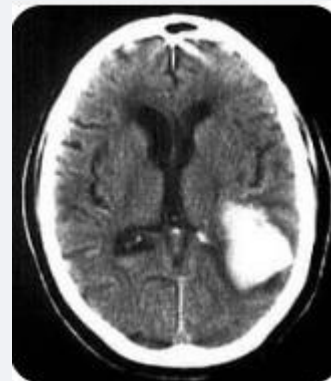

**11-Patient with Parkinson , what is the name of his gait?**



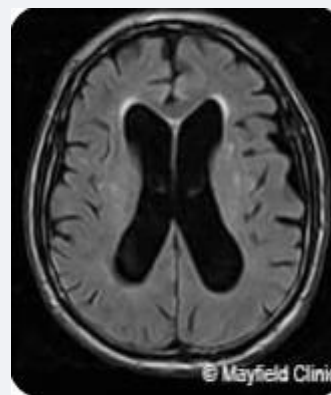
ANS: Shuffling gait

**12-45 year old female perfectly healthy (no DM no hypertension) came with headache with the following CT scan what is the cause ?**



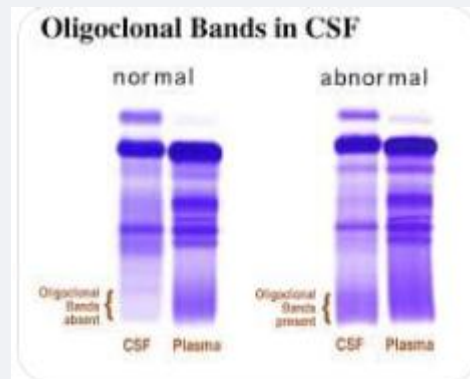
ANS :AVM(arteriovenous malformation)

**13-Patient with cognitive impairment presents with the following CT , what do you expect to find in him?**



AMS: Gait and sphincter disturbance

**14-Patient found to have oligoclonal bands in CSF , what's their cause?**



ANS: Intrathecal IgG production

**15-Polymorphonucleocytes in CSF + <100 WBCs + low glucose + high protein (meningitis) ?**

ANS: Bacterial meningitis

**16-Brachioradialis root?**

ANS: C6

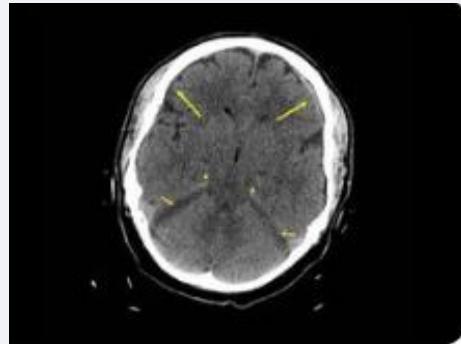
**17-Rivastigmine and donepezil are used in Alzheimer , what drug group are they ?**

ANS: Anticholinesterases

**18-What's the part of the basal ganglia that's defective in Parkinson?**

ANS: Substantia nigra

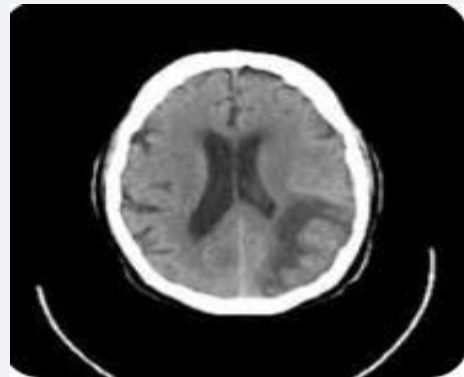
**19-Female with headache that increases upon standing up and decreases upon lying down , undergone LP some time ago , what does she have?**



ANS: Intracranial hypotension

**20-Patient with the following CT, what do you expect to find in him?**

ANS: Wernicke's aphasia

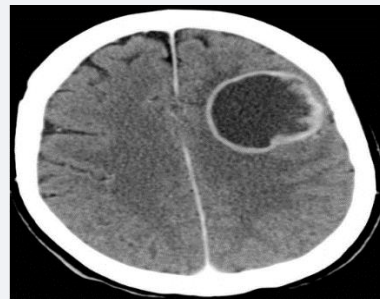

## 2<sup>nd</sup> month

1-Damage to which structure causes hemiballismus ?

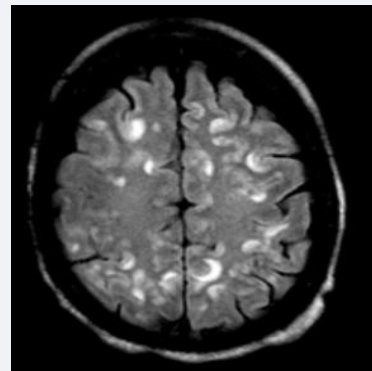
ANS: Subthalamic nucleus

2-Patient with previous sinusitis presents to the ER with headache and bilateral papilledema, what is the diagnosis?



Answer: Brain abscess

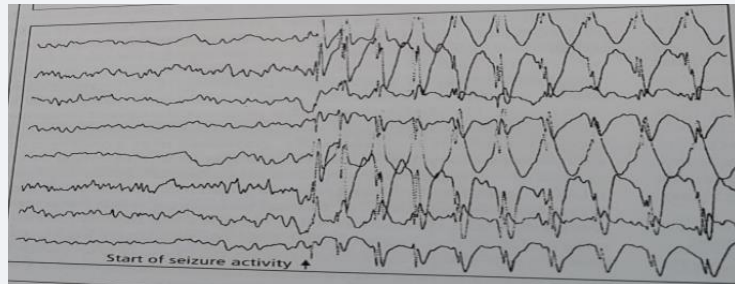
3-Young lady presents with photosensitivity ,rash on face with the following brain MRI, what is the diagnosis?



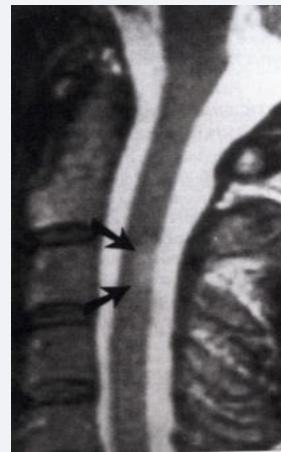
ANS: CNS lupus

4-Young kid with multiple attacks of " inattentiveness " with the following EEG, what is the diagnosis?

ANS: Absence seizure

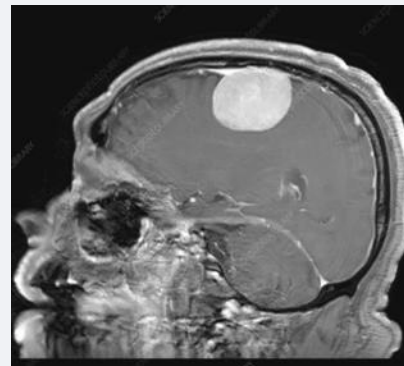


5-Lady had symptoms of optic neuritis a year ago, now presents with spinal cord symptoms with the following spinal cord MRI ,what is the diagnosis?



ANS: Multiple sclerosis

6-A 55 year old woman presents to the ER complaining of headache ,weakness in arms and legs and episodes of seizure, based on the following figure what is the diagnosis?

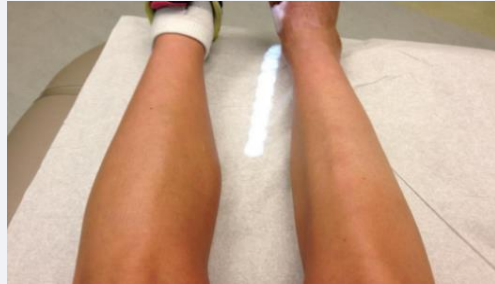

ANS: Meningioma

**7-Which of the following muscles is supplied by the radial nerve?**

ANS: Extensor carpi radialis

**8-Damage to which nerve causes the atrophy in the following picture?**

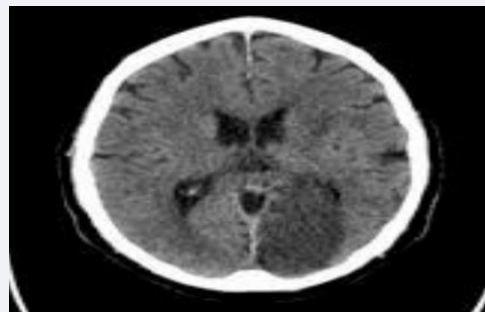


ANS: Right common peroneal

**9-Which nerve root is the main root of the radial nerve ?**

ANS :C7

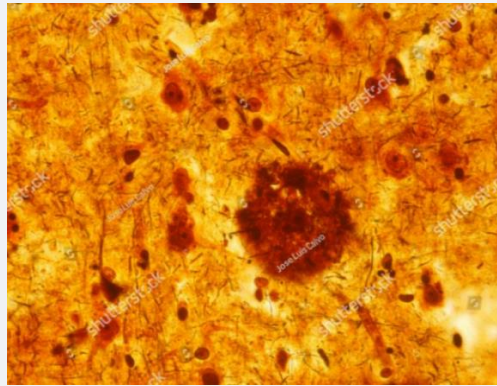
**10-What visual disturbance would happen if a stroke happened in the occipital lobe as in the following figure ?**



ANS: Right lateral hemianopia



**11-A patient with Alzheimer's disease with the following autopsy ,what are these plaques called?**

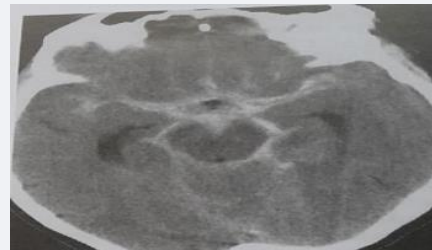


ANS: Amyloid plaques

**12-At which level does the lateral corticospinal tract cross over?**

ANS: Medulla oblongata

**13-Woman presents to ER with severe sudden headache nausea and vomiting with the following CT ,what is the diagnosis?**

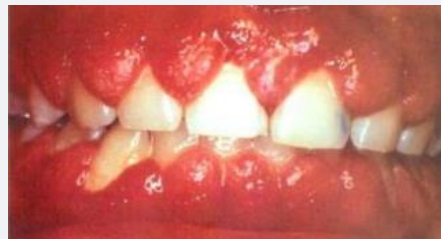

ANS: Subarachnoid hemorrhage

**14-Where are the dopaminergic neurons located?**

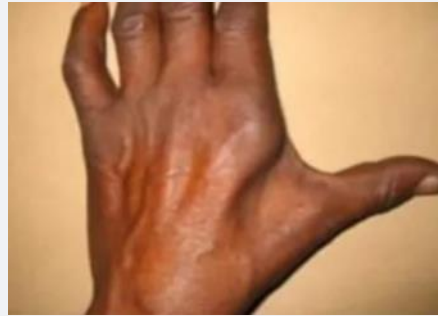ANS: Substantia nigra

**15-Which antiseizure drug causes the side effect in the picture ?**



ANS: Phenytoin

**16-which nerve is affected in the following picture ?**



ANS: Ulnar nerve

**17-45 year old man with headache as in the following picture ,what is the proper treatment ?**



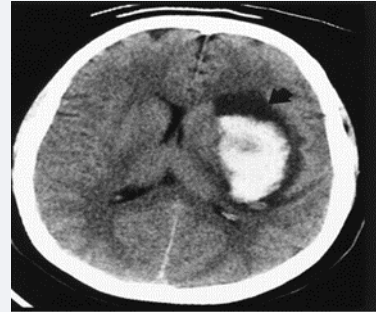ANS: Sumatriptan

**18-what is the proper abortive treatment for the following type of headache ?**



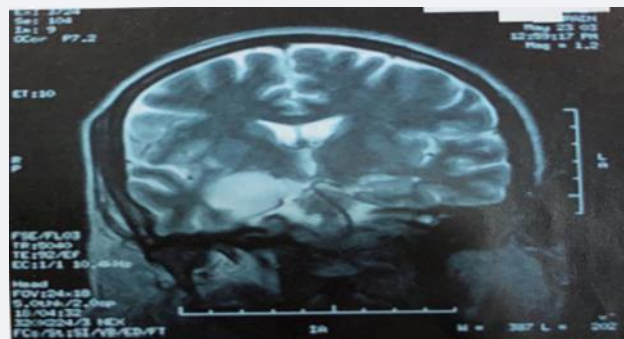
ANS: Oxygen

19- 65 year-old patient came to ER with headache and other neurologic signs .The following figure represents his brain CT , what is the most common cause of his disease ?



ANS :Uncontrolled hypertension

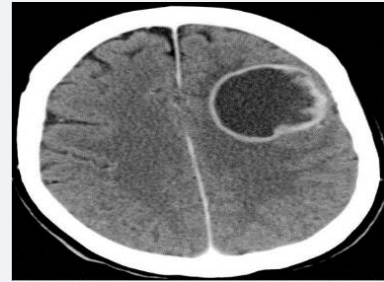20-The following Brain MRI is for a 58 year-old patient with headache, fever and altered level of consciousness ,what is the diagnosis?



ANS : Herpes encephalitis

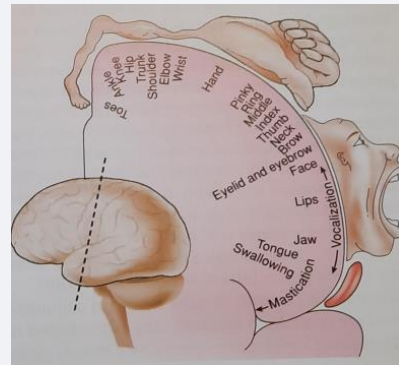
## 3<sup>rd</sup> month

1- Which of the following doesn't cause the disease shown in the following CT?



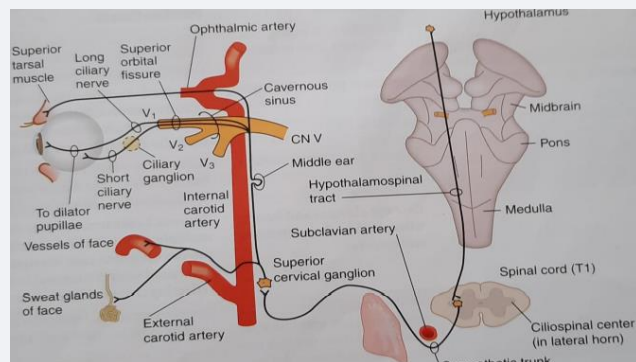
AMS: Cyanotic congenital heart diseases

2- Which type of seizures spread with the motor strip of the homunculus?



ANS: Jacksonian march

3- Which of these lesions don't lead to Horner syndrome?



ANS: Pontine infarction

4- Patient with blurred vision, he has a history of muscle weakness one year ago that resolved spontaneously 3 weeks later, what is the diagnosis?

ANS: MS

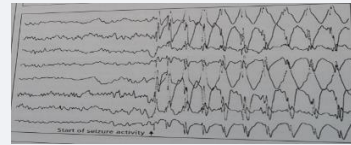
**5-Which part of the basal ganglia is degenerated in Huntington's disease?**

ANS: Caudate

**6-Which type of aphasia is associated with impaired fluency and repetition but preserved comprehension?**

ANS: Broca's aphasia

**7-What is the appropriate drug for the seizure represented by the following EEG?**



ANS: Valproic acid (ethosuximide is not in the choices)

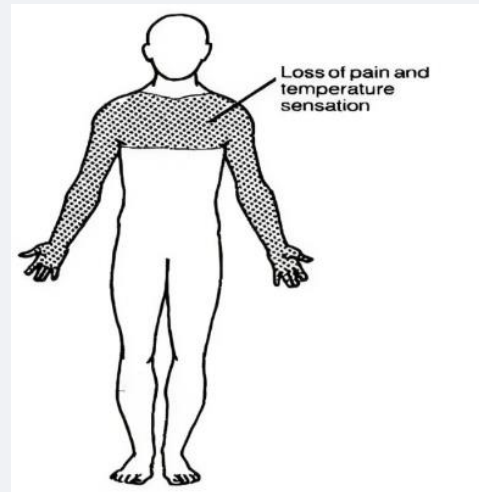
**8-Which disease cause increased albumin and low cells in CSF (albuminocytological dissociation) ?**

ANS: Gllian barr

**9-CSF has high polymorph, high protein and low glucose ,what is the diagnosis?**

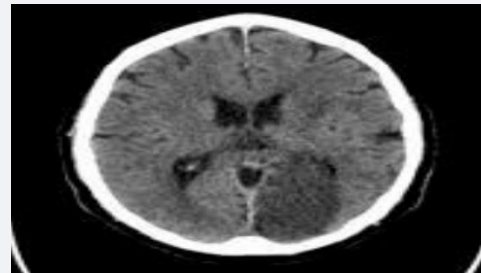
ANS: Bacterial meningitis

**10-Patient with upper limb loss of pain and temperature as shown in the figure, sings of UMN injury bilaterally in the lower limbs ,what is the diagnosis?**



ANS: Syringomyelia

**11- The following CT shows Left Occipital lobe infarction , what visual disturbance would happen?**



ANS: Right lateral hemianopia

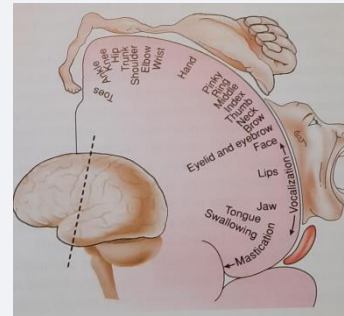
**12-Drug that cause gingival hyperplasia?**

ANS: Phenytoin

**13-What is the treatment for migraine ?**

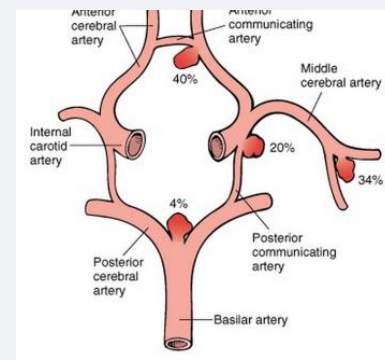
ANS: Sumatriptan

**14-Which artery supplies the leg region in the motor homunculus?**



ANS: ACA

**15-Which type of hemorrhage is suspected in the following disease?**



ANS: SUH

**16-Which nerve supply the brachioradialis muscle?**

ANS: Radial nerve

**17-Which of the following doesn't happen with LMN lesion?**

ANS: Plantar flexion

**18-What is the type of headache shown in the following figure ?**

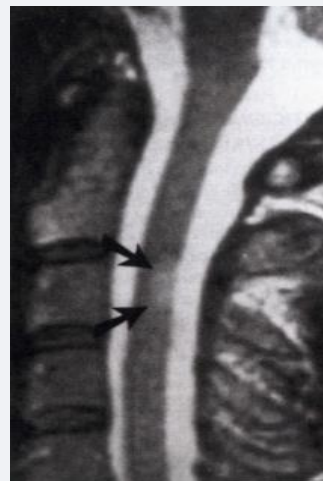


ANS: Cluster

**19-Mechanism of action of pramipexole ?**

ANS: Dopamine agonist

**20-Which of the following symptoms isn't caused by the following lesion?**



ANS: Cape like sensation loss

**Collected by : AHMAD SAMI**





## Neuro mini-osce 4th month

1-Which of the following nerve root values is responsible for the triceps reflex ?

**Answer:** C7

2-Which of the following nerves innervates the tibialis anterior muscle ?

**Answer:** Deep peroneal nerve

3-Which of the following nerves innervates the extensor carpi ulnaris muscle ?

**Answer:** Radial

4-These CSF findings are for a patient with:

Color clear

PMN cells Nil

Mononuclear cells < 5 (mm<sup>3</sup> idk)

Glucose 2/3 > 1/2 blood glucose ( 40-80 gm/ dL)

Protein 50 mg ( 2-4 g ???? Idk )

1. Normal CSF
2. Viral meningitis
3. Bacterial meningitis
4. TB meningitis
5. Fungal meningitis

**Answer:** Normal CSF

5- Which of the following is the environmental factor most associated with MS ?

1. Vitamin D deficiency
2. Low exposure to sunlight
3. EBV
4. Smoking
5. Idk ❤️

**Answer:** EBV

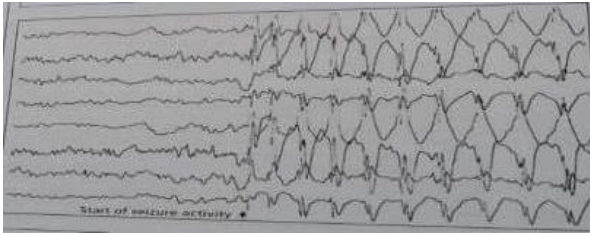
6-A pic of medial temporal hyperintensity

History of fever + altered mental state + without meningeal irritation signs

1. Herpes encephalitis
- Other insignificant options?

**Answer:** Herpes encephalitis

7- A 7 years old patient with atonic seizure name its type:



**Answer:** Petit mal absence seizure

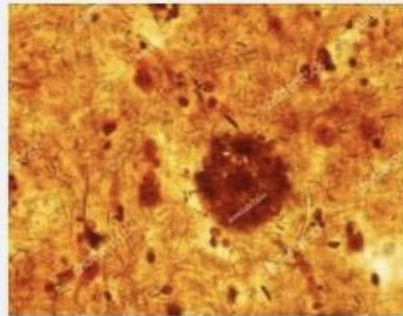
8- Sumatriptan is a :

1. 5HT 1 D antagonist
  2. 5HT 1 B/D agonist
  3. 5HT 2 B agonist
- I don't remember the rest

**Answer:** 5HT 1 B/D agonist

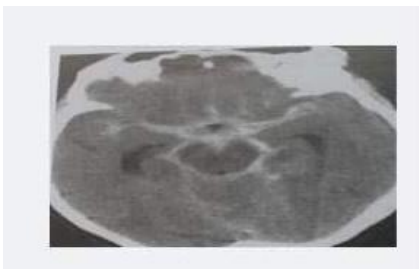
9-

11-A patient with Alzheimer's disease with the following autopsy ,what are these plaques called?



ANS: Amyloid plaques

10- A pic of subarachnoid hemorrhage ,What is the most common cause ?



1. Head injury
  2. Rupture of berry aneurysm
  3. HTN
  4. Rupture of Charcot aneurysm
- I don't remember the rest

**Answer:** Rupture of berry aneurysm

11-A 45 patient presented with decrease in visual activity that lasted for two weeks then faded away, and after a couple of months maybe ?, he complained of lower limb weakness or so that lasted for 3 months ig + a pic of dawson's fingers ? What is the diagnosis ?

1. MS

2. NMO

I don't remember the rest

**Answer:** MS

12- Right-handed patient presented with a right hemisphere anterior ischemic lesion  
All of the following can be a result of this ischemic injury except ?

1. Sensory loss

2. Hemiplegia

3. Upper motor neurons pattern of facial weakness

4. Broca aphasia

5. Idk

**Answer:** Broca aphasia

13- What is the role of carbidopa in the levodopa - carbidopa regimen?

**Answer:** Inhibits the peripheral dopa decarboxylase

14- Which of the following isn't a characteristic of Parkinson's?

**Answer:** Action tremor

15- A MRI with multiple abscesses ... high fever ... what is the cause ?

**Answer:** Bacterial infective endocarditis

16- Drug of choice to treat absence seizure ( valproic acid wasn't one of the options ) ?

**Answer:** Ethosuximide

17- The dopaminergic neurons get degenerated in Parkinson's disease in which area of the brain ?

**Answer:** Substantia nigra

18- A 34 man with unilateral headache eyelid edema lacrimation nasal congestion what is the first line treatment?

**Answer:** oxygen inhalation

19- The most common cause of cardioembolic stroke ?

**Answer:** A fib

20- A dementia diagnosis can be established with mini-mental examination score of less than ?

1. 27
2. 28
3. 23
4. 25
5. 20

**Answer:** 25

# Neuro miniOSCE | 5<sup>th</sup> group

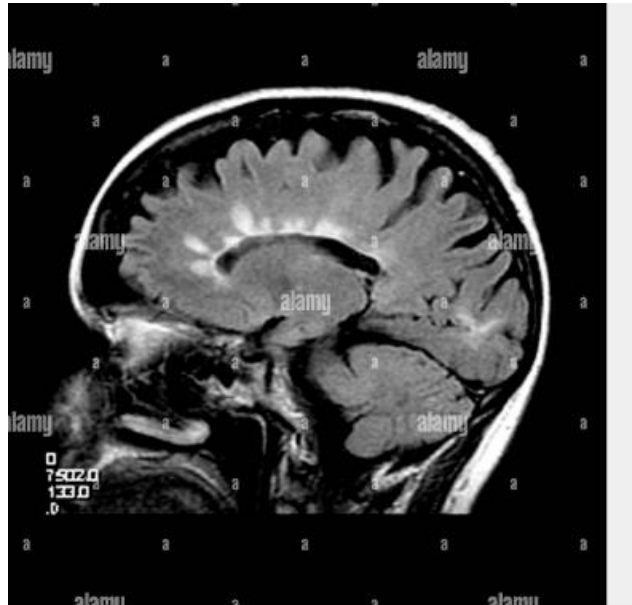
1- Defect in which muscle causes foot drop? (With a picture of lower limb muscles)

ANS: Tibialis anterior

2- Which nerve supplies Brachioradialis muscle (with a picture of upper limb muscles)

ANS: radial nerve

3- Patient MRI is as following, what do you expect to find in his CSF analysis?



ANS: Positive oligoclonal bands (it's Dawson fingers sign, seen in Multiple sclerosis)

4- A woman was diagnosed with essential tremor bilaterally. Her brother has a history of asthma, what's the best treatment? (There was a picture of drugs list)

ANS: mostly it's Primidone( the options for essential tremor are Propranolol and Primidone, but since there's a history of asthma, we can't give beta blocker to her.)

- 5- Obese female patient was diagnosed with migraine. Best preventive therapy for her? (A table of drugs similar to this table was shown):

**TABLE 10-2. Migraine Prophylaxis Oral Medications**

<b>Antihypertensives</b>	<b>Antiseizure Drugs</b>	<b>Antidepressants</b>
Metoprolol	Sodium valproate	<i>Amitriptyline</i>
Propranolol	<b>Topiramate</b>	<i>Venlafaxine</i>
<b>Timolol</b>		

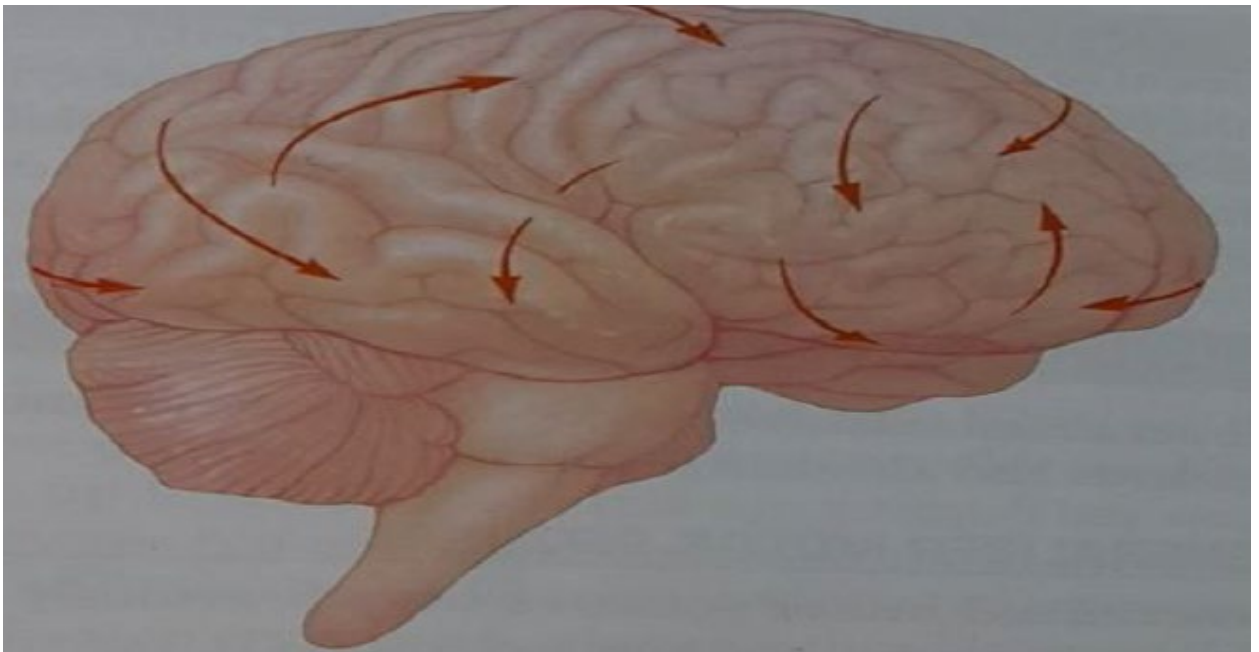
Medications in **bold** have level A evidence for efficacy. Medications in *italics* have level B evidence for efficacy.

ANS: Topiramate (since it causes weight loss as a side effect, which is desired for this patient)

- 6- 18 years old patient came with sudden jerking involuntary movements bilaterally in the morning without loss of consciousness. Which drug is contraindicated (with a picture showing list of anti seizure drugs)

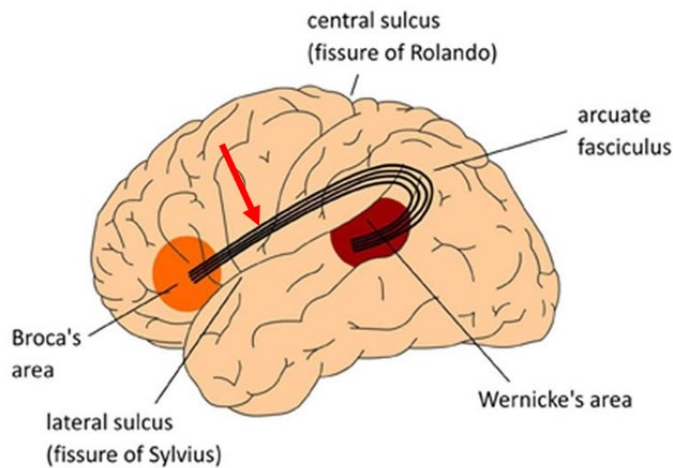
ANS: Carbamazepine (patient is mostly a case of juvenile myoclonic epilepsy)

- 7- Which of the following seizure types is not represented by this picture?



ANS: Jacksonian march (this picture represents Generalized seizures, and Jacksonian march is a focal seizure subtype)

8- A patient came with a stroke affecting the area pointed by the arrow. Which of the following will be seen in the patient?



ANS: Quadrantopia

9-Patient with weakness in hip girdle muscles. What type of gait will be seen (a list of gaits is shown)

ANS: Waddling gait

10- Patient was diagnosed with cluster headache. What's the 1<sup>st</sup> line drug in prevention therapy?

ANS: Verapamil

11- A patient came with signs and symptoms of encephalitis and he's suspected to have viral encephalitis with CT/MRI picture. Which virus is the most common cause?

ANS: Herpes simplex virus

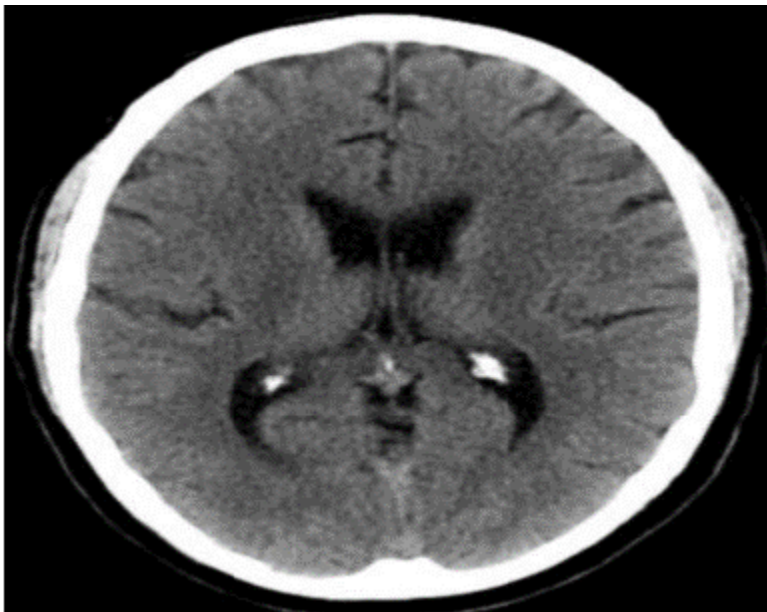

12- A table showing the results of a CSF findings. Which organism is mostly the cause?(Viral, bacterial, fungal, parasitic) :

Opening pressure	≤250 mm H <sub>2</sub> O
Leukocyte count	50-1000/μL
Leukocyte differential	Lymphocytes
Glucose	>45 mg/dL
Protein	<200 mg/dL
Gram stain	Negative
Culture	Negative

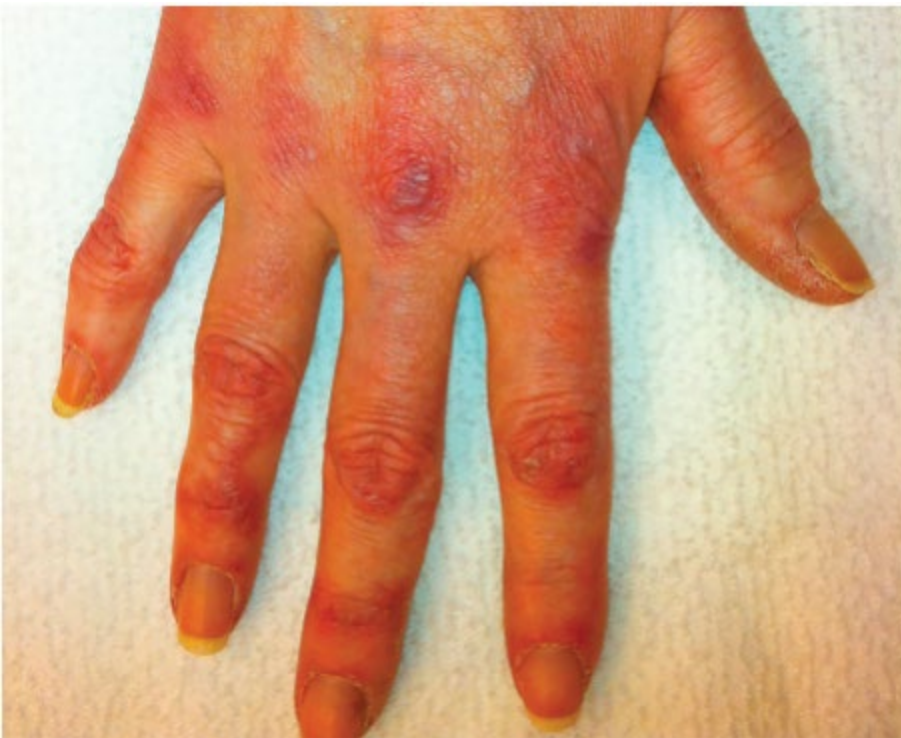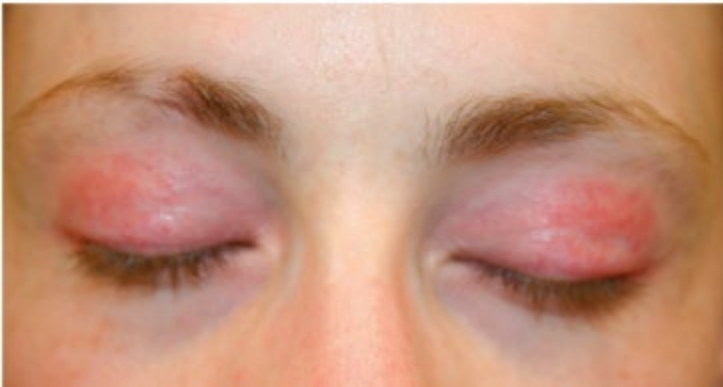ANS: Viral

13- Elderly patient came with right side hemiparesis and some other symptoms and signs of stroke. This CT was shown. What does it describe?



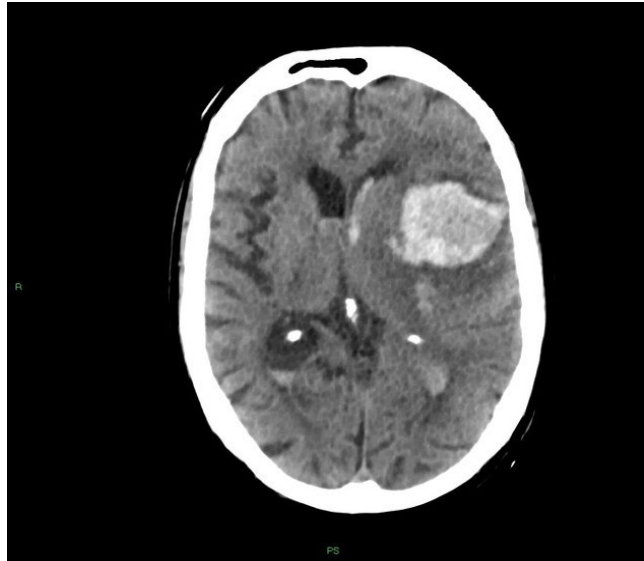
ANS: possibly normal CT scan (there's calcified choroid plexus)

14- Female patient came with these 2 findings in the pictures and other neurologic abnormalities. What can you also find in this patient?



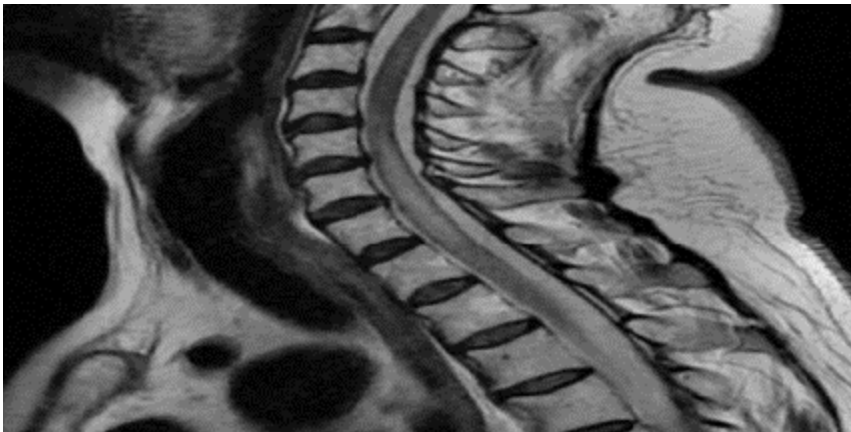ANS: Proximal muscle weakness (mostly the patient is a case of dermatomyositis), the pictures came from [this](#) article.

15- A 65 years old hypertensive patient came with stroke. CT scan showed this pic( close to the one in exam). What is the most probable cause?



ANS: Charcot-Bouchard aneurysm

16- This pic came with another pic( MRI of brain ) and some neurological symptoms and signs. What's the diagnosis?



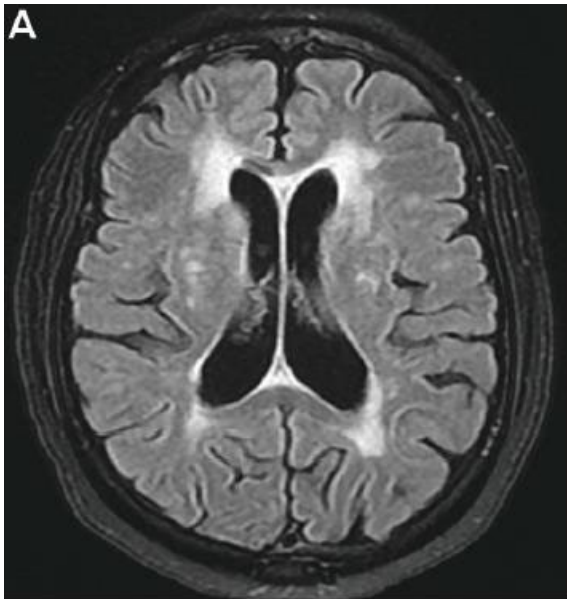
ANS: Neuromyelitis Optica

17- All of the following disease-modifying drugs in Alzheimer's disease are Anti-cholinesterases except?

- a- Donepezil
- b- Rivastigmine
- c- Memantine
- d- Galantamine

ANS: Memantine (NMDA receptor antagonist)

18- A picture showing this MRI scan and asking what type of dementia is seen here?



ANS: vascular dementia

19- A picture showing a list of stroke risk factors, asking which is the most important modifiable risk factor for stroke?

ANS: Hypertension

Glutamate antagonist.... Memantine

Prevent cluster headache... Verapamil

Patient with history of diplopia and vision loss with recurrent oral ulcers.... Neuro behcet

The examiner tried to EXAMINE...tibialis anterior

Ankle reflex... S1, S2

patient has a history of weakness and now vision loss... MS كان اشفي زي هييك

EEG... absence seizure

Retroorbital pain more in men duration for 120min, many episodes a day... Cluster headache

Pic.... Right third nerve palsy

Parkinson all of the following except

Shuffling gait

Decreased arms swings during walking

Resting tremor

الخيار المش موجود هو الصح نسيته

Unilateral headache with jaw claudication... Temporal vasculitis

MRI.. Herpes encephalitis

Lateral stroke in left side... Wrenicks aphasia

Muscle disease result in fatigue and weakness

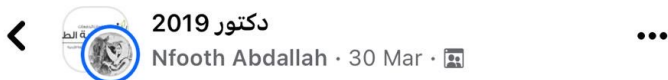Intracranial bleeding... Cause HXN

Pic of.... Amyloid plaques

Pic of - Jacksonian seizure

Increased dopamine and decrease Ach associated with? Chorea

Most common cause of cardiovascular embolism... A. FIBRILLATION



بوست تجميع اسئلة النيورو الشهر السادس  
#انطلقوا 🔥🔥🔥



Like



Comment



Send

All comments ▾

**Nfooth Abdallah**

Author

[Waad Almanaseer](#)

36w Like Reply

**Waad Almanaseer**[Malak Ma'ayah](#)

36w Like Reply

**Abrar Al-Ali**

Triceps jerk ...root C7

Posterior tibialis ... tibial nerve

Ulnar nerve ..for figure of hand with ulnar nerve damage

Most important risk factor for ischemic stroke..hypertension

Drug that cause renal calculi..toprimate

Drug not used for focal seizures..ethx..

36w Like Reply

**Sreen Natorieh**

Fever, behavioral change 3 months ago




Write a comment...





دكتور 2019

Nfouth Abdallah · 30 Mar · 

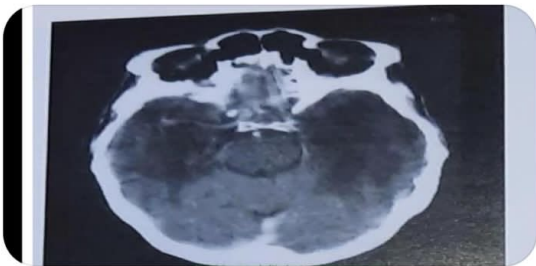
Drug not used for focal seizures..ethx..

36w Like Reply

**Sreen Natorieh**

Fever, behavioral change 3 months ago...  
Resolved by the pt still has memory  
problems..MRI was done ....answer was 'old  
heratic encephalitis'

36w Like Reply

**Sreen Natorieh**

36w Like Reply

**Abrar Al-Ali**[Sreen Natorieh](#) herps\*

36w Like Reply



Write a reply...

**Sreen Natorieh**

Infarction.. Cerebellum and lateral medulla are  
affected on MRI.. Which artery is affected?



Write a comment...





دكتور 2019

Nfooth Abdallah · 30 Mar ·



Sreen Natorieh

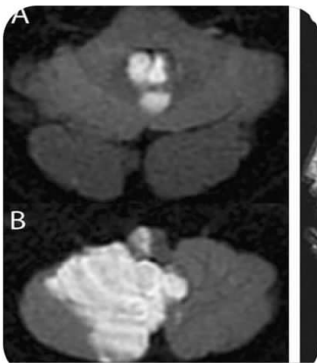
Infarction.. Cerebellum and lateral medulla are affected on MRI.. Which artery is affected?

A. PICA

36w Like Reply



Sreen Natorieh



36w Like Reply



Write a reply...



Sreen Natorieh

MRI of Subarachnoid hemorrhage.. What is the most common cause?

A. Rupture of berry aneurysm

36w Like Reply



Sreen Natorieh



Write a comment...







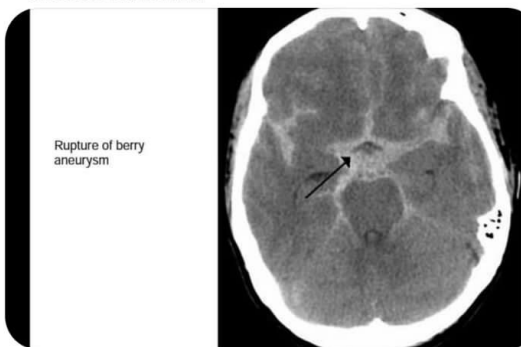
دكتور 2019

Nfooth Abdallah · 30 Mar · **Sereen Natorieh**

MRI of Subarachnoid hemorrhage.. What is the most common cause?

A. Rupture of berry aneurysm

36w Like Reply

2 **Sereen Natorieh**

36w Like Reply



Write a reply...

**Sereen Natorieh**

Pt with headache that isn't relieved by simple analgesia..with picture of enlarged temporal artery ..

Not sure about the answer but I think it's giant cell arteritis.

36w Like Reply

1 

Write a comment...



Write a reply...



**Sereen Natorieh**

Pt with headache that isn't relieved by simple analgesia..with picture of enlarged temporal artery ..

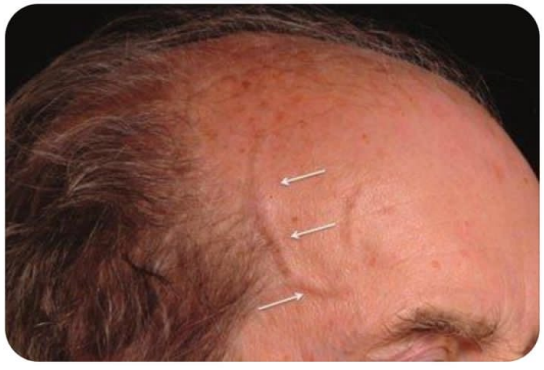Not sure about the answer but I think it's giant cell arteritis.

36w Like Reply



**Sereen Natorieh**

Similar to this picture



36w Like Reply

Write a reply...



**Sereen Natorieh**

Picture of person with Parkinson's disease



Write a comment...





دكتور 2019

Nfooth Abdallah · 30 Mar ·



36w Like Reply



Write a reply...



Sreen Natorieh

\_Picture of person with Parkinson's disease (stooped posture, short narrow steps).. What type of gait? .. Shuffling gait.

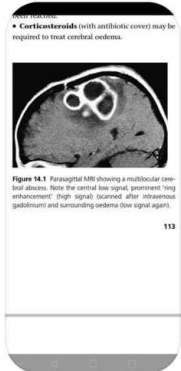
\_sinusitis headache pattern

\_MRI of brain abscess

36w Like Reply



Sreen Natorieh



36w Like Reply



Write a reply...



Sreen Natorieh



Write a comment...





دكتور 2019

Nfooth Abdallah · 30 Mar ·



36w Like Reply



Write a reply...

**Sreen Natorieh**

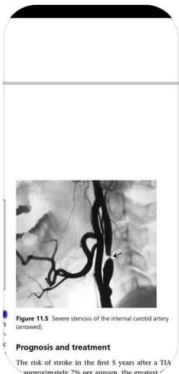Pt with history of TIA involving the right side of the body.. Angioraphy done..

A.severe left internal carotid artery stenosis

36w Like Reply



**Sreen Natorieh**



36w Like Reply



Write a reply...

**Sreen Natorieh**

Pt was asked to look to the right... What is the abnormality?




Write a comment...





دكتور 2019

Nfooth Abdallah · 30 Mar ·



36w Like Reply



Write a reply...



Sereen Natorieh

Pt was asked to look to the right... What is the abnormality?

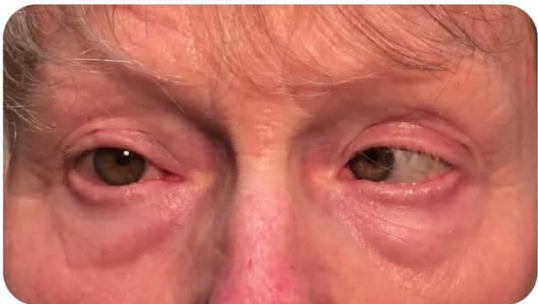A.6th cranial nerve palsy

36w Like Reply



Sereen Natorieh

Picture similer to this



36w Like Reply



Write a reply...



Sereen Natorieh

Pt who is right handed. Brain ct showed this



Write a comment...





دكتور 2019

Nfooth Abdallah · 30 Mar · 

36w Like Reply



Write a reply...

**Sereen Natorieh**

Pt who is right handed.. Brain ct showed this lesion.. What do you expect him to have?

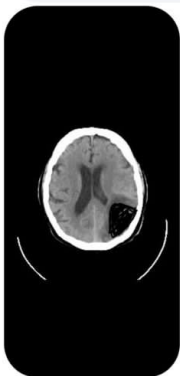
- 1.left hemiparesis
- 2.broca's aphasia
- 3.Wernicke's aphasia
- 4.opthalmoplegia

I think the answer is Wernicke's aphasia

36w Like Reply

**Sereen Natorieh**

Lesion was similar to this



36w Like Reply



Write a comment...





Like



Comment



Send



1

All comments ▾

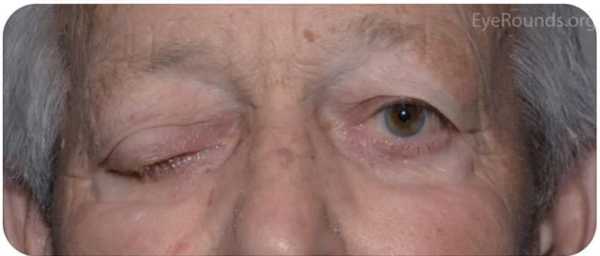

بشرى محمود

Author

Pic of complete ptosis :

1. 2nd nerve pulsy
2. 3rd nerve pulsy ✓
3. Horner syndrome



33w Like Reply



بشرى محمود

Author

Gingival hyperplasia -&gt; phynetoin

33w Like Reply



Hamza AbuRadaha

Multible brain abscesses&gt;&gt;&gt; infective endocarditis

33w Like Reply



Hamzah Alzaben



Write a comment...





دكتور 2019

بشرى محمود · 19 · Apr · 

33w Like Reply



Hamzah Alzaben

Gait سؤالين -&gt; shuffling

33w Like Reply



بشرى محمود

Author

Hamzah Alzaben

The first one maybe " spastic gait " ?

33w Like Reply



Write a reply...



بشرى محمود

Author

Abductor pollicis brevis -&gt; median nerve

33w Like Reply



بشرى محمود

Author

7 year old , stare , pic of EEG -&gt; absence seizure

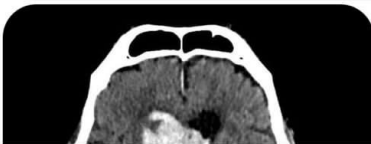
33w Like Reply



بشرى محمود

Author

Pic like this of CT -&gt; brain hemorrhage



Write a comment...

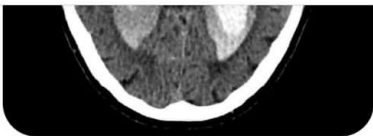






دكتور 2019

بشرى محمود · 19 Apr ·



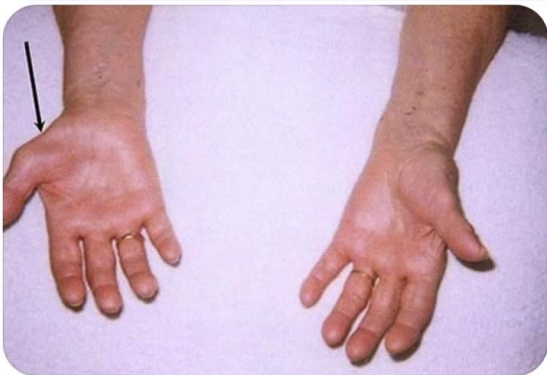33w Like Reply



بشرى محمود

Author

Maybe pic. Like this -> carpal tunnel syndrome



33w Like Reply



بشرى محمود

Author

All true about dopamine/ ach imbalance exsept.

33w Like Reply



Bayan Thainat

Noor Jabr

29w Like Reply



Yumna Al-wraikat

Islam Bilal



Write a comment...

