


MEDIASTINAL MASSES

Prof MoaathAlsmady



- ▶ Benign or malignant mediastinal masses can develop from structures that are normally **located** in the mediastinum or that **pass** through the mediastinum during development, as well as from **metastases** of malignancies that arise elsewhere in the body.

- ▶ The mediastinum is the region in the chest between the pleural cavities that contain the heart and other thoracic viscera except the lungs
 - ▶ Boundaries
 - Lateral – parietal pleura
 - Anterior – sternum
 - Posterior – vertebral column and paravertebral gutters
 - Superior – thoracic inlet
 - Inferior – diaphragm
- 

Divisions of the Mediastinum

SUPERIOR MEDIASTINUM

Superior – thoracic inlet

Inferior – transverse
thoracic
plane

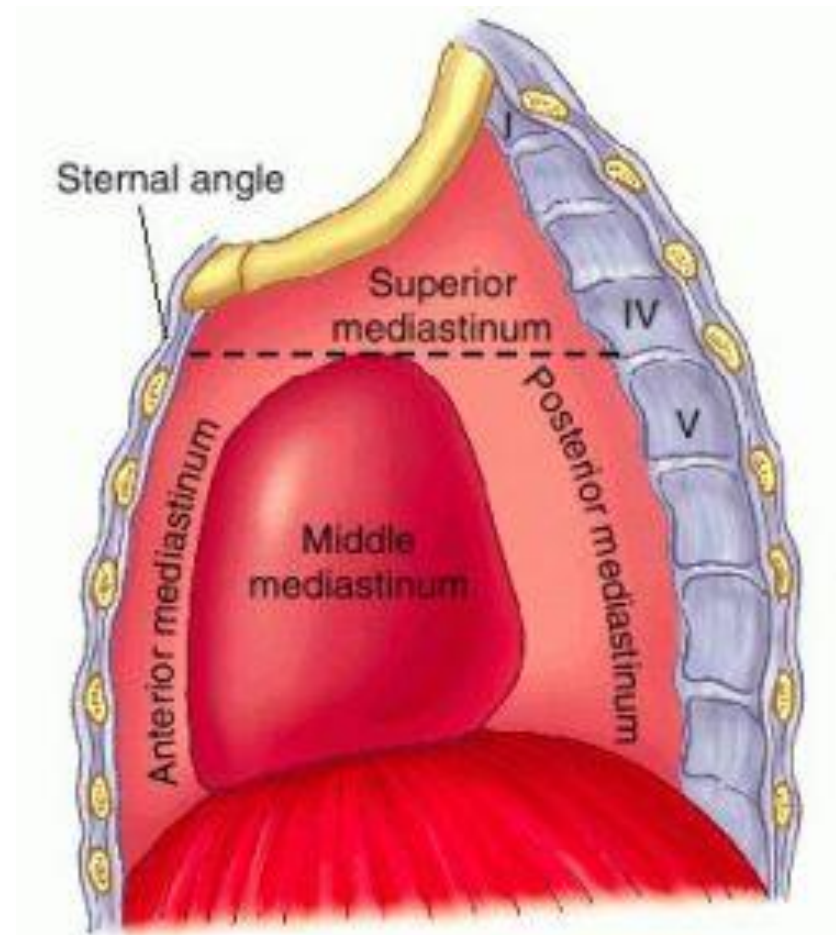
Anterior – sternal angle

Posterior – IV disc T4 & T5

INFERIOR MEDIASTINUM

Superior – transverse thoracic
plane

Inferior – diaphragm



▶ Anterior mediastinum

- Everything lying forward of and superior to the heart shadow
 - **Boundaries**
 - Sternum, first rib, imaginary curved line following the anterior heart border and brachiocephalic vessels from the diaphragm to the thoracic inlet
 - **Contents**
 - Thymus gland, substernal extension of the thyroid and parathyroid gland and lymphatic tissues

▶ Middle mediastinum


- Dorsal to the anterior mediastinum, extends from the lower edge of the sternum along the diaphragm and then cephalad along the posterior heart border and posterior wall of the trachea
- **Contents**
 - Heart, pericardium, aortic arch and its major branches, innominate veins and superior vena cava, pulmonary arteries and hila, trachea, group of lymph nodes, phrenic and upper vagus nerve

▶ Posterior Mediastinum

- Occupies the space between the back of the heart and trachea and the front of the posterior ribs, and paravertebral gutter
- It extends from the diaphragm cephalad to the first rib
- **Contents**
 - Esophagus, descending aorta, azygos and hemiazygos vein, paravertebral lymph nodes, thoracic duct, lower portion of the vagus nerve and the sympathetic chain

DDx of Mediastinal Masses

■ **Antero-superior mediastinum:**


- **Thymic tumors:**
 - **Lymphomas:**
 - **Germ cell tumors:**
 - **Endocrine tumors:**
 - **Mesenchymal tumors:**
- 

■ **The middle mediastinum:**

- **Lymphomas.**
- **Cysts:**
- **Mesenchymal tumors.**
- **Tracheal tumors.**
- **Cardiac and pericardial tumors**
- **Vascular tumors:**
- **Lymphadenopathy:**

■ **The posterior mediastinum:**

- **Lymphomas**
- **Neurogenic tumors:**
 - **Mesenchymal tumors**
 - **Esophageal tumors and cysts**
 - **Hiatal hernias.**
 - **Thoracic duct cyst.**
 - **Meningocele.**



Regionalization

**Anterior
Mediastinum**



**Teratoma, Thymus
Ectopic Thyroid
Adenopathy**

**Middle
Mediastinum**




**Adenopathy
Bronchogenic Cysts
Esophageal
Duplication Cysts**

**Posterior
Mediastinum**



**Neurogenic Tumors
Esophageal
Duplication Cysts**

Anterior Mediastinum

1. Lymphoma .
 2. Teratoma
 3. Germ cell tumors
 4. Cystic hygromas
 5. Thymic lesions
- 


Anterior Mediastinum

Lymphoma

- ▶ Usually older child
 - Hodgkin's - 14 yrs
 - Non-Hodgkin's - 9 yrs
- Often have other symptoms and other adenopathy
- Frequently have airway compromise

Symptoms

- Mediastinal mass effects – **Direct** involvement or compression of normal mediastinal structures cause a wide range of symptoms. These can include cough, stridor, hemoptysis, shortness of breath, pain, dysphagia, hoarseness, facial and/or upper extremity swelling due to vascular compression (eg, superior vena cava syndrome), hypotension due to tamponade or cardiac compression, and Horner syndrome due to sympathetic chain involvement.



Symptoms

- ▶ Systemic effects – Systemic symptoms such as fever, night sweats, and weight loss can be present in the case of lymphoma or may be due to a variety of **paraneoplastic** syndromes, such as myasthenia gravis with thymoma.

THYMOMAS

- ▶ Thymic lesions account for approximately **one-half** of all anterior mediastinal masses and can include a range of benign and malignant histologies
- ▶ Thymomas occur in patients of all ages, with a peak incidence between **ages 40 to 60** years. The gender distribution is approximately equal

Mediastinal Masses: Jordan University Hospital (10 Year Experience)

*Moaath Alsmady¹, Mohammad Aladaileh², Ibraheem obaidat³,
Abdullah Nassar³, Mohammad Al Qaisi³*

Abstract

Background: Mediastinal masses is one of the common diseases faced in thoracic surgical practice, patterns of histopathological distribution of these masses are similar in many reports in the literature, with verities of differences in patients and tumors characteristics.

AIM: To describe the most common clinical presentations and histological diagnosis of our patients that are treated by surgery, and to report the experience in our center in treating such patients with surgery.

Methods: By reviewing medical records of all patients diagnosed with mediastinal masses at Jordan University hospital over a period of 10 years; from 2005 to 2015. Data about Patients' demographic characteristics, preoperative and postoperative diagnosis and perioperative course were collected and analyzed.

Results: Over a period of 10 years; 100 patients treated with surgery for mediastinal masses at the thoracic surgery division of Jordan University Hospital. 50 % of patients had postoperative diagnosis of masses with thymic gland in origin and another 50 % diagnosed with other masses that were not thymic in origin. Thymic masses tend to occur in younger patients with an average age of 36 years compared with the non-thymic masses which were found in older patients with an average age of 42 years (p value of 0.04). Benign masses (75% of patients) were more common in the diagnosis compared with malignant ones (25 % of patients). No perioperative mortality was reported in our patients, with morbidity of 12%. Post-operative bleeding, pleural effusion and Deep Vein Thrombosis (DVT) being of the most common morbidity.

Keywords: Mass, Jordan, Mediastinal Masses

(J Med J 2020; Vol. 54(1):37-46)

Received


April 8, 2019

Accepted

Oct. 3, 2019

- ▶ Thymomas are associated with a variety of paraneoplastic syndromes .The most common is **myasthenia gravis**, which occurs in approximately **30** percent of patients with thymoma. Furthermore, some patients who are diagnosed with myasthenia gravis will be found to have a thymic mass on imaging. Patients with a thymic mass who have not been evaluated for myasthenia gravis should be tested for anti-acetylcholine receptor antibodies. Computed tomography (CT) of the chest.

THYMOMAS

- ▶ All thymomas originate from epithelial thymic cells
 - ▶ 4% of them consist of a pure population of epithelial cells
 - ▶ Most have mixed populations of lymphoid cells to a varying extent
- 

THYMOMAS

- ▶ ~50% – asymptomatic, discovered incidentally on CXR or at autopsy
- ▶ ~30% local symptoms related with pressure or local invasion: SVC sdr., cough, chest pain, dysphonia, dysphagia
- ▶ ~20%– 70% associated with an autoimmune disease:
 - Myasthenia gravis
 - Pure red cell aplasia
 - Polymyositis
 - hypogammaglobulinemia

Masaoka Classification.

STAGE I

Encapsulated tumor with no gross or microscopic invasion

TREATMENT Complete surgical excision

STAGE II

Macroscopic invasion into the mediastinal **fat** or **pleura** or microscopic invasion into the capsule

TREATMENT Complete surgical excision and postoperative radiotherapy to decrease the incidence of local recurrence

STAGE III

Macroscopic invasion of the pericardium, great vessels, or lung

TREATMENT Complete surgical excision and postoperative radiotherapy to decrease the incidence of local recurrence

STAGE IVA

Pleural or pericardial metastatic spread

TREATMENT Surgical debulking, radiotherapy, and chemotherapy

STAGE IVB

Lymphogenous or hematogenous metastases

TREATMENT Surgical debulking, radiotherapy, and chemotherapy

PROGNOSIS

- Benign tumors are noninvasive and encapsulated.
- Conversely, malignant tumors are defined by local invasion into the thymic capsule or surrounding tissue.
- The Masaoka staging system of thymomas is the most commonly accepted system.
- Preponderance of evidence indicates that all thymomas, except completely encapsulated stage 1 tumors, benefit from adjuvant **radiation** therapy
- The prognosis of a person with a thymoma is based on the tumor's gross characteristics at operation, not the histological appearance.


DIAGNOSIS

- **Chest scan is the imaging procedure of choice**
 - - Thymic enlargement should be determined because most enlarged thymus glands on CT scan represent a thymoma.
 - CT scan with intravenous contrast dye is preferred
 - to show the relationship between the thymoma and surrounding vascular structures,
 - to define the degree of its vascularity, and
 - to guide the surgeon in removal of a large tumor, possibly involving other mediastinal structures

DIAGNOSIS

Biopsy:


- If a patient presents with atypical features or is found to have an invasive tumor and is under consideration for induction therapy, obtaining preoperative biopsy is indicated.
- The limited anterior mediastinotomy . A thoracoscopic approach for biopsy also can be used

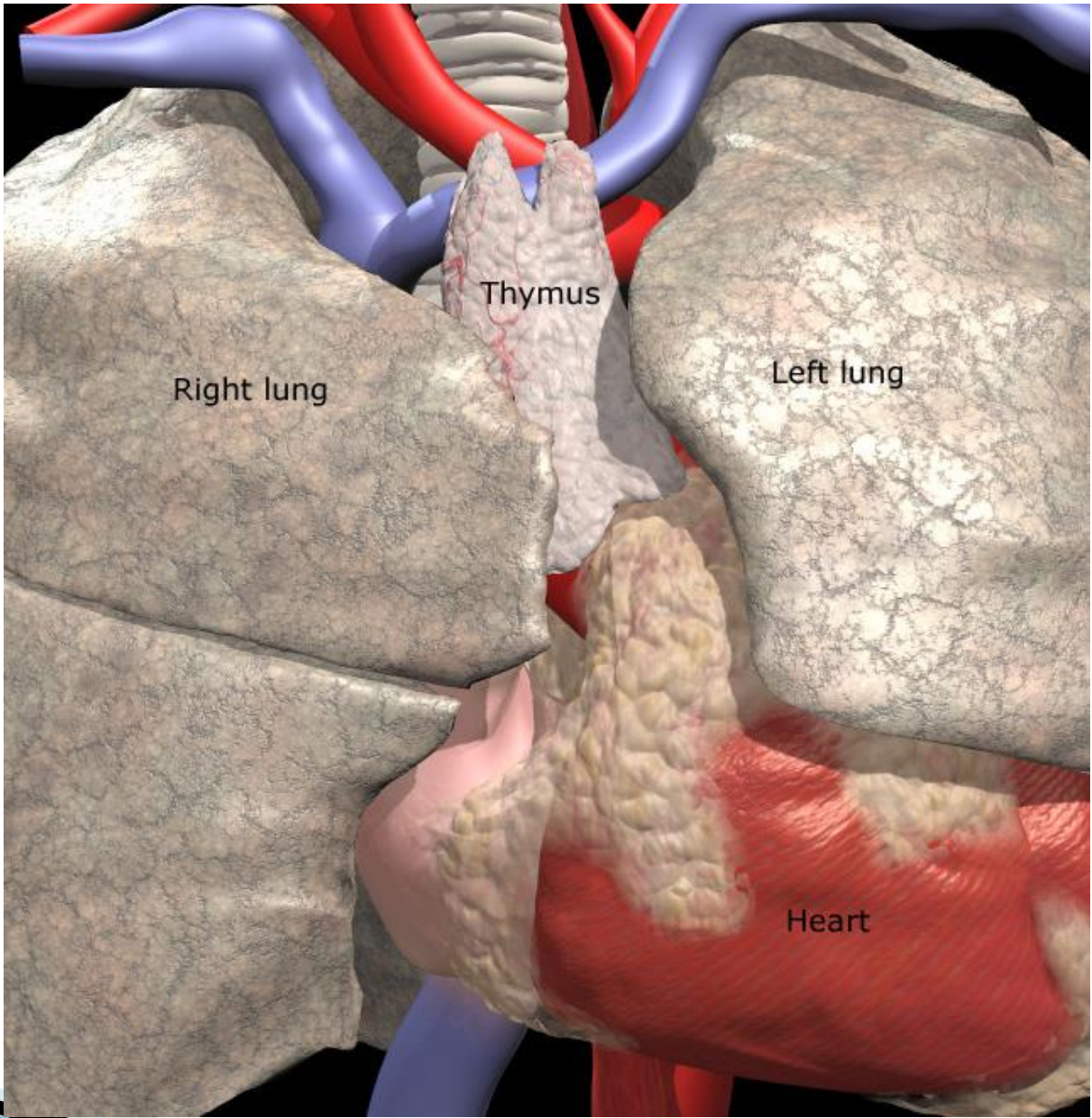
- If the tumor is small and appears readily accessible, perform a **total thymectomy with contiguous removal of mediastinal fat.**
 - **If the tumor is invasive, perform a total thymectomy in addition to en bloc removal of involved pericardium, pleura, lung, phrenic nerve, innominate vein, or superior vena cava.** Resect one phrenic nerve; however, if both phrenics are involved, do not resect either nerve, and debulk the area.
 - **Clip areas of close margins or residual disease to assist the radiation oncologist in treatment planning**
- 

Chemotherapy

- The most common chemotherapy drugs in the treatment of thymoma are:
 - doxorubicin (Adriamycin, Rubex),
 - cisplatin (Platinol),
 - cyclophosphamide (Cytosan, Neosar),
 - etoposide (VePesid, Etopophos, Toposar), and
 - ifosfamide (Ifex, Holoxan).
- The common combinations used for the treatment of thymoma include:
 - cyclophosphamide, doxorubicin, and cisplatin, or etoposide and cisplatin.

Radiotherapy

- Adjuvant radiation therapy in completely or incompletely resected stage III or IV thymomas is considered a standard of care.
 - The use of postoperative radiation therapy in stage II thymomas has been more questionable.
 - Thymomas are indolent tumors that may take at least 10 years to recur; therefore, short-term follow-up will not depict relapses accurately.
- 

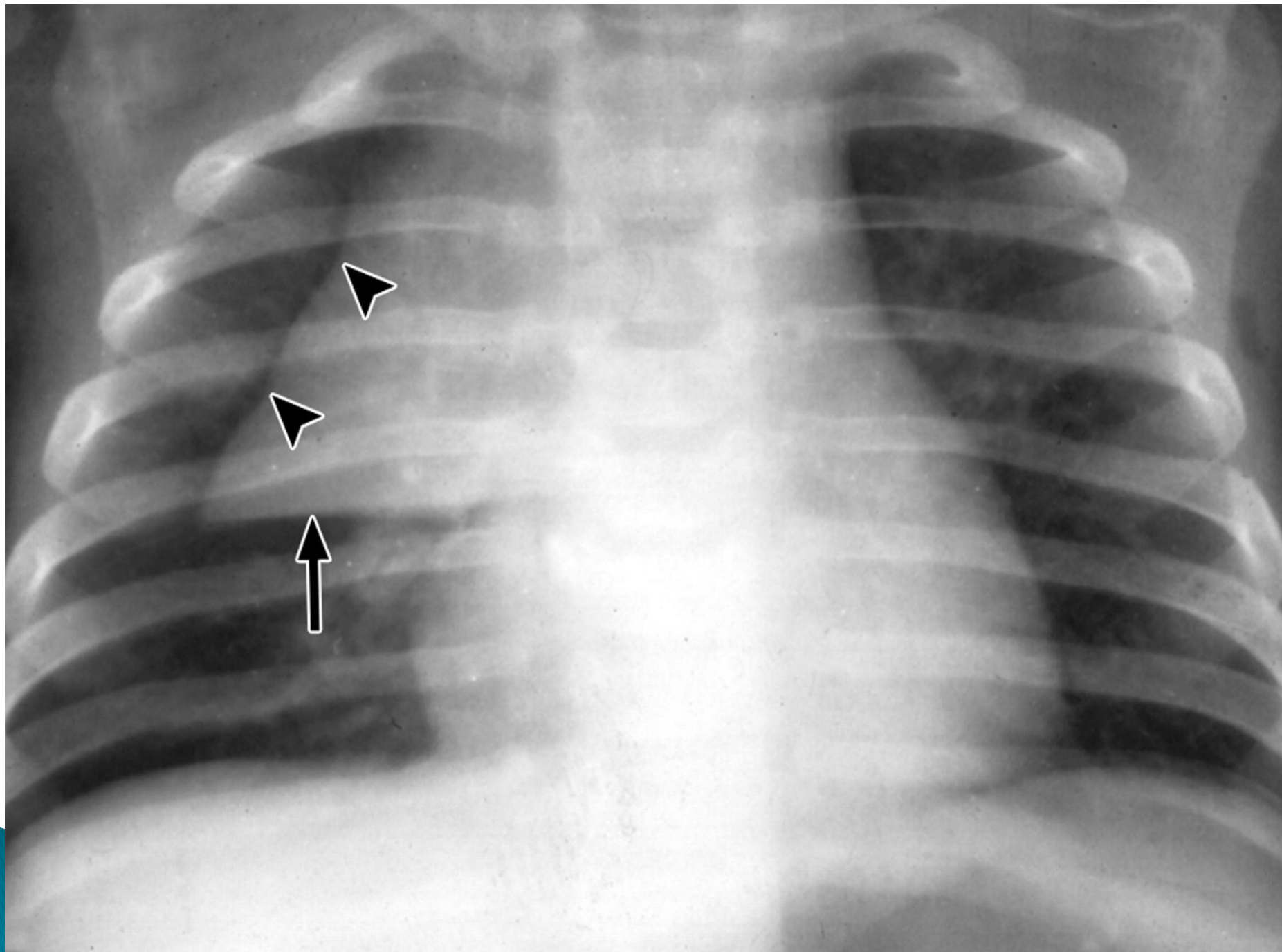


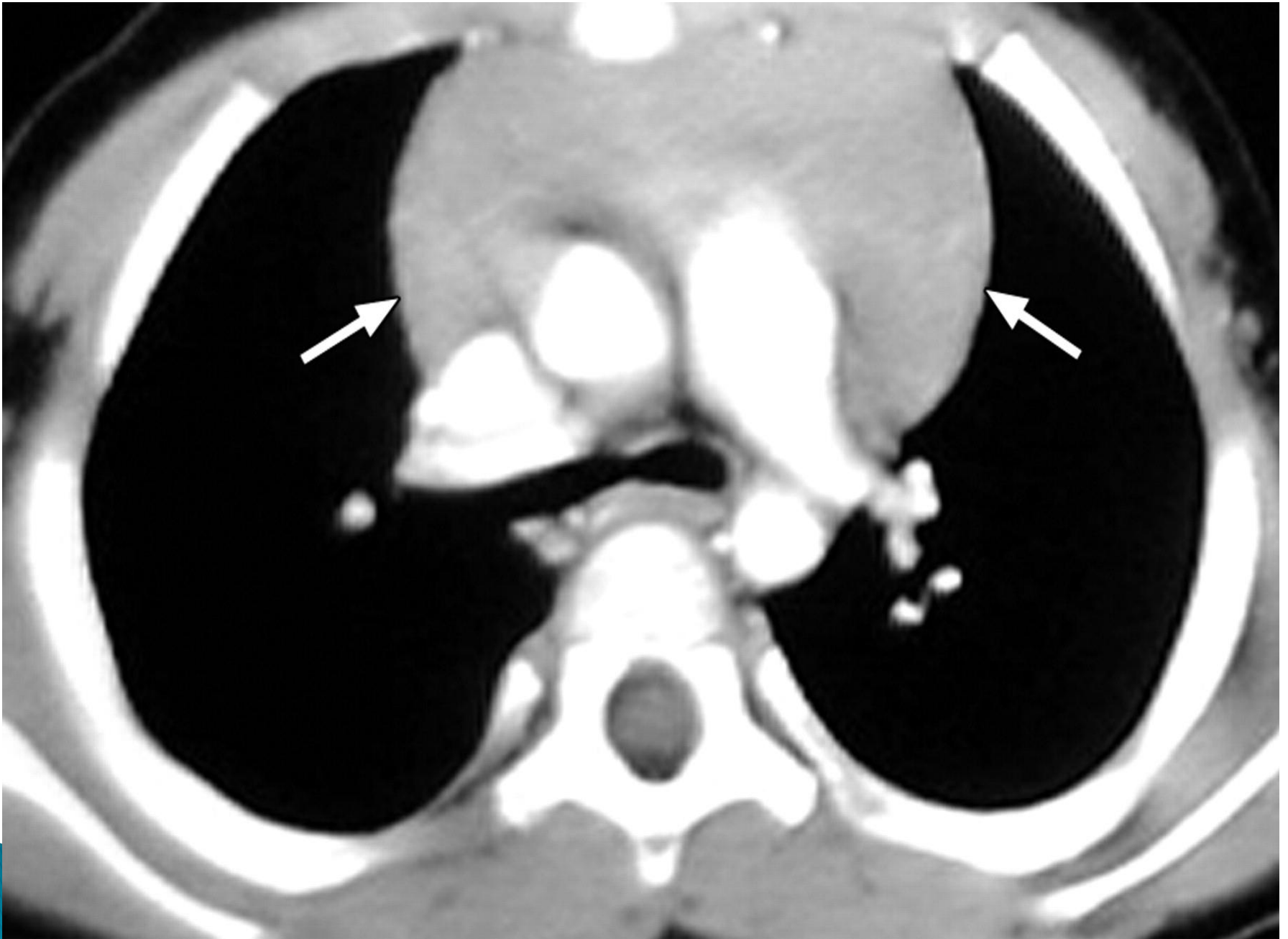
Thymus

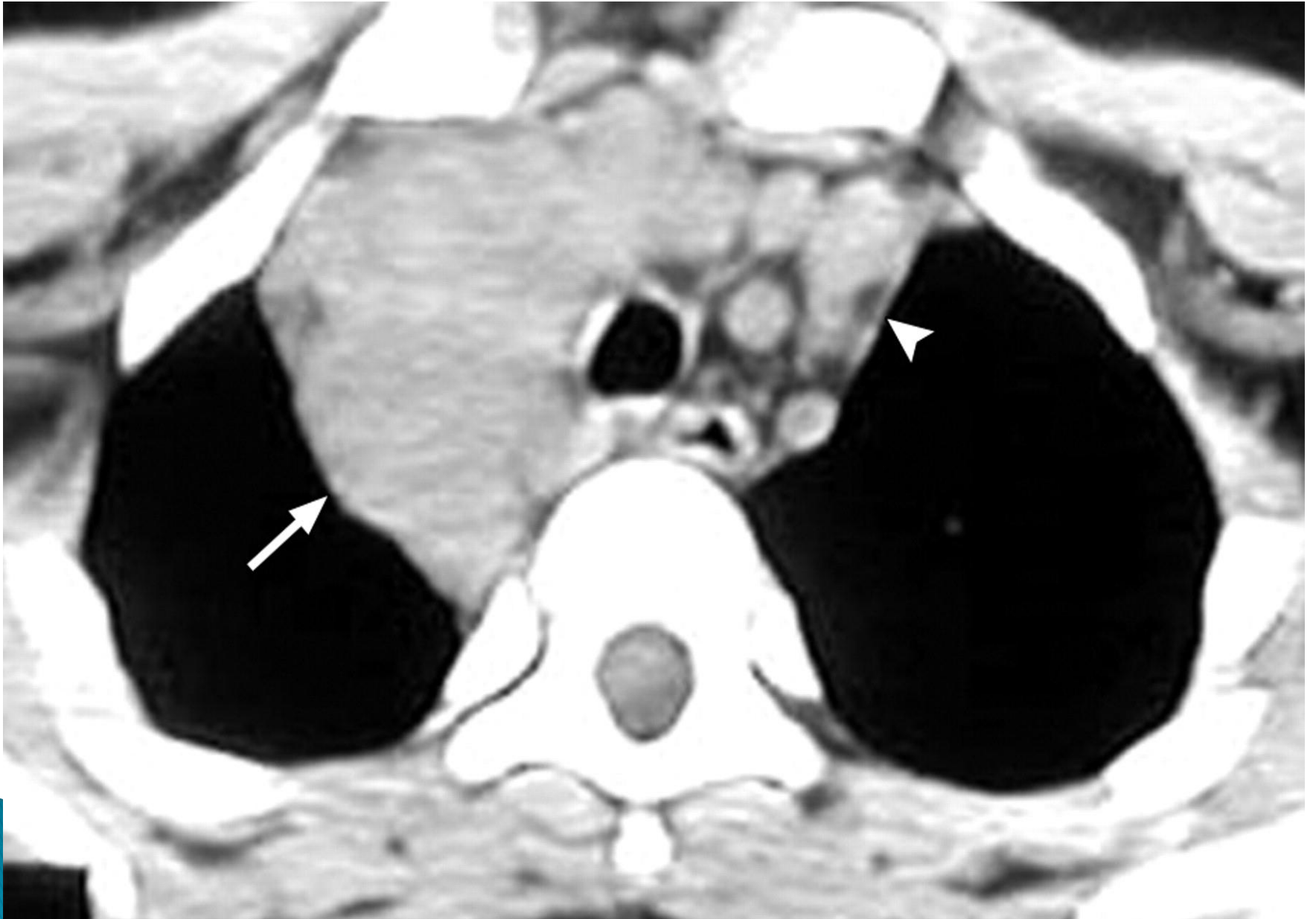Right lung

Left lung


Heart







Mediastinal tumor — The mediastinum is the **most** common site for **extragonadal** germ cell tumors in adults. Germ cell tumors can be either benign (teratomas, dermoid cysts) or malignant (seminomas, nonseminomatous germ cell tumors). Seminomas are more common than nonseminomatous germ cell tumors. All patients with a mediastinal mass that could be a germ cell tumor should have alpha-fetoprotein (**AFP**), lactate dehydrogenase (LDH), and beta-human chorionic gonadotropin (**β-HCG**) measured prior to any therapy.




Enlarged/ectopic thyroid

- ▶ — Intrathoracic thyroid tissue typically causes symptoms of shortness of breath or dysphagia. The intrathoracic mass is usually **continuous** with the thyroid gland in the neck; only 2 percent of cases are separate from the cervical thyroid.

Middle mediastinum

- ▶ Lymphadenopathy — Lymphadenopathy is the most common lesion presenting as a mass in the middle compartment of the mediastinum .The most common causes include lymphoma, sarcoid, and metastatic lung cancer.

Middle Mediastinum

- ▶ < 2 yrs: Remnants of embryonic foregut (trachea & esophagus)
 - ▶ Pericardial cysts
 - ▶ Lymphadenopathy
- 

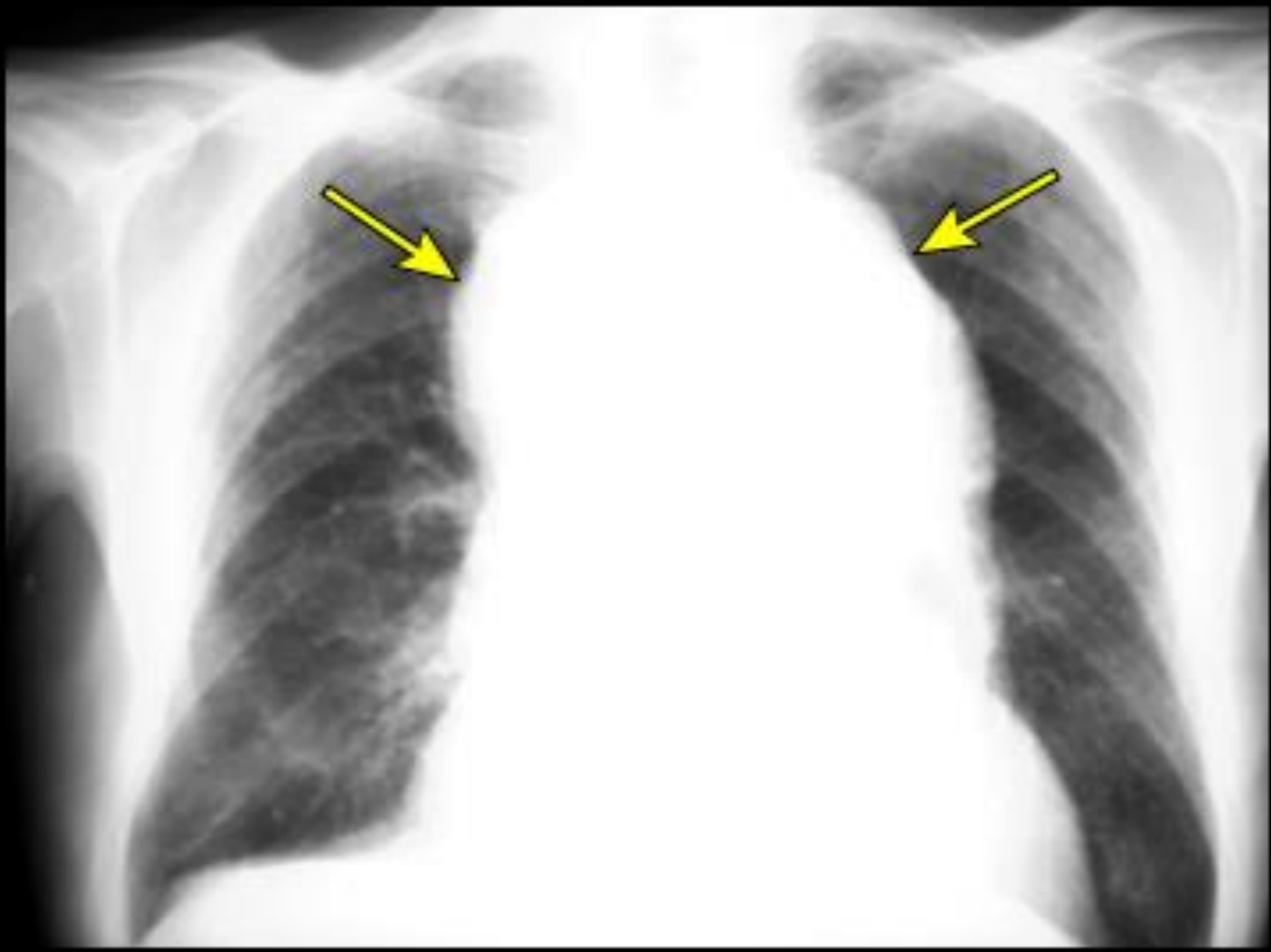
Middle Mediastinum

Esophageal Duplication Cyst

- ▶ Adjacent to or embedded in wall of esophagus
- ▶ Can have respiratory or GI epithelium
- ▶ May either obstruct or erode through esophageal wall

- ▶ Benign cystic tumor — Cystic masses comprise approximately 20 percent of middle mediastinal masses.
- ▶ Bronchogenic cysts are the **most** common cystic lesion and are felt to be secondary to abnormal lung budding during development. Bronchogenic cysts are more common in **men**. These lesions are sometimes identified because patients have symptoms of substernal pain, cough, recurrent **infection** symptoms, or dyspnea and are typically located in the right paratracheal region and in the subcarinal location.

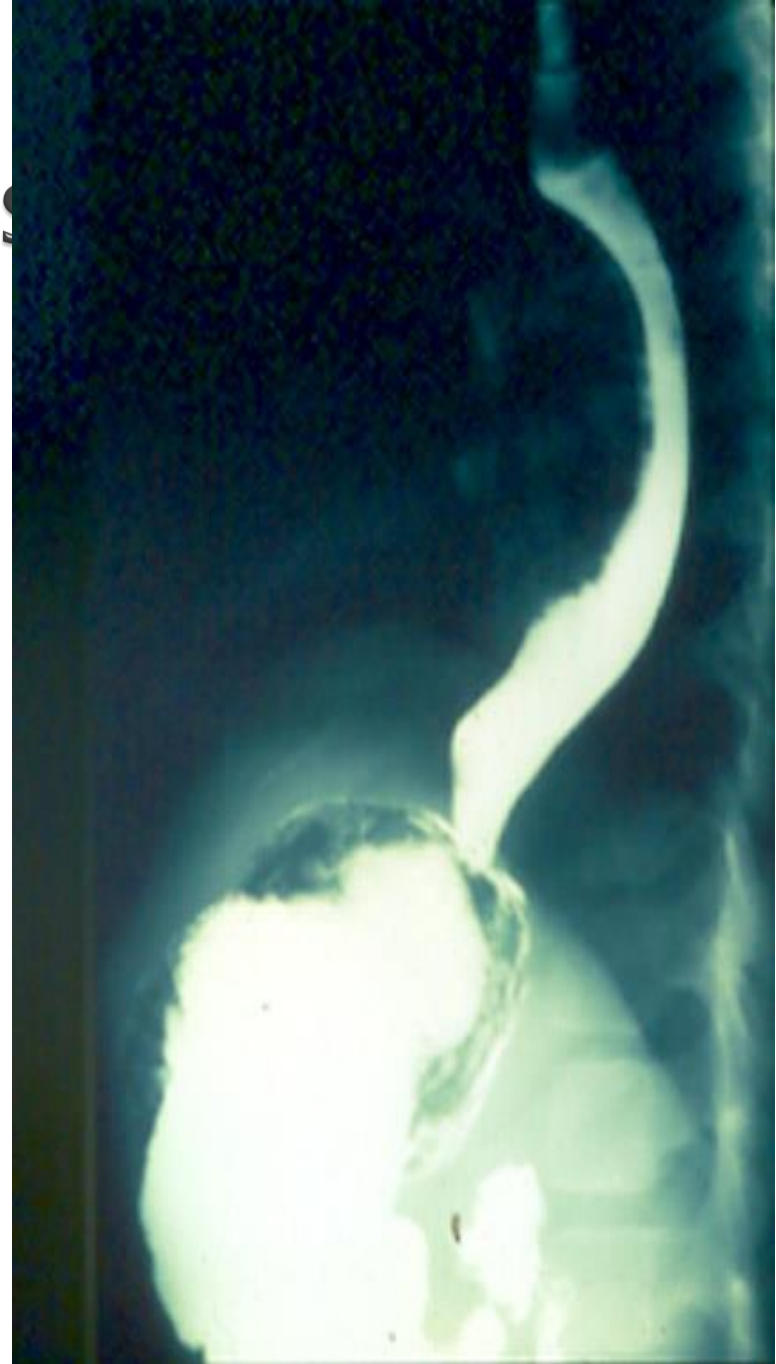- ▶ Cardiovascular aneurysm or anomaly — A variety of cardiovascular pathologies (eg, thoracic aortic aneurysm, pulmonary artery aneurysm, vascular rings) can present as a mediastinal abnormality.



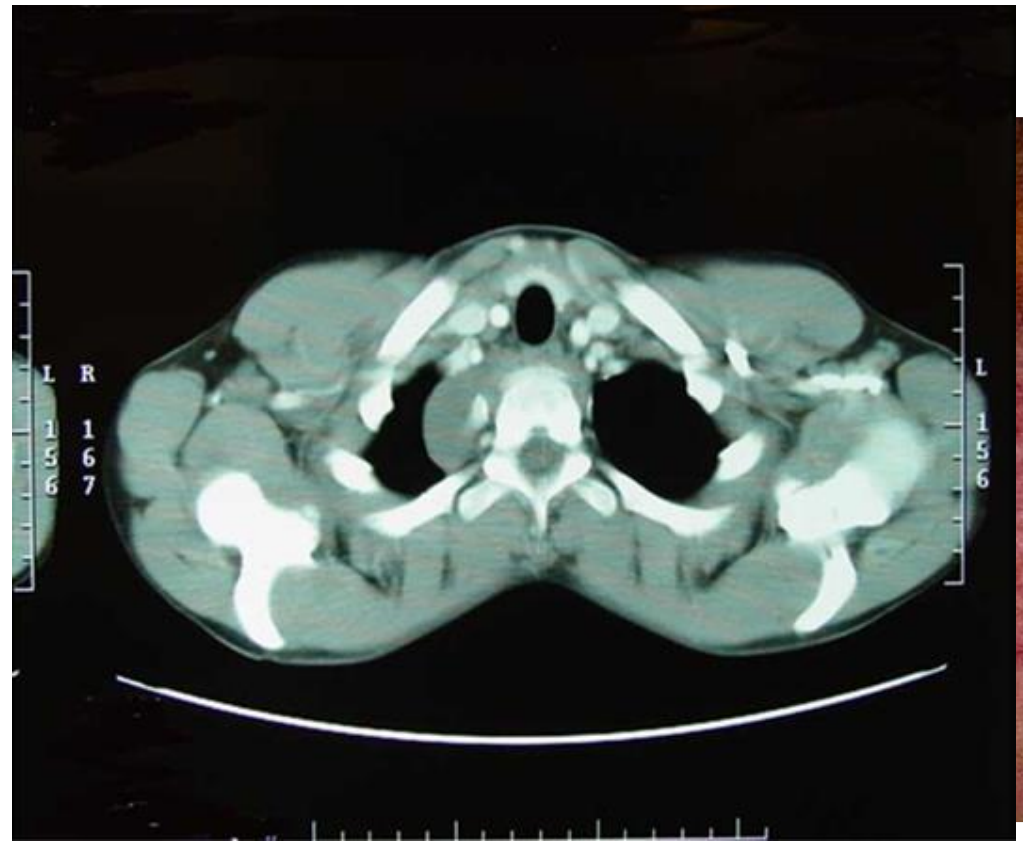
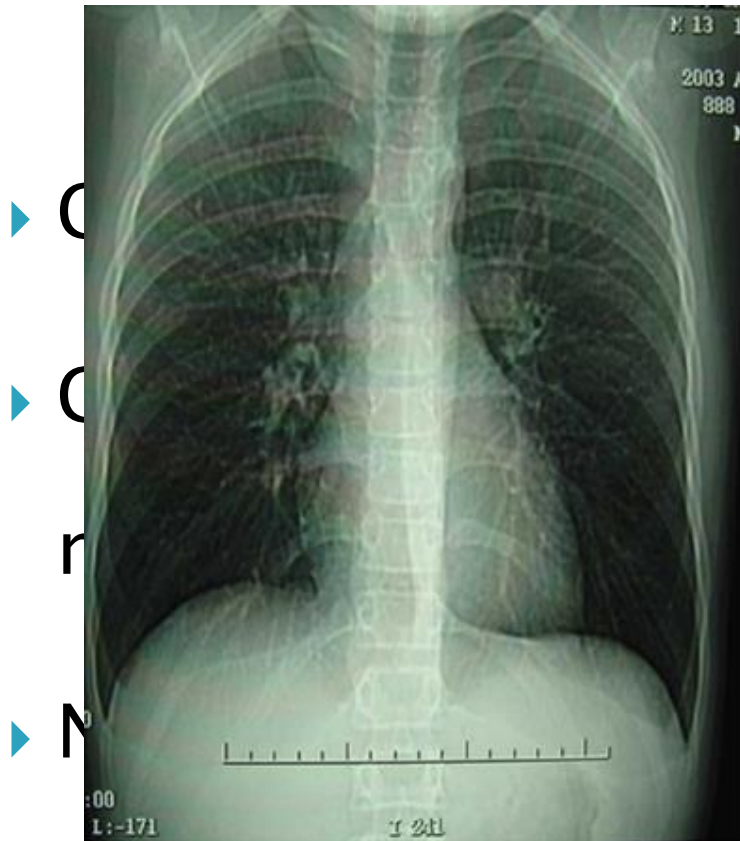
- ▶ Esophageal tumor — Advanced esophageal tumors may be identified on imaging as a mediastinal mass; however, the location and symptoms such as dysphagia, weight loss, and occult blood loss are not likely to be confused with lymphadenopathy or other middle mediastinal masses


Imaging Studies


- ▶ Contrast esophagram



Posterior Mediastinum

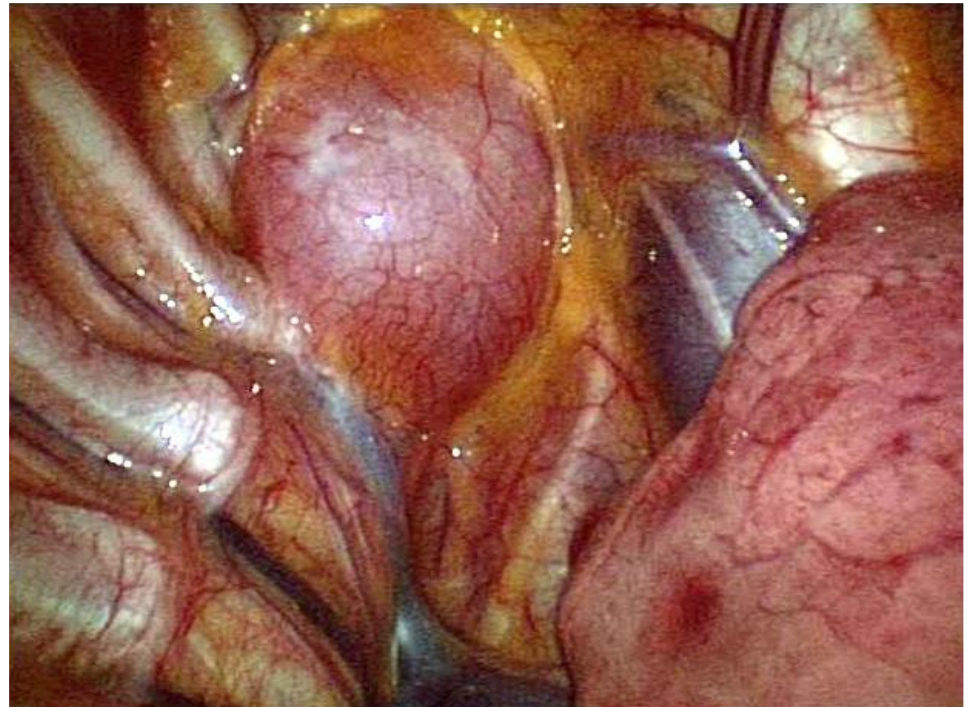


- ▶ Posterior mediastinum
 - ▶ Neurogenic tumors — Neurogenic tumors represent more than 60 percent of posterior mediastinal mass. These lesions are classified based upon their neural of origin.
 - ▶ ● Schwannomas and neurofibromas are benign lesions that arise from the intercostal nerve sheath and make 90 percent of adult neurogenic tumors.
- 

- ▶ ● Neuroblastomas and ganglioneuroblastomas are **malignant** tumors that occur most commonly in children and originate from the sympathetic ganglia.
 - ▶ ● Ganglioneuromas are benign lesions that arise from the sympathetic ganglia and are most common in young adults.
- 

Posterior Mediastinum

- ▶ Ganglioneuroma
- ▶ Ganglioneuroblastoma
- ▶ Neuroblastoma



Posterior Mediastinum

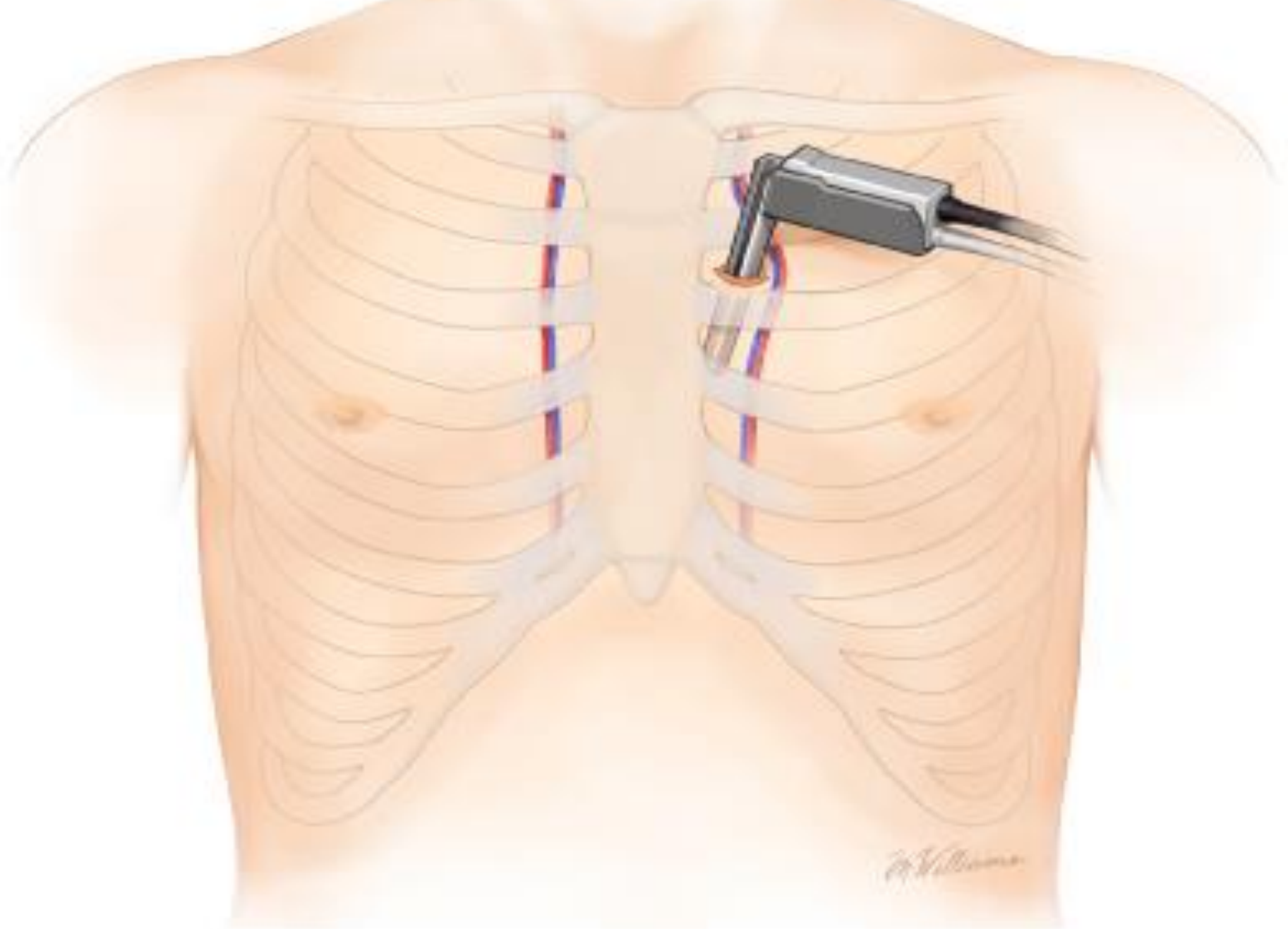
Neuroblastoma

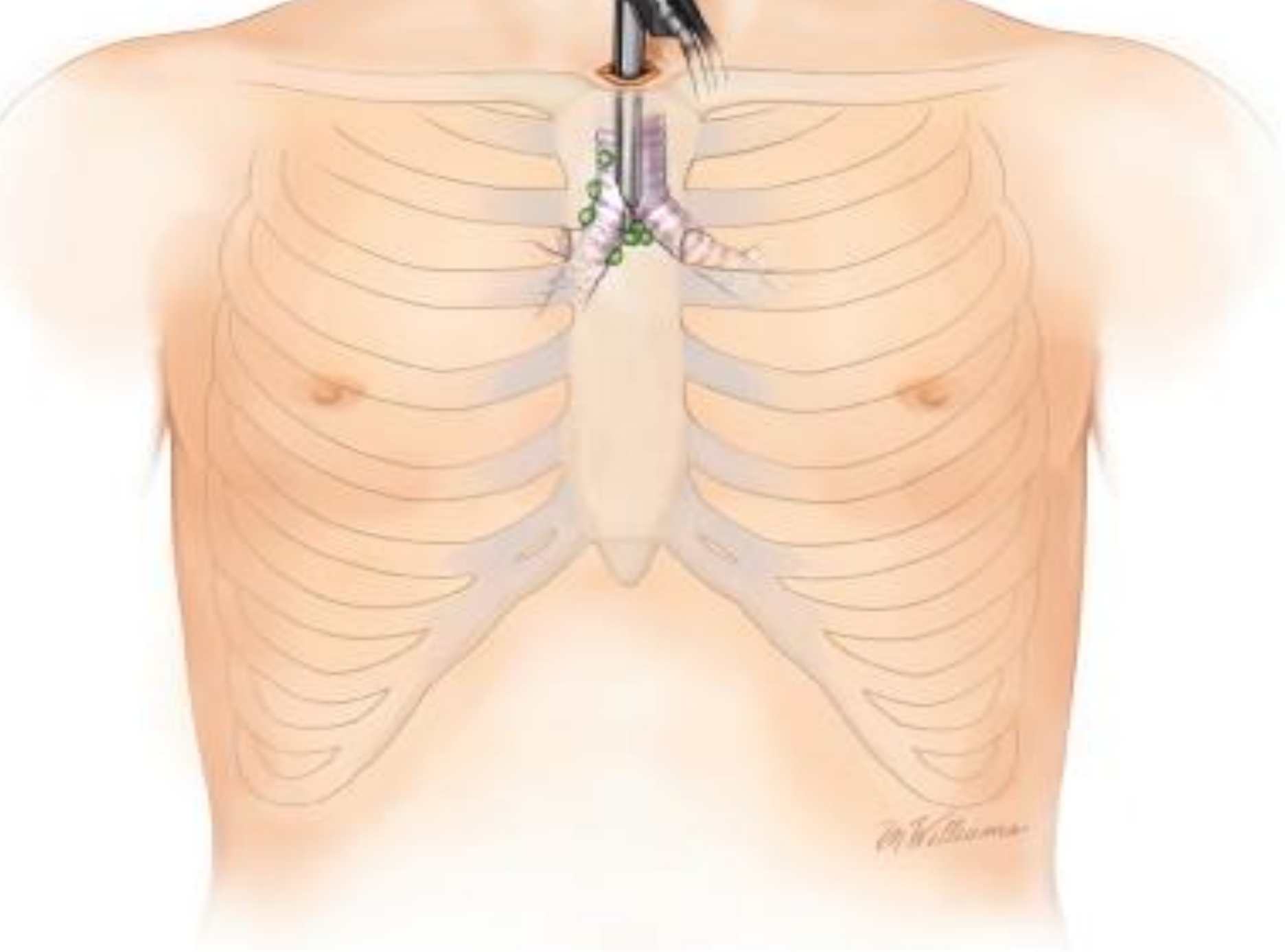
- ▶ Very good prognosis, especially Stage I & II

*Paraplegia implies compression of spinal cord (MRI & urgent laminectomy)

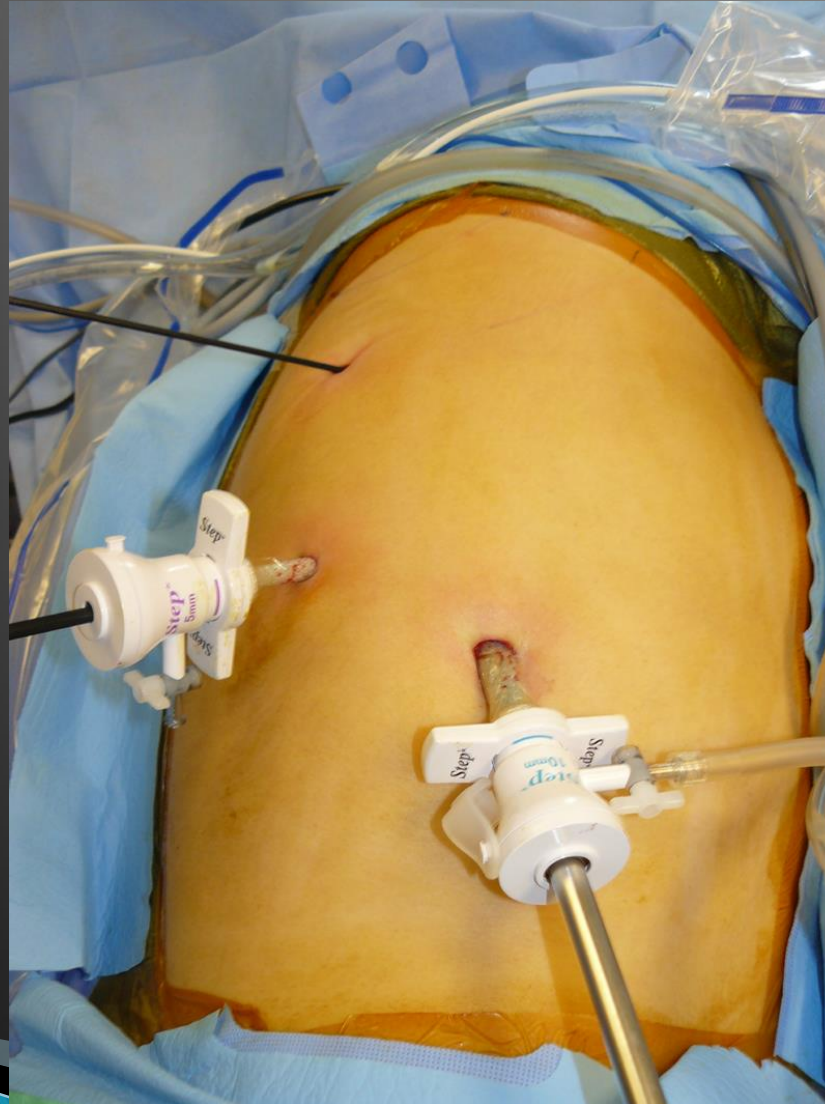SURGERY

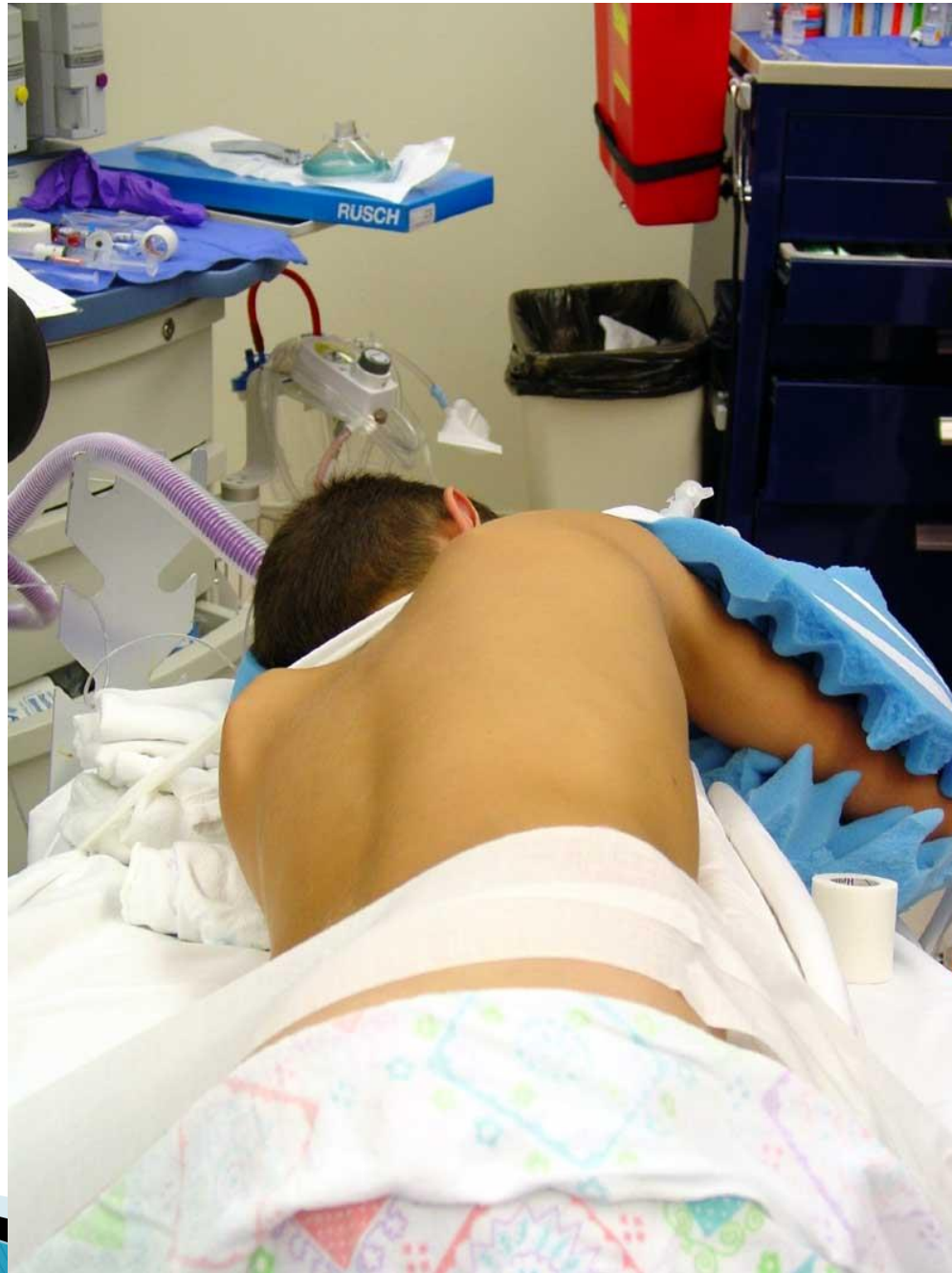
- **TWO TECHNIQUES:**
- **1. OPEN MEDIAN STERNOTOMY.**
- **2. VIDEO ASSISTED THORACOSCOPIC SURGERY (VATS)**
- The preferred approach is a median sternotomy providing adequate exposure of the mediastinal structures and allowing complete removal of the thymus,

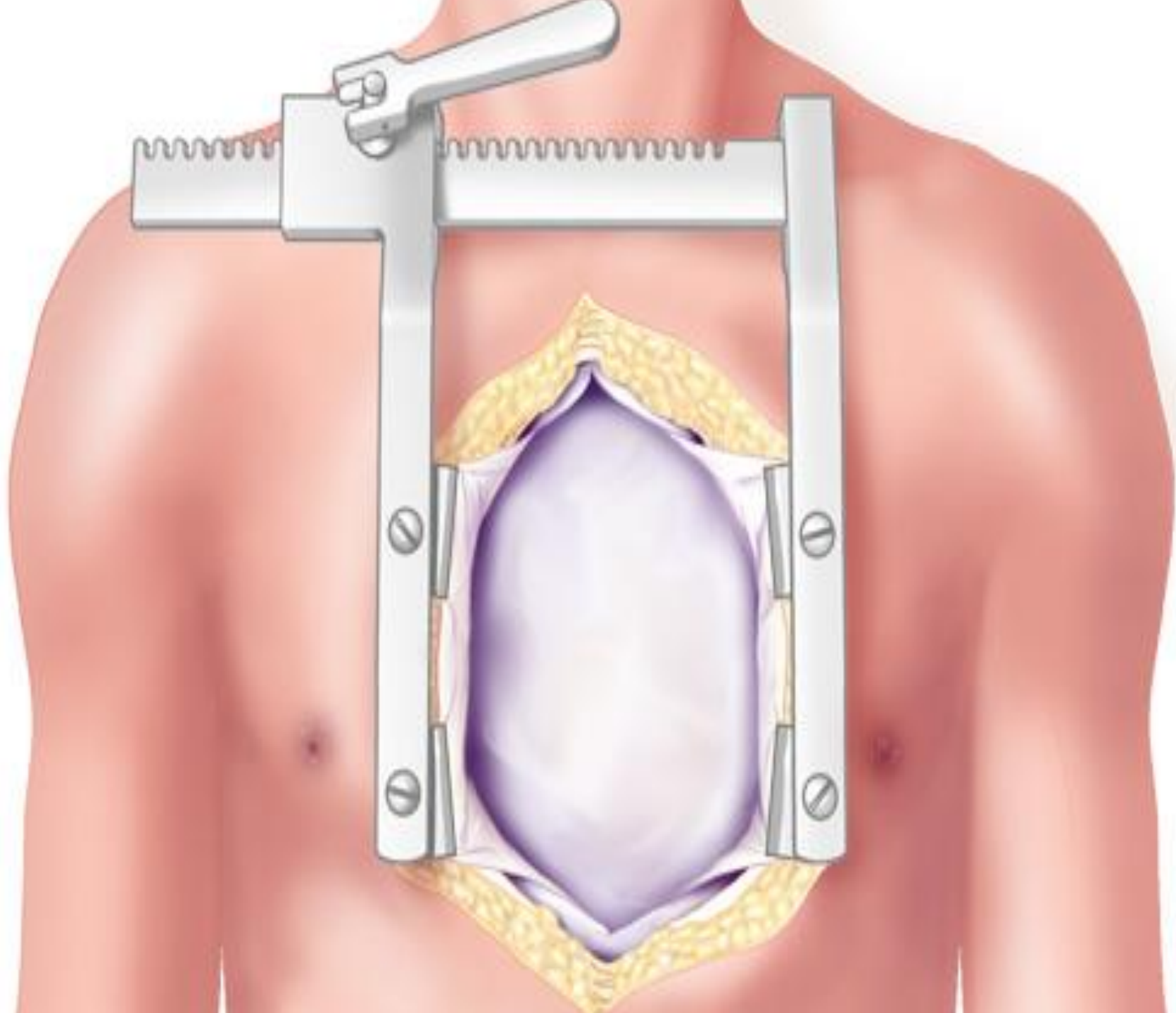


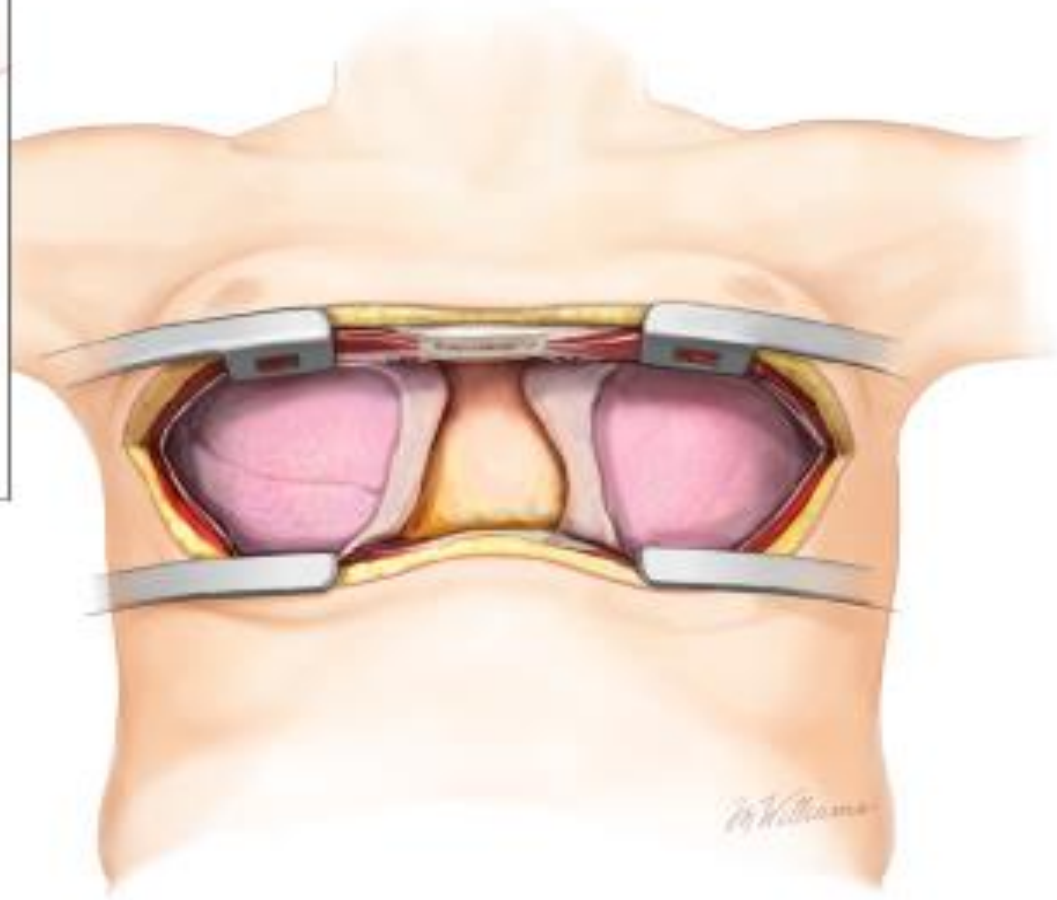
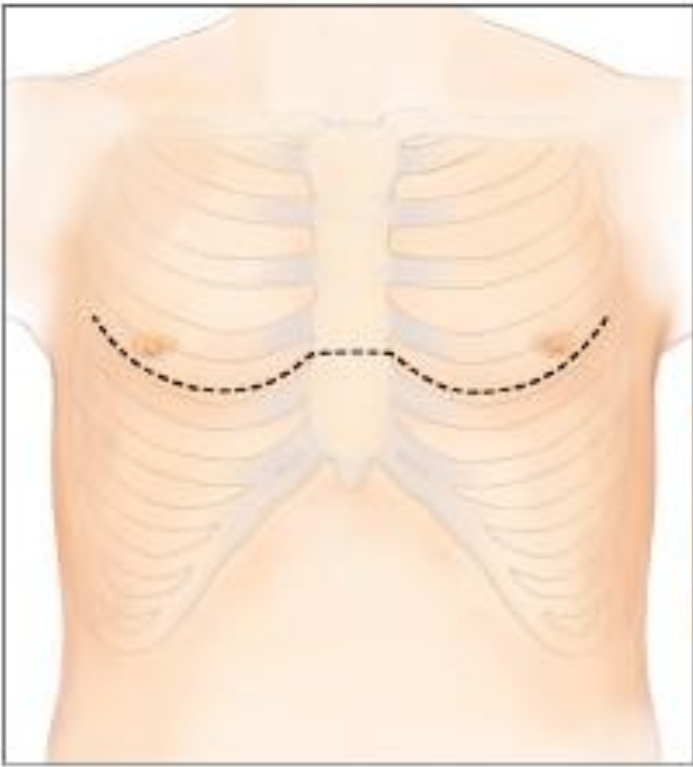


Lateral Decubitus Position









THANK YOU

