

# **RS , CVS , PVS EXAMINATION**

Done by : Adan nawaiseh

# Respiratory Physical Examination:

## General Resp. Examination

### 1) intro :

- 1) **HYGIENE** + warmth hand
- 2) introduce yourself + Permission
- 3) Privacy & chaperone → I have to insure privacy & chaperon if needed
- 4) warmth & illumination → there is a good lighting & warmth  
→ Good exposure from the neck to umbilicus, the patient is lying down 45° degrees on the bed.
- 5) position + exposure.

### 2) First impression :

- 1) Consciousness & alerte & orientation. (PPT)
- 2) Connected to ventilator or not → no ventilator + no medical devices.
- 3) in distress / breathlessness / in pain. → Pt not in distress, pain & breathlessness
- 4) use of accessory muscles for breathing
- 5) Cyanosis
- 6) Horner's syndrome (ptosis & myosis) + pursed lips
- 7) Smell + listen (تعجب و استمع) → no special sounds + no strong odor.

### 3) **vital signs**:

- 1) BP & Pulsus paradoxus
- 2) RR
- 3) Temp
- 4) Pulse
- 5) BMI
- 6) O<sub>2</sub> Saturation

2 rate  
2 Sh  
① ②

### 4) hands :

2C 2P 3T muscle wasting

→ Cyanosis clubbing  
→ Temp  
→ Tenderness  
→ Tremor

⊕ tremors + wrist tenderness

- 1) Fine tremors.
- 2) Flapping tremors.

\* hands & dorsal aspect: ① no nail abnormality (yellow nail, cyanosis)

② Tar staining

palmer aspect: ① Temp, sweat

\* Clubbing

② Muscle wasting → Pancoast tumor

③ palmer erythema → CO<sub>2</sub> retention

5] Face: (2 \* 2 \* 2)

1] Face = a) Facial swelling.

b) plethora.

2] eye = a) jaundice.

b) Conjunctival pallor + edema.

3] mouth = a) Central cyanosis.

b) Dental hygiene.

6] Neck:

1] inspection: a) Dilated veins.

SMV

b) Masses.

c) scars.

2] Palpate for lymph nodes.

3] Examine for JVP.

## Chest Examination

1] inspection:

\* From the foot of the BED

① Breathing → Abdomino-thoraco / thoraco-abdominal / tachypnic / Kussmaul

② Expansion → Bilateral symmetrical chest movement

③ Deformities → Pectus excavatum / Carinatum / Kyphosis / Scoliosis / barrel chest

④ nipple in line → nipples are in line

⑤ Pemberton Sign → For SVC

## ⊕ From the right side & SMYH

- extra
- ① Accessory muscle use.
  - ② Scars + masses + visible vein
  - ③ Hair distribution + skin marks or spots

## ② Palpitation & (لاثاني الفرج)

- ① comment - I have to maintain eye to eye contact.
- ② Warm your hand
- ③ فياشي بوجبات

### ① Superficial palpitation &

- Tenderness, mass
- Subcutaneous emphysema

Don't forget  
Axilla + Apical lunges

### ② TVF (44) & → Bilateral Symmetrical Normal TVF,

### ③ Mediastinum & → مكان اذ الفل

- (a) upper & → tracheal Deviation. → Trachea is centrally located
- Cartico-sternal Distance. → 3 fingers - 4 cm.
  - Tracheal Tug → No tracheal tug.

trachea

heart

- (b) lower & → apex beat → apex beat is gently tapping, 5<sup>th</sup> ICS, MCL
- Right ventricular heave → no Rt. v. h

### ④ Chest expansion &

→ grab lower part of the thorax & under it with both of your hands. **Bilateral Symmetrical Chest Expansion**

## ③ Percussion &

NOTE = Don't forget Axilla & Apex of the lungs. → Bilateral Symmetrical Resonance note.

extra = " " Liver Dullness liver dullness in Rt. 5<sup>th</sup> intercostal at MCL.

## ④ Auscultation &

ليس في لثاني

- ① Breathing → normal symmetrical vascular Breathing. Normal air entry, **no added sound.**
- ② Vocal Resonance (44) → " " Vocal Resonance. Tactile → ابيته بالتقول
- ③ Aegophony (EEEE) → No aegophony. R. Percussion
- ④ Whistling pectoriloquy (12345) → No whistling pectoriloquy.

# CVS physical examination:

## General CVS examination:

### [1] intro &

[1] introduce yourself + Permission

[2] **HYGIENE**

[3] Privacy & chaperone

→ I have to insure privacy & chaperone if needed

[4] warmth & illumination  
Position + exposure.

→ there is a good lighting & warmth  
→ Good exposure from the neck to umbilicus, the patient is lying down 45° degrees on the bed.

### [2] First impression:

[1] Consciousness & alerte & orientation.

[2] in distress / breathlessness / in pain. → Pt not in distress, pain & breathlessness

[3] Cyanosis, Pallor, Jundice.

extra: Horner's syndrome (ptosis & myosis).

medical devices

### [3] **vital signs:**

① Temp ② RR ③ BMI

### [3] hands:

#### ⊕ inspection:

① nails = Clubbing, splinter hemorrhage, prethral cyanosis.

② tar stain & tendon xanthomata. + prethral rash.

③ Osler's nodes (painful) & Janeway lesions (painless).

Extra = fine & flapping tremor.

#### ⊕ palpation:

① Palmer aspect = Temp, sweating

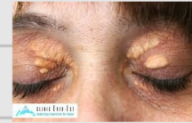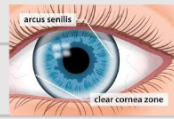
② Capillary refill → normal capillary refill

CC TT XP → prethral rash  
↓  
Goswami → capillary refill

### [3] face :

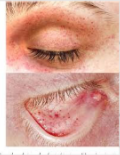⊕ eye = ① signs for hyperlipidemia:

Corneal arcus, xanthelasma



② signs of anemia:

Conjunctival pallor



⊕ ③ signs of infective endocarditis

retinal hemorrhage, Roth spot

→ I need fundoscopy to check for Roth spot

④ sign of jaundice: yellowish discoloration.

⊕ mouth: → Central cyanosis + dental caries

⊕ cheek: malar flush. → mitral stenosis.

### [4] Pulses:

→ Radial artery → lateral to tendon of flexor carpi radialis.

① Pulse (Rate, Rhythm, Pulse deficit) → normal rate, regular rhythm, no pulse deficit

② Collapsing pulse → no collapsing pulse

③ radio-radial symmetry → no Radio-Radial asymmetry, I have to check R-femoral delay.

→ Brachial artery: → cubital fossa, medial to biceps tendon.

① Rate, Rhythm

② Volume, compressibility → normal volume, Compressible.

③ character → no slow rising pulse, Pulsus

bisferiens

alternans

Paradoxus

→ Carotid artery: → ant. border to SCM muscle

① Puls

② listen for bruits → There is no bruits, bruey

→ I have to check Femoral, Popliteal, Post. tibial, Dorsalis pedis artery.

### [5] Jugular venous pressure:

\* inspection → Diffuse inward movement (ص) 2 wave per pulse (سین تک، راسن (آبجی اقلاب))

\* palpation → impalpable.

\* JVP high → (ص + 5 cmH<sub>2</sub>O).

\* special maneuvers →

• varies with respiration. (inspiration ↓ JVP)

inspiration → ↓ JVP, BP ↑ HR

النبض مع التنفس

• Compression on the root of the neck → ↓ JVP

• Sitting ↓ JVP

- Abdominojugular reflux. ↑
- Ask pt to lie flat. ↑ JVP

# Precordium Examination

## ① Inspection

\* From the foot of the bed &

- ① B = Breathing Pattern
- ② E = symmetry, move with respiration → symmetrical chest movement.
- ③ Deformities: pectus excavatum & pectus carinatum.

\* From the right side: (Don't forget Lateral (Axilla))

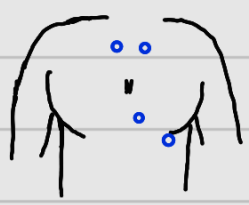
- ① scars → midline sternotomy / left submammary / infraclavicular scars.
- ② Mass & Dilated vein SMVH
- ③ Body hair distribution.
- ④ visible pulsation & apex beat

## ② Palpation (لا تلمس بشئ الحرج)

- ① General palpation → no tenderness & subcutaneous mass.
- ② apex beat = B on your eye
  - ② on your hand ⇒ Apex beat is gently tapping, 5<sup>th</sup> ICS, MCL.
- ③ Vent. heave (طبع نفس وامس)
  - LUH
  - RUH
- ④ thrills (3 Places)

## ③ Auscultation & Carotid Pulse = طوق العنق و ابي على

- ① 4 area [diaphragm + bell] → normal S<sub>1</sub>, S<sub>2</sub>, normal physiological splitting, no S<sub>3</sub>, S<sub>4</sub>
- ② Radiated murmurs
  - Carotid (خذ نفس وامس) → no radiation of AS. ASMR
  - Axilla → no radiation of MR
- ③ Murmurs
  - Mitral stenosis [only = bell / نصف مالك]
  - Aortic regurg [Aortic area + Erb's area] بين رقبة، خذ نفس و طعنة وامس



④ lung for basal crackles + Sacral edema.

⑤ I have to check for lower limb edema + hepatosplenomegaly + ascites

## PVD Examination

### 1] HYGIENE

② introduce yourself + Permission

③ Privacy & chaperone → I have to insure privacy & chaperon if needed

④ warmth & illumination → there is a good lighting & warmth

⑤ position + exposure.

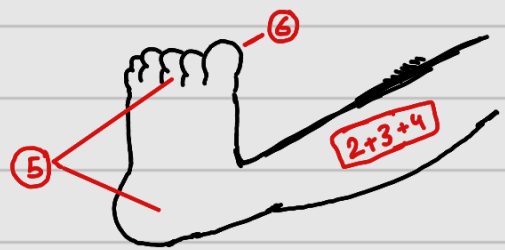
## vital signs:

① Temp ② RR ③ BME

### 1] inspection &

on front of the Bed: (Ant + Post + Lateral)

- ① normal Bilateral symmetrical, no Deformity
- ② Scar, mass, Dilated vein, hair Distribution SMV + hair. Dis
- ③ discoloration, shiny skin
- ④ swelling, Muscle wasting
- ⑤ ulcer, fungal infection
- ⑥ onycholysis, Brittle nails, Clubbing finger



### 2] Palpation & (warming + eye to eye + خیاتی بوجیدن)

① Temp → normal Bilateral symmetrical Temp.

② Superficial palpation + squeeze muscles → Good Bulk, no tenderness

③ Pulses

- Femoral + Popliteal
- Post. Tibial (medial mal)
- Dorsalis pedis (Extensor hallucis longus)
- Ankle - Brachial Pressure index (ABPI)

← ادیکھا مجھ ذی

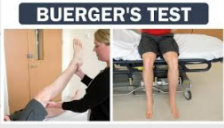

### [3] special Test :

① leg Circumference (10cm below tibial tuberosity)

② edema of leg & ankle (3 places by thumb at tibial shin & above medial malleolus)

③ Capillary refill : → normal capillary refill.



④ Burger's test : برقع رجليه ويبستار بعد ما → Pallor, venous guttering.

بنزليها ويطلب من يوقف → Reactive hyperemia.

⑤ بطلب منه يوقف : → Swelling, discoloration, Scar, mass.

⑥ Trendelenburg

[4] Auscultation & Femoral bruits.



if u have aquestion,  
feel free to text me :).