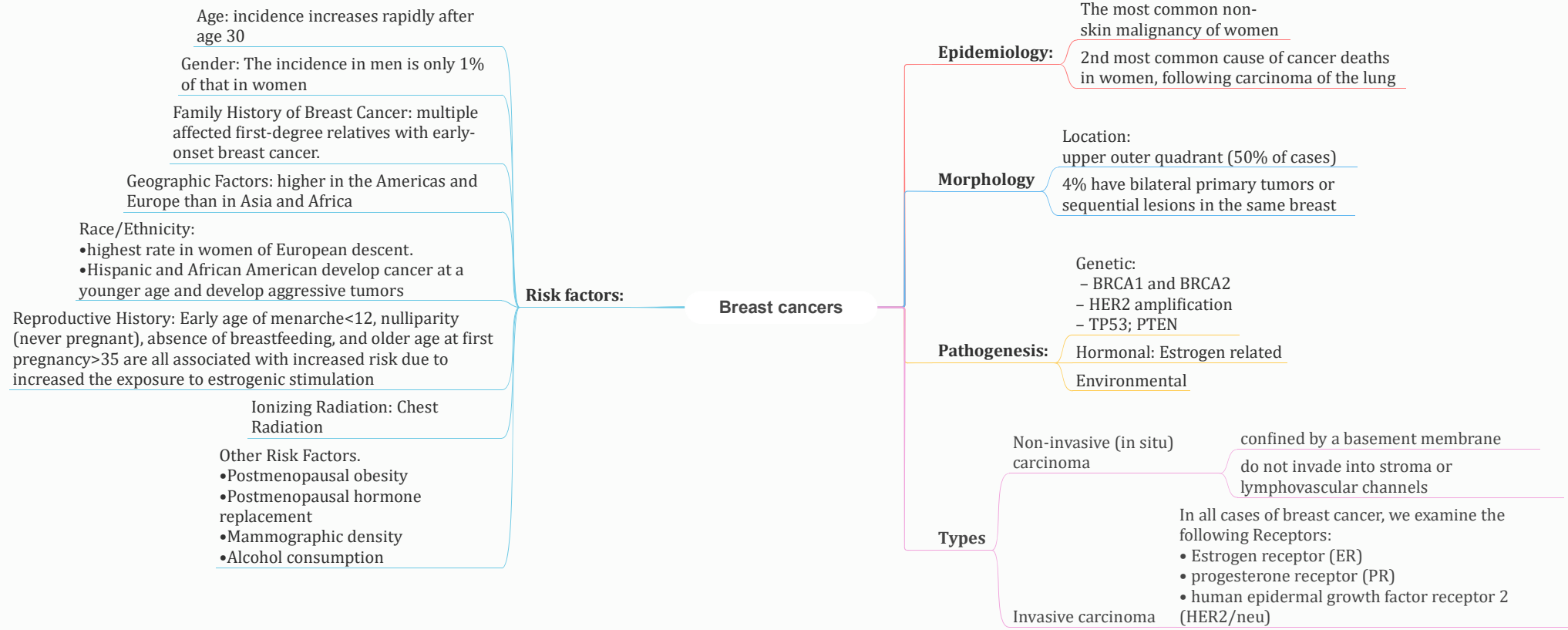

Noninvasive Carcinoma

Lobular carcinoma in situ

Malignant clonal proliferation of epithelial cells within ducts and lobules

Proliferation takes an appearance resembling lobules

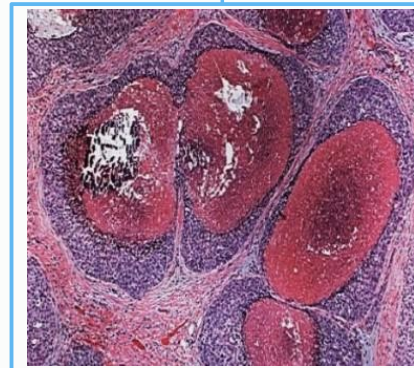
Acquired loss of E-cadherin

Cells grow in a discohesive fashion

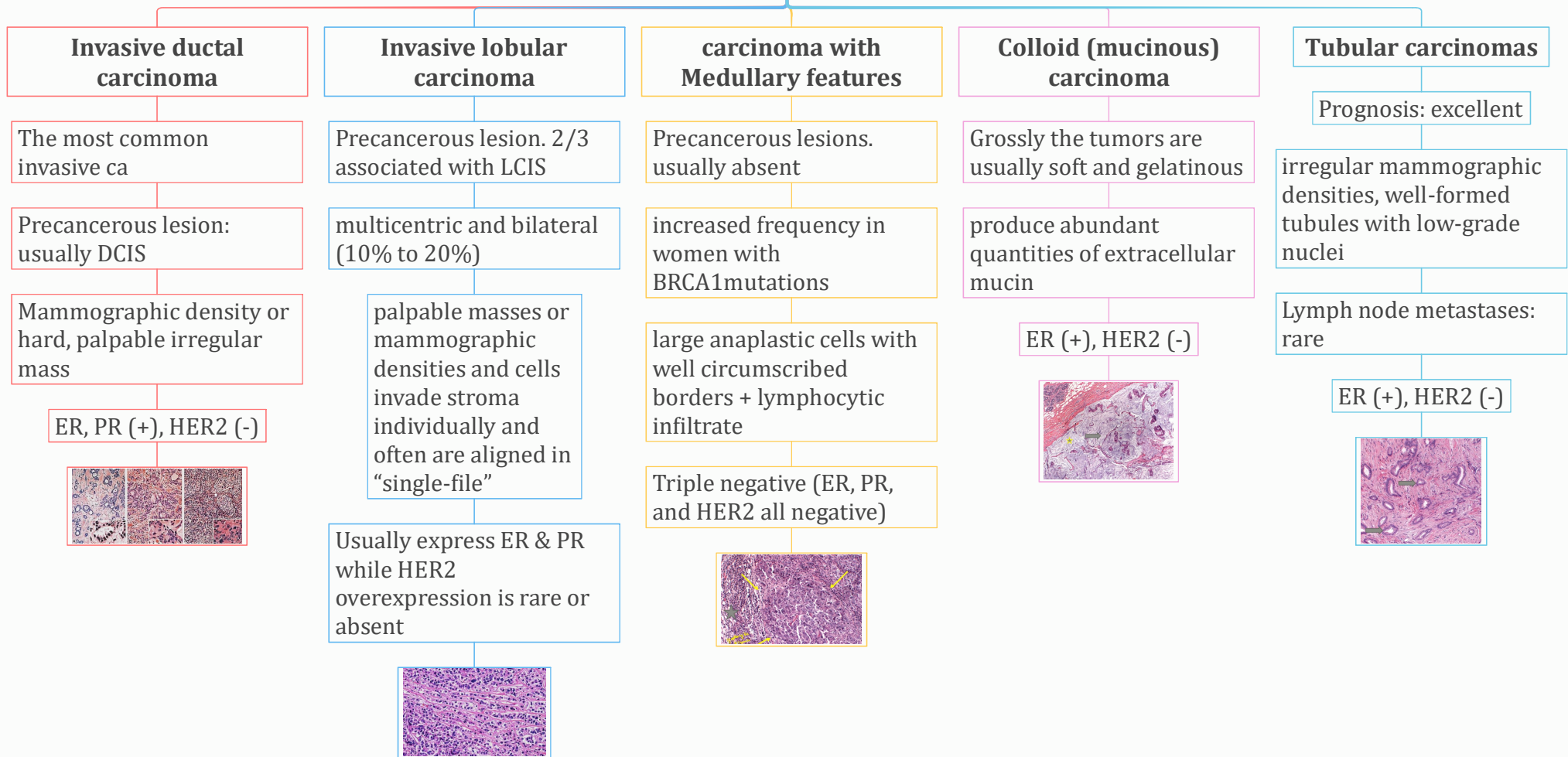
Ductal carcinoma in-situ

Malignant clonal proliferation of epithelial cells within ducts and lobules

Histologic appearances including: solid, comedo, cribriform, papillary, and micropapillary



Invasive carcinoma



Features Common to All Invasive Cancers:

- **Fixation:** adherent to the pectoral muscles or deep fascia of the chest wall
- **retraction or dimpling of the skin or nipple:** adherence to the overlying skin
- **peau d'orange (orange peel):** Involvement of the lymphatic pathways cause localized lymphedema, the skin becomes thickened and exaggerated around hair follicles

Breast cancers

Spread

through lymphatic and hematogenous channels

Favored mets are the bone, lungs, skeleton, liver, and adrenals and (less commonly) the brain, spleen, and pituitary

Metastases may appear many years after therapeutic control of the primary lesion

Screening

mammographic screening

MRI

Prognosis

Tumor stage

Invasive carcinoma versus carcinoma in situ

tumor size

Lymph node involvement and the number of lymph nodes involved by metastases

Distant metastases

Histologic grade

histologic type of carcinoma

Lymphovascular invasion

estrogen or progesterone receptors expression

Overexpression of HER2

the importance of evaluating HER2 s to predict response to a monoclonal antibody ("Herceptin") against the gene product