



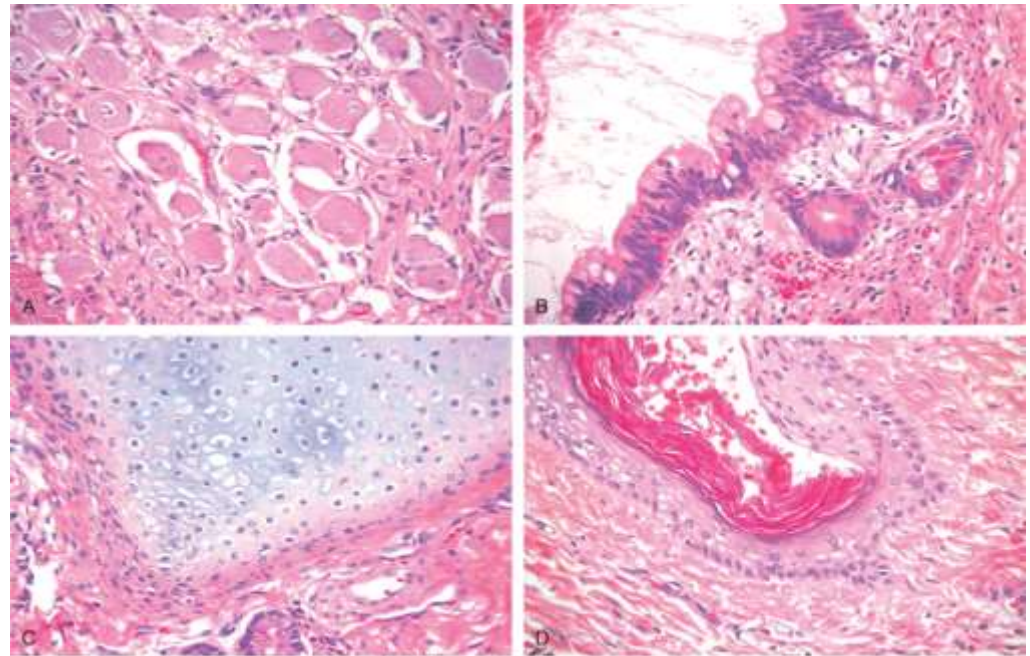
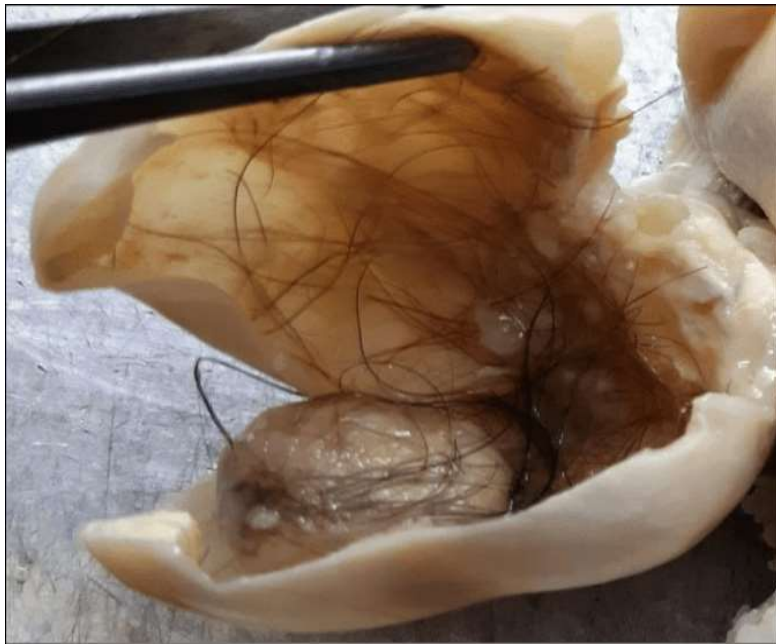UGS 2023

Pathology of The Female Genital Tract

Practical Questions

Dr. Nisreen Abu Shahin
Associate Professor of Pathology
University of Jordan

Note: check with Dr. Maram for the practical pathology questions in breast pathology lectures



Kumar et al: Robbins Basic Pathology, 9e.
Copyright © 2013, by Saunders, an imprint of Elsevier Inc.

- A 20-year-old female presented with vague left pelvic pain. Pelvic exam revealed a large adnexal mass. Ultrasound showed a large, heterogenous, cystic mass replacing much of the left ovary. The contents of the cystic mass included hair, sebaceous material and a tooth. What is your diagnosis?

- **Mature cystic teratoma**

- What is the expected clinical behavior of this ovarian tumor? **Benign**

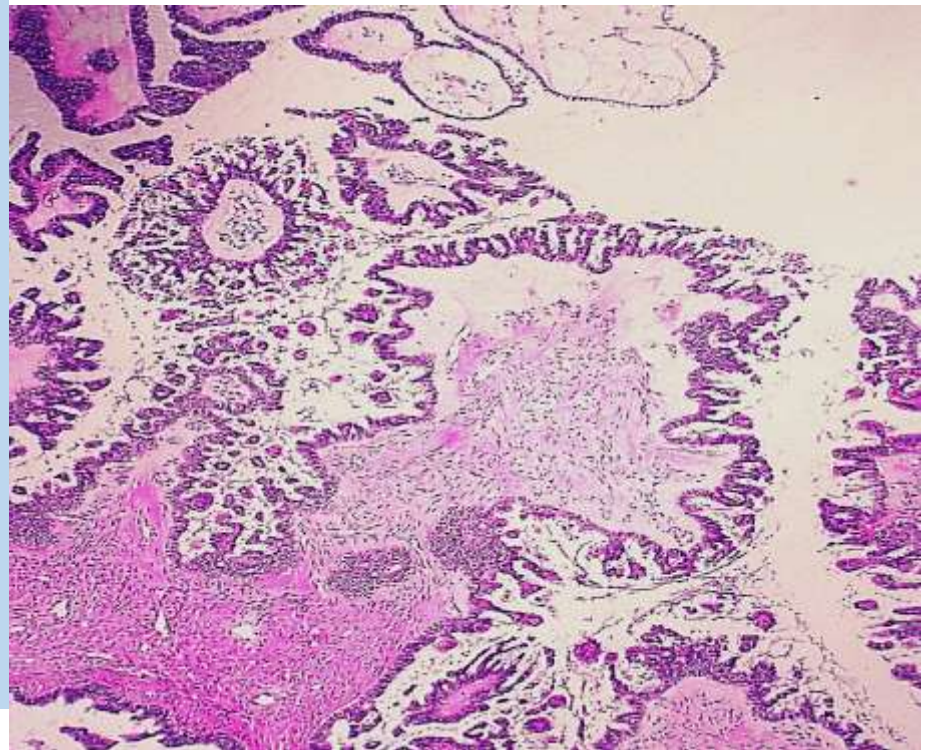
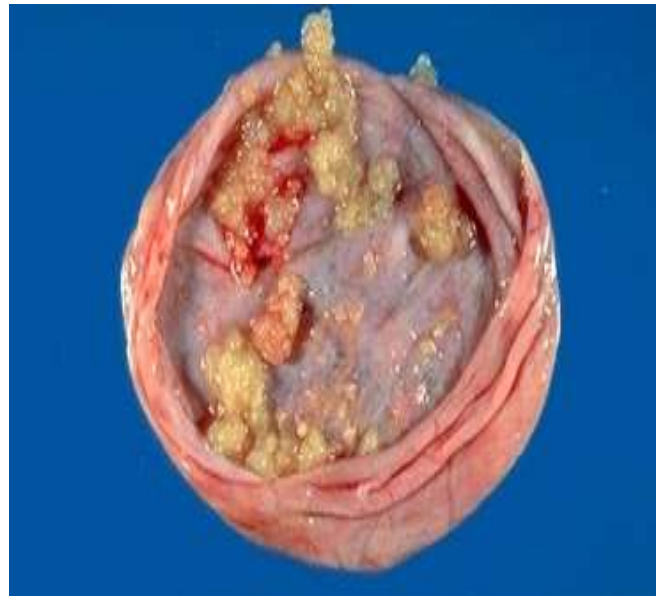- What is the key microscopic feature of these tumors? **Mature tissues from all types**

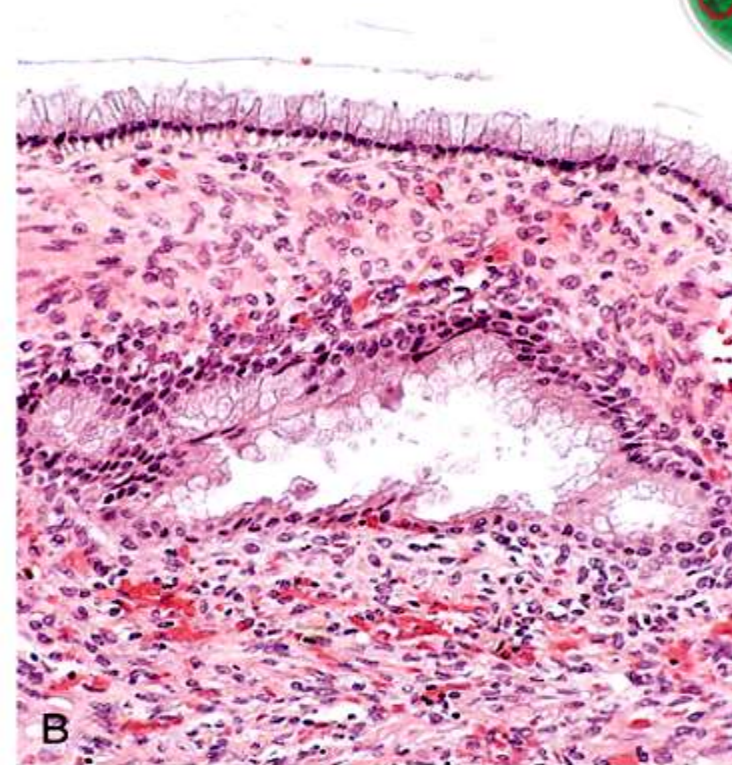
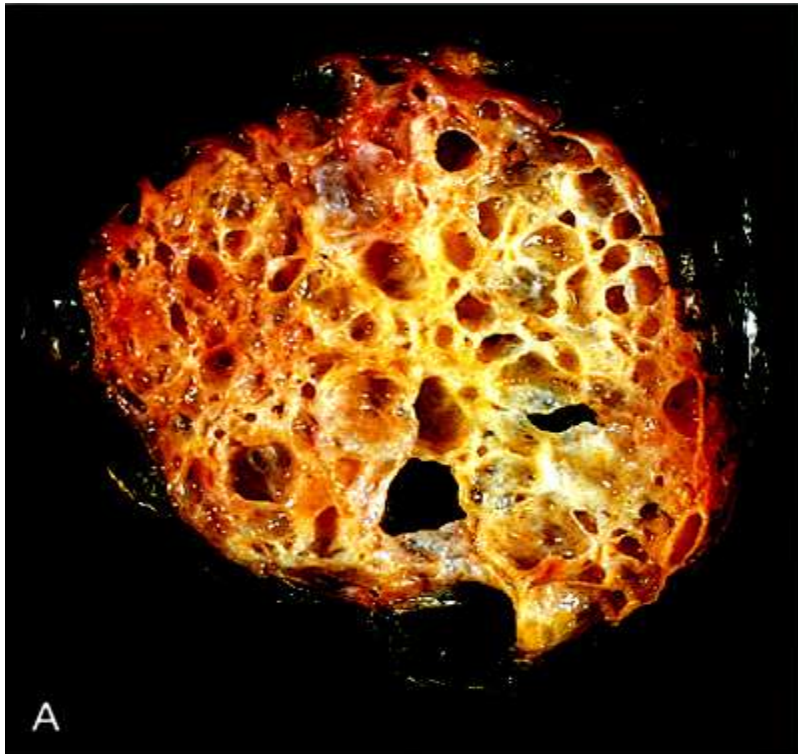


- A 36 y/o woman complained of pelvic pain, her U/S examination in clinic revealed a unilateral right ovarian cystic mass. Grossly, the cyst has these projections on the surface and inside the cyst. It contained thin serous fluid. Shown here are sections from the mass. No stromal invasion is identified. What is your diagnosis?

Serous borderline tumor

- What are the microscopic features you see? **Complex papillae**





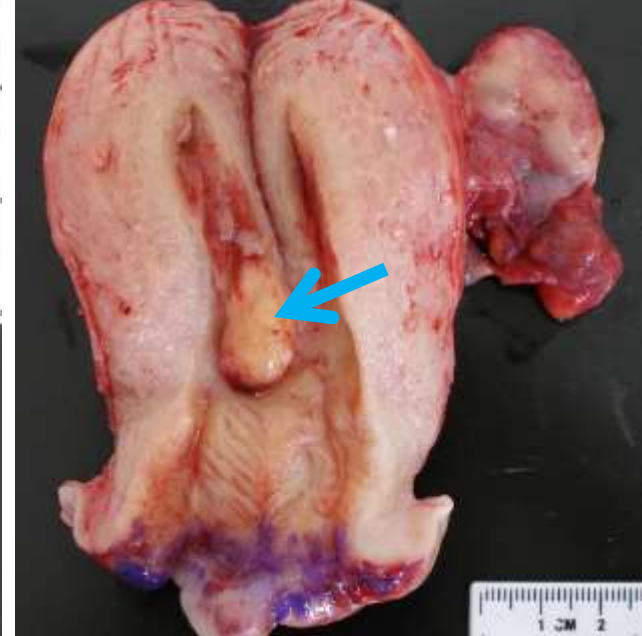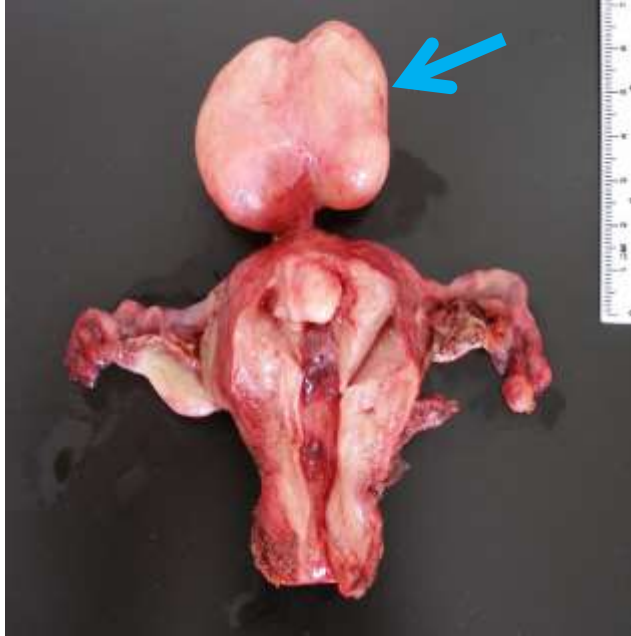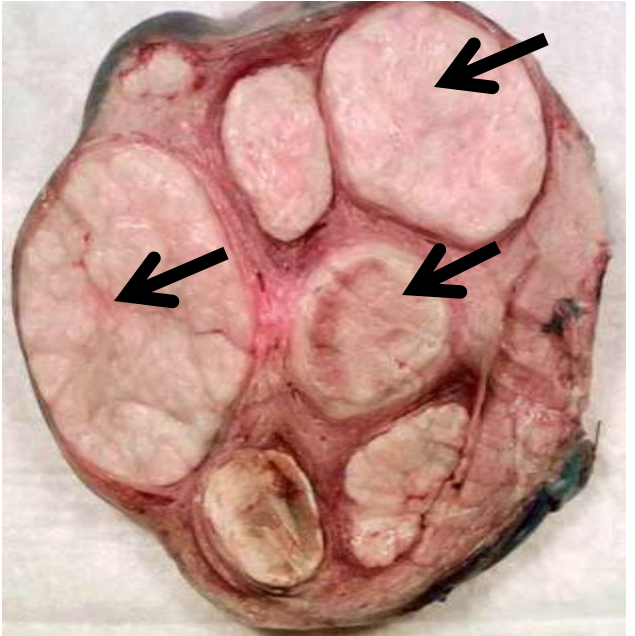
© Elsevier. Kumar et al: Robbins Basic Pathology 8e - www.studentconsult.com

A 43 year old lady complained of increased abdominal girth was found to have this huge 30x 20x 15 cm mass in left ovary. Picture A shows you how the mass looks from inside. Picture B reveals the characteristic microscopic appearance of the tumor cells.

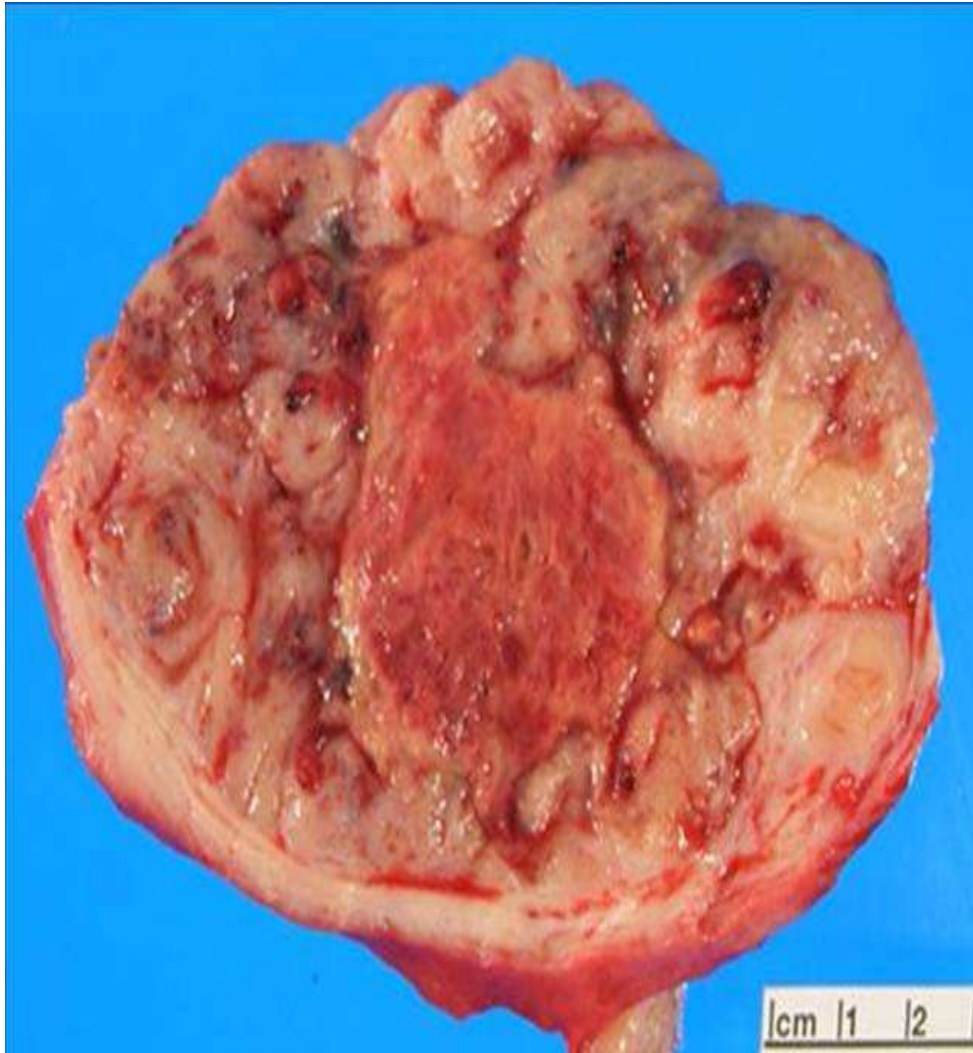
- Describe the macroscopic appearance of the tumor. **Multilocular**
- What do these cells contain in the cytoplasm? **Mucin**
- What is your diagnosis? **Mucinous cystadenoma**



Uterine leiomyoma



- what are the myometrial lesions you see in these pictures? **uterine leiomyoma (fibroid)**
- How common are (fibroids) leiomyomata ? **Very common**
- In what age group are they most prevalent? **Reproductive years**
- Are they malignant? **No**
- What are the presenting symptoms? **Menorrhagia, dysmenorrhea, ...**



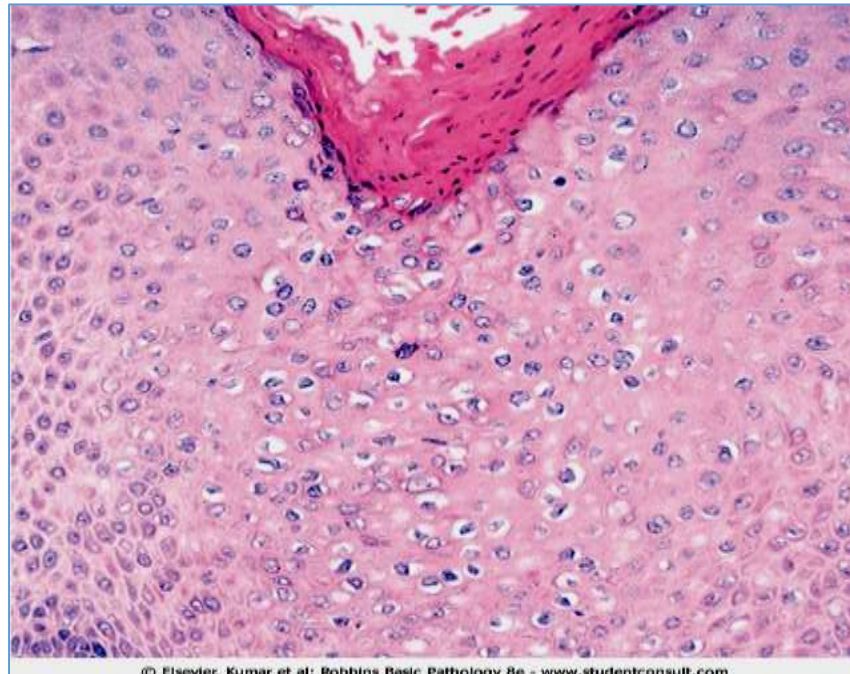
- A 57 year-old lady, presented to GYN clinic complaining of postmenopausal bleeding, and underwent hysterectomy. Cut section of the enlarged uterus showed this lesion. What is the likely diagnosis?

Leiomyosarcoma

- What features you see favor a malignant neoplasm? **Irregular invasive borders; hemorrhage; necrosis**

Vulvar pathology

HPV infection



© Elsevier. Kumar et al: Robbins Basic Pathology 8e - www.studentconsult.com

- Describe the most distinct microscopic feature of this vulvar lesion caused by low risk-HPV infection. **koilocytosis**

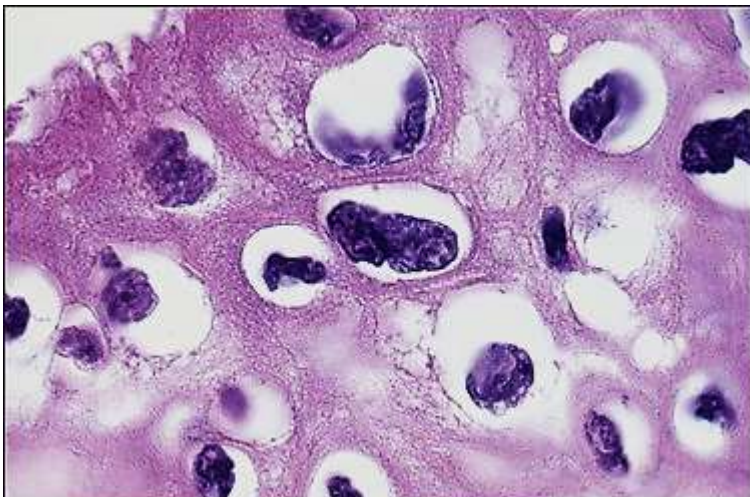
What is the name of the skin lesion?

condyloma accuminatum (genital warts)

- Do you see viral induced cytologic changes? **Yes**

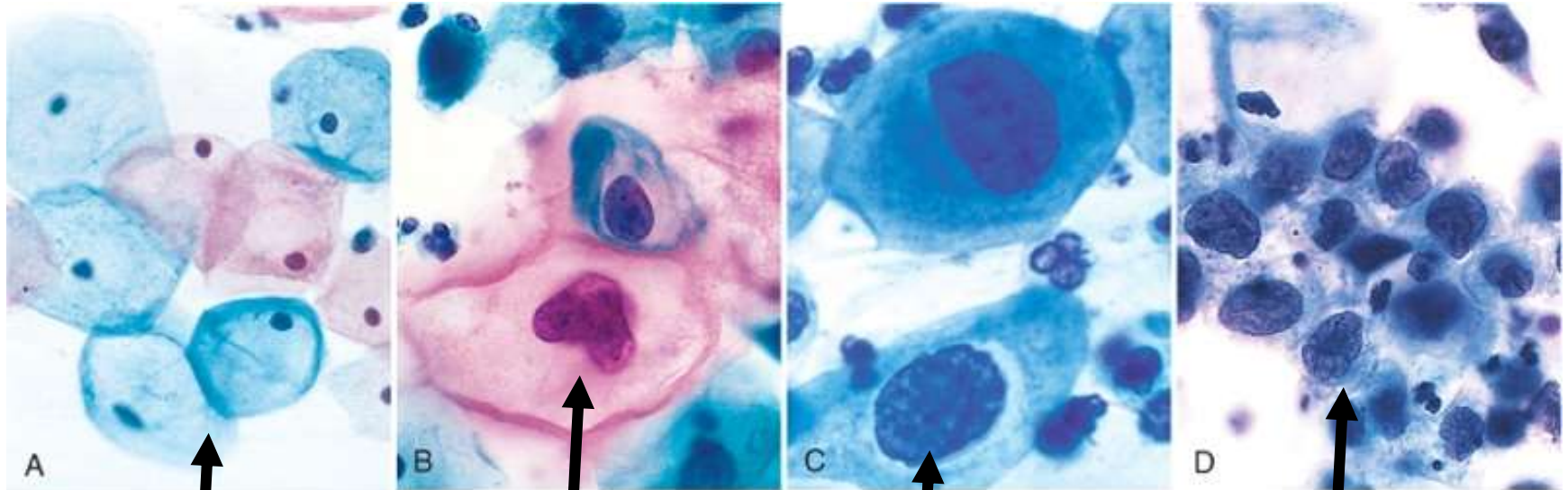
What are those cells called?

Koilocytes





Cervical Intraepithelial Neoplasia (CIN)



© Elsevier. Kumar et al: Robbins Basic Pathology 8e www.studentconsult.com

normal

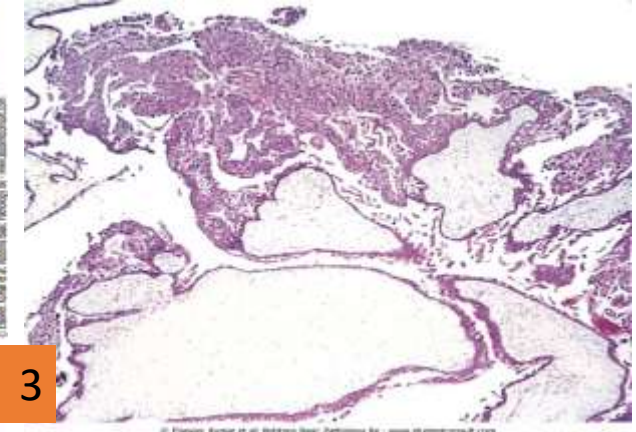
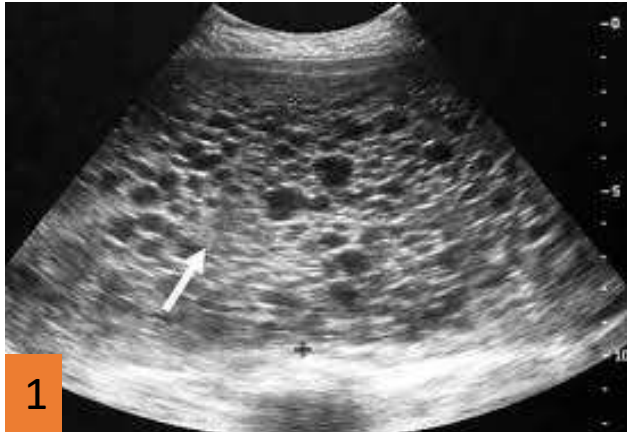CIN 1

CIN 2

CIN 3

The higher the grade of CIN; the higher the nuclear/cytoplasm ratio, the larger the nucleus, and the smaller the cytoplasm is.

Complete molar pregnancy



- A 22 year old lady who had a positive pregnancy urine test and went to a gynecology clinic for antenatal care. During her examination, identify the abnormality in the pictures:
- Picture 1: the **ultrasound** test **No fetus; vesicles and Snow storm morphology**
- Picture 2: She had in-hospital evacuation of **uterine contents**..... **vesicles**
- Picture 3: A sample **tissue** was sent to pathology lab for evaluation... **swollen edematous chorionic villi**
- What is your diagnosis???? **Complete Molar pregnancy**