


Neurodegenerative disorders-3

Manar Hajeer, MD, FRCPath
University of Jordan, School of medicine

Different diseases

- ▶ **Involving the cortex>>>> cognitive abnormalities of memory, behavior and language >>>> dementia >>>>>ALZHEIMER DISEASE (AD) , FRONTOTEMPORAL DEMENTIA (FTD), PICK DISEASE (SUBTYPE OF FTD)**
- ▶ **Involving the basal ganglia >>>>> movement disorders >>>>>hypokinesia (PARKINSON DISEASE) or hyperkinesia (HUNTINGTON DISEASE)**
- ▶ **Involving the cerebellum >>>> ataxia >>> (SPINOCEREBELLAR ATAXIA, Friedrich ataxia, ataxia telangectasia)**
- ▶ **Involving the motor system >>> difficulty swallowing and respiration with muscle weakness >> (AMYOTROPHIC LATERAL SCLEROSIS)**

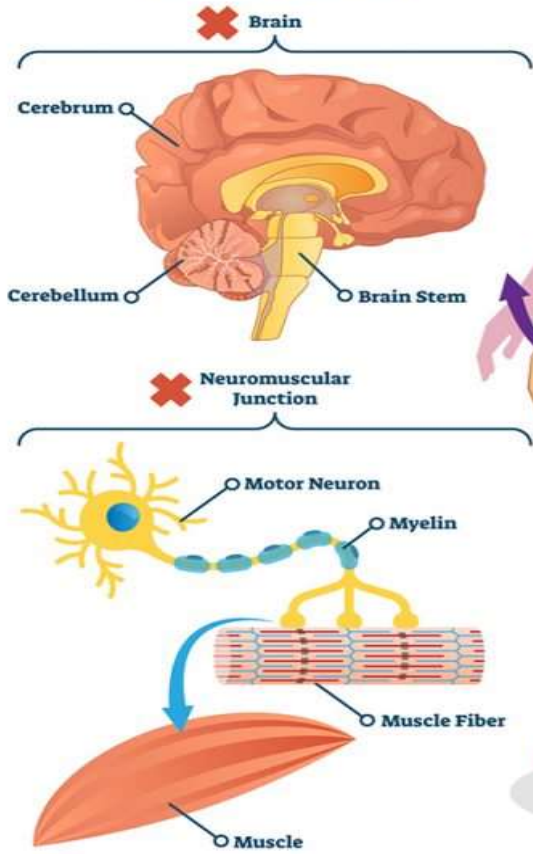
Spinocerebellar Ataxias

- ▶ **Heterogeneous group of diseases**, characterized by **cerebellar and sensory ataxia, spasticity, and sensorimotor peripheral neuropathy**.
 - ▶ Differ in causative mutations, patterns of inheritance, age at onset, and signs and symptoms.
 - ▶ Affects cerebellar cortex, spinal cord, other brain regions, and peripheral nerves variably.
 - ▶ Several forms of SCA are caused by CAG repeat expansions (like HD), causing intranuclear inclusions, among other mutations.
- 

ATAXIA

Ataxia is a Degenerative Disease of the Nervous System Consisting of Lack of Voluntary Coordination of Muscle Movements

ATAXIA is a Clinical Manifestation Indicating **DYSFUNCTION** of the Parts of The **NERVOUS SYSTEM** that **COORDINATE MOVEMENT**



ATAXIA SYMPTOMS



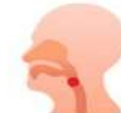Lack of Coordination



Eye Movement Abnormalities



Slurred Speech



Trouble Eating and Swallowing



Heart Problems



Tremors and Deterioration of Fine Motor Skills



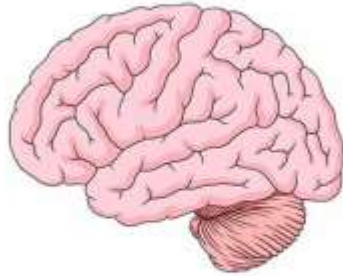
Gait Abnormalities



Difficulty Walking and Poor Balance

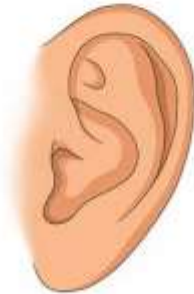Ataxia

Types of ataxia



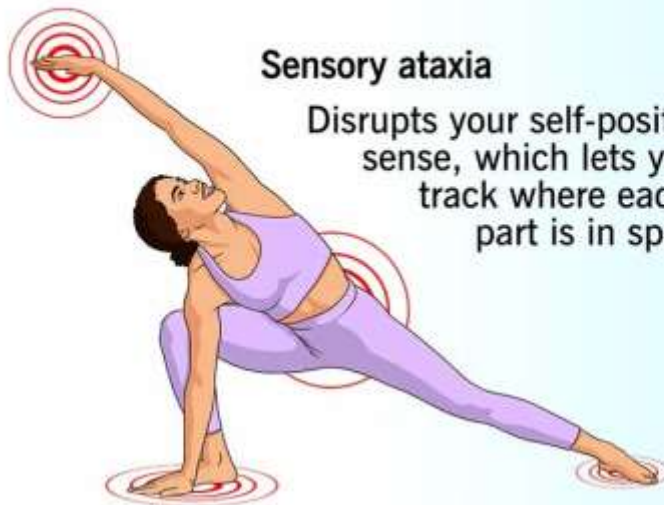
Cerebellar ataxia

Disrupts the part of the brain that manages how different parts of your brain work together.



Vestibular ataxia

Disrupts your sense of balance, so it is hard to coordinate how you move.

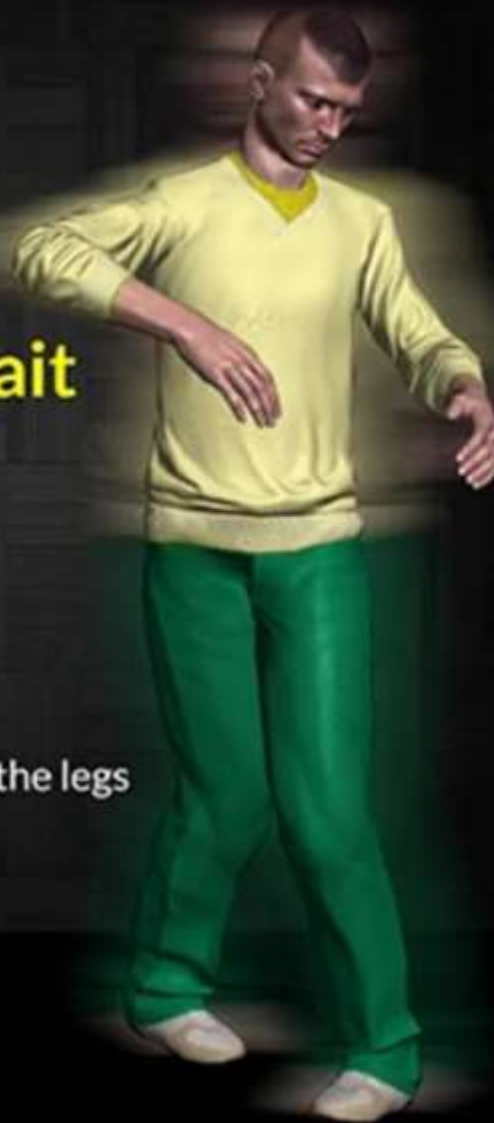

Sensory ataxia

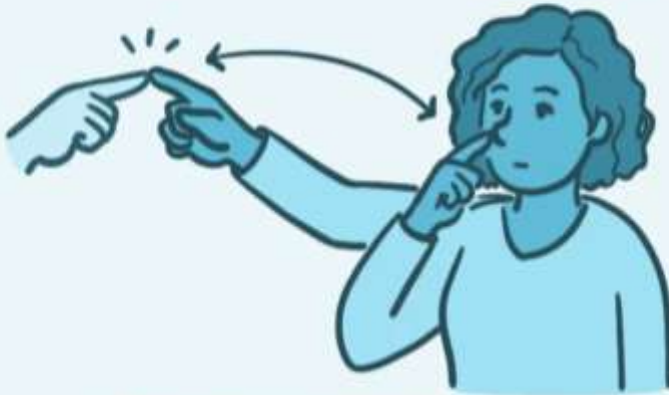Disrupts your self-positioning sense, which lets your brain track where each body part is in space.

Symptoms Of **Ataxic Gait**

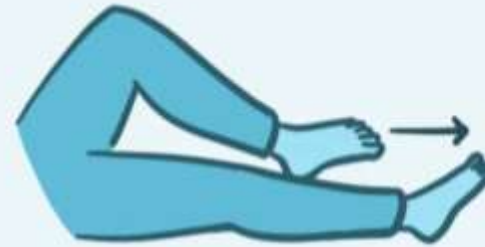- Lack of proper coordination
- Unsteady gait with a potential to stumble and fall
- Frequent falling episode
- Lack of muscle coordination in the legs
- Ambulation difficulties



DIAGNOSTIC TESTS




FINGER to NOSE TEST

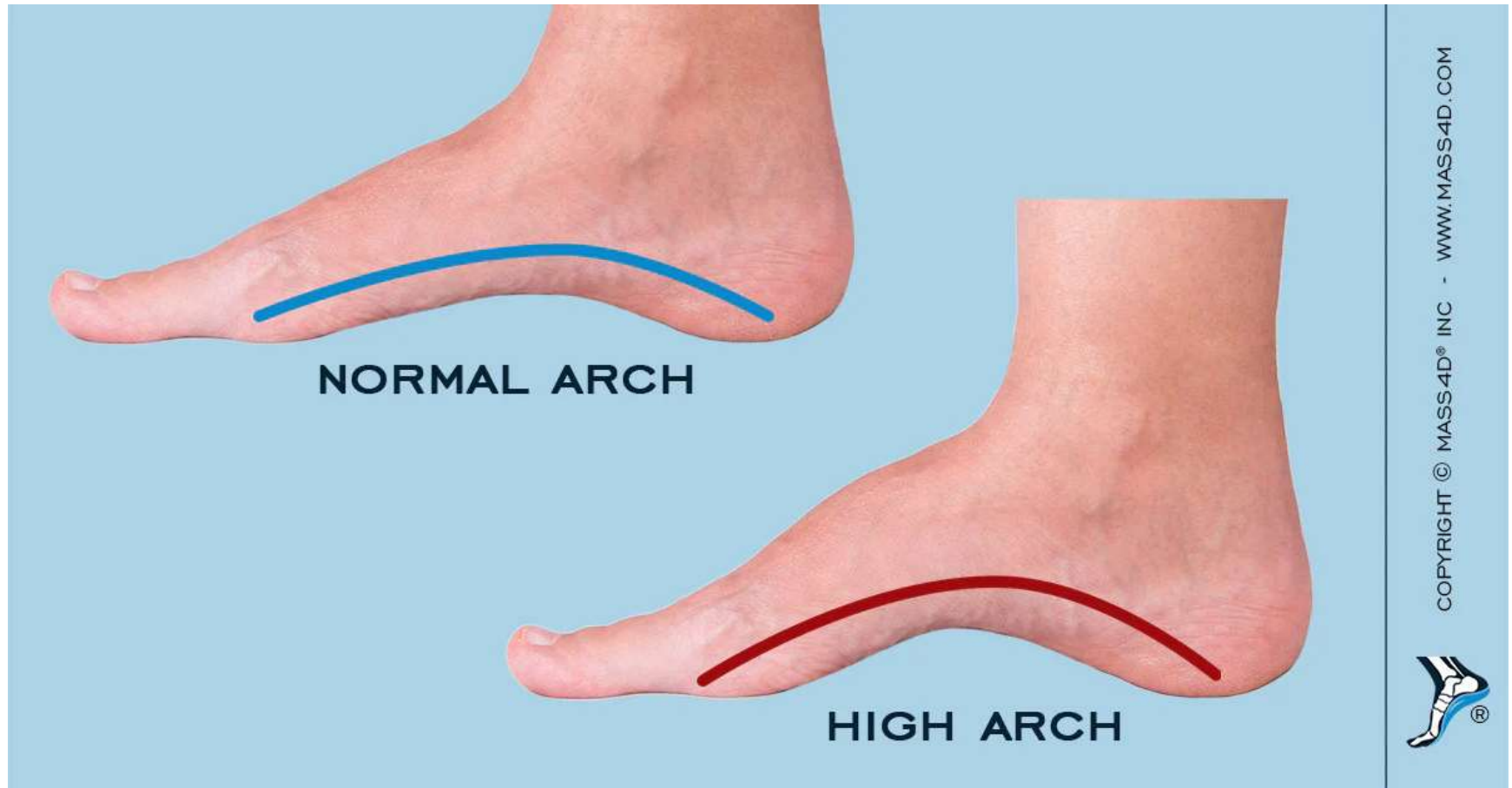


HEEL to SHIN TEST

Friedreich ataxia

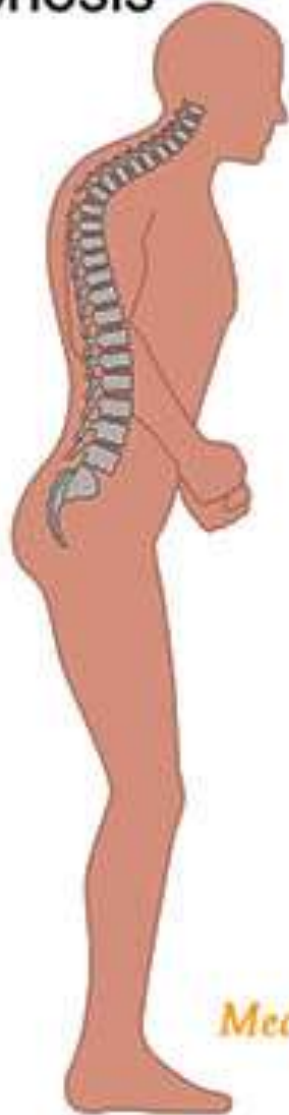- ▶ Most important SCA.
 - ▶ Autosomal recessive disorder.
 - ▶ First decade of life.
 - ▶ Gait ataxia, followed by hand clumsiness and dysarthria.
 - ▶ Pes cavus and kyphoscoliosis.
 - ▶ High incidence of cardiac disease and diabetes.
- 

Pes cavus

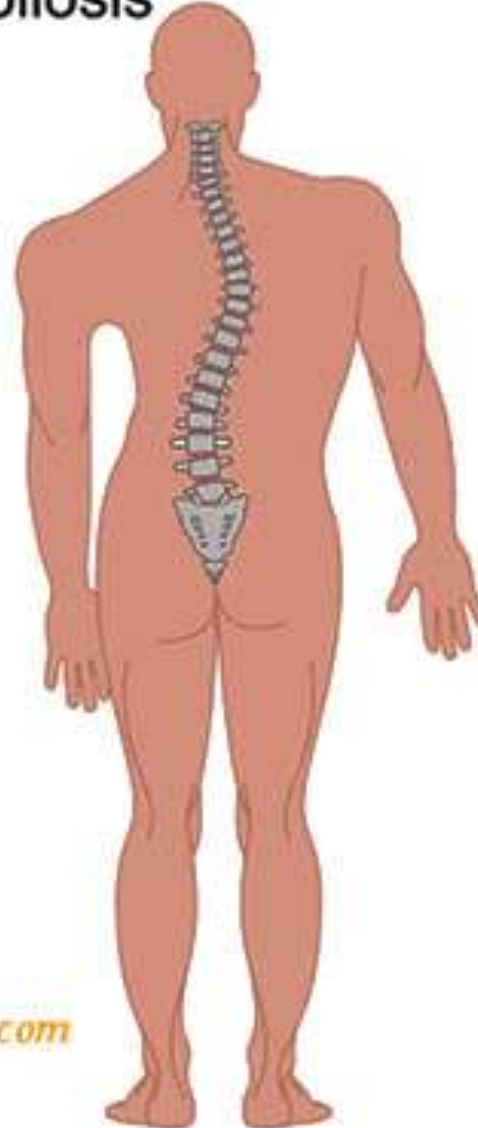


Abnormal Spine

Kyphosis



Scoliosis



MedicosNotes.com

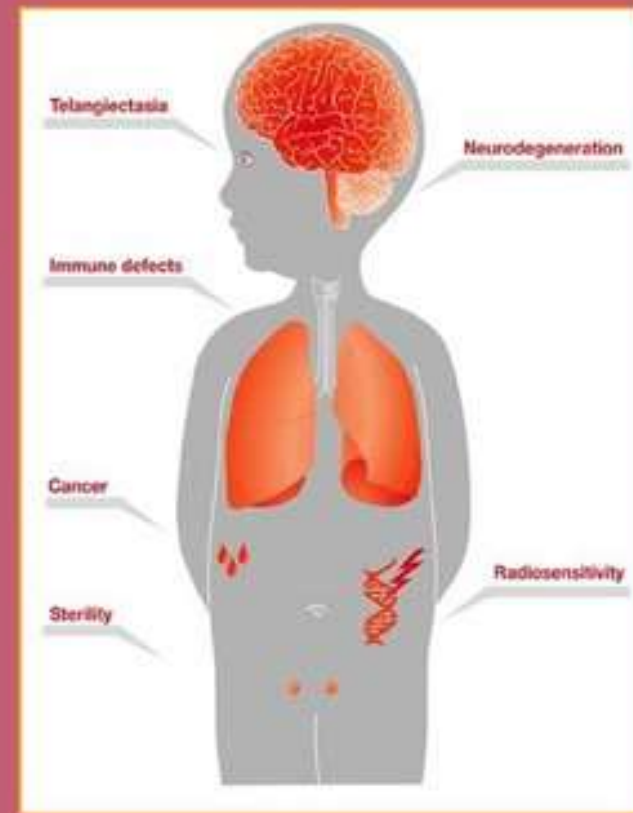
Mutations :

- ▶ GAA trinucleotide repeat expansion.
- ▶ Frataxin protein (regulates mitochondrial iron).
- ▶ Transcriptional silencing >> decreased frataxin >> mitochondrial dysfunction >> oxidative damage (ROS).
- ▶ The damage is not caused by the protein deposition. (loss of frataxin)

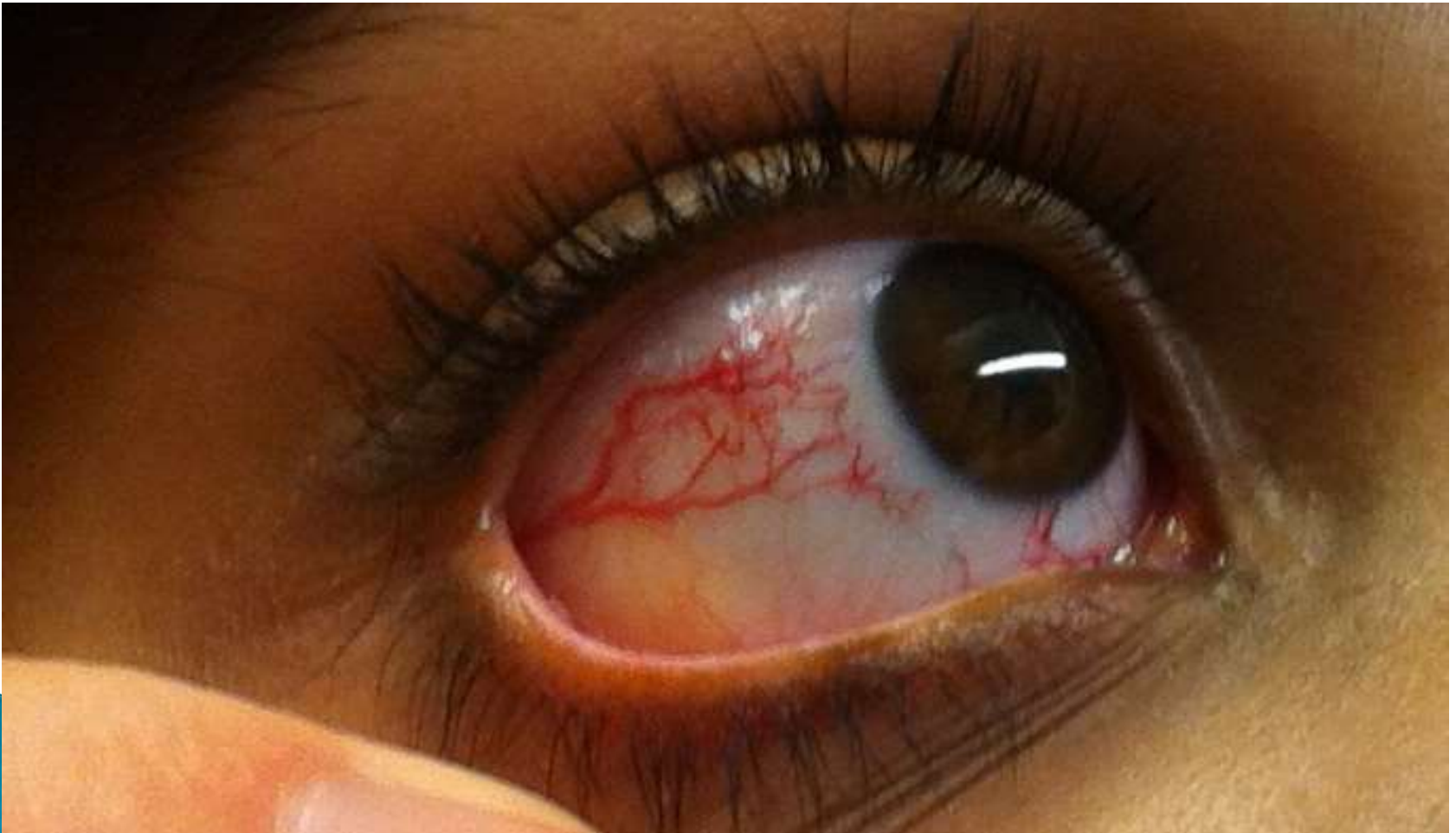
Ataxia Telangiectasia

Characterized by:

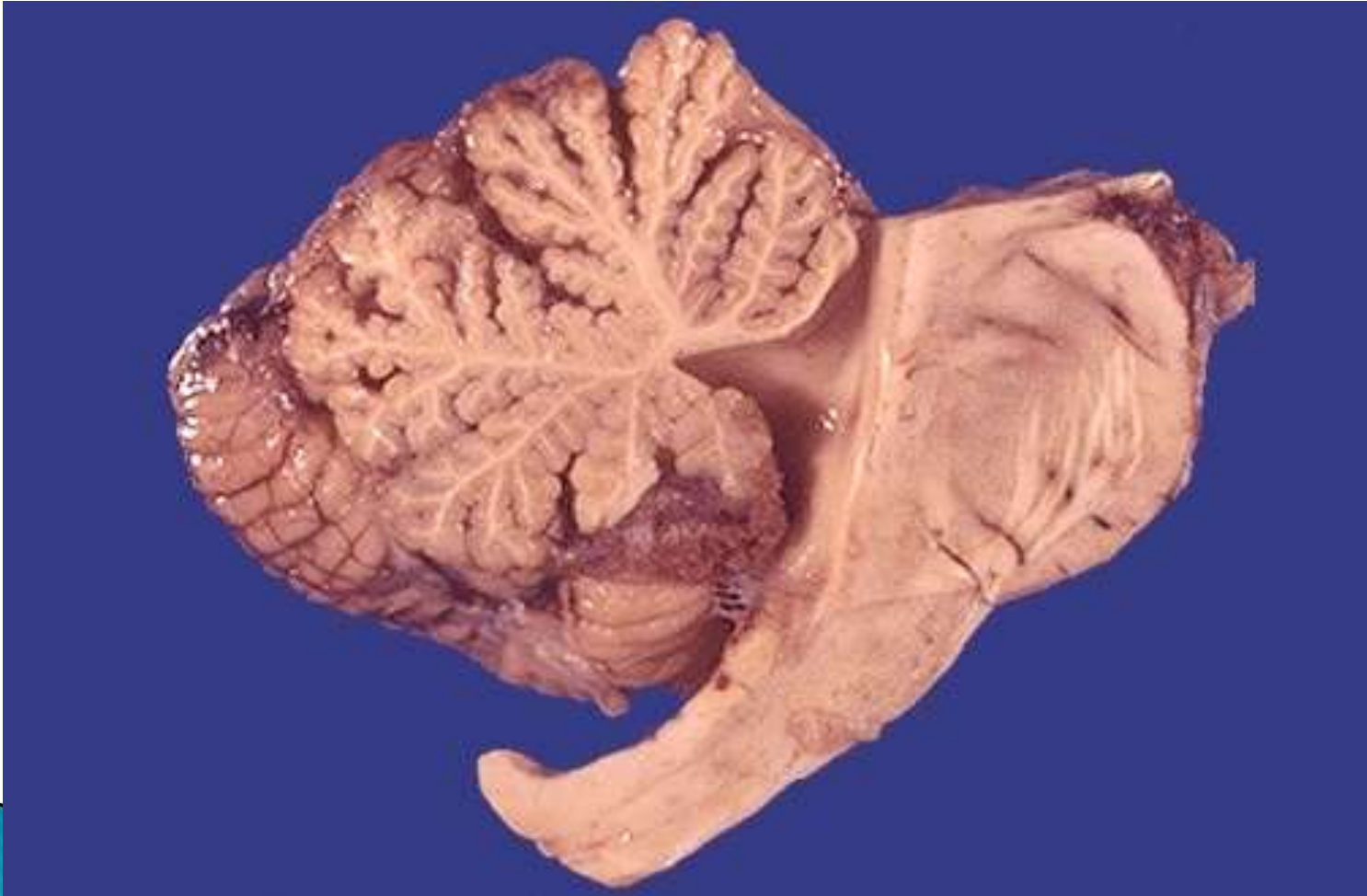
- Cerebellar deterioration
- Oculocutaneous telangiectasia
- Immunodeficiency
- Genomic Instability
- Acute sensitivity to ionizing radiation
- Predisposition to malignancy




Telangectasia



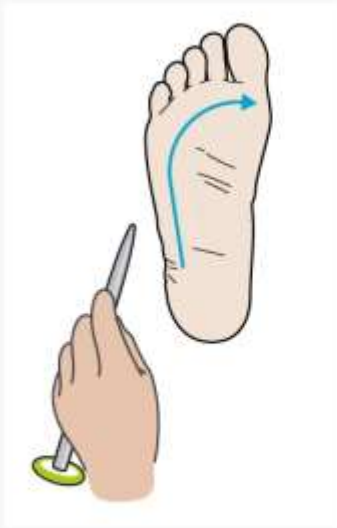Cerebellar atrophy



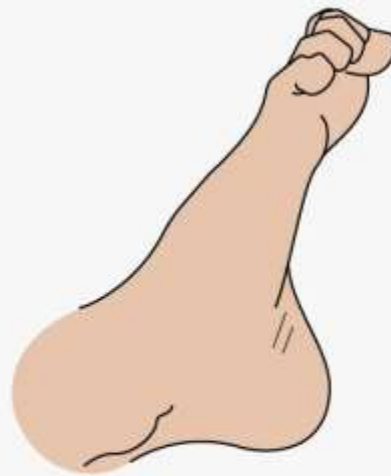Amyotrophic Lateral Sclerosis

- ▶ Death of lower motor neurons in the spinal cord and brain stem as well as upper motor neurons in the motor cortex.
 - ▶ **Loss of lower motor neurons** results in denervation of muscles, muscular atrophy (amyotrophy), weakness, and fasciculations.
 - ▶ **Loss of upper motor neurons** results in paresis, hyperreflexia, spasticity, along with a Babinski sign.
- 

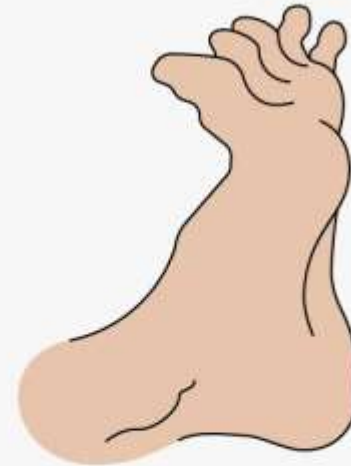
The Babinski Reflex




test



negative



positive

- ▶ Degeneration of the corticospinal tracts in the lateral portion of the spinal cord (**lateral sclerosis, hardening**)
 - ▶ Sensation usually is unaffected, but cognitive impairment is not infrequent.
 - ▶ Male predominance.
 - ▶ 5th decade and after.
- 

Pathogenesis

- ▶ Most cases are sporadic.
- ▶ 10% are familial (AD, early onset)
- ▶ Mutations in the superoxide dismutase gene, *SOD1*, on chromosome 21.
- ▶ Generate abnormal misfolded protein >>> trigger the unfolded protein response >>>> apoptotic death of neurons.

- ▶ **OTHER MUTATIONS:**
- ▶ Hexanucleotide repeat expansion of C9orf72 (familial forms)
- ▶ TDP43 (also associated with FTLD)
- ▶ FUS gene.

- ▶ Genetic and clinical overlap with FTLD.

Symptoms


- ▶ Begins with subtle asymmetric distal extremity weakness.
- ▶ As the disease progresses, muscle strength and bulk diminish.
- ▶ Involuntary contractions of individual motor units (*fasciculations*)
- ▶ Eventually involves the respiratory muscles >>> recurrent bouts of pulmonary infection (the usual cause of death).
- ▶ Most patients exhibits both upper and lower motor neuron disease.
- ▶ ***Bulbar amyotrophic lateral sclerosis*** : degeneration of the lower brain stem cranial motor nuclei. abnormalities of swallowing and speaking dominate.

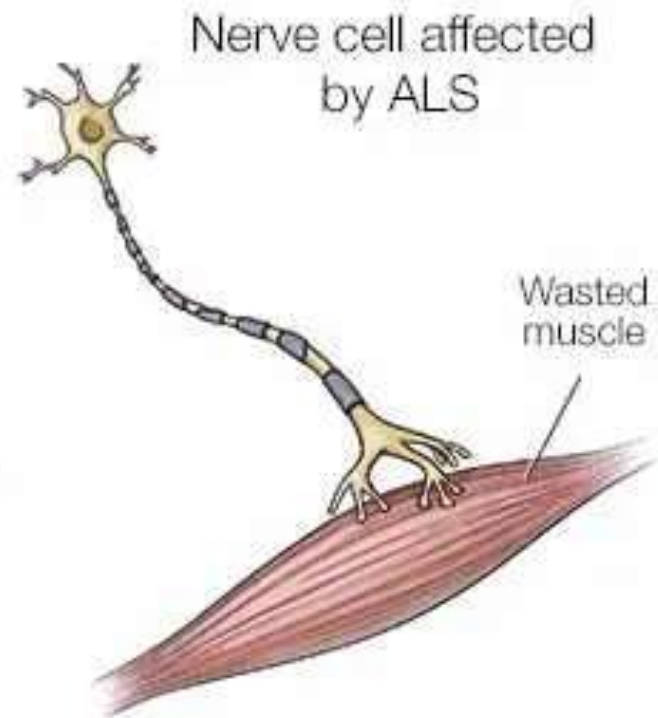
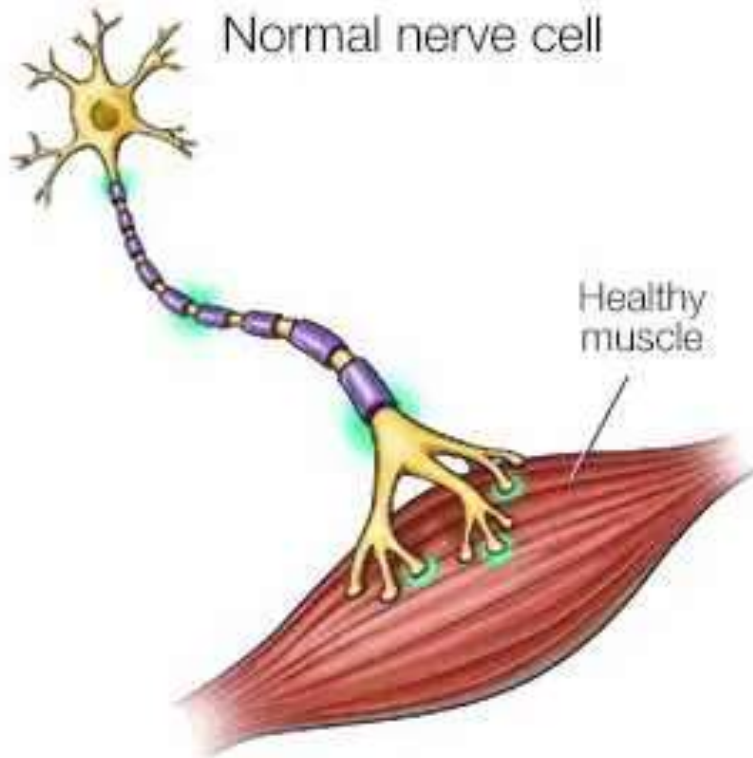
MORPHOLOGY

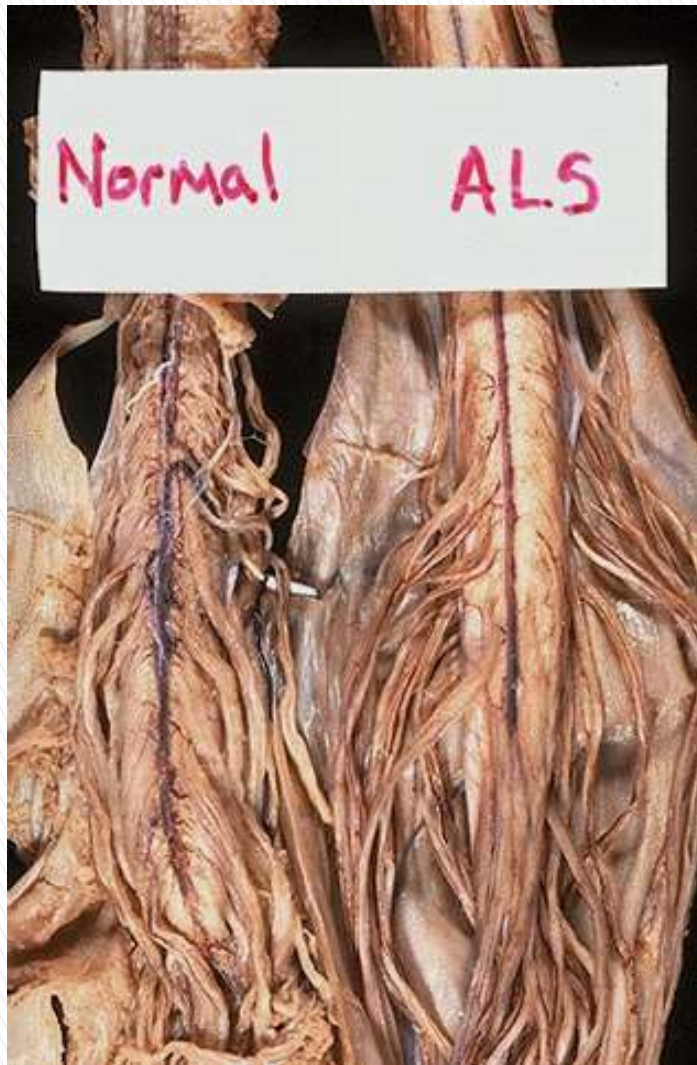- ▶ **MACROSCOPY:**

- ▶ Anterior roots of the spinal cord (most striking): thin and gray.
- ▶ In severe cases: atrophy of precentral gyrus (motor cortex)

▶ **Microscopy:**

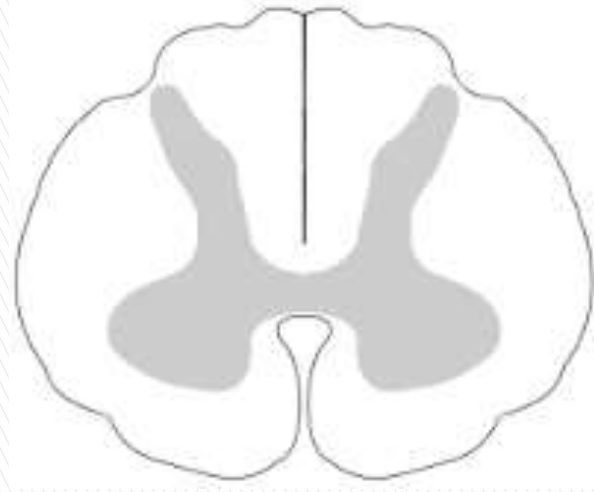
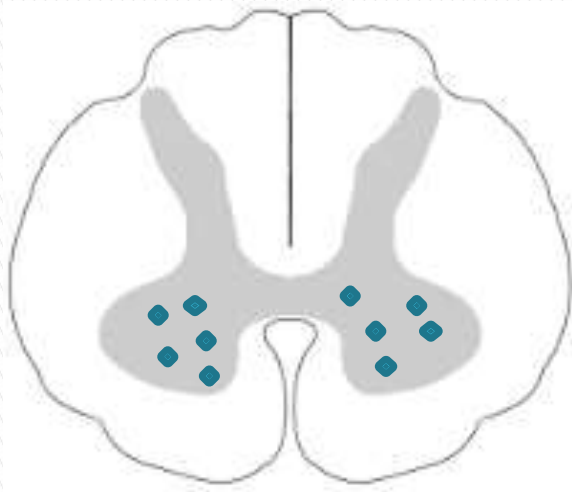- ▶ Reduction in number of anterior horn neurons **(throughout the spinal cord)**
 - ▶ Reactive gliosis and loss of anterior root myelinated fibers.
 - ▶ Similar changes in motor cranial nerve nuclei.
 - ▶ Sparing of those supplying the extraocular muscles.
 - ▶ Cytoplasmic inclusions that contain TDP43.
 - ▶ Skeletal muscles show neurogenic atrophy
- 





- ▶ Loss of anterior horn cells>> (ventral) spinal motor nerve roots demonstrate **atrophy**, as seen here in comparison with **normal** ventral spinal cord nerve roots.

Normal versus ALS



Lateral column degeneration with gliosis--the "sclerosis" of ALS.

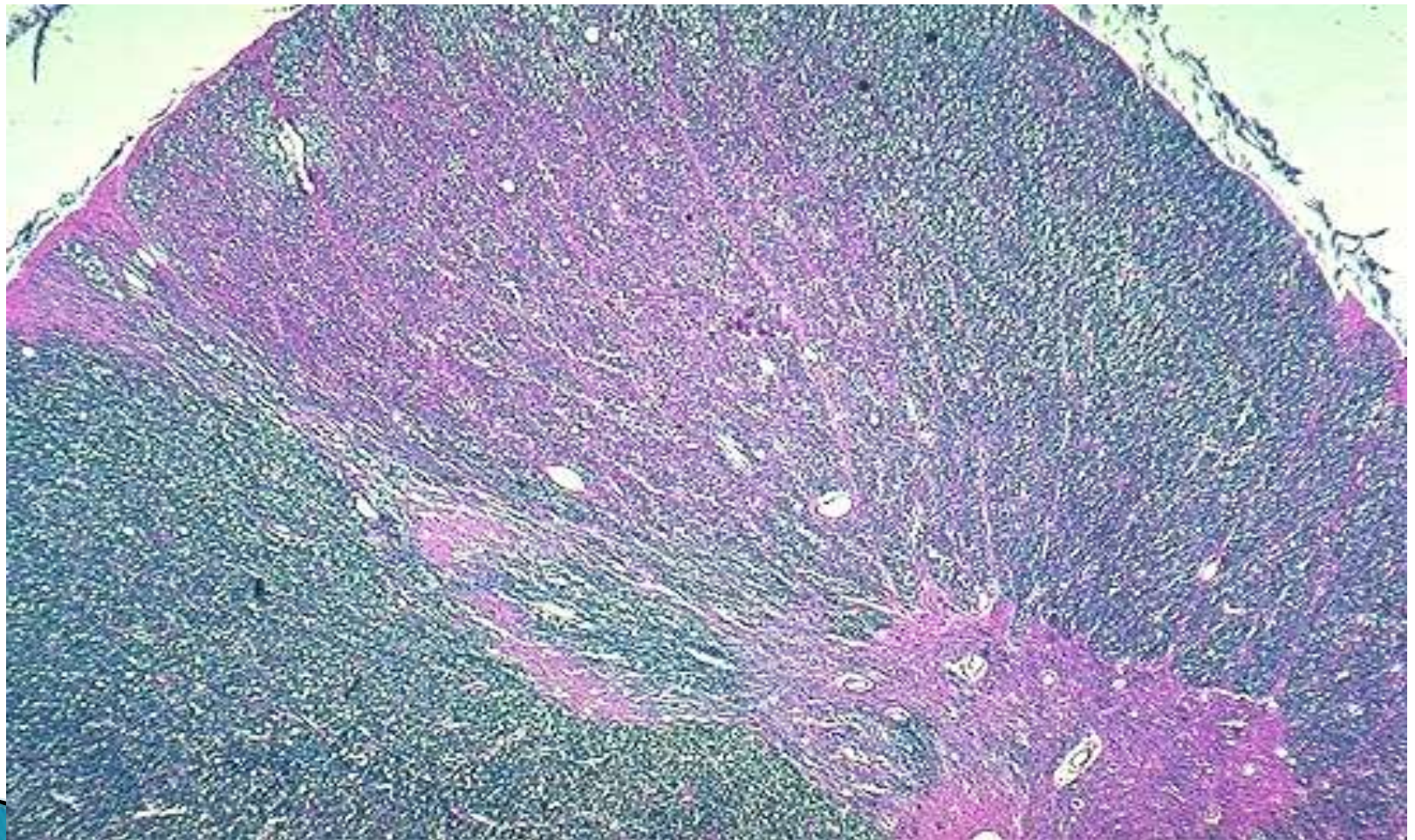


Table 23.3 Features of the Major Neurodegenerative Diseases


Disease	Clinical Pattern	Protein Inclusions
Alzheimer disease (AD)	Dementia	A β (plaques) Tau (tangles)
Frontotemporal lobar degeneration (FTLD)	Behavioral changes, language disturbance	Tau TDP43 Others (rare)
Parkinson disease (PD)	Hypokinetic movement disorder	α -synuclein Tau
Huntington disease (HD)	Hyperkinetic movement disorder	Huntingtin (polyglutamine repeat expansions)
Spinocerebellar ataxias	Cerebellar ataxia	Various proteins (polyglutamine repeat expansions)
Amyotrophic lateral sclerosis (ALS)	Weakness with upper and lower motor neuron signs	SOD1 TDP43


ACQUIRED METABOLIC AND TOXIC DISTURBANCES

- ▶ Common causes of neurologic illnesses.
- ▶ Brain is particularly vulnerable because of its high metabolic demands.


Nutritional Diseases

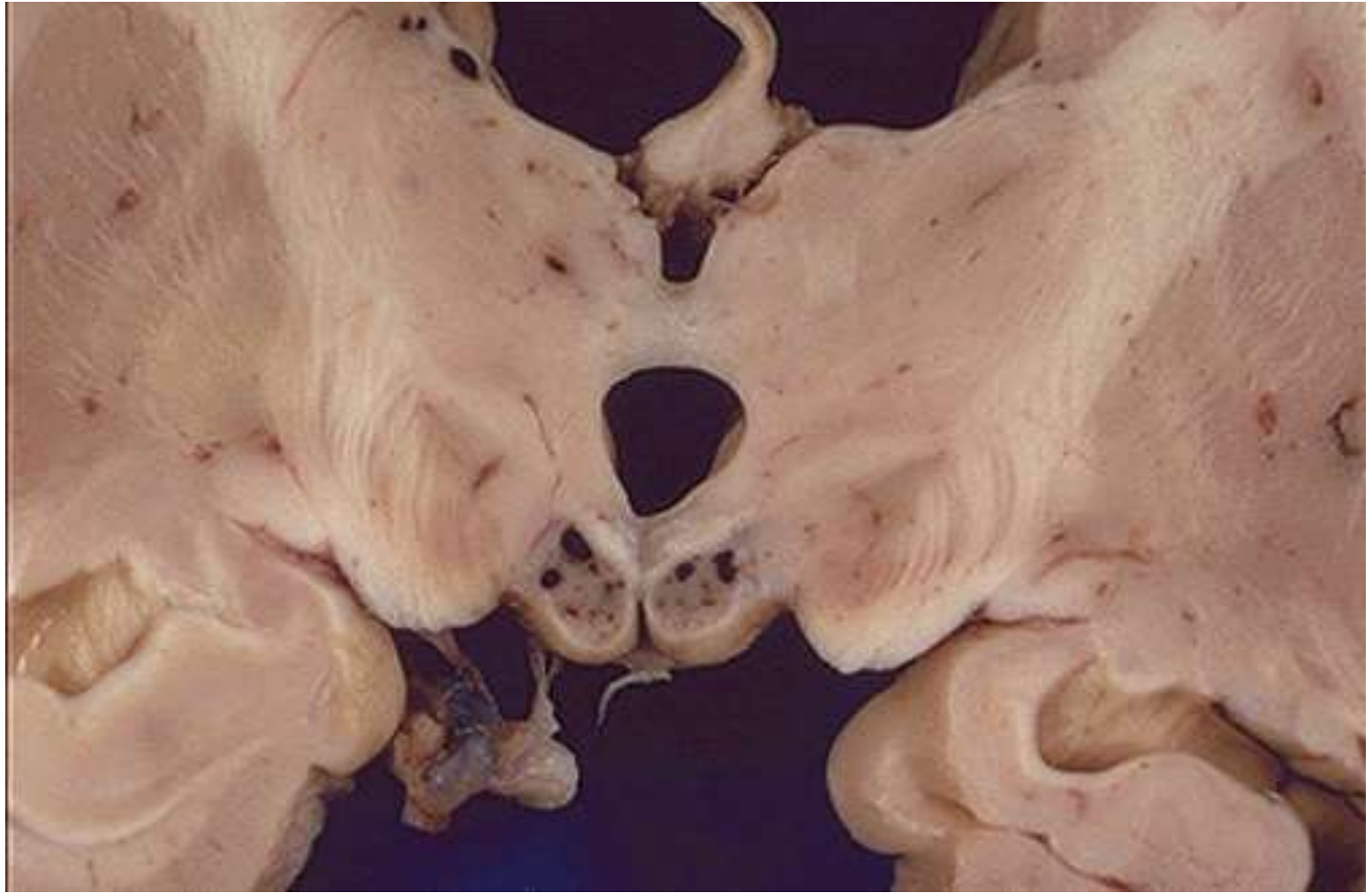- ▶ **Thiamine Deficiency:**
 - ▶ Chronic alcoholism, gastric disorders, gastric bypass surgery, or persistent vomiting.

 - ▶ **Beriberi (systemic manifestations)**
 - ▶ **Wernicke encephalopathy**
 - ▶ Abrupt onset of confusion
 - ▶ Ataxia.
 - ▶ Abnormalities in eye movement
- 


- ▶ Tx: thiamine reverses deficits.
 - ▶ **Delayed Tx:** irreversible profound memory disturbance (Korsakoff syndrome)
 - ▶ *Wernicke–Korsakoff syndrome*
- 

MORPHOLOGY


- ▶ Foci of hemorrhage and necrosis (mammillary bodies & adjacent to the 3rd and 4th ventricles).
 - ▶ later, cystic space with hemosiderin-laden macrophages.
 - ▶ Medial dorsal nucleus of thalamus best correlates with the memory disturbance in Korsakoff syndrome.
- 




Vitamin B12 Deficiency

- ▶ Anemia + neurologic deficits.
 - ▶ **Subacute combined degeneration of the spinal cord.**
 - ▶ Ascending and descending tracts of the spinal cord are affected.
 - ▶ Symptoms develop over weeks.
 - ▶ Early clinical signs:
 1. Mild ataxia.
 2. lower-extremity numbness and tingling.
 3. Can progress to spastic weakness of the lower extremities
 4. Complete paraplegia (poor outcome despite Tx)
- 


Metabolic Disorders

- ▶ **Hypoglycemia:**
 - ▶ Effect resemble those of global hypoxia (anoxia).
 - ▶ Energy substrate (glucose).
 - ▶ Hippocampal neurons are particularly susceptible.
 - ▶ Cerebellar Purkinje cells are relatively spared.
 - ▶ If level and duration of hypoglycemia are sufficiently severe
>> widespread injury.
- 

▶ **Hyperglycemia**

- ▶ Uncontrolled diabetes mellitus.
 - ▶ Ketoacidosis or hyperosmolar coma.
 - ▶ Confusion, stupor, and eventually coma.
 - ▶ Intracellular dehydration.
 - ▶ Rapid correction can produce severe cerebral edema (correct gradually).
- 

▶ **Hepatic Encephalopathy:**

- ▶ Hepatic dysfunction leads to depressed levels of consciousness or coma.
 - ▶ Early stages: flapping tremor “asterixis”.
 - ▶ Elevated levels of ammonia, inflammation and hyponatremia.
 - ▶ Ammonia metabolism occurs only in astrocytes “glutamine synthetase” .
 - ▶ (Alzheimer type II cells): astrocytes in the cortex and basal ganglia with swollen pale nuclei
- 

Ethanol

- ▶ **Acute intoxication** is reversible.
- ▶ Excessive intake leads to profound metabolic disturbances (brain swelling and death)

- ▶ **Chronic alcoholism** : cerebellar dysfunction, 1% of cases, (atrophy in the anterior vermis) :
 1. Truncal ataxia
 2. Unsteady gait
 3. Nystagmus.