★ Topic 1

- **Neuron**
  - morphological
    - Unipolar / pseudounipolar
    - Bipolar
    - multipolar (most common)
  - functional
    - Affrent / sensory :- dindrites
    - Effrent / motor :- axons
    - Interneuron :- in CNS, high brain function

- **myleine sheaths**
  - Neurilemma (schwann) :- PNS, only can repair 1.
  - oligodendrocyte :- CNS, can repair 60.

- **Nerve fibers**
  - white :- axon
  - gray :- body
  - Naked fibers :- Grey matter
  - unmylinated with neurilemma :- post-ganglionic symphetic
  - mylinated with neurilemma :- PNS
  - mylinated without neurilemma :- white matter

- **Nerve** :- surrounded by epineurium → fascieles :- perineurium
  - → fiber :- endoneurium

- **ganglion** :- Collection of nerve cells & fibers surrounded by capsule of CT outside the CNS.
  - spinal
  - cranial
  - Autonomic
    - symphatic
    - parasymphatic

- **Glial cells**
  - oligodendrocyte :- CNS, myline & insulation
  - Schwann :- PNS, myline & insulation
  - Astrocyte :- support & repair + BBB
    - fibrous :- long
    - protoplasmic :- short
  - Ependymal :- Lining cavities on CNS.
  - Microglia :- phegocytic cells.

- **CNS**
  - Spinal Cord (31 segment)
  - Brain
    - cerebrum
      - 2 hemispheres
      - Dinecephelon
      - corpus collusum :- connect
    - cerebellum
      - 2 hemispheres
      - vermis :- connect, tree of life
    - Brain stem
      - midbrain
      - pons
      - medulla oblongata.
- **PNS**
  - 12 Cranial Nerves
  - 31 spinal nerves (8C, 12T, 5L, 5S, 1C).
- **Embryology** (25-27d)
  - foreBrain :- cerebrum + Dinecephelon (thalamus)
  - midBrain :- MidBrain
  - HindBrain :- Pons + medella + cerebellum.

* Topic 2

- **4 Lines**
  - central sulcus
  - posterior ramus of Lateral fissure
  - Immaginary line Between parito-ocipital fissure & preorbital notch
  - Immaginary line Between posterior ramus & previous line
- **4 Lobes**
  - frontal lobe.
  - parital lobe.
  - Temporal lobe.
  - occiptal lobe.
- **Components of cerebral hemisphere**
  - outer gray matter (cerebral cortex)
  - white matter
  - Basal nucli (inner gray matter) :- motor cordination
  - Lateral ventricle :- (1st & 2nd)
- **The 5th Layer of cerebrum → V - Internal pyramidal**
  - Gaint prymidal cells of Betz
  - in motor area (precentral gryus)
  - form pyrmidal track (corticospinal track)
  - responsiple of fine voluntary movement.



• Surfaces

1) suprolateral surface

- central sulcus :- medial 1 cm → above posterior ramus
- parito-ocupital fissure
- Lateral fissure :-
  - stem :- Begins in inferior surface
  - Anterior ramus :- forward Inferior frontal
  - posterior ramus :- end in parital Lobe
  - Acending ramus :- Ascend Inferior frontal

★ Frontal Lobe

- 3 sulcus
  - precentral sulcus
  - Superior frontal sulcus
  - Inferior frontal sulcus
- 4 gyrus
  - precentral (4) :- central sulcus - precentral
  - Superior frontal
  - Middle frontal :- Between superior & Inferior sulcus
  - Inferior frontal :- Inferior sulcus → Lateral fissure
    - orbital
    - Tringular
    - opercular

    } → Broca's area (44, 45)

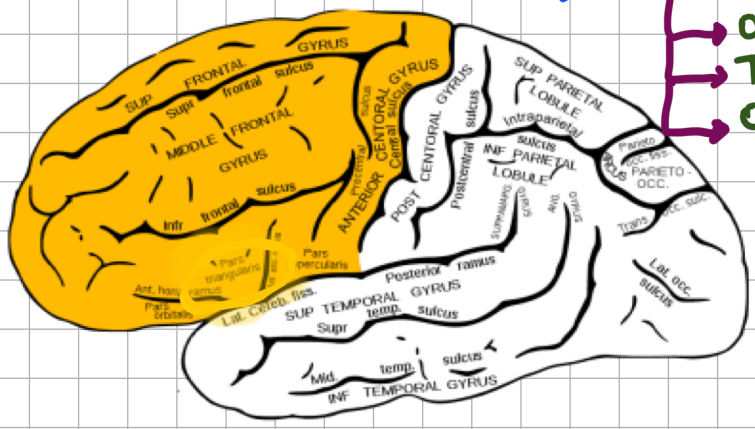

★ Temporal Lobe

- 2 sulcus
  - superior temporal sulcus
  - Inferior temporal sulcus
- 3 gyrus
  - superior temporal :- primary auditory area (41, 42)
  - Middle temporal
  - Inferior temporal

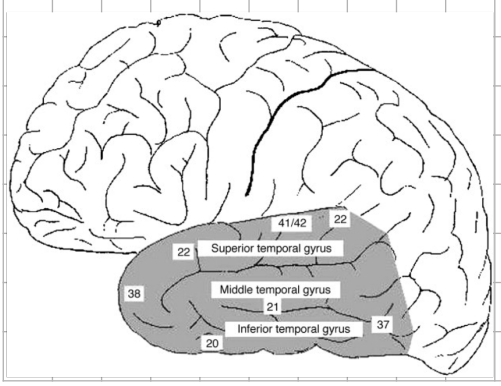

★ Insula (Island of Reli, 5th Lobe)

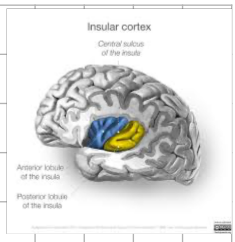

- Sulcus centralis
- 2 gyrus
  - Anterior :- short
  - Posterior :- Long
- Function :- taste (gustatory area) + Autonomic Aspect of pain

★ parital Lobe

- 2 sulcus
  - Postcentral sulcus
  - Intraparital sulcus
- 3 gyrus
  - Postcentral gyrus
  - Superior Lobule
  - Inferior Lobule
    - Angular
    - submargilar
    - → wernicke's area (39, 40, 22)

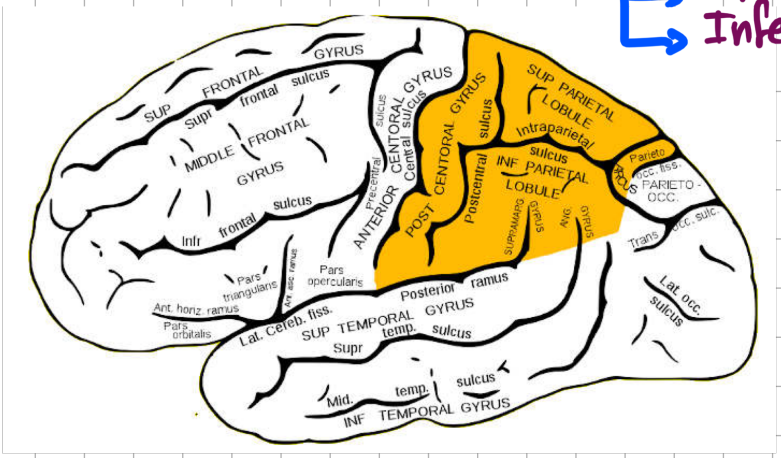

★ occipital Lobe

- 2 sulcus
  - Transverse occipital
  - Lateral occipital
- 2 gyrus
  - Superior occipital
  - Inferior occipital

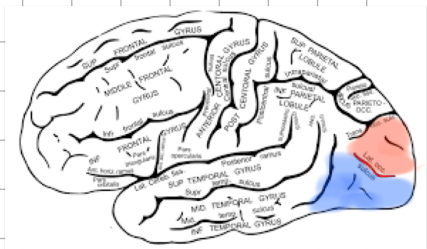

2) medial surface

- 4 sulcus
  - callosal
  - cingulate → Ascending → marginal
  - Subparietal
  - cancrine
- 6 gyrus + corpus callusum
  - Cingulate gyrus
  - medial frontal
  - paracentral Lobule
  - paracuneus
  - cuneus
  - Lingual :- primary visual area (17)

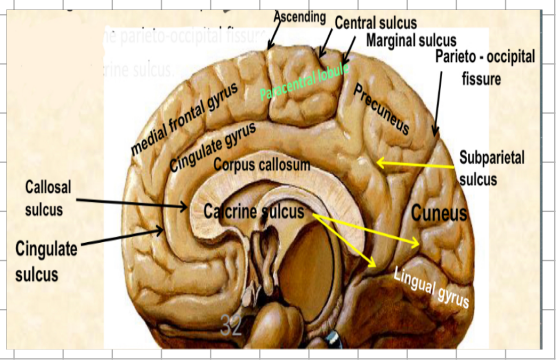

★ Topic 3

3) Inferior surface :- divided By stem of Lateral fissure to:-

1) orbital surface
- 2 sulcus
  - olfactory :- olfactory bulb & track
  - orbital (H)
- 2 gyrus
  - gyrus rectus :- (+ superior frontal)
  - posterior, anterior, lateral, medial orbital gyri
- anterior & posterior profilated areas.

2) Tentorial surface
- 3 sulcus
  - Hippocampal sulcus.
  - collateral sulcus → Rhinal sulcus
  - occipito-temporal sulcus.
- 3 gyrus
  - parahippocampal gyrus & uncus.
  - medial occipito-temporal gyrus.
  - lateral occipito-temporal gyrus :- (inferior temporal, location memory)

★ uncus :- smell center in olfactory cortex + fear sensation

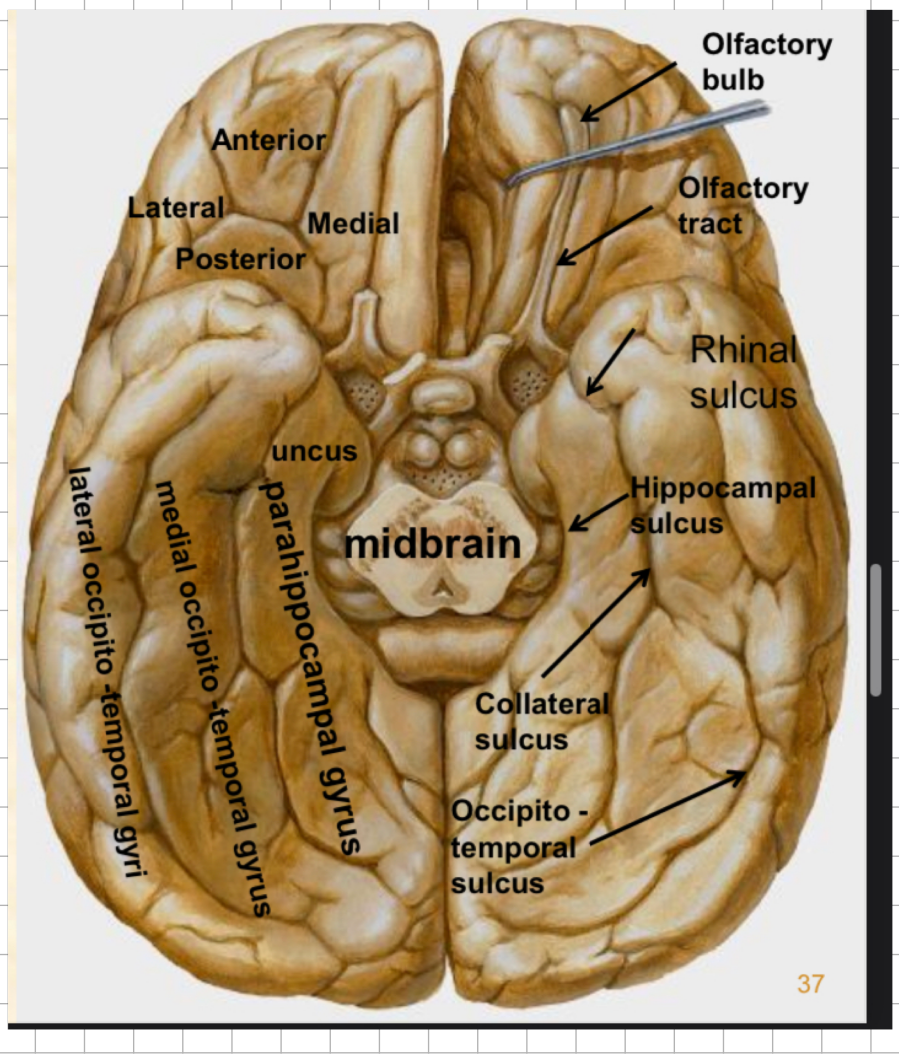

• Functional localization of cerebral cortex

- Sensory :- primary & secondary sensory area's
- Motor :- primary & secondary motor area's & SMA
- Association :- parietal, occipital, temporal cortex, prefrontal

1) Motor areas

→ Primary motor area (4)

- site :- precentral gyrus (homunclus)
- pyrmidal cells of Betz (5th) → corticospinal or pyrmidal
- afferent :- premotor area, SMA, sensory, thalamus.
- function :- fine voluntary movement
- lesion :- upper motor neuron, contralateral hemiplegia

→ premotor area (6) (extrapyrmidal center).

- site :- front of area 4
- afferent :- thalamus, cerebellum, Basal ganglia
- functions
  - → motor program
  - → coordination of coarse
  - → movement of
    - → trunk
    - → shoulder
    - → hip muscles
- Lesion :- motor apraxia, sparticity (↑tone), Loss of postural

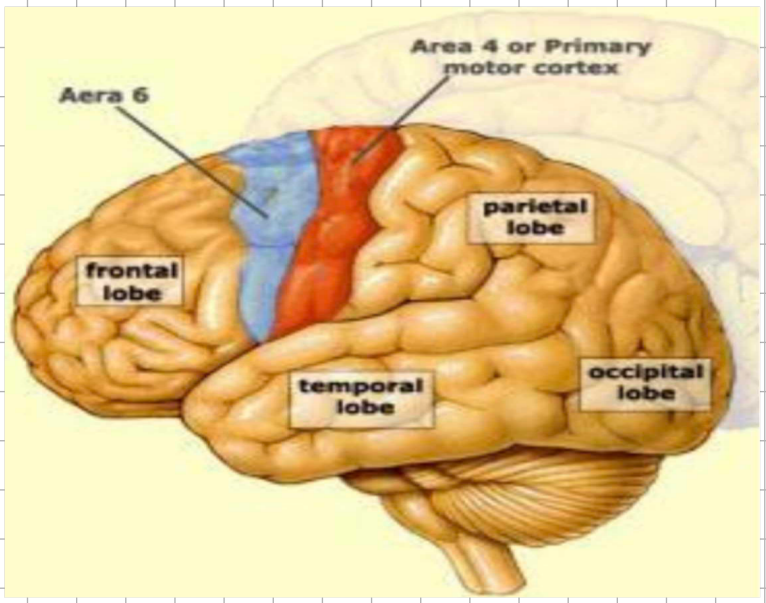

Supplementry Motor area (SMA).

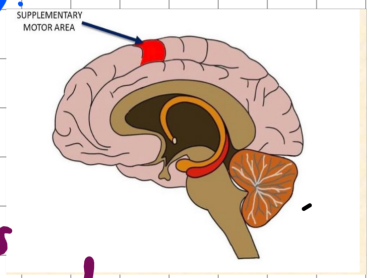

- site → medial frontal gyrus
  → premotor area on medial site
- affrent :- thalamus, Basal ganglia
- function :- coordination of Both sides & control of sequence of movement.
- Lesion :- not difine.

Frontal eye field (8)

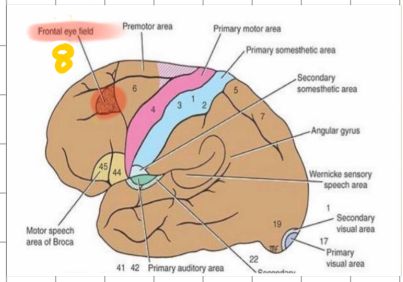

- site:- front of premotor/middle frontal gyrus.
- function :- voluntery tracking to opplsite site.
- lesion deviation of Both eyes to same side of Lesion.

★ unvoluntary tracking (Reding) :- occipital eye felid area

Broca's area (44, 45)

- site :- Inferior frontal gyrus (Lt)
- function :- Coordination of muscles of → Larynx, → mouth, → tounge, → palate
- Lesion :- motor aphasia/non-fluent aphasia

★ connected to wernicke's area through arcuate fasiculas. (39, 40, 22)

2) sensory areas

primary sensory area (3, 1, 2)

- site :- postcentral gyrus
- function → Localize, discriminates diffrent sensation
  → 20% of prymidal track.
- Lesion :- contralateral hemianathesia.

Secondary sensory area

- site:- Lowermost part of postcentral gyrus.

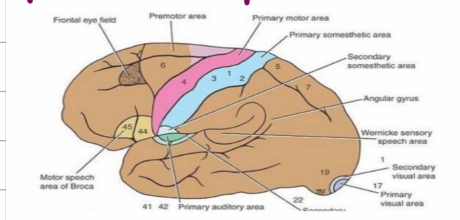

Visual Cortex

VI (17)

- site:- around calcarine sulcus (cuneus / Lingual)
- function:- visual perception
- Lesion:- contralateral homonymous hemianopia with muscular sparing.

VII (18, 19) (visual association area)

- site:- cuneus & Lingual gyri
- function:- Interpretation of visual stimulus with past experence
- Lesion:- visual agnosia / color blindness.

occipital eye field area

- site:- Rest of occipital lobe
- function:- unvoluntary tracking of eyes opposite.

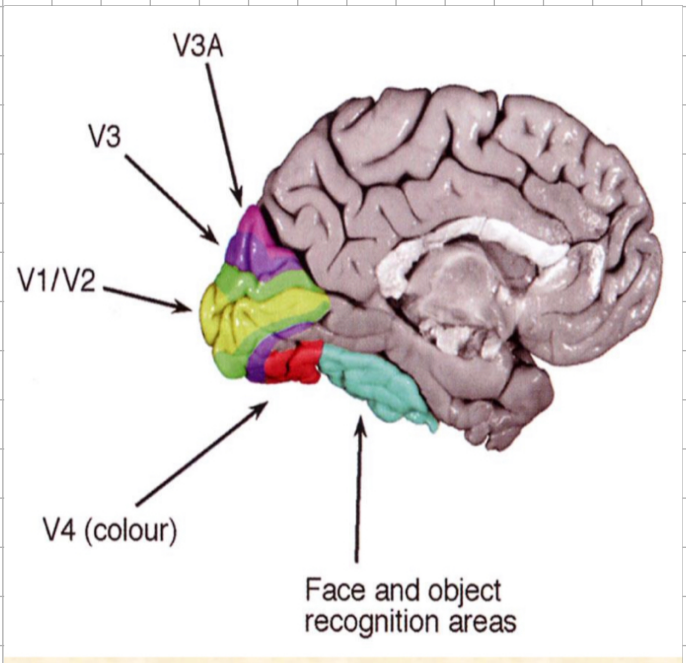

Auditory area (superior temporal gyrus)

primary auditory (41, 42)

- Lesion:- defect of hearing

secondary auditory (22)

- Lesion:- auditory agnosia.

★ Topic 4

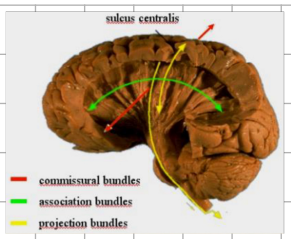

- white matter of the Brain
  - Association fibers:- Diffrent area, same hemisphere.
  - commissural fibers:- similar area in 2 hemisphere.
  - projection fibers:- from & to the cortex

1) Association fibers

- short:- adjacent gyri, U-shaped arcuate
- Long
  - superior longitudinal bundle:- frontal & occipital & temporal lobes.
  - Inferior longitudinal bundle:- temporal & occipital.
  - Cingulum:- incomplete circle around corpus callosum
    - rostrum of corpus callosm → uncus
    - (+ hippocampus & cingulate gyrus).
  - uncinate fasiculus:- frontal → temporal.

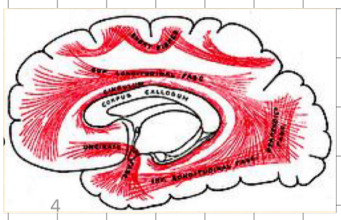

2) commissural fibers

- Anterior commissure
  - Temporal lobe
  - connect both piriform fossae.
  - function:- acute pain & smell.
- posterior commissure
  - Lower pineal
  - function:- Indirect pupillary light reflex (oculomotor).
- Habenular commissure
  - superior pineal
  - Rt & Lt habenular nuclei, Amygdaloid nucleus
  - Integration of olfactory, visceral pathway.
- fornix commissure:-
  - efferent of hippocampus.
  - connects crura & body of the fornix across both hippocampus.
- Corpus callosum
  - 4 parts
    - Rostrum
    - Genu
    - Body
    - splenium
  - 3 fibers
    - forceps minor:- frontal
    - forceps major:- occipital
    - Tapetum:- other
  - Blood supply
    - anterior cerebral
    - Posterior cerebral (splenium)
  - Lesion:- callosal (split Brain), Apraxia.

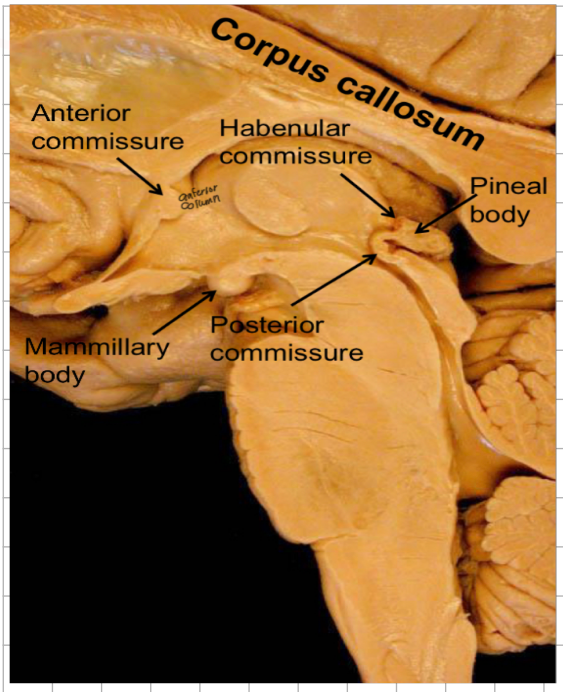

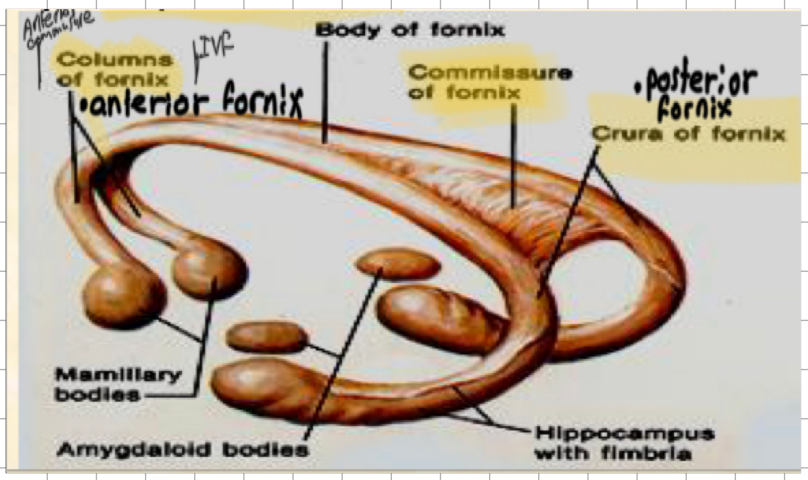

3) projection

- To cortex, sensory, Assending (thalamo-cortical, thalamic radation).
  - sensory radiation:- pLNVT (general sensation) → area 3, 1, 2 (postcentral gyrus)
  - Anterior thalamic:- anterior thalamus → cingulate
  - visual Radation:- Lateral geniculate body → area 17
  - Auditory Radiation:- medial geniculate body → Audiotry area.
- from Cortex, motor, dessending
  - pyramidal tract (corticospinal).
  - Extrapyramidal tract.
  - Cortico-pontine fibers (pons → cerebellum).
  - Cortico-thalamic fibers (thalamus).

- precentral area / primary motor area :- 4.
- premotor area / secondary motor area :- 6.
- Primary sensory Area / postcentral gyrus :- 3, 1, 2.
- Broca's area :- 44, 45.
- wernicke's area :- 39, 40, 22.
- frontal eye field :- 8.
- primary visual area :- VI, 17.
- visual association area :- VII, 18, 19.
- primary audotary area :- 41, 42.
- secondary audotary area :- 22 (part of wernicke's).

★ Topic 5

- **Internal capsule** :- V-shaped bundle of projection fibers,
  - Anterior Limb :- Between cudate & Lentiform,
  - Genu
  - posterior Limb :- Between thalamus & Lentiform.
  - Retrolentiform :- visual Radiation
  - Sublentiform :- Temporal lobe (auditory).

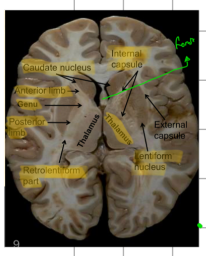

- **Types of fibers in internal capsule**
  - Anterior Limb fibers.
    - Decending :- Frontopontine
      - cortico-ponto-Dento-Rhobro-themo-cortico-spinal pathway.
      - cross in middle cerebral bundle / Learning function
      - fibers from frontal cortex → pons.
    - Assending :- Thalamocortical (Anterior thalamic radiation)
      - Thalamus → frontal lobe → cin ulate (limbic)
  - Genu :- corticobulbar :- cortex → cranial nuclei in Brainstem
    - part of prymidal track.
  - posterior limb
    - Decending anterior half :-
      - corticospinal
    - Assending posterior half :-
      - sensory fibers (superior thalamic radiation)
      - To pLNVT, General sensation
  - Retrolentiform :- optic radiation
    - posterior thalamic Radiation.
  - sublentiform :- Auditory Radiation
    - (Inferior thalamic radiation)

- **Lesion** :- contralateral by cerebral hemorge

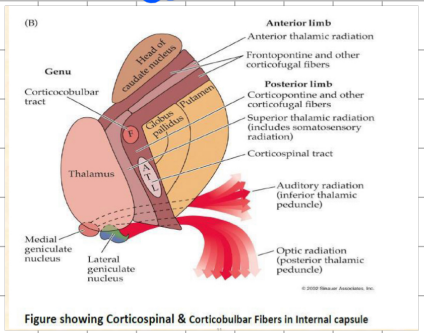

Figure showing Corticospinal & Corticobulbar Fibers in Internal capsule

- No Nuclei
  - I olfactory
  - II optic
- MidBrain
  - III oculomotor
  - IV trochlear
- Pons
  - V Trigeminal
  - VI Abducens
  - VII facial
  - VIII vestibulocochlar
- Medella
  - IX Glossopharyeal
  - X vagus
  - XI Acessory
  - XII Hypoglossal

- **Basal ganglia**
  - function → Voluntary movement :- Intiation
    programing, Learning motor skills.
    → postural :- Automatic association, antigravity.
    → cognitive function of motor activity.

  - subdivision
    → Neostratium or striatum :- putamen + caudate.
    → pallostratium / pallidum / Globus pallidus.
    → Lentiform neuclei → putamen (outer lateral)
      → Globus pallidus (inner medial) I E
    → Archistiatum / Amygdala :- oldest part.
    → Substania nigra :- in midbrain.
    → subthalamic neuclei :- motor zone of Diencephalon.
    → claustrum :- unknown function

  - corpus stratium = caudate + Lentiform (putamen + GP)

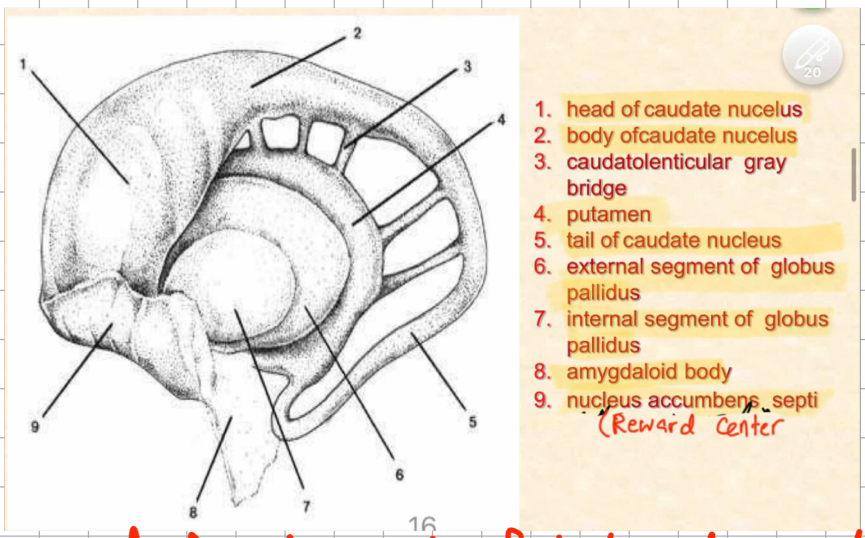

- **Relations of Basal ganglia & Lateral ventricle (3)**
  → Head of caudate :- Intreolateral
  → Body of caudate :- floor of lateral ventricle
  → tail of caudate :- Roof of lateral ventricle.

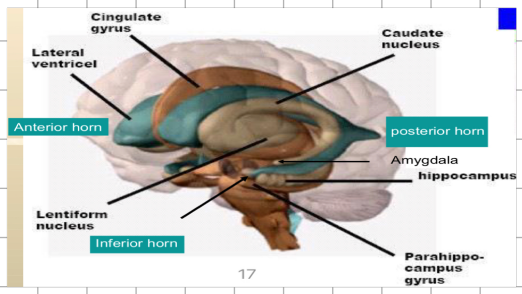

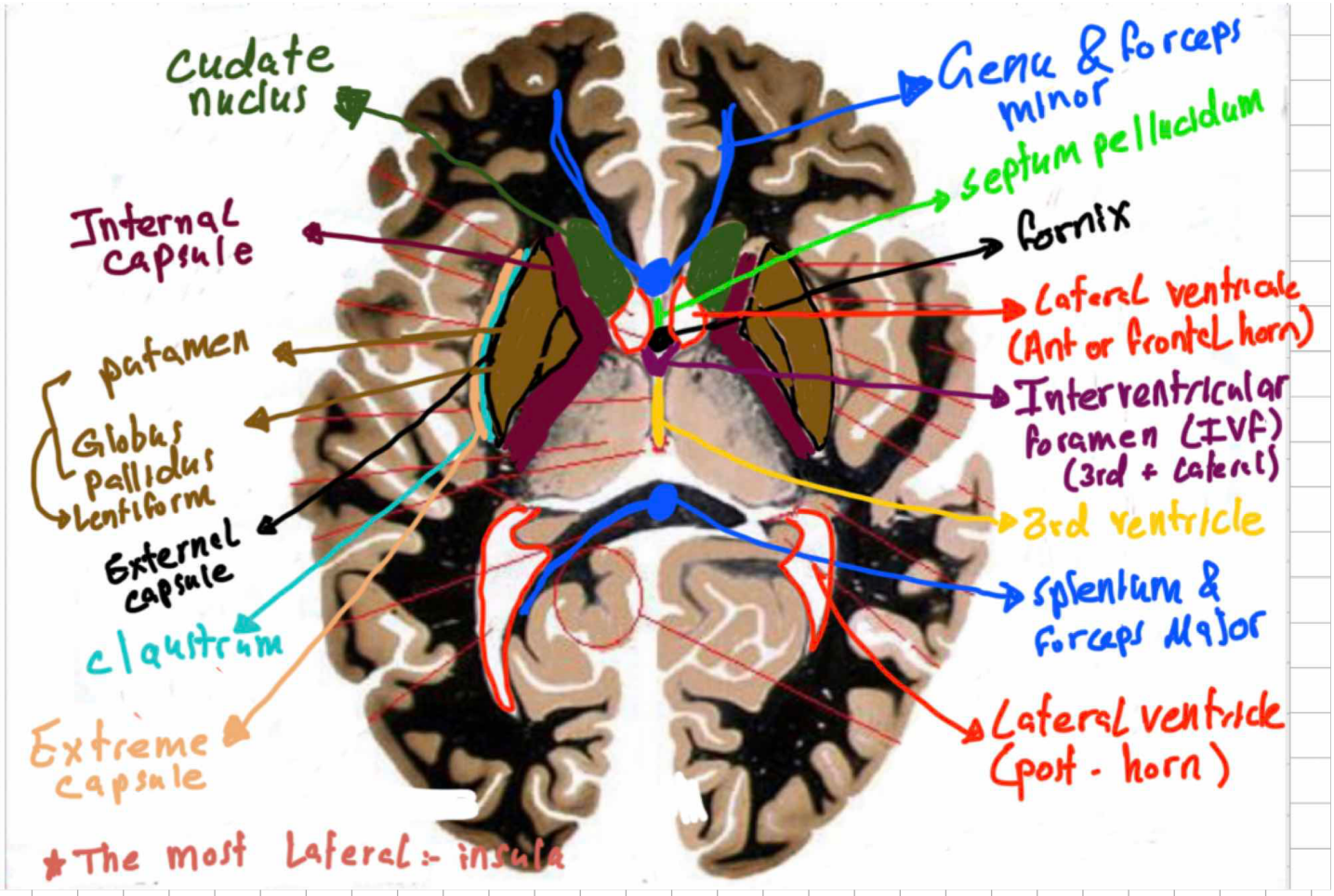

- Cudate :- C-shaped → Head :- in frontal lobe.
  → Body
  → tail :- in occipital lobe.
  - end by amygloid (in uncus, roof of Inferior horn of lateral ventricle
- Lentiform nuclei :- putamen (Dark)
  Globus pallidure (pale) → Internal (Gi)
  → external (Gp)
  - Between Internal & External capsule.
- Amygdaloid :- In temporal lobe (uncus), part of limbic system.
  - give axons to → stria terminalis → curves on superior surface of thalamus → hypothalamus.
  - function :- sense of fear & smell.
- Subtantia nigra :- in mid brain → pars compacta :- Dopamine
  → pars Reticulata :- output of Brain
- Subthalomic nuclei :- Dinecephalon (excitary)
- claustrum :- • Location :- Lateral to Lentiform, Between External & Extreme capsule.
  • function :- unknown.

- 2 circuits
  - Direct :- Exicatory.
    cortex → putamen ⊖→ Globus pallidus → thalamus → cortex.
  - Indirect :- Inhibitory.
    Globus pallidus —GABA→ thalamus

- Diseases of Basal ganglia :- (contralateral)

1) parkinosism :- hypokinetic + hypertonia
   - Lesion of direct pathway.
   - ↓ dopamine
   - symptoms :- Resting tremor, Rigidity, bradykinesia, postural distrubences, No loss of motor & sensory.

2) Hyperkenitic
   - → Huntington's disease
   - → Sydenham chorea
   - → Hemiballism

   - Lesion in indirect pathway.
   - hypotonia + hyperkinesia.