



CVS

Physiology

Writer: Doctor 2018/2019

corrected by:

Doctor: Faisal Mohammad

Normal Electrography

When the cardiac impulse passes through the heart, electrical currents generated during depolarization and repolarization also spreads from the heart into the adjacent tissues surrounding the heart. A small portion of the current spreads all the way to the surface of the body. If electrodes are placed on the skin on opposite sides of the heart, electrical potentials generated by the current can be recorded; the recording is known as an electrocardiogram (ECG). Before we start talking about ECG, let's first understand the principal of recording potential difference.

* Depolarization Waves Versus Repolarization Waves

- The following figure shows a single cardiac muscle fiber in four stages of depolarization and repolarization, being recorded using a galvanometer. The electrodes are put on the **surface** of the muscle fiber. Let's define some concepts to understand the graph:

- ✓ The color red designates depolarization in which during, the normal negative potential inside the fiber reverses and becomes slightly positive inside and negative outside.
- ✓ Depolarization is demonstrated as an upward deflection (+), and repolarization as a downward deflection (-).
- ✓ The potential difference between the two electrodes increase as the impulse moves from left to right until it reaches the halfway mark. When it reaches the halfway mark, the membrane potential difference between the two sides is maximum. When it exceeds the halfway mark, the potential difference decreases until the muscle fiber is either completely depolarized or repolarized → no potential difference (**isoelectric line**).

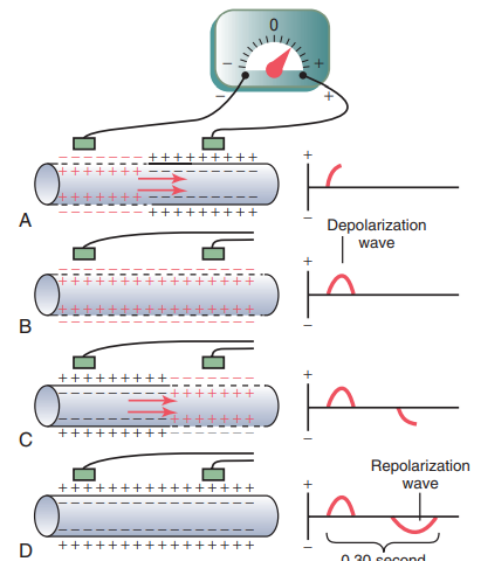


Figure 11-2. Recording the depolarization wave (A and B) and the repolarization wave (C and D) from a cardiac muscle fiber.

- In (A), depolarization, demonstrated by red positive charges inside and red negative charges outside, is traveling from left to right. The first half of the fiber has already depolarized, while the remaining half is still polarized. Therefore, the left electrode on the outside of the fiber is in an area of negativity, and the right electrode is in an area of positivity, which causes the meter to record **positively**. To the right of the muscle fiber is shown a record of changes in potential between the two electrodes, as recorded by the galvanometer. Note that when depolarization has reached the halfway mark, the record has risen to a maximum positive value (upward deflection).
- In (B), depolarization has extended over the entire muscle fiber, and the recording to the right has returned to the zero baseline because both electrodes are now in areas of equal negativity (**isoelectric line**). The completed wave is a **depolarization wave** because it results from spread of depolarization along the muscle fiber membrane.
- (C) shows halfway repolarization of the same muscle fiber, with positivity returning to the outside of the fiber. At this point, the left electrode is in an area of positivity, and the right electrode is in an area of negativity. This polarity is opposite to the polarity in (A).
→ Consequently, the recording, as shown to the right, becomes negative.

- In (D), the muscle fiber has completely repolarized, and both electrodes are now in areas of positivity so that no potential difference is recorded between them (**isoelectric line**). Thus, in the recording to the right, the potential returns once more to zero. This completed negative wave is a repolarization wave because it results from spread of repolarization along the muscle fiber membrane.

* Characteristics of the Normal Electrocardiogram (ECG)

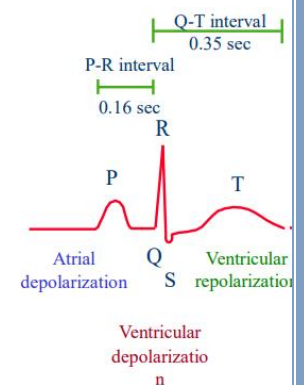
- The electrograph is a machine composed of a galvanometer with amplifiers.
- To record the electrical potentials generated by the cardiac impulse (ECG), the electrodes of the galvanometer are placed on the skin on opposite sides of the heart; one on the left arm, the other on the right arm.
- The potential difference during the cardiac action potential (the difference between the electrical potential in depolarization **+20mv** and repolarization **-90mv**) is nearly 110 mv.
- However, the potential difference that is recorded in the arms is much less than that of the heart, so in order to record the potential difference in the heart (110mv), we add amplifiers to amplify the potential difference between depolarization and repolarization.

- The normal ECG is composed of a **P wave**, a **QRS complex**, and a **T wave**. The QRS complex is often, but not always, three separate waves: the Q wave, the R wave, and the S wave.

- The **P wave** is caused by electrical potentials generated when the **atria depolarize** before atrial contraction begins. The **QRS complex** is caused by potentials generated when the **ventricles depolarize** before contraction, that is, as the depolarization wave spreads through the ventricles.

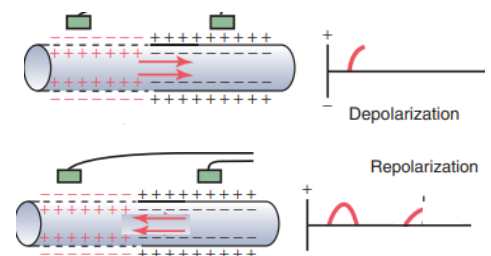
→ Therefore, both the P wave and the components of the QRS complex are **depolarization waves**.

- The T wave is caused by potentials generated as the ventricles recover from the state of depolarization. The **T wave** is known as a **repolarization wave**.



- Note that even though it's a repolarization wave, the T wave exhibits a positive deflection. The reason for this is that the last cells to depolarize in the ventricles are the first to repolarize (direction of repolarization is **opposite** of that in figure 11-2C).

- This occurs because the depolarization of ventricles starts from the endocardial part of the muscle to the epicardial part (base of the heart → apex), but repolarization starts from the epicardial part to the endocardial part (apex → base). This might be due to intrinsic properties of the cardiac action potential.

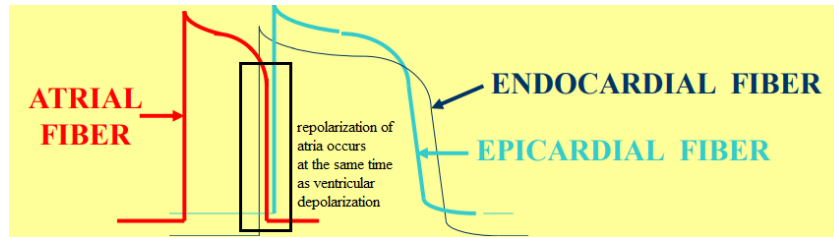


- Therefore, repolarization waves of the ventricles generally are oriented opposite of depolarization waves, and since the left is area of negativity and the right is area of positivity, the meter records **positively** (just like in figure 11-2A).

- In conclusion, the **ECG** is composed of both **depolarization and repolarization waves**.

*ECG can be called EKG as well, EKG is the German spelling for *elektrokardiographie*, which is the word *electrocardiogram* translated into the German language.

- During each cardiac cycle, we record atrial depolarization, ventricular depolarization and ventricular repolarization. But what about atrial repolarization? Atrial repolarization occurs at the same time as ventricular depolarization, and since the depolarization of the ventricles is strong, it masks the repolarization of atria and that's why it doesn't show in the record.



- The recording of ECG shows repeated cycles of P, QRS and T waves. The interval between 1 R and the following one represents a cardiac cycle. The same applies to each of the intervals between (P-P, T-T, S-S and Q-Q) but the R-R interval is the most definite one with significant sharp peaks.
- The number of electrical cardiac cycles per minute is equal to the number of heart beats per minute (normally ranges from 60 to 100 BPM). Which means that we can calculate the heart rate using ECG.

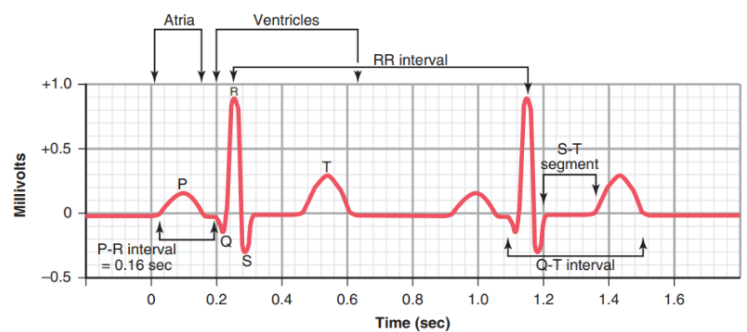


Figure 11-1. Normal electrocardiogram.

* Standardized (ECG):

- Time and voltage calibrations are standardized by putting a heat-sensitive vapor under the pointer of the electrocardiograph. Underneath this pointer, is a paper that is squared.
- The horizontal calibration lines (**Y-axis**) are arranged so that each 10 small squares upward or downward in the standard ECG represent 1 millivolt, with positivity in the upward direction and negativity in the downward direction.
- The vertical lines (**X-axis**) are time calibration lines. A typical ECG is run at a paper speed of 25 millimeters per second. Therefore, each 25 millimeters in the horizontal direction is 1 second, and each 5-millimeter segment (big square), indicated by the **dark** vertical lines, represents 0.20 second. The 0.20-second intervals are then broken into five smaller intervals by thin lines (5 small squares), and each small square represents 0.04 second.
- Now let's discuss the intervals and segments that are recorded in normal ECG:

1. Intervals:

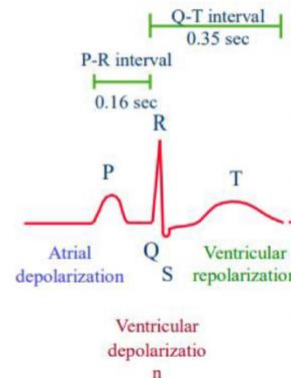
- The term interval refers to a period that contains a wave

a) The P-Q or P-R Interval:

- The first interval that shows in normal ECG is the P-Q interval (often this interval is called the P-R interval because the Q wave is likely to be absent).
- The normal P-R interval is about 0.16 second and it represents the time between the beginning of electrical excitation of the atria and the beginning of excitation of the ventricles.

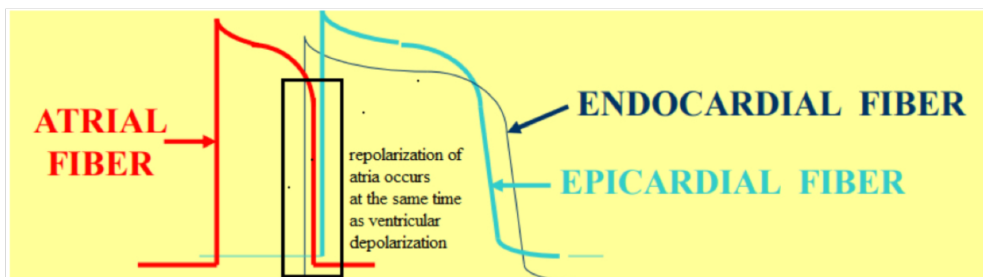
As a revision:

- The normal ECG is composed of a **P wave**, a **QRS complex**, and a **T wave**. The QRS complex is often, but not always, three separate waves: the Q wave, the R wave, and the S wave.
- The **P wave** is caused by electrical potentials generated when the **atria depolarize** before atrial contraction begins. The **QRS complex** is caused by potentials generated when the **ventricles depolarize** before contraction, that is, as the depolarization wave spreads through the ventricles.
→ Therefore, both the P wave and the components of the QRS complex are **depolarization waves**.
- The T wave is caused by potentials generated as the ventricles recover from the state of depolarization. The **T wave** is known as a **repolarization wave**.



In conclusion, the ECG is composed of both depolarisation and repolarization waves.

During each cardiac cycle, we record atrial depolarisation, ventricular depolarisation and ventricular repolarization. But what about atrial repolarization? Atrial repolarization occurs at the same time as ventricular depolarisation, and since the depolarisation of the ventricles is strong, it masks the repolarization of atria and that's why it doesn't show in the record.



The recording of ECG shows repeated cycles of P, QRS and T waves. The interval between 1 R and the following one represents a cardiac cycle. The same applies to each of the intervals between (P-P, T-T, S-S and Q-Q) but the R-R interval is the most definite one with significant sharp peaks.

The number of electrical cardiac cycles per minute is equal to the number of heart beats per minute (normally ranges from 60 to 100 BPM). Which means that we can calculate the heart rate using ECG.

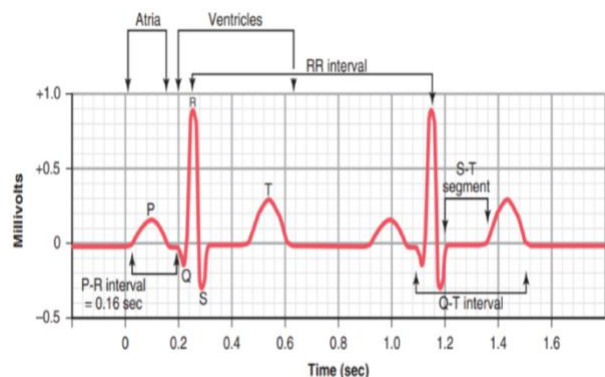


Figure 11-1. Normal electrocardiogram.

❖ Standardised (ECG):

- Time and voltage calibrations are standardised by putting a heat-sensitive vapor under the pointer of the electrocardiograph. Underneath this pointer, is a paper that is squared.
- The horizontal calibration lines (Y-axis) are arranged so that each 10 small squares upward or downward in the standard ECG represent 1 millivolt, with positivity in the upward direction and negativity in the downward direction.
- The vertical lines (X-axis) are time calibration lines. A typical ECG is run at a paper speed of 25 millimetres per second. Therefore, each 25 millimetres in the horizontal direction is 1 second, and each 5-millimetre segment (big square), indicated by the dark vertical lines, represents 0.20 second. The 0.20-second intervals are then broken into five smaller intervals by thin lines (5 small squares), and each small square represents 0.04 second.
- Now let's discuss the intervals and segments that are recorded in normal ECG:

1. Intervals:

- The term interval refers to a period that contains a wave

a) The P-Q or P-R Interval:

- The first interval that shows in normal ECG is the P-Q interval (often this interval is called the P-R interval because the Q wave is likely to be absent).
- The normal P-R interval is about 0.16 second and it represents the time between the beginning of electrical excitation of the atria and the beginning of excitation of the ventricles.

b) The QRS Interval:

- Represents the period of ventricular depolarisation

c) The Q-T interval:

- Extends from the beginning of ventricular depolarisation to part of ventricular repolarization.
- Contraction of the ventricles lasts almost from the beginning of the Q wave (or R wave, if the

Q wave is absent) to the end of the T wave. This interval ordinarily is about 0.35 second.

d) The R-R Interval:

- Represents the duration of the cardiac cycle
 - If the time between 2 successive R is 20 small squares, and each small square as mentioned above is 0.04 sec, then the cardiac cycle is 0.8 sec.
 - Now the question is, if each cardiac cycle takes 0.8 sec, how many cardiac cycles are in 1minute (60 seconds)? ($60\text{sec}/0.8\text{sec}=75\text{beats/minute}$).
 - If the R-R interval is 15 small squares→cardiac cycle is 0.6 sec→heart rate = 100BPM.
 - If the R-R interval is 25 small squares→cardiac cycle is 1 sec→heart rate = 60BPM.
- **In conclusion**, the heart rate is inversely proportional to the duration of the cardiac cycle.

2. Segments:

- Segments are the isoelectric (flat) lines between the end of a wave and the start of another. Thus, a segment doesn't contain waves.

- Here we study the deflection of these segments (depression or elevation) not time

a) P-R segment: the isoelectric line between the end of P to the beginning of R.

b) S-T segment: the isoelectric line between the end of S to the beginning of T.

-A deflected S-T segment (whether depressed or elevated) denotes ischemia to the muscle (decreased blood flow to the muscle) → might end with infarction (no blood flow).

c) T-P segment:the isoelectric line between the end of T to the beginning of P.

Relationship of Atrial and Ventricular Contraction to the Waves of ECG

Record of electrical events in the myocardium can be correlated with mechanical events

P wave:

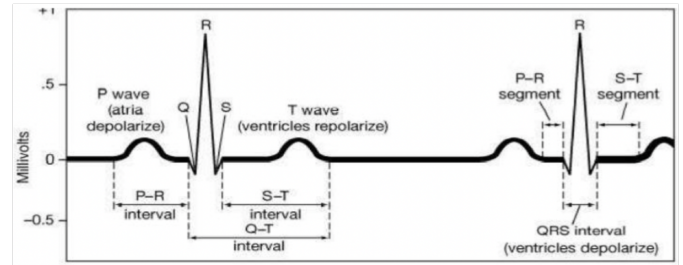
- Depolarisation of atrial myocardium
- Signals onset of atrial contraction (Atrial systole)

QRS complex:

- Ventricular depolarisation
- Signals onset of ventricular contraction (Ventricular systole)
- Should be equal to 0.12 sec

T wave:

- Repolarization of ventricles
- Signals onset of ventricular relaxation (Ventricular diastole)



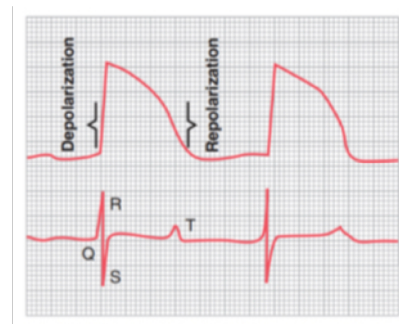
PR interval or PQ interval:

- Extends from beginning of atrial depolarisation to beginning of ventricular depolarisation (QRS complex)
- It is prolonged by the delay caused by the AV node (in order for ventricular systole to occur after atrial diastole)
- The maximum accepted PR interval is 0.2 sec; can indicate damage to the conducting pathway or AV node if greater than 0.20sec

Q-T interval:

- Time required for ventricles to undergo a single cycle of depolarisation and repolarization
- It usually equals half the duration of the cardiac cycle (0.35-0.45sec)
- Can be lengthened by electrolyte disturbances, conduction problems, coronary ischemia, myocardial damage

****Remember** that in order to record the potential difference (ECG), we place the electrodes on the surface of the muscle fibre (Biphasic action potential). However, in order to record the mono-phasic action potential, the electrodes are placed one inside the cell and the other outside.



Flow of Electrical Currents in the Chest Around the Heart

Ventricular depolarization starts at the ventricular septum and the endocardial surfaces of the heart and spreads to both ventricles at the same time.

- When one portion of the ventricles depolarizes and therefore becomes electronegative with respect to the remainder, electrical current flows from the depolarised area to the still- polarised area in large circuitous routes, as noted in the figure.

In other words, the electrical current flows from a negatively charged area to a positively charged one.

- Each current is a vector (has a magnitude and a direction).

We can calculate an instantaneous mean of the current flow when the heart is partially polarised.

Since it's instantaneous, we get different means every time so we must calculate a resultant vector.

- Since we are talking about ventricular depolarisation, then the vector is QRS. We know that right and left ventricles contract simultaneously, therefore there are currents going towards the left and towards the right at the same time, but since the force of contraction in the

left ventricle is way stronger than that of the right, we can conclude that the mean QRS vector is directed anteriorly, inferiorly and to the left. As in, the average current flows positively from the base of the heart to the apex.

