



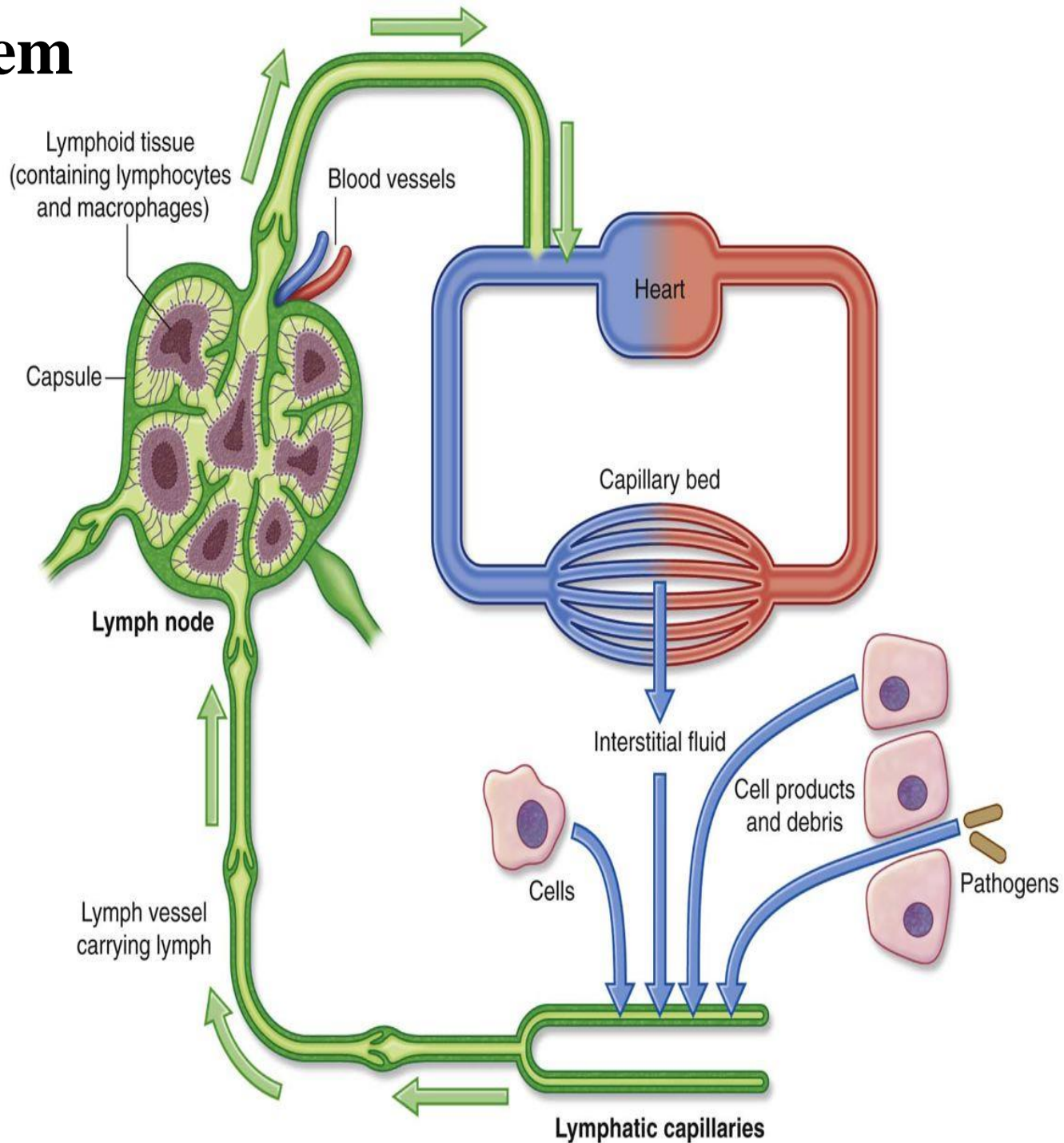
# Lymphatic System

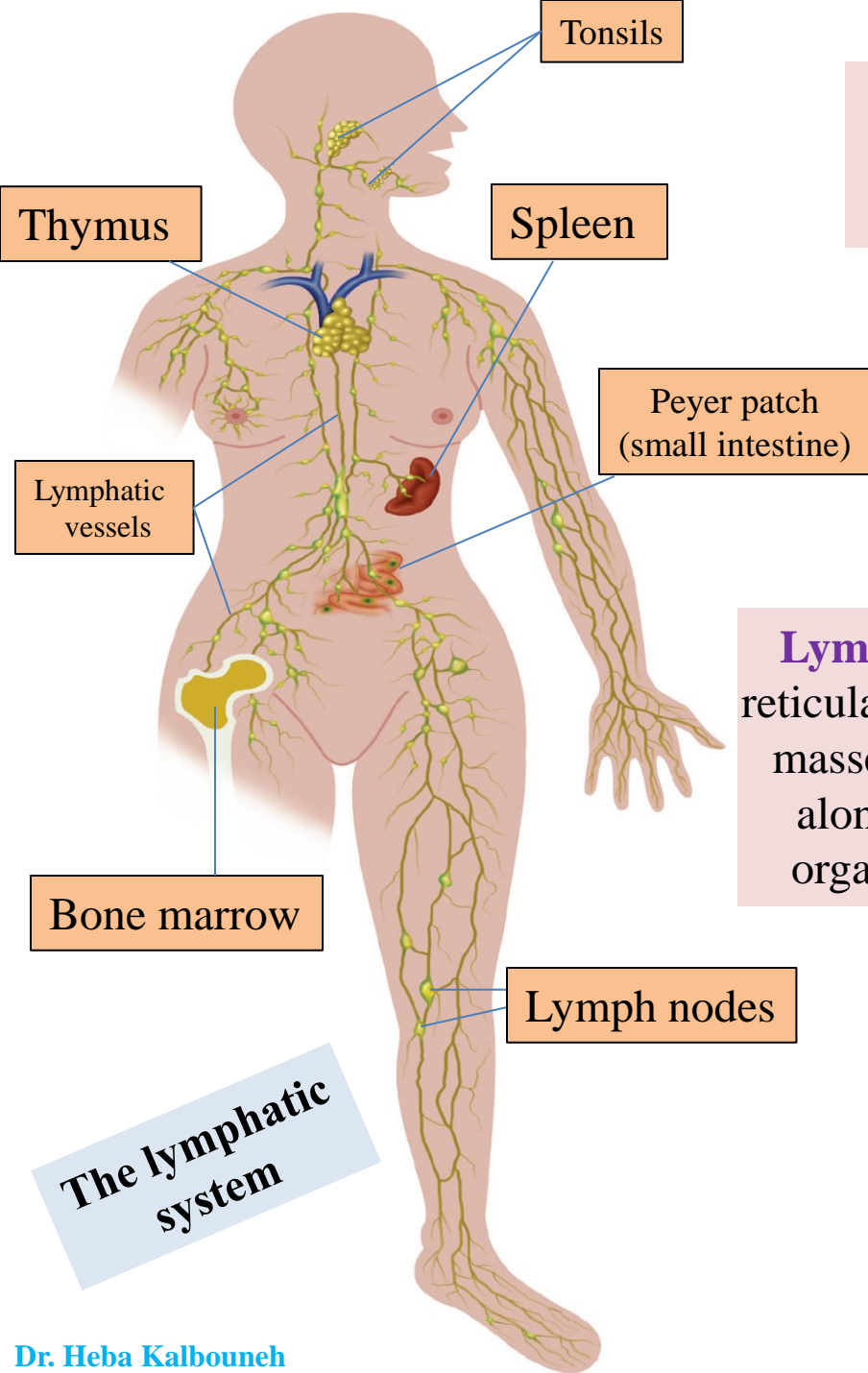
Dr. Heba Kalbouneh  
Associate Professor of Anatomy and Histology

# Lymphatic system

The lymphatic system consists of lymphatic fluid, lymphatic vessels, lymphatic tissue, and lymphatic organs located throughout the tissues of the body. It functions to:

- 1- Drain excess interstitial fluid from the tissues and return to blood stream**
- 2- Initiate an immune response against disease by producing and transporting lymphocytes**
- 3- Transport dietary lipids absorbed by the gastrointestinal tract into the blood.**





**Lymph** is a colorless fluid that floats in the lymphatic vessels. It is similar in composition to blood plasma

**Lymphatic vessels** are thin vessels that accompany arteries and veins throughout the body and transport lymph.

**Lymphatic tissue** is a specialized form of reticular connective tissue that is composed of masses of lymphocytes. These either occur alone as lymph nodules (follicles) or are organized into various lymphatic organs.

**Lymphatic organs** include the lymph nodes, spleen, thymus, and red bone marrow

# Fluid balance

The tissues of the body are supplied by blood capillaries that bring oxygen-rich blood and remove carbon dioxide-rich blood.

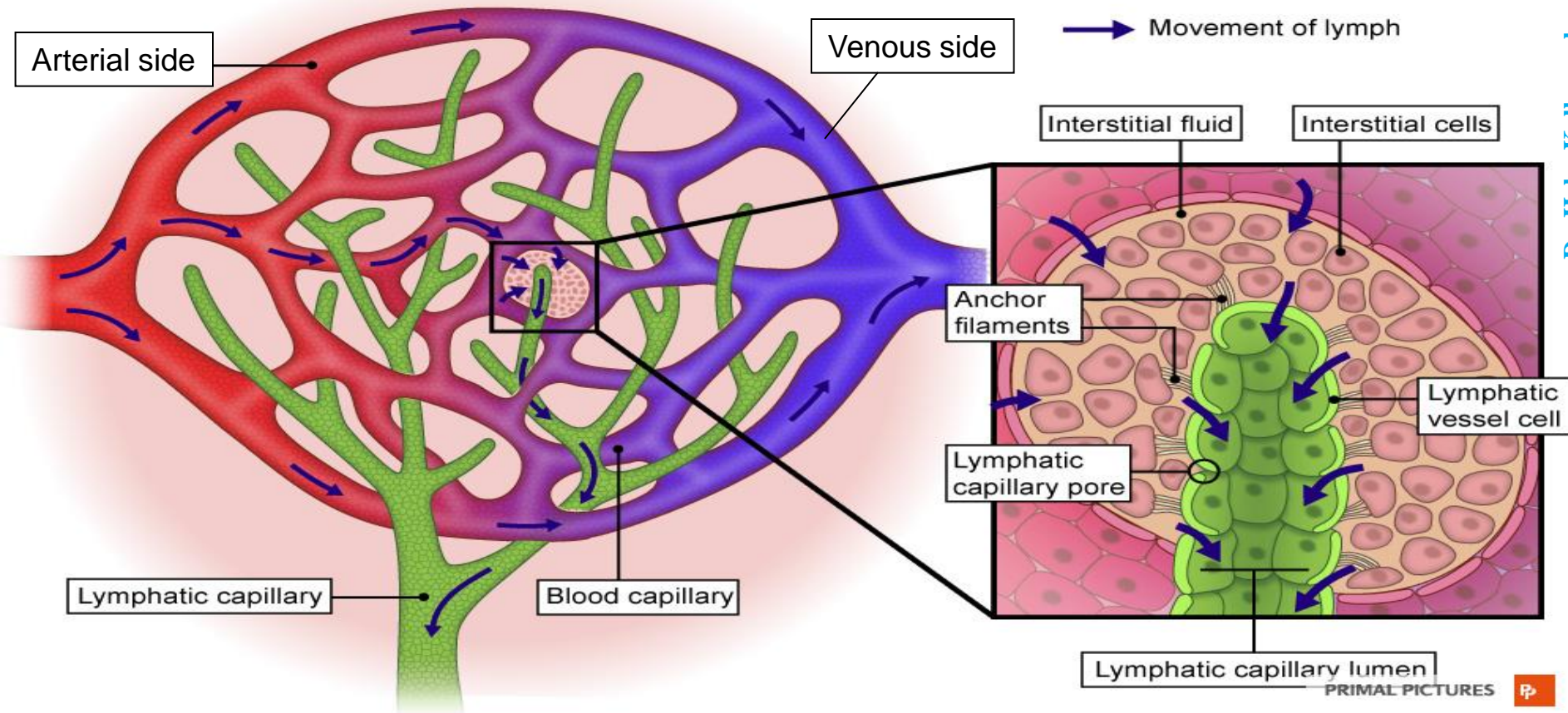


Fluid similar to blood plasma, called **interstitial fluid**, leaches from these vessels into the surrounding tissue.

Around 20 liters of fluid leaves the arterial capillaries every day, but only 17 liters of fluid returns to the venous capillaries.

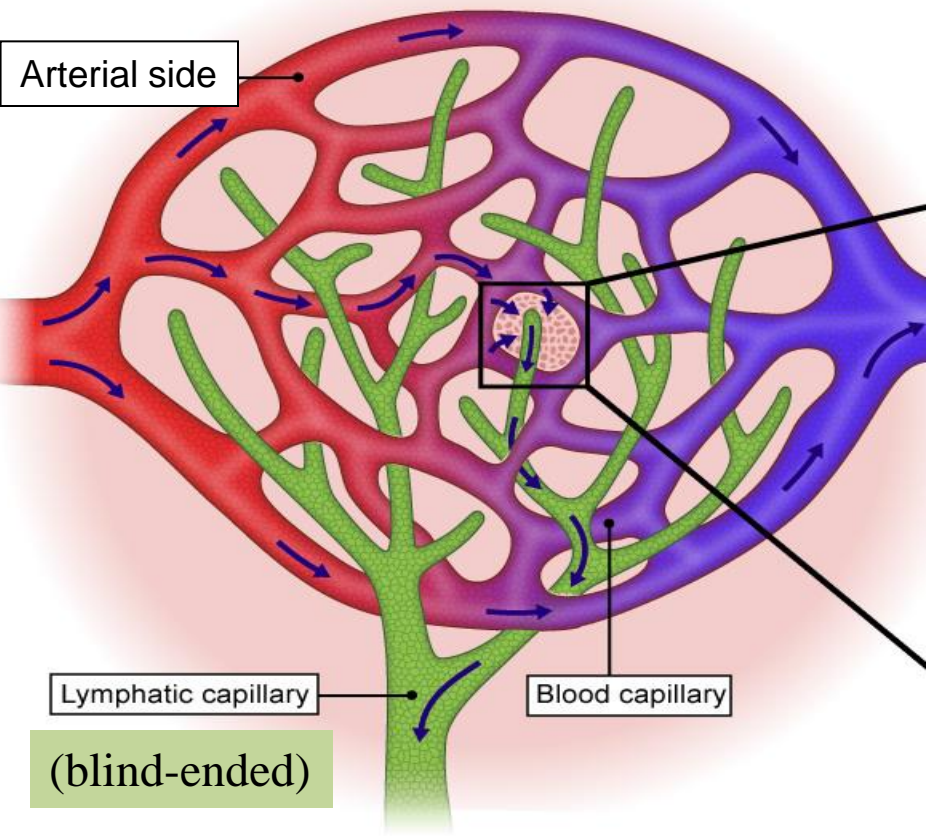
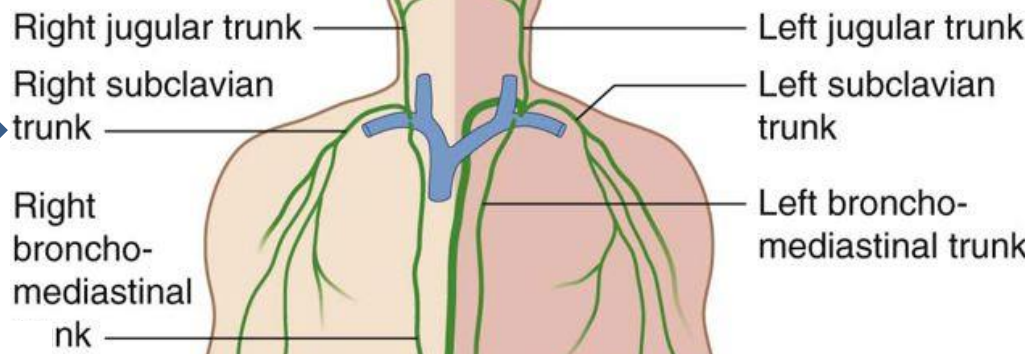


Lymphatic vessels function to drain this excess fluid from the tissues as lymph and return this fluid to the blood.

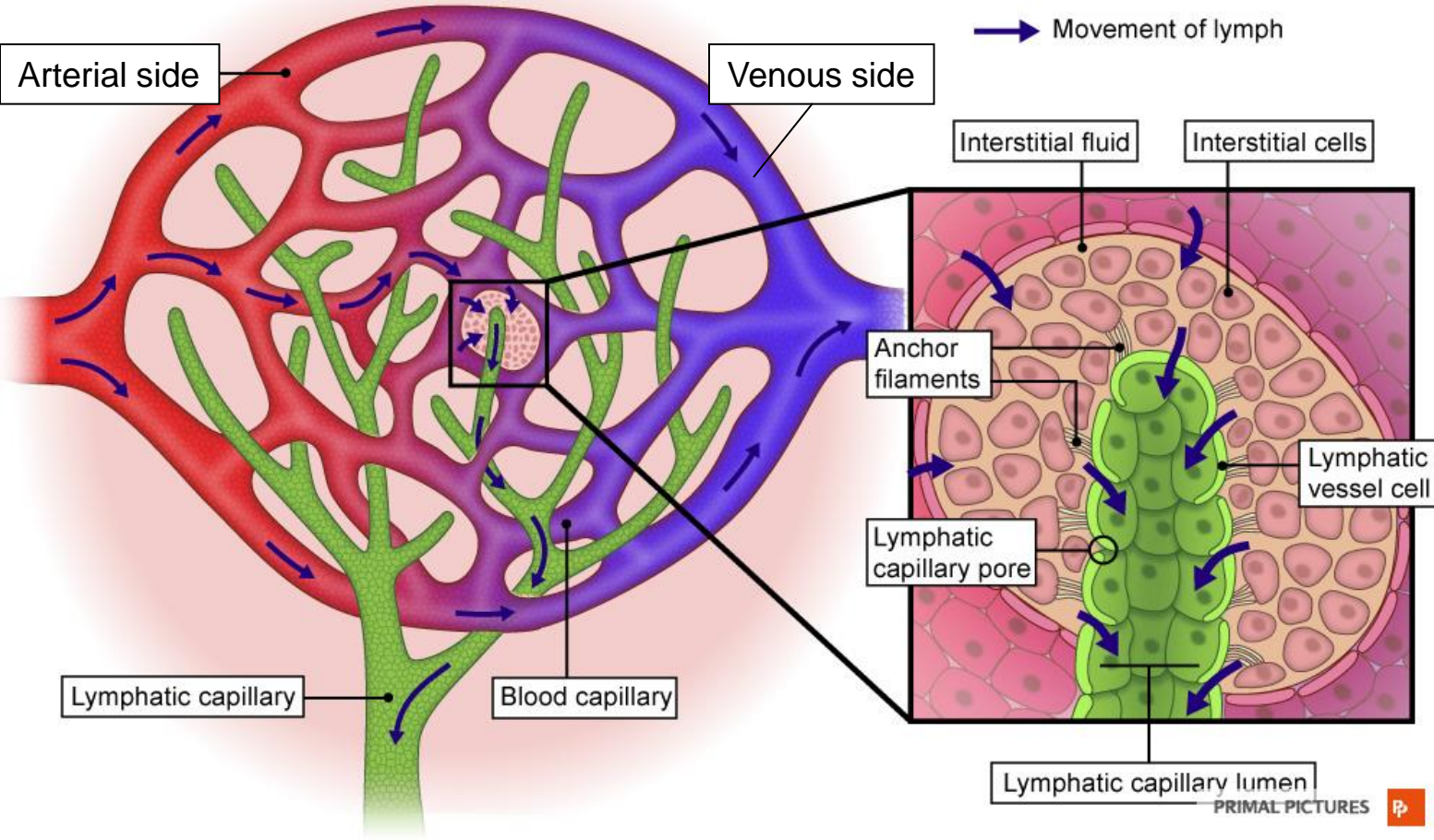


Dr. Heba Kalbouneh

**Lymphatic vessels** begin as “porous” blind-ended lymphatic capillaries in tissues of the body and converge to form a number of larger vessels, which ultimately connect with large veins in the root of the neck.



Lymph returns back to the big veins (**venous angle**: the junction between subclavian and internal jugular veins) through the Thoracic duct and Right lymphatic duct.



Lymphatic capillaries are made of overlapping endothelial cells with large gaps. The overlapping flaps function as a one-way valve.

When fluid accumulates in the tissue, interstitial pressure increases pushing the flaps inward, opening the gaps between cells, allowing fluid to flow in.

As pressure inside the capillary increases, the endothelial cells are pressed outward, closing the gaps, thus preventing backflow.

Unlike blood capillaries, the gaps in lymphatic capillaries are so large that they allow bacteria and immune cells (ex. Macrophages/ dendritic cells) to enter. This makes the lymphatic system a useful way for large particles to reach the bloodstream.

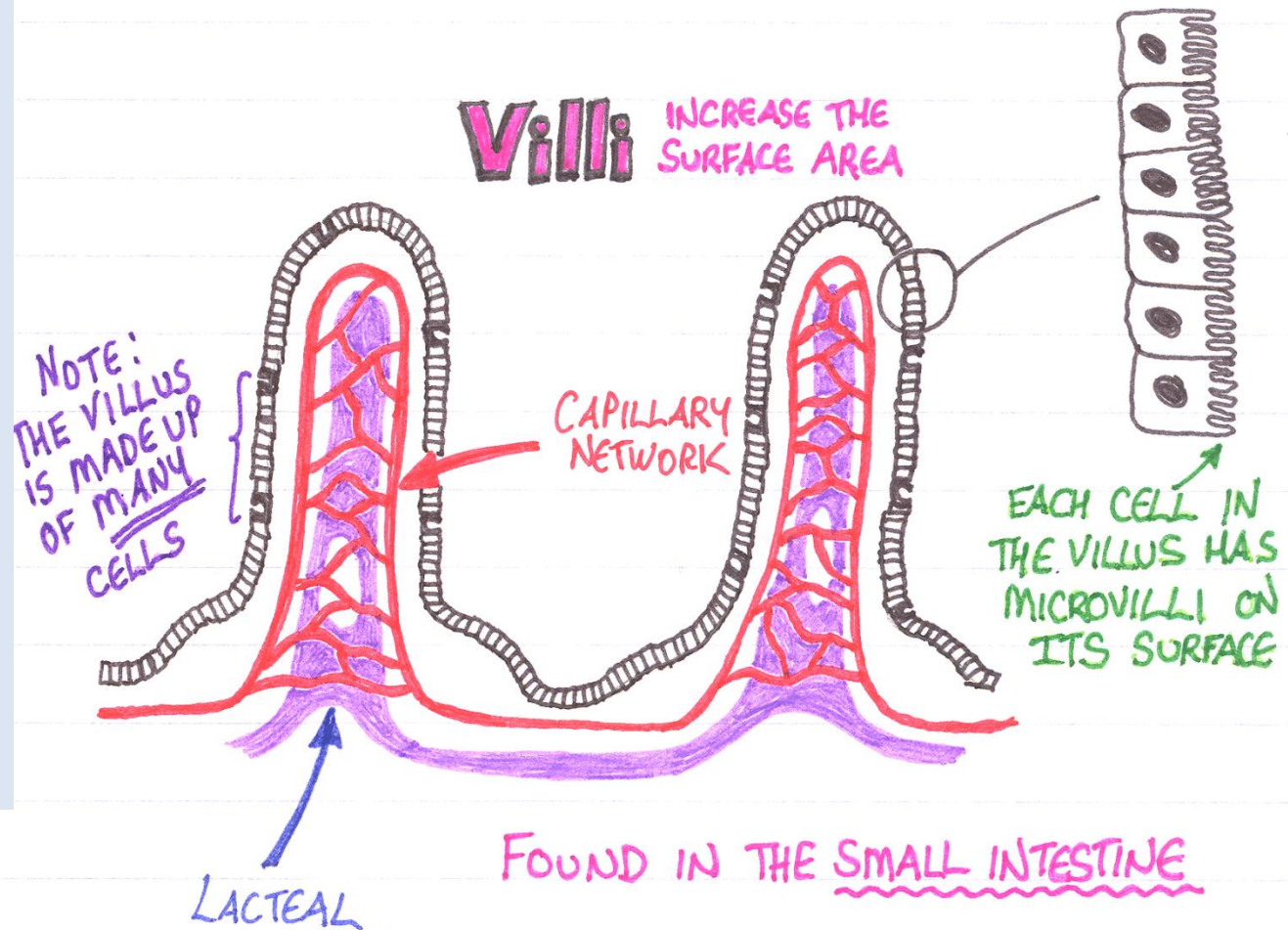
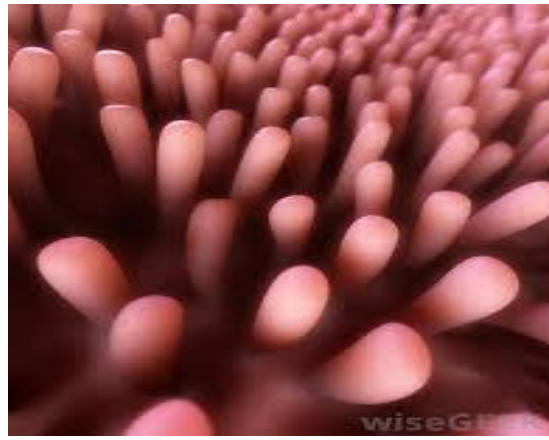*Remember: lymphatic system is used, for example, for dietary fat absorption in the intestine.*

# Transport

Some lipids are too large to pass through the capillary walls of the small intestine and therefore cannot be absorbed.



The lymphatic capillaries within the small intestine, known as **lacteals**, can absorb these large lipid molecules and transport them into the venous circulation via the thoracic duct. Lymph containing these lipids becomes a creamy white color and is referred to as **chyle**.



# Lymphatic Organs and Tissues

Lymphocytes can be found throughout the body, however, they aggregate in places where they are most likely to come into contact with pathogens.

Lymphocytes are produced within the red bone marrow and are transported via the blood vessels to lymphatic tissues and organs.

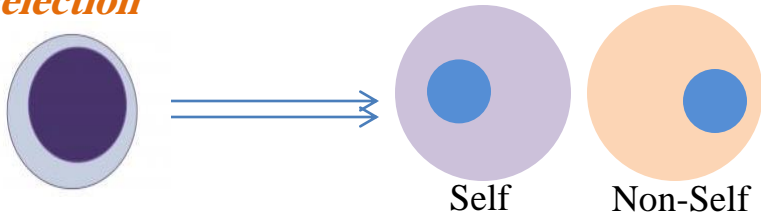
Lymphatic organs are divided into:

## Primary lymphatic organs

**Bone marrow.**

**Thymus gland.**

*Are sites of Lymphocyte production, maturation, selection*



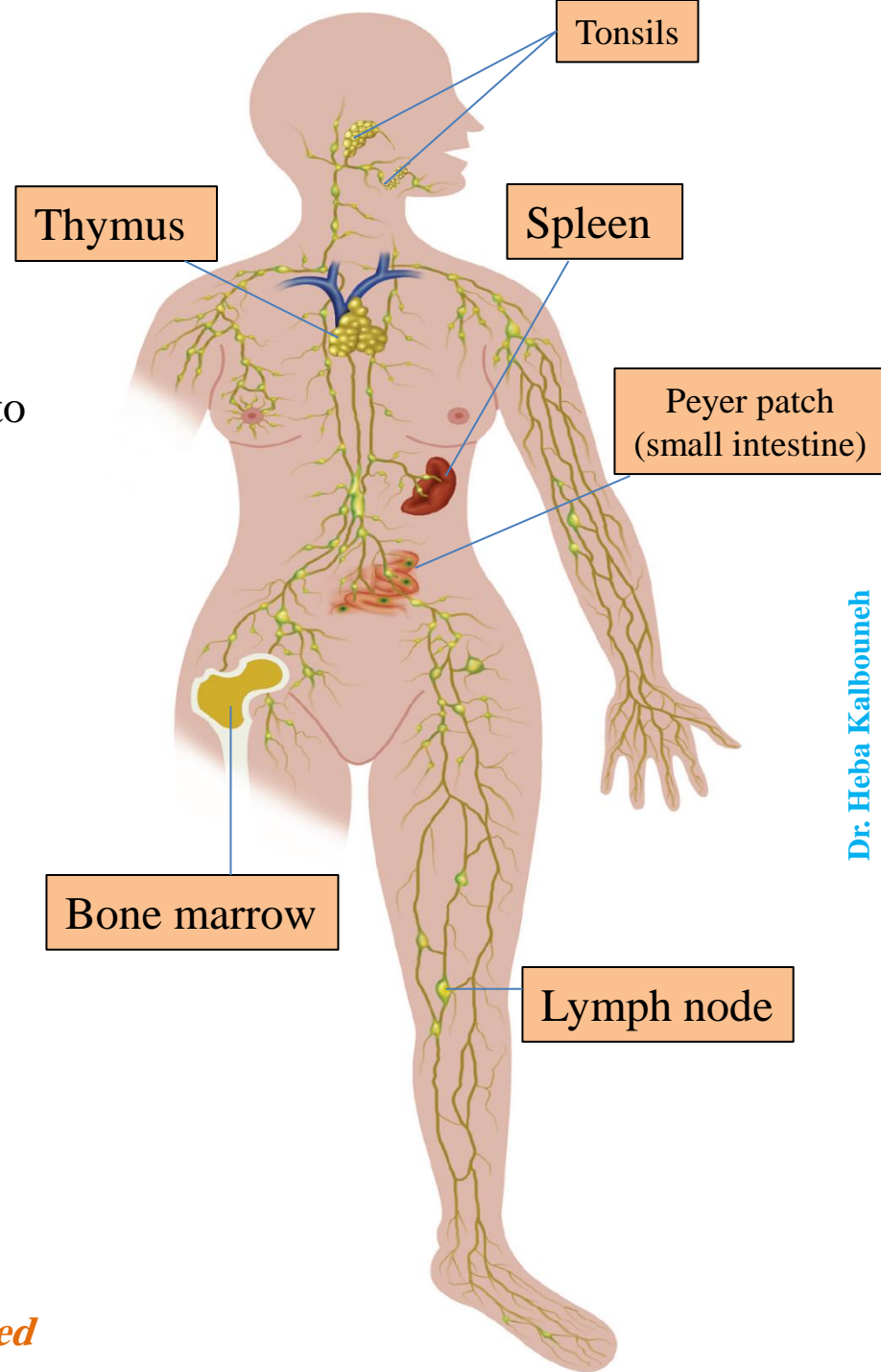
## Secondary lymphatic organs

**Diffuse lymphatic tissue (lymphatic nodules).**

**Spleen.**

**Lymph nodes.**

*Are sites to encounter pathogens and become activated*

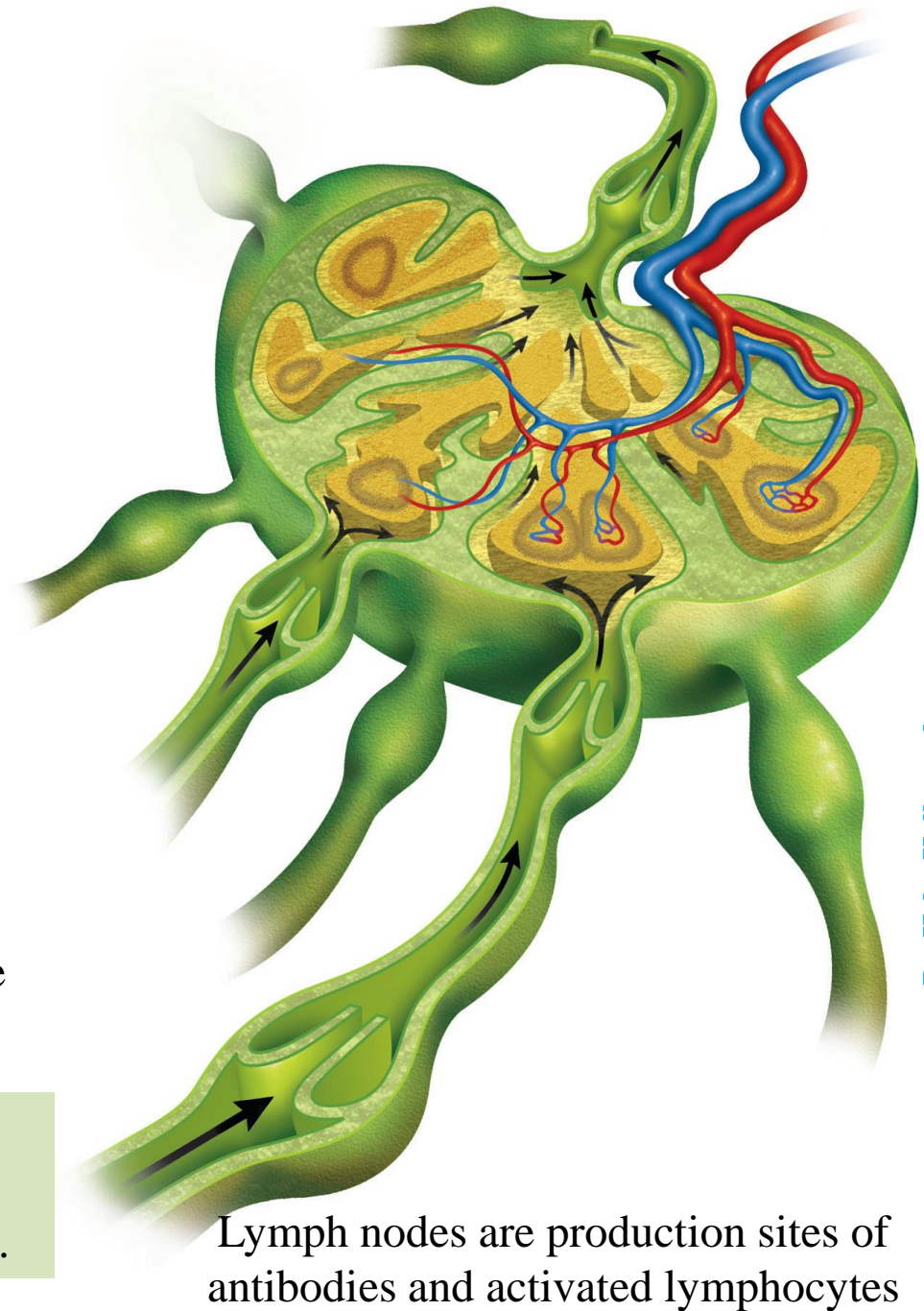




# Lymph nodes

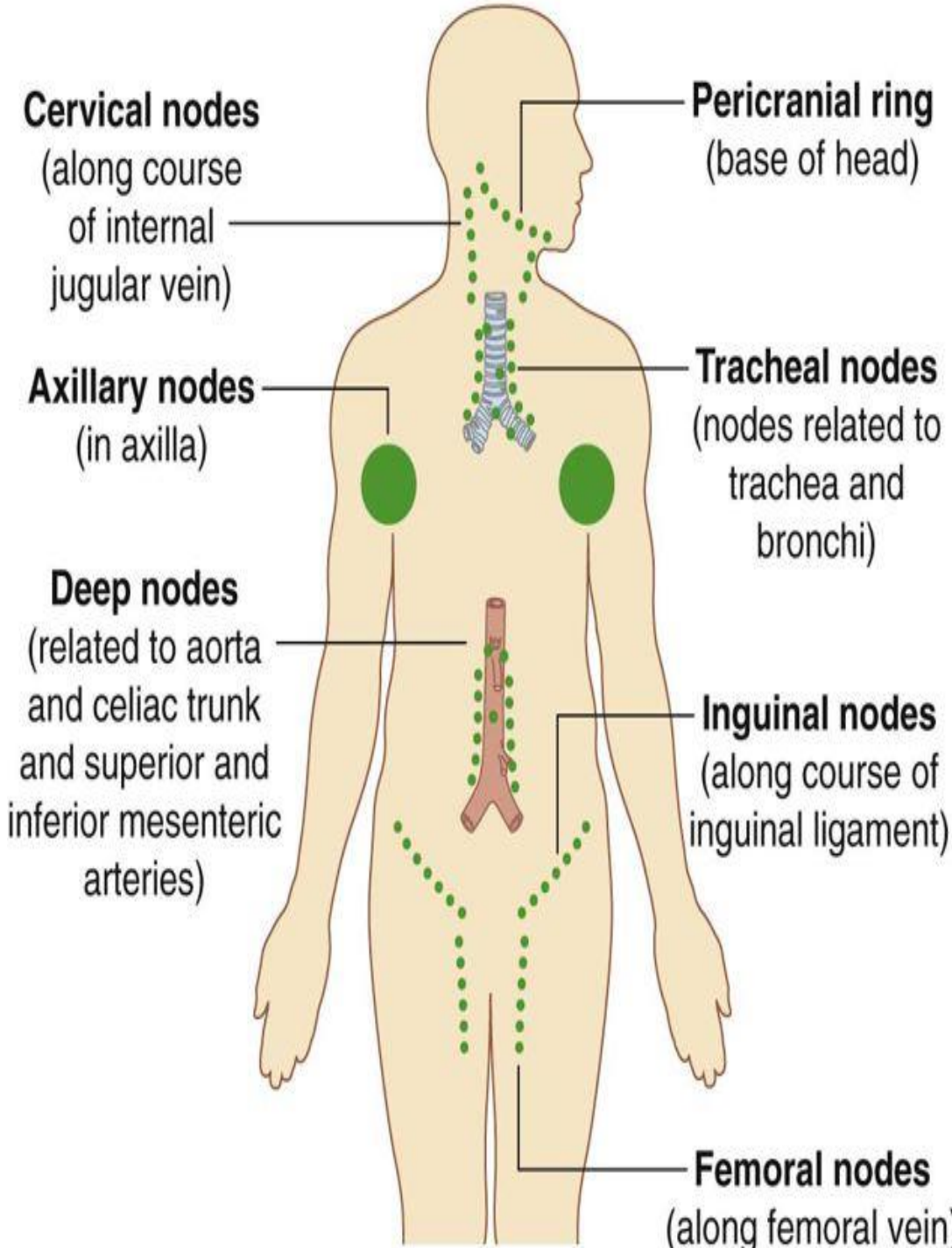
- ✓ Are kidney-shaped small encapsulated bodies located along the course of lymphatic vessels (Approximately 600 lymph nodes )
- ✓ Reticular tissue forms the stroma of the lymph node
- ✓ Lymph nodes are up to 3 cm in length
- ✓ Immunocompetent B cells and T cells are suspended throughout the lymph node
- ✓ Nodes filter the lymph, removing foreign material and microorganisms.
- ✓ All lymph is filtered by at least one lymph node before it returns to the blood.
- ✓ Antibody- mediated and cell- mediated immune responses occur in the lymph nodes
- ✓ Lymph nodes congregate around blood vessels in clusters and are usually named according to the vessel or location that they are associated with.

Lymph node enlargement can happen in cases of lymphoma (painless lymphadenopathy) or infection (painful).

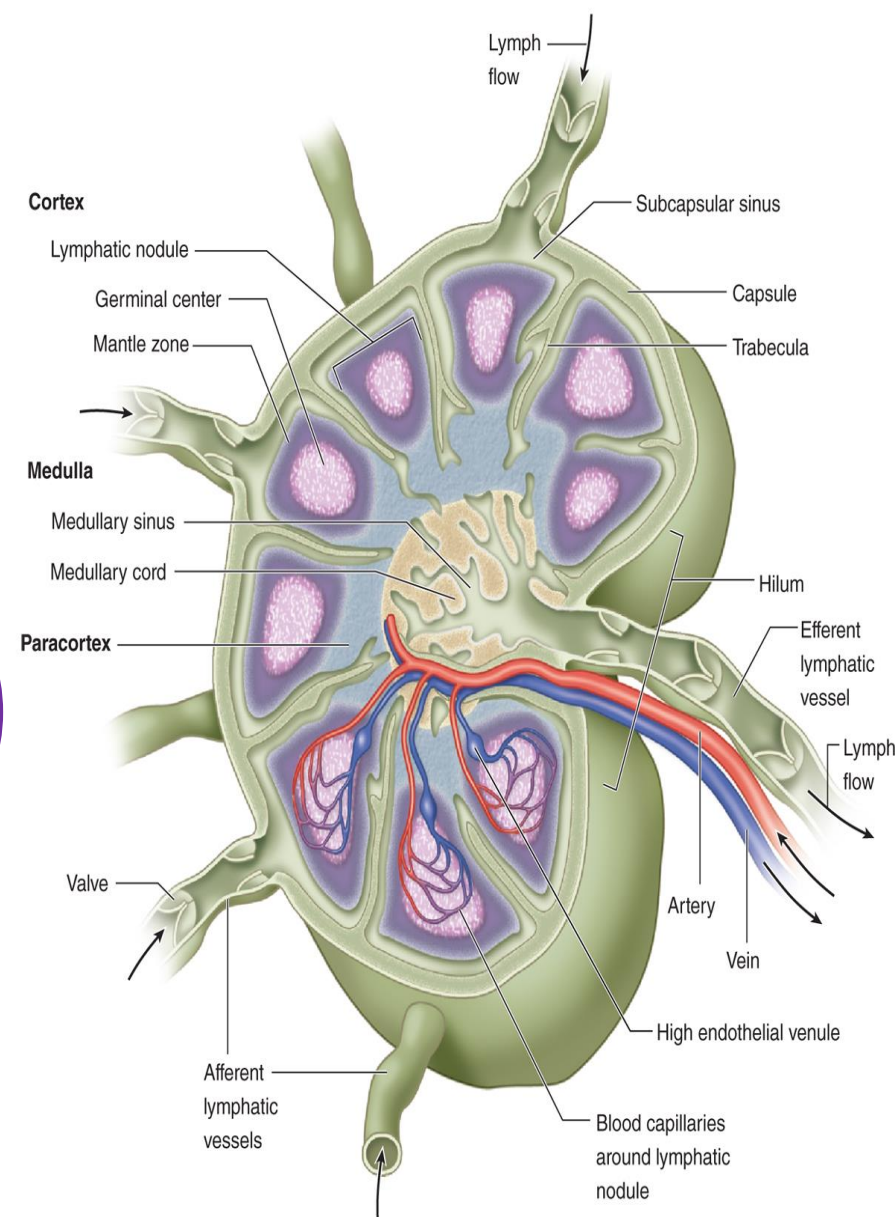
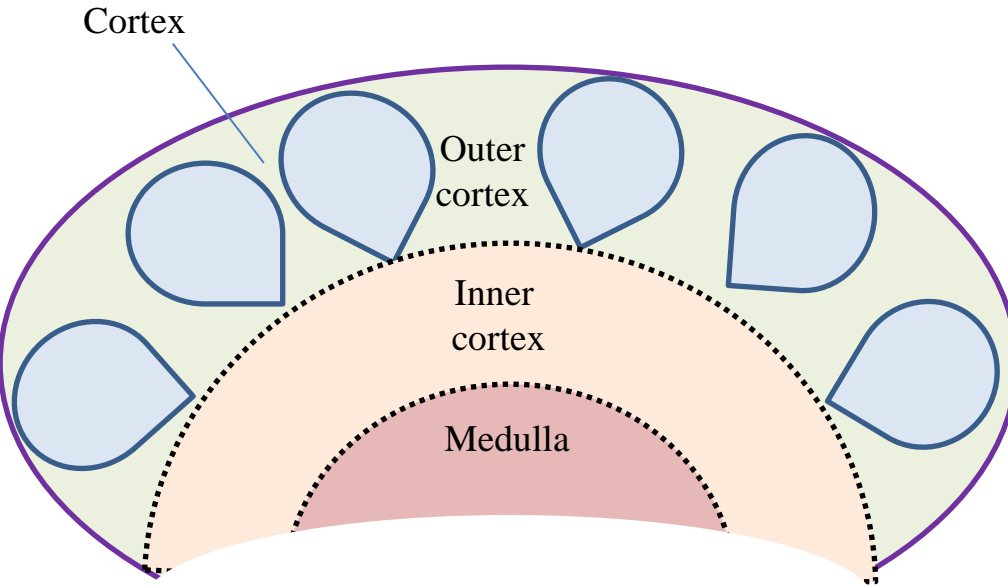


The main groups of lymph nodes include:

Name	Location	Associated vessel
Axillary nodes	Armpit	Axillary vein
Cubital nodes	Elbow	Basilic vein
Popliteal nodes	Posterior knee	Popliteal vein
Inguinal nodes (superficial and deep)	Groin	Great saphenous vein Femoral vein
Cervical lymph nodes (superficial and deep)	Neck	Internal jugular vein External jugular vein

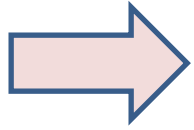


The lymph node consists of an outer cortex and an inner medulla



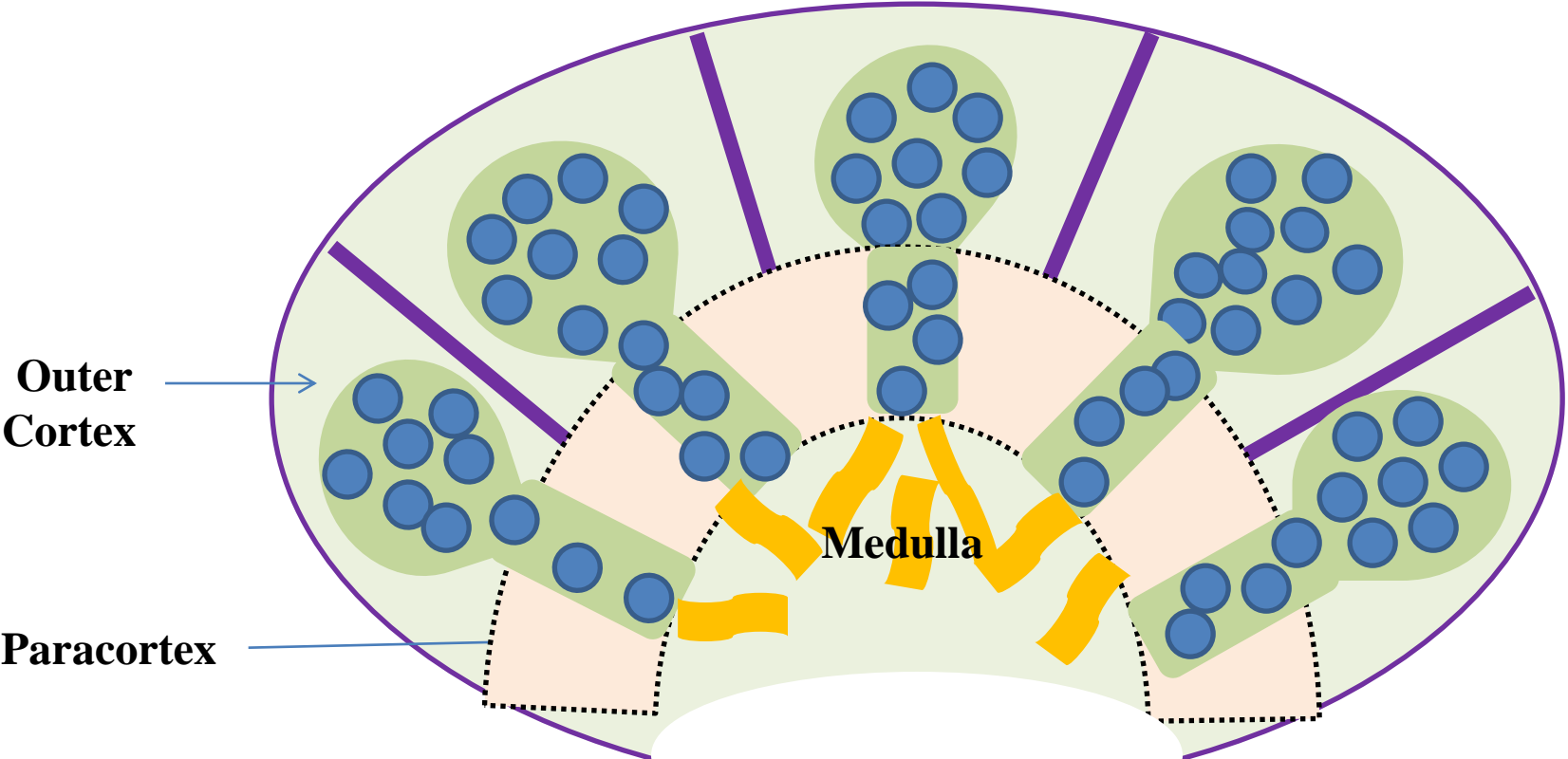
Cortex	Medulla
Contains lymphatic follicles	No follicles
Receives lymph from afferent vessels	Forms sinuses that lead to efferent vessels at the hilum

The nodes are covered by a **capsule** of dense connective tissue, and have capsular extensions called the **trabeculae**, which provide support for blood vessels entering into the nodes.



*When lymph nodes become enlarged, the capsule is stretched and becomes painful*

The cortex is the outer, highly cellular part of the lymph node; it can be divided into an outer cortex and inner paracortex.



Dr. Heba Kalbouneh

The **outer cortex** has lymphatic follicles that mostly contain **B-cells**.

The **inner cortex (paracortex)** contains mostly **T-cells**.

The **medullary cords** contain mostly **plasma cells**.

Both the macrophages, and the dendritic cells trap antigens and present them on their surfaces

As B cells in lymphatic follicle are stimulated, they differentiate into plasma cells. Plasma cells move to medulla (medullary cords)

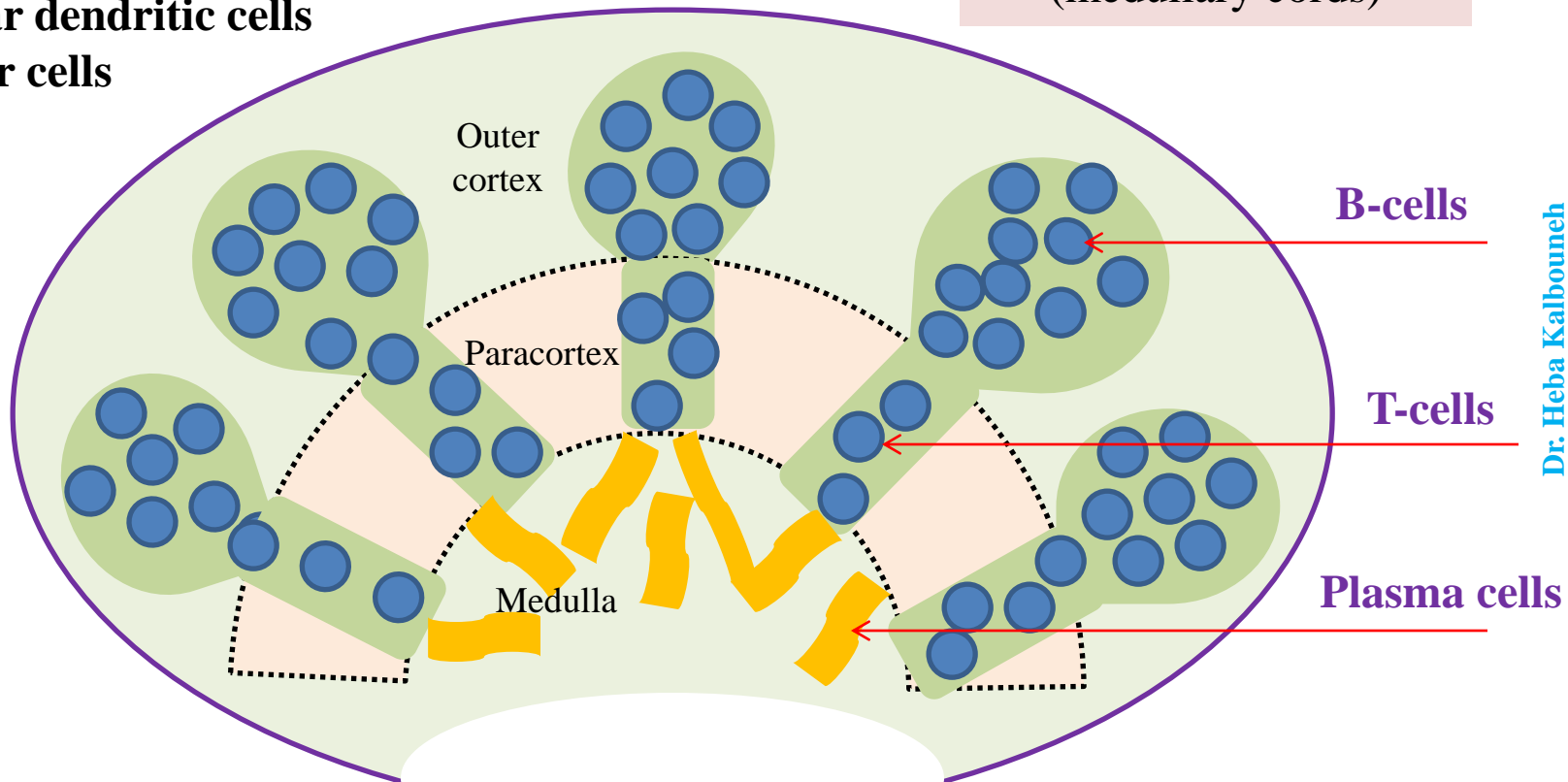
Other cells in the lymph node:

**Macrophages**

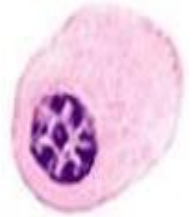**Dendritic cells**

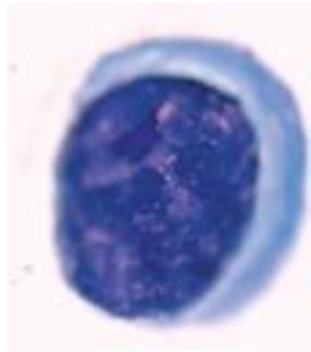
**Follicular dendritic cells**

**Reticular cells**



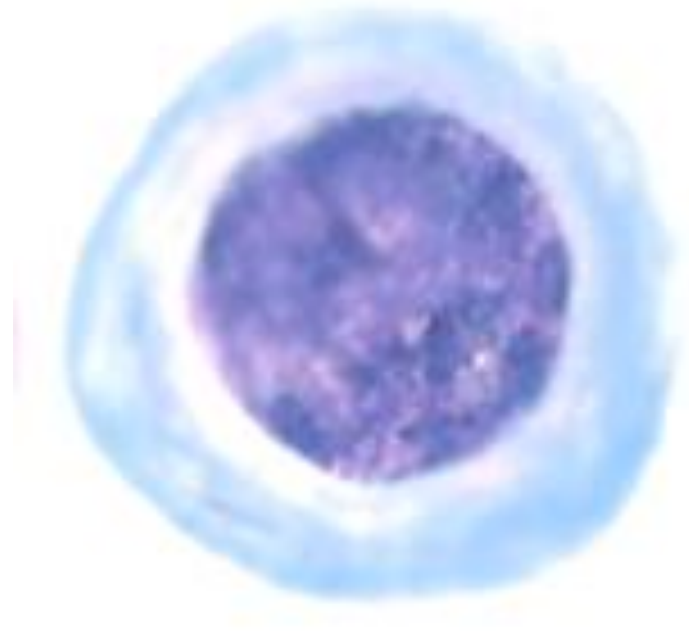
Plasma cell





Small  
(6-9  $\mu\text{m}$ )  
Inactive lymphocyte

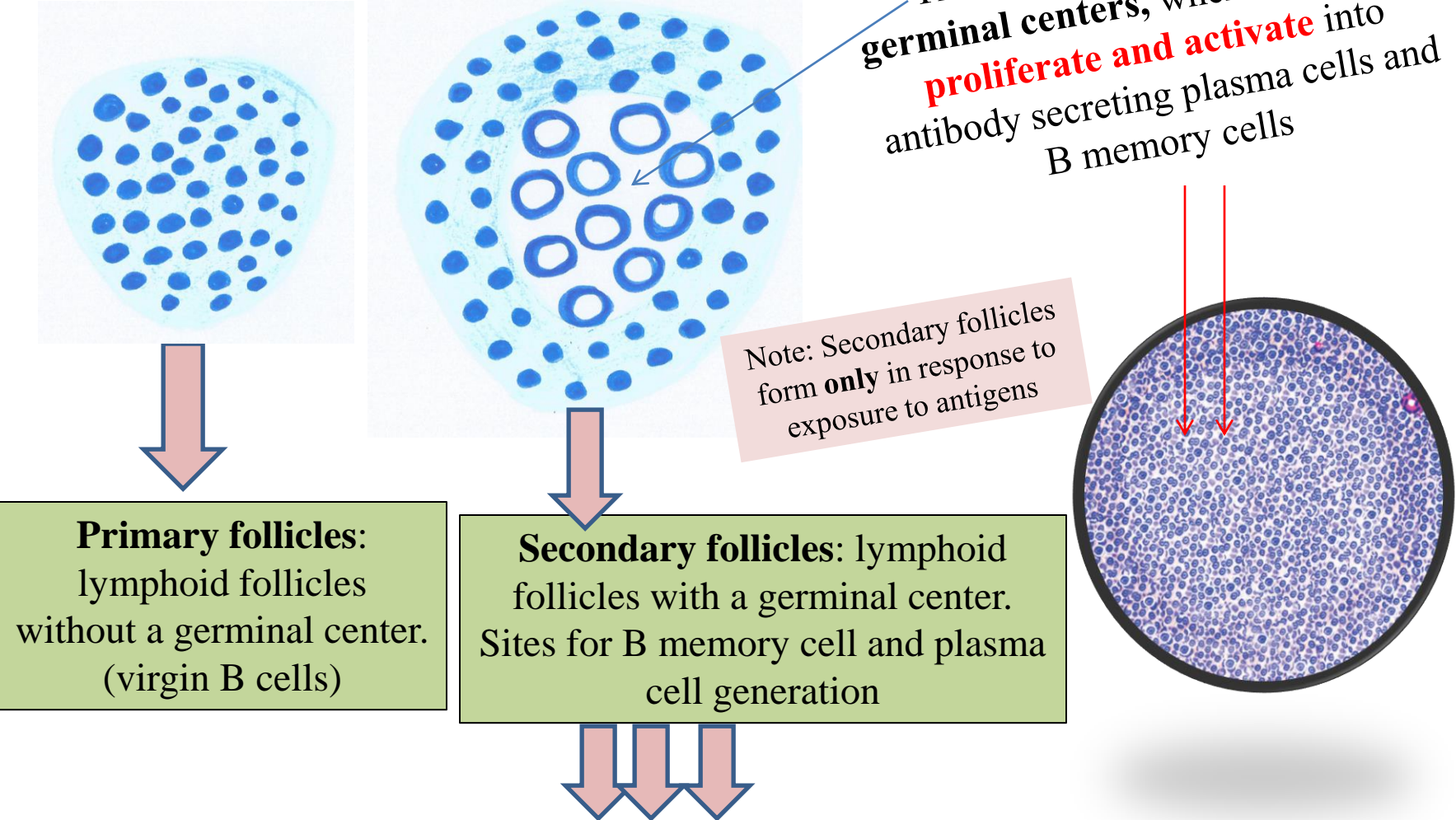
Darkly stained cell



Large  
(9-18  $\mu\text{m}$ )  
Active lymphocyte

Lightly stained cell

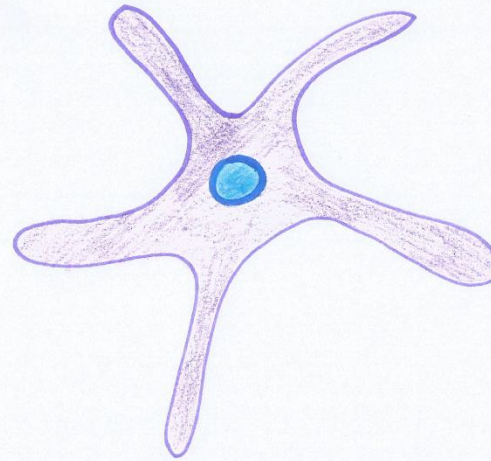
The outer cortex houses lymphatic follicles (nodules) which are of two types:



When activated by antigens (and T helper cells), B cells migrate to the center of the follicle, forming a germinal center. Germinal centers are the central regions of secondary follicles where activated B cells are proliferating (dividing by mitosis) and differentiating into plasma cells and memory B cells. When stimulated by antigens, lymph nodes enlarge due to the formation of germinal centers and B cell proliferation



Macrophage

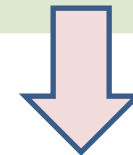
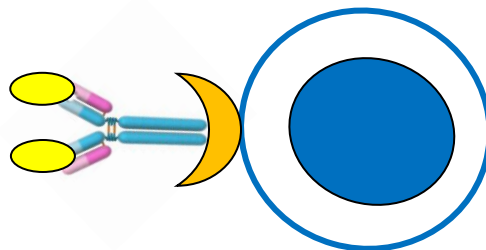


Dendritic cell

Macrophages and Dendritic cells capture antigen within tissues and transport antigen to secondary lymphoid tissue

	Macrophage	Dendritic cell	Follicular dendritic cell
<b>Phagocytosis</b>	Most phagocytic	Moderately phagocytic	X
<b>Antigen presenting (via MHC-II)</b>	Moderate Ag-presenter	Very powerful Ag-presenter	X
<b>Location in lymph node</b>	Cortex and medulla	Cortex and medulla	Outer cortex

Dr. Heba Kalbouneh



Are antigen **HOLDING** cells  
Holds the Ag for long time

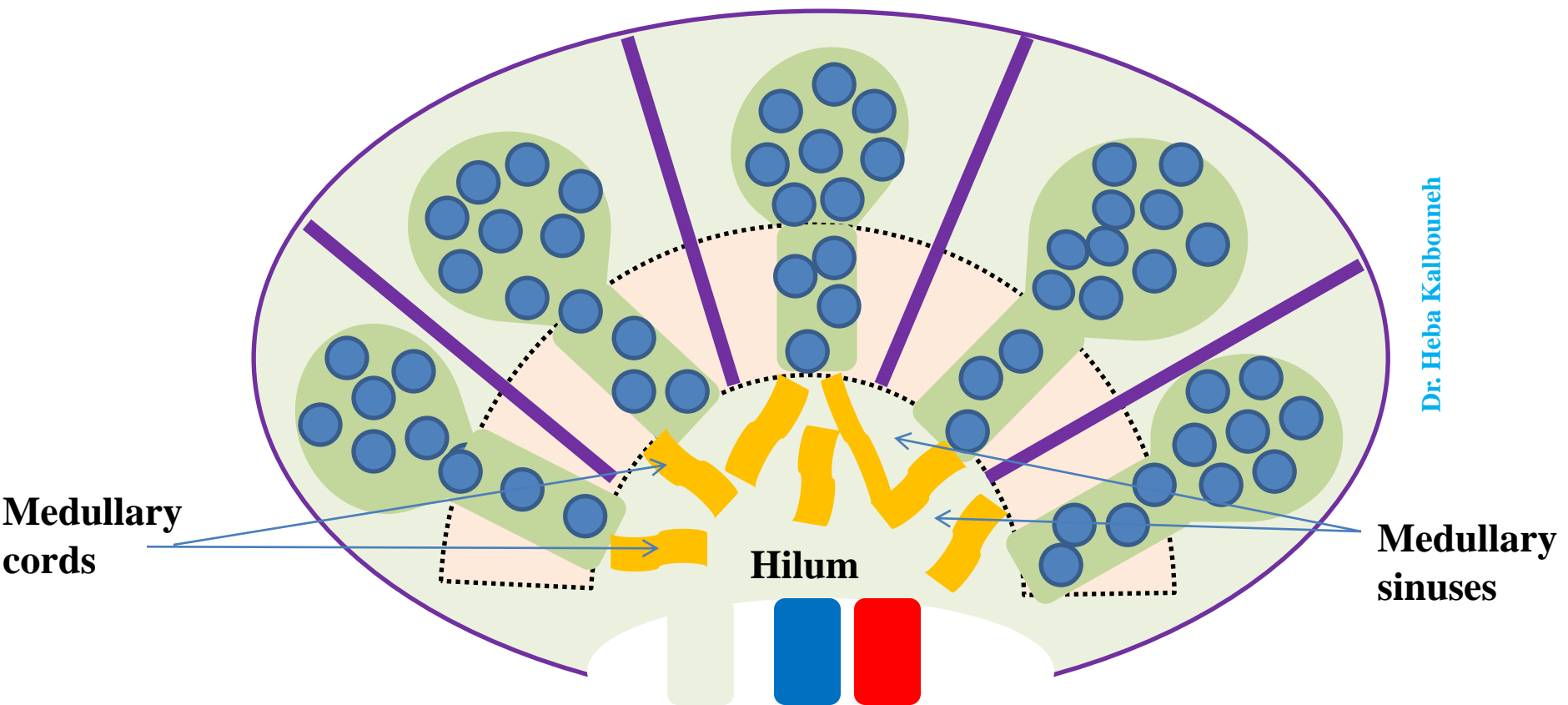


The **medulla** is the deep, cavitated part of the lymph node; it is composed of **medullary cords**

The cords are separated by spaces known as **medullary sinuses**

The medullary sinuses converge at the **hilum**.

The hilum is a slight indentation on one side of the node. Here, an artery, vein, and an efferent lymphatic vessel enter and leave the node.



## Afferent vessels

Many afferent lymphatic vessels enter the lymph node at different points over its convex surface, each containing valves to prevent backflow of lymph.

## Subcapsular sinuses

Each afferent vessel empties into the subcapsular sinus.

## Trabecular sinuses

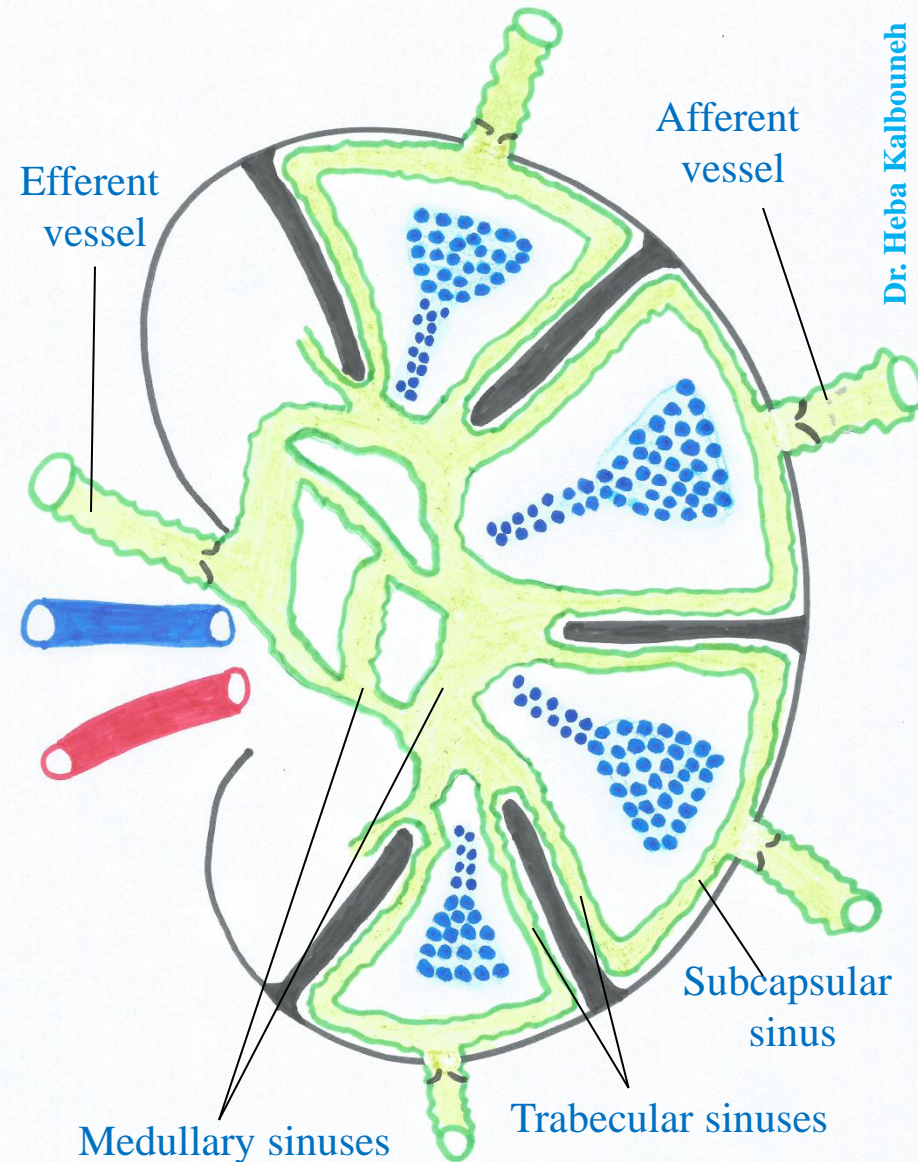
The trabecular sinuses are a continuation of the subcapsular sinuses that follow the trabeculae and drain into the medullary sinuses.

## Medullary sinuses

Found separating the cords. The medullary sinuses converge at the hilum into the efferent lymphatic vessel.

## Efferent vessels

The lymph is removed from the medullary sinus via one or two efferent lymphatic vessels that leave the lymph node at the hilum. Valves in the vessels prevent lymph from flowing in the wrong direction.



**Sinuses are irregular spaces through which the lymph percolates**

## Lymph flow

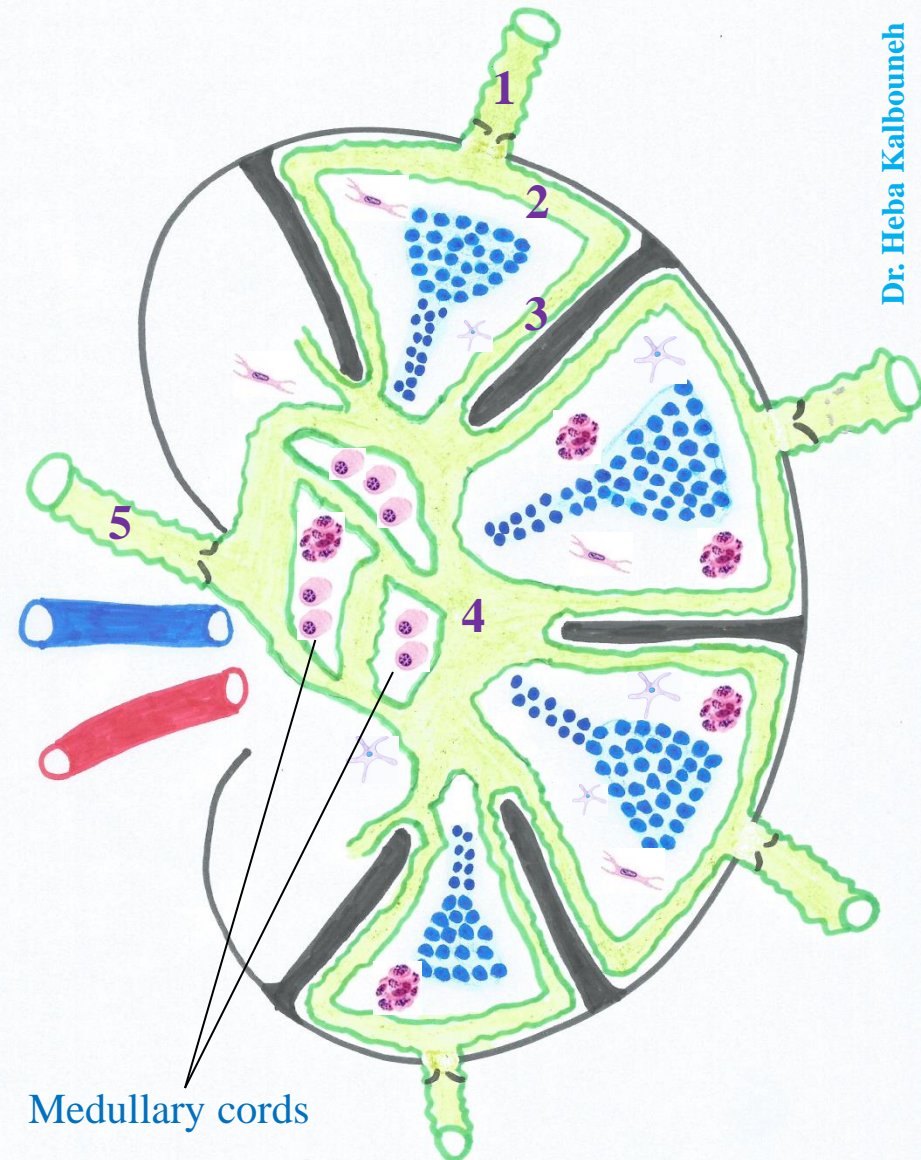
Lymph nodes are linked together by lymphatic vessels. Lymph flows through a lymph node via a series of sinuses and lymphatic tissue

**Lymph**, containing micro-organisms, soluble antigens and antigen presenting cells, enters the lymph node via **afferent lymphatic vessels (1)** which enter the **subcapsular sinus (2)**. It then runs through **trabecular (cortical) sinuses (3)** then into **medullary sinuses (4)** and leaves through the **efferent lymphatic vessels (5)**, at the **Hilum** as **efferent lymph**.



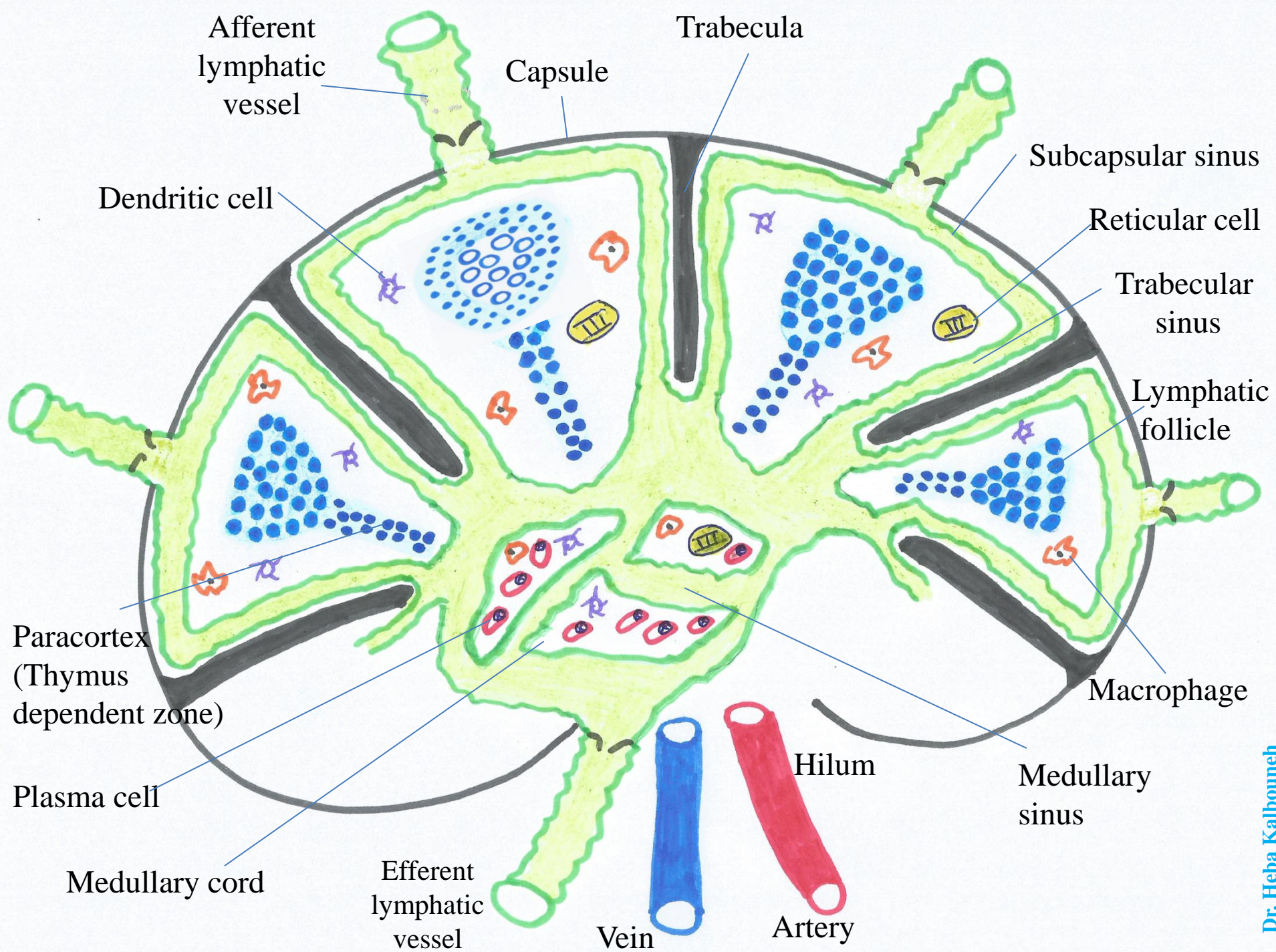
**Efferent lymph** contains lots of activated T-lymphocytes, activated B-lymphocytes, plasma cells and antibodies.

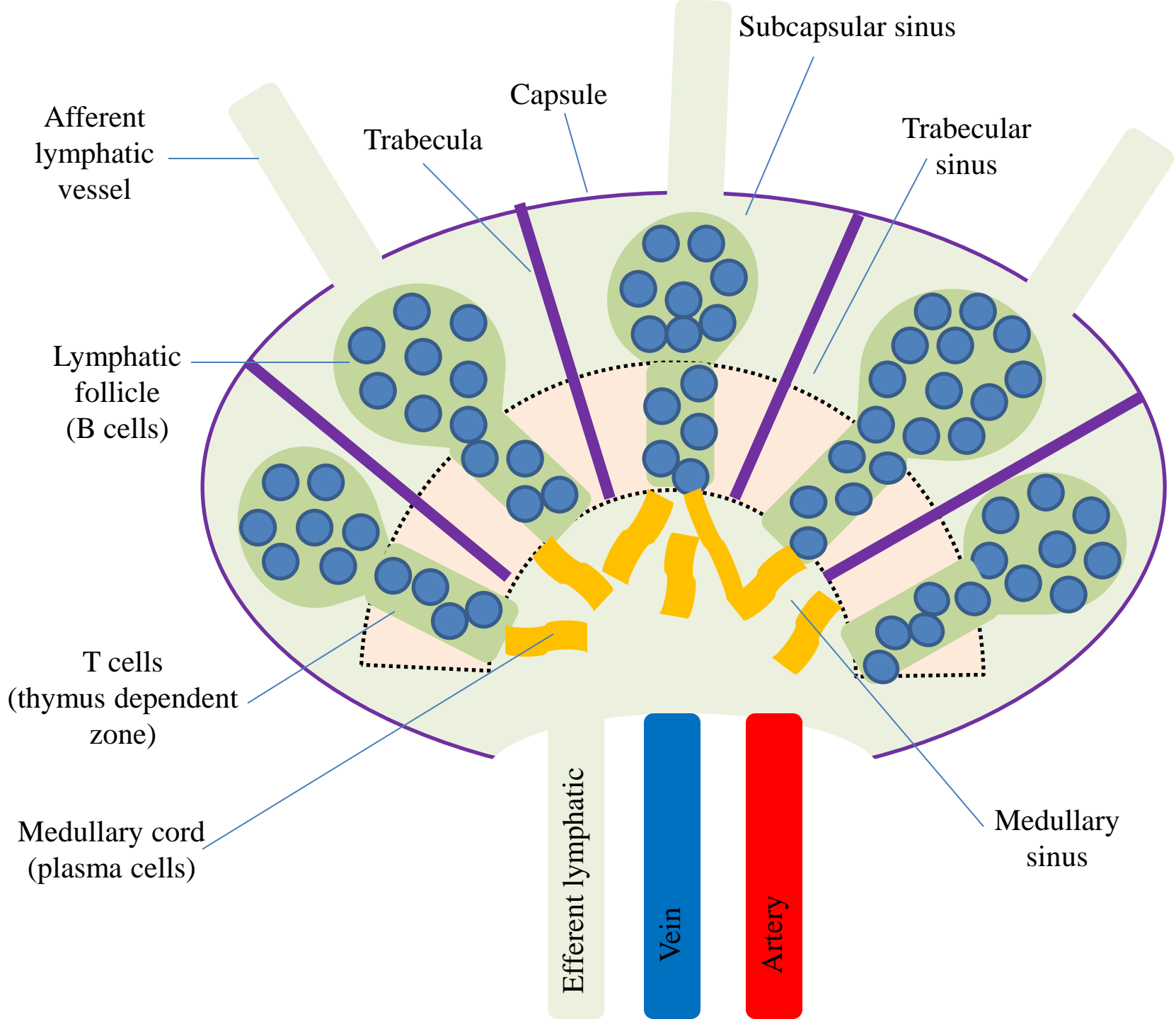
Lymph slows down when it passes in lymph nodes.



Medullary cords

All the **lymphatic sinuses** are lined by a discontinuous layer of simple squamous endothelium

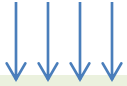



## Lymphocytes can enter lymphoid tissues in two ways:

- 1) Direct entry into lymph nodes via afferent lymphatics
- 2) Entry from blood capillaries across specialized endothelial cells present in the postcapillary venules (High Endothelial Venules= HEV) within the **paracortex** of the lymph node

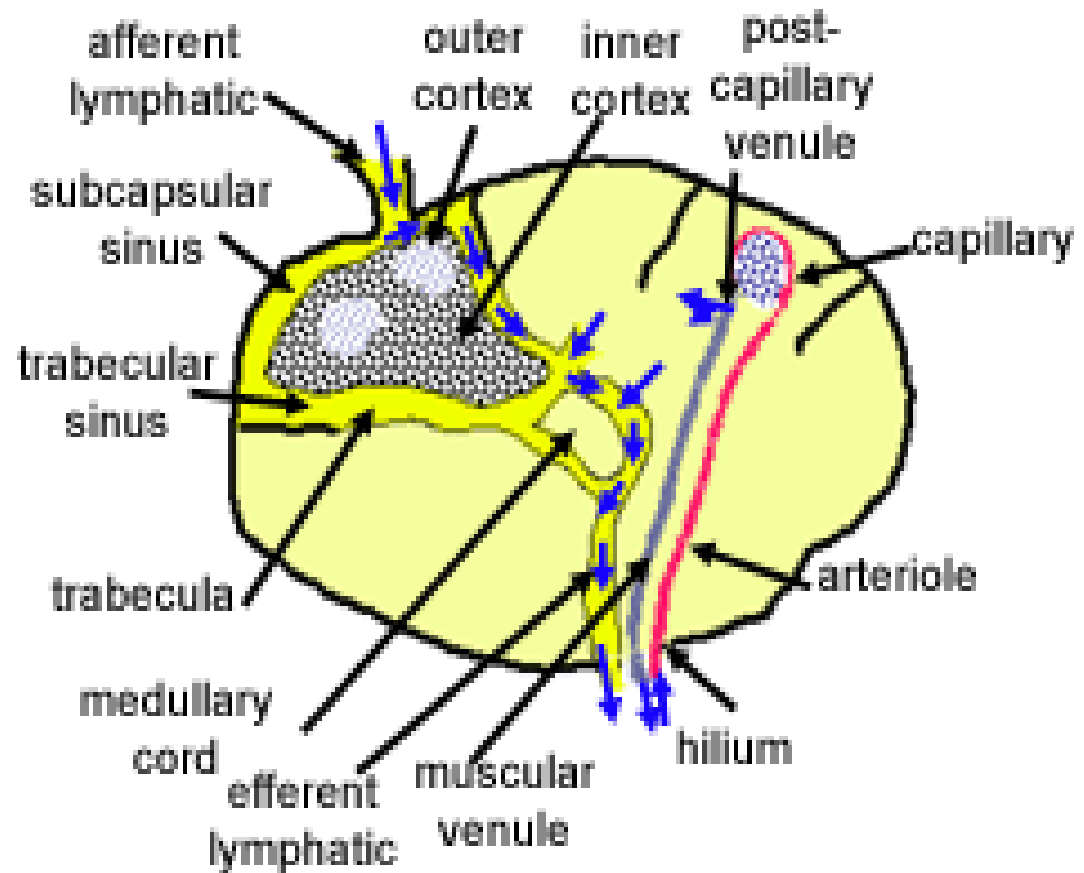
### Why naïve lymphocytes migrate preferentially to lymph node?????



The structure of the post-capillary venule, in the paracortex is unusual in that it is not lined by simple squamous epithelium, but by a **simple cuboidal epithelium**. These are called high endothelial venules (HEVs)

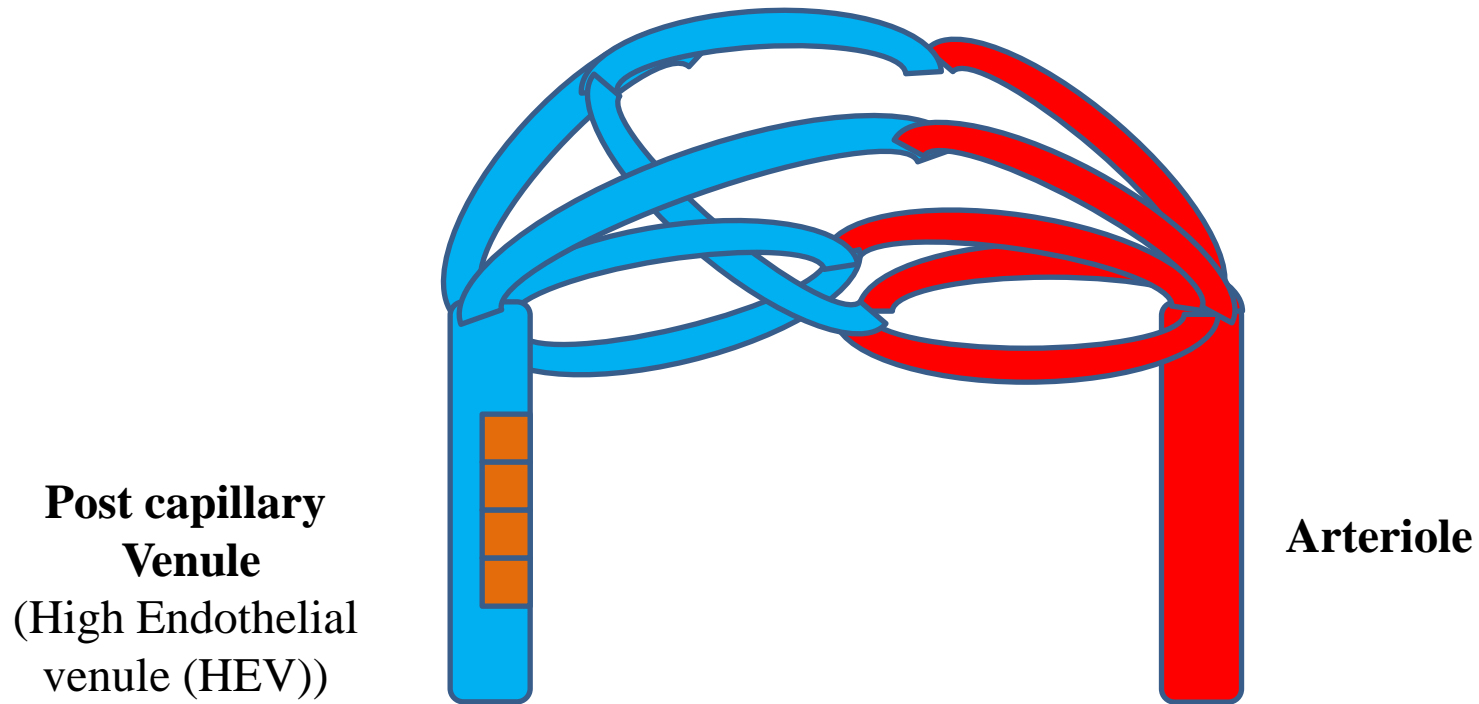
Lymphocytes recognize and adhere to these endothelial cells, and squeeze through them into the paracortex

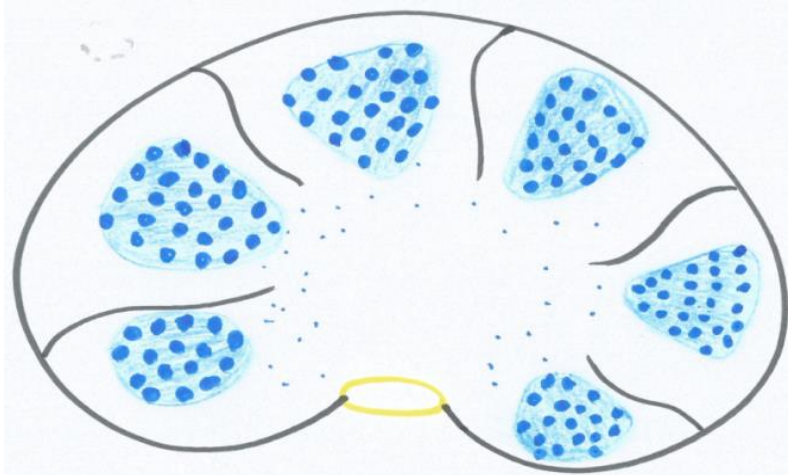
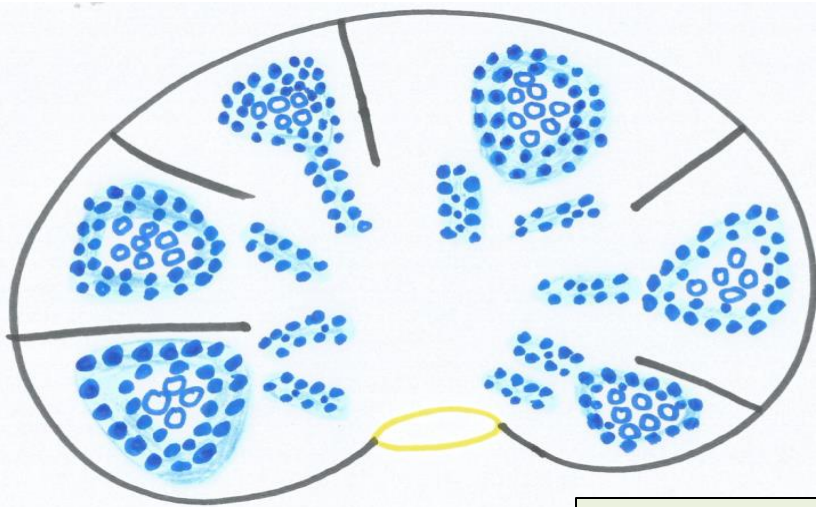
The process of lymphocyte recirculation is regulated by adhesion molecules on lymphocytes called **Homing receptors** and their ligands on vascular endothelial cells called **Adressins**



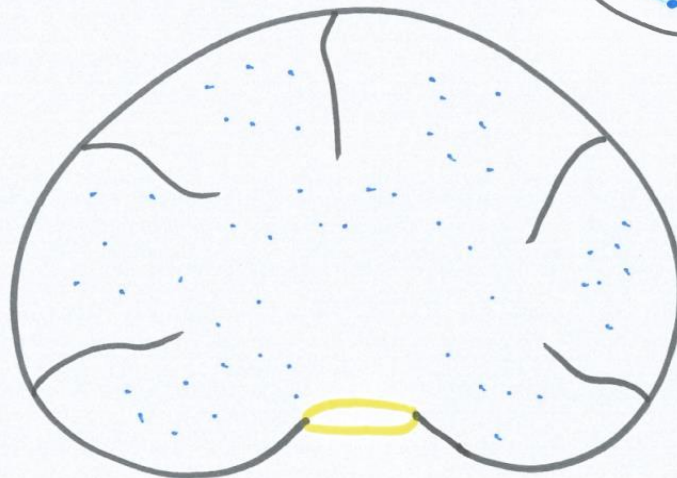
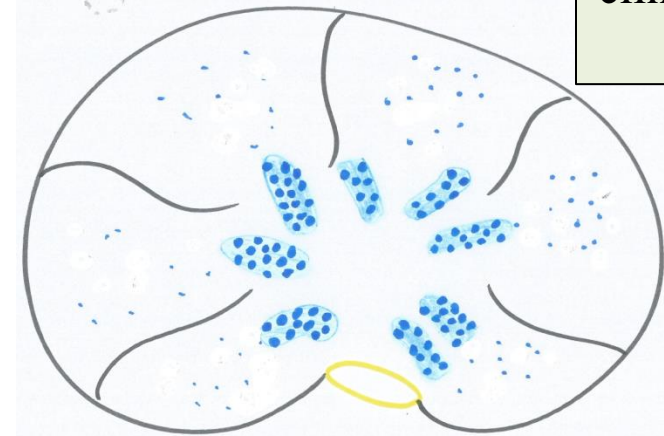
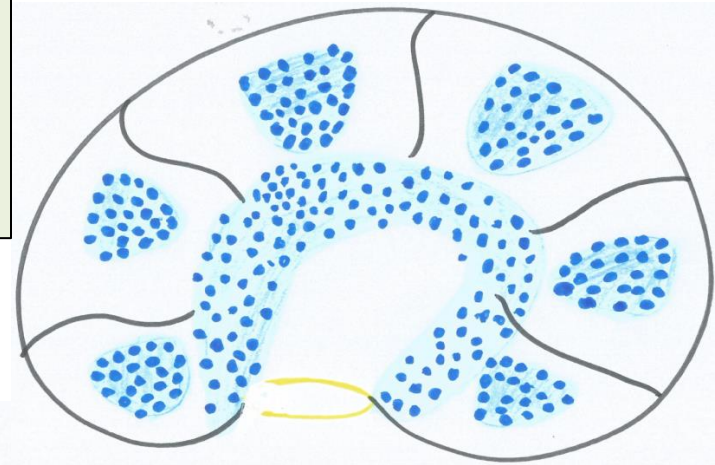
This diagram of a lymph node shows the pathways that lymphocytes can take, in and out of the lymph node.

Note: Most of the lymphocytes enter the lymph nodes via blood vessels, and about 10% enter through the lymph.





Try to describe these histological sections and the clinical picture a patient would have in each case





## Lymphatic trunks and ducts

All lymphatic vessels coalesce to form larger trunks which eventually converge to form the right lymphatic duct and the thoracic duct

### Right lymphatic duct

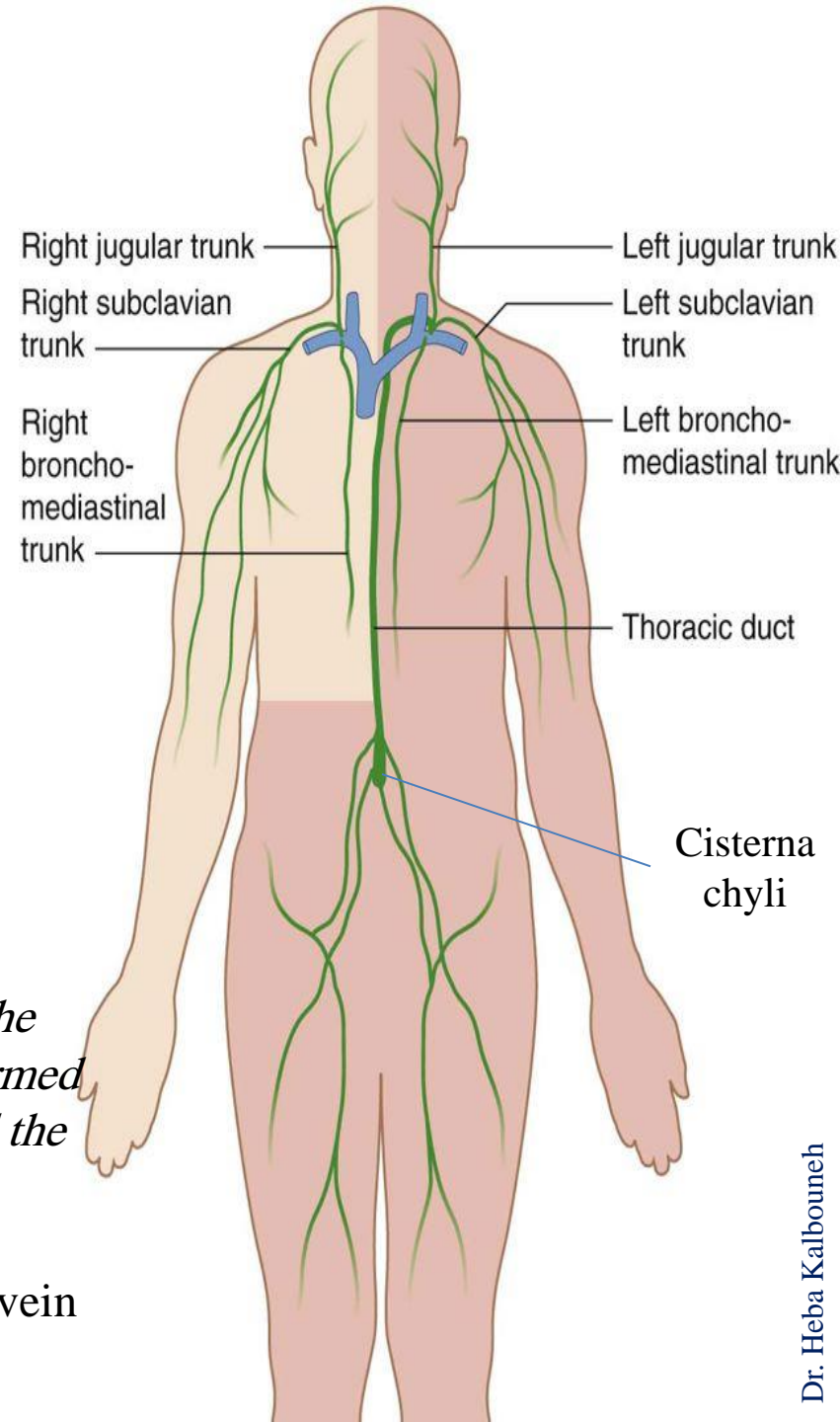
- ✓ Is formed by right jugular and right subclavian trunks
- ✓ Drains lymph from the upper right quadrant of the body (the right side of the head and neck, the right side of the thorax and the right upper limb)
- ✓ Empties into the junction where right internal jugular vein joins the right subclavian vein (**Rt venous angle**)

### Thoracic duct (Left lymphatic duct)

- ✓ Is larger and drains lymph from the rest of the body.
- ✓ Originates in the abdomen as cisterna chyli

*Cisterna chyli is a dilated sac at the lower end of the thoracic duct (anterior to the bodies of L1 and L2) formed by confluence of the right and left lumbar trunks and the intestinal trunk*

- ✓ Passes through the diaphragm at the aortic aperture
- ✓ Empties into the junction where left internal jugular vein joins the left subclavian vein (**Lt venous angle**)



# Spleen

- ✓ The spleen is an oval-shaped **intraperitoneal** organ
- ✓ Approximately
  - 5** inches in height (12-13 cm)
  - 3** inches in width (7-8 cm)
  - 1** inch in thickness (2.5 cm)
  - Weights **7** ounces (200gm)
  - Lies under ribs **9** to **11**
- ✓ Has a notched anterior border.

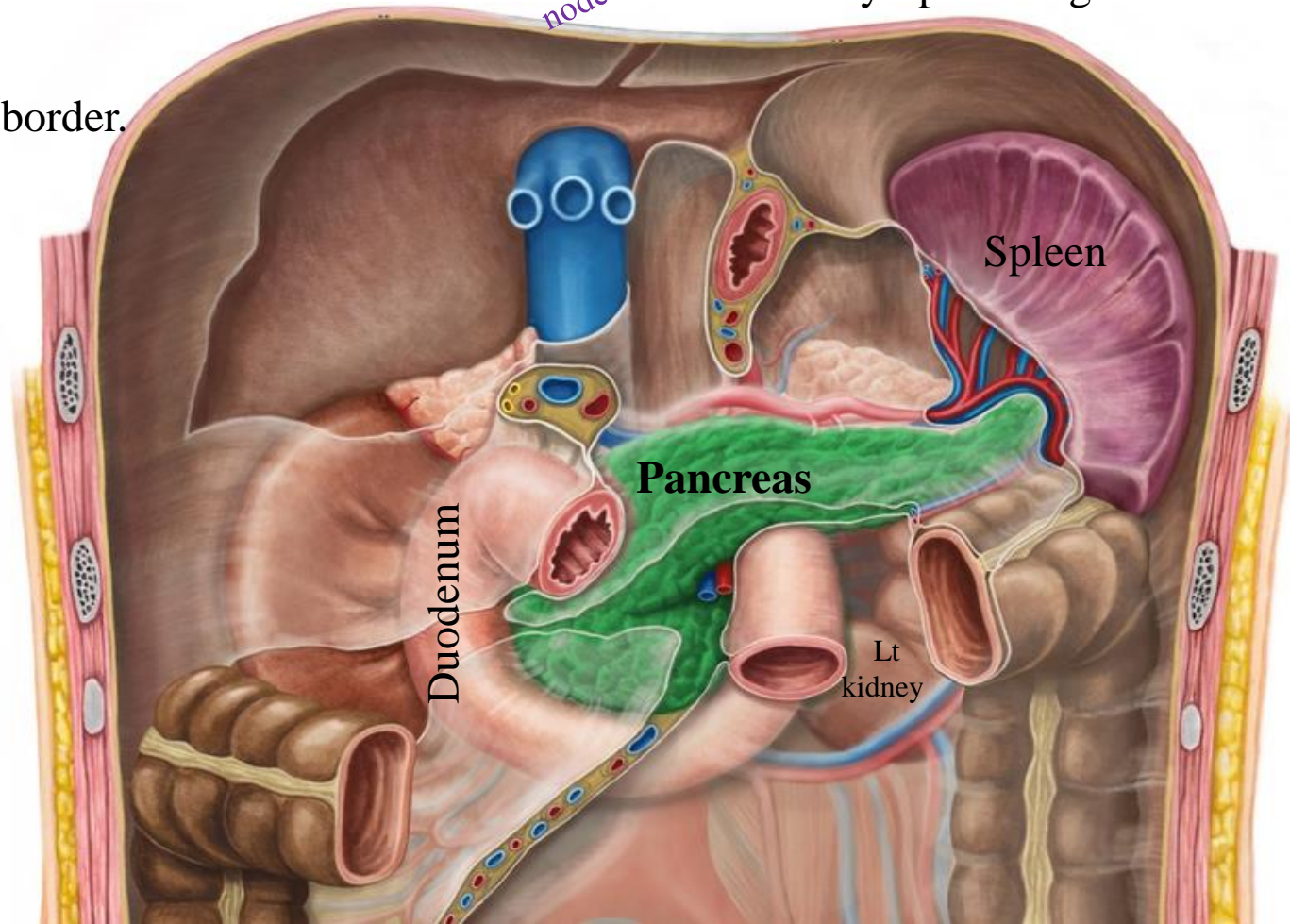
The spleen is the organ of odds number 1, 3, 5, 7, 9, and 11

The spleen resembles a large lymph node  
The spleen filters the blood while lymph nodes filter the lymph

- ✓ It lies high on the upper left portion of the abdomen, just beneath the diaphragm, behind the stomach and above the left kidney.
- ✓ It is the largest of the lymphoid organs

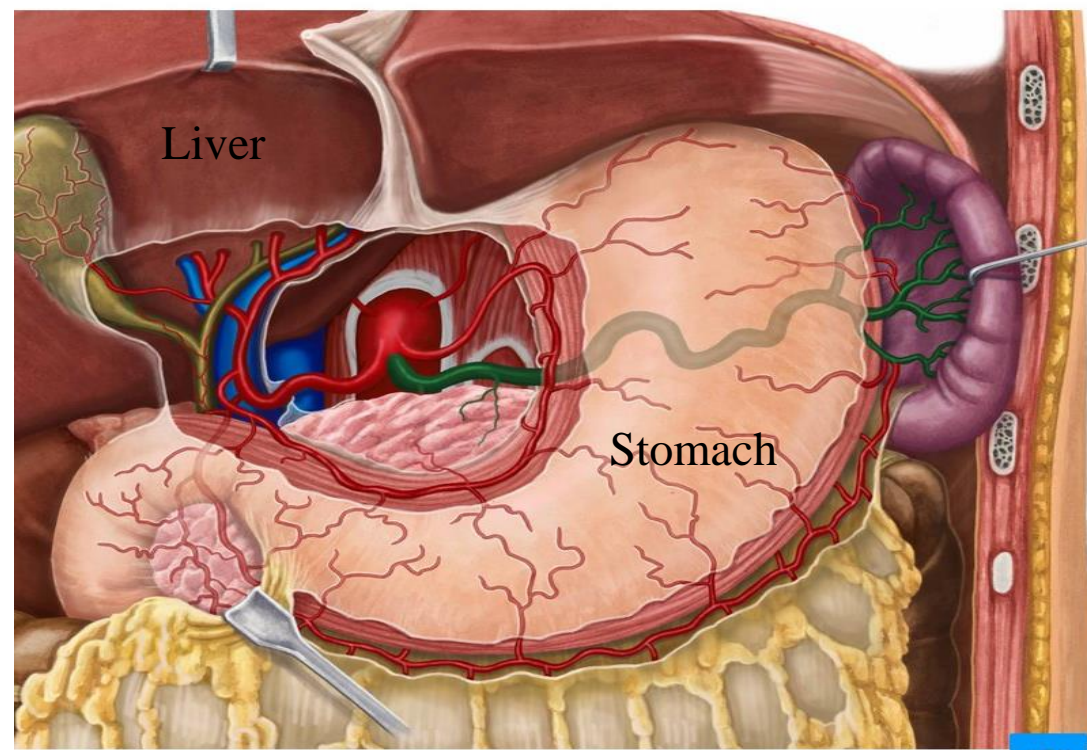
## Functions

- ✓ Filtration of blood (defense against blood-borne antigens)
- ✓ The main site of old RBCs destruction.
- ✓ Production site of antibodies and activated lymphocytes (which are delivered directly into the blood)



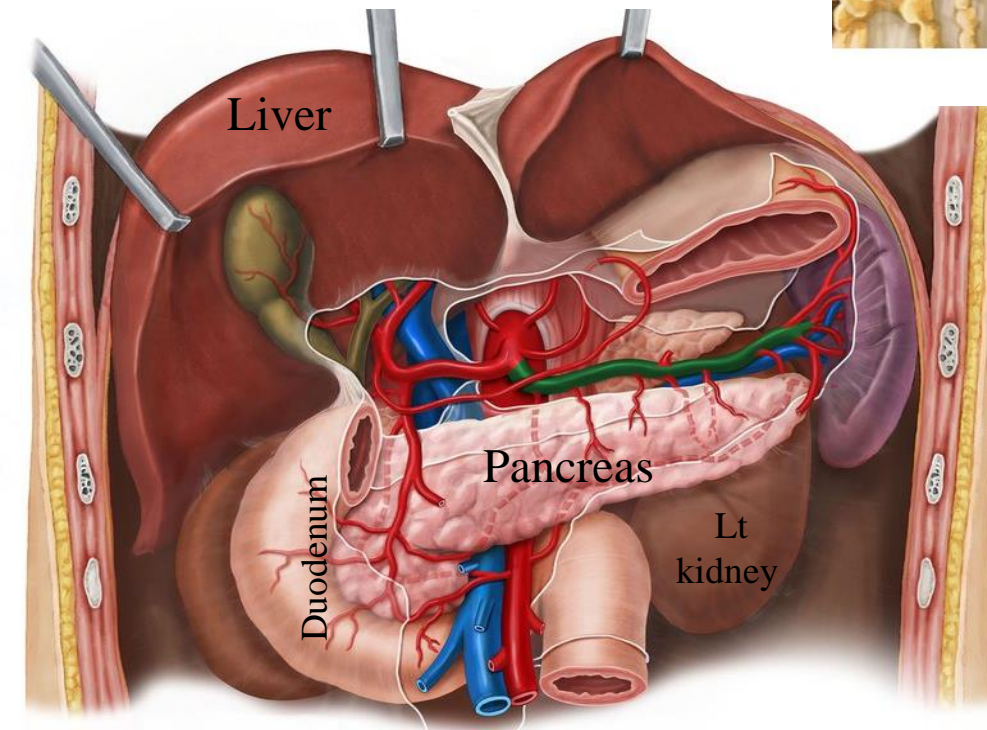
The **splenic artery** is the largest branch of the celiac artery. It has a tortuous course as it runs along the upper border of the pancreas. The splenic artery then divides into about six branches, which enter the spleen at the hilum

The **splenic artery** supplies the spleen as well as large parts of the stomach and pancreas



© www.kenhub.com

KEN HUB



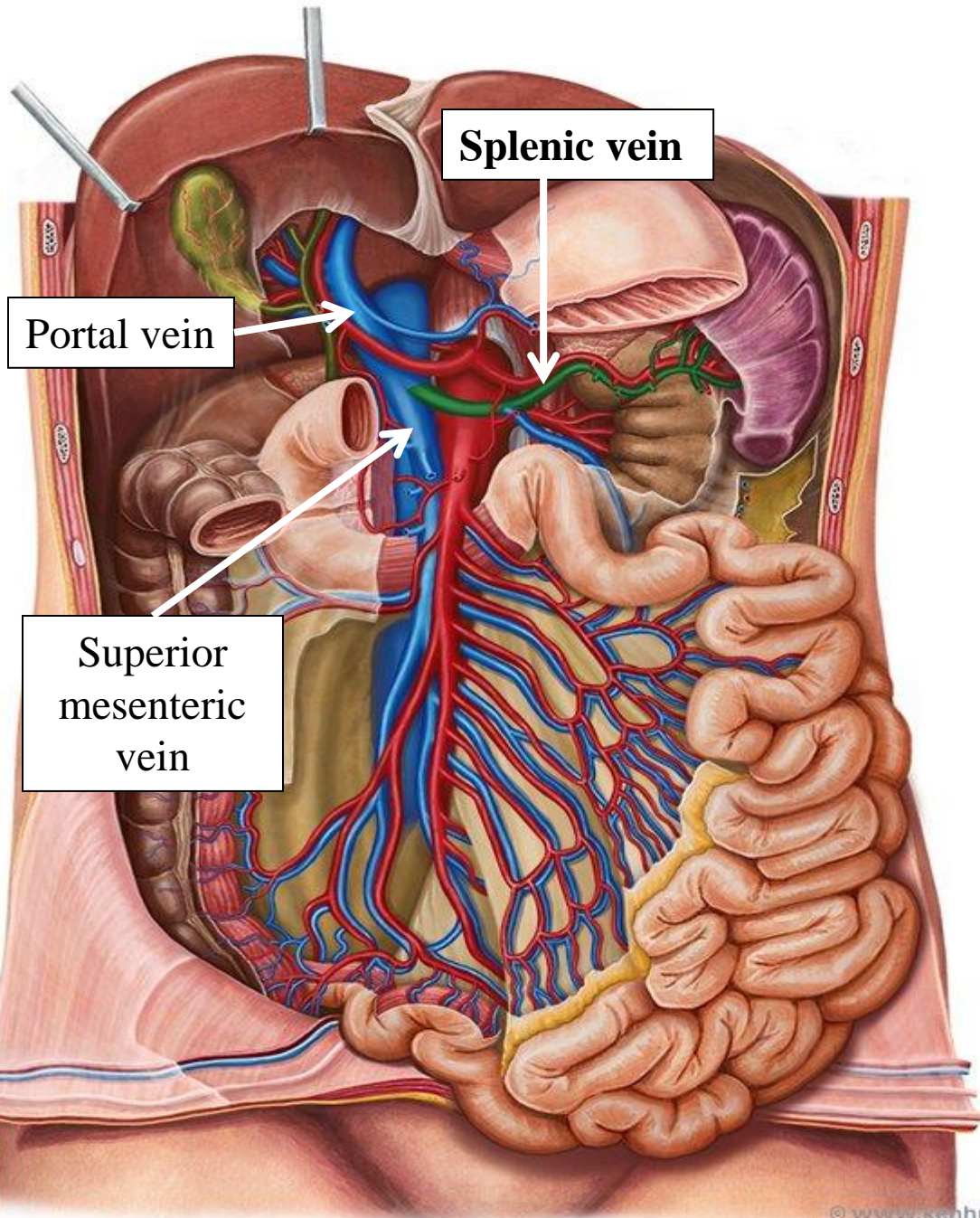
Abdominal Aorta




Celiac Trunk



Splenic artery



The **splenic vein** leaves the hilum and runs behind the tail and the body of the pancreas. Behind the neck of the pancreas, the splenic vein joins the superior mesenteric vein to form the portal vein

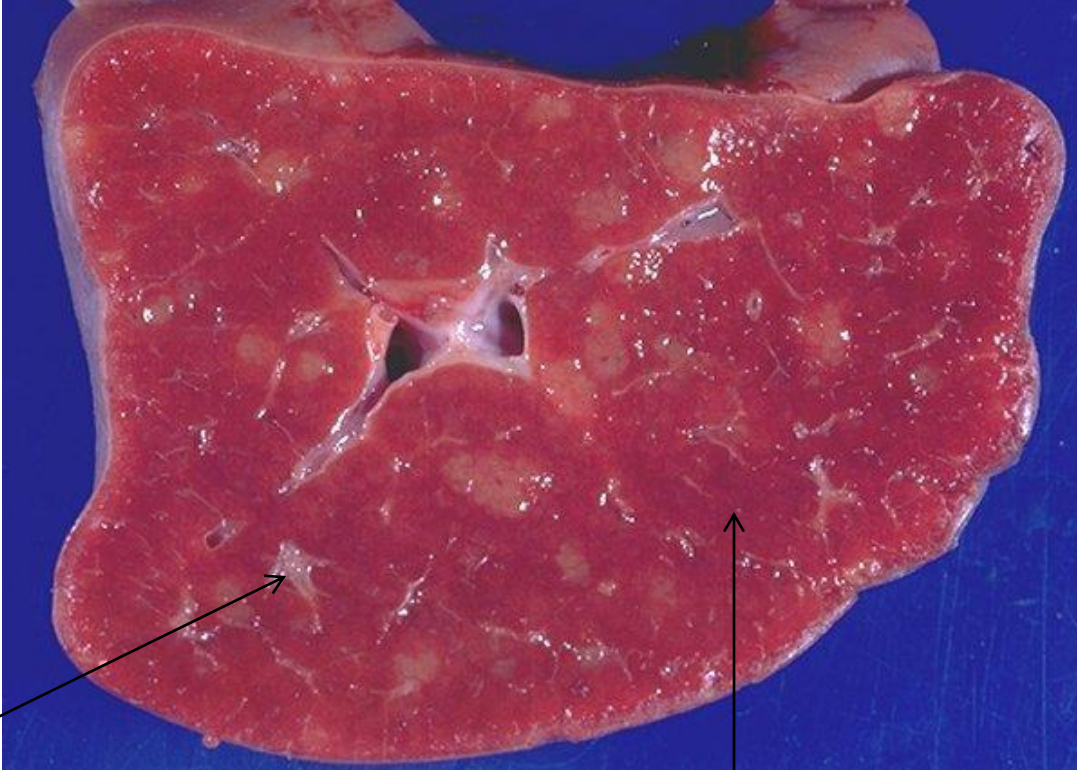


In cases of portal hypertension, spleen often enlarges from venous congestion.

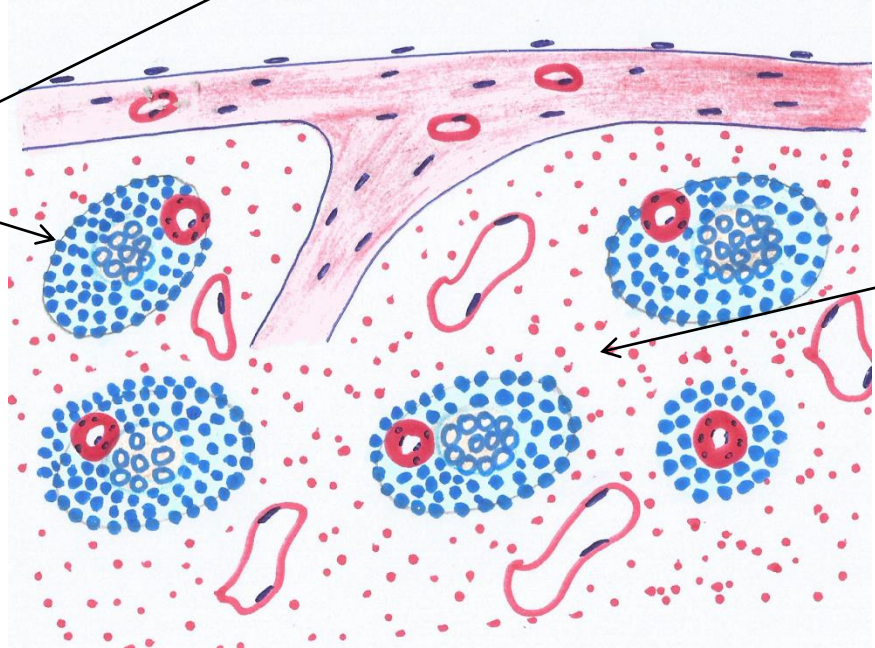
The parenchyma of the spleen appears in fresh specimen as:

**White pulp** which appears white on gross examination (collection of both B and T lymphocytes)

**Red pulp** which appears red on gross examination (blood filled)



**White pulp**



**Red pulp**

H.K

The spleen is covered by a **capsule** of dense connective tissue, and have capsular extensions called the **trabeculae**

Large trabeculae originate at the hilum, on the medial surface of the spleen, and carry branches of the splenic artery, vein, lymphatics, and nerves into the spleen

The spleen is composed of parenchyma and stroma

**Parenchyma:** Splenic pulps

**Stroma:** Reticular tissue (reticular fibers and reticular cells)

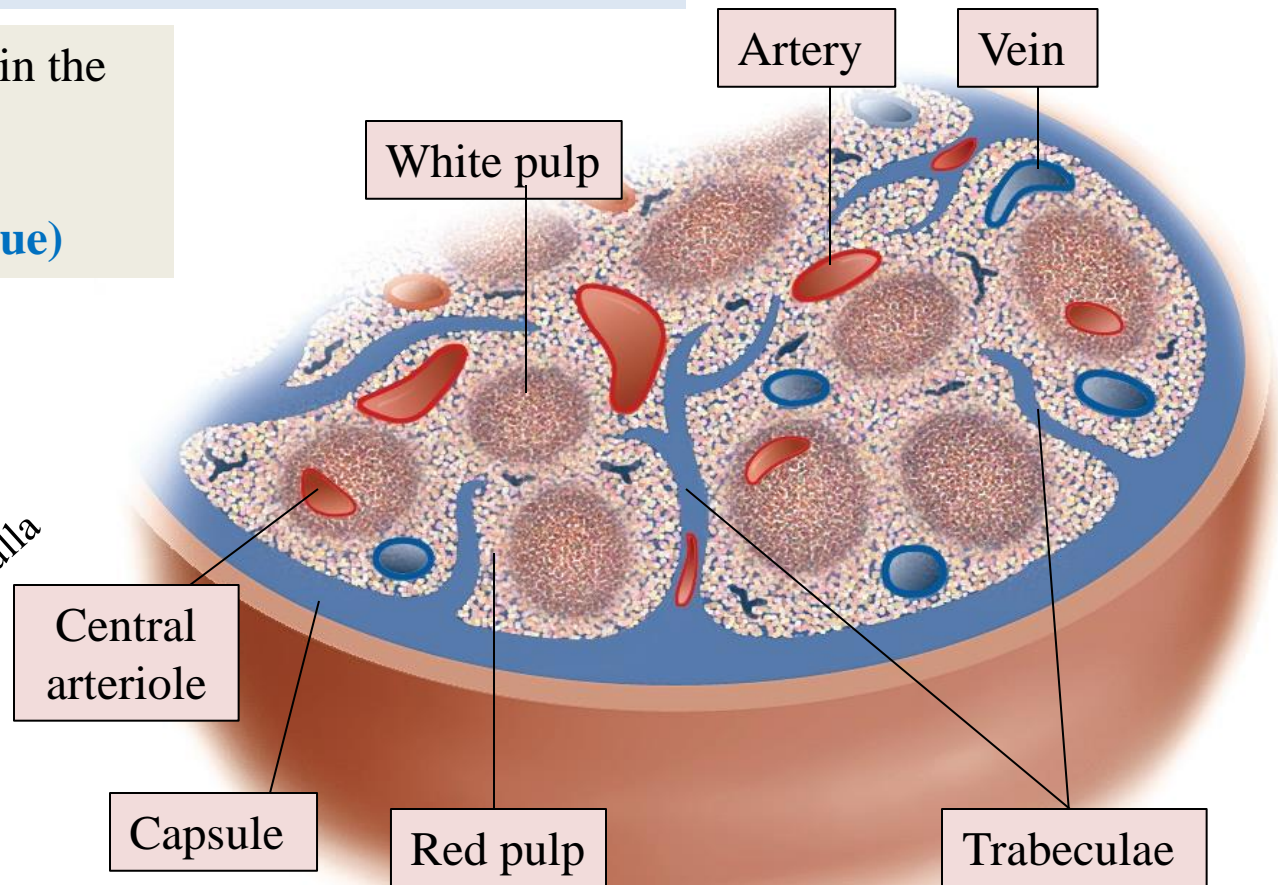
There are two types of pulp in the spleen:

**Red pulp (rich in blood)**

**White pulp (lymphatic tissue)**

Unlike lymph nodes, the spleen:

- 1- Has no afferent lymphatics
- 2- Has no lymphatic sinus system
- 3- Its lymphatic tissue is not arranged into cortex and medulla



**Splenic artery**

Divides into trabecular arteries as it enters the hilum

**Trabecular arteries**

Follow the course of trabeculae

**Central arterioles**

Are branches of trabecular arteries entering the white pulp. They are surrounded by a sheath of lymphocytes.

**Penicillar arterioles** *The morphology is like penicillus*

Each central arteriole eventually leaves the white pulp and enters the red pulp, losing its sheath of lymphocytes and branching as several short straight penicillar arterioles that continue as terminal capillaries.



**Terminal capillaries** (Sheathed capillaries)

Some of these terminal capillaries are sheathed with APCs for additional immune surveillance of blood

Blood flow through the splenic red pulp can take either of two routes:

**Open circulation:** the capillaries open into the spaces of the red pulp (splenic cords) and then the blood returns to the venous system through the wall of the splenic sinusoids

**Closed circulation:** the capillaries open directly into the splenic sinusoids (blood is enclosed by endothelium)

**Splenic sinusoids**

**Trabecular veins**

**Splenic vein**



## White pulp (lymphoid tissue)

✓ Constituting 25% of the spleen, the white pulp is responsible for the immunological (lymphatic) function of the spleen.

✓ The white pulp contains:

### Periarteriolar lymphatic sheaths (PALS):

tightly packed T cells arranged in cylindrical sheaths around central arterioles

**Lymphoid follicles:** spherical aggregations of B cells scattered throughout the PALS

Primary (unstimulated) follicles contain resting (inactive) B cells

Secondary (stimulated) follicles contain activated B cells in a central region (germinal center)

### Splenic nodules (Malpighian corpuscles)

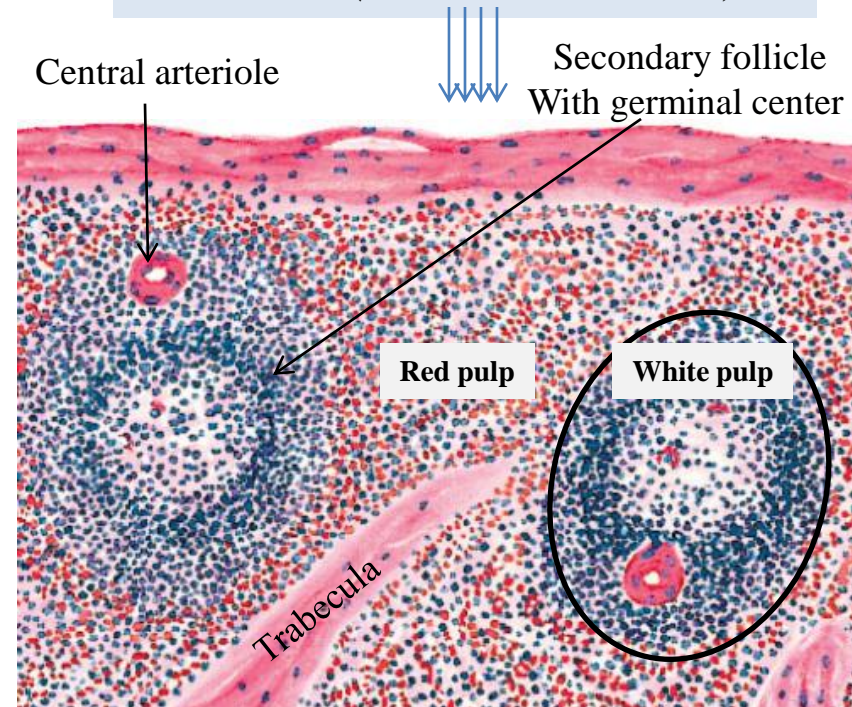
*Note: These follicles have the same structural organization as those found in lymph nodes*

**Function:** The lymphocytes and APCs monitor the blood for foreign antigens and respond in a similar way to those in the lymph nodes.



*Production of antibodies and activated lymphocytes (which are delivered directly into the blood)*

*When the lymphatic sheath expands to incorporate the follicles, the central arteriole is displaced to one side and acquires an eccentric position in the follicle but is still called the central arteriole (Follicular arteriole).*





## Red pulp (blood filled)

✓ Constituting 75% of the spleen, the red pulp is responsible for the hematological (circulatory) function of the spleen.

✓ The red pulp contains :

**Splenic cords (Billroth's cords):** consist of all cells between the sinusoids in the red pulp (reticular cells, macrophages, plasma cells, lymphocytes, RBCs, platelets, other leukocytes)

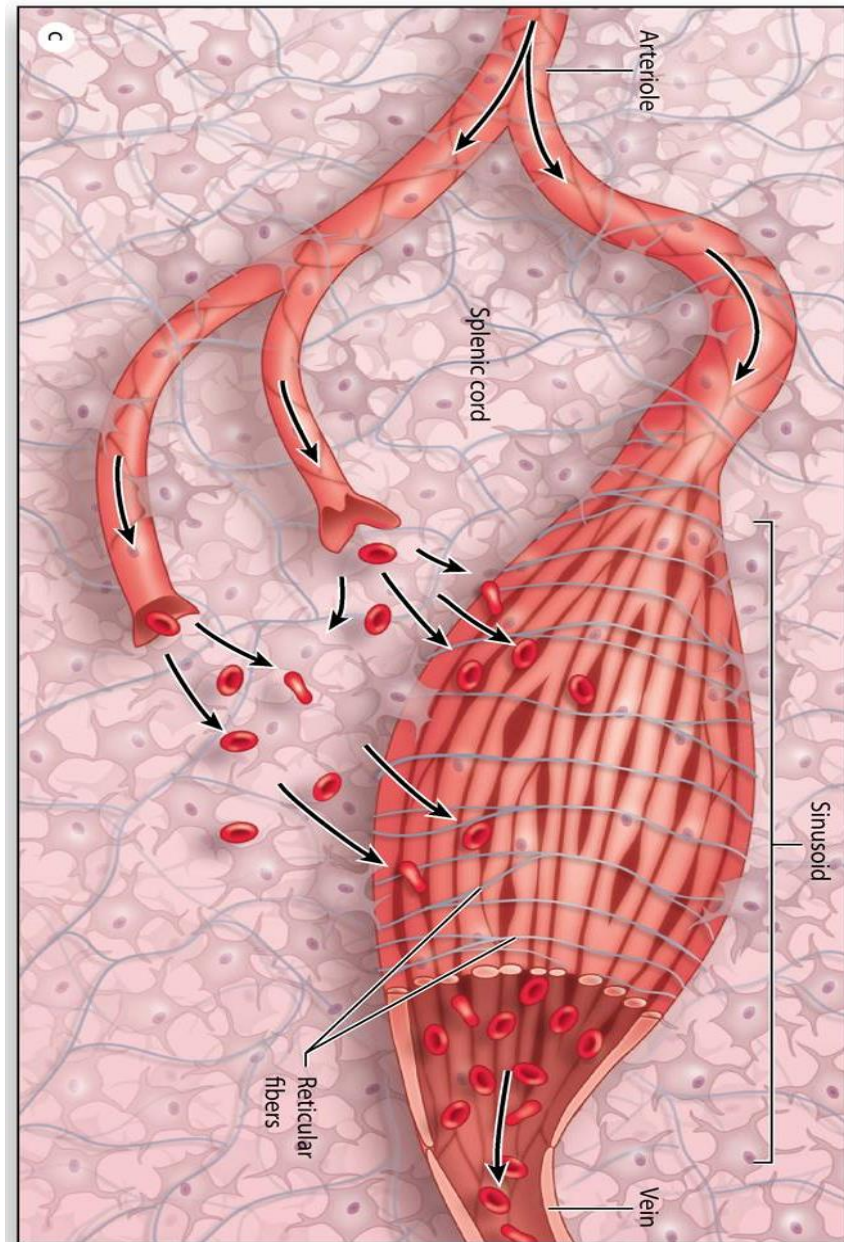
**Splenic sinusoids:** are blood- filled spaces located throughout the red pulp. They have large, dilated, irregular lumens and large pores (spaces between the endothelial cells)

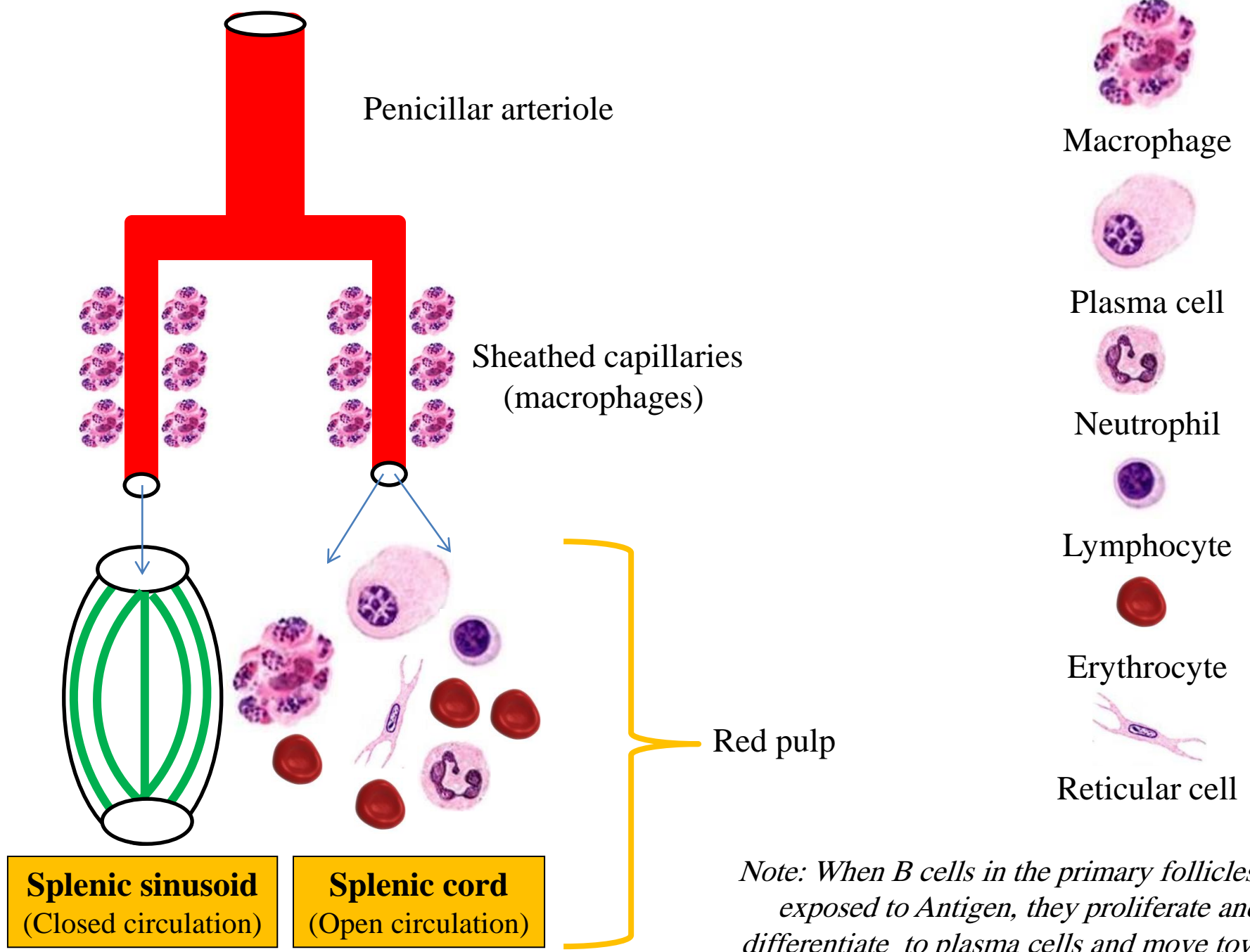


1. The endothelial cells (**stave cells**) are elongated, fusiform cells that lie parallel to the long axis of the vessel
2. The cells lie side by side around the vessel but not joined by any type of intercellular junctions
3. The endothelial cells are supported by highly discontinuous basal lamina (forms bars and encircles the sinusoid)

**Function:** Destruction of worn-out RBCs and platelets

## ↓↓ Red pulp



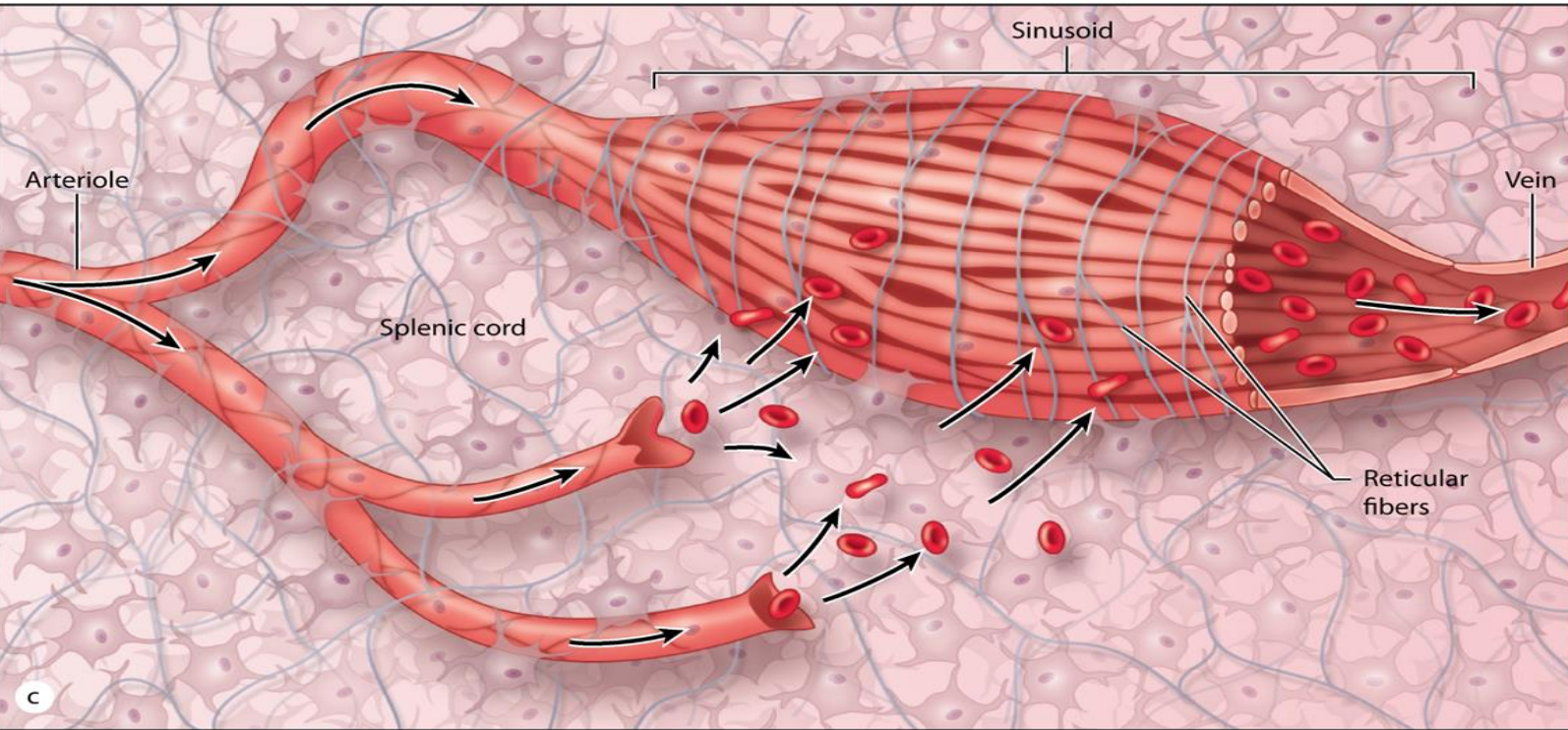


**Splenic sinusoid**  
(Closed circulation)

**Splenic cord**  
(Open circulation)

Red pulp

*Note: When B cells in the primary follicles are exposed to Antigen, they proliferate and differentiate to plasma cells and move toward the red pulp.*

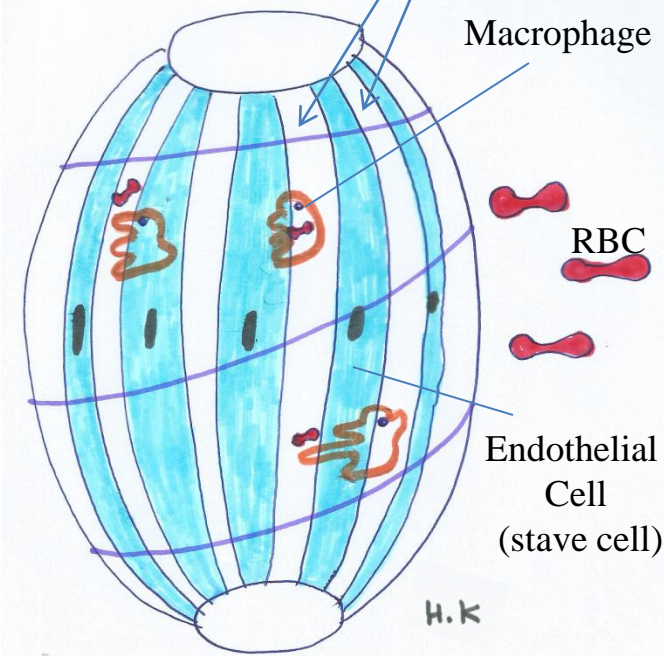


Note the wide gaps between endothelial cells which allow for movement of entire cells from cords to sinuses

In this route plasma and all the formed elements of blood must reenter the vasculature by passing through narrow slits between the stave cells into the sinusoids. These small openings present no obstacle to platelets, to the motile leukocytes, or to thin flexible erythrocytes. However stiff or swollen RBCs at their normal life span of 120 days are blocked from passing between the stave cells and undergo selective removal by macrophages



*Deformed or less pliable RBCs cannot squeeze effectively from the cord into the sinus and upon their mechanical fragmentation are removed by resident macrophages (lie just next to the sinusoids)*



Macrophages monitor erythrocytes as they migrate from splenic cords between the endothelial cells into the splenic sinusoids

Old erythrocytes **lose their flexibility**



They cannot penetrate the spaces between the endothelial cells and are phagocytosed by macrophages



Old erythrocytes lose sialic acid from their cell membranes



Galactose exposed



Induce phagocytosis of RBCs



Hemoglobin is broken into **Heme** and **Globin**

After surgical removal of the spleen (splenectomy), the number of abnormal erythrocytes in the circulation increases although most such cells are then removed by macrophages in sinusoids of the bone marrow and liver.

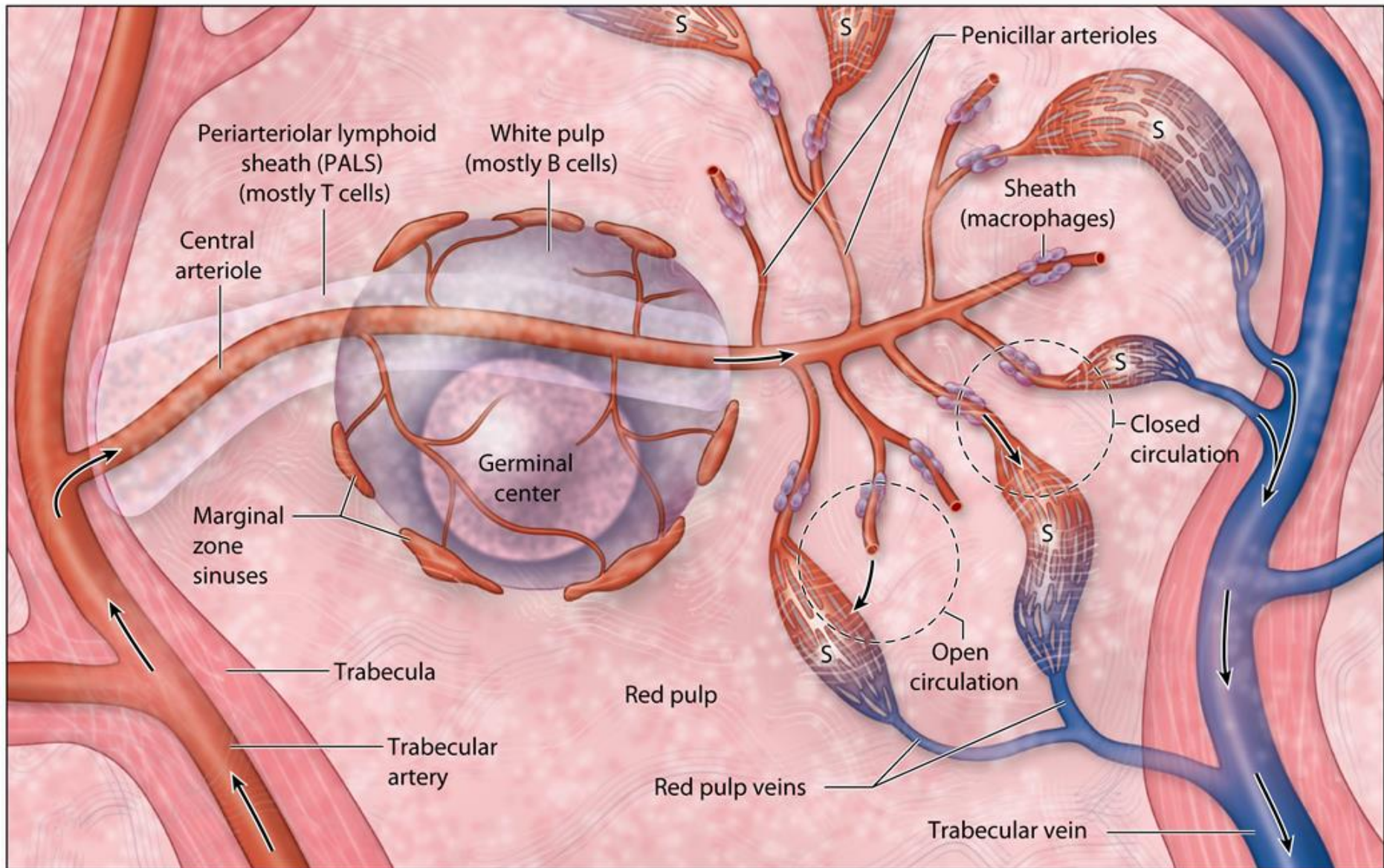
amino acids

pool of blood

**Iron:** carried by transferrin to bone marrow (used again)

**Bilirubin:** excreted by liver bile

Schematic view of the blood circulation and the structure of the spleen, from the trabecular artery to the trabecular vein.



## Marginal zone sinuses

✓ Located between the white and the red pulp

✓ The spaces between these sinuses are wide (2-3um)



It is here the blood-borne antigens and particulate matter have their first free access to the parenchyma of the spleen

*The following events occur at the marginal zone:*

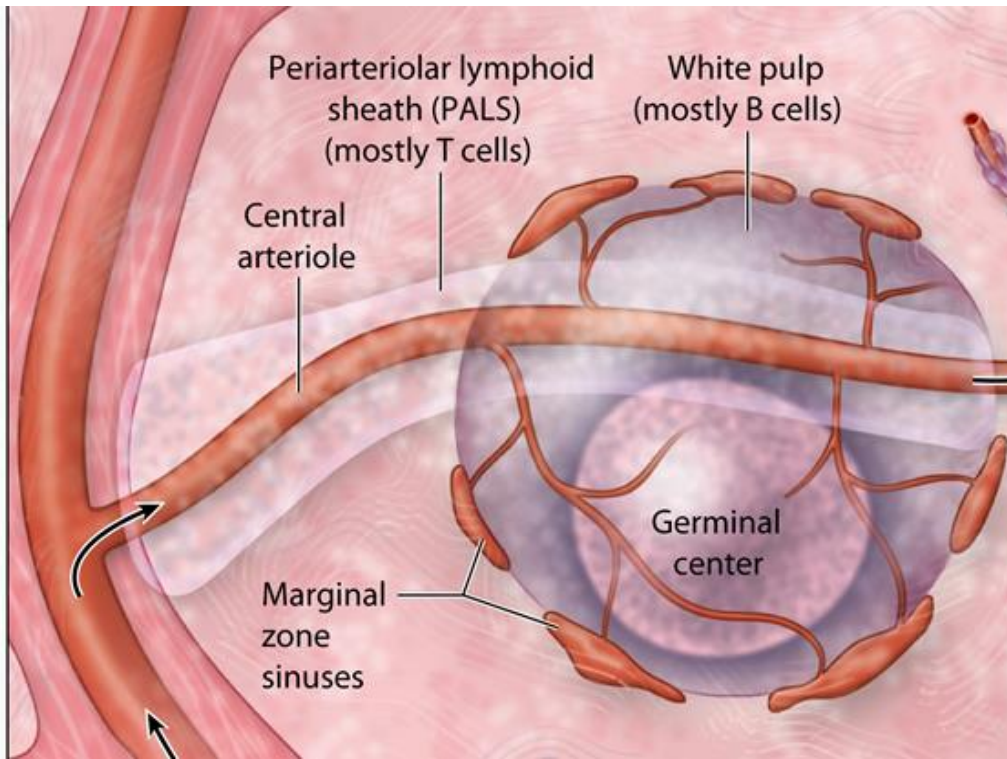
- 1- APCs sample the material travelling in blood searching for antigens
- 2- Macrophages attack microorganisms present in the blood

Lymphocytes come into contact with APCs, if they recognize their Ag-MHC complex, the lymphocytes initiate immune response within the white pulp

- 3- The circulating B and T cells leave the blood stream to enter the preferred location within the white pulp

**T cells: PALS**

**B cells: lymphatic follicles**



## Functions of the spleen:

It has circulatory as well as lymphatic functions

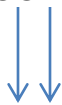**Blood cell production:** During the fetal life, blood cells are produced in the spleen

**Blood storage:** A small quantity of blood is stored in the sinusoids of the red pulp

**RBC destruction:** Most worn-out or damaged red blood cells are destroyed in the spleen (some in the liver and bone marrow). They are phagocytized by macrophages

### Defense mechanism:

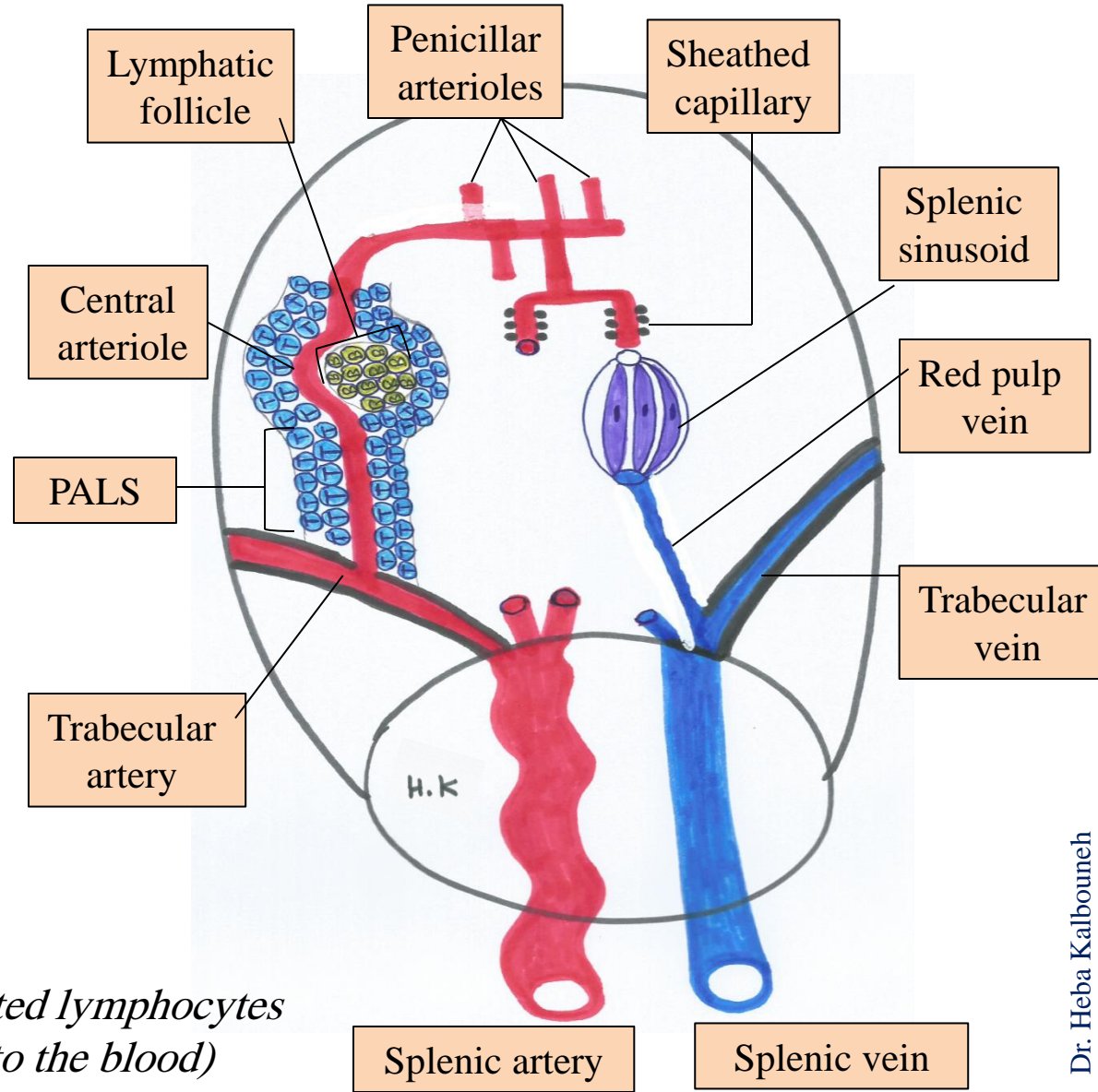
Macrophages phagocytize microbes that have penetrated the blood. Antigens in the blood activate B and T cells residing in the spleen, triggering immune response

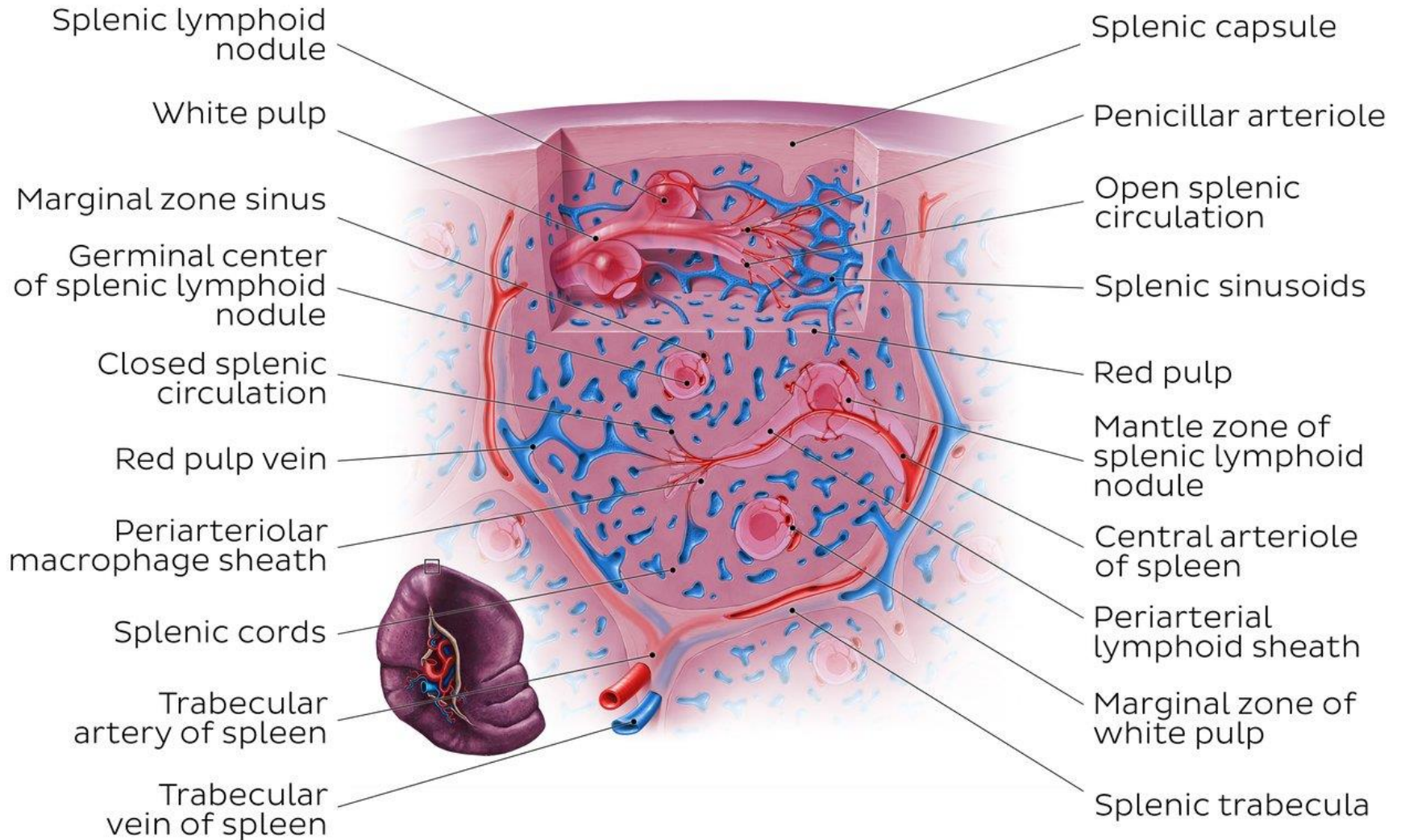


*Production of antibodies and activated lymphocytes  
(which are delivered directly into the blood)*

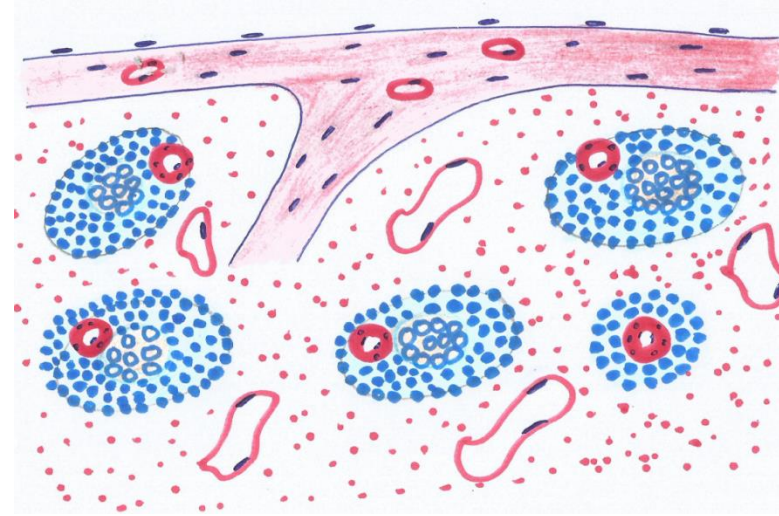
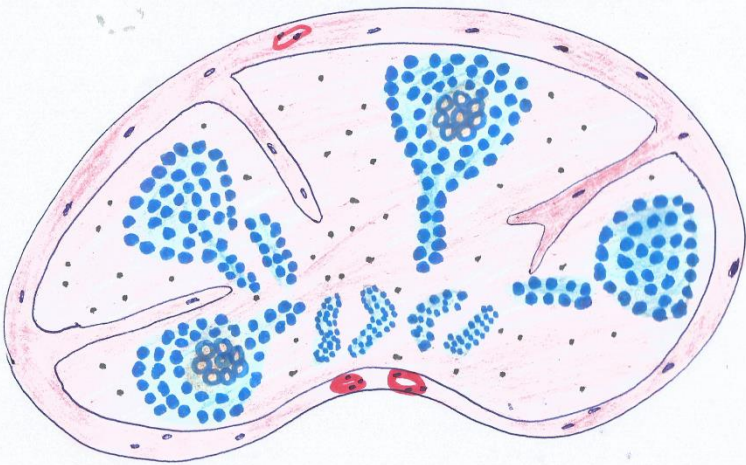
To summarize

The blood flow in the spleen goes from splenic artery to trabecular artery to central arteriole, and upon leaving the white pulp, the blood flows through penicillar arterioles and terminal sheathed capillaries to the splenic sinusoids, and back to veins of the pulp, trabecular veins and the splenic vein









Lymph node	Spleen
Multiple, small	Single, large
Along the course of lymphatic vessels	Intra-abdominal
Filters lymph	Filters blood
Covered by fascia	Covered by peritoneum
Has afferent vessels	No afferent vessels
Cortex and medulla	White pulp and red pulp
Contains Lymphatic sinuses	Contains Blood sinuses

# Diffuse lymphatic tissue (lymphatic nodules)

- ✓ Is formed by aggregations of lymphatic tissue
- ✓ Is found in various mucosal sites of the body

The mucosa or inner lining of the digestive, respiratory, and genitourinary tracts is a common site of invasion by pathogens because their lumens open to the external environment.

- ✓ It can therefore be referred to as:



## Mucosa-Associated Lymphatic Tissue (MALT)

- ✓ These aggregations are **not encapsulated**
- ✓ MALT can be found in the following locations:

Palatine tonsils

Lingual tonsils

Pharyngeal tonsils

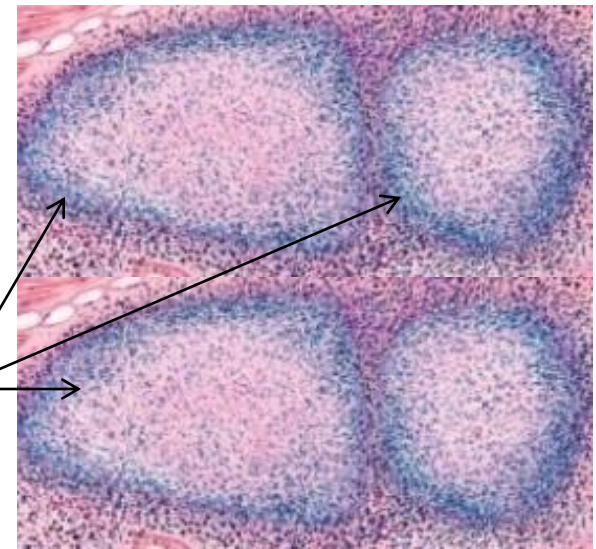Gut-associated lymphoid tissue (GALT)

Bronchus-associated lymphatic tissue (BALT)



Collectively the MALT is one of the largest lymphoid organs, containing up to 70% of all the body's immune cells.

Lymphatic nodules



Dr. Heba Kalbouneh

MALT is populated by:

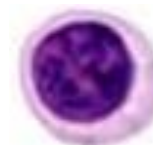T cells

B cells

Plasma cells

APCs

Each of which is well situated to encounter antigens passing through the mucosal epithelium



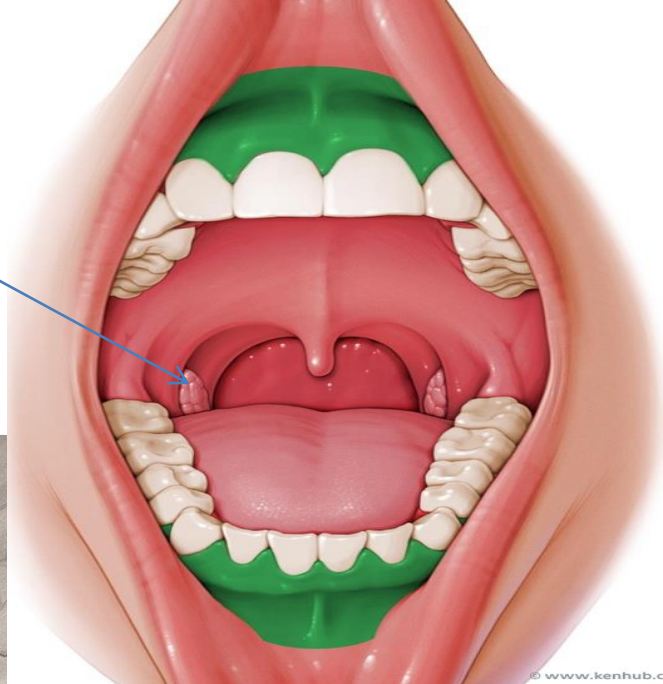
Because lymphocytes have prominent basophilic nuclei and very little cytoplasm, lymphoid tissue packed with such cells usually stains **dark blue** in H&E stained sections

# Tonsils are large, irregular masses of lymphoid tissue

**Function of tonsils:** Protect the body from inhaled and ingested pathogens.

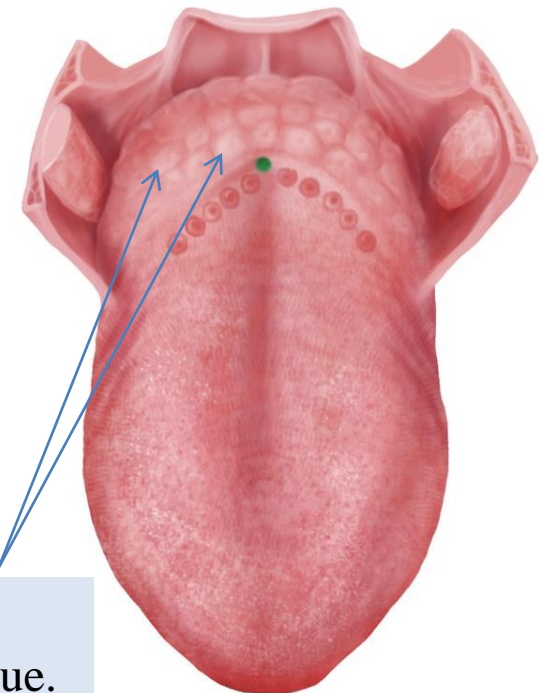
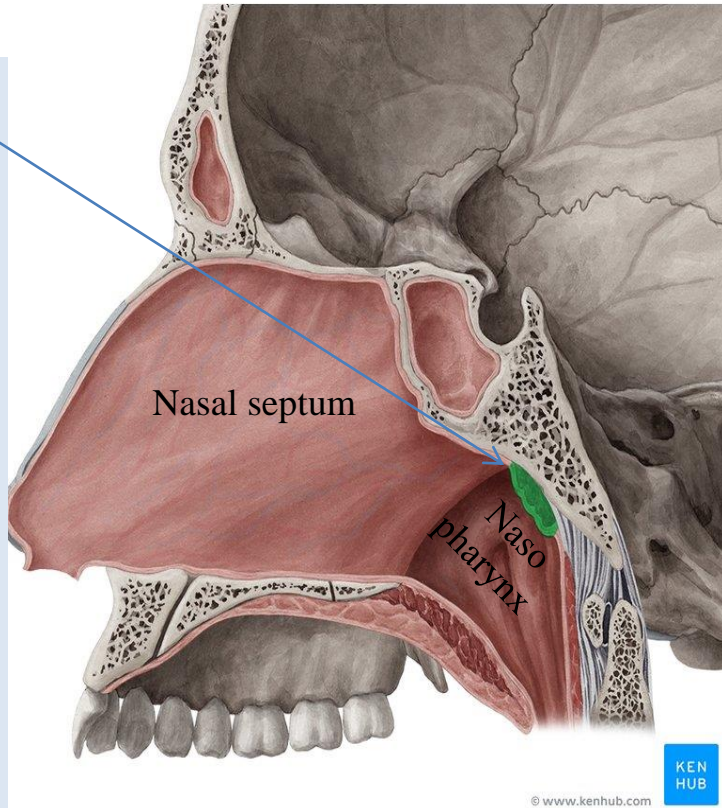
## Palatine tonsils

Are located at the lateral wall of oropharynx, between the glossopalatine and pharyngopalatine arches (two masses )  
*Acute inflammation of these tonsils causes tonsillitis.*



## Pharyngeal tonsils

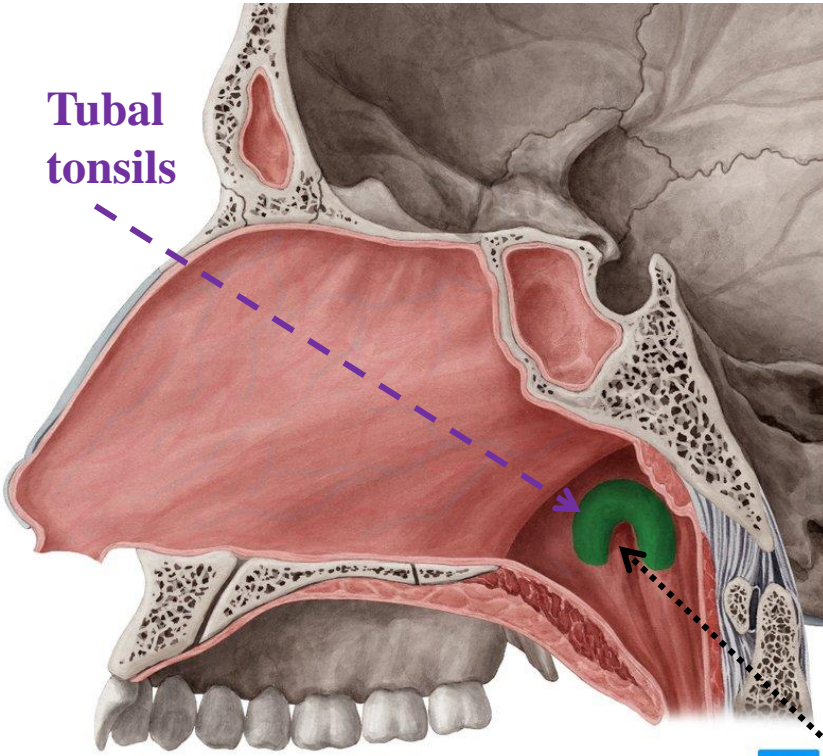
Are located in the posterior wall of the nasopharynx.  
*It is most prominent in children, but begins to atrophy from the age of seven.*  
*Hypertrophied regions of pharyngeal tonsils resulting from chronic inflammation are called adenoids.*



## Lingual tonsils

Are located on the posterior 1/3 of the tongue.

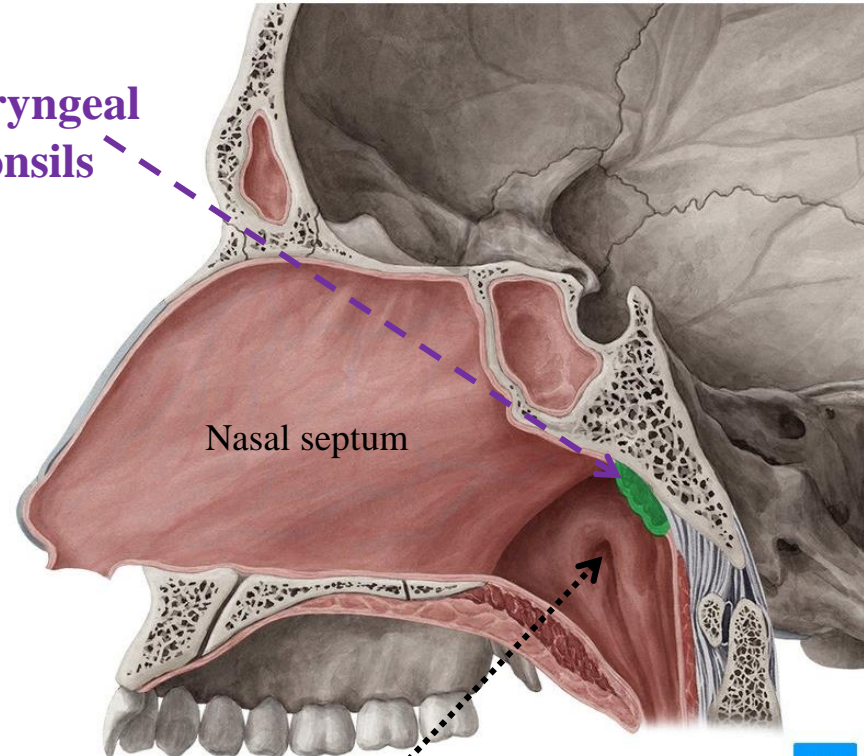
**Tubal  
tonsils**



© www.kenhub.com



**Pharyngeal  
tonsils**



Nasal septum

© www.kenhub.com



Opening for Eustachian tube

## **Adenoids**

Excessive hypertrophy of the lymphoid tissue, usually associated with infection, causes the pharyngeal tonsils to become enlarged; they are then commonly referred to as adenoids. Marked hypertrophy blocks the posterior nasal openings and causes the patient to snore loudly at night and to breathe through the open mouth. The close relationship of the infected lymphoid tissue to the auditory tube may be the cause of recurrent otitis media. Adenoidectomy is the treatment of choice for hypertrophied adenoids with infection.

Note:

Pharyngeal tonsils are covered by ciliated pseudostratified columnar epithelium (respiratory epithelium)

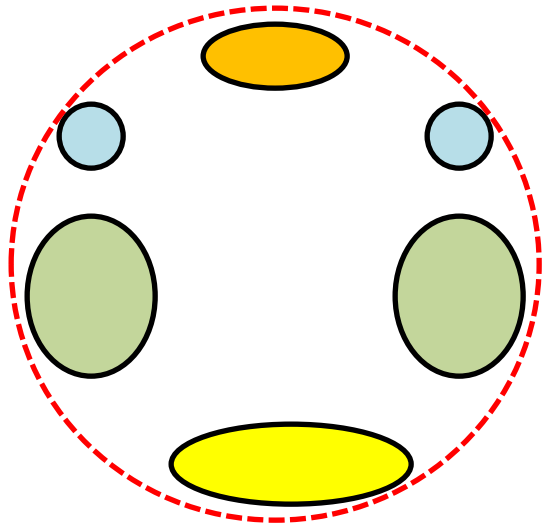
## Waldeyer's tonsillar ring

(Waldeyer's lymphatic ring) is a ringed arrangement of lymphoid

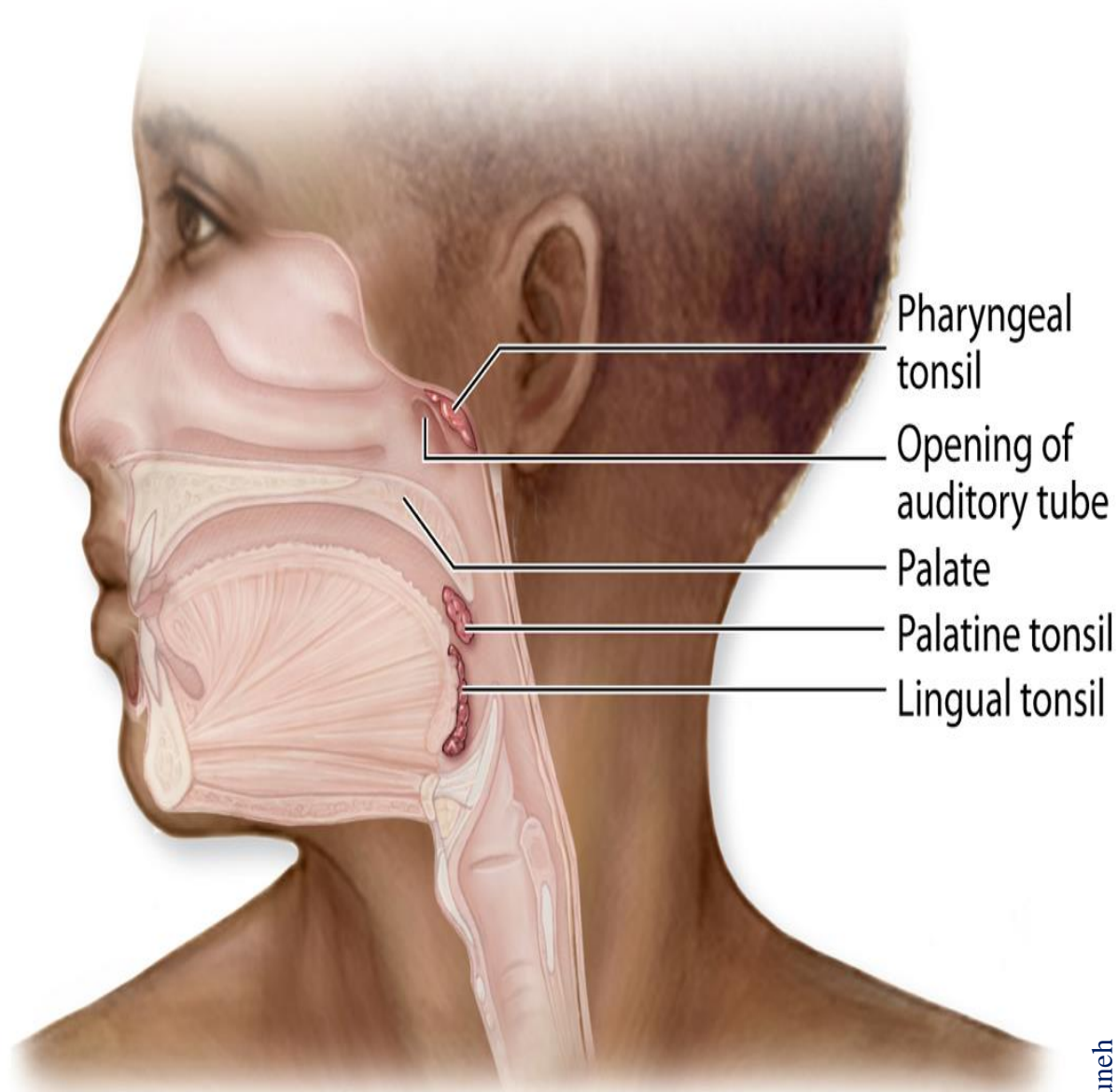
tissue



In the nasopharynx, oropharynx,  
and base of the tongue.

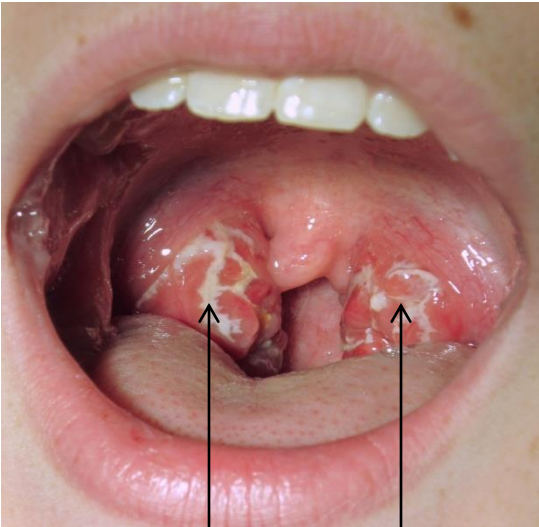


Anterior view

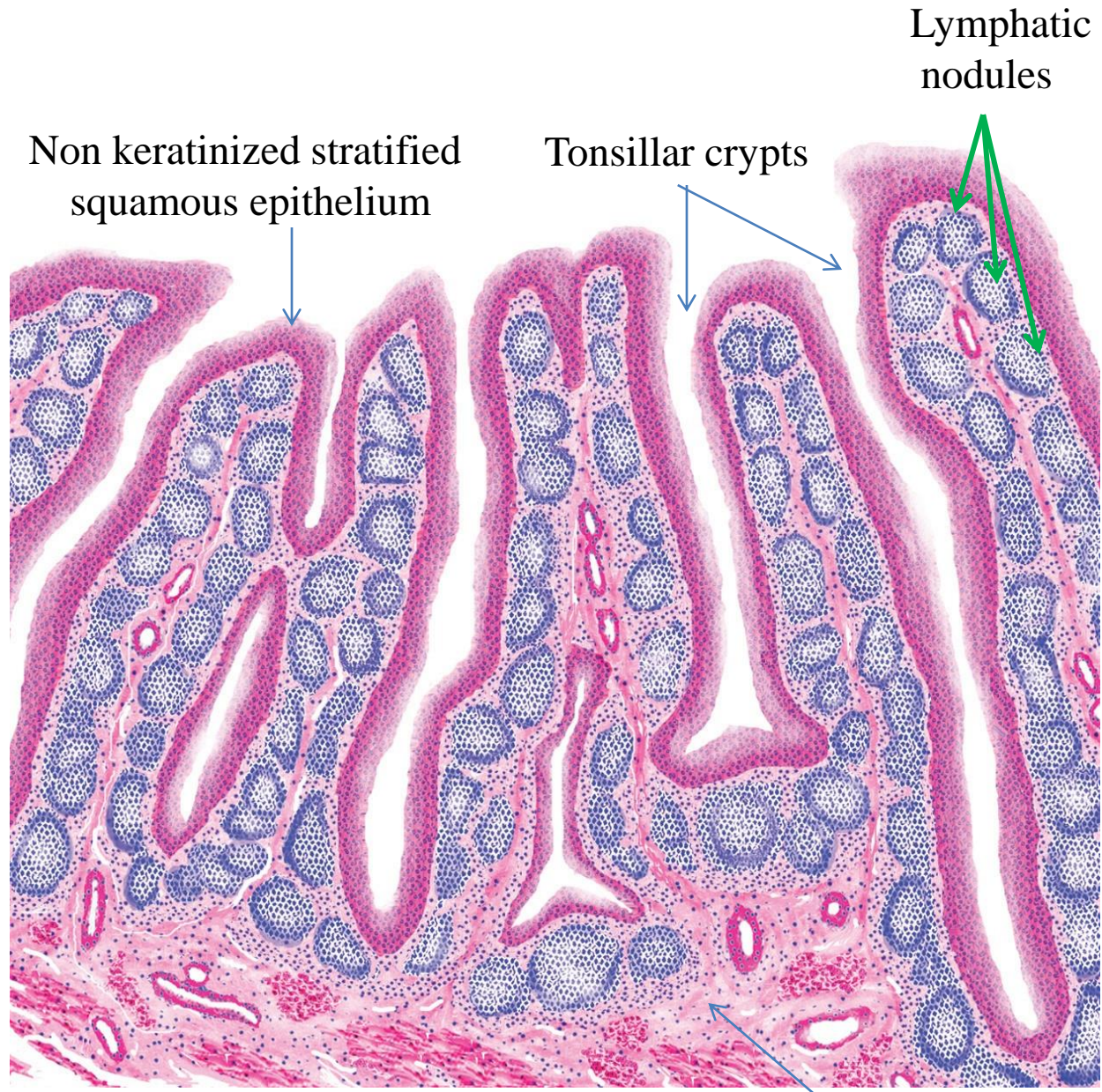


# Palatine tonsils

- ✓ Are covered by stratified squamous epithelium.
- ✓ The surface area of each is enlarged with 10-20 tonsillar crypts (deep invaginations )
- ✓ Many lymphoid nodules around the crypts
- ✓ Has an underlying capsule (partial capsule)



Pus in tonsillar crypts

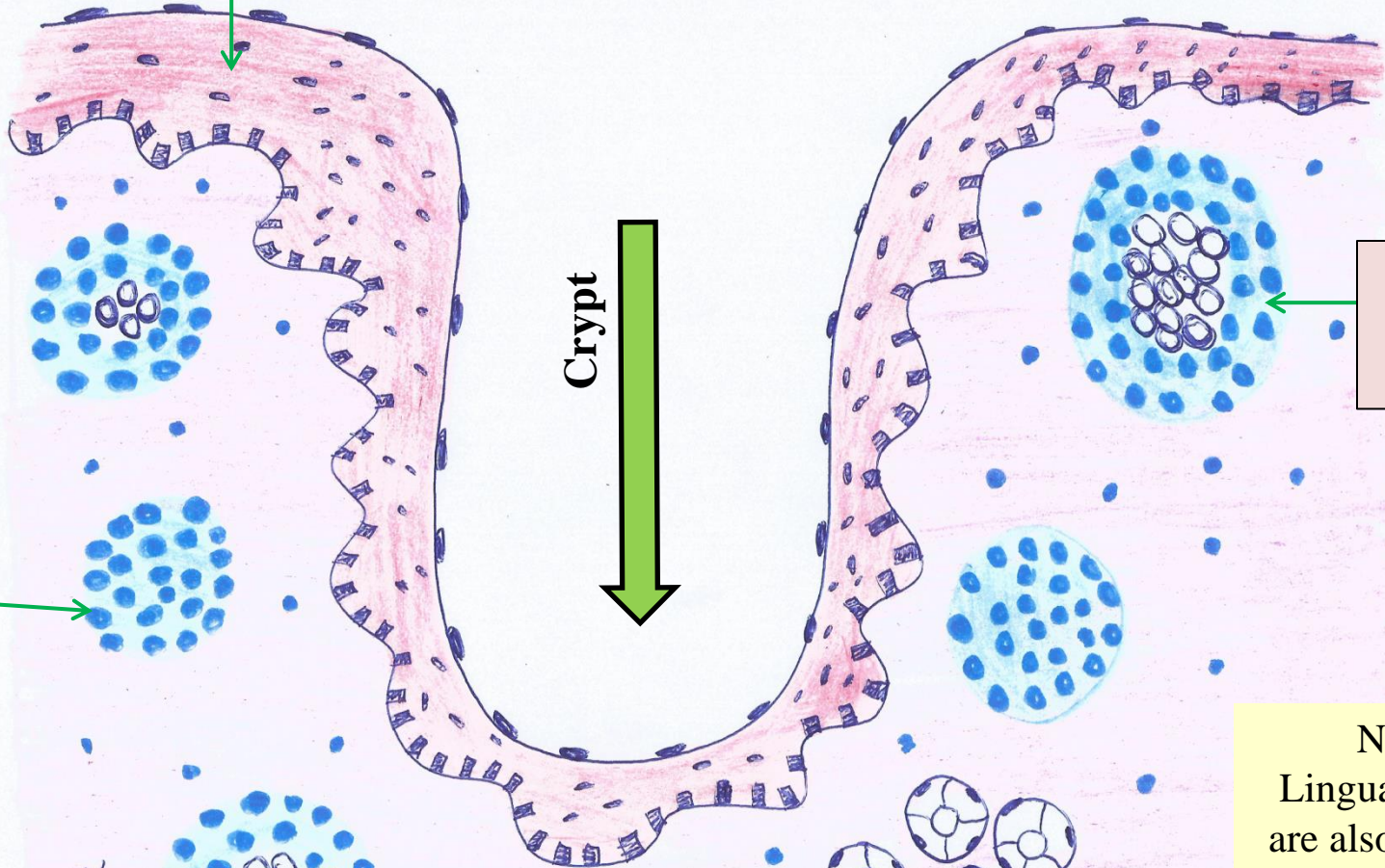


Palatine tonsils

Capsule

# Palatine tonsils

Stratified non-keratinized squamous epithelium



Secondary Lymphoid follicle

Primary Lymphoid follicle

Germinal center

H.K

Note:  
Lingual tonsils are also covered by stratified squamous epithelium with crypts

## Gut-associated lymphoid tissue (GALT)

Is located in the mucosa of the intestine.

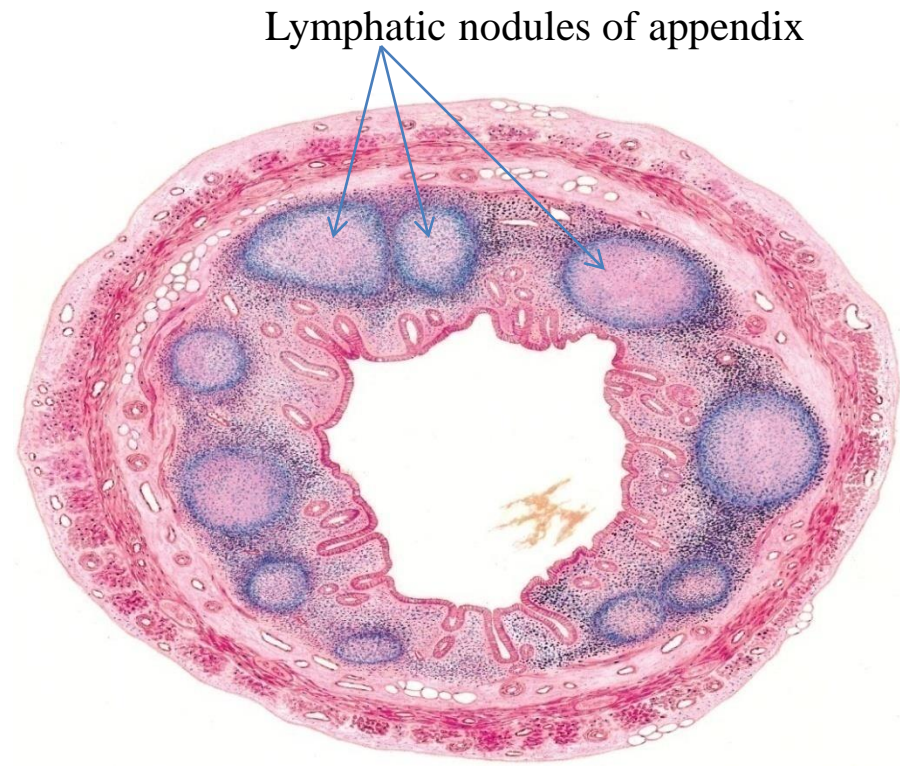
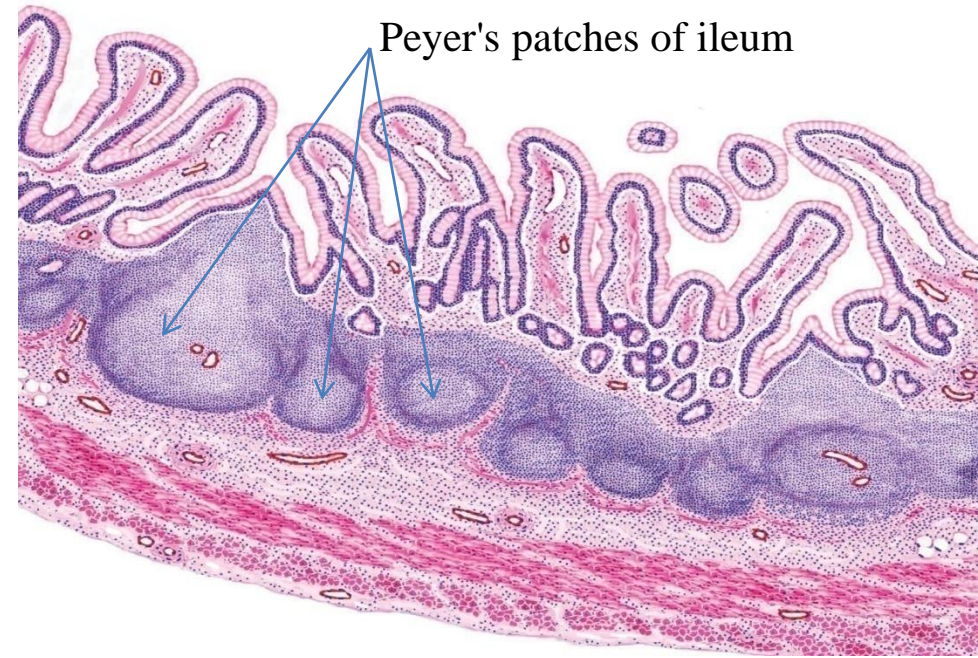
### Examples:

- 1- Peyer's patches of ileum
- 2- Lymphatic nodules of appendix

### Function:

Protects the body from ingested pathogens.

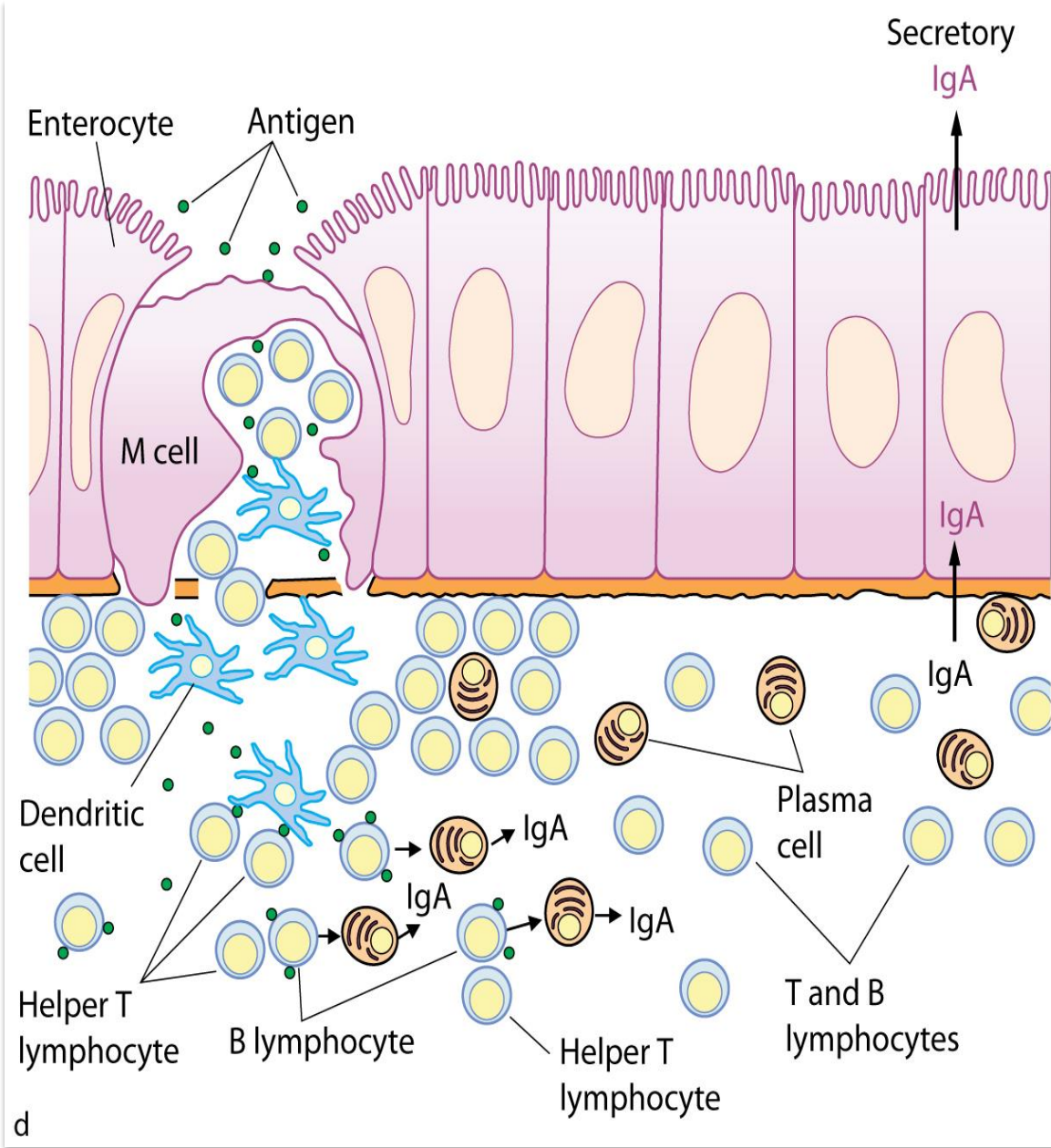
*Remember:*  
Diffuse MALT extends from the pharynx along the entire gastrointestinal tract but becomes very well-developed again in the mucosa and submucosa of the **ileum**. Here large aggregates of lymphoid nodules comprise the Peyer patches, each containing dozens of nodules with no underlying connective tissue capsule.  
Another significant collection of MALT occurs in the mucosa of the **appendix**



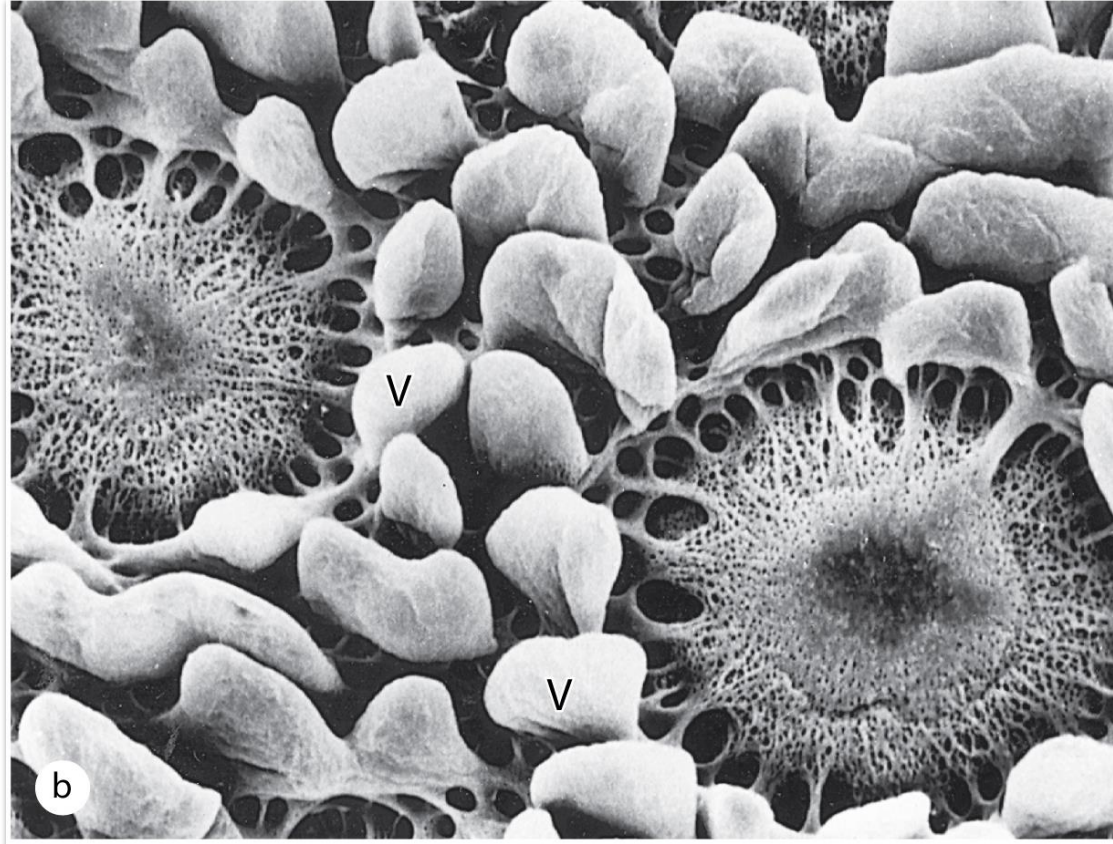


## Peyer's patch and M cells

A summary diagram showing that antigens in the gut lumen are bound by **M cells** and undergo transcytosis into their intraepithelial pockets where **dendritic cells** take up the antigen, process it, and present it to **T helper cells**. B lymphocytes stimulated by the Th cells differentiate into **plasma cells** secreting IgA antibodies. The IgA is transported into the gut lumen where it binds its antigen on the surface of microorganisms, neutralizing potentially harmful invaders before they penetrate the mucosa.



With the surface epithelial cells removed, scanning electron microscopy (SEM) shows typical basement membrane over the villi (V) but reveals a highly porous covering over lymphoid nodules of the Peyer patch.



**Peyer's patch  
and M cells**

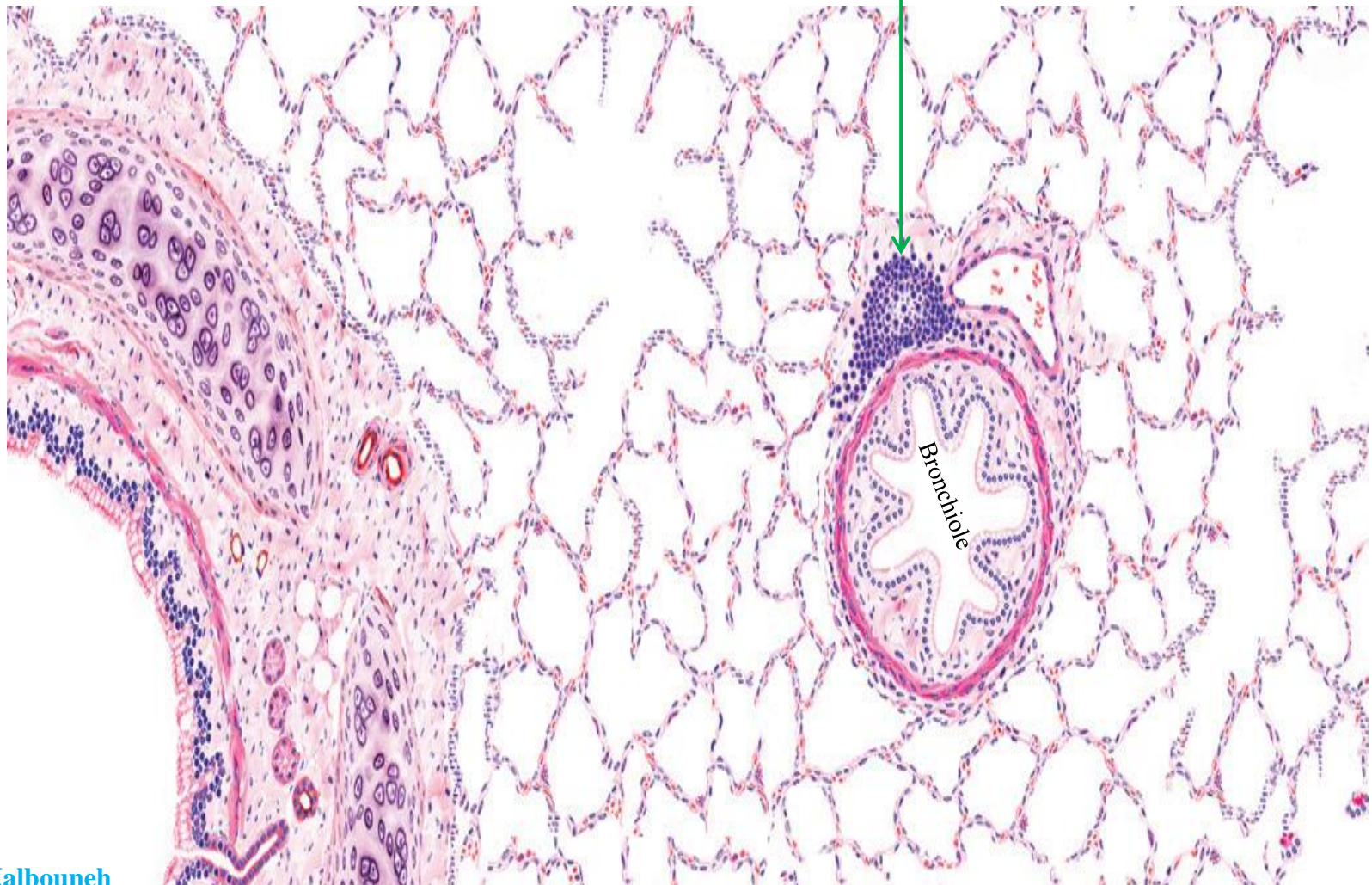
This sieve-like basement membrane facilitates interactions between immune cells and M cells in the epithelium over the nodules.

## Bronchus-associated lymphatic tissue (BALT)

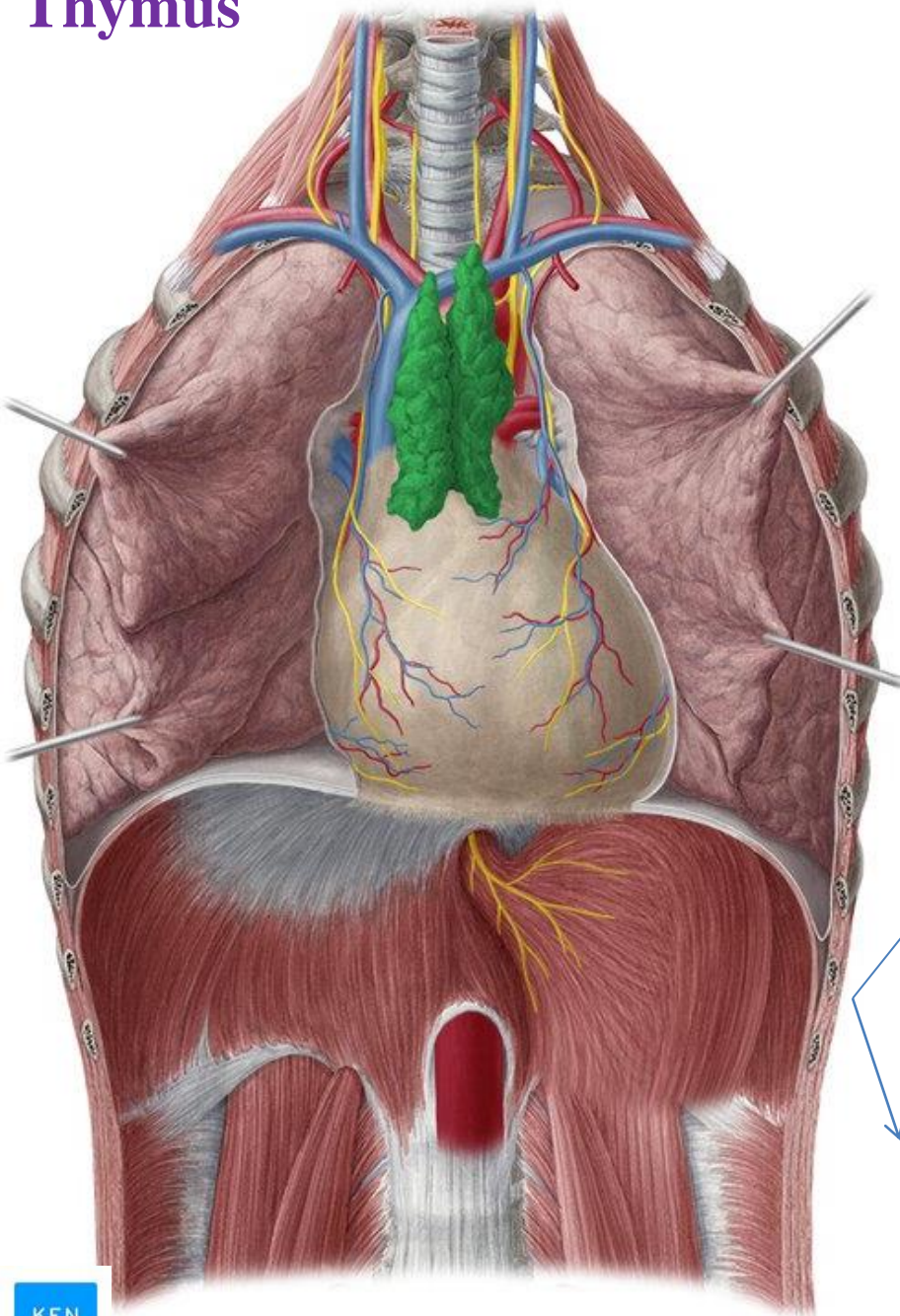
Is located in the mucosa of the bronchioles.

### Function:


Protects the body from inhaled pathogens.



# Thymus



- ✓ Within the thymus, immature T-cells develop, differentiate, and multiply, as well as gaining their antigen specificity and immune tolerance to the body's own tissues.
- ✓ The thymus is a bi-lobed gland located in the anterior mediastinum, posterior to the sternum and anterior to the trachea.
- ✓ It is large in the newborn and young child. From puberty onwards, it gradually becomes replaced by fat.



*Fully formed and functional at birth, the thymus remains large and very active in T-cell production until puberty during which it normally undergoes involution, with decreasing lymphoid tissue mass and cellularity and reduced T cell output*

may be involved with the decline of immune function in the elderly

- ✓ The thymus is also part of the endocrine system.

## The thymus has a double embryonic origin

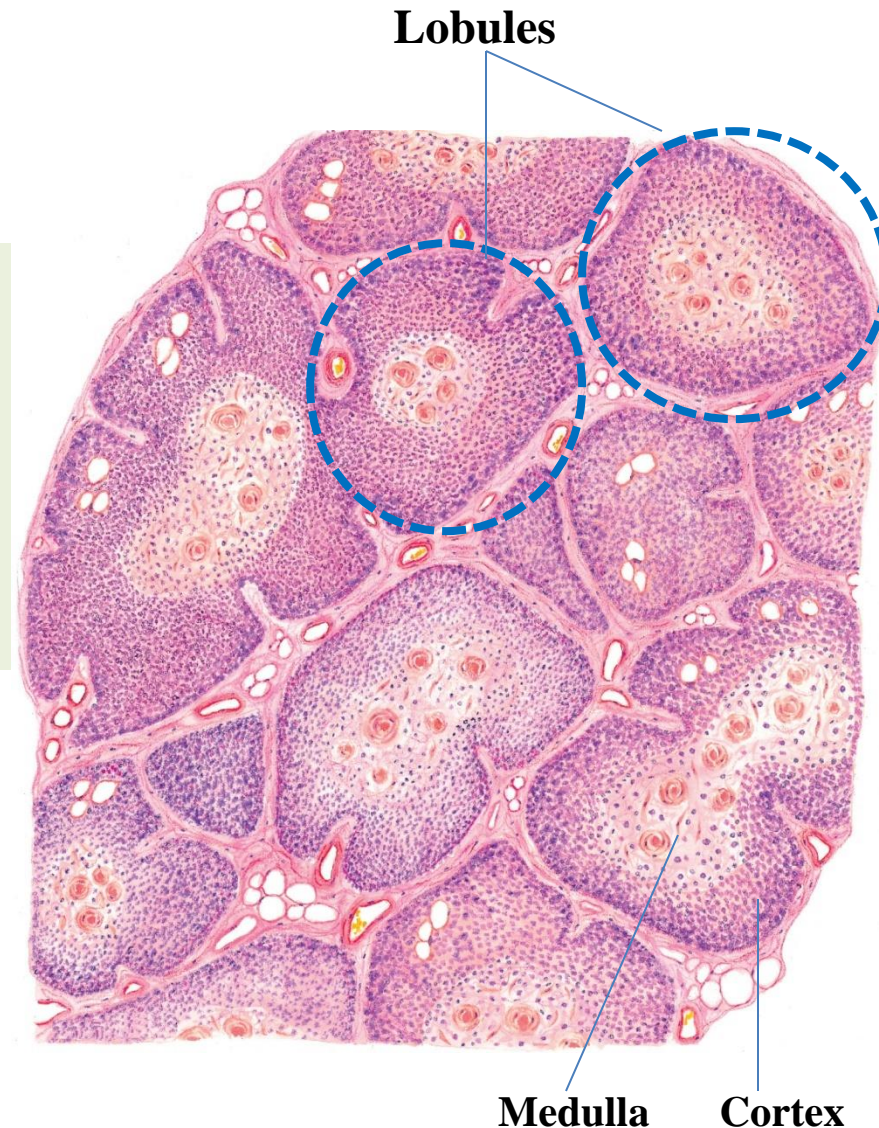
### Endoderm and Mesoderm

Originates from the embryo's third pair of pharyngeal pouches



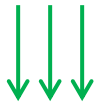unique thymic epithelial cells

**Hematopoietic origin**  
Immature T lymphocytes (T lymphoblasts) circulating from the bone marrow to invade and proliferate in thymus during its development.



The thymus has a connective tissue capsule that extends septa, dividing the organ into many incomplete **lobules**.

Each lobule has an outer **darkly basophilic cortex** surrounding a more **lightly stained medulla**.



*The staining differences reflect the much greater density of lymphocytes in the cortex than the medulla*

Note: Cells of the medulla are less densely packed than in the cortex

**Thymic Epithelial Cells (TECs)**  
(Epithelial reticular cells)

immature T cells  
(T lymphoblasts,  
pre T cells,  
thymocytes)  
*(in various stages of  
differentiation  
and maturation)*

**Thymotaxin**  
**Thymosin**  
**Thymopoietin**

Thymotaxin: is a chemotactic peptide that attracts the migration of T lymphoblasts from bone marrow to thymus

Trabecula

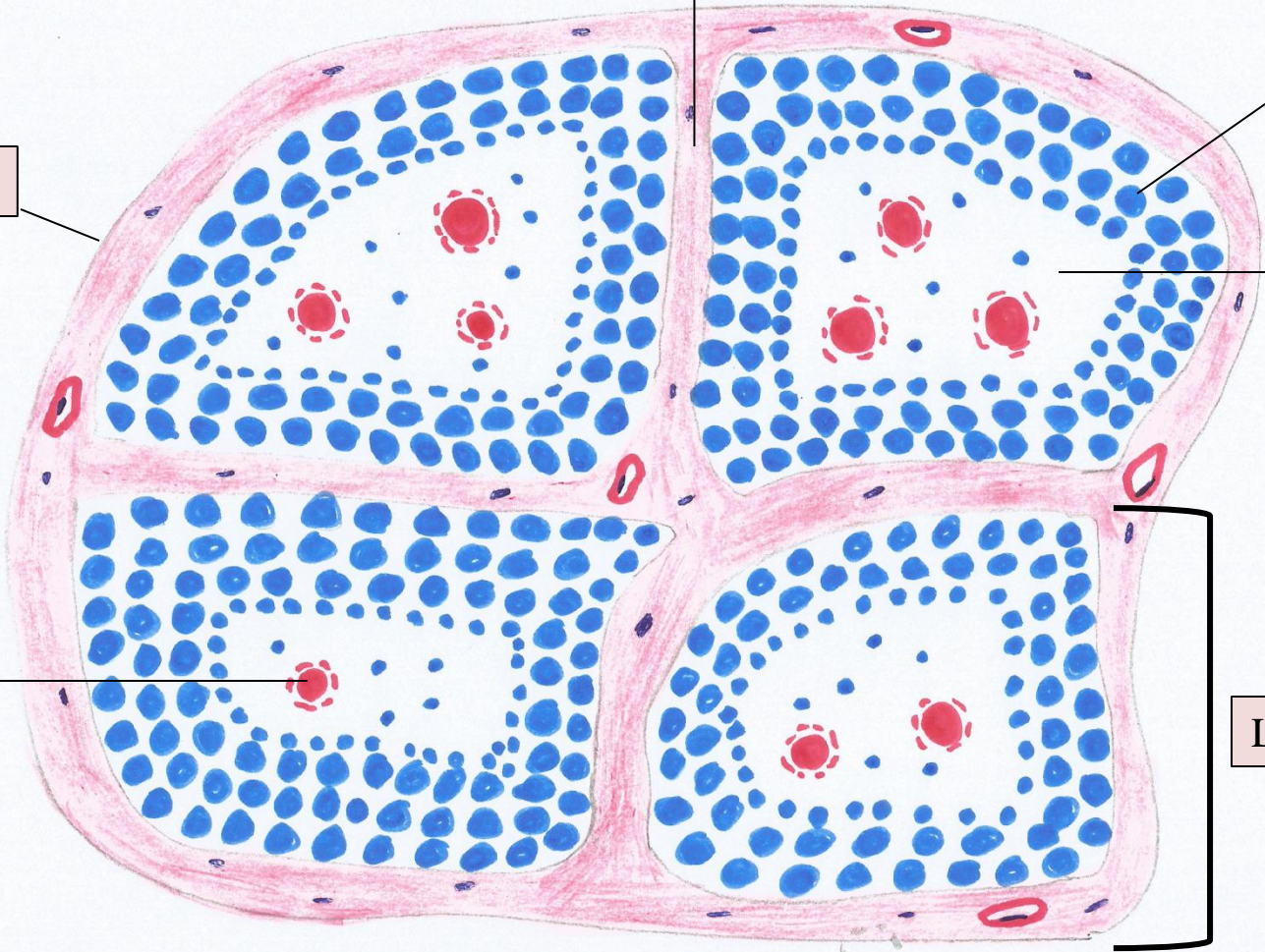
Cortex

Capsule

Medulla

Hassall corpuscle

Lobule



**The cortex contains:**

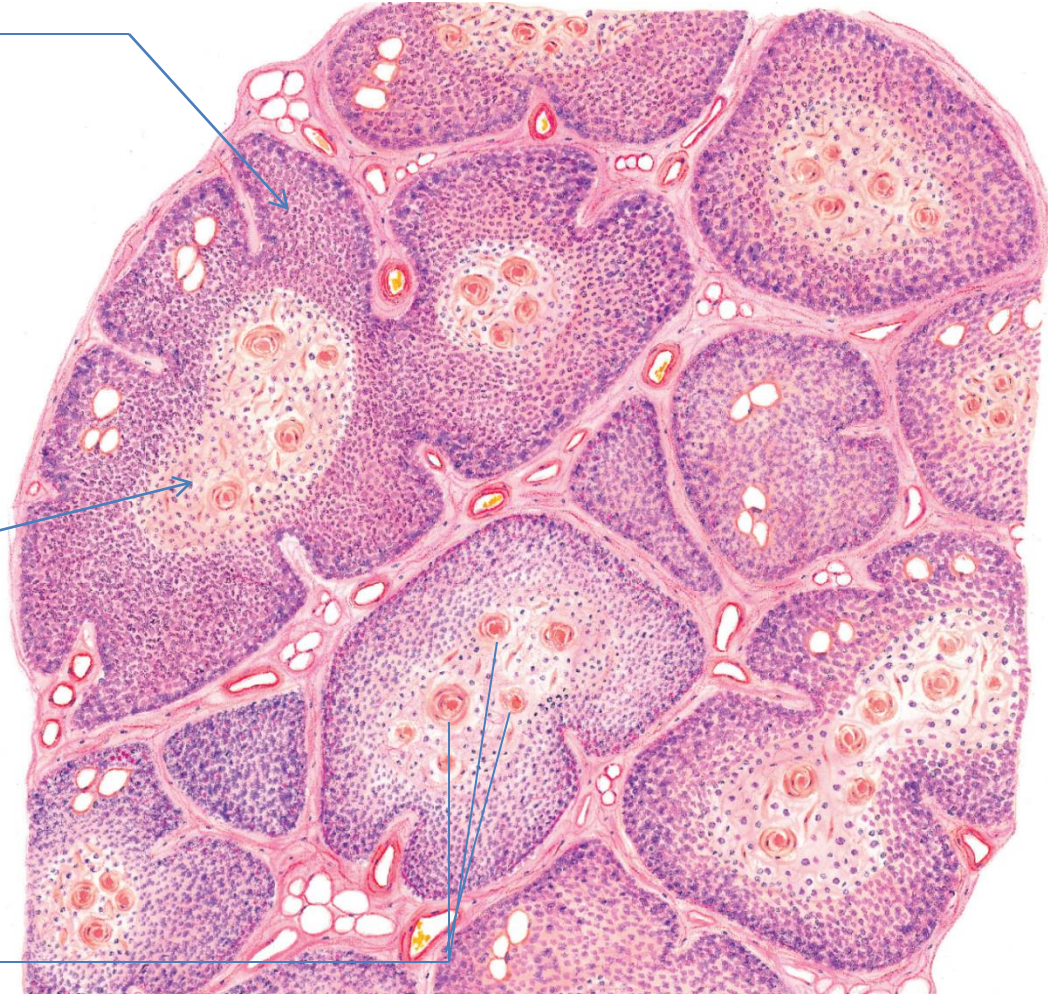
- 1. Immature T cells (T lymphoblasts, thymocytes) (*in various stages of differentiation and maturation*)
- 2. Macrophages
- 3. Unique thymic epithelial cells (TECs)

As T cells mature, they migrate to the medulla

**The medulla contains:**

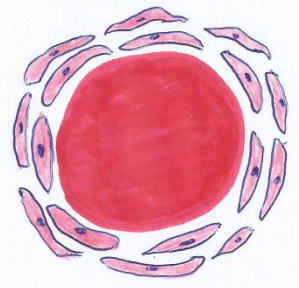
- 1. Fewer and more mature lymphocytes.
- 2. Macrophages
- 3. Dendritic cells (APCs)
- 4. Unique thymic epithelial cells (TECs)
- 5. Large aggregates of TECs called

**Hassall corpuscles**



**Hassall corpuscles** are unique to the thymic medulla

- ✓ Up to 100 μm in diameter
- ✓ Are concentric aggregates of squamous cells with central keratinization (**acidophilic**)
- ✓ Tend to grow larger with age





# Thymic Epithelial Cells (TECs) (Epithelial reticular cells)

*Develop from endoderm*

1- Form a stroma to which macrophages and developing lymphocytes attach instead of reticular fibers

Form a network of cells bound together by desmosomes

2- Line the capsule and septa and surround all blood vessels in the cortex



Form a **blood-thymus barrier** preventing antigens in the blood from making contact with the developing T cells (**in cortex**)

3- Envelop groups of T cells that are multiplying and maturing (**in cortex**)

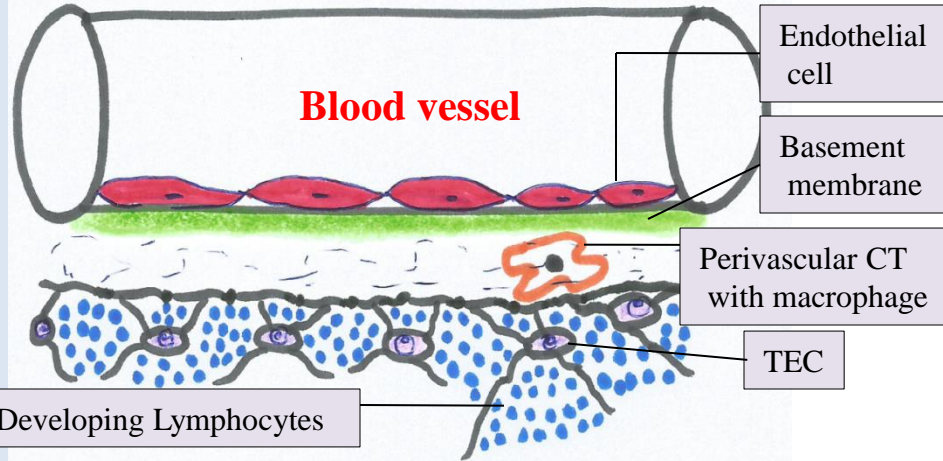
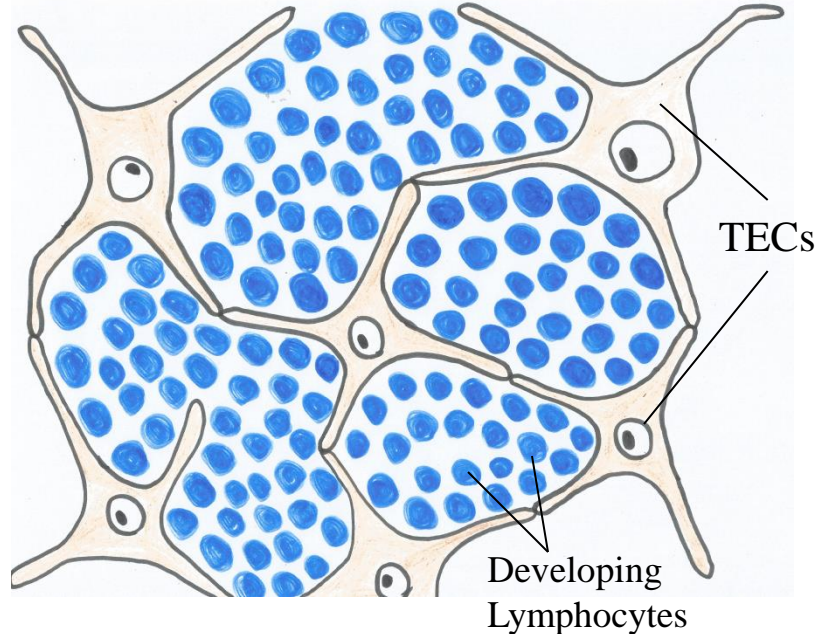
4- Act as APCs, expressing MHC class II and MHC class I molecules (**in cortex**)

5- Express many specialized proteins specific to cells of other organs, *tissue specific antigens* (**in medulla**)

6- Secrete hormones that promote the differentiation of T cells (endocrine thymus)

**Thymosin, Thymopoietin**

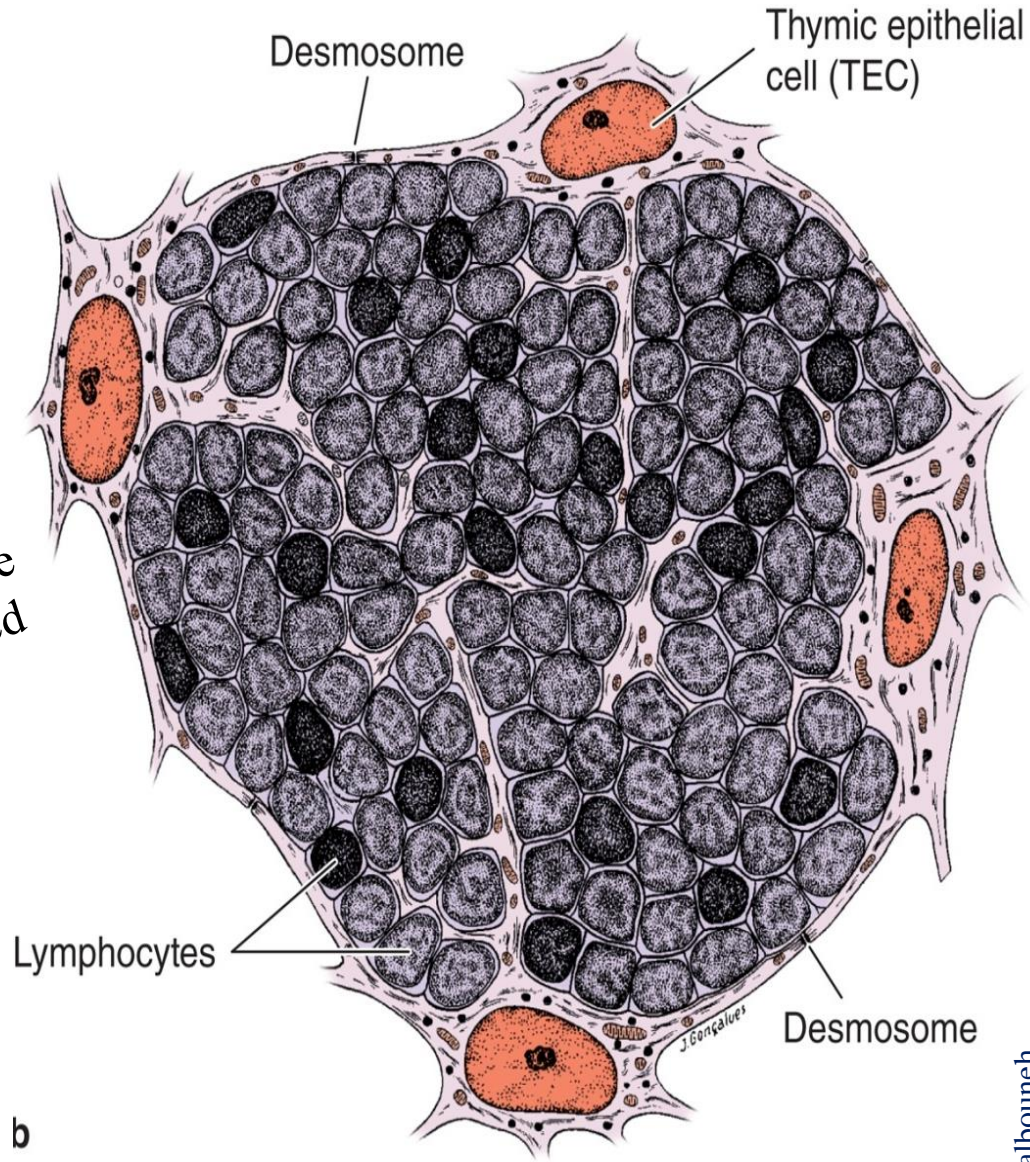
Dr. Heba Kalbouneh




Thymic epithelial cells are also called  
**Nursing Cells**



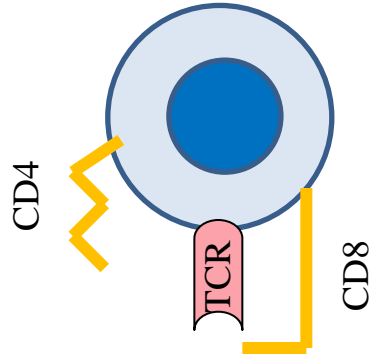
They form sheets for cells deep to the capsule, around septa and blood vessels, to isolate developing T lymphocytes in the cortex from contact with antigens (present in the blood), while they are programmed



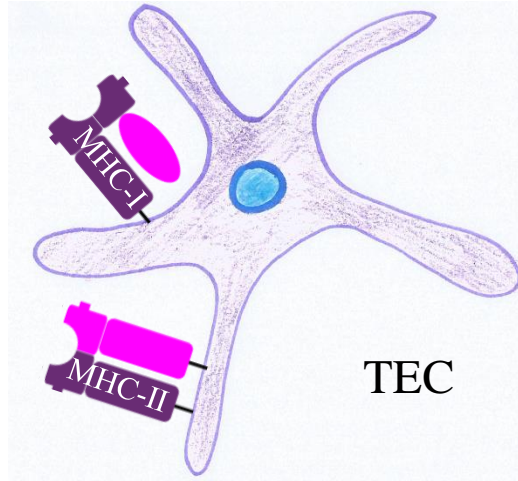
b



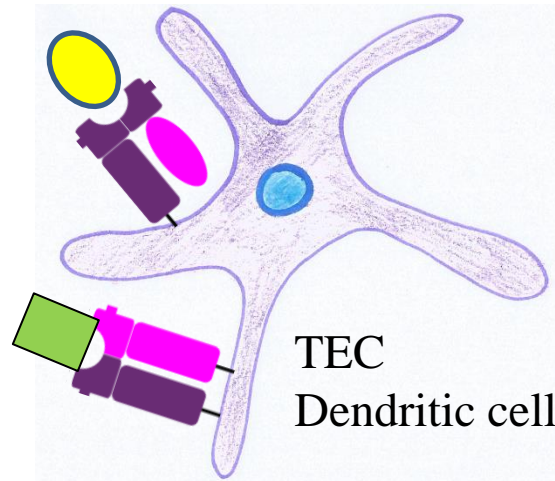

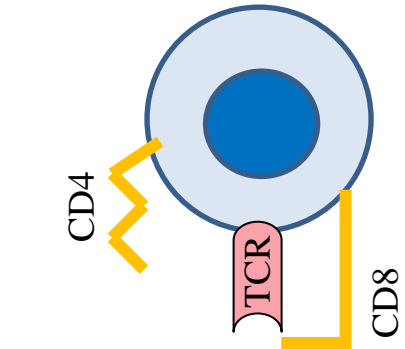
Double negative



Double positive



Cortex



Medulla

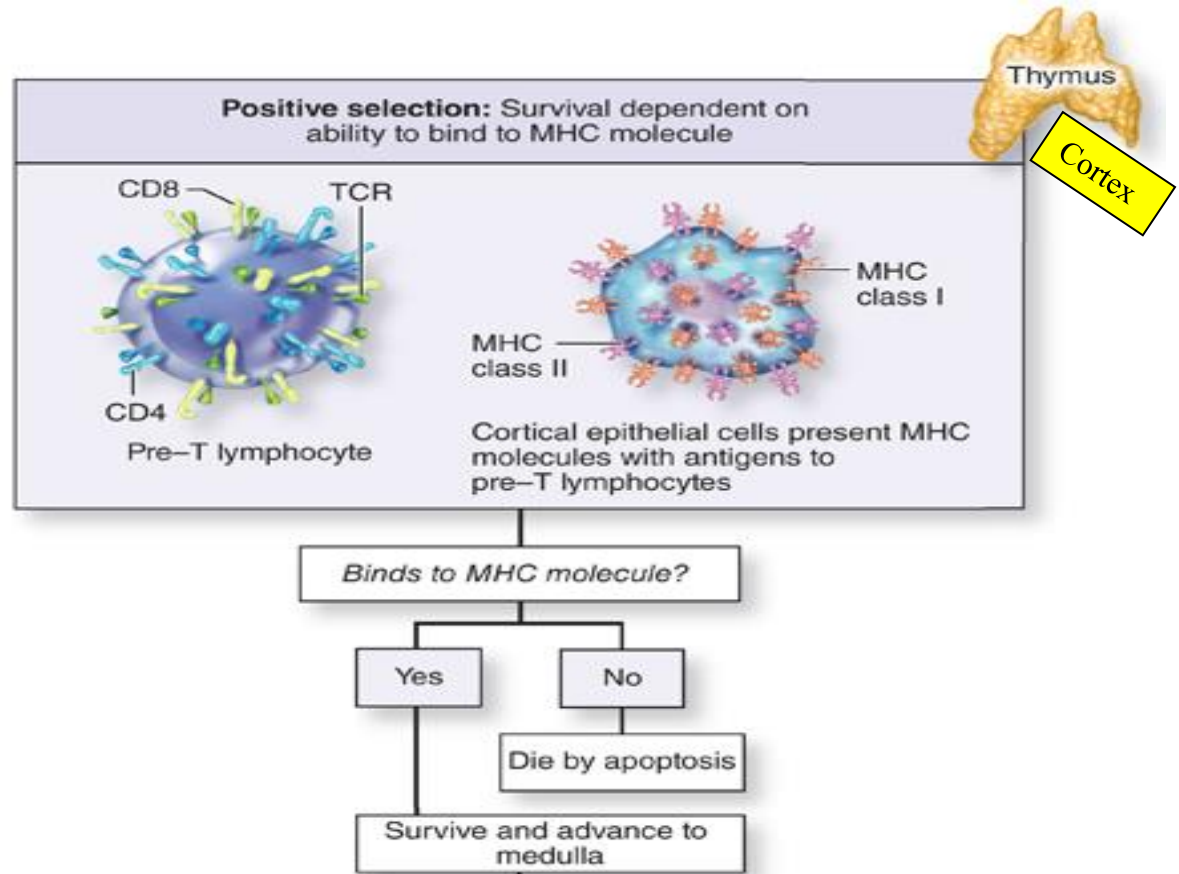
Immature T cells arriving in the thymus do not yet express CD4, CD8, or a TCR.



These cells populate the cortex and begin to proliferate and express TCR proteins, CD4 and CD8



TECs in the cortex present the developing T cells with peptides on both MHC class I and class II molecules



Developing T cells whose TCRs or whose CD4 or CD8 cannot recognize MHC molecules undergo apoptosis before they leave the cortex

*This interaction determines whether the newly made TCR proteins of these cells are functional.*



A cell's survival depends on whether its TCRs can recognize and bind MHC molecules properly (**positive selection**)



80% of the developing T cells die in the cortex (undergo apoptosis) and are removed by the macrophages

The surviving cells (T cells with functional TCRs) enter medulla

In the medulla, T cells encounter antigens presented on both TECs and dendritic cells.



Here the focus is on removing T cells whose TCRs bind self-antigens

A cell's survival depends on a cell **not** binding to MHC molecules with self-antigens  
(**negative selection**)



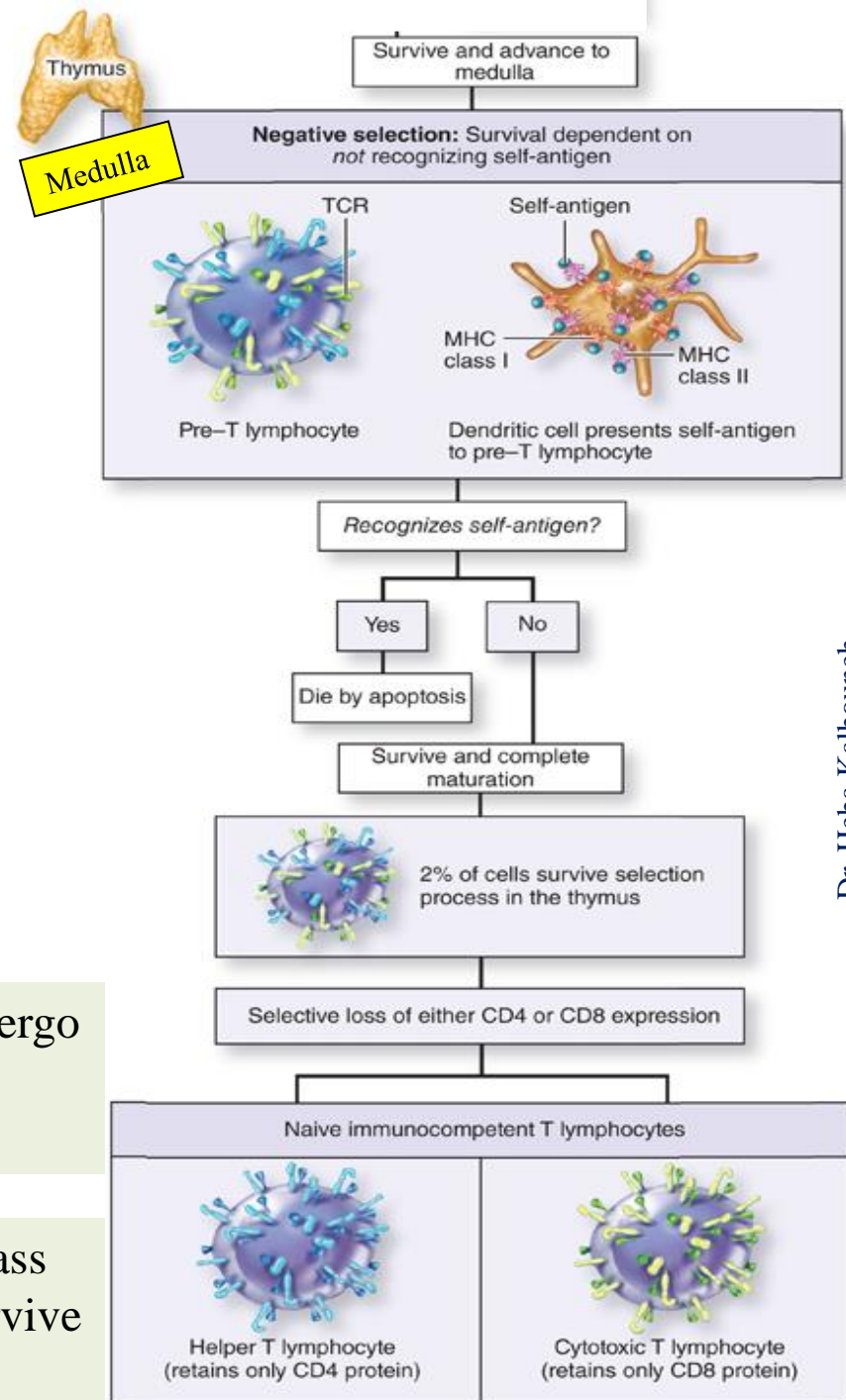
Self-antigens presented here are those from proteins specific for many tissues other than the thymus (tissue specific antigens )



T cells that bind MHCs containing self antigens undergo apoptosis and are removed by the macrophages  
(**if survive** → **autoimmune response!!!**)



Only about 2% of all developing T lymphocytes pass both the positive and negative selection tests and survive to exit the thymus as immunocompetent T cells.



To summarize:

**Positive selection** occurs in the cortex and allows survival only of T cells with functional TCRs that recognize MHC class I and class II molecules. **Negative selection** occurs in the medulla and allows survival only of T cells that do **not** bind self-antigens presented on dendritic cells and TECs there.



T cells undergo positive and negative selection processes to ensure that they will not react with healthy cells of the body.

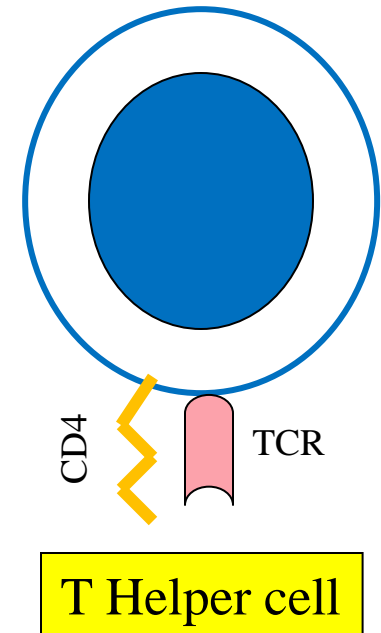
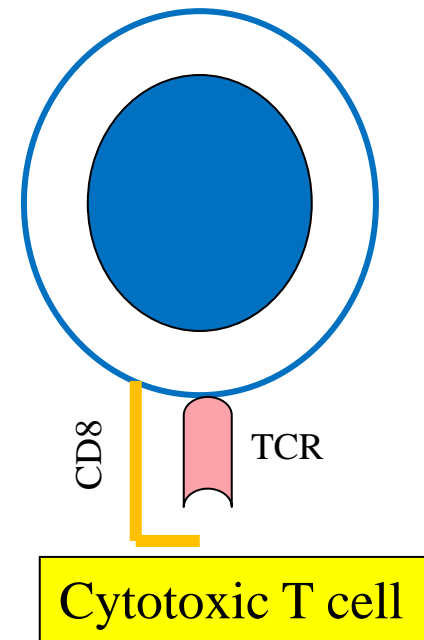
Depending on which class of MHC they interacted with, most of these lymphocytes will have stopped expressing either CD8 or CD4, and become either helper T cell or cytotoxic T cell

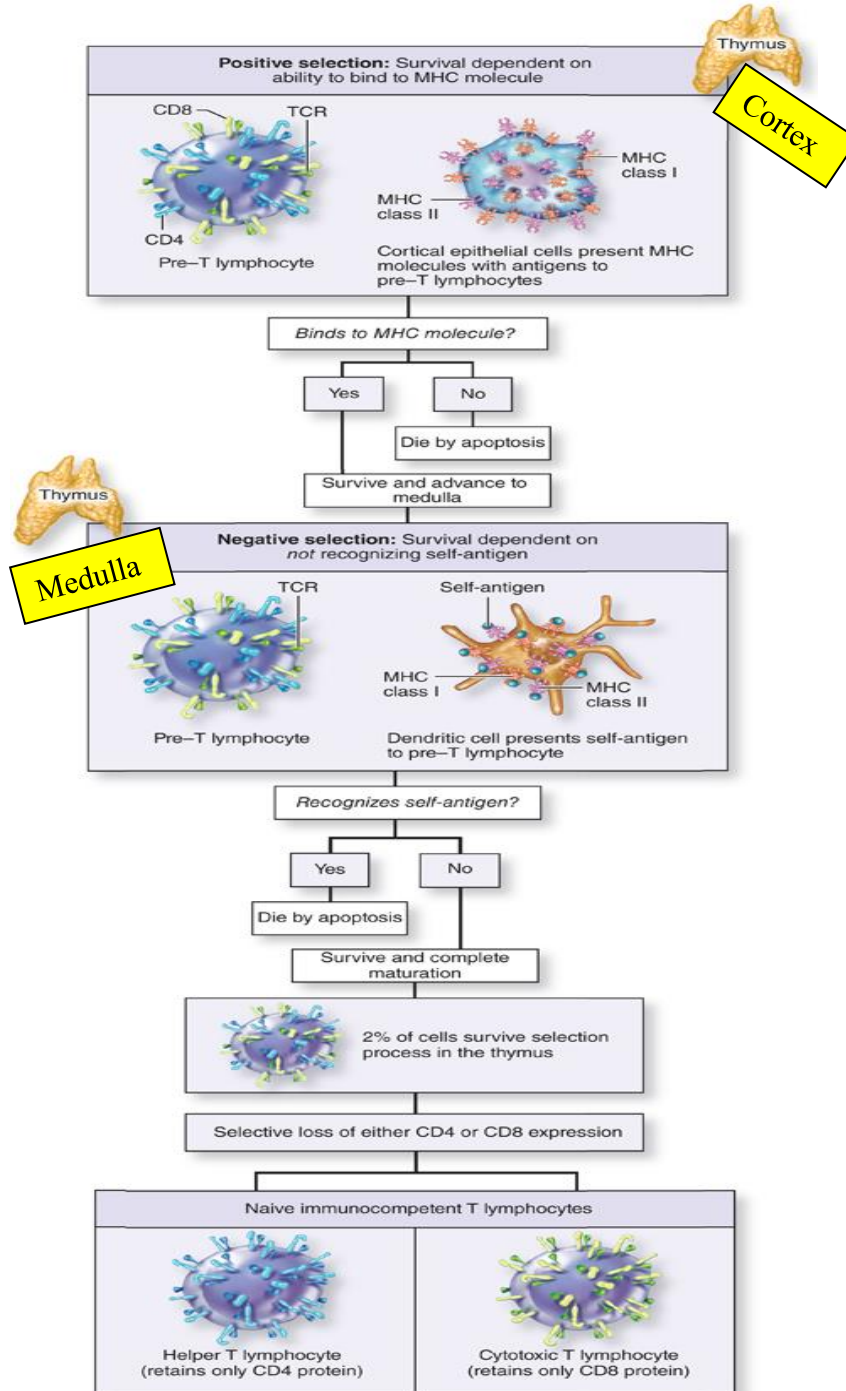
Fully mature T cells (immunocompetent T-cells) leave the medulla via venules and efferent lymphatic vessels

Then..

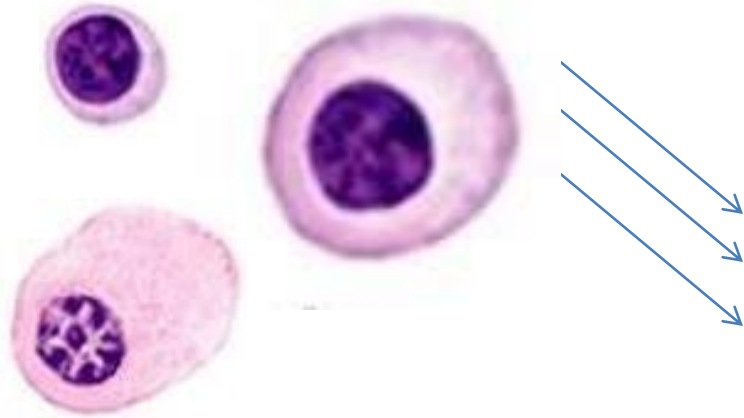
They migrate from the thymus to specific regions in the lymph nodes (paracortex), the spleen (PALS), and diffuse lymphatic tissues, where they reside and are responsible for

**cell-mediated immune responses**





After maturation in primary lymphoid organs, B and T cells circulate to the peripheral secondary lymphoid organs (the MALT, the lymph nodes, and the spleen). Lymphocytes do not stay long in the lymphoid organs; they continuously recirculate through the body in connective tissues, blood, and lymph.



*Lymphocytes continuously **circulate** between the lymph and blood until they encounter their antigen*

### Choices of lymphocytes:

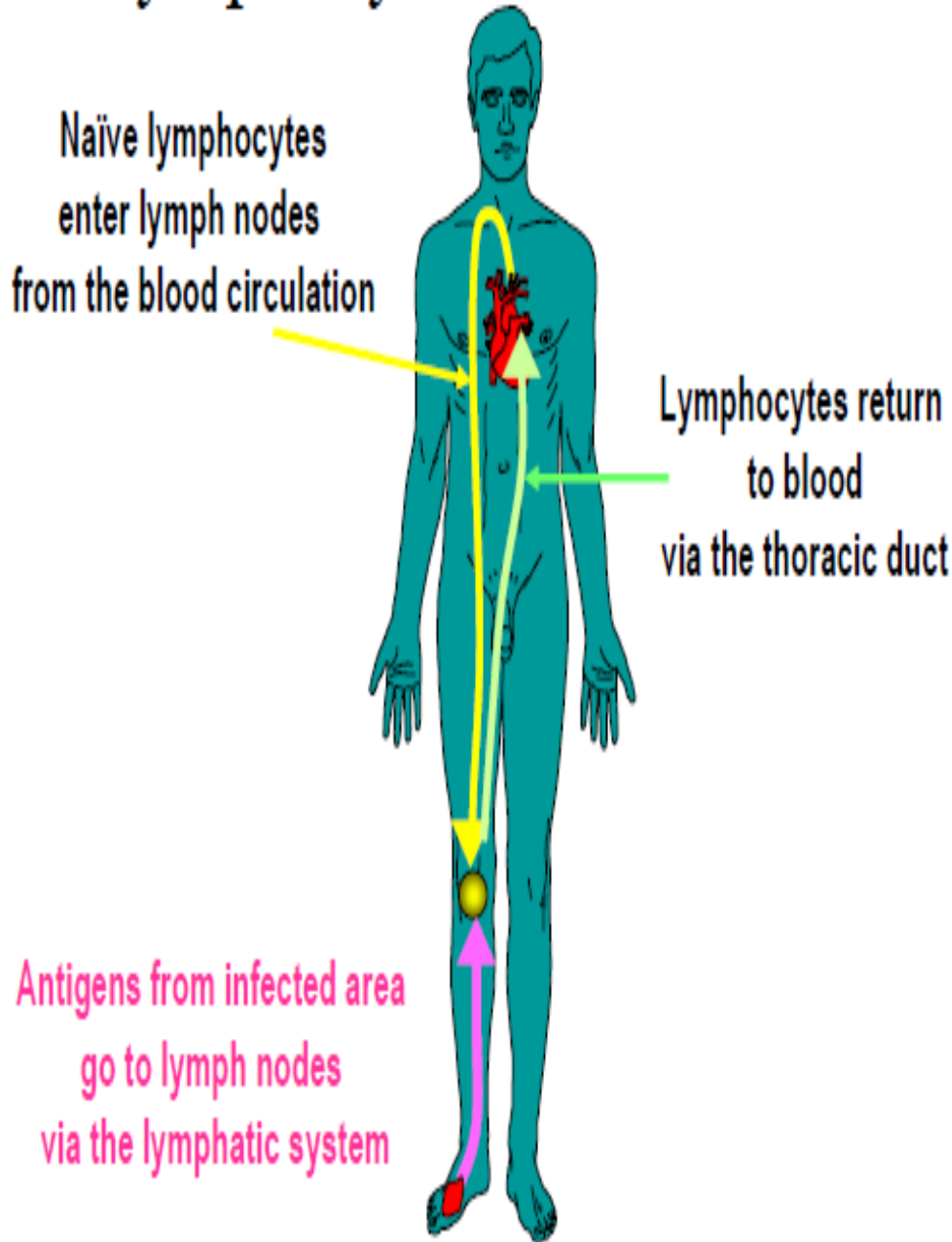
- 1- If no antigen is present:** lymphocytes routinely enter and leave secondary lymphoid tissues
- 2- If antigen enters the secondary lymphoid tissue:** Lymphocyte proliferation in response to antigen occurs within the lymphoid tissue. After several days, antigen-activated lymphocytes begin leaving the lymphoid tissue.

Because of the constant mobility of lymphocytes and APCs, the cellular locations and microscopic details of lymphoid organs differ from one day to the next. However, the relative percentages of T and B lymphocytes in these compartments are relatively steady

Lymphocytes in the marrow and thymus of a newborn infant not yet exposed to antigens are immunocompetent but naive (not yet exposed to antigens). After circulating to the various secondary lymphoid structures, lymphocytes are exposed to antigens on APCs and become activated, proliferating to produce a clone of lymphocytes all able to recognize that antigen



# Lymphocyte Recirculation



*Advantage of lymphocyte recirculation:*

Lymphocyte recirculation enables the limited number of naïve lymphocytes in an individual that are specific for a particular antigen to search for that antigen throughout the body

It ensures that particular lymphocytes are delivered to particular tissue



Recirculation of naïve lymphocytes:  
recirculate through secondary lymphoid organs

Recirculation of activated lymphocytes:  
migrate to peripheral tissues at sites of infection