Embryology

Derivatere of Phryngeal Arches

1st Arch
- maxillary (maxilla, zygomatic, Lower Part of temporal)
- mandibular (Meckel's cartilage)
  - Ventral
    - ramus of the mandible
    - "complete with intramembranous ossification"
  - middle
    - Anterior ligament of malleus
    - sphenomandibular ligment
  - dorsal
    - malleus
    - Incus

Muscles →
- M of mastication
- tensor tympani
- Anterior digastric
- mylohyoid
- tensor veli palatini

2nd Arch ⟹ Reichert's cartilage
- Ventral
  - upper part of the body of hyoid
  - Lesser horn of the hyoid bone
- middle
  - stylohyoid ligment
- dorsal
  - stapes
  - styloid Process

Muscles →
- M of facil expression
- stapedius
- stylohyoid
- Posterior belly of digastric

Fate of Pharyngeal clefts

* first cleft
  - EAM
  - outer layer of tympanic membrane (skin)

* 2nd 3rd and 4th clefts

2nd arch growth donwnword and cover the 2nd 3rd and 4th clefts creat a space in between called (cervical sinus)

Cervical (branchial) cyst
Remnant of cervical sinus
Can form a fluid filled cyst in the neck

The cervical cyst is usually not visible at birth but becomes evident as it **enlarges during childhood.**

Presents as a slowly enlarging lateral neck mass typically located in the lateral aspect of the neck, arising at any point along the anterior border of the **sternocleidomastoid muscle.** These cysts may intermittently swell, particularly in association with upper respiratory tract infections.

fate of Phryneal pouches

1st Pouch
- Dorsal
  - inner mucosa of tympanic membrane
  - Middle ear
  - Eustachian tube
- ventral
  - occupied by the developing tongue

2nd pouch
- Dorsal
  - Palatine tonsils

"Congenital Anomalies"

case	Defect
Dermoid cyst	cystic swelling at a line of fusion between processes of the face
Oblique facial cleft	failuer of fusion between maxillary and fronto-nasal processes
macrostomia or microstomia	failuer of fusion of maxillary and mandibular processes
Cleft hare Lip	failuer of fusion between maxillary and intramaxillary segment
median cleft lip	mal fusion between medial nasal prominences
cleft lower Lip	incomplete fusion between mandibular processes
Primary cleft palate	failure of fusion between maxillary and intramaxillary segment
Secondary cleft Palate	failure of fusion between maxillary processes with each other

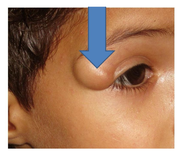

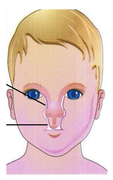

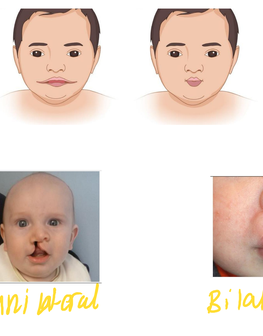
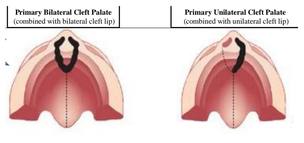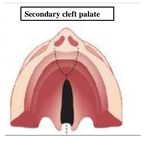
Unilateral Bilateral