(Lecture 6).

- There is a certine bone tumor that we don't know the cell of origin or the Pathogenesis like :-

① Ewing Sacroma :- Consider small blue cell tumor

(PENT :- Primitive neuroectodermal tumor) → high grade Primitive

histologically → we see sheet of small sized tumor cell with large nucleus & little cytoplasm

Called Blue → when we stain it with H&E they appear blue due to the blue color

nucleus occupies 98% Probably of the cell volume.

2nd most common sacroma of bone after osteosacroma & between 10-20 age & Diaphysis of long bone

* most common translocation Present about 90% of Ewing Sacroma case is t(11:22) (q24:q12) which generate an aberrant transcription factor through fusion of the EWSR1 gene with FLI1 gene

* Treatment :- neoadjuvant chemotherapy & followed by surgery / long time survival reach 75%

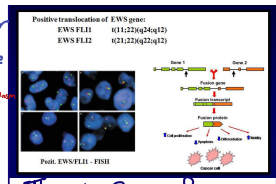

- This is Pic of FISH (Florescent In situ hybridization) analysis which is The most sensitive Test for Ewing Sacroma

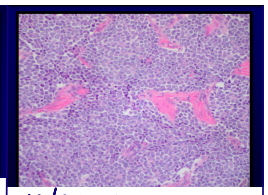

- under microscope we see alot of small blue cell tumor destroying the bone

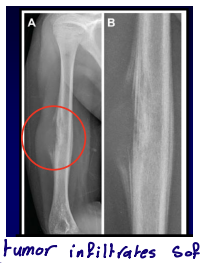

- tumor infiltrates soft Tissue and elevat Periosteum causing Codman's traingle which isn't specific for this Tumor only

② Giant cell tumor of bone :- locally agressive neoplasm of adult

you can't see it in children or under age 20

* Epiphyses of long bone
* Rare malignant behavior & 95% behaves in a benign fashion
* cell contain high levels of RANKL (which stimulat the diferentiation of osteoclast)
* Treatment :- curetting and Put abone cement or resection

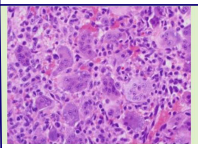

* histologically :- we see wall to wall multi-nucleated osteo clast-like giant cell tumor cell = giant cell + The one in between The single mononuclear cell

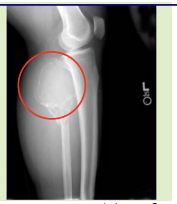

* it has bubble apearance expanding the cortex without infiltration of the extra cortical space

③ Aneurysmal Bone cyst (ABC)

- Benign tumor & Blood filled with cyst
* metaphysis of long bone & adult
* Treatment :- Curetting & bone cementing
* if it localized you can remove it without impact the function like This Pic

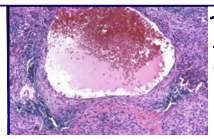

- histologically :- blood filled with cyst and reactive fibrouse tissue around it

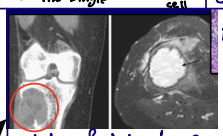

it could be a giant cell tumor so we go in it if there is alot of blood comes out with fibrous septa its (ABC)

④ nonossifying Fibroma :- (fibroma without ossification)

Benign lesion & maybe reactive not true neoplasm

other name (FCD / MFD) & metaphysis

histology :- bland fibroblastic Proliferation

- may resolve spontaneously

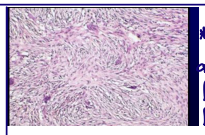

* look like a benign fibroma or fibroblast
* There is multi nucleated giant cell but not common

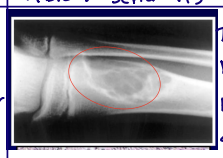

There is a lesion here but not destroying the sounding structure or elevating Periosteum and it is well circumscribed - (fibroma in the bone)

* fibrous dysplasia (FD) :- not real tumor & rather a developmental abnormality of bone genesis due to mutation in GNAS1 gene wich is (cAMP mediated osteoblast differentiation) and this will lead abnormal bone formation

forms of FD :- ① Monostatic : affect 1 bone (maxillary & mandibular most common) ② Polystatic :- multiple bone ③ Mazabraud Syndrom :- (Polystatic of monostatic) FD + Soft tissue myxoma (common tumor for soft tissue)

④ McCune-Albright Syndrom :- Polystatic FD + Café-au-lait Pigmentation (multiple brownish Pigment) + endocrine abnormalities (Precocious Puberty)

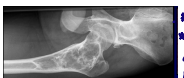

* endocrine abnormality
* slightly similar to Paget disease There is a laghi-mised and sclerotic region
* biopsy help us to differentiate between PAGET and McCune-Albright Syndrom

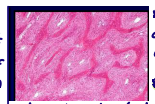

classic charactristic feture of FD

* Biobsy Polyostatic FD appearance of haphazard arrangment of bone trabecule
* Chinese latter apearance

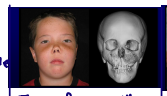

FD of maxillary bone

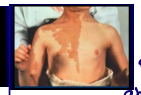

Café-au-lait skin Pigmentation + endocrine abnormalities (Precocious Puberty)

* metastatic tumors to bone :-

① much more common than Primary bone tumors (having tumor from carcinoma or hematopoietic malignancy more common than (osteo, Ewing, chondro) sacroma)

② in adult : most are carcinomas and most common type adenocarcinoma (lung & Prostate breast & kidney / Hyping liver)

③ in children : Neuroblastoma & wilms tumor & rhabdomyo sacroma (Carcinoma in children Rare)

④ usually multiple & axial : vertebra + shoulders & Pelvic bone mostly hematogenous spread

⑤ Lytic & blastic or mixed metastasis occure through mediator secretions

BLASTIC METASTASIS

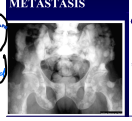

* This Patient with alots of Blastic metastasies
* Primary source is Prostate is commonly associated with Blastic metastasis
* when Prostate goes to bone it can cause Blastic or lytic But Blastic more common

LYTIC METASTASIS

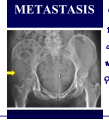

* The bone is eaten in multiple area (vertebra + Pelvic + femur)
* most common Primary of those adenocarcinoma in lung
* This is stage (4) bad Prognosis Patient don't survive 6-12 month

Done by :- Ammar sweilem