



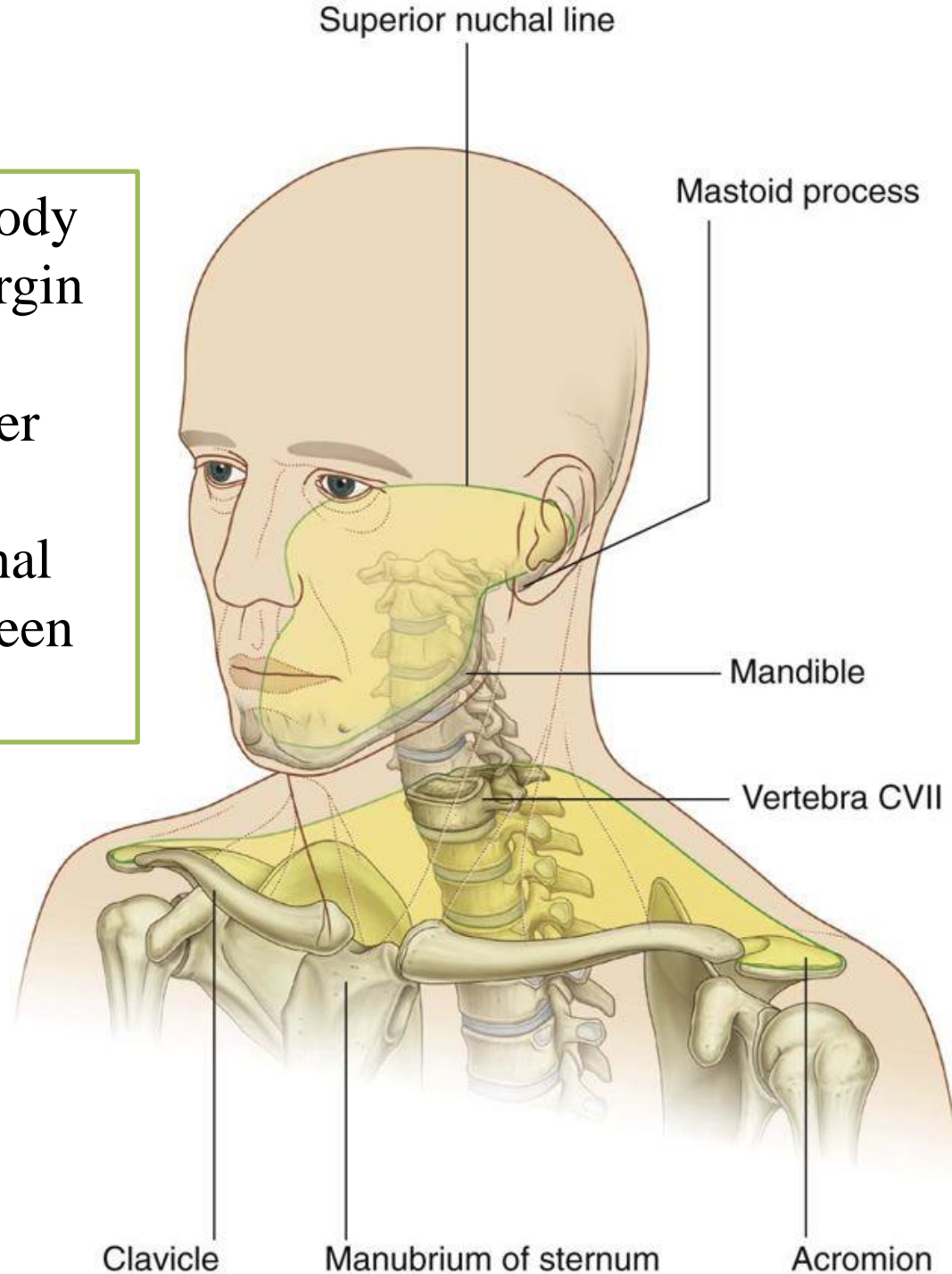
Neck-1

Dr. Heba Kalbouneh, DDS, MSc, DMD/PhD
Associate Professor of Anatomy and Histology

The Neck

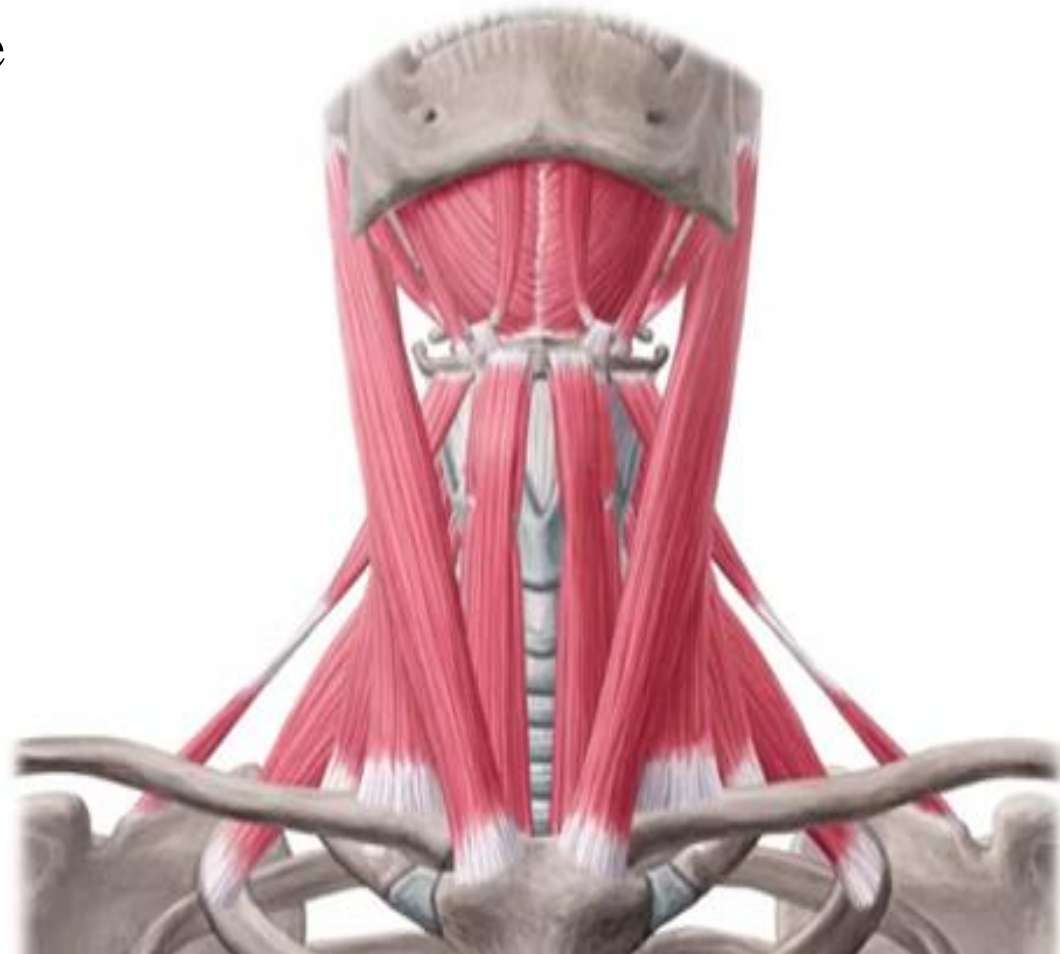The neck is the region of the body that lies between the lower margin of the mandible above and the suprasternal notch and the upper border of the clavicle below.

Posteriorly, from superior nuchal line to intervertebral disc between C7 and T1



Muscles of the neck

- 1- Sternocleidomastoid muscle
- 2- Scalene muscles
- 3- Infrahyoid muscles
- 4- Suprahyoid muscles
- 5- Platysma *Superficial*



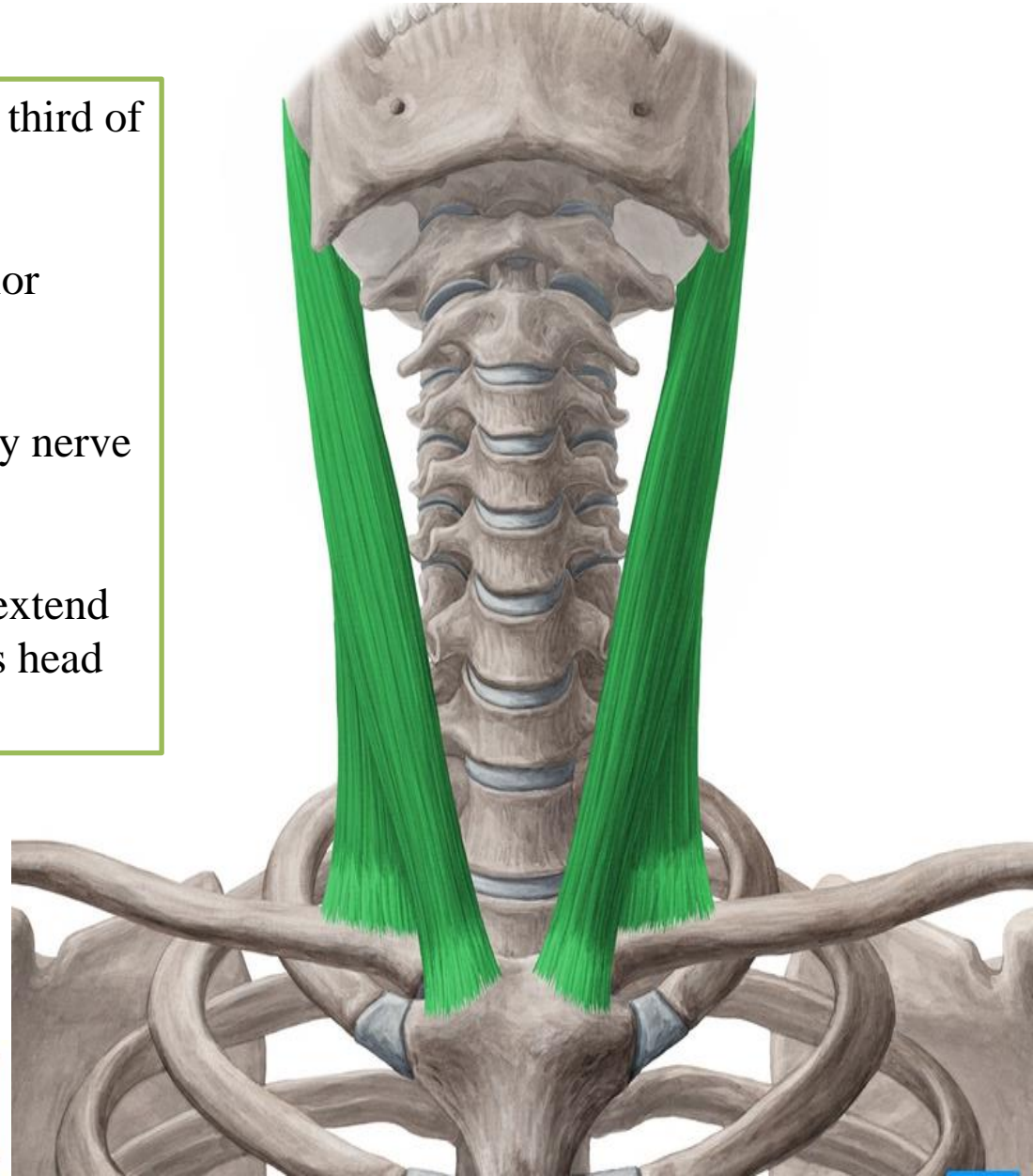
Sternocleidomastoid

Origin: Manubrium sterni and medial third of clavicle (**two heads**)

Insertion: Mastoid process and superior nuchal line

Nerve supply: Spinal part of accessory nerve and C2 and 3

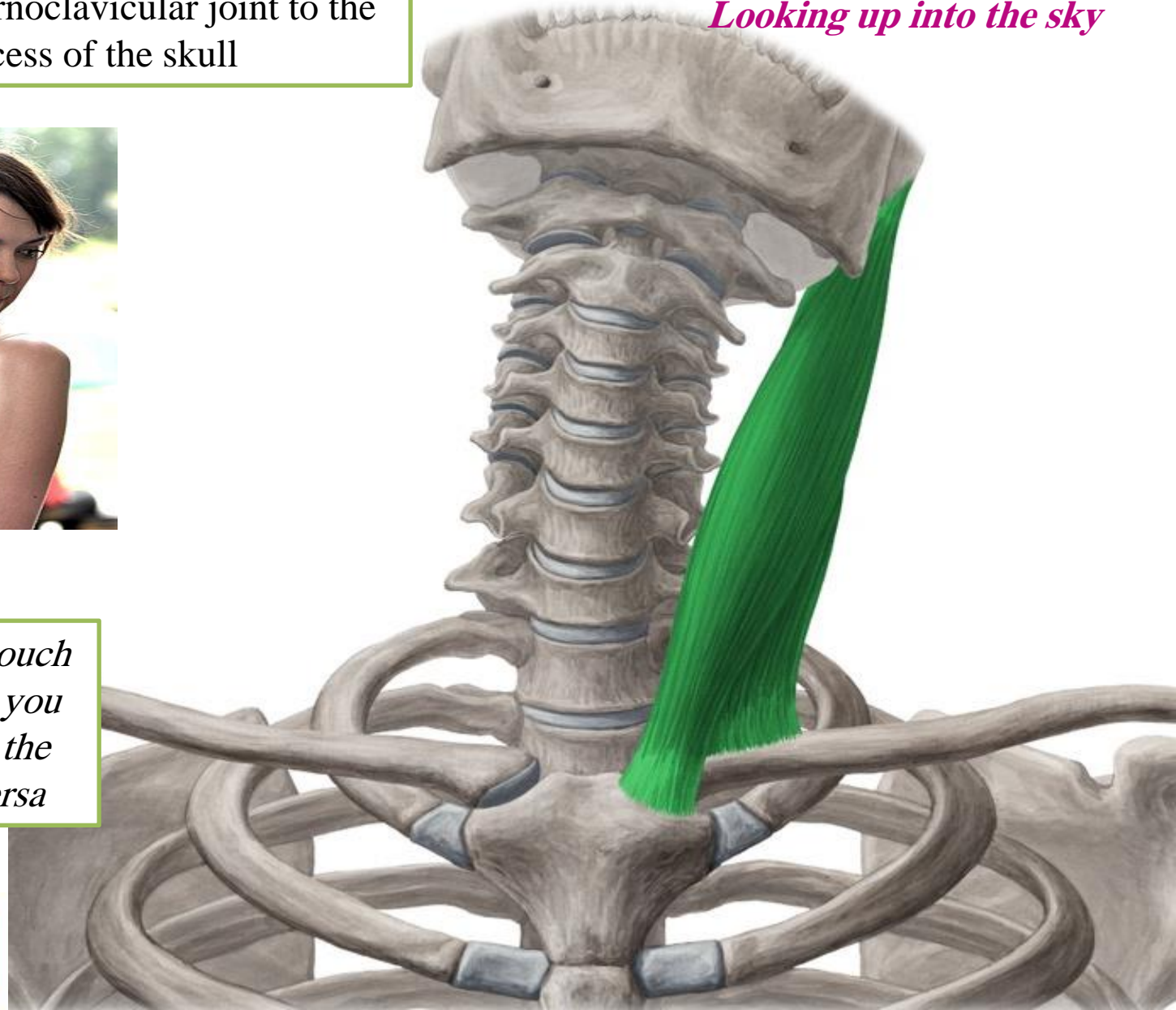
Action: Two muscles acting together extend head and flex neck; one muscle rotates head to opposite side



When **Sternocleidomastoid** contracts, it appears as an oblique band crossing the side of the neck from the sternoclavicular joint to the mastoid process of the skull



Ipsilateral flexion
When you try to touch your shoulder with your ear
Looking up into the sky



You can feel and touch the left one when you turn your face to the right and vice versa

Facts about sternocleidomastoid

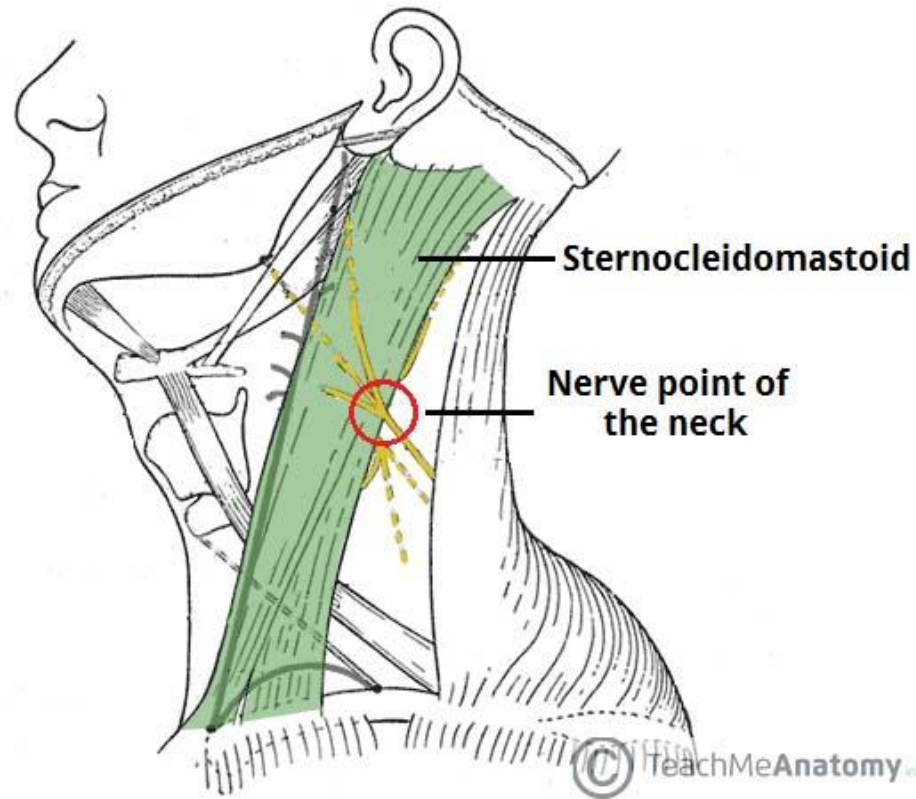
- The carotid pulse can be easily felt just anterior to the middle third of sternocleidomastoid
- Sensory cutaneous branches of cervical plexus emerge at the posterior border of sternocleidomastoid

For anaesthesia of the neck area, a **cervical plexus block** can be used.


Local anaesthetic is injected along the **posterior border** of sternocleidomastoid where the cutaneous branches of the cervical plexus emerge, known as the **nerve point** of the neck (Erb's point/ punctum nervosum)



Congenital torticollis



Poor posture

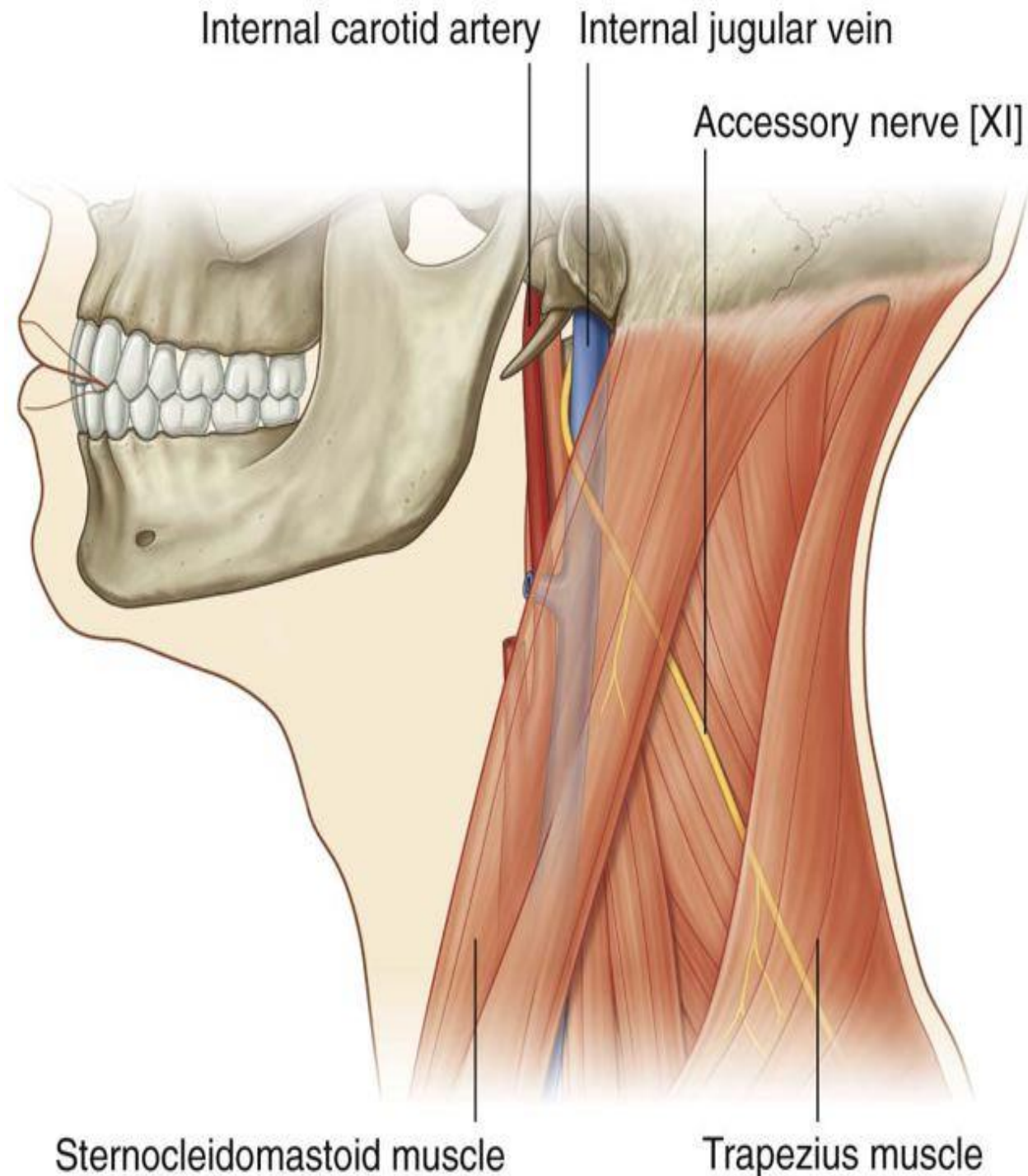


Excessive strain of sternocleidomastoid is caused by poor posture stances like when reading in bed, sleeping with more than one or two pillows, or even long periods of having your head turned to one side. Over time, this can **cause sternocleidomastoid spasm**

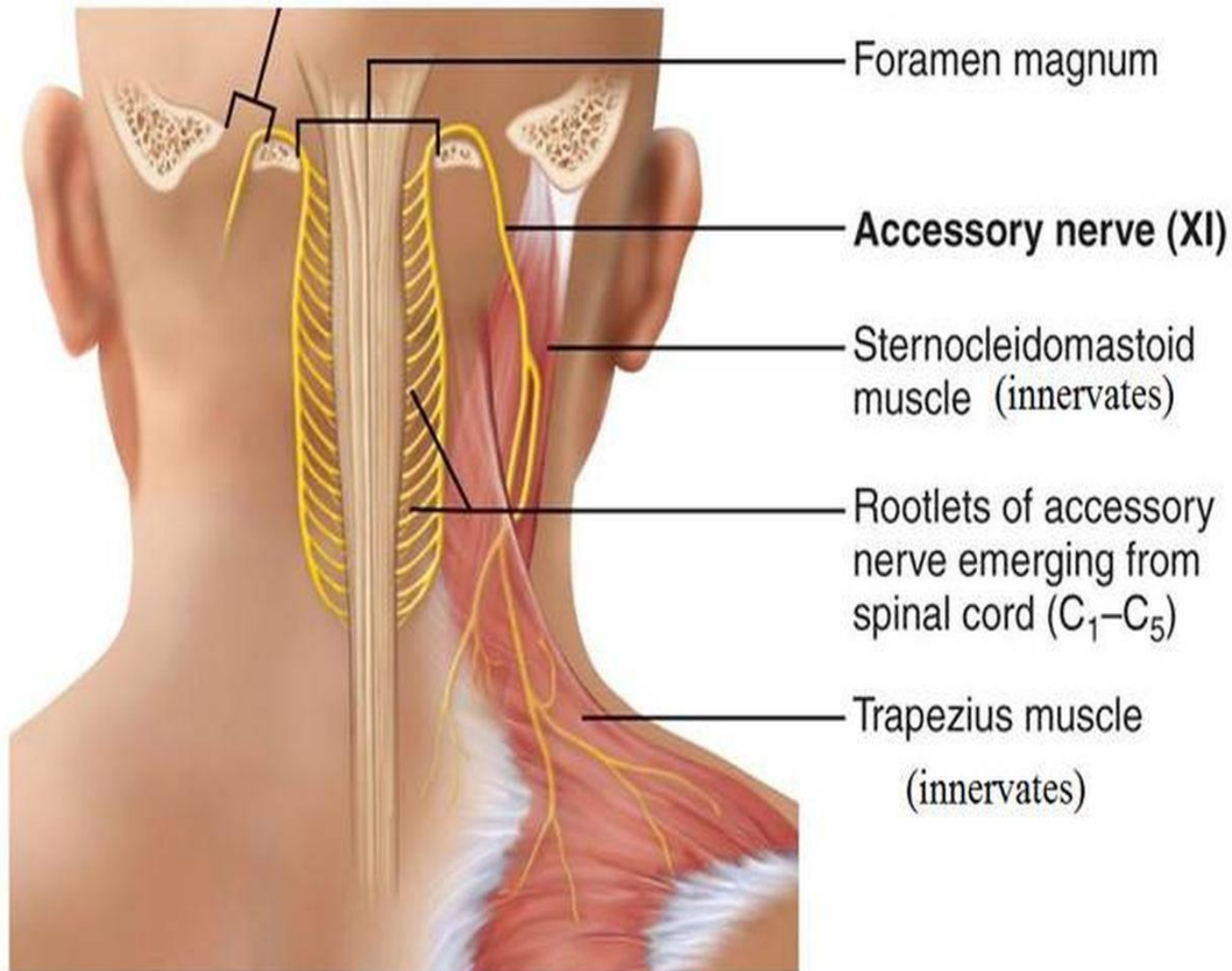
The accessory nerve

- Leaves the skull through the **jugular foramen**
- Two roots :
 - **The cranial root:** joins the vagus nerve
 - **The spinal root:** runs downward and laterally and enters the deep surface of sternocleidomastoid, and crosses the posterior triangle of the neck to supply trapezius

Supplies both sternocleidomastoid and trapezius



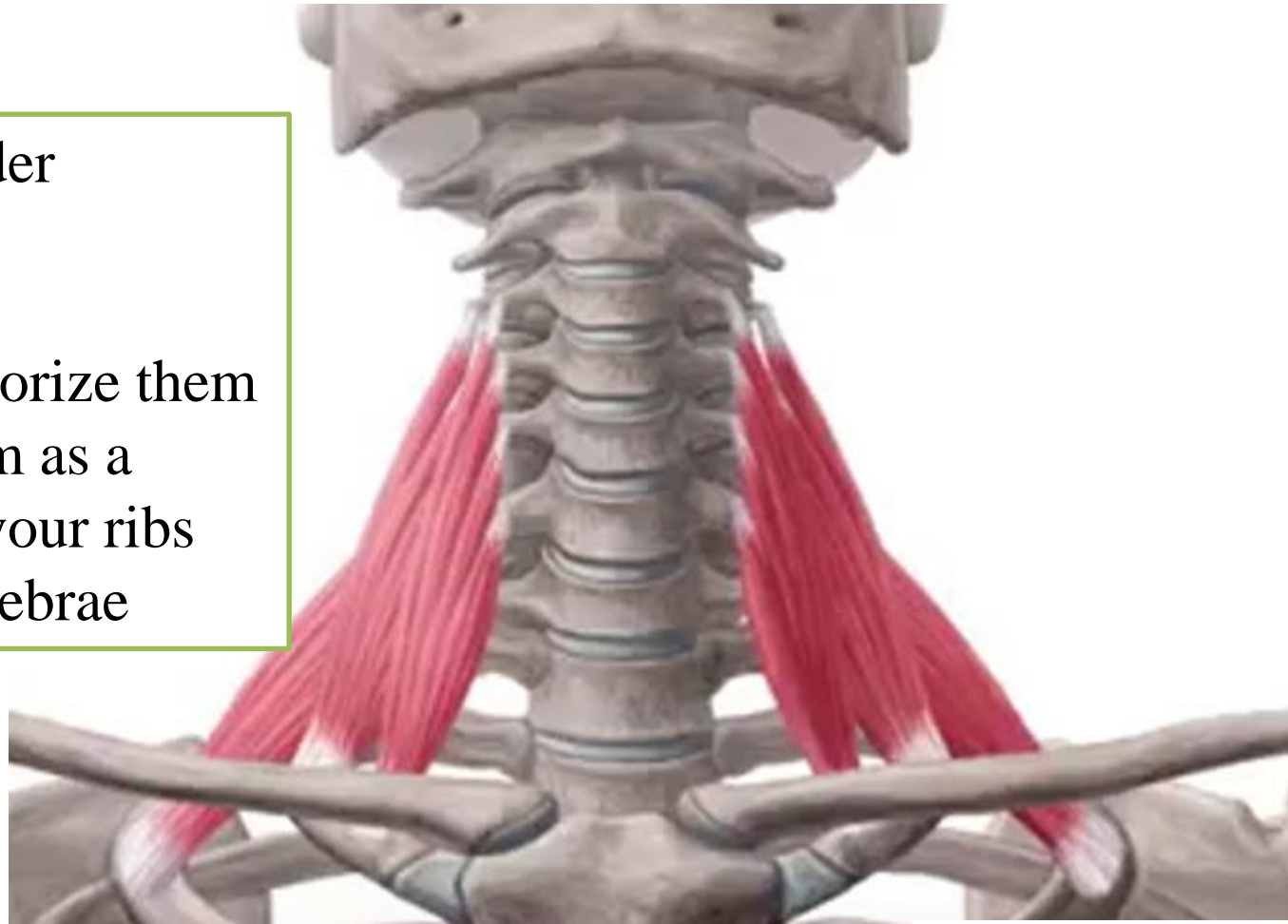
The Accessory Nerves – XI – unique origin from spinal cord



Scalene muscles

In latin : the ladder

So you can memorize them
by picturing them as a
ladder between your ribs
and cervical vertebrae



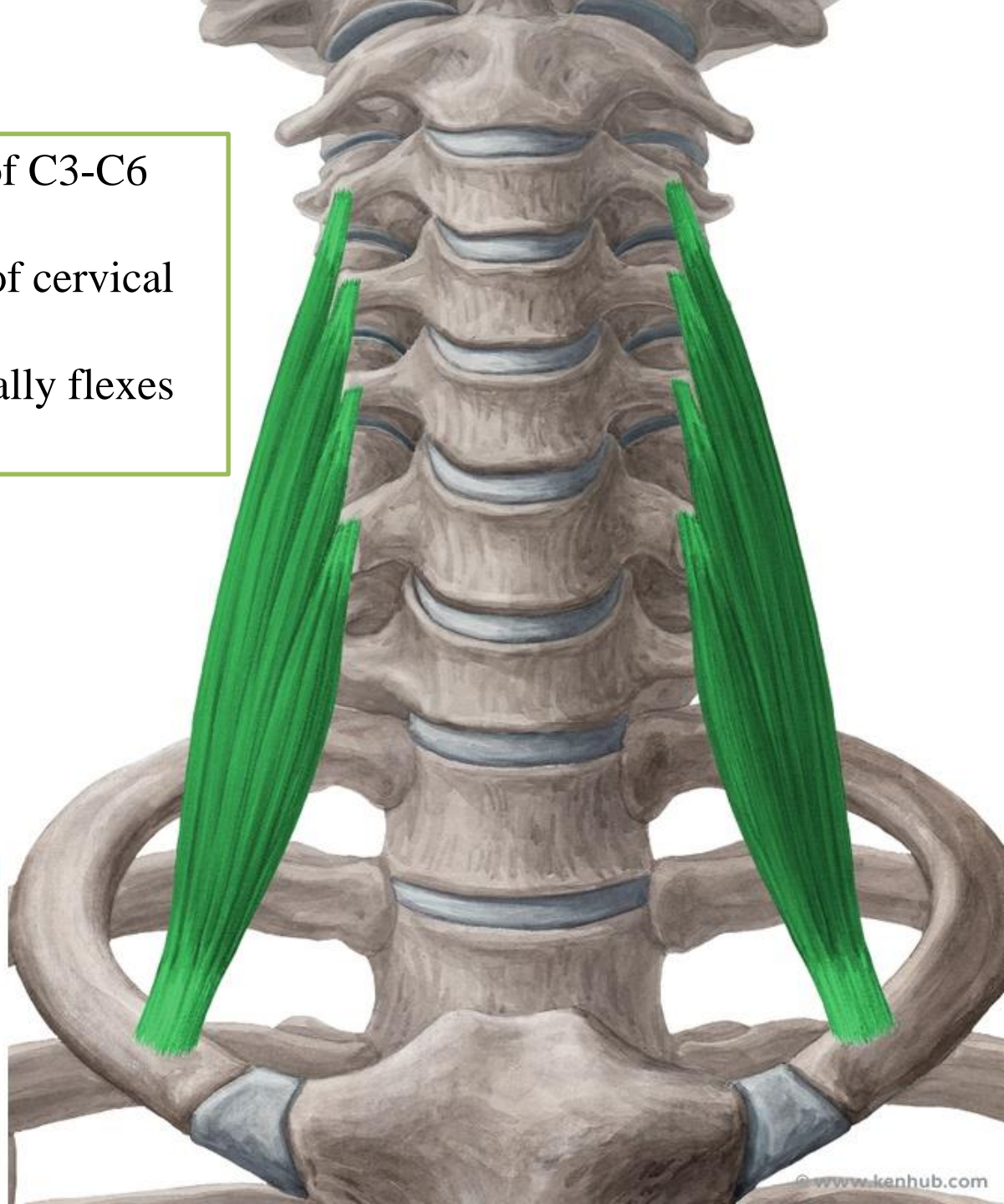
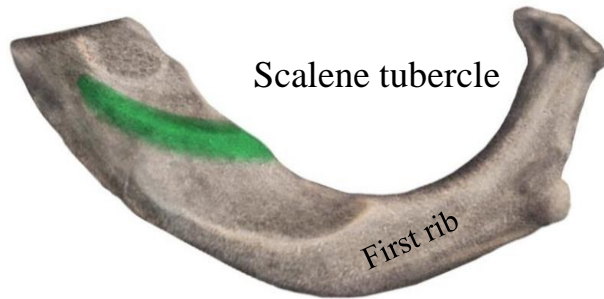
Scalenus anterior

Origin: Transverse processes of C3-C6

Insertion: First rib

Nerve supply: Anterior rami of cervical nerves

Action: Elevates first rib; laterally flexes the cervical spine



© www.kenhub.com

KEN
HUB

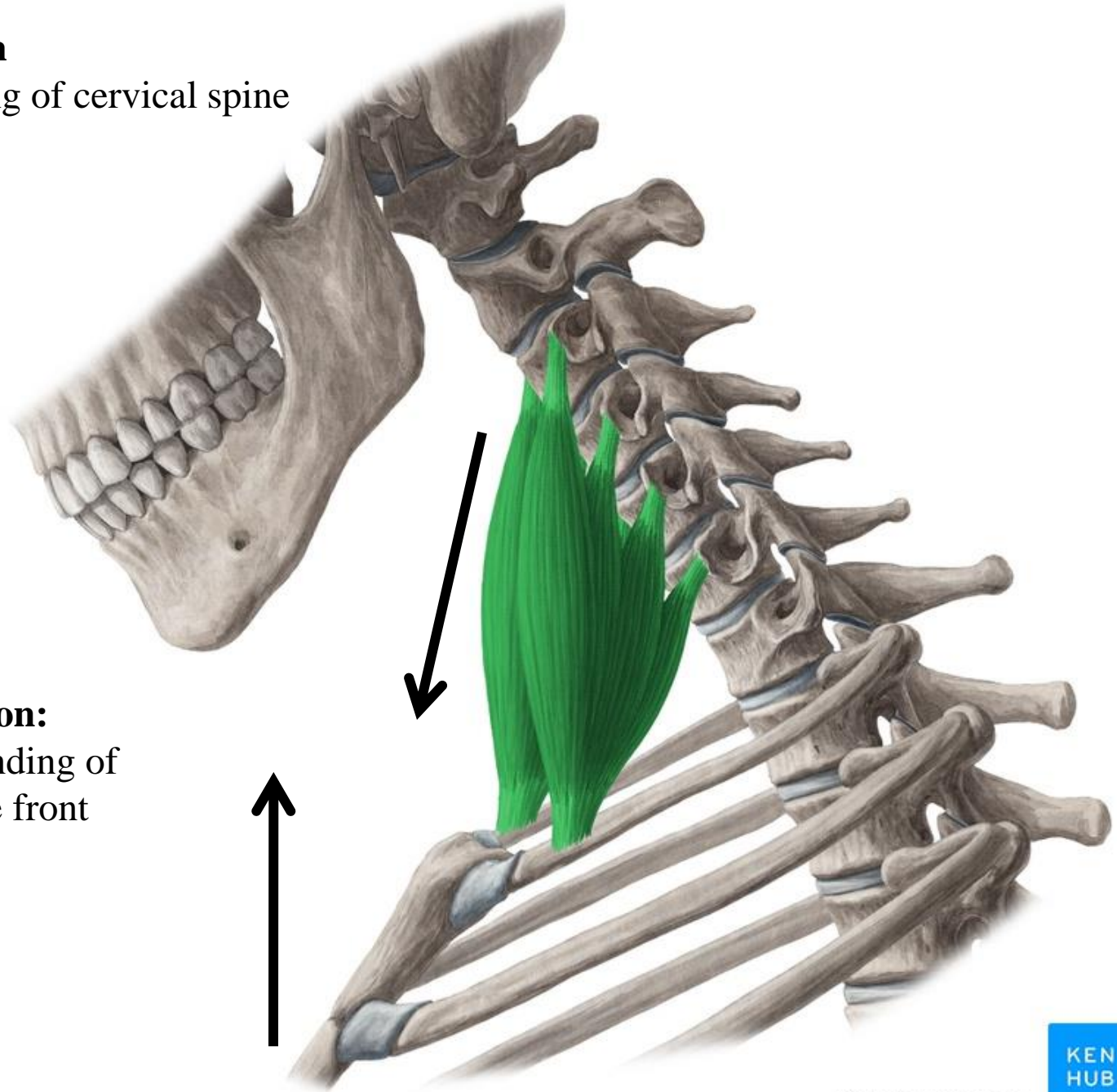
KEN
HUB

© www.kenhub.com

© www.kenhub.com

Unilateral contraction

Lateral flexion: Bending of cervical spine to the side



Bilateral contraction:

Ventral flexion: Bending of cervical spine to the front



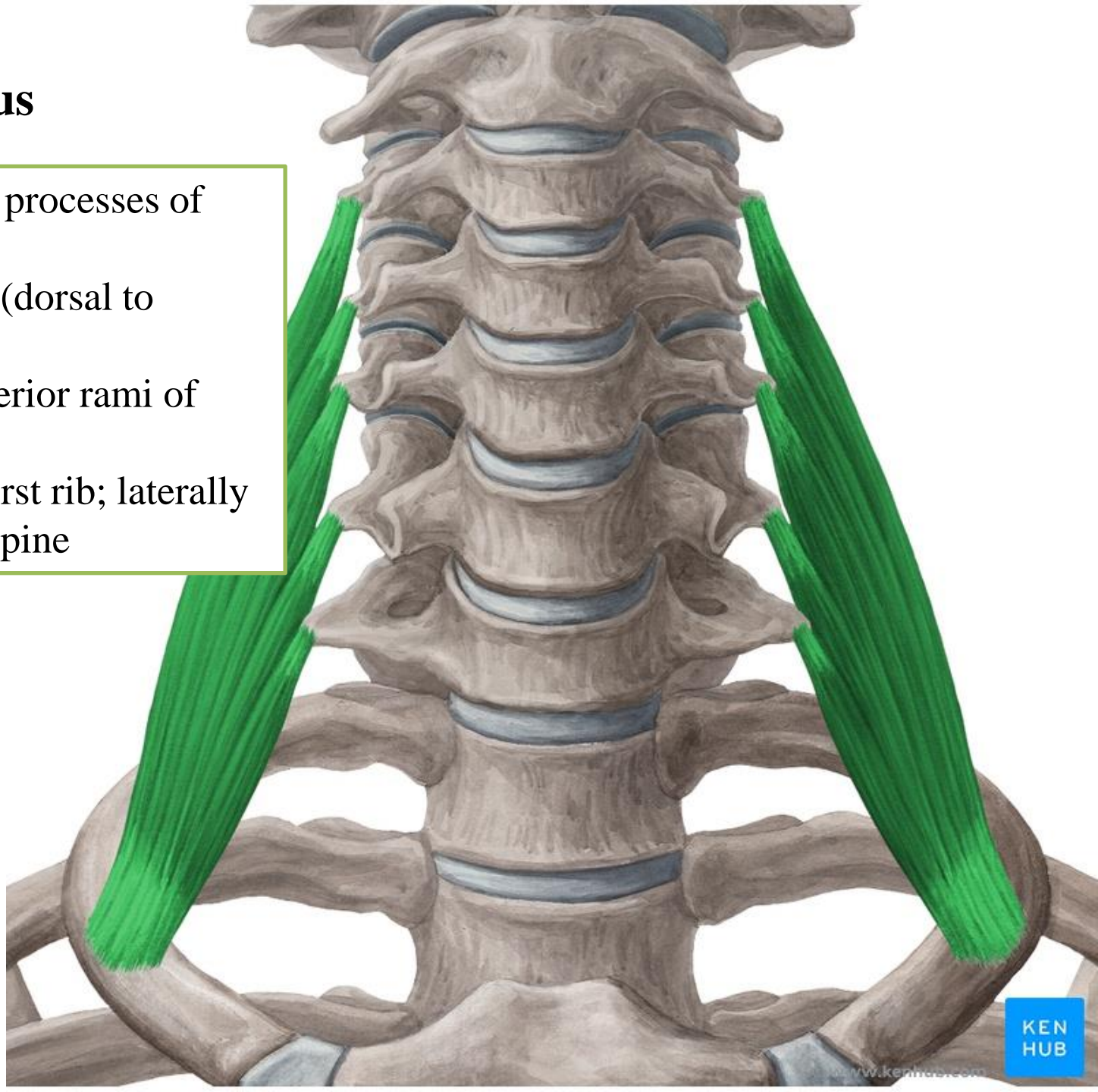
Scalenus medius

Origin: Transverse processes of C2-C7

Insertion: First rib (dorsal to scalene anterior)

Nerve supply: Anterior rami of cervical nerves

Action: Elevates first rib; laterally flexes the cervical spine



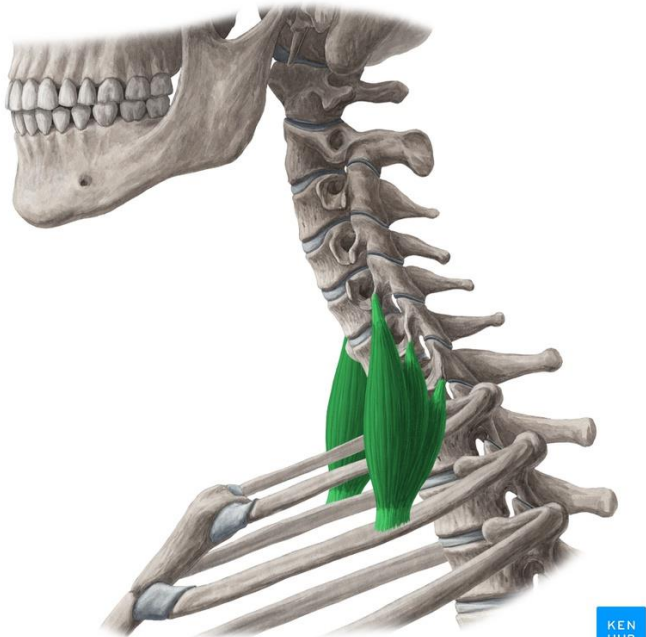
Scalenus posterior

Origin: Transverse processes of C4-C6

Insertion: Second rib

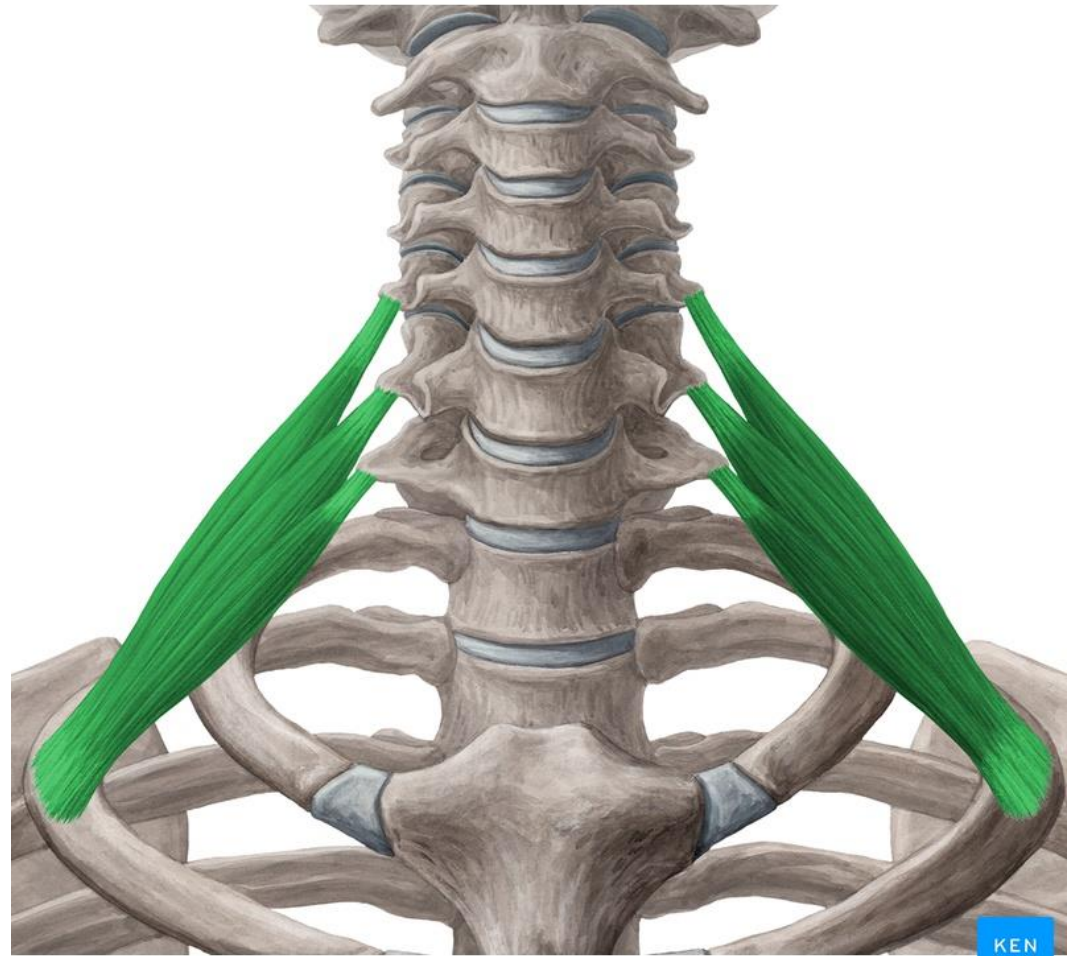
Nerve supply: Anterior rami of cervical nerves

Action: Elevates second rib; laterally flexes the cervical spine



© www.kenhub.com

KEN
HUB

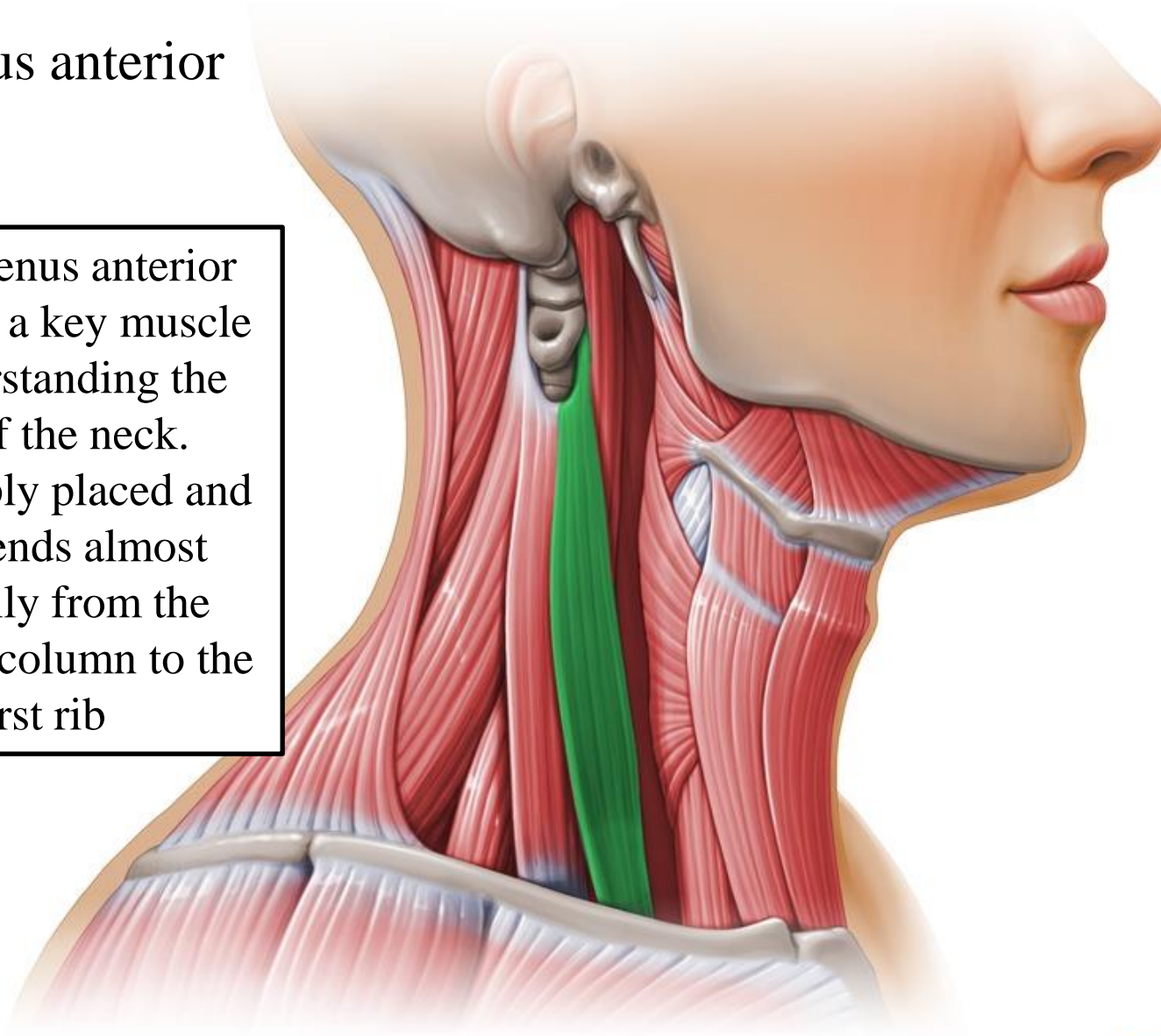


© www.kenhub.com

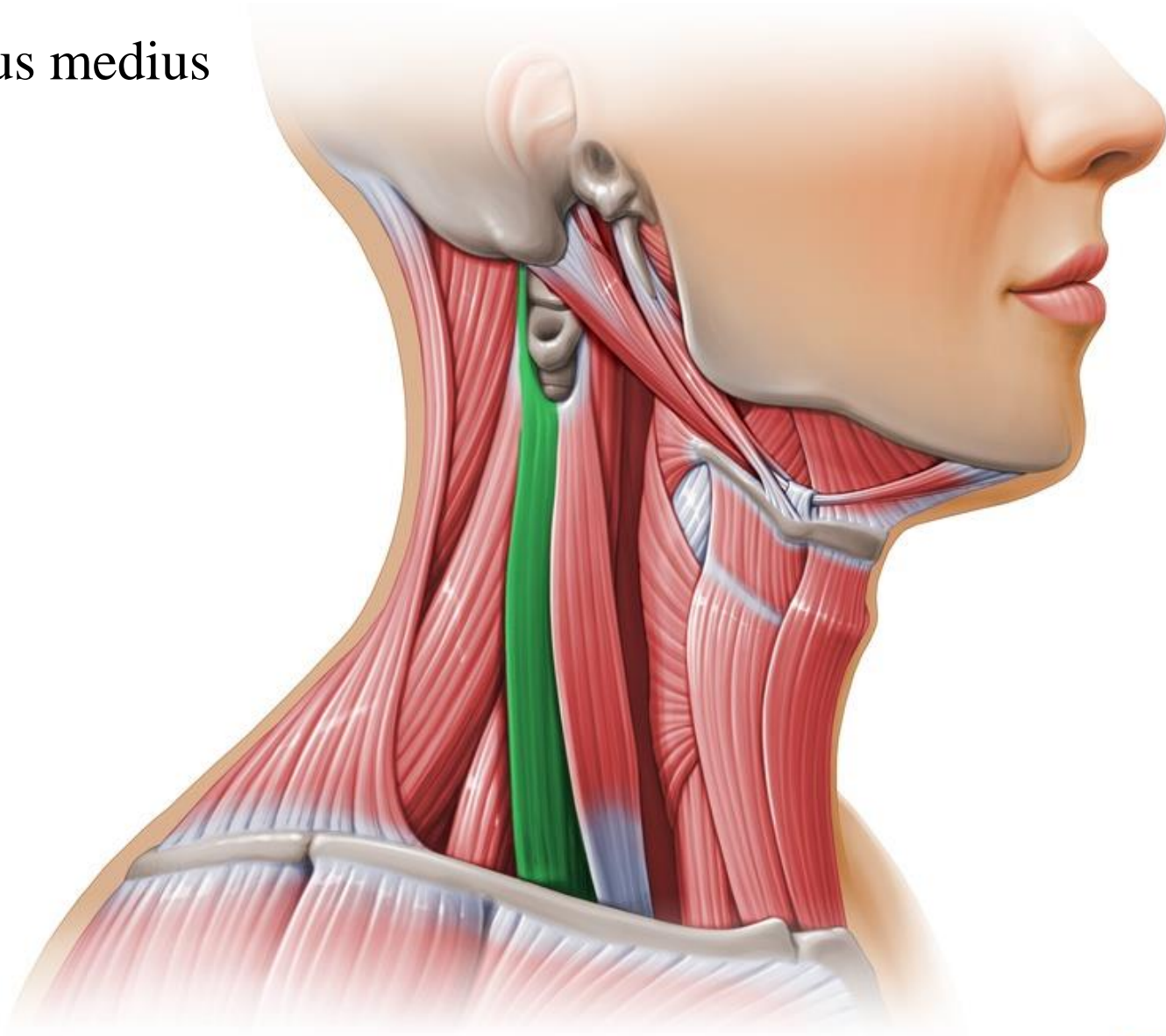
KEN
HUB

Scalenus anterior

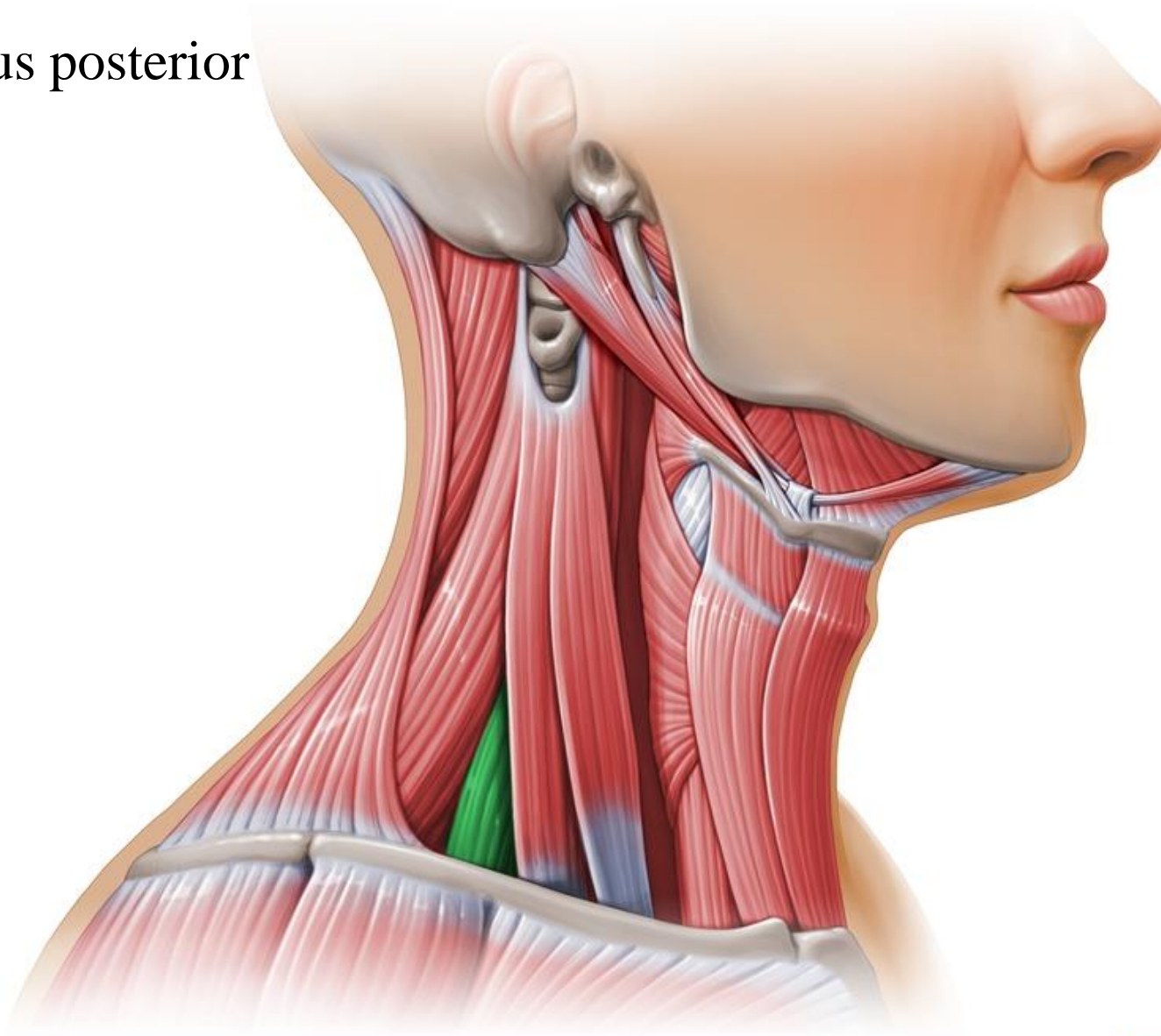
The scalenus anterior muscle is a key muscle in understanding the root of the neck. It is deeply placed and it descends almost vertically from the vertebral column to the first rib



Scalenus medius

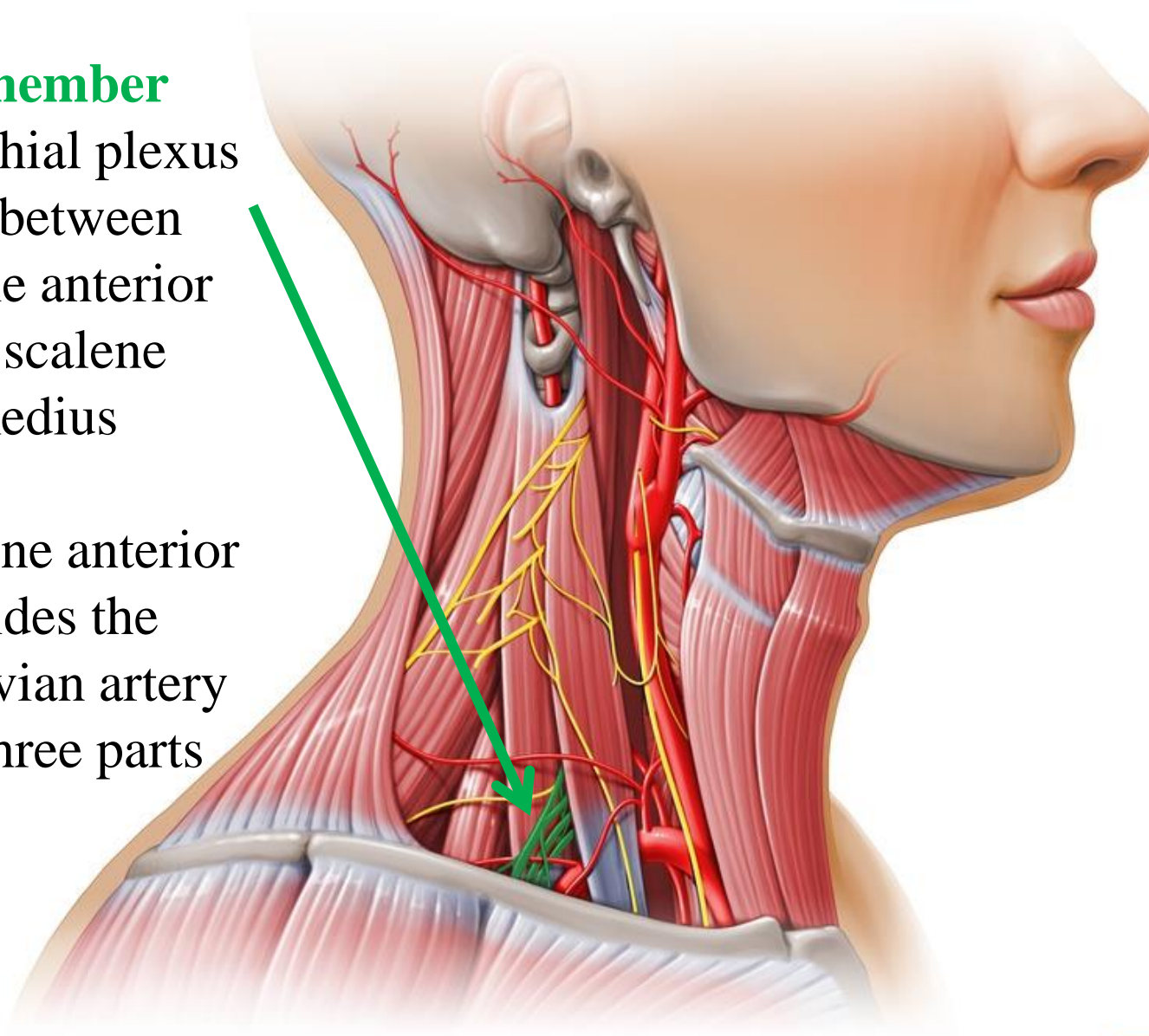


Scalenus posterior



Remember

- Brachial plexus lies between scalene anterior and scalene medius
- Scalene anterior divides the subclavian artery into three parts



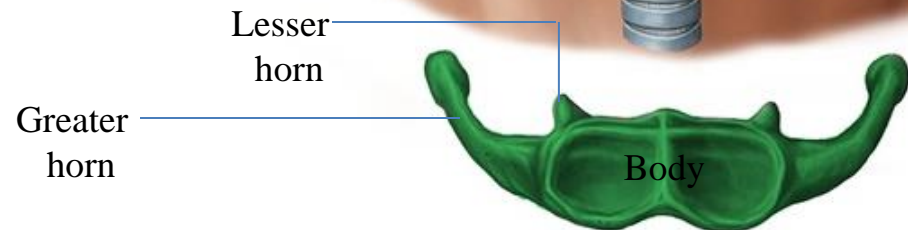
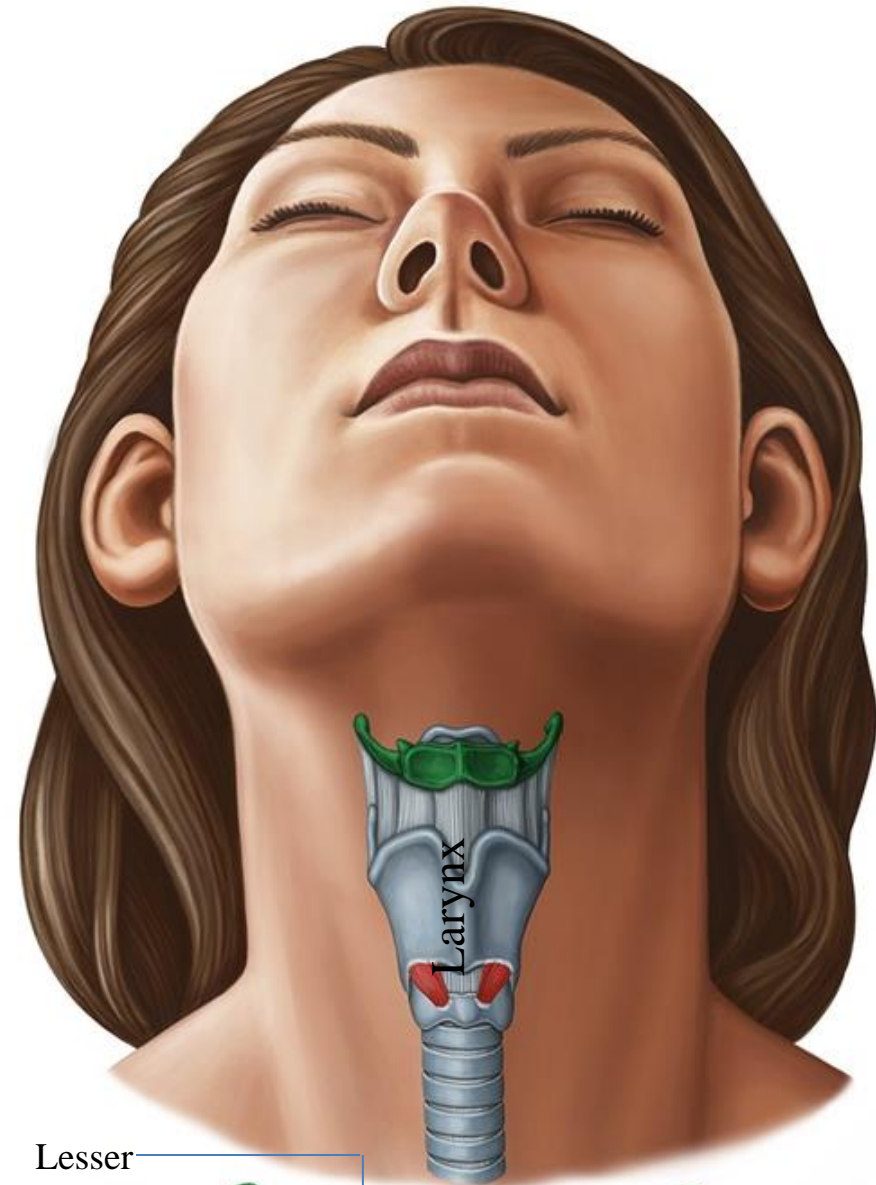
Bones of the Neck

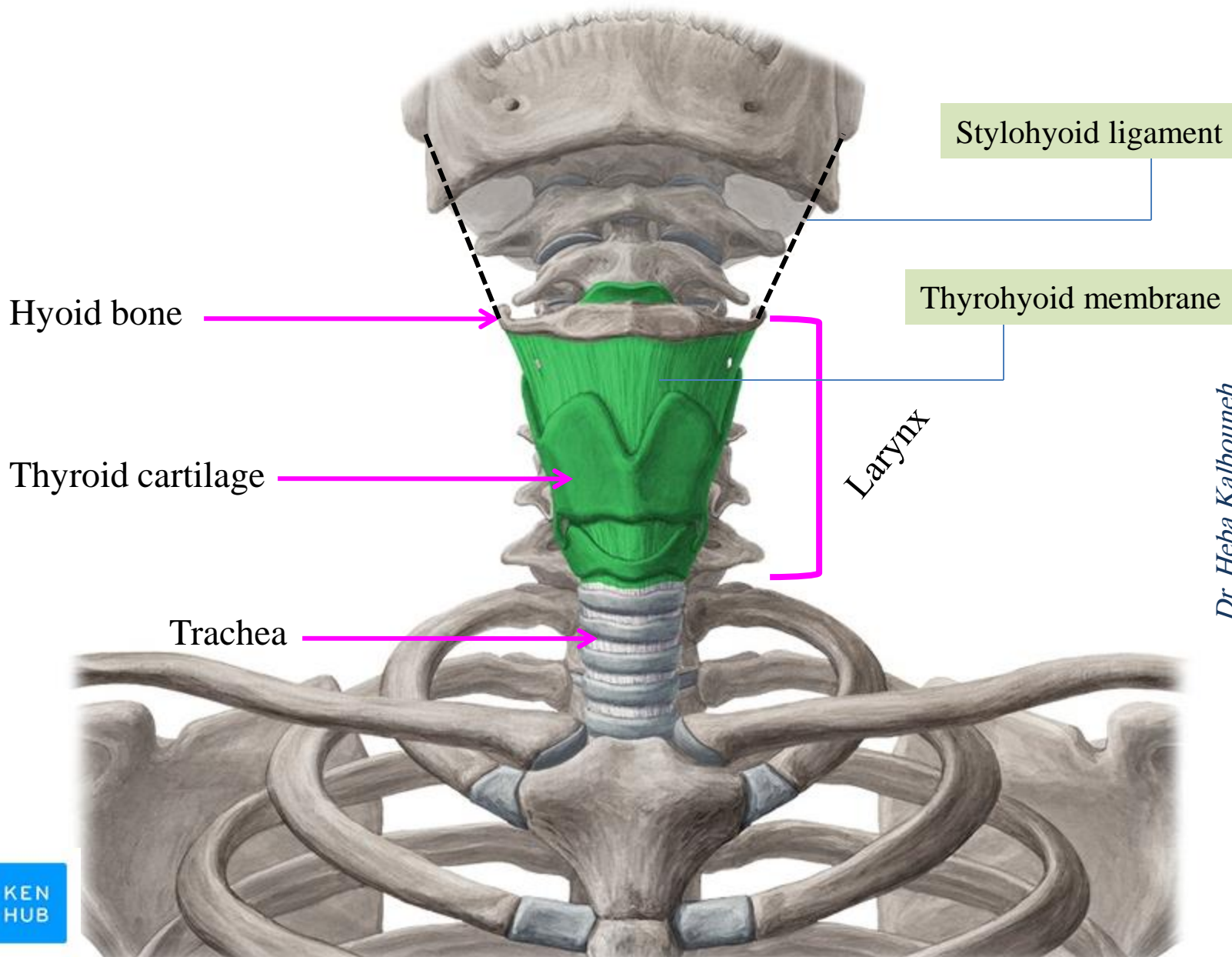
Cervical Vertebrae

Hyoid Bone

At **C3** level

- ✓ The hyoid bone is a mobile single bone found in the midline of the neck below the mandible and abides the larynx
- ✓ It does not articulate with any other bones
- ✓ The hyoid bone is U shaped and consists of:
 - 1- **Body**
 - 2- **Two greater horns**
 - 3- **Two lesser horns**
- ✓ It is attached to the skull by the stylohyoid ligament
- ✓ It is attached to the thyroid cartilage by the thyrohyoid membrane
- ✓ The hyoid bone forms a base for the tongue






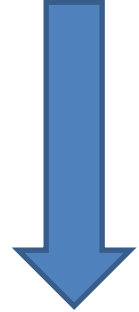
Muscles superior to hyoid are classified as **suprahyoid muscles**



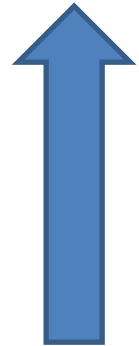
1. **Stylohyoid**
2. **Digastric**
3. **Mylohyoid**
4. **Geniohyoid**



Raise the hyoid
(during swallowing)



**Positioning
of
hyoid bone**

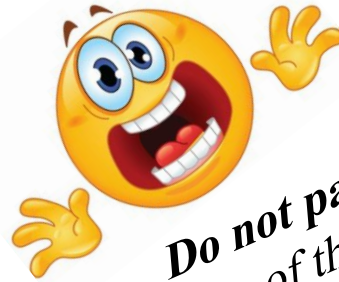


Depress the hyoid
Except sternothyroid

Muscles inferior to hyoid are classified as **infrahyoid muscles**
(strap muscles)



1. **Omohyoid**
2. **Sternohyoid**
3. **Thyrohyoid**
4. **Sternothyroid**

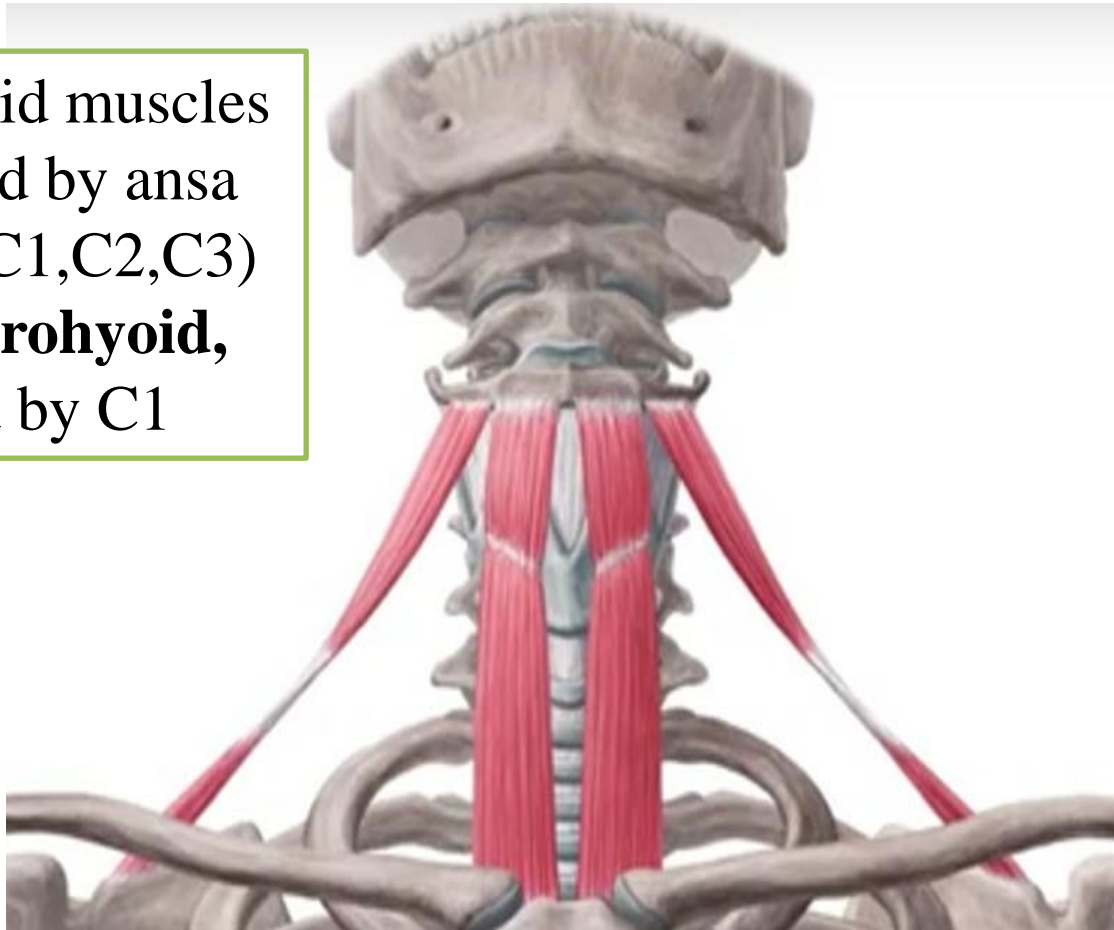


Do not panic
The names of these muscles offer u clues from where these muscles are going to be attached



Infrahyoid muscles

All infrahyoid muscles are supplied by ansa cervicalis (C1,C2,C3) except **thyrohyoid**, supplied by C1



Sternohyoid

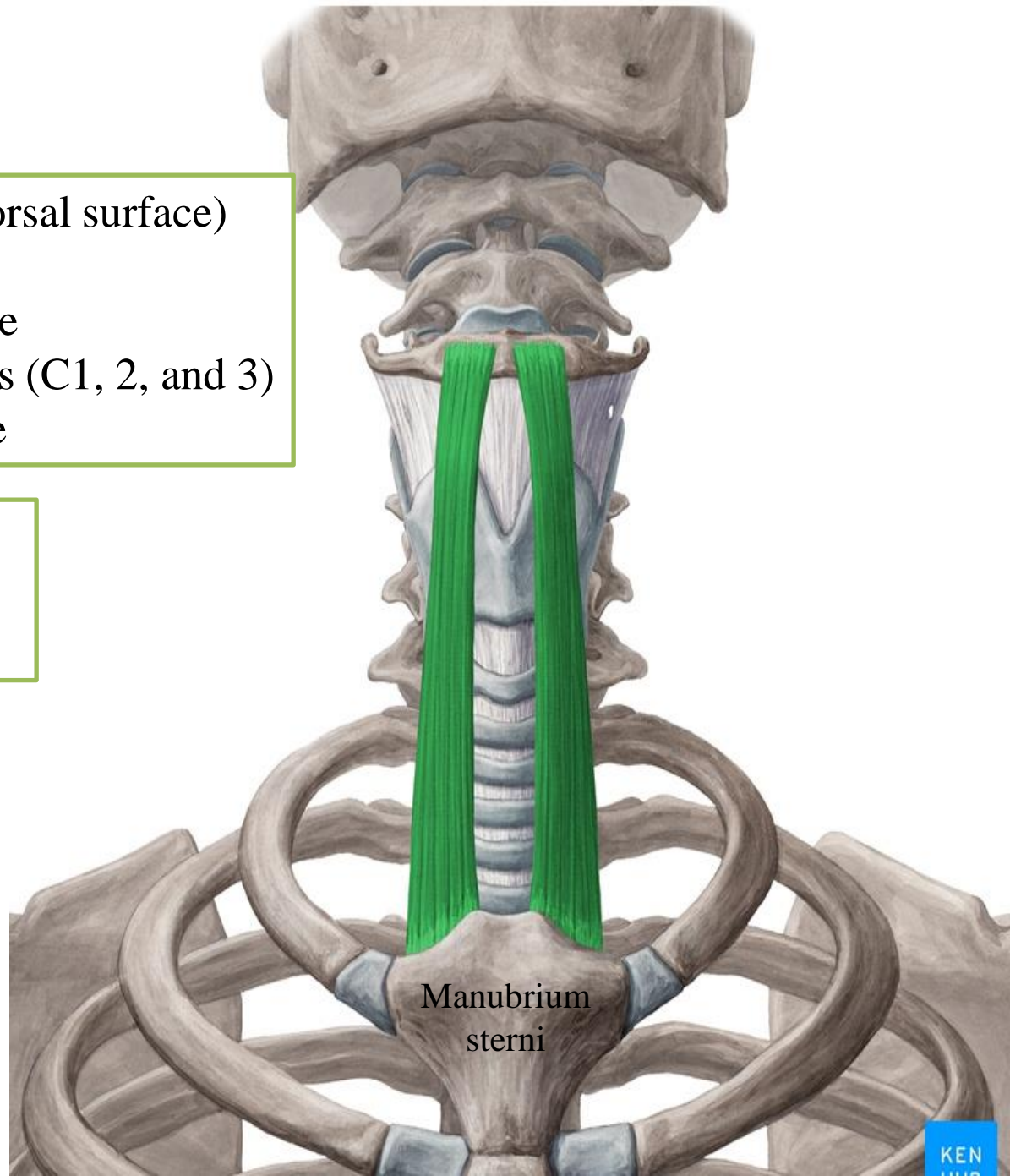
Origin: Manubrium sterni (dorsal surface) and sternoclavicular joint

Insertion: Body of hyoid bone

Nerve supply: Ansa cervicalis (C1, 2, and 3)

Action: Depresses hyoid bone

Sternohyoid is the most **superficial** of infrahyoid muscles



Manubrium
sterni

Superior belly Omohyoid

Origin: Body of hyoid bone

Insertion: Intermediate tendon is held to clavicle and first rib by fascial sling

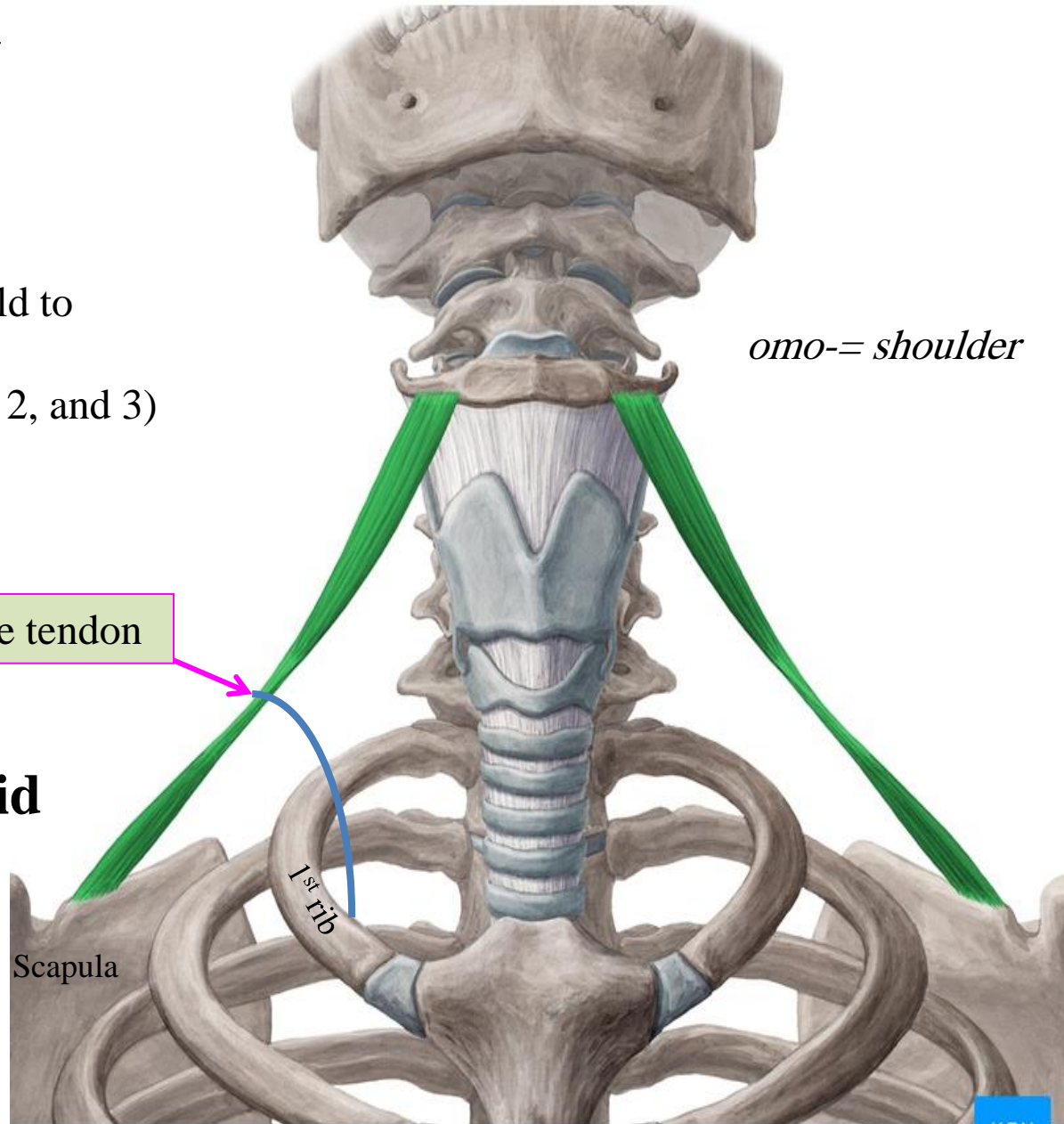
Nerve supply: Ansa cervicalis (C1, 2, and 3)

Action: Depresses hyoid bone

Intermediate tendon

Inferior belly of Omohyoid

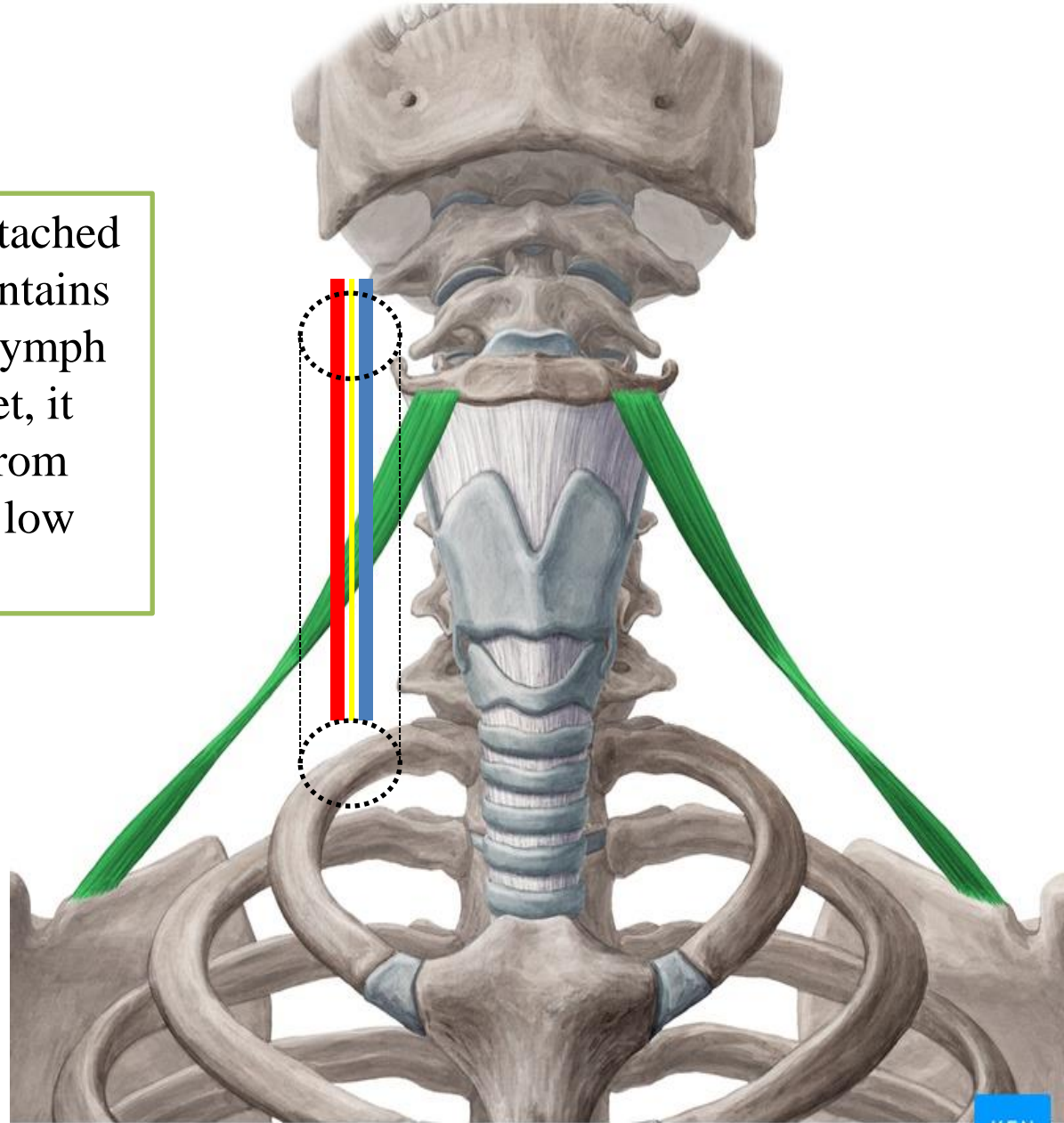
Origin: Upper margin of scapula



The intermediate tendon is attached to the carotid sheath (which contains IJV, CCA, vagus nerve and lymph nodes), by pulling this sheet, it prevents the big thin IJV from collapsing and maintains a low pressure in the IJV



This increases the blood return from the head to Superior vena cava



Sternothyroid

Origin: Manubrium sterni (dorsal surface)

Insertion: Thyroid cartilage

Nerve supply: Ansa cervicalis (C1, 2, and 3)

Action: Depresses larynx

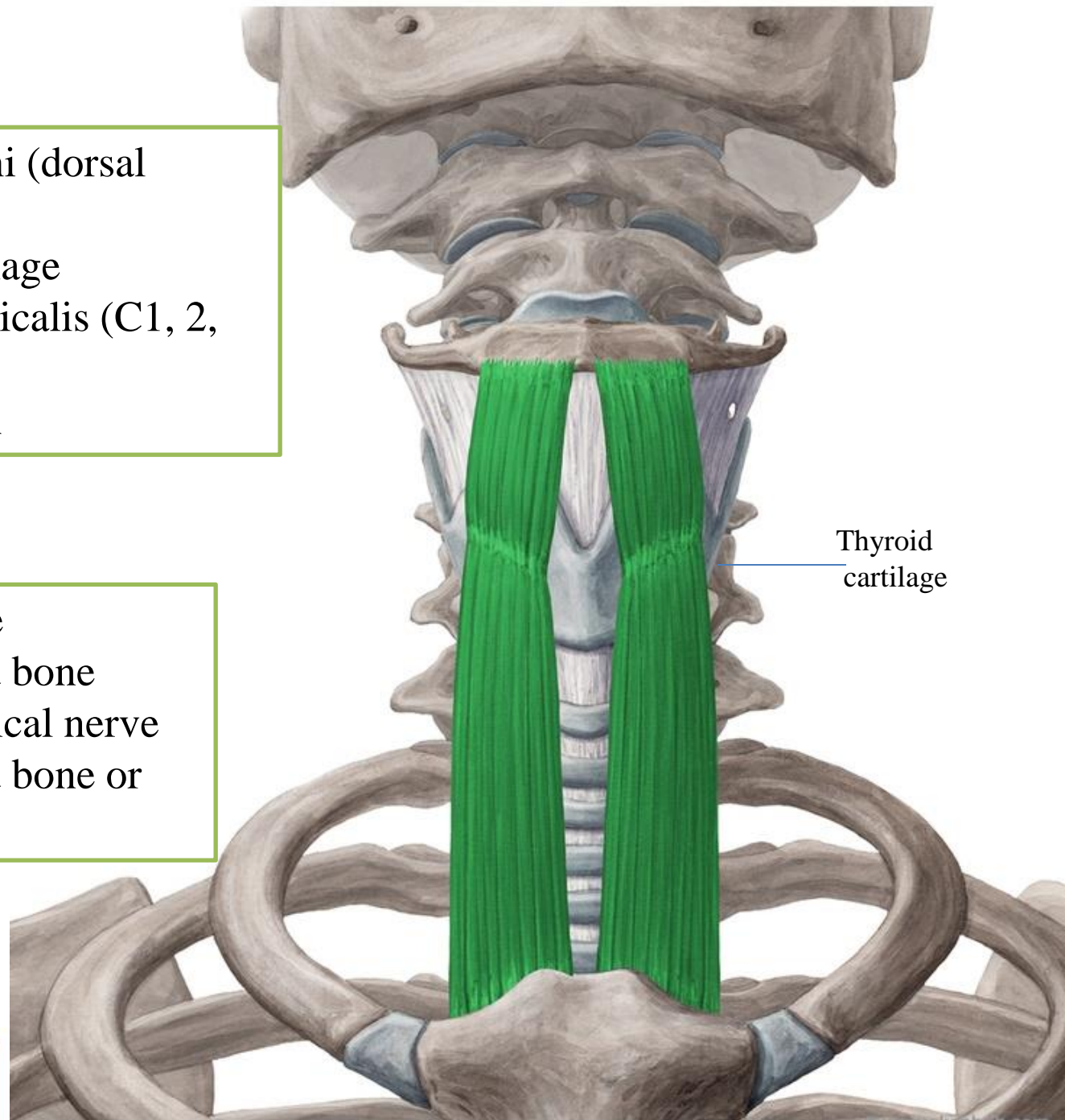
Thyrohyoid

Origin: Thyroid cartilage

Insertion: Body of hyoid bone

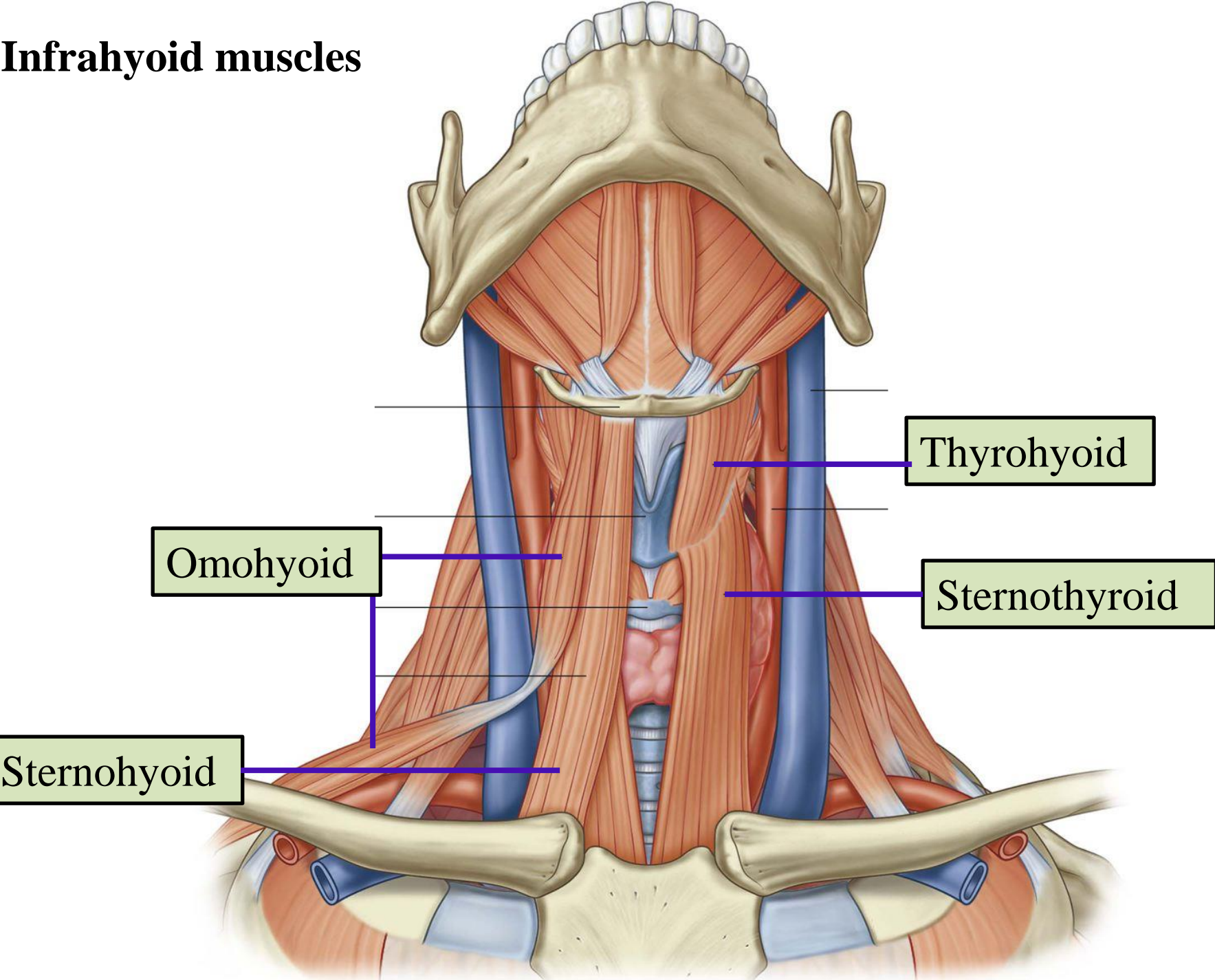
Nerve supply: First cervical nerve

Action: Depresses hyoid bone or elevates larynx



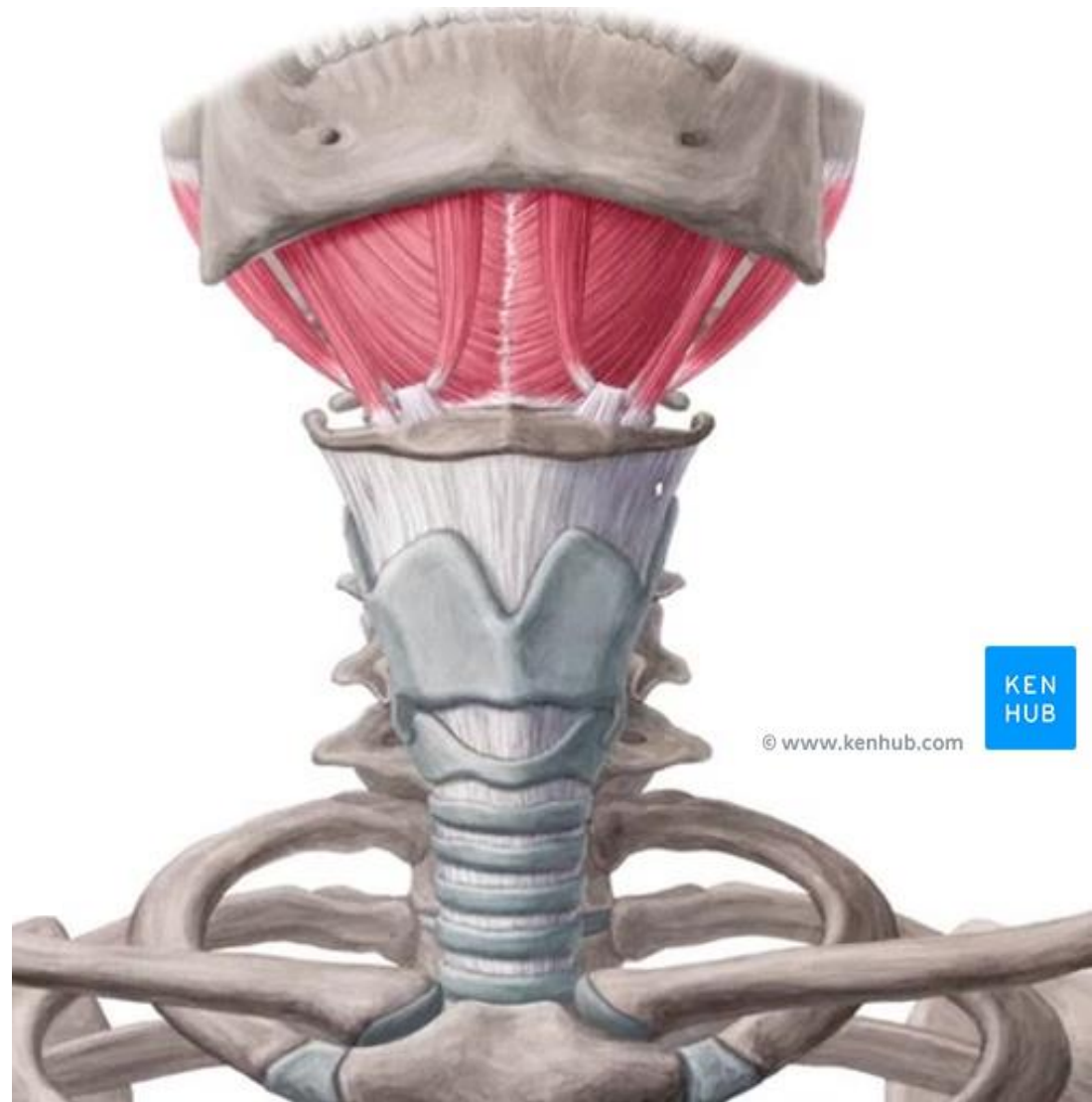
Thyroid
cartilage

Infrahyoid muscles



Suprahyoid muscles

Involved in swallowing and movement of the larynx



© www.kenhub.com

KEN
HUB

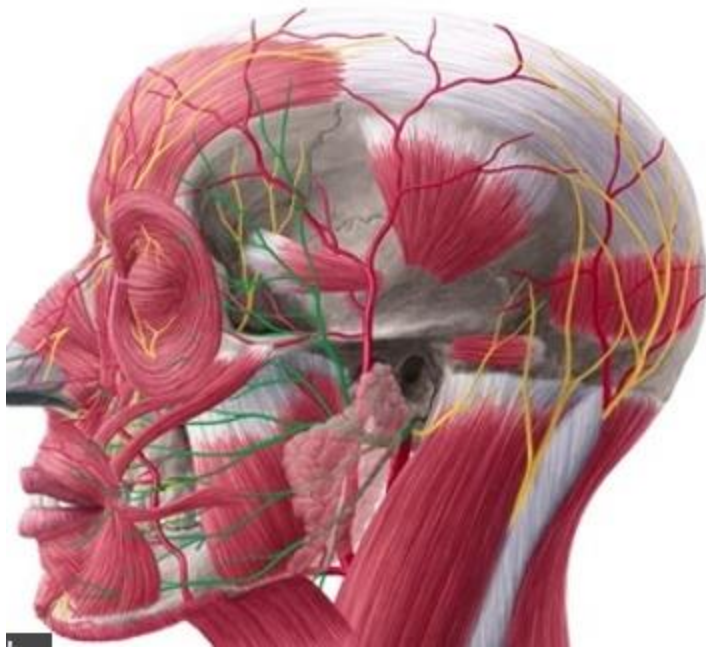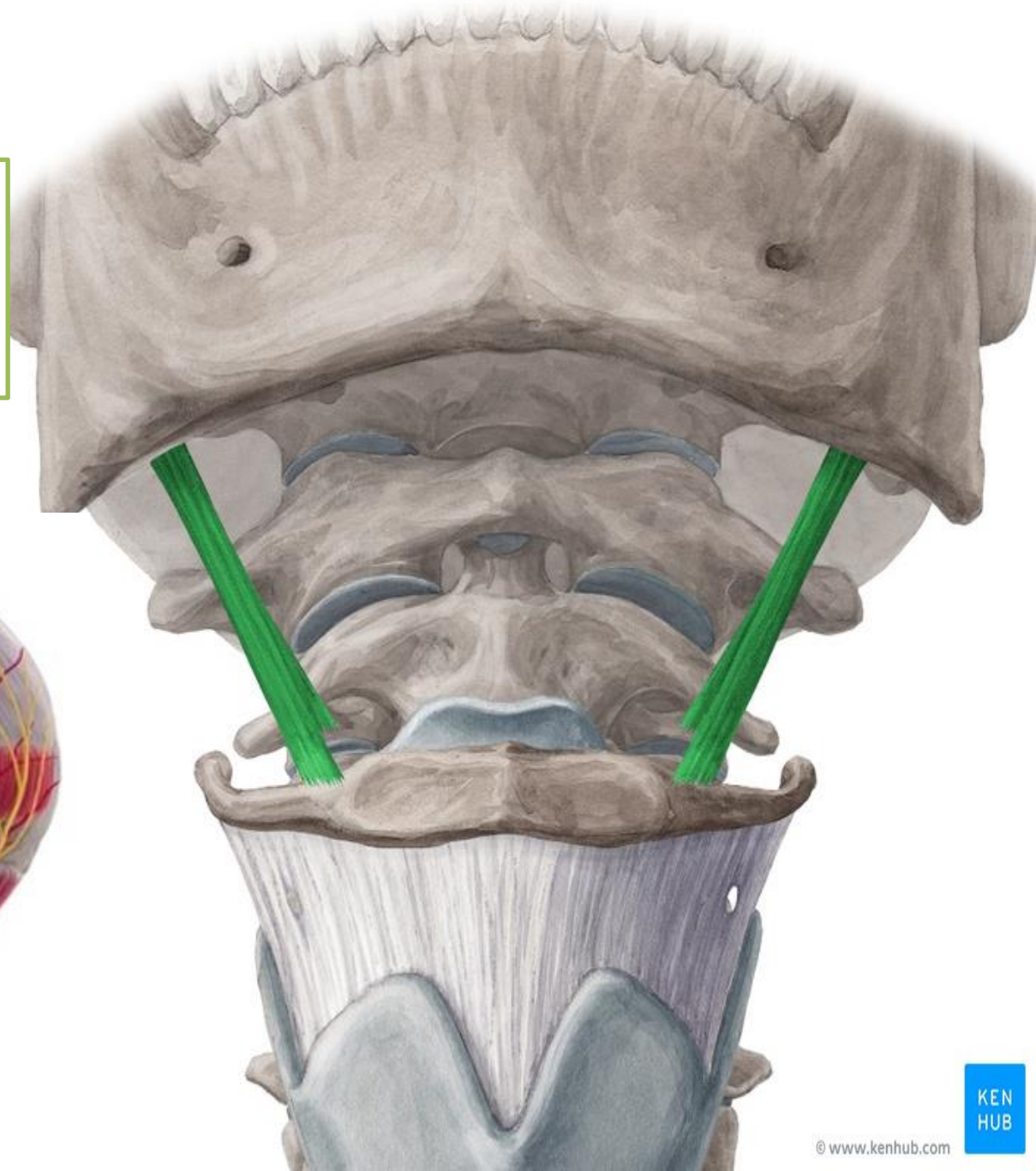
Stylohyoid

Origin: Styloid process

Insertion: Body of hyoid bone

Nerve supply: Facial nerve

Action: Elevates hyoid bone



Anterior belly of digastric

Origin: Digastric fossa of the mandible

Nerve supply: Nerve to mylohyoid
(mandibular nerve)

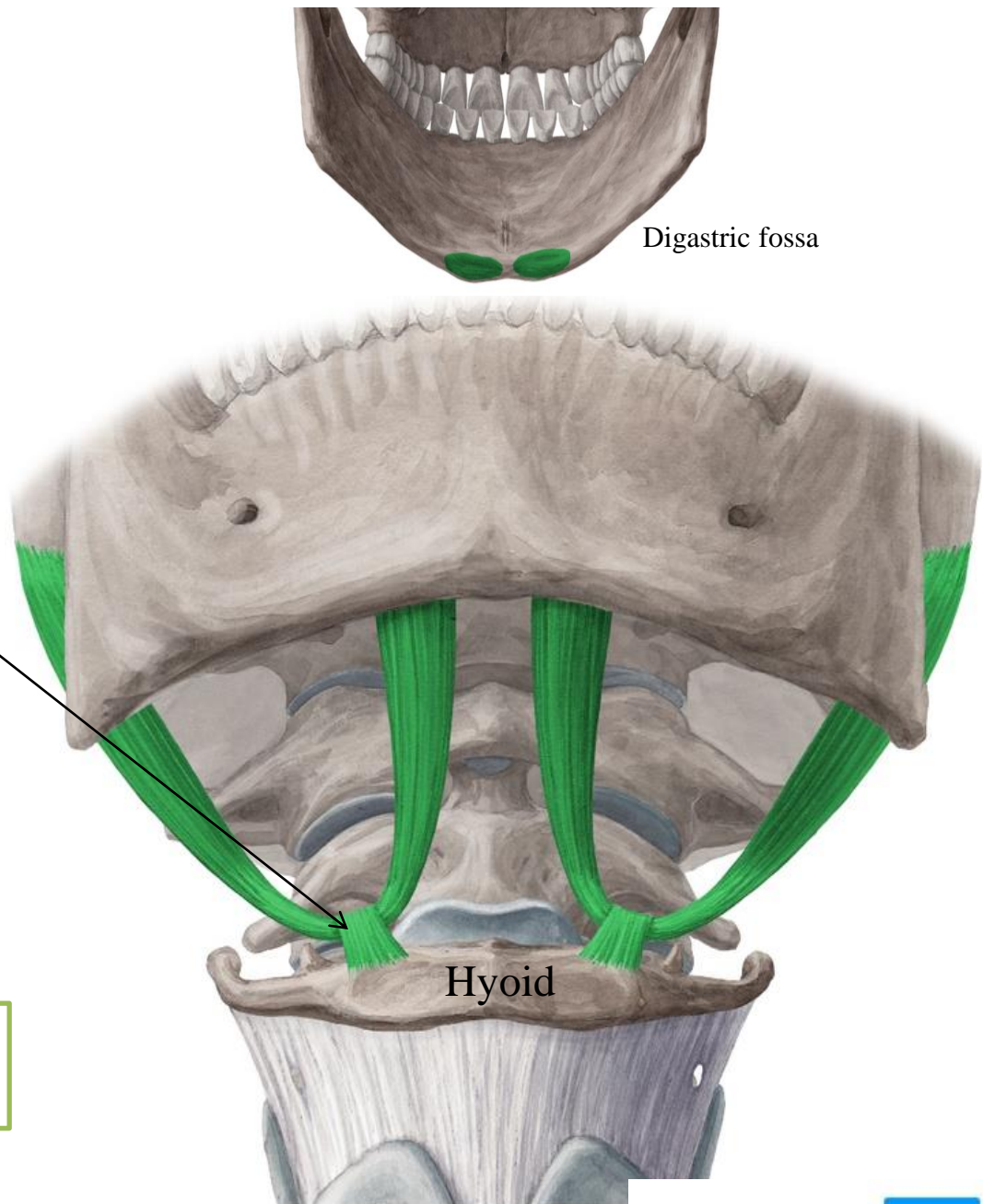
Insertion: Intermediate tendon is held
to hyoid by fascial sling

Action: Depresses mandible or elevates
hyoid bone

Posterior belly of digastric

Origin: Mastoid notch

Nerve supply: Facial nerve



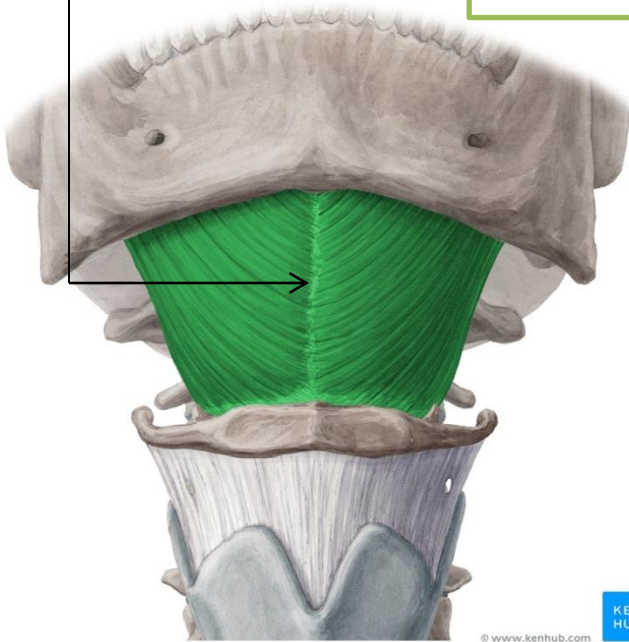
The **mylohyoid raphe** is where both muscles meet. It inserts into body of hyoid

Origin: Mylohyoid line of mandible

Insertion: Body of hyoid bone and fibrous raphe

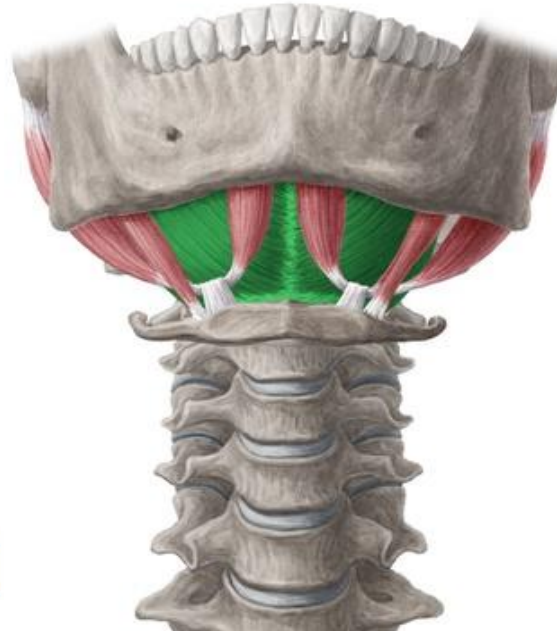
Nerve supply: Nerve to mylohyoid (from inf. alveolar n/ mandibular n)

Action: Elevates floor of mouth and hyoid bone or depresses mandible

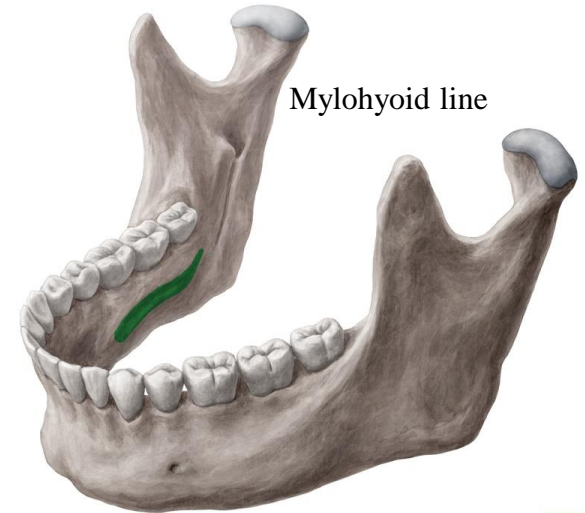


© www.kenhub.com

KEN
HUB

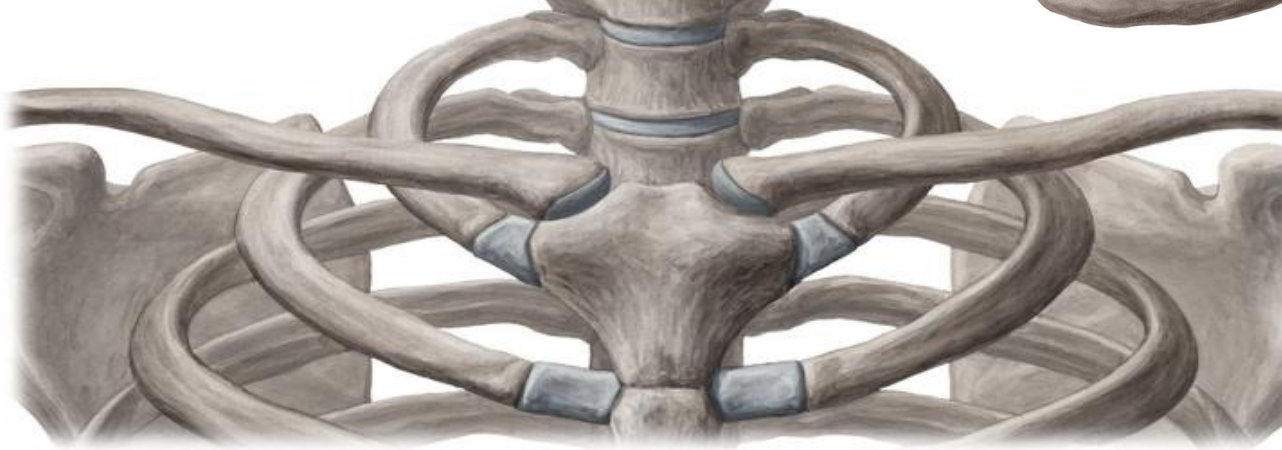

Mylohyoid



© www.kenhub.com

KEN
HUB



KEN
HUB

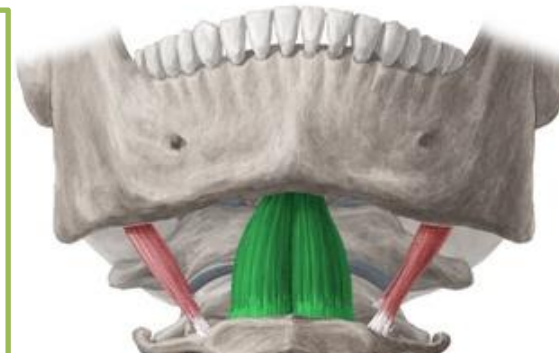Geniohyoid

Origin: Inferior mental spine of mandible

Insertion: Body of hyoid bone

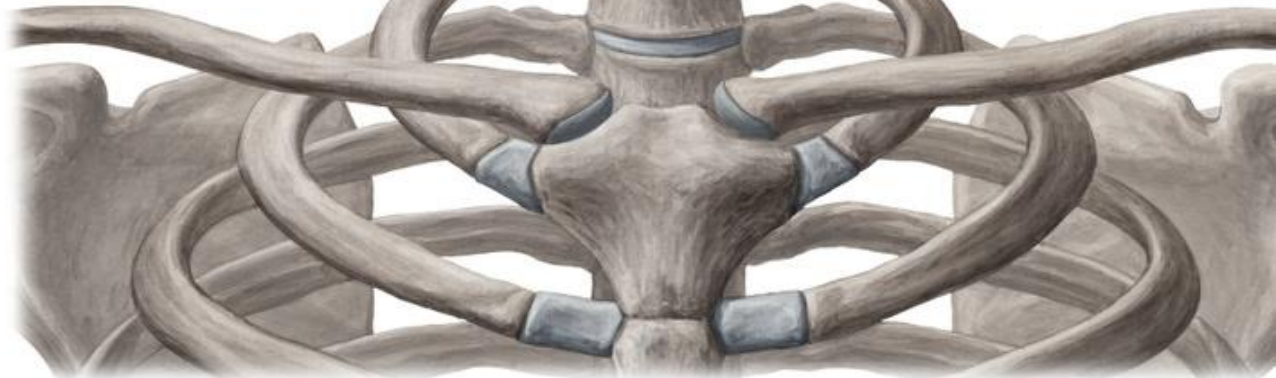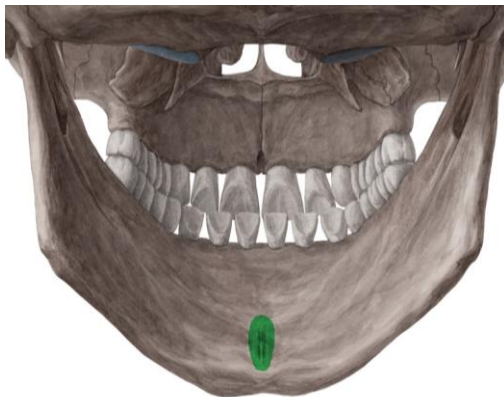
Nerve supply: First cervical nerve
(cervical plexus)

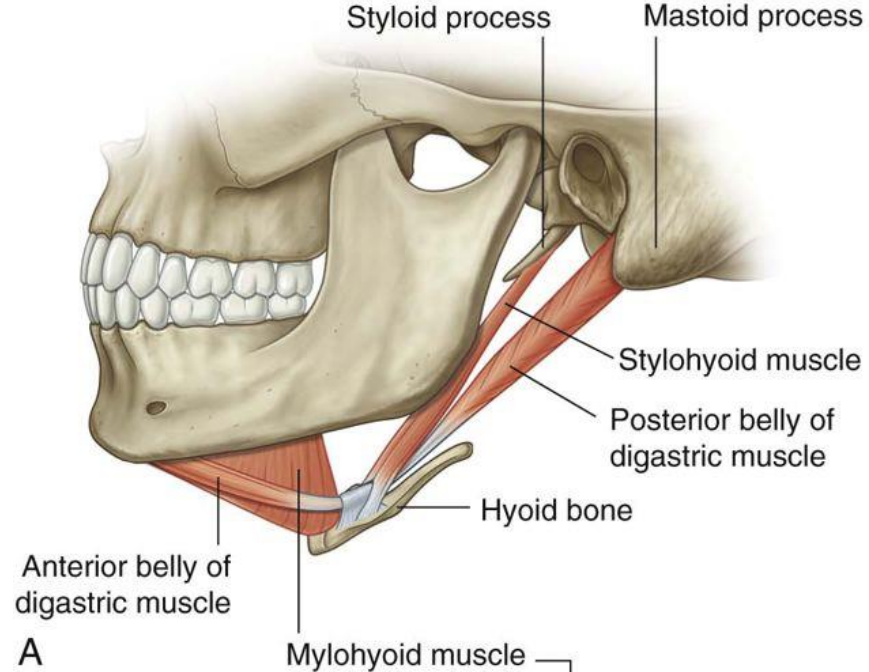
Action: Elevates hyoid bone or depresses
mandible



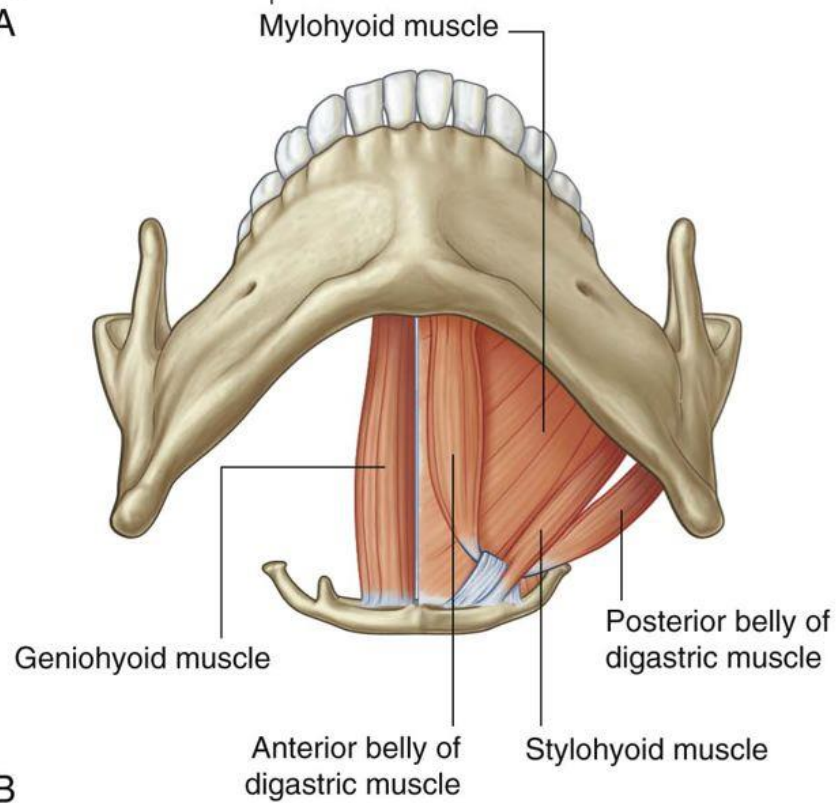
Mentum
Genio
Chin

Mental spines





A

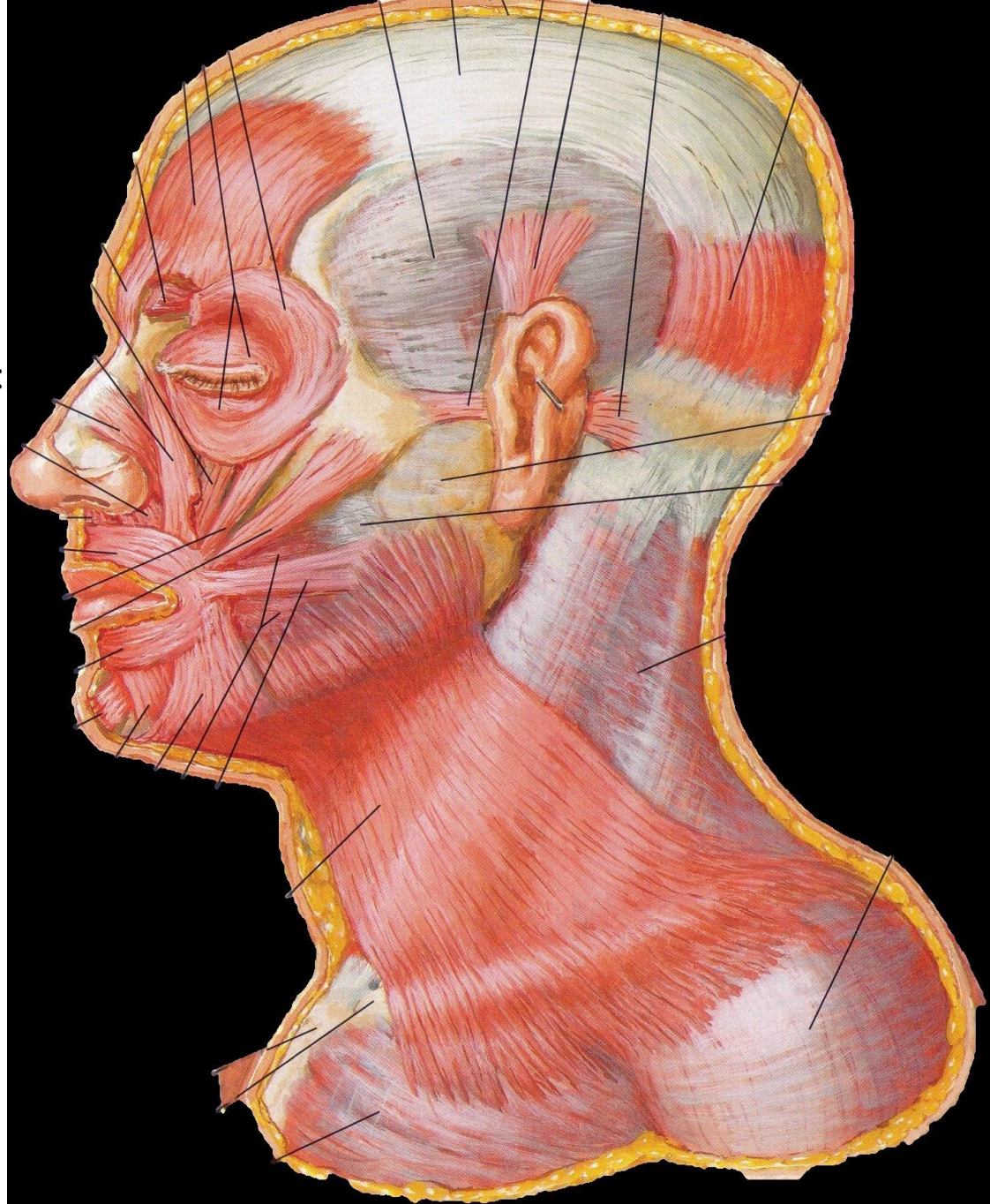


B

Superficial Fascia

It is a thin layer of fascia that contains:

- 1- Platysma muscle
- 2- Superficial veins
- 3- Cutaneous nerves
- 4- Superficial lymph nodes



Superficial Veins

1- External Jugular Vein

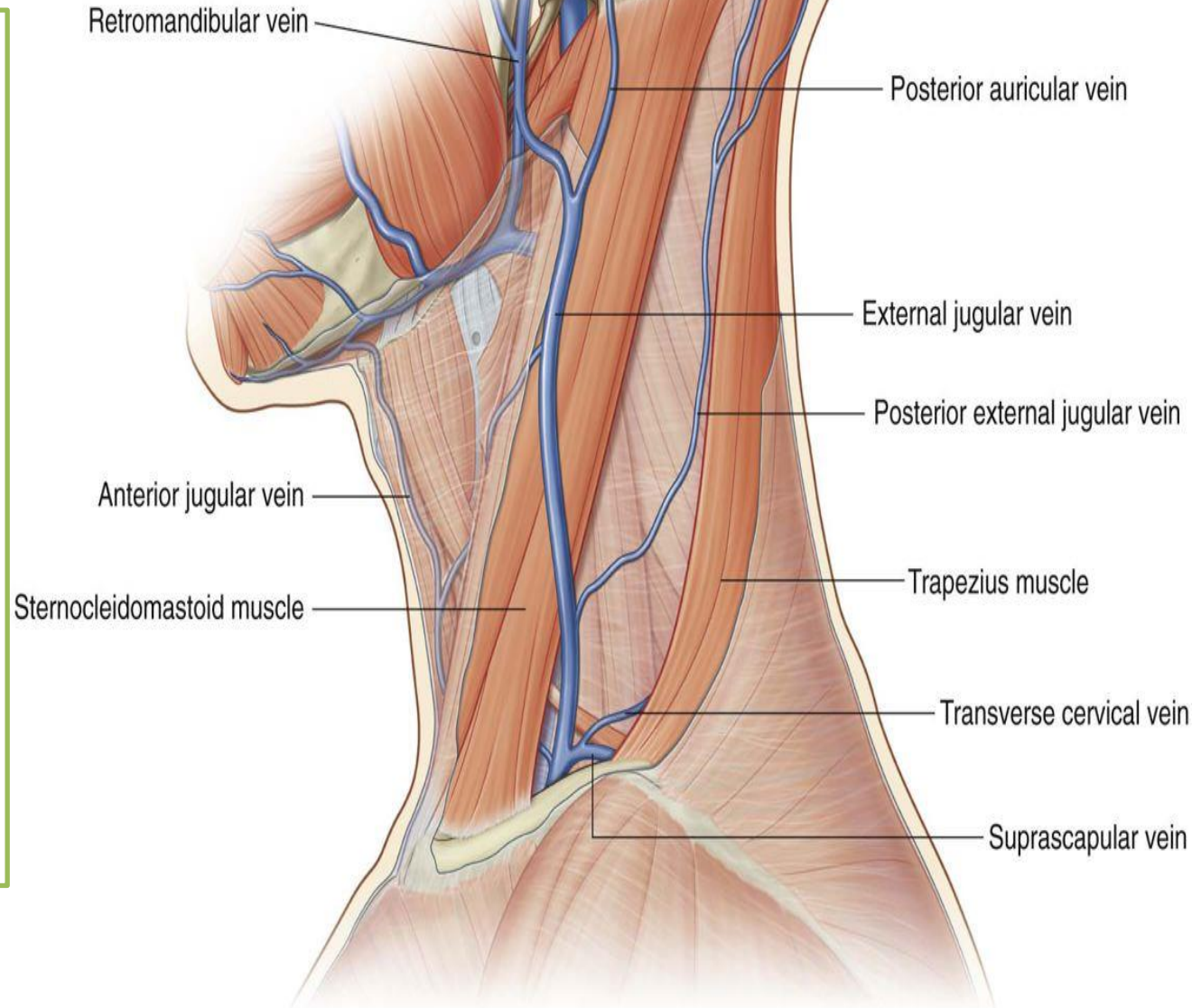
2- Anterior Jugular Vein

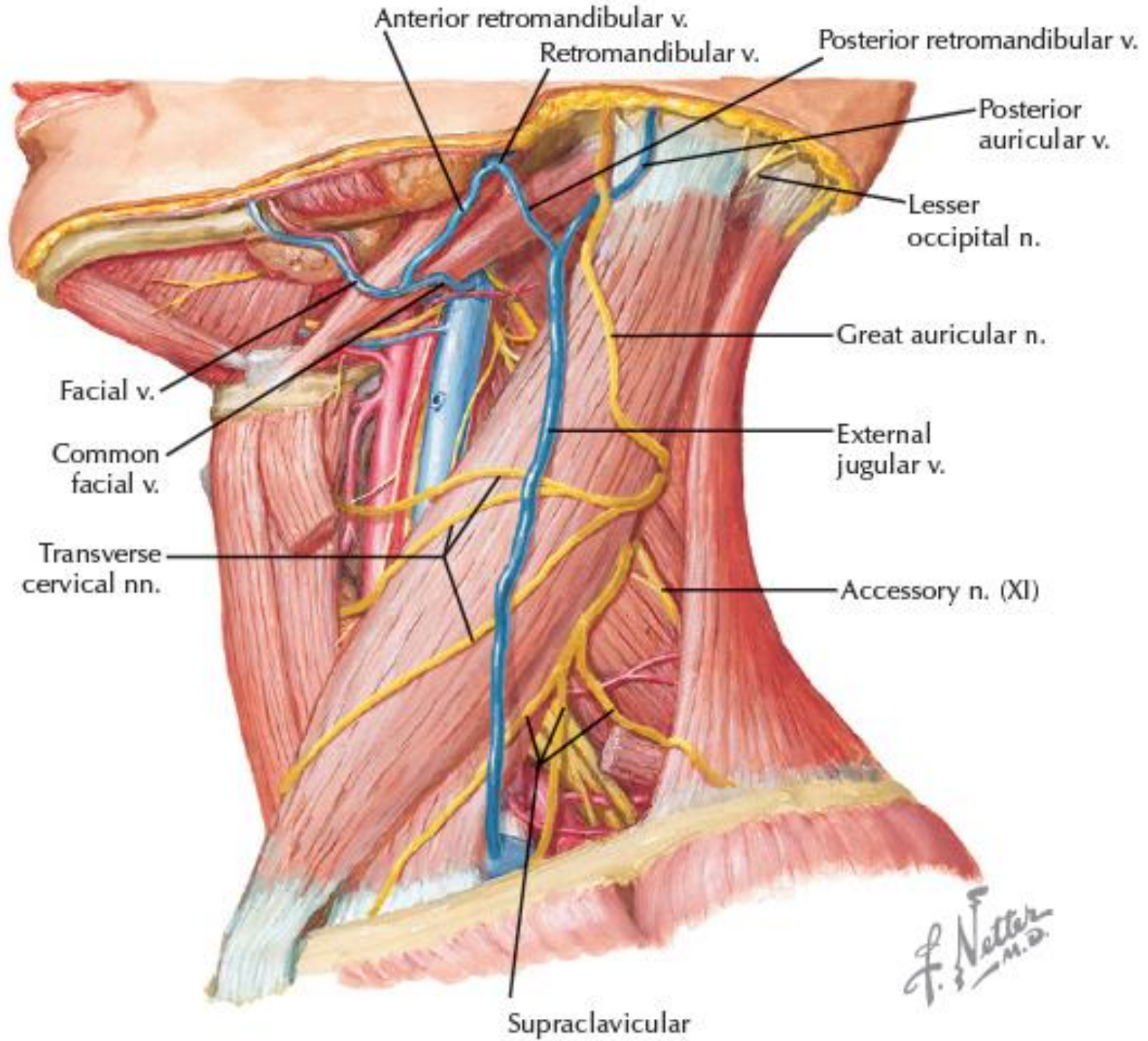
1- External Jugular Vein

✓ Begins just **behind the angle of mandible** by union of posterior auricular vein with posterior division of retromandibular vein

✓ Descends vertically across sternocleidomastoid

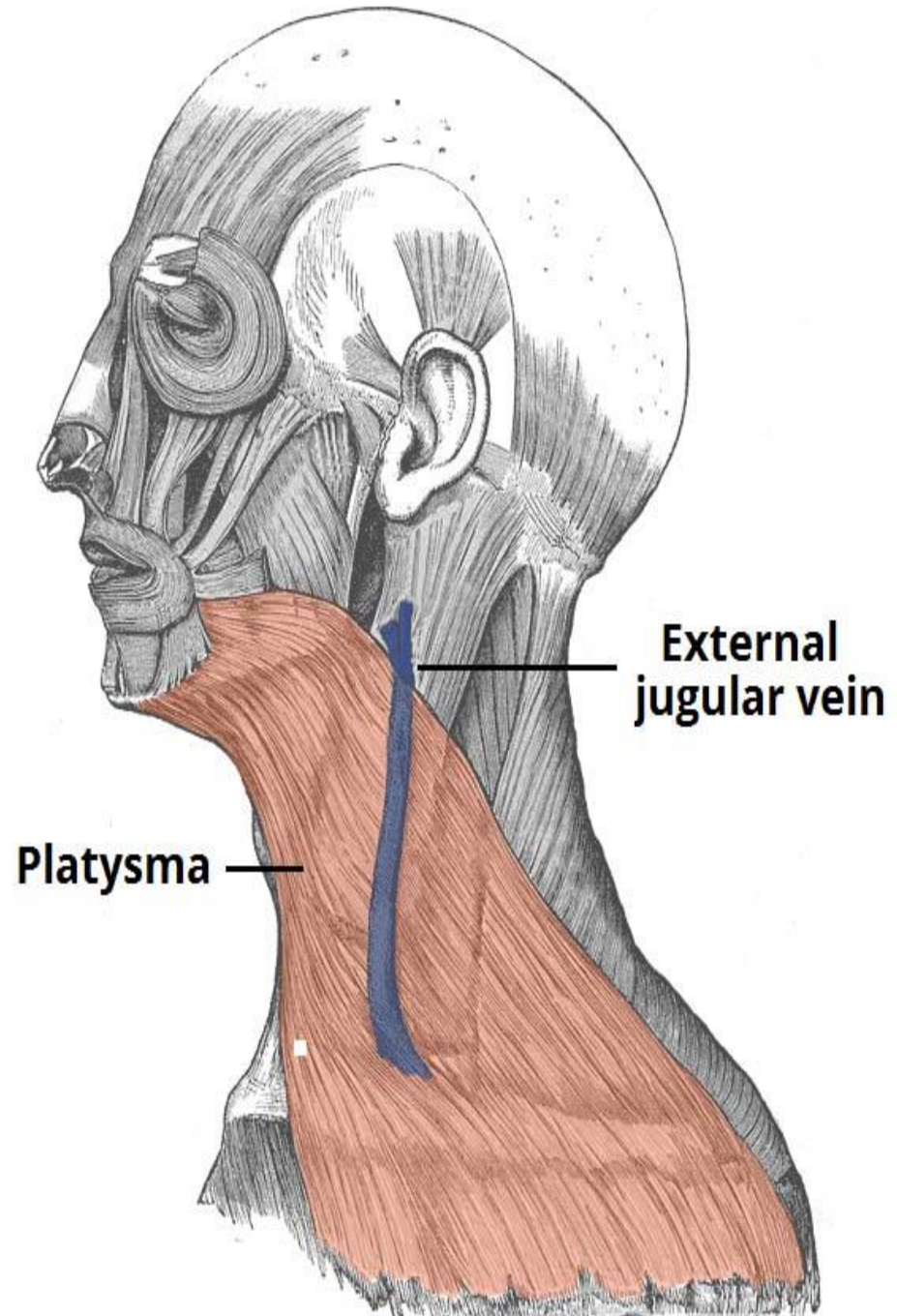
✓ Just above the clavicle in the posterior triangle, it pierces the deep fascia (investing layer) and drains into **subclavian vein**

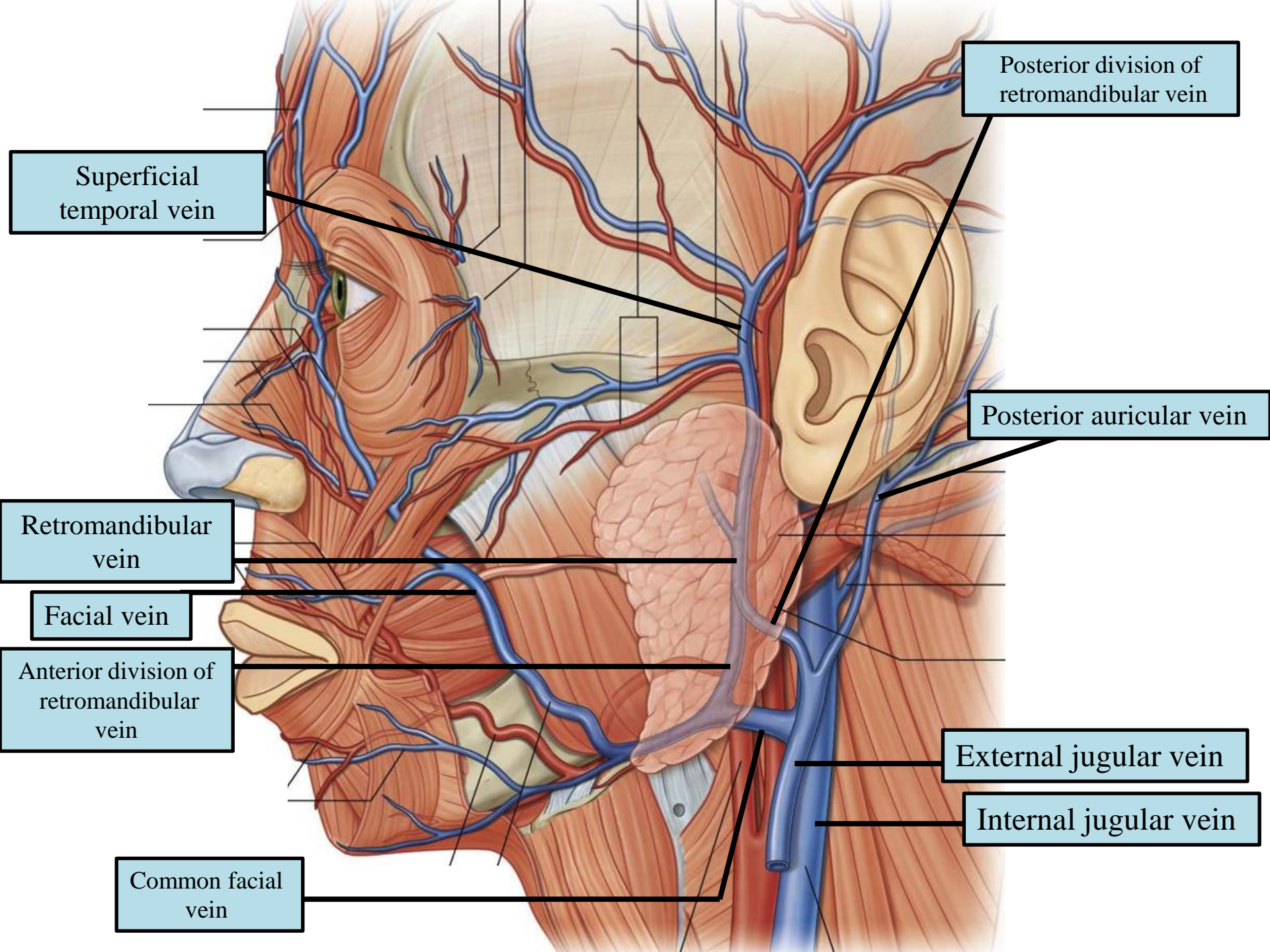




F. Netter
M.D.

Its course
extends from the
angle of the
mandible to the
middle of the
clavicle





Posterior division of retromandibular vein

Superficial temporal vein

Posterior auricular vein

Retromandibular vein

Facial vein

Anterior division of retromandibular vein

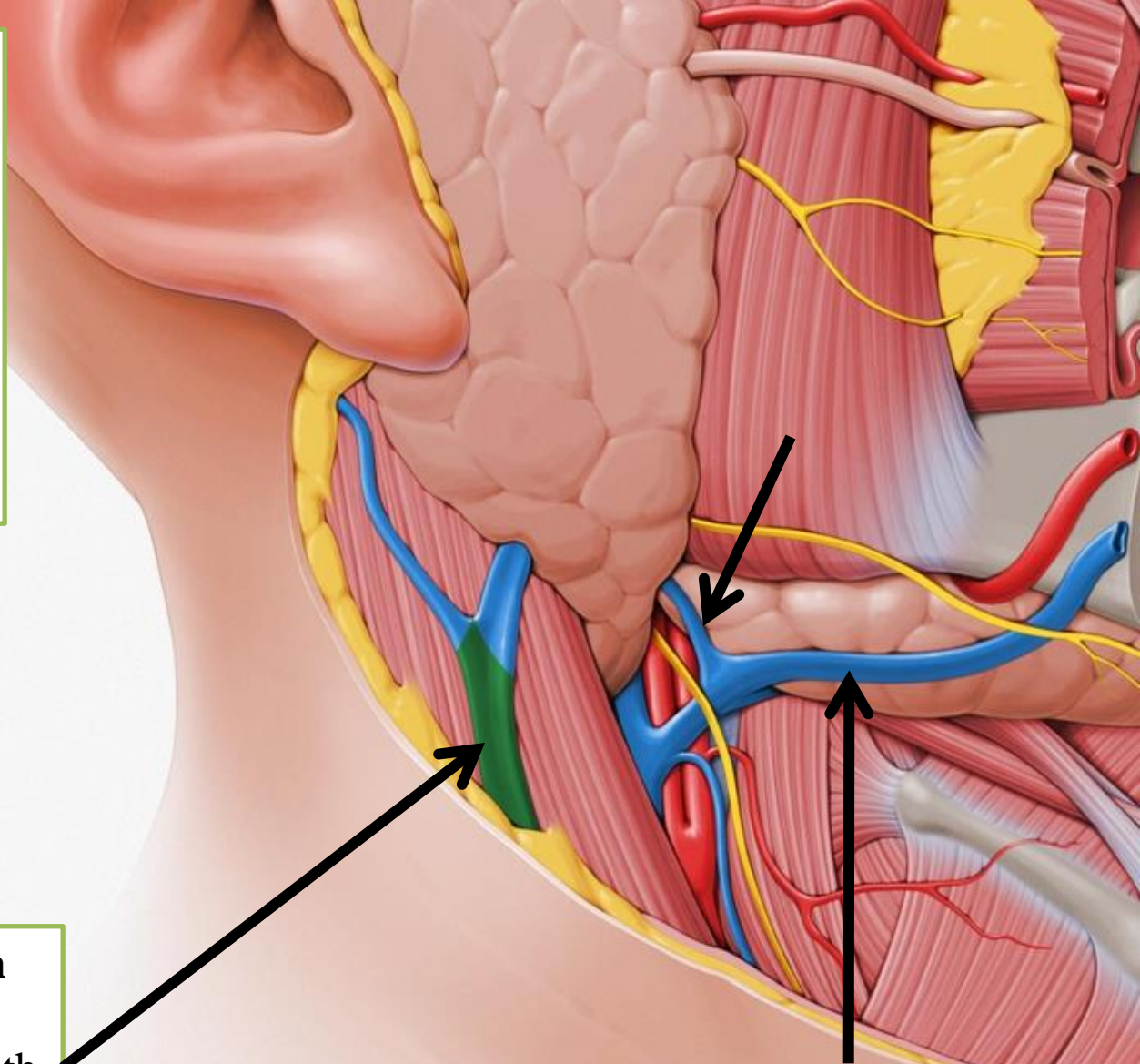
External jugular vein

Internal jugular vein

Common facial vein

✓ The retromandibular vein is formed when **superficial temporal** and **maxillary veins** join in the substance of parotid gland

✓ On leaving the parotid gland, it divides into **anterior and posterior divisions**



The **external jugular vein** begins by the union of the **posterior auricular vein** with the **posterior division of the retromandibular vein**

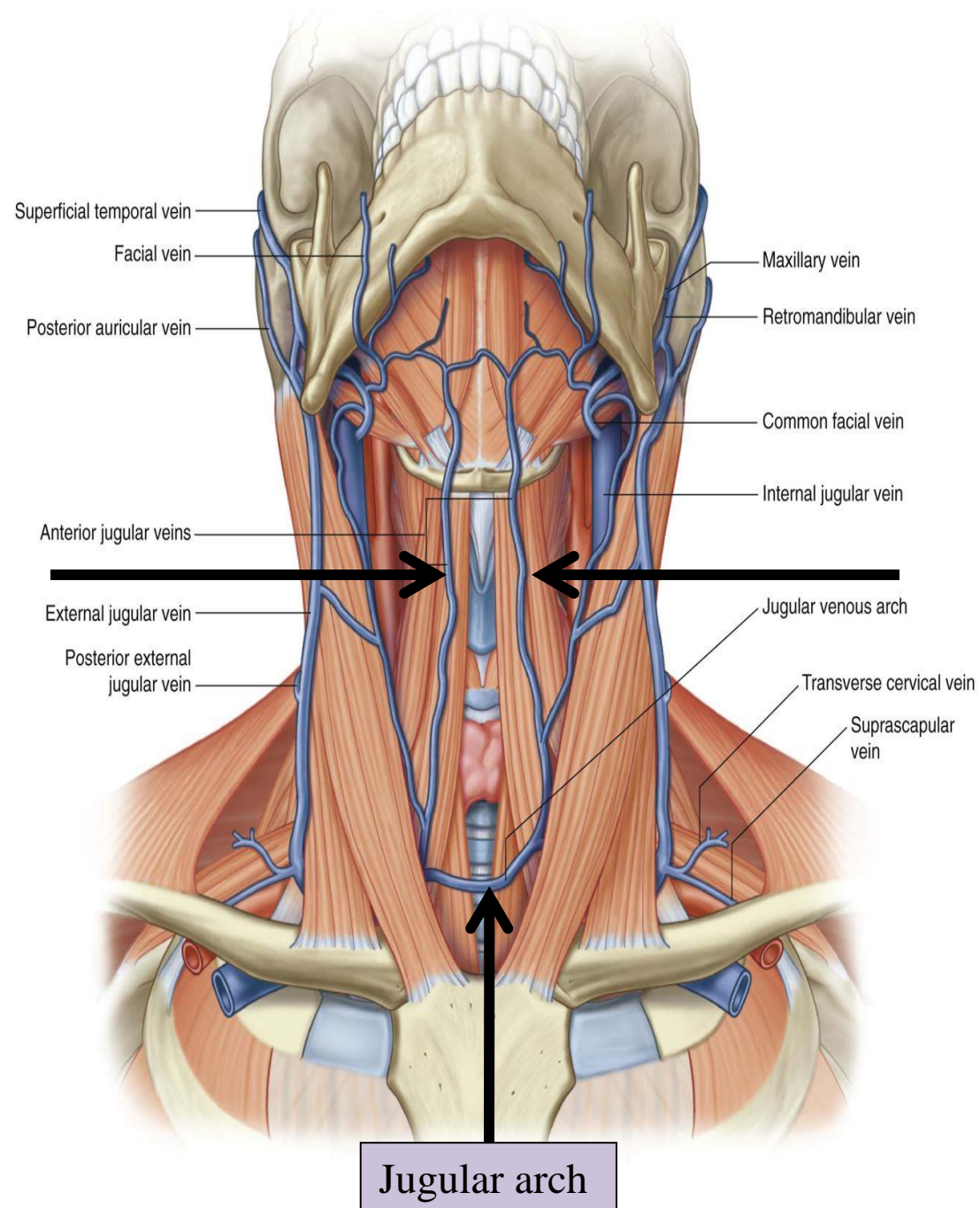
Facial Vein is joined by the anterior division of the retromandibular vein, and drains into the internal jugular vein.



Superficial Veins

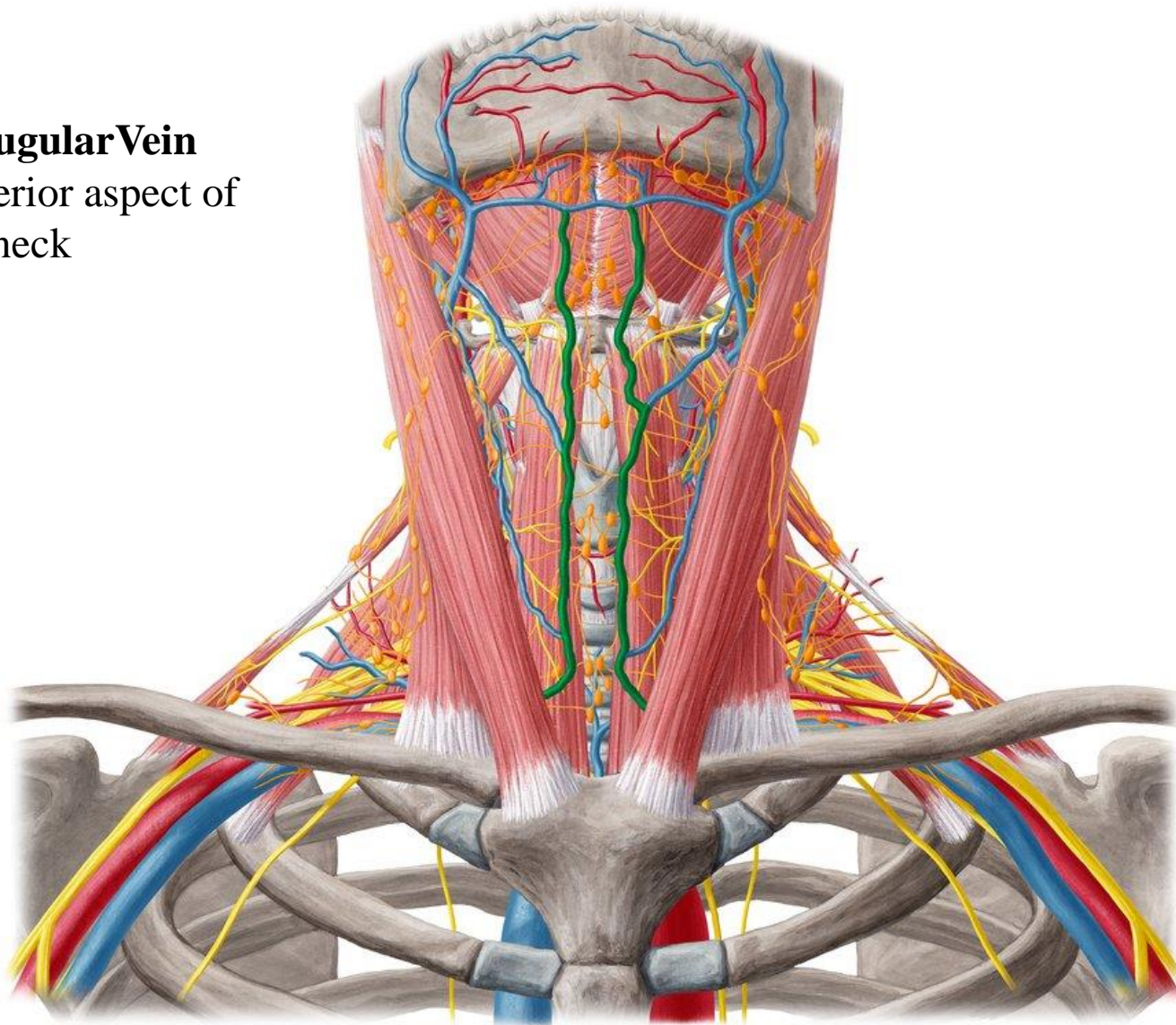
2- Anterior Jugular Vein

- ✓ Begins just below the chin
- ✓ Runs down the neck close to the midline
- ✓ Just above the suprasternal notch, the veins of the two sides are united by a transverse trunk called the **jugular arch**
- ✓ At the lower part of the neck, it passes beneath sternocleidomastoid and drains into **external jugular vein**



Anterior Jugular Vein

drains the anterior aspect of
the neck



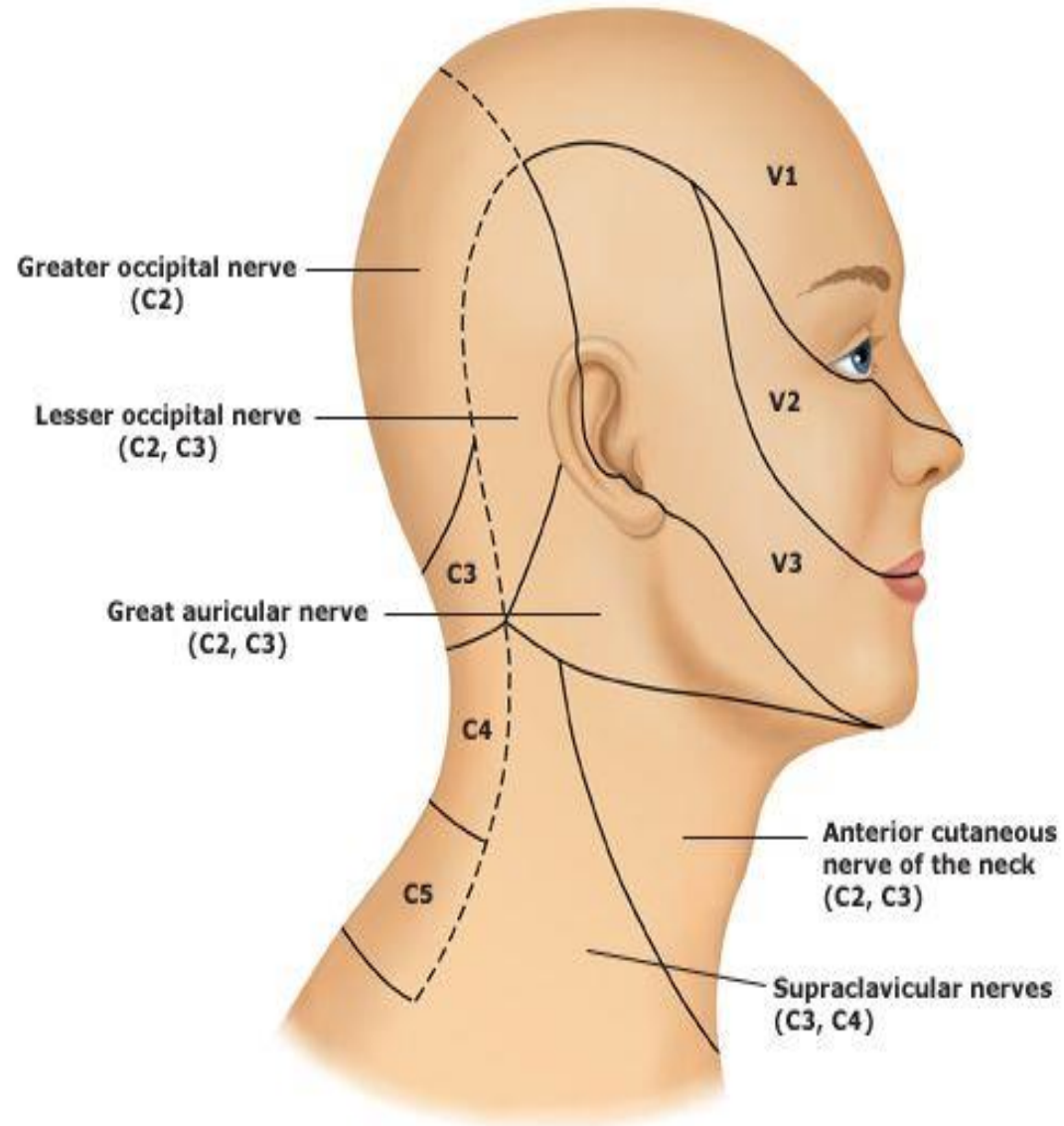
Cutaneous Nerves of the neck

The first cervical nerve has no cutaneous branch

Back: is supplied segmentally by posterior rami of cervical nerves 2 to 5

Remember Greater occipital nerve (C2) supplies the back of the scalp

Front and sides: is supplied by anterior rami of cervical nerves 2 to 4 through branches of cervical plexus

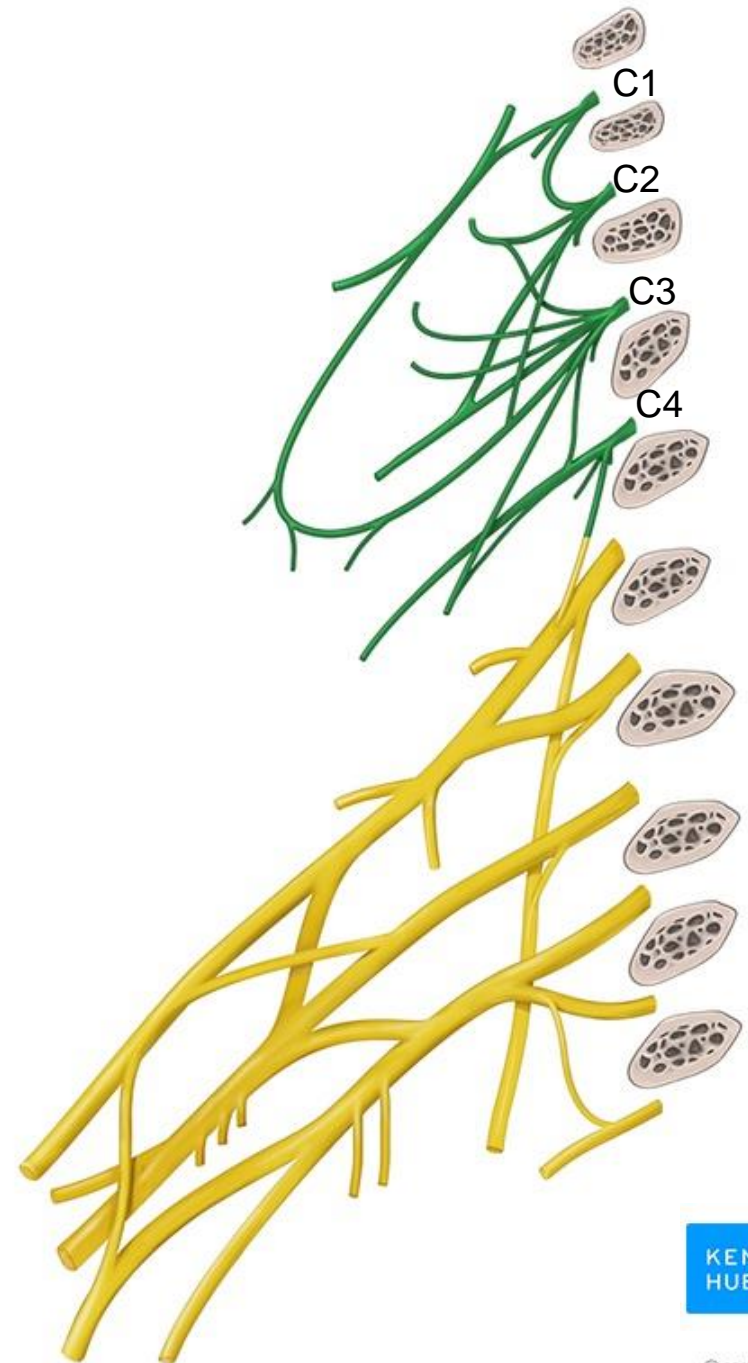


Cervical plexus

The **cervical plexus** is formed by the anterior rami of C1-C4

Branches:

- 1- Cutaneous nerves** emerge from the posterior border of sternocleidomastoid and visible on posterior triangle
- 2- Superior and inferior roots of ansa cervicalis** (C1-C3): innervates the infrahyoid muscles
- 3- Phrenic nerve** (C3-C5)



Cutaneous branches of Cervical plexus

The **lesser occipital nerve** (C₂): supplies the skin over the lateral part of the occipital region and the medial surface of the auricle (upper half)

The **great auricular nerve** (C₂ and 3): supplies the skin over the angle of the mandible and on both surfaces of the auricle (lower half)

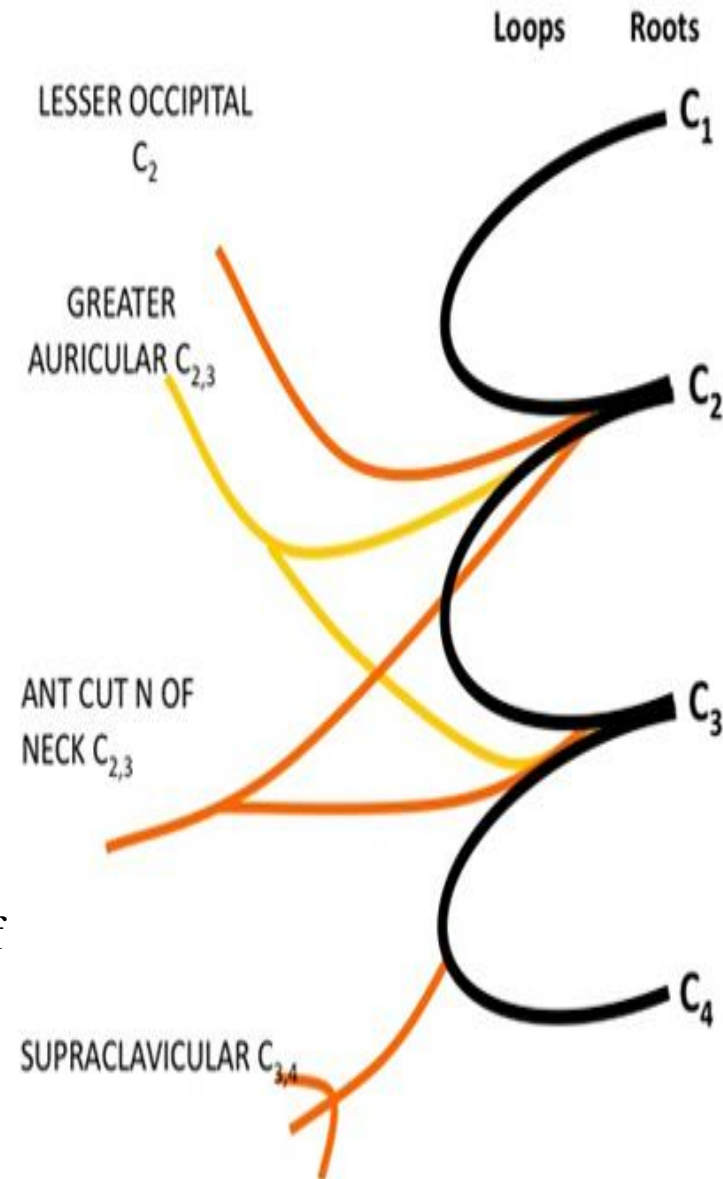
The **transverse cervical nerve** (C₂ and 3): supplies the skin on the anterior and lateral surfaces of the neck, from the body of the mandible to the sternum

The **supraclavicular nerves** (C₃ and 4) descend across the side of the neck down to the level of the second rib.

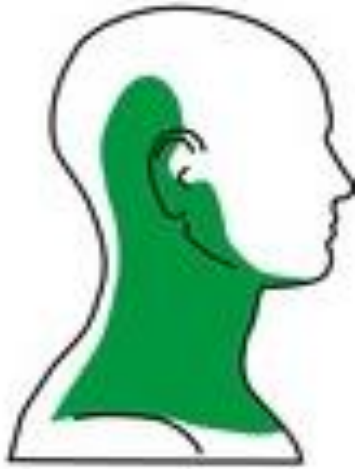The medial supraclavicular nerve crosses the medial end of the clavicle and supplies the skin as far as the median plane.

The intermediate supraclavicular nerve crosses the middle of the clavicle and supplies the skin of the chest wall.

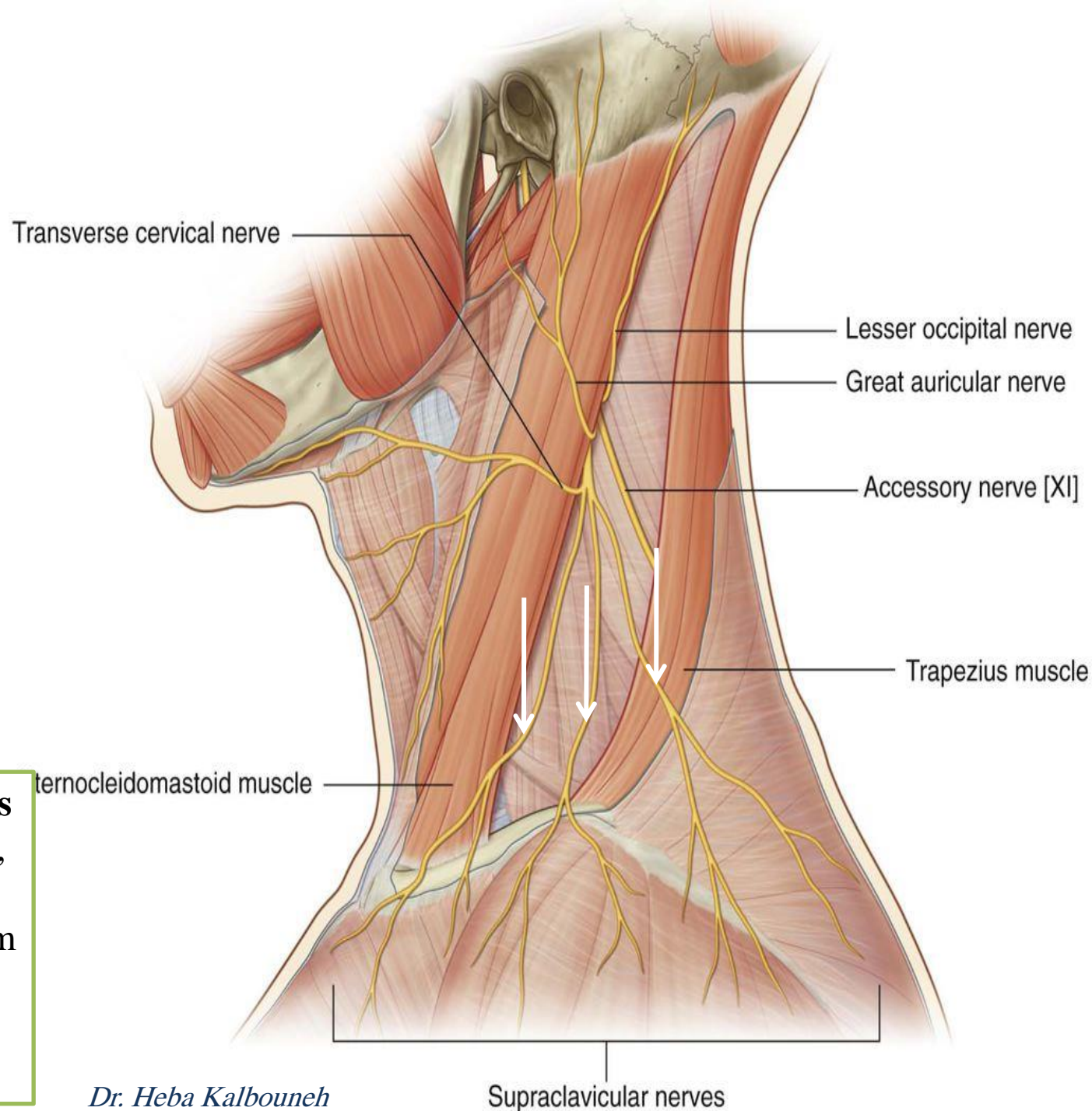
The lateral supraclavicular nerve crosses the lateral end of the clavicle and supplies the skin over the shoulder and the upper half of the deltoid muscle and the posterior aspect of the shoulder as far down as the spine of the scapula



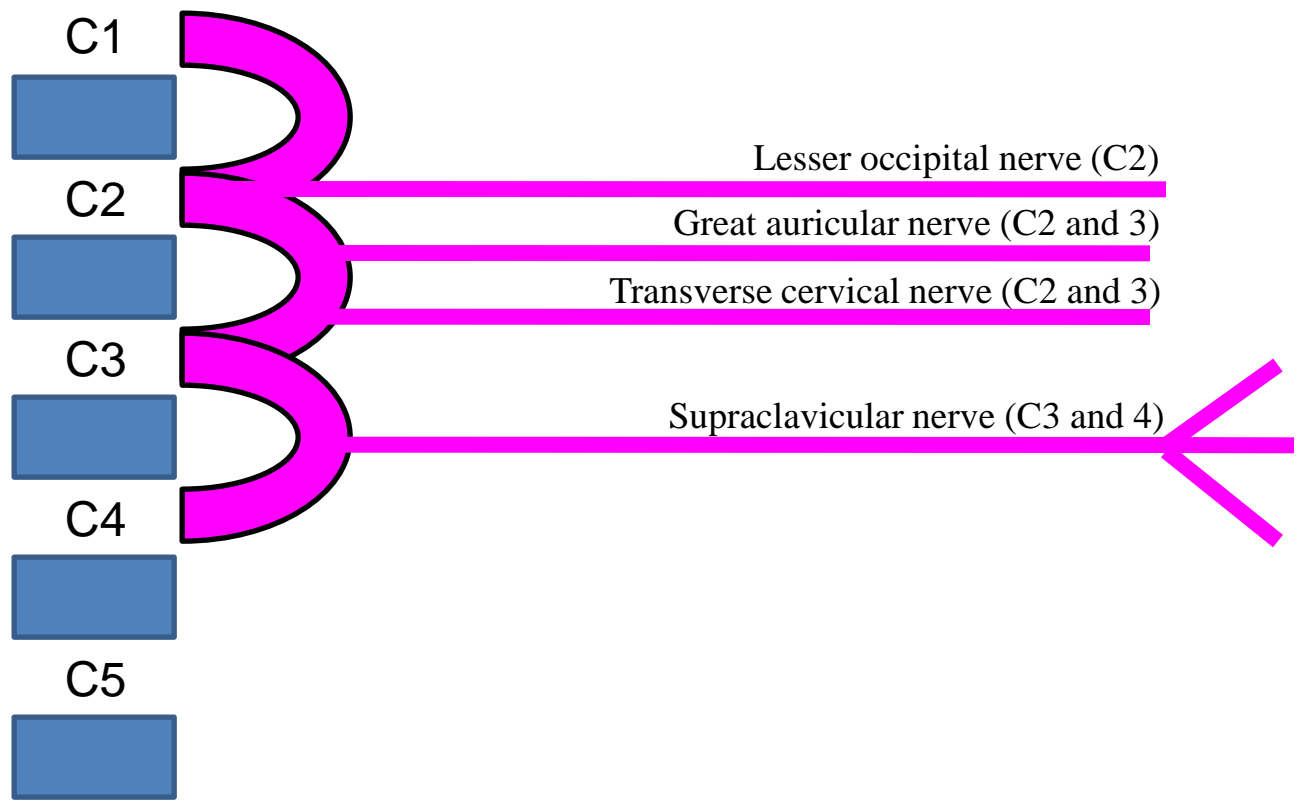
Sensory cutaneous branches of cervical plexus emerge at the **posterior border of sternocleidomastoid muscle (Erb's point)**

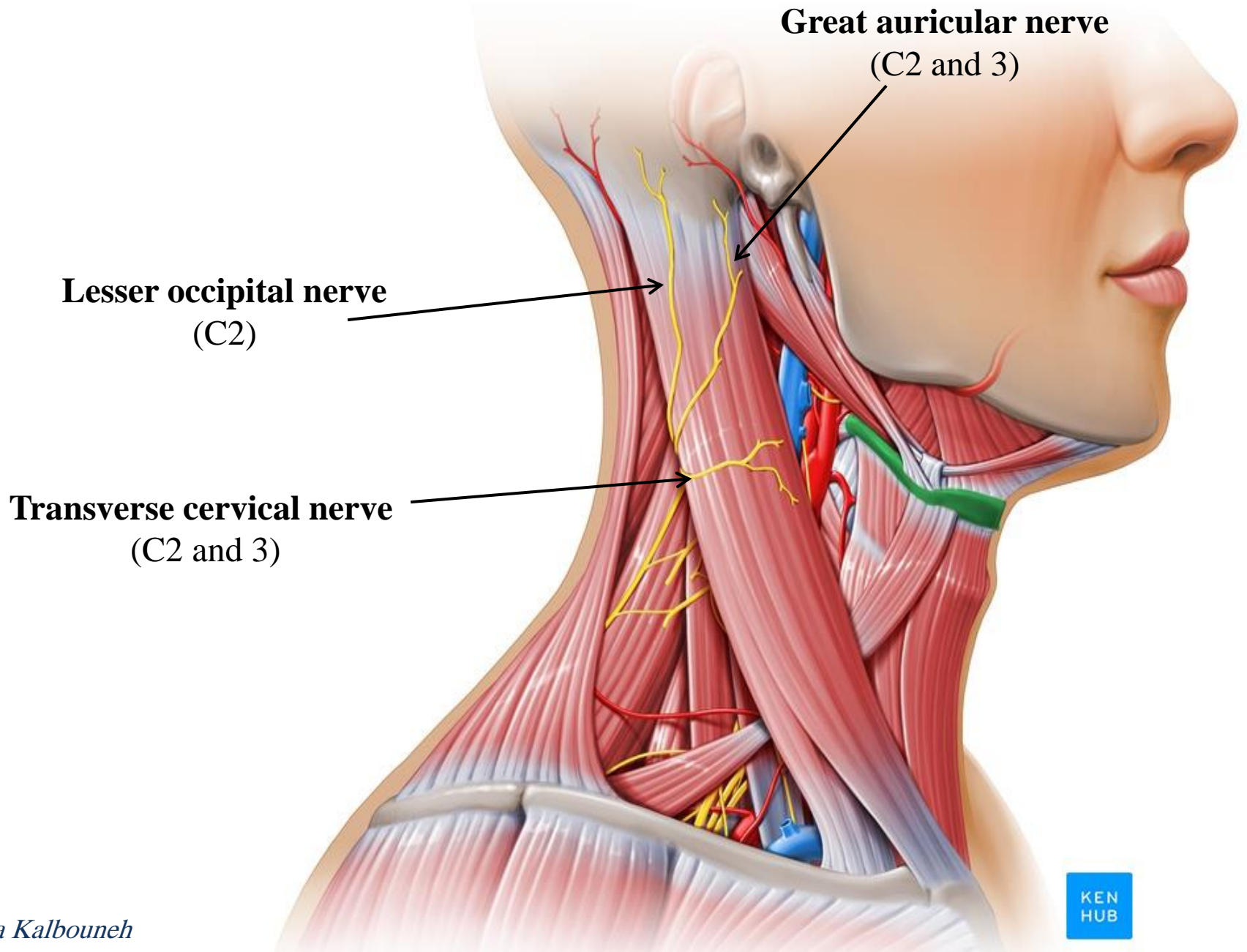


Supraclavicular nerves are important clinically, because pain may be referred along them from the phrenic nerve (C3C4C5) (gallbladder disease)



Cutaneous branches of Cervical plexus





Great auricular nerve
(C2 and 3)

Lesser occipital nerve
(C2)

Transverse cervical nerve
(C2 and 3)

Ansa cervicalis

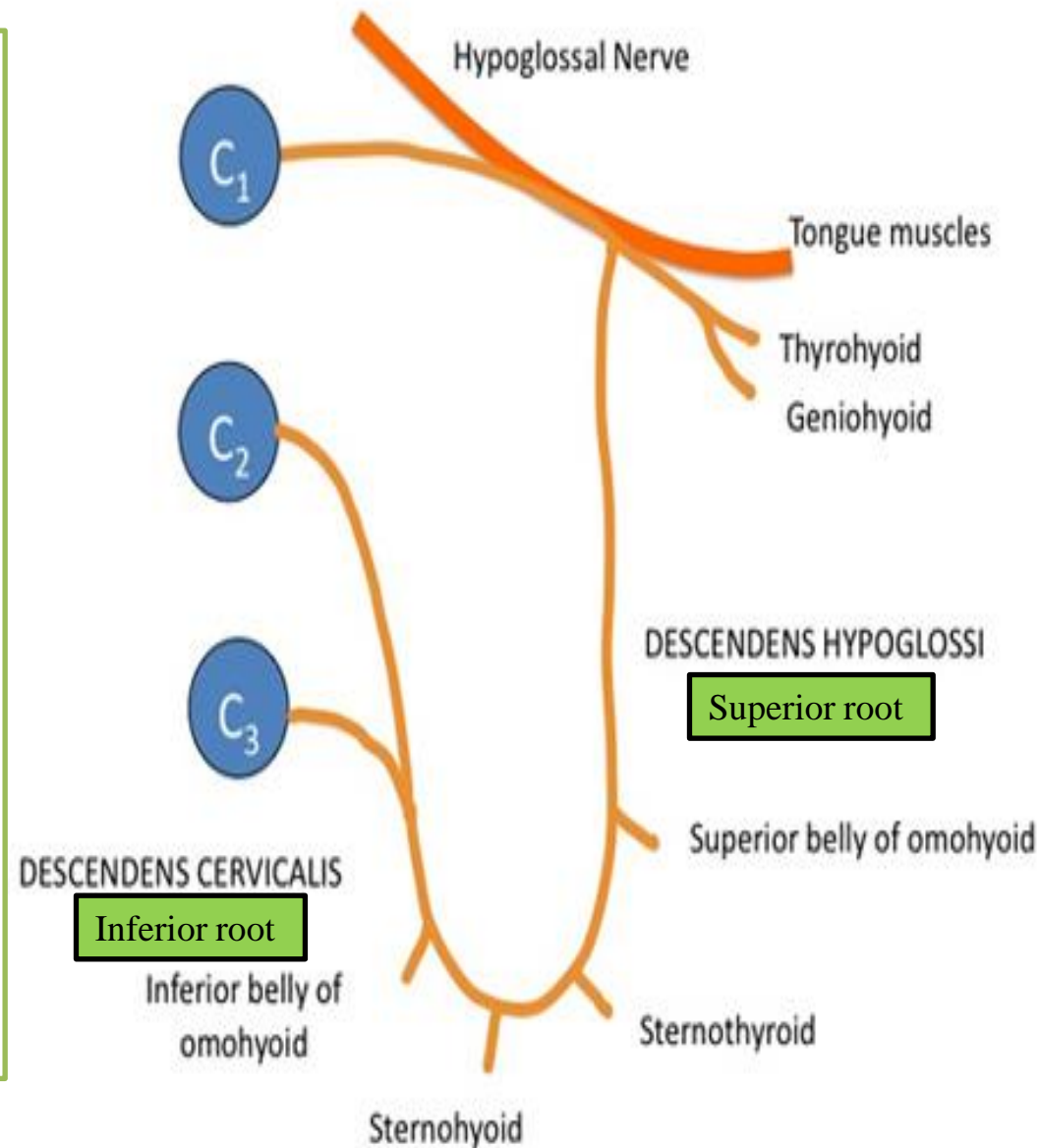
Ansa cervicalis innervates the infrahyoid muscles except thyrohyoid (C1)

✓ A branch from C1 joins the hypoglossal nerve
Some of these C1 fibers later leave the hypoglossal as the **descending hypoglossi** which unites with the **descending cervicalis** nerve (C2 and 3) to form the **ansa cervicalis**

✓ The first, second, and third cervical nerve fibers within the ansa cervicalis supply:

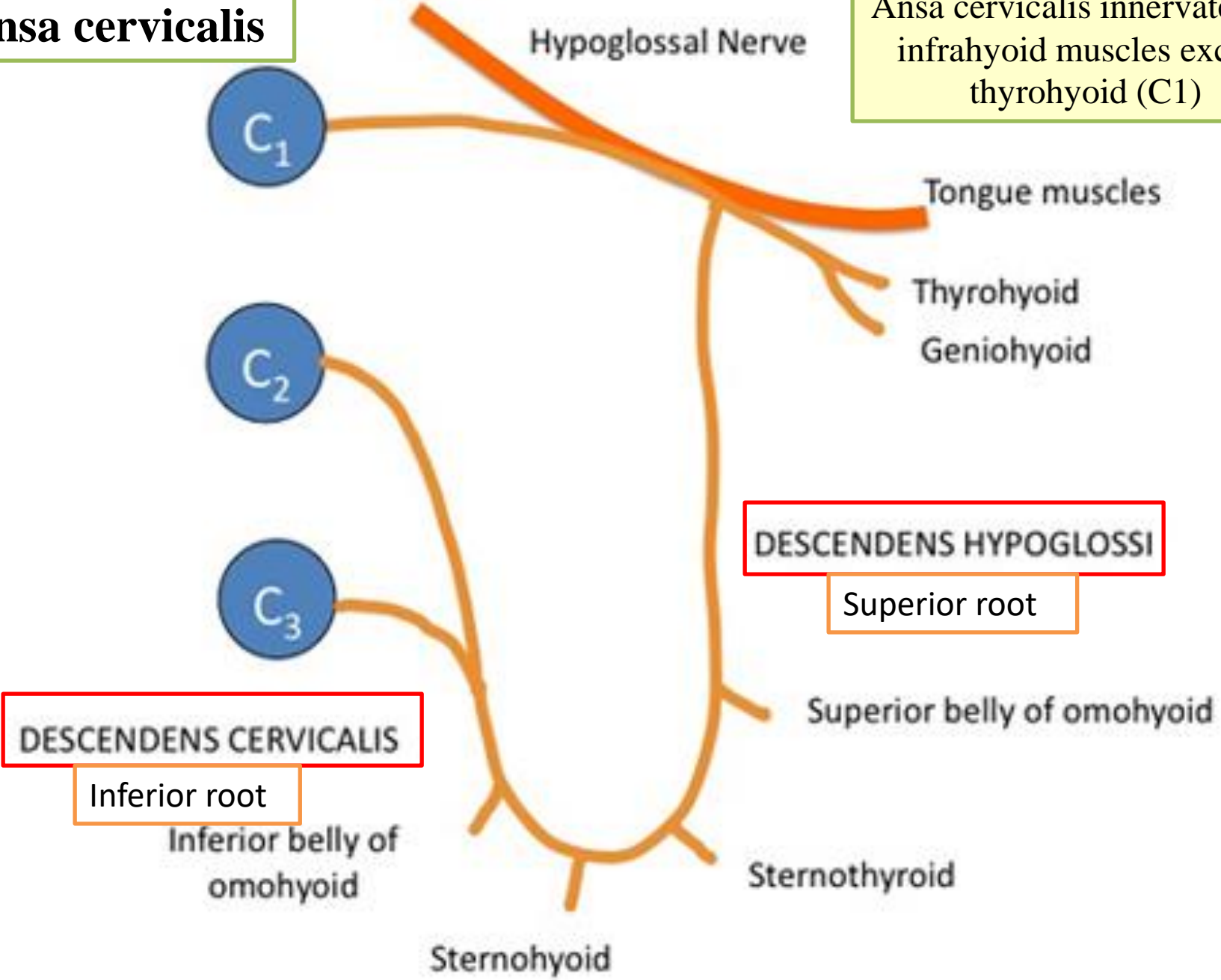
- 1- Omohyoid
- 2- Sternohyoid
- 3- Sternothyroid

✓ Other C1 fibers within the hypoglossal nerve leave it as the nerve to the thyrohyoid and geniohyoid



Ansa cervicalis

Ansa cervicalis innervates the infrahyoid muscles except thyrohyoid (C1)



DESCENDENS HYPOGLOSSI

Superior root

DESCENDENS CERVICALIS

Inferior root

Hypoglossal Nerve

Tongue muscles

Thyrohyoid
Geniohyoid

Superior belly of omohyoid

Inferior belly of omohyoid

Sternohyoid

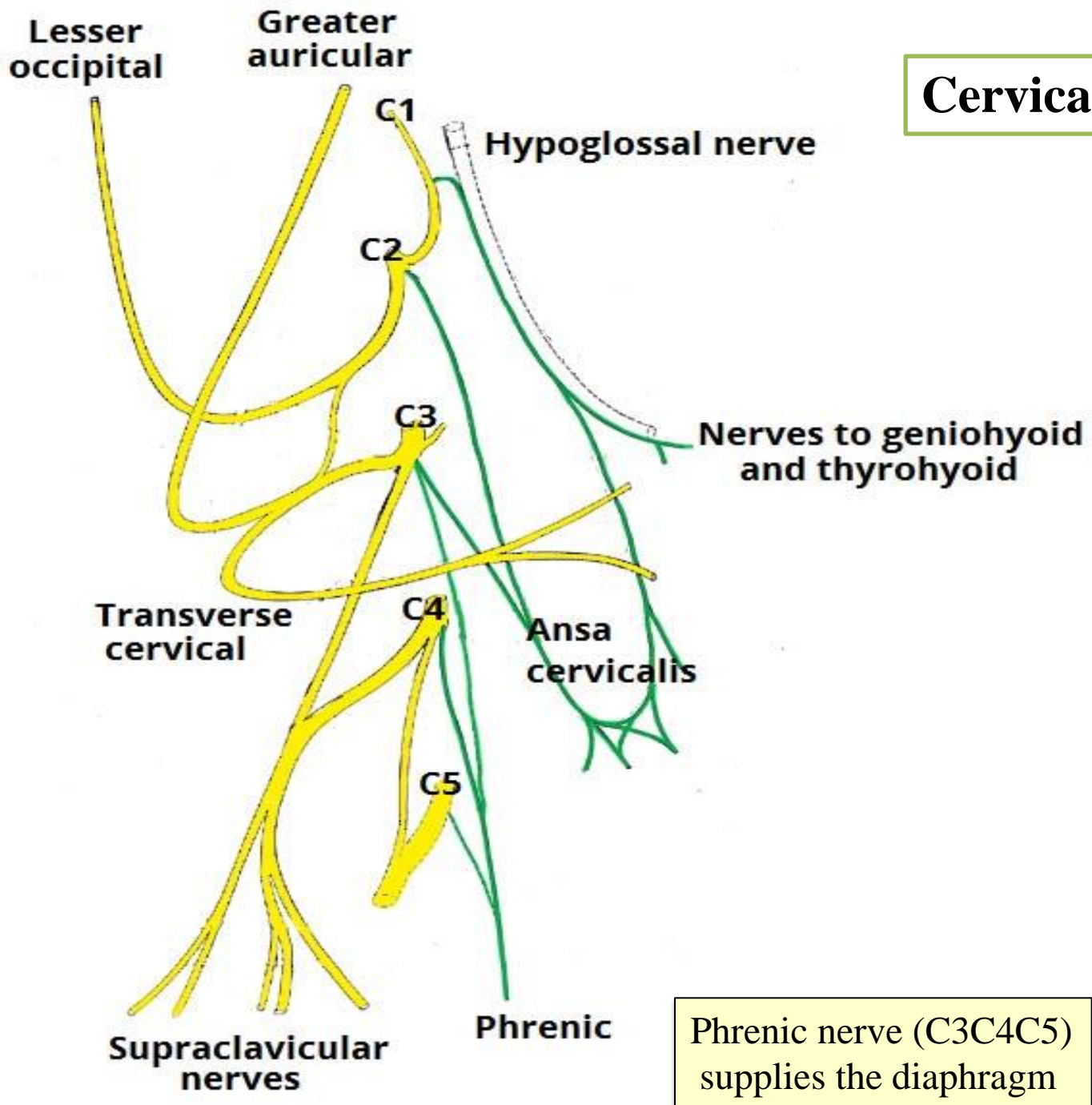
Sternohyoid

C₁

C₂

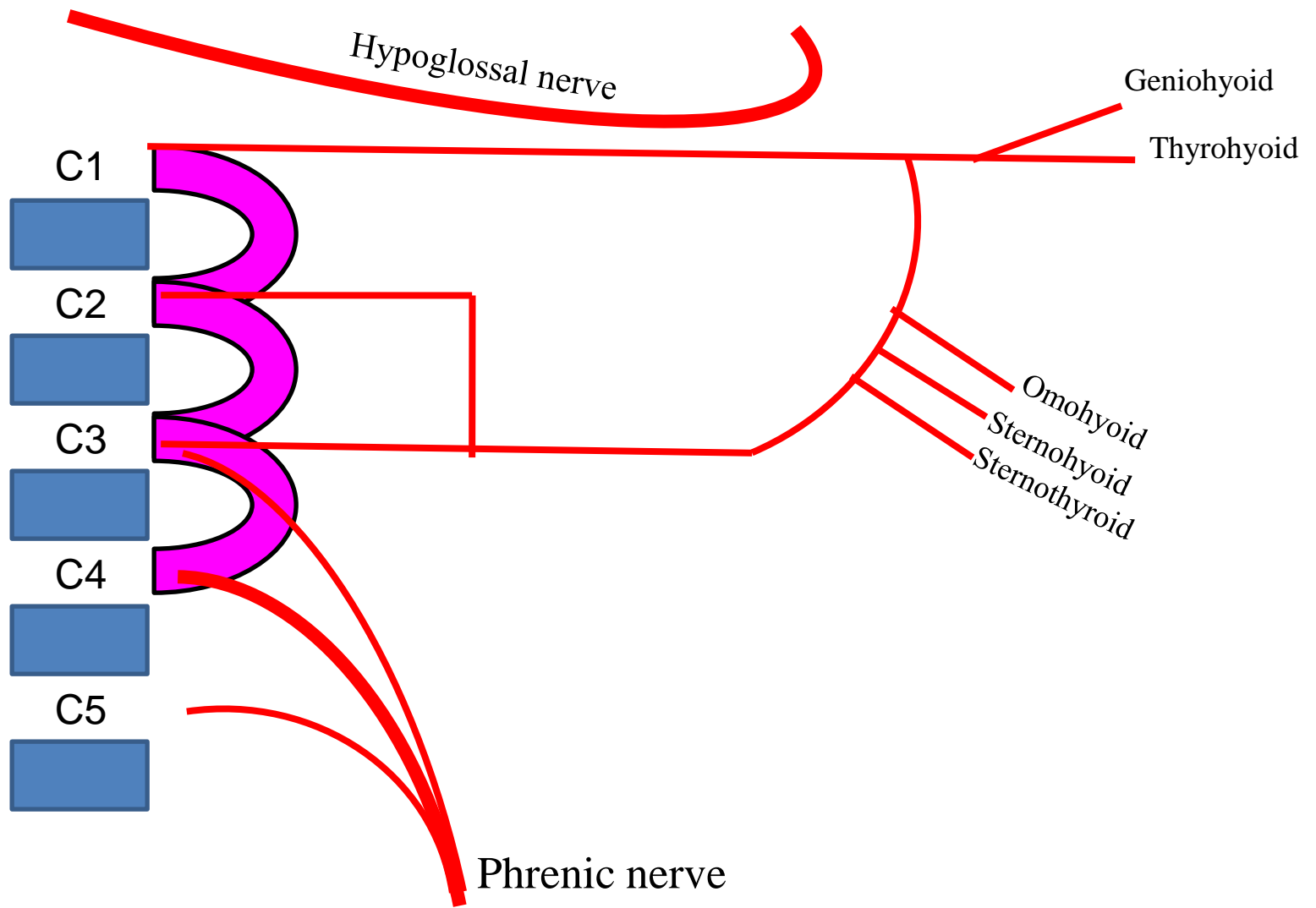
C₃

Cervical plexus



Phrenic nerve (C3C4C5) supplies the diaphragm

Muscular branches of Cervical plexus



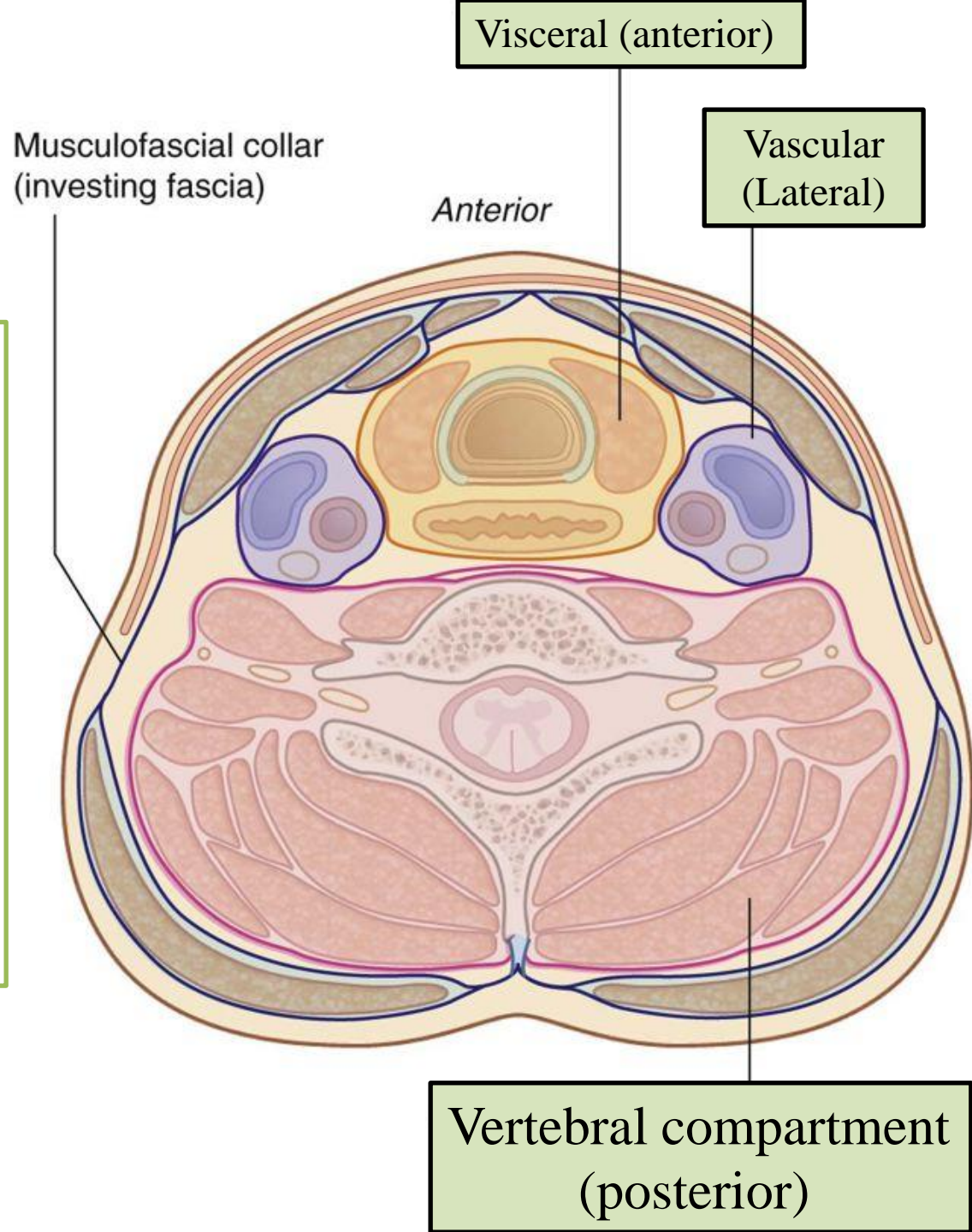
Deep fascia

Neck compartments

Visceral compartment: contains parts of digestive and respiratory systems and several endocrine glands

Vertebral compartment: contains cervical vertebrae, spinal cord, cervical nerves and vertebral muscles

Two vascular compartments: contain major blood vessels and vagus nerve



Deep fascia

In the neck, deep fascia not only act to support internal structures, but also help to **compartmentalize** structures of the neck

Deep cervical fascia is organized into several layers.

These layers act like a shirt collar, supporting the structures and vessels of the neck.

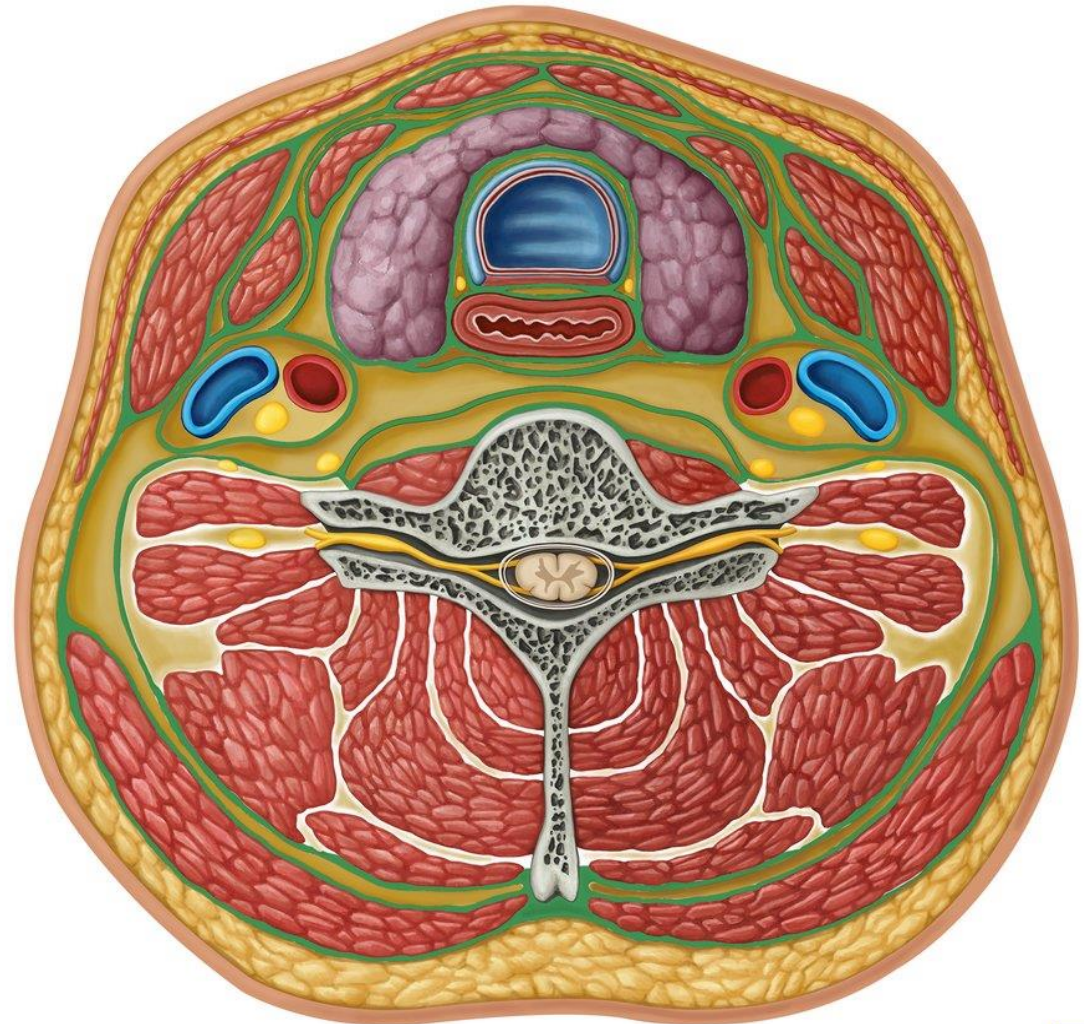
1- Investing layer: surrounds all structures in the neck

2- Prevertebral layer: surrounds the vertebral column and the muscles around it

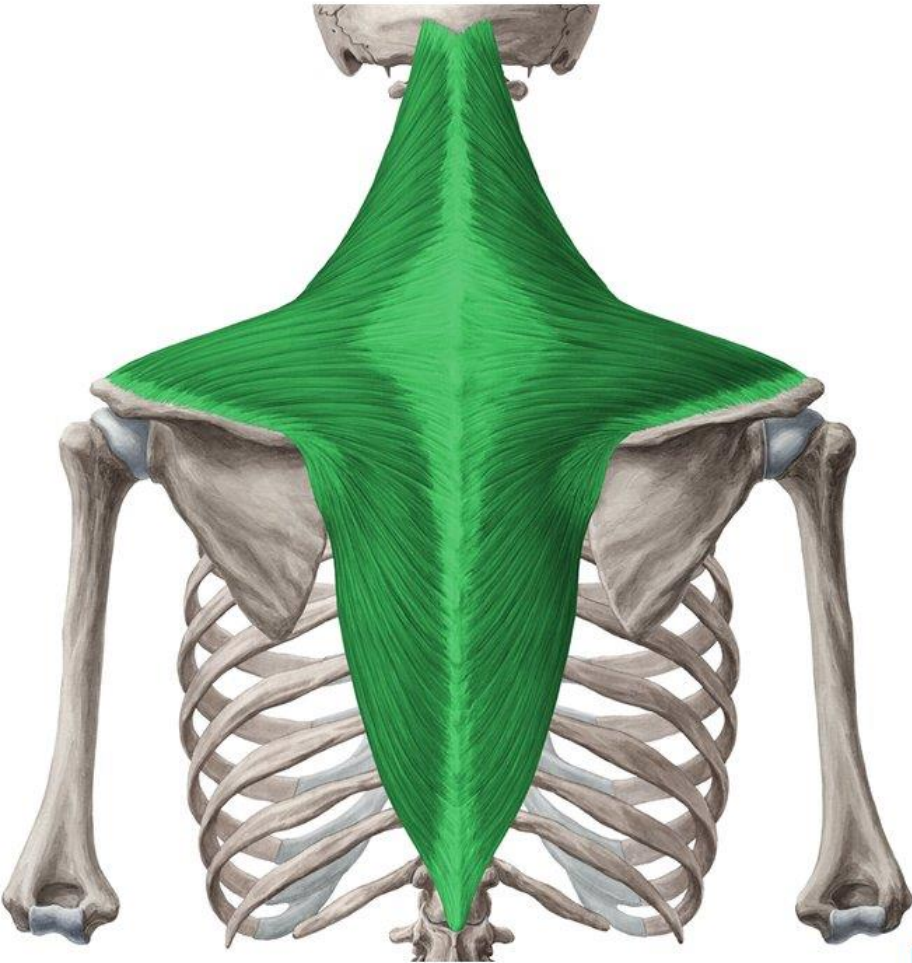
3- Pretracheal layer: encloses the viscera of the neck and infrahyoid muscles

4- Carotid sheaths: receive contribution from the other three layers

Surround neurovascular bundles on the side of the neck



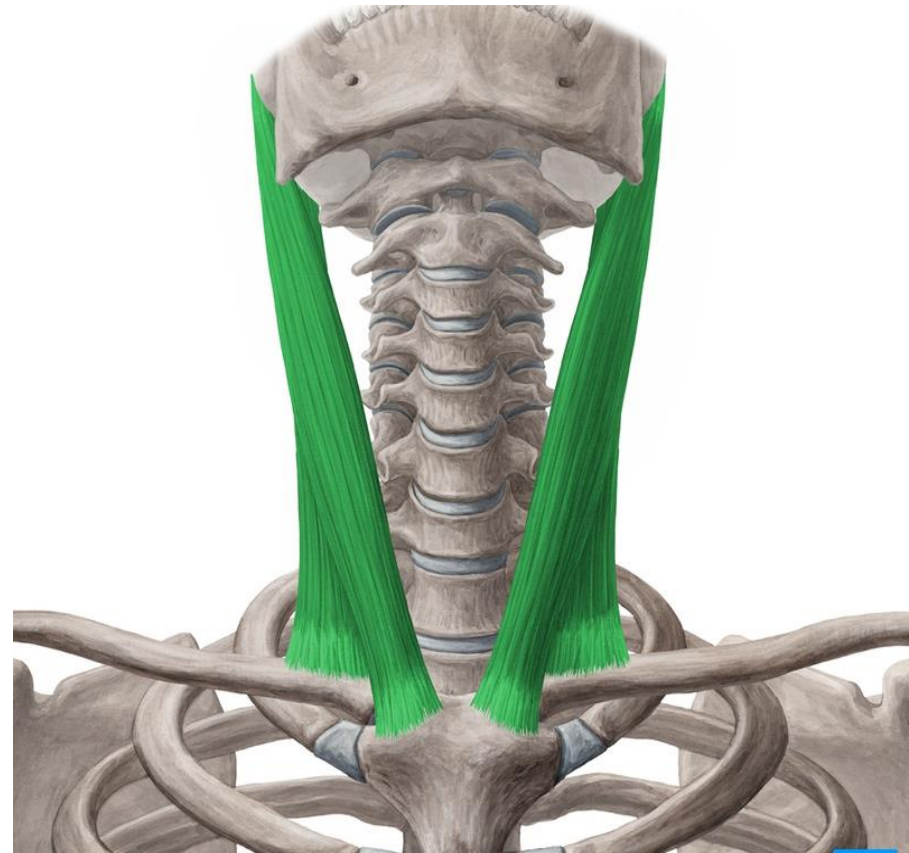
Trapezius



KEN
HUB

© www.kenhub.com

Sternocleidomastoid



KEN
HUB

Investing layer of deep fascia

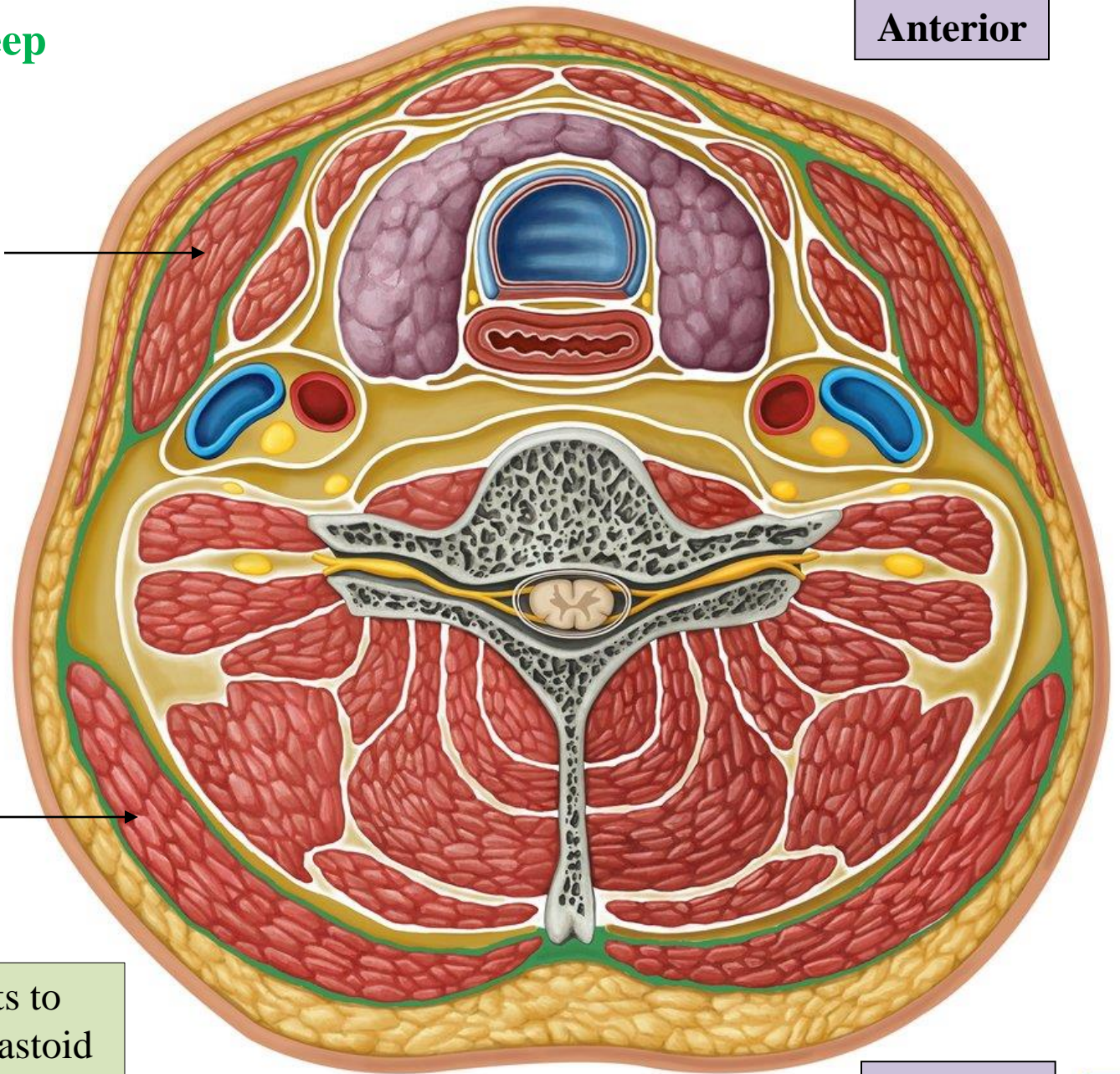
Anterior

Sternocleidomastoid

Encloses infrahyoid muscles??!!

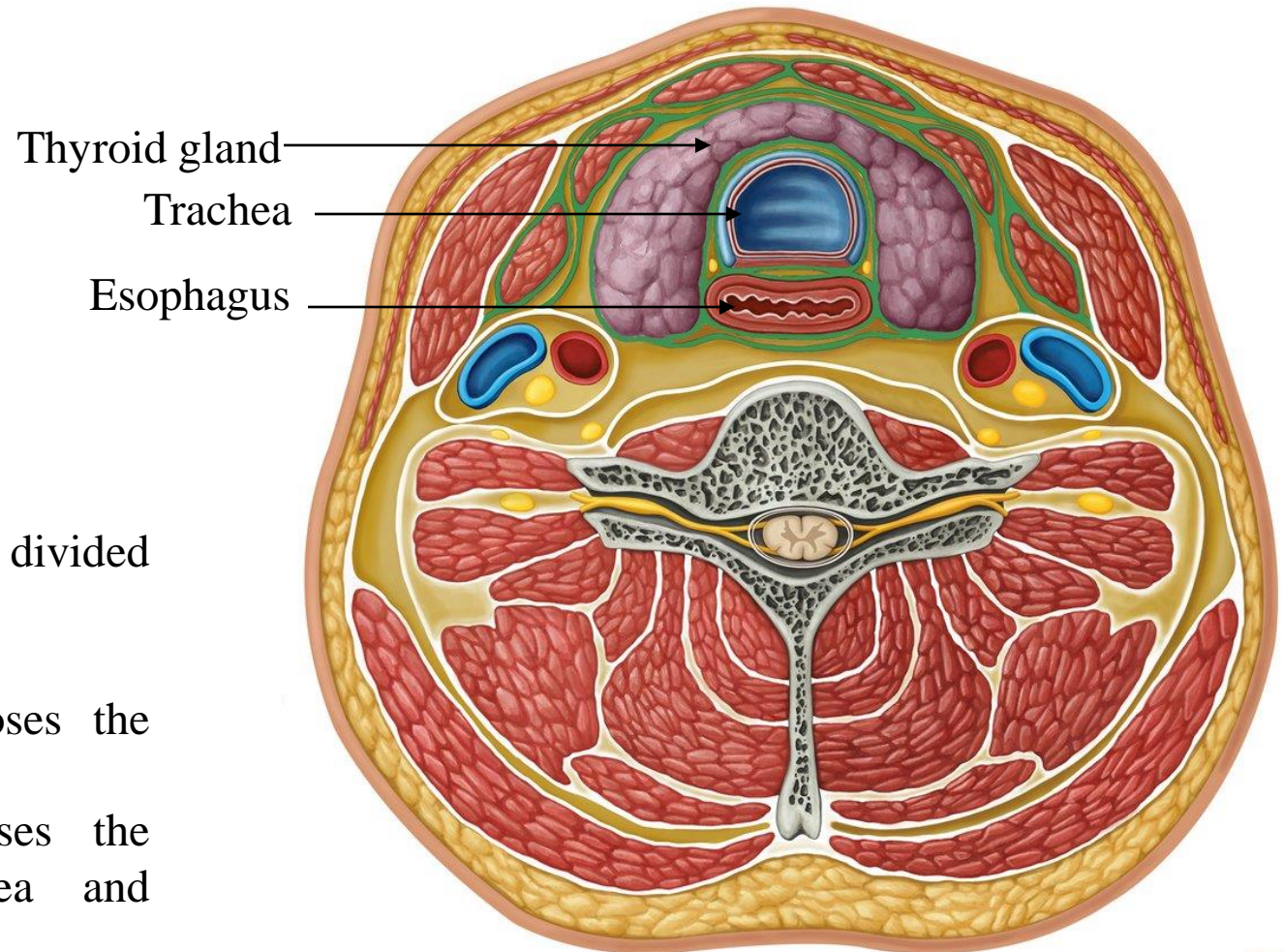
Trapezius

Investing layer splits to enclose sternocleidomastoid and trapezius muscles



Posterior

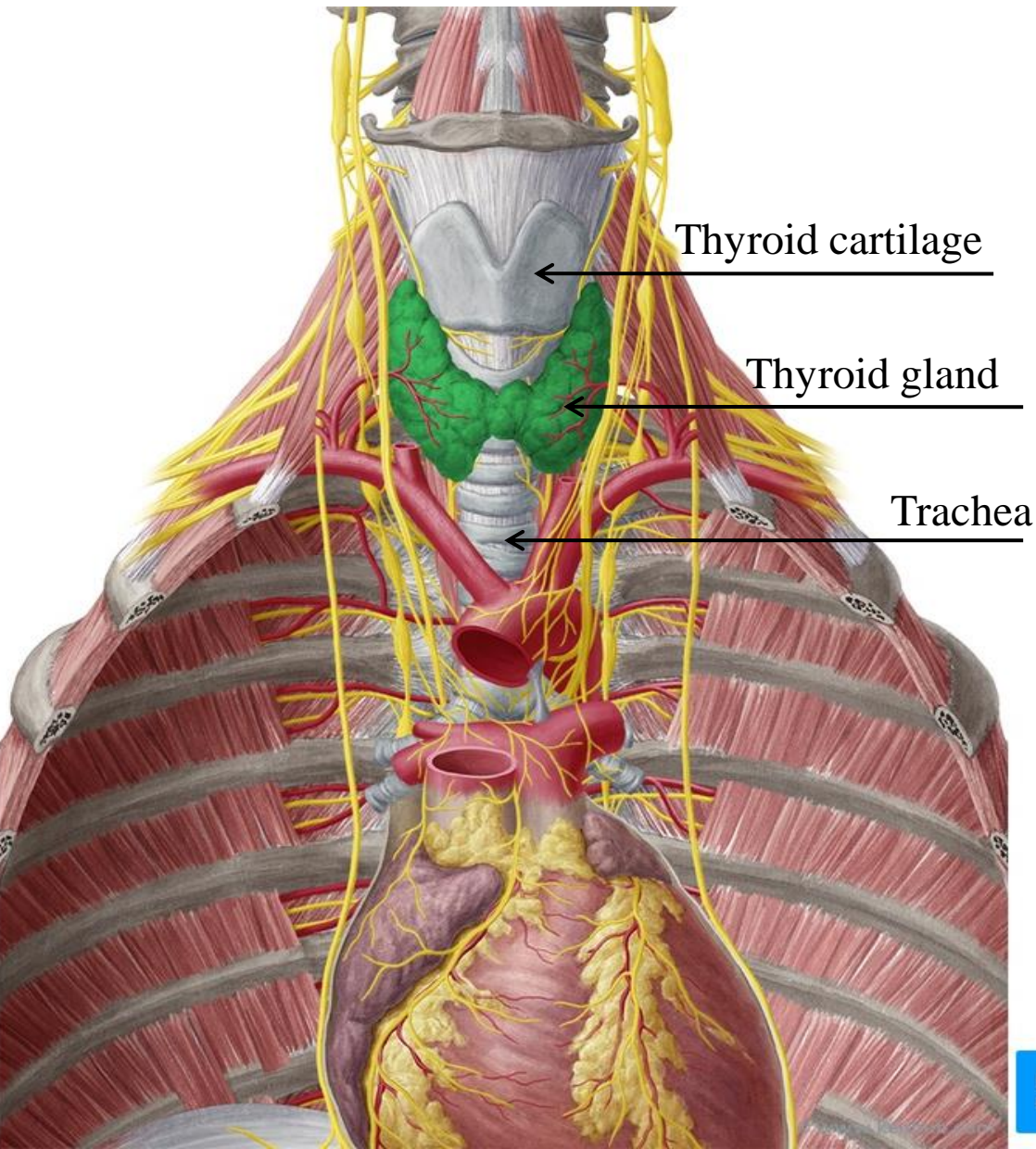
Pretracheal fascia



Anatomically, it can be divided into two parts:

Muscular part: encloses the infrahyoid muscles.

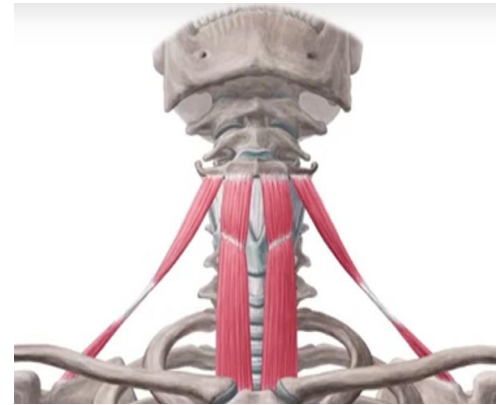
Visceral part: encloses the thyroid gland, trachea and esophagus.



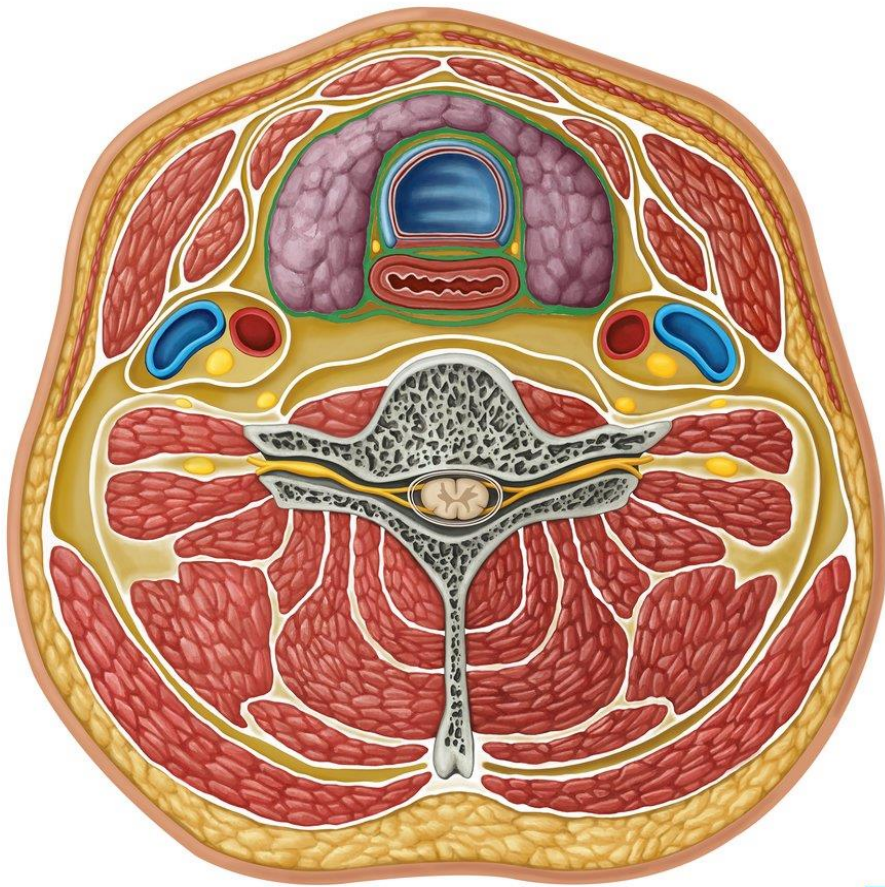
Thyroid cartilage

Thyroid gland

Trachea



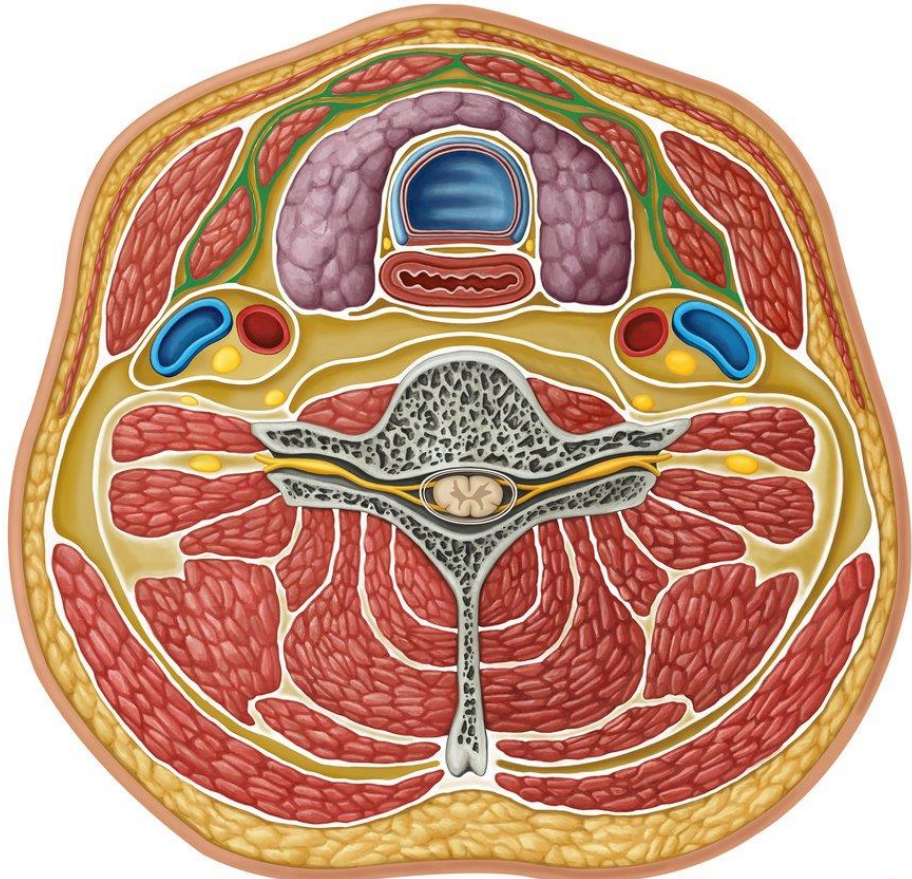
Infrahyoid muscles



Pretracheal fascia-
Visceral part

© www.kenhub.com
KEN HUB

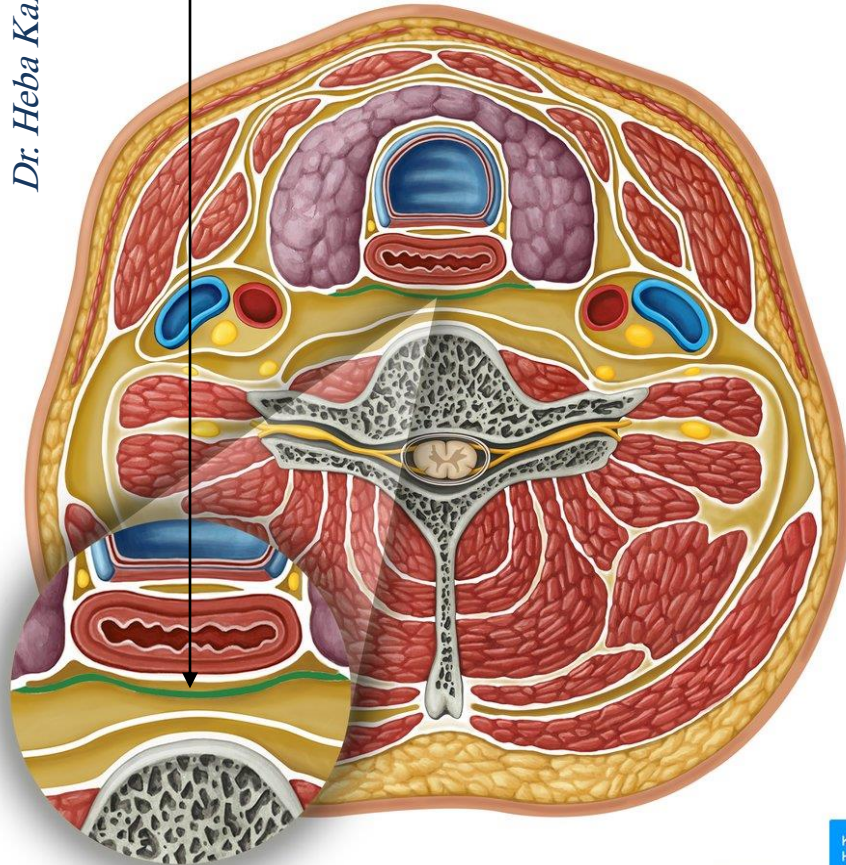
Pretracheal fascia-
Muscular part



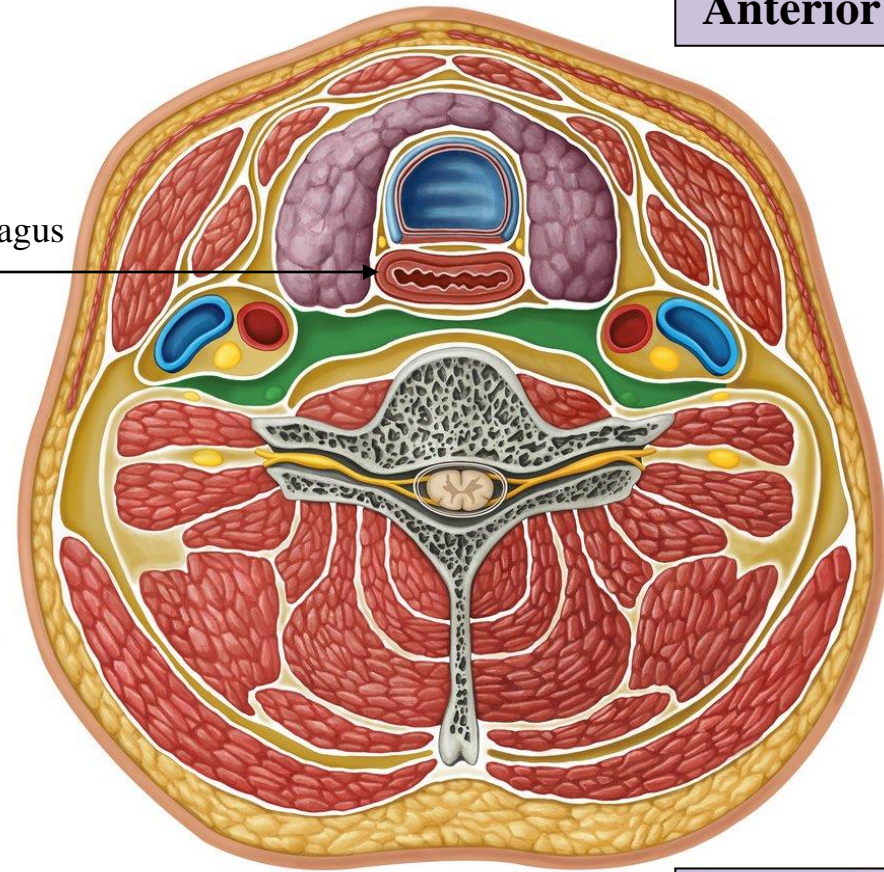
© www.kenhub.com
KEN HUB

Pretracheal layer posterior to the pharynx is called **Buccopharyngeal fascia** (invests the pharyngeal muscles and is continued forward onto the buccinator)

Dr. Heba Kalbouneh



Esophagus



Anterior

Posterior

The **retropharyngeal space** is a potential space, bounded by the buccopharyngeal fascia, it is posterior to the pharynx and esophagus

Note: more precisely, the superior portion posterior to the pharynx is termed the **retropharyngeal space**, while the inferior continuation is the **retroesophageal space**.

Anterior

Prevertebral fascia

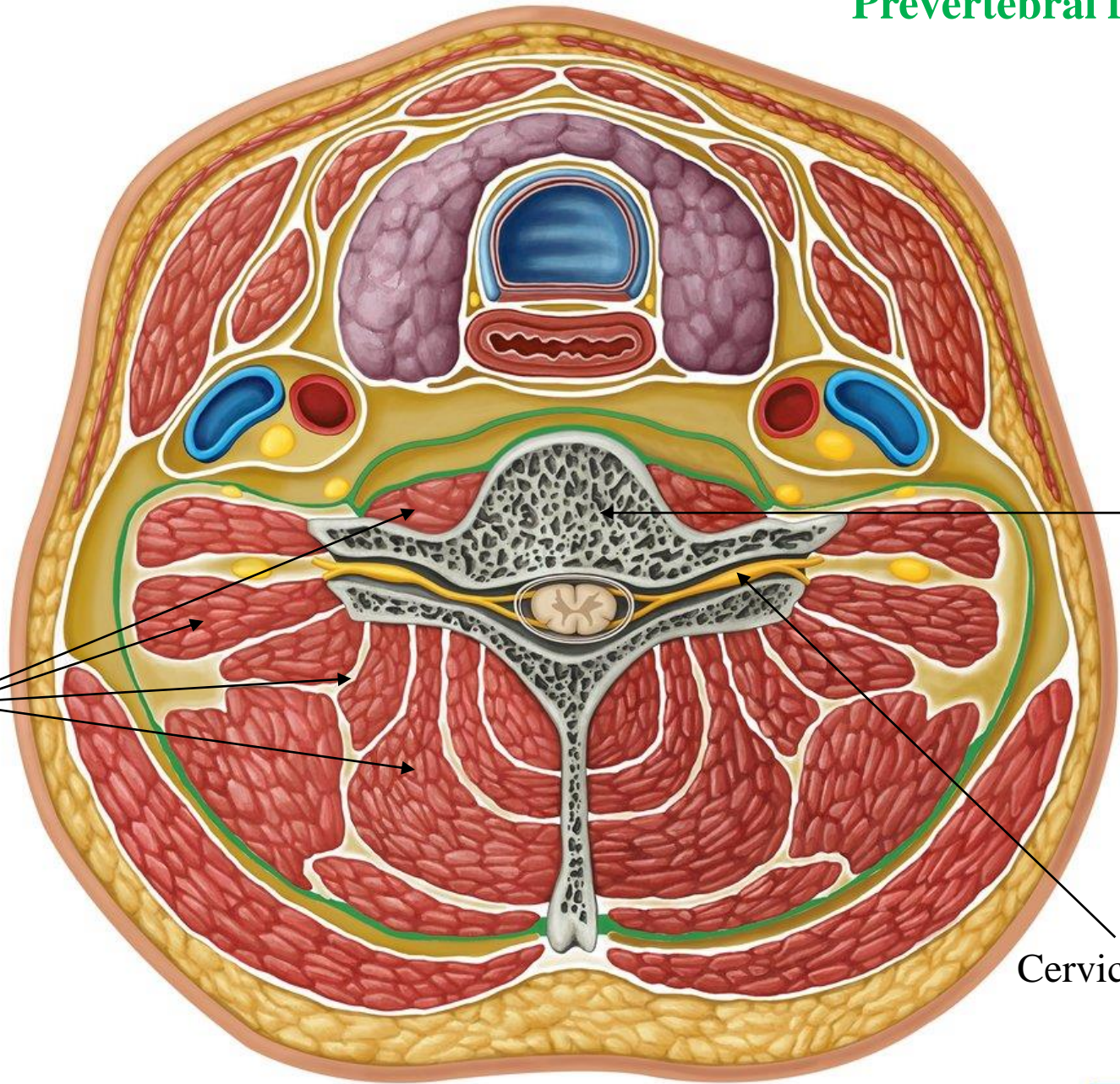
Dr. Heba Kalbouneh

Vertebral muscles

Cervical vertebra

Cervical spinal nerve

Posterior

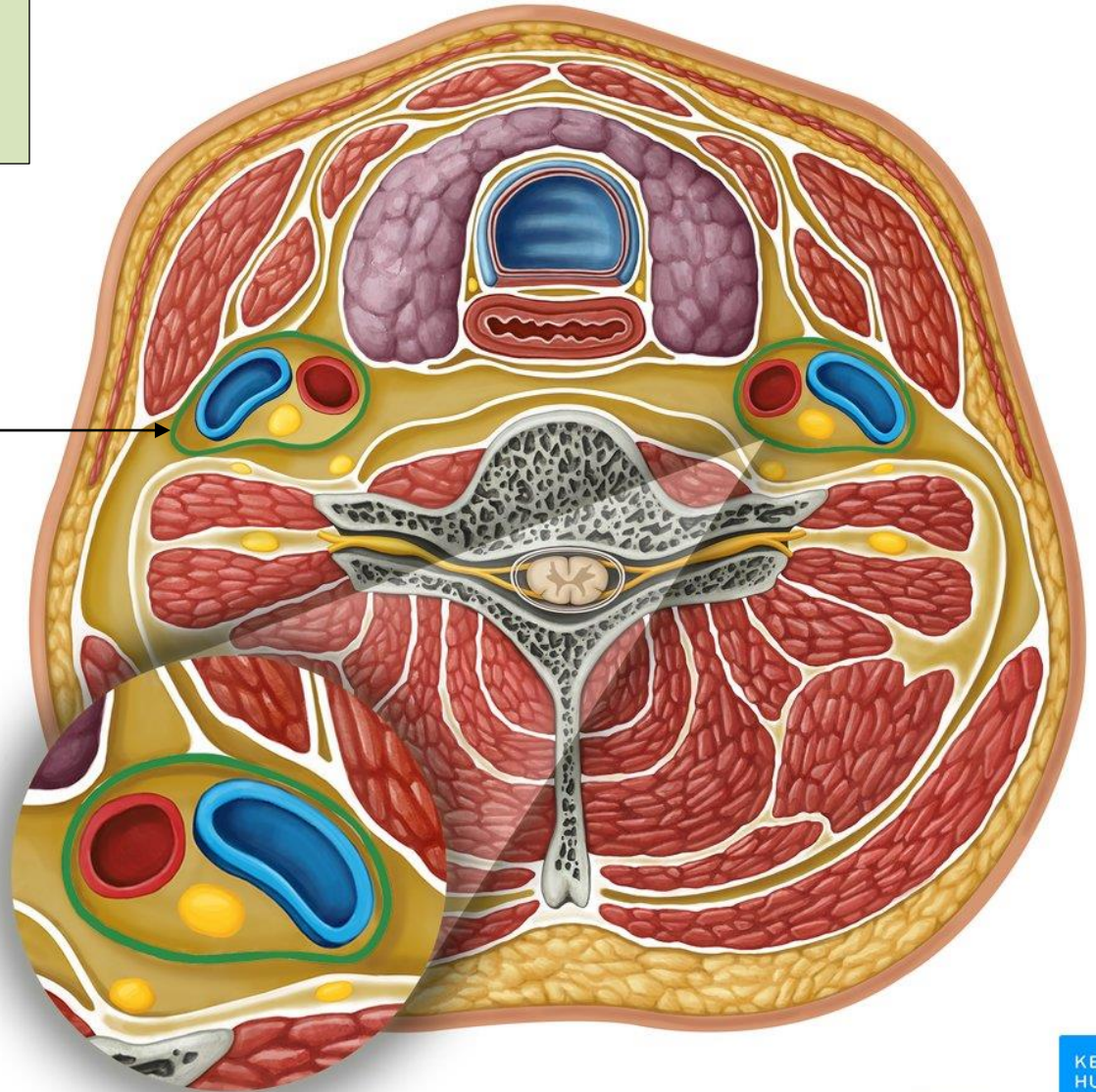


Carotid sheath is a column of fascia (from base of skull to thoracic cavity) that surrounds

- 1- Common carotid artery
- 2- Internal carotid artery
- 3- Internal jugular vein
- 4- Vagus nerve

Carotid sheath

Carotid sheath



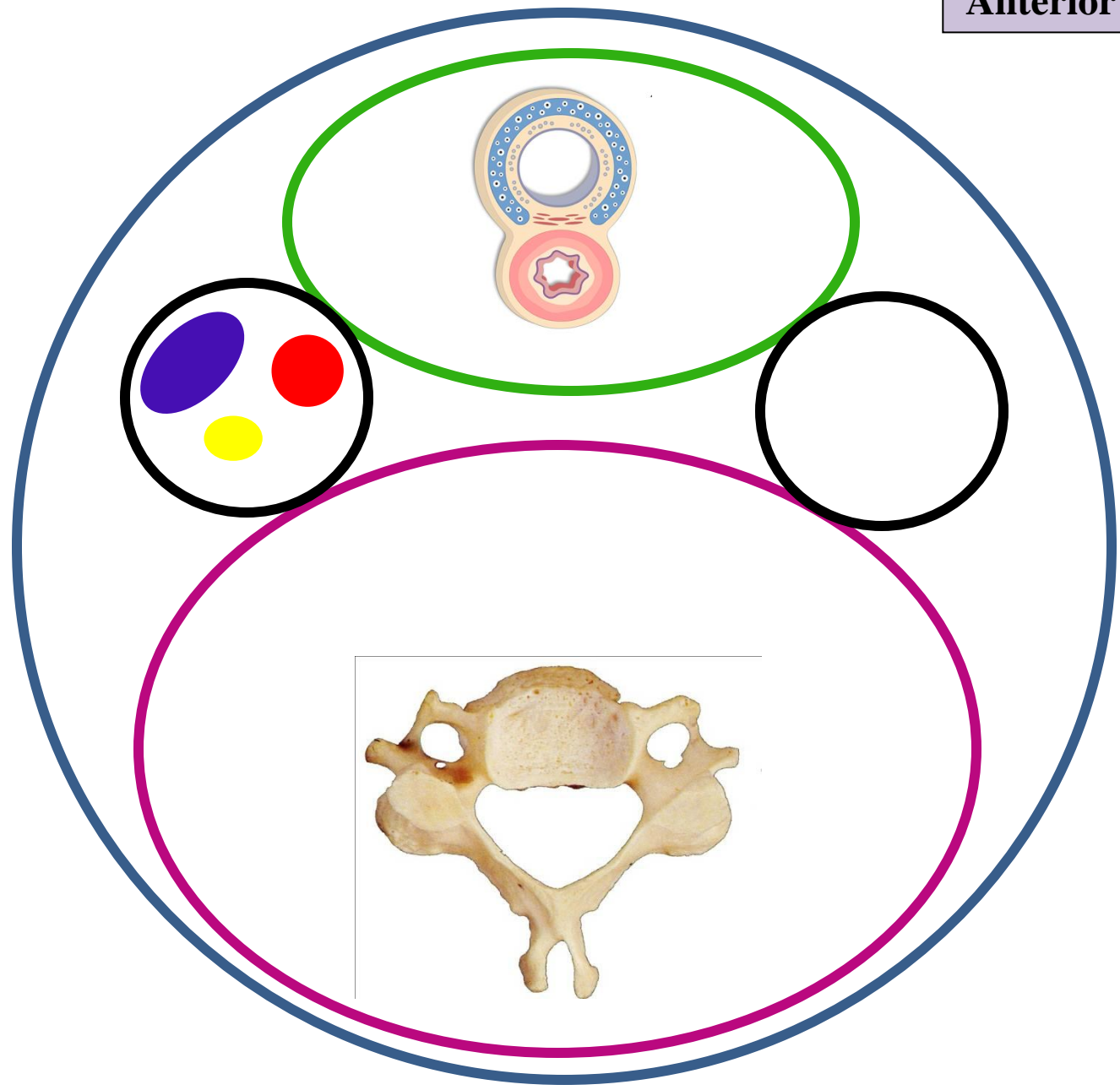
Anterior

Investing fascia

Prevertebral fascia

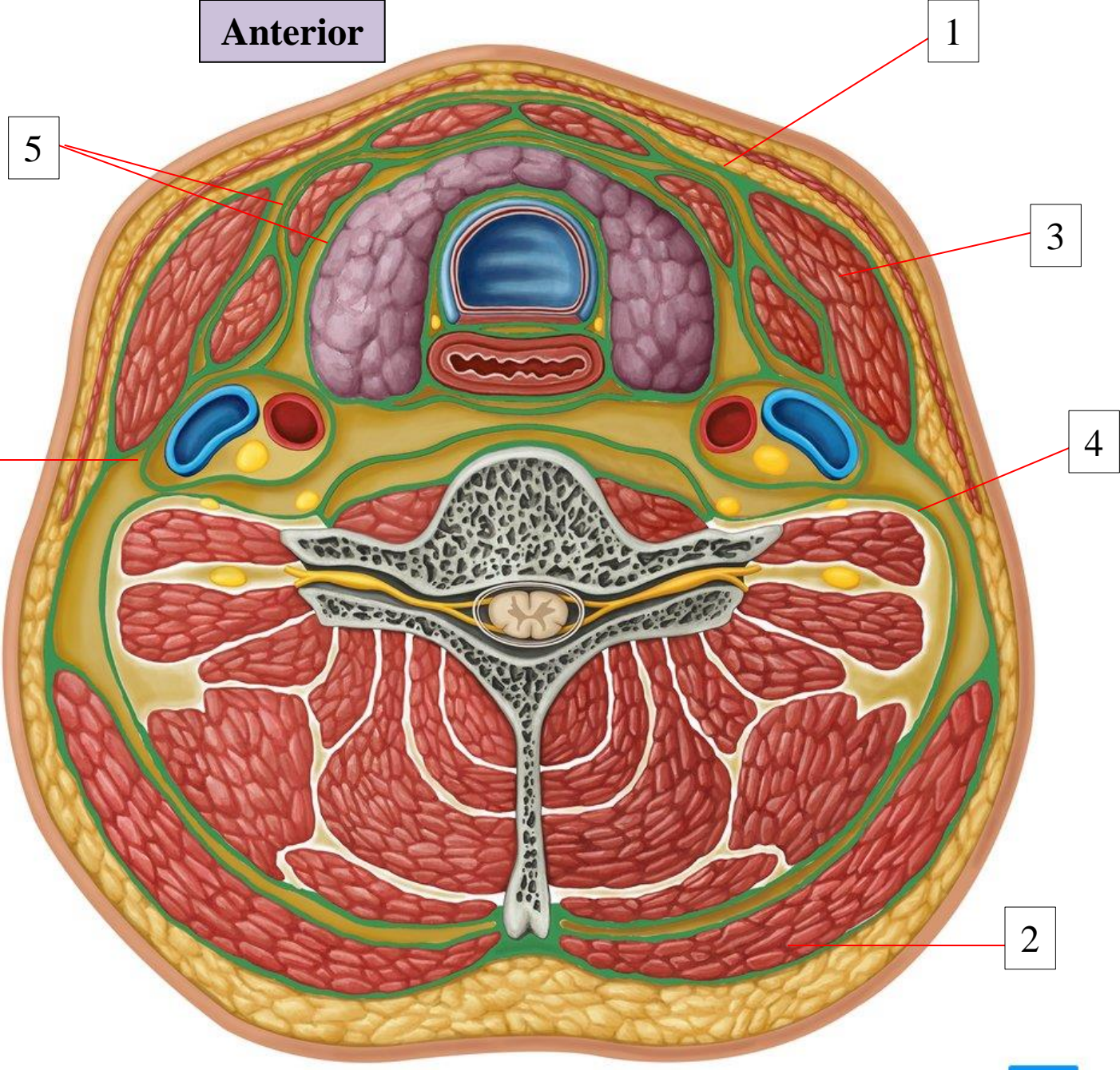
Pretracheal fascia

Carotid sheath



Posterior

Anterior



- 1: Investing layer
- 2: Trapezius
- 3: Sternomastoid
- 4: Prevertebral layer
- 5: Pretracheal layer
- 6: Carotid sheath

Posterior

The investing layer of deep cervical fascia encloses the whole neck

The **investing fascia** can be thought of as a tube; with superior, inferior, anterior and posterior attachments:

Superiorly (from backwards to forwards):

External occipital protuberance and Superior nuchal line

Mastoid process

External acoustic meatus

Lower border of body of mandible from the angle of mandible to the symphysis menti

Inferiorly (from backwards to forwards):

Spinous process of C7

Spine and acromion of scapula

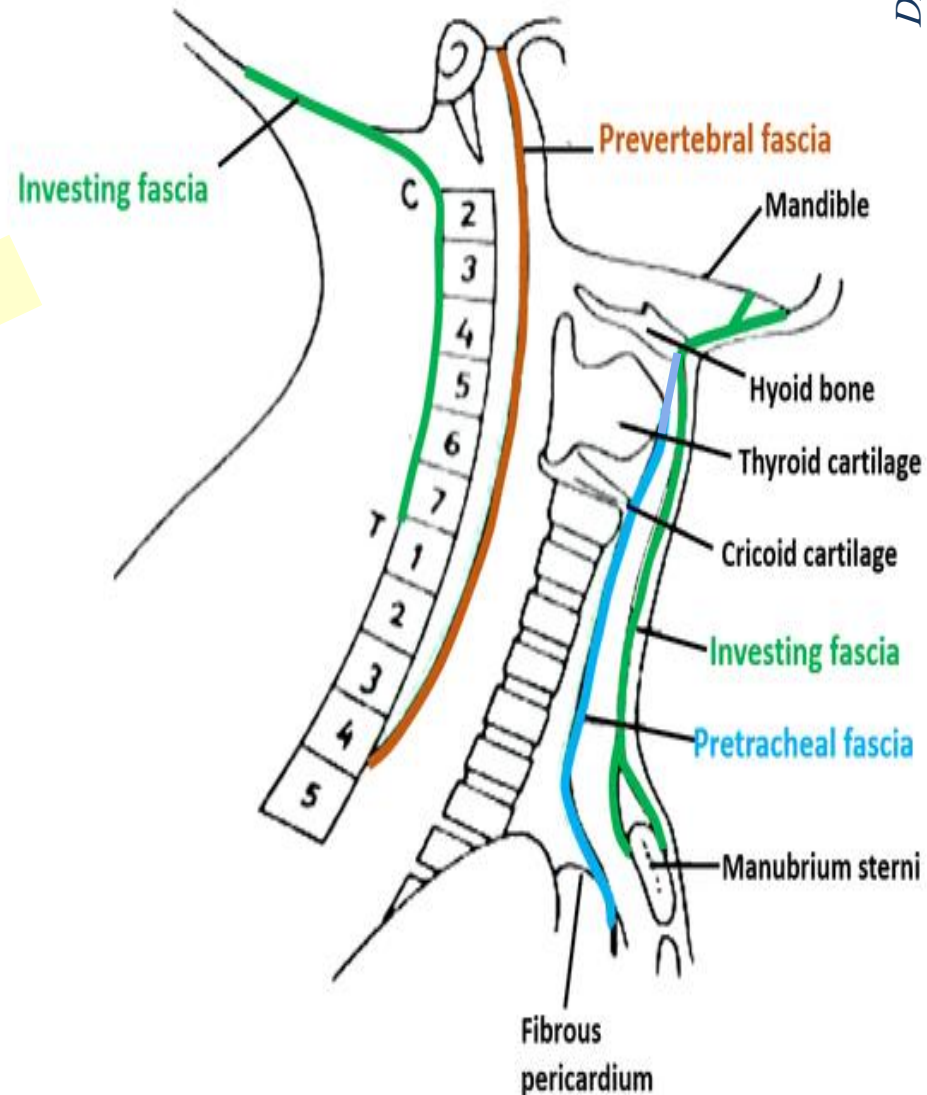
Clavicle

Suprasternal notch

Posteriorly: attaches along the nuchal ligament of the vertebral column

Anteriorly: attaches to the hyoid bone

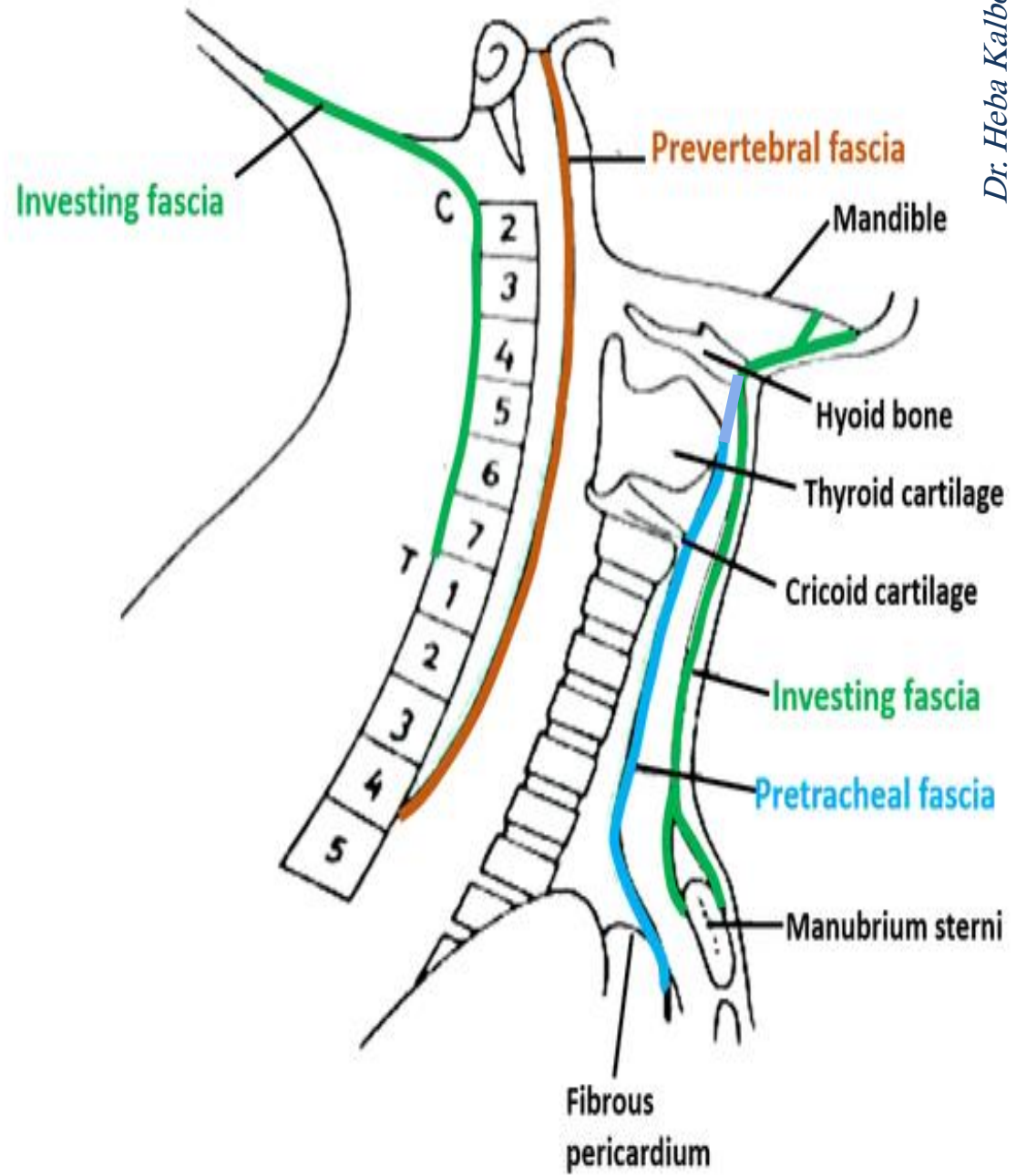
Read only 😊



The **pretracheal layer** spans between the hyoid bone superiorly and the superior mediastinum inferiorly (where it fuses with the pericardium).

Read only 😊

The **prevertebral layer** is fixed above to the base of the skull, and below to the body of the fourth thoracic vertebra (it extends behind the esophagus into the posterior mediastinum)



“An important function of the cervical fascia is to limit the spread of infection (for example, a superficial skin abscess may be prevented from spreading deeper into the neck by the investing fascia).

However, a potential pathway for spread of infection exists...”

Between the fascial layers in the neck are spaces that may provide a conduit for the spread of infections from the neck to the mediastinum

- 1- Pretracheal space
- 2- Retropharyngeal space (located between the buccopharyngeal fascia (posterior aspect of the visceral pretracheal fascia) and the prevertebral fascia)
- 3- Space within prevertebral layer

Note that the pretracheal and prevertebral layers continue inferiorly into the thoracic cavity

The infection tends to spread within compartments or within the spaces between the fascial layers



If infection arises in the pretracheal space, it may spread inferiorly into the superior mediastinum and lie anterior to the pericardium

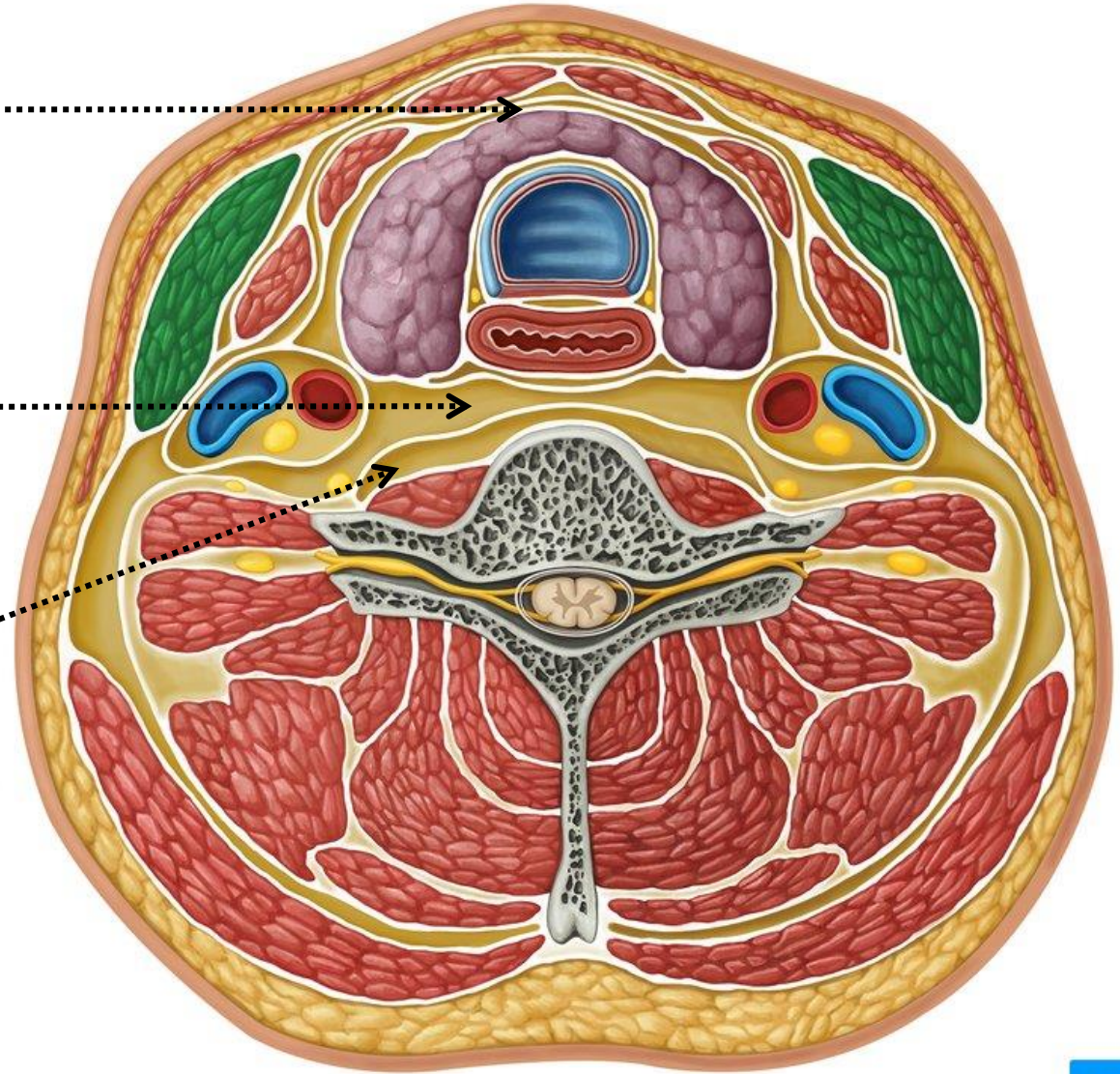
The fascial spaces:

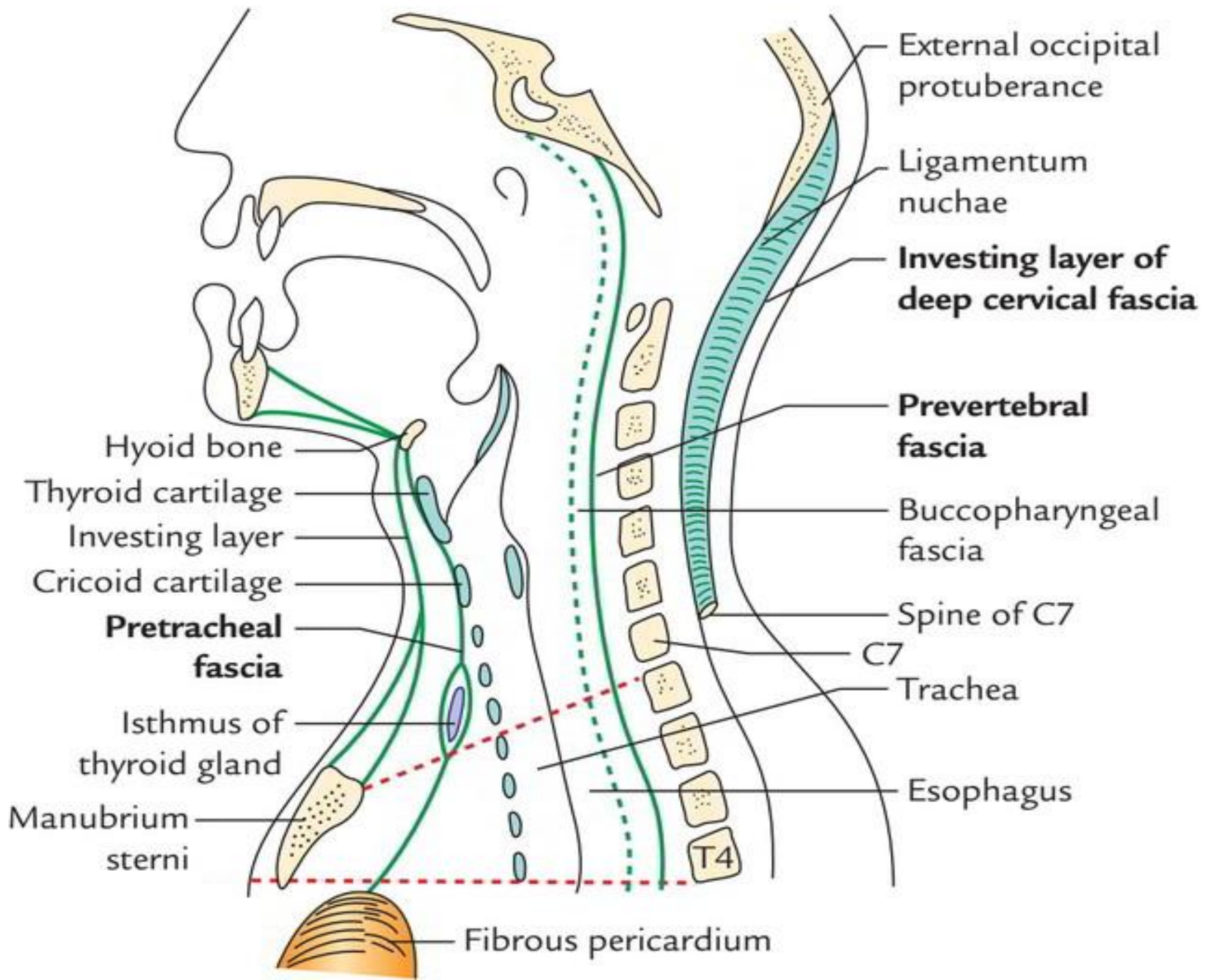
- They are potential spaces that consist largely of fatty areolar tissue and lymph nodes
- These spaces can provide a conduit for the spread of infections from the neck to the mediastinum

Pretracheal space

Retropharyngeal space

Space within prevertebral layer

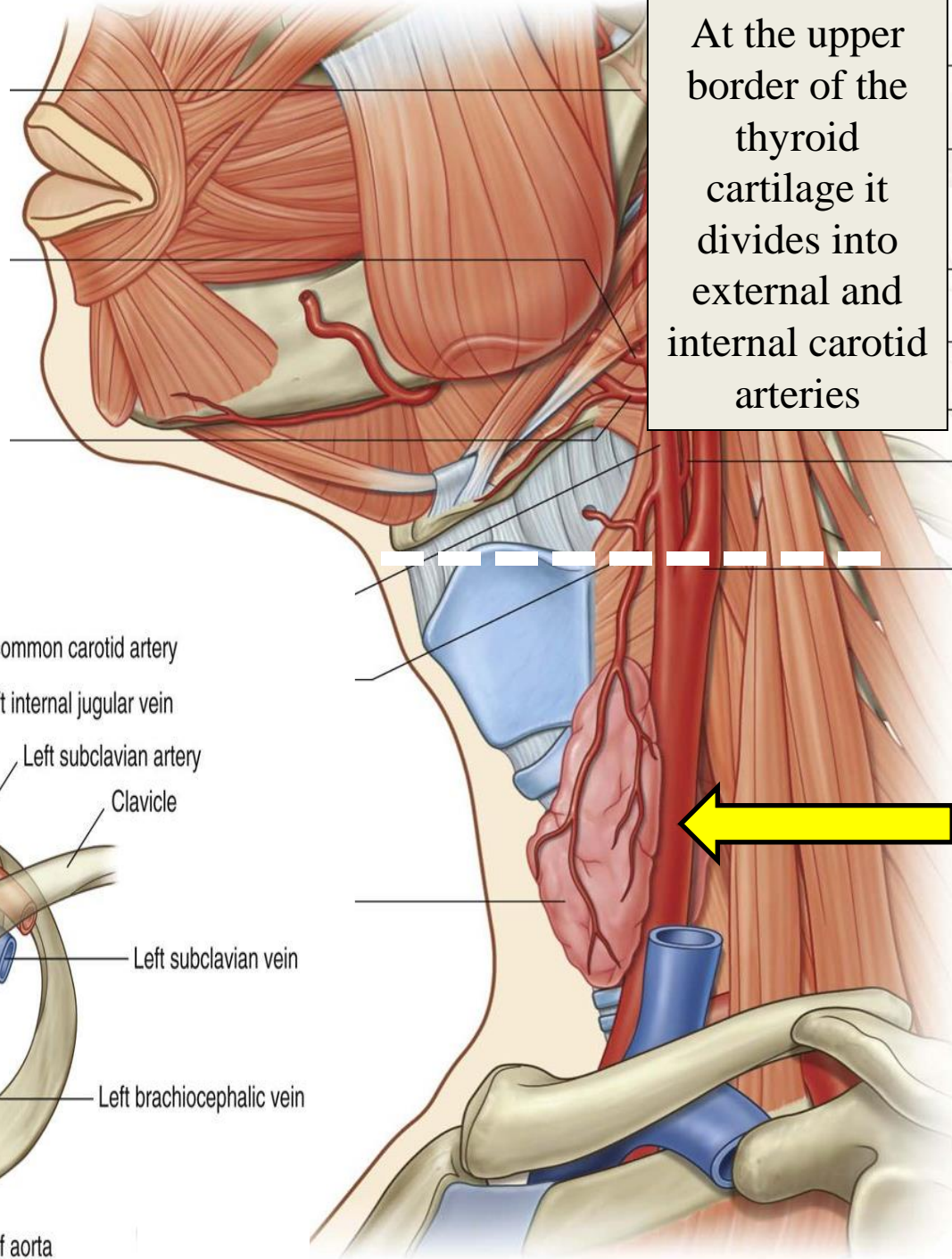




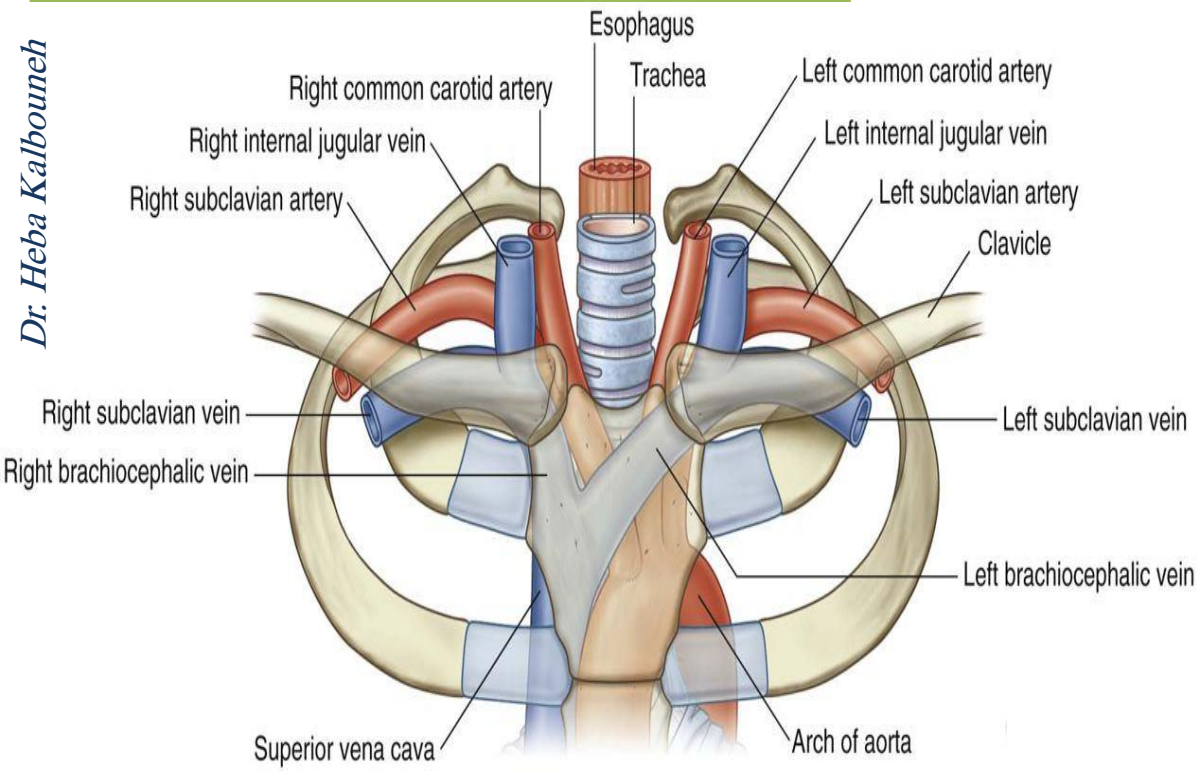
Common Carotid Artery

- Right common carotid artery arises from brachiocephalic artery behind the right sternoclavicular joint
- Left common carotid artery arises from arch of aorta in superior mediastinum
- The common carotid artery runs upward through the neck under cover of sternocleidomastoid

At the upper border of the thyroid cartilage it divides into external and internal carotid arteries

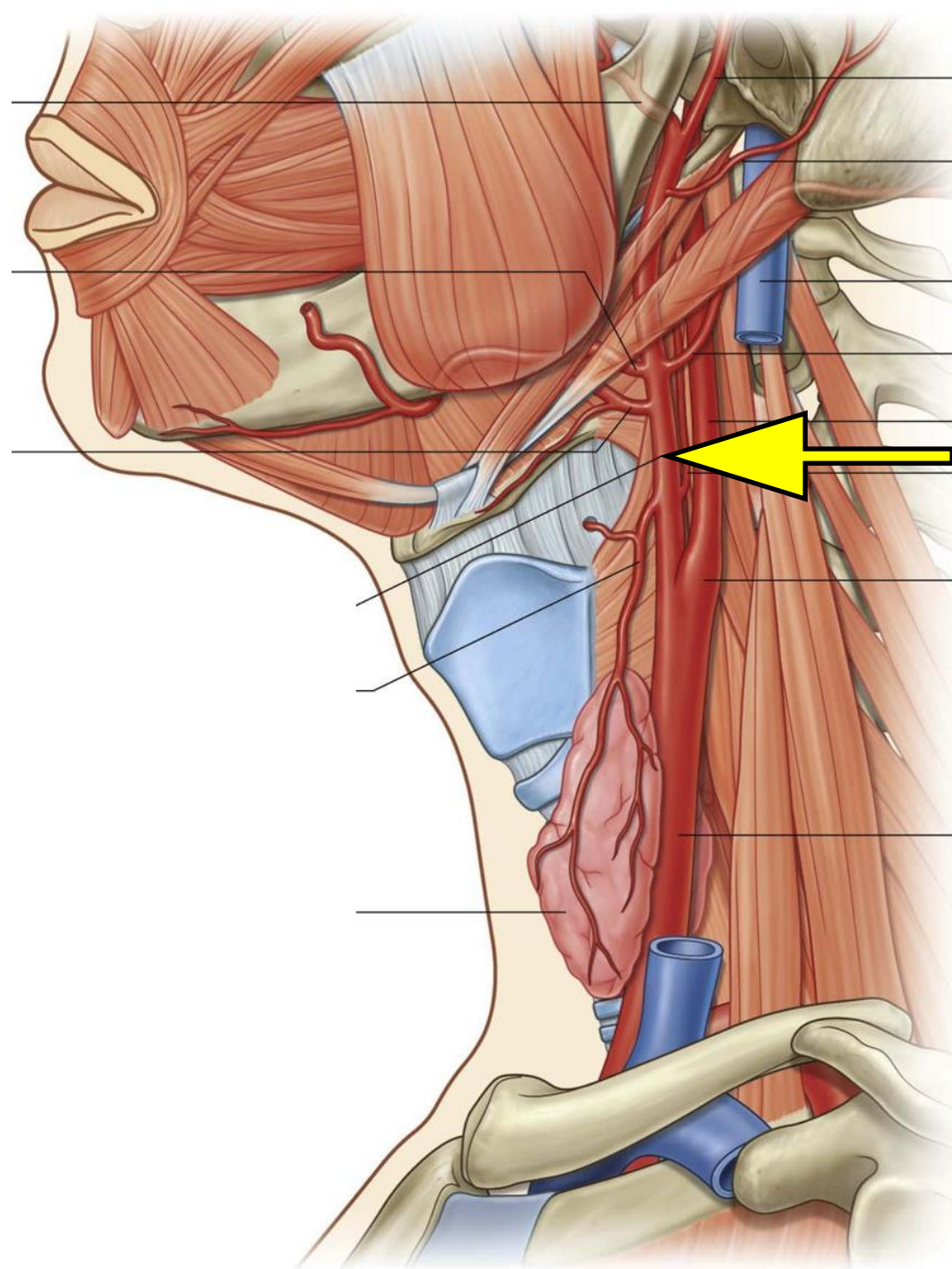


Dr. Heba Kalbouneh



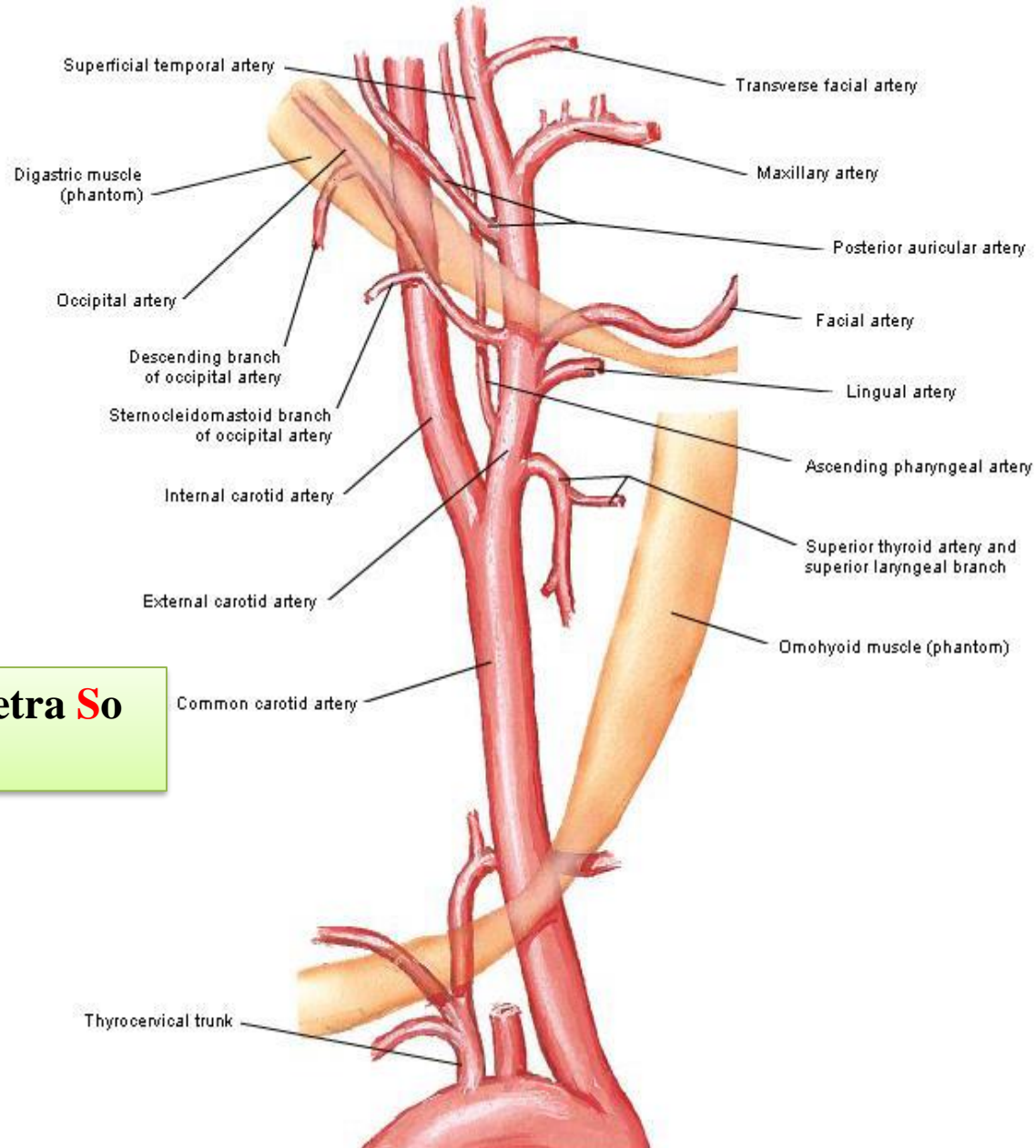
External Carotid Artery

- Is one of the terminal branches of the common carotid artery
- Supplies structures in the neck, Face, scalp, tongue and the maxilla
- It **lies outside the carotid sheath**
- Begins at the level of the upper border of the thyroid cartilage
- Terminates in the substance of the parotid gland behind the neck of the mandible by dividing into the **superficial temporal and maxillary arteries**

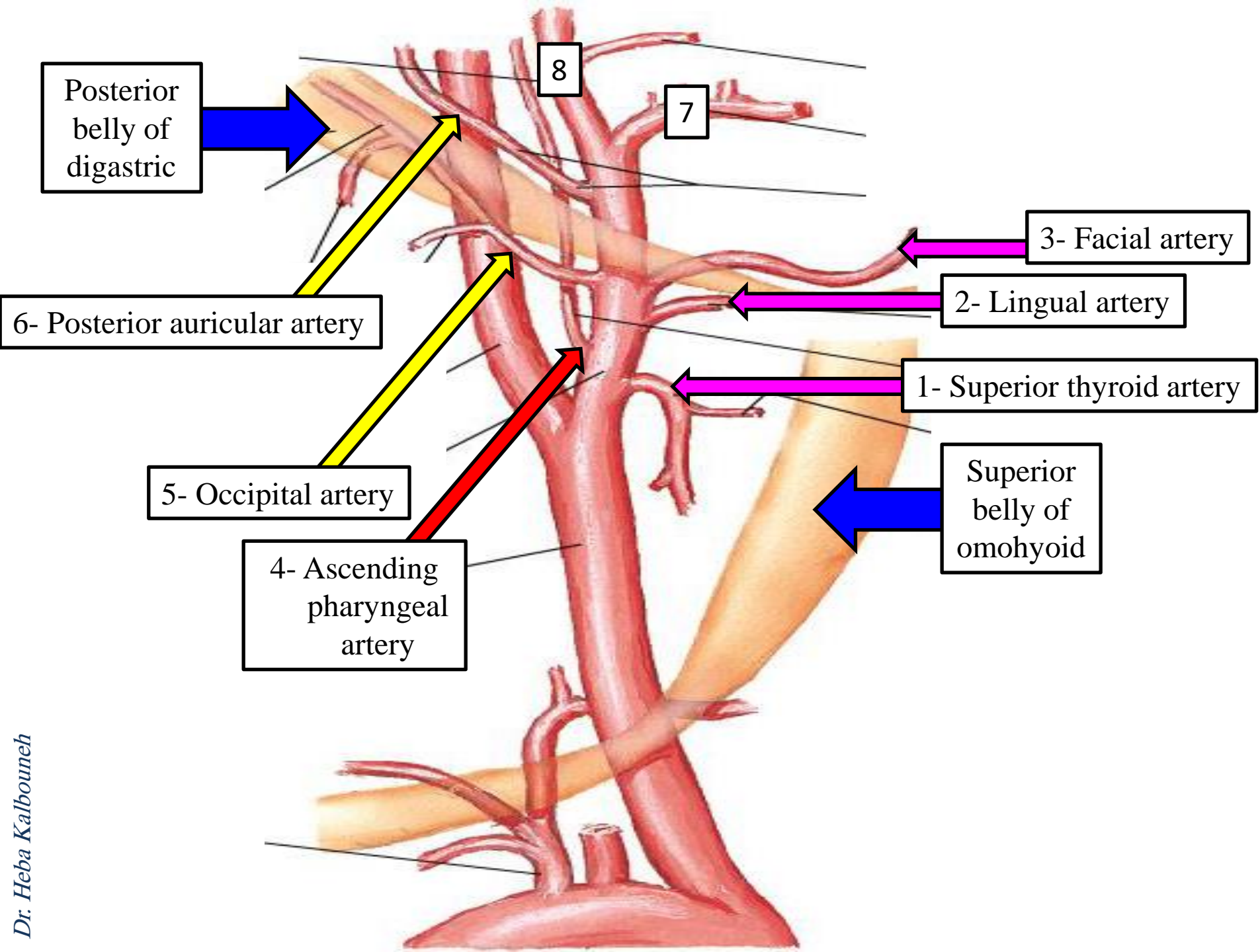


Branches of External Carotid Artery

1. Superior thyroid artery
2. Ascending pharyngeal artery
3. Lingual artery
4. Facial artery
5. Occipital artery
6. Posterior auricular artery
7. Maxillary artery
8. Superficial temporal artery



Some American Ladies Find Our Petra So Magnificent



Maxillary artery

Superficial temporal artery

Posterior auricular artery

Internal jugular vein

Occipital artery

Internal carotid artery

Ascending pharyngeal artery

Carotid sinus

Common carotid artery

Facial artery

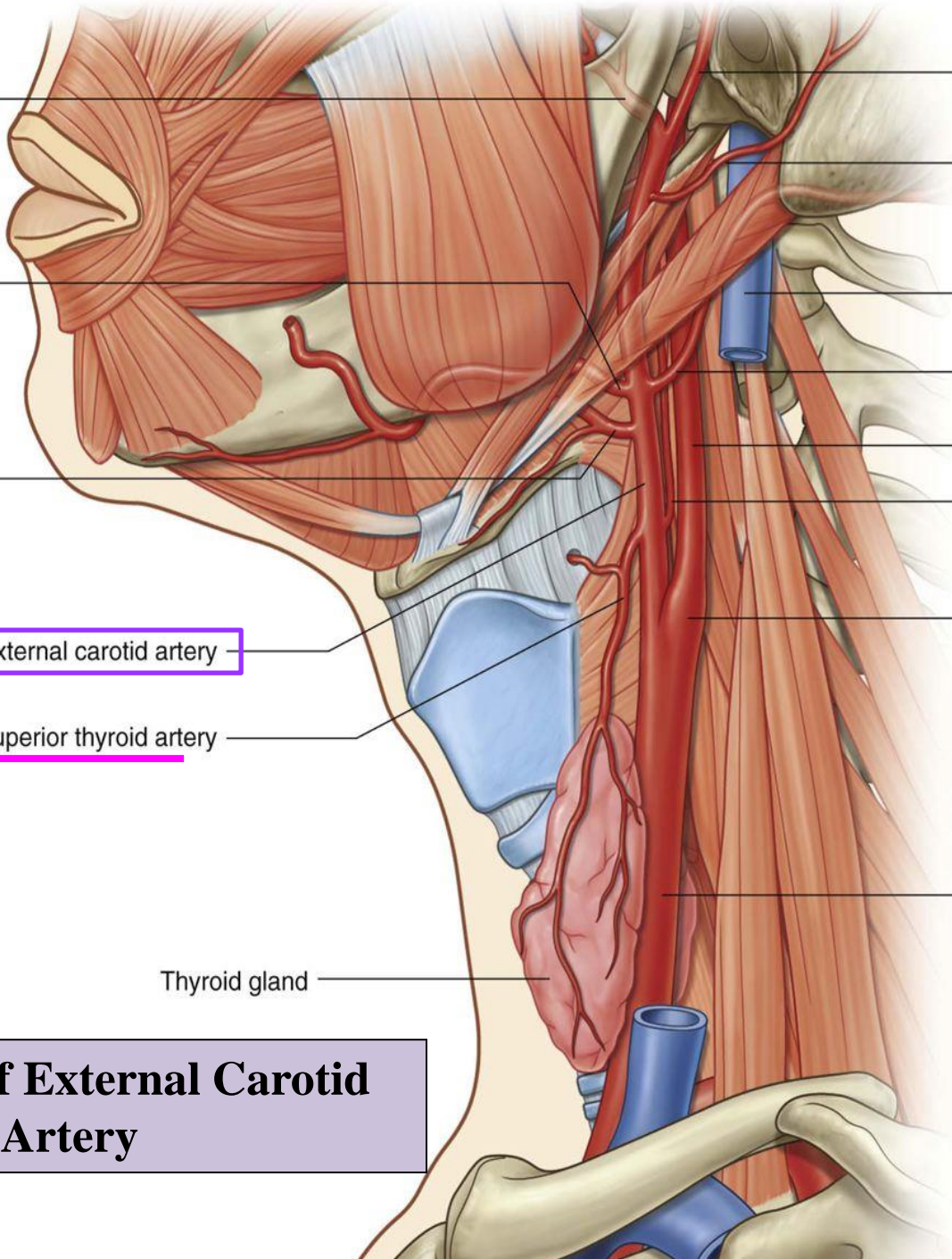
Lingual artery

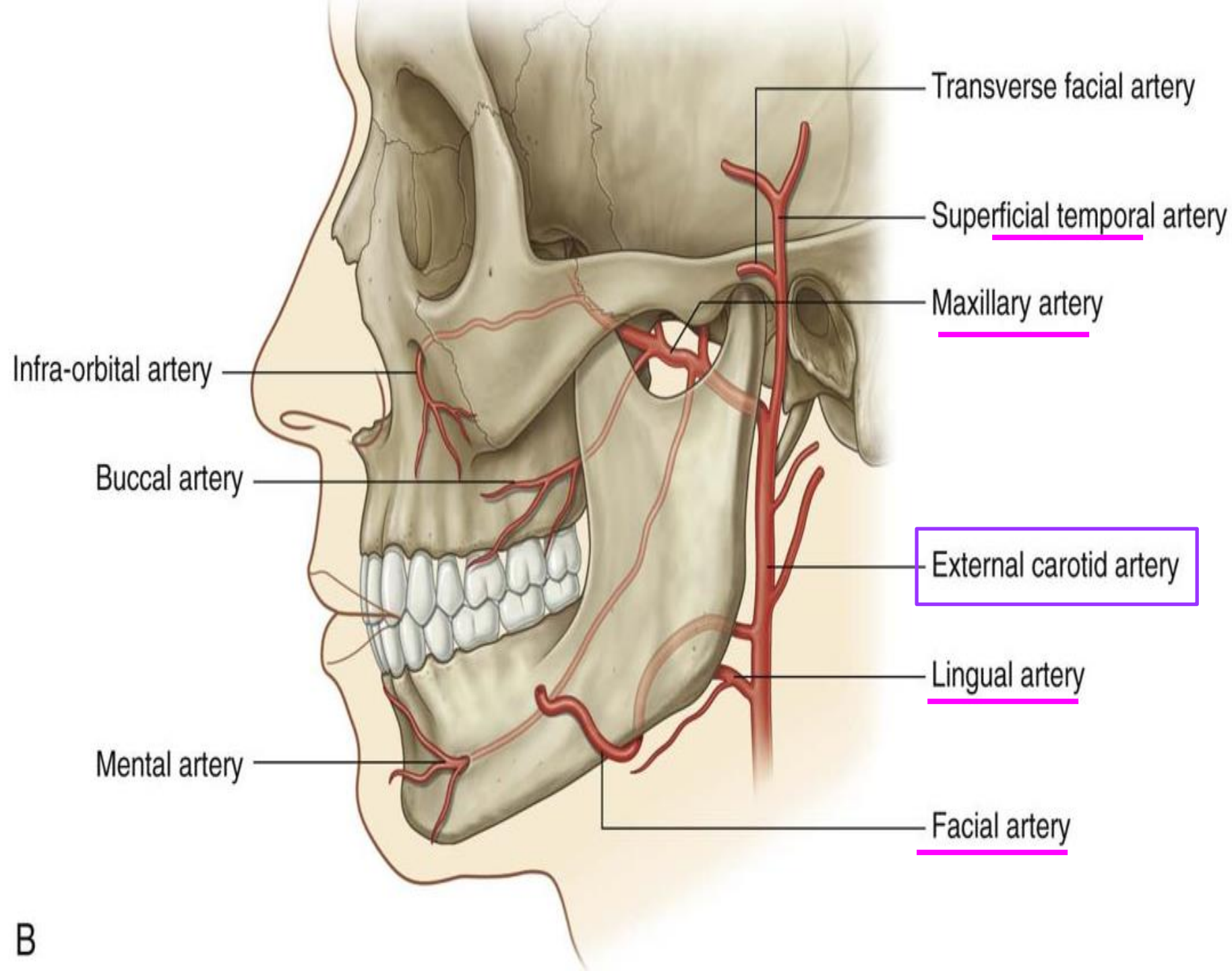
External carotid artery

Superior thyroid artery

Thyroid gland

Branches of External Carotid Artery

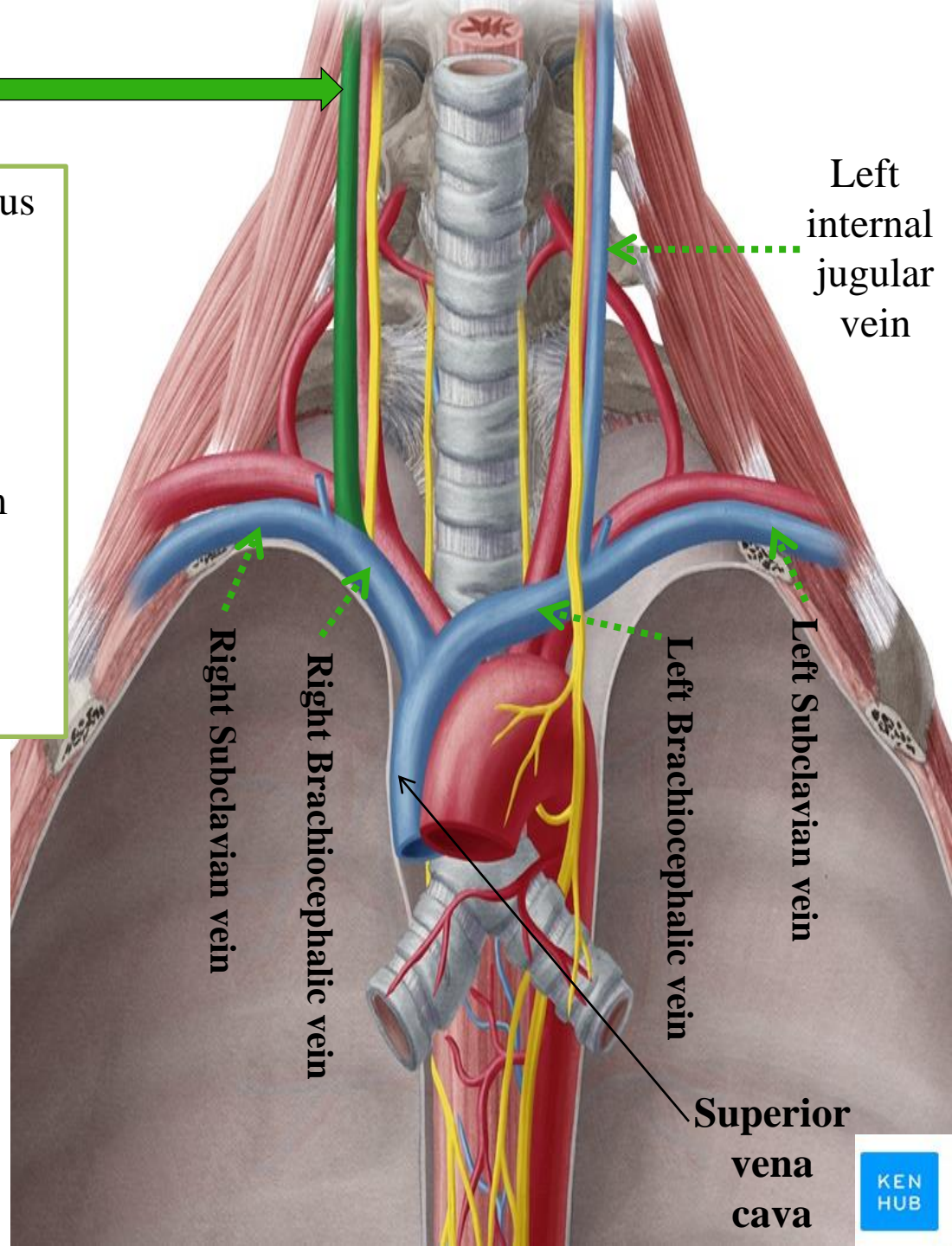




Internal jugular vein

- Starts as a continuation of sigmoid sinus
- Leaves the skull through jugular foramen
- Descends through the neck **in carotid sheath**
- Ends by joining the subclavian vein behind the medial end of clavicle to form brachiocephalic vein
- Has a dilatation at its upper end called the superior bulb and another near its termination called the inferior bulb

A central venous catheter (central line) is a catheter placed into a large vein. Catheters can be placed in internal jugular vein



The internal jugular vein is closely related to the deep cervical lymph nodes

