

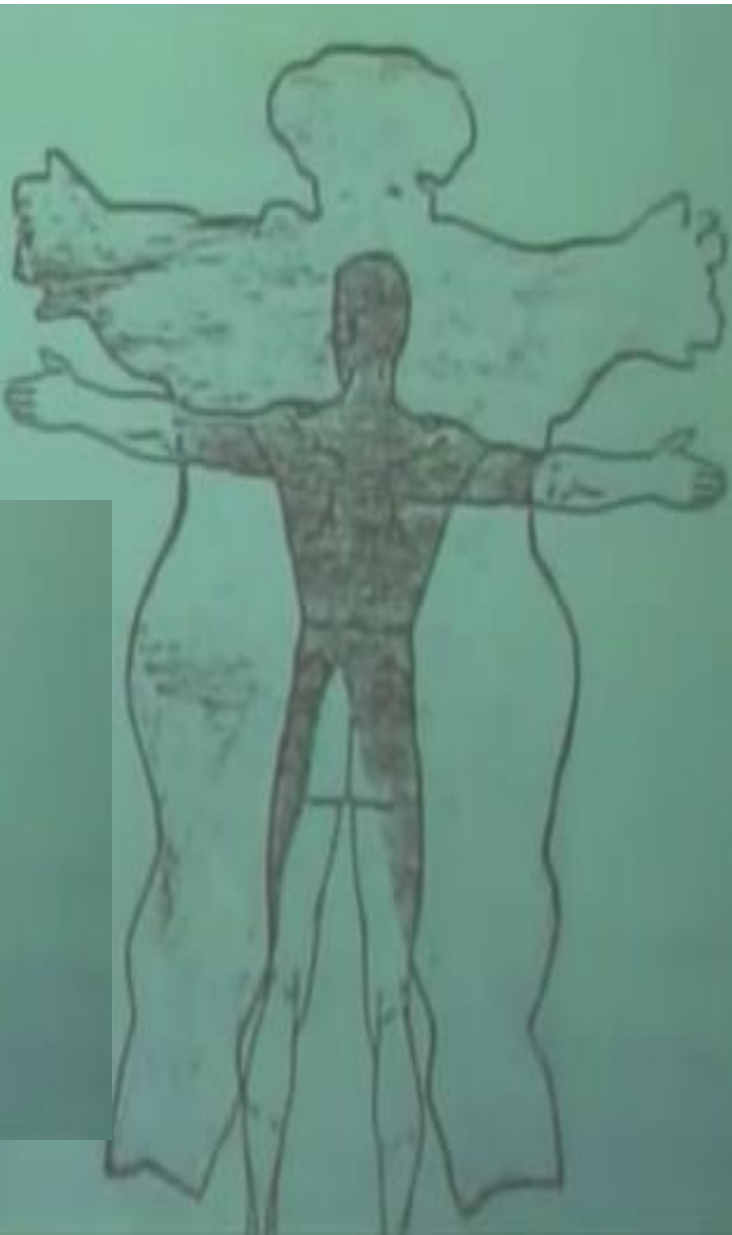


Skin Histology

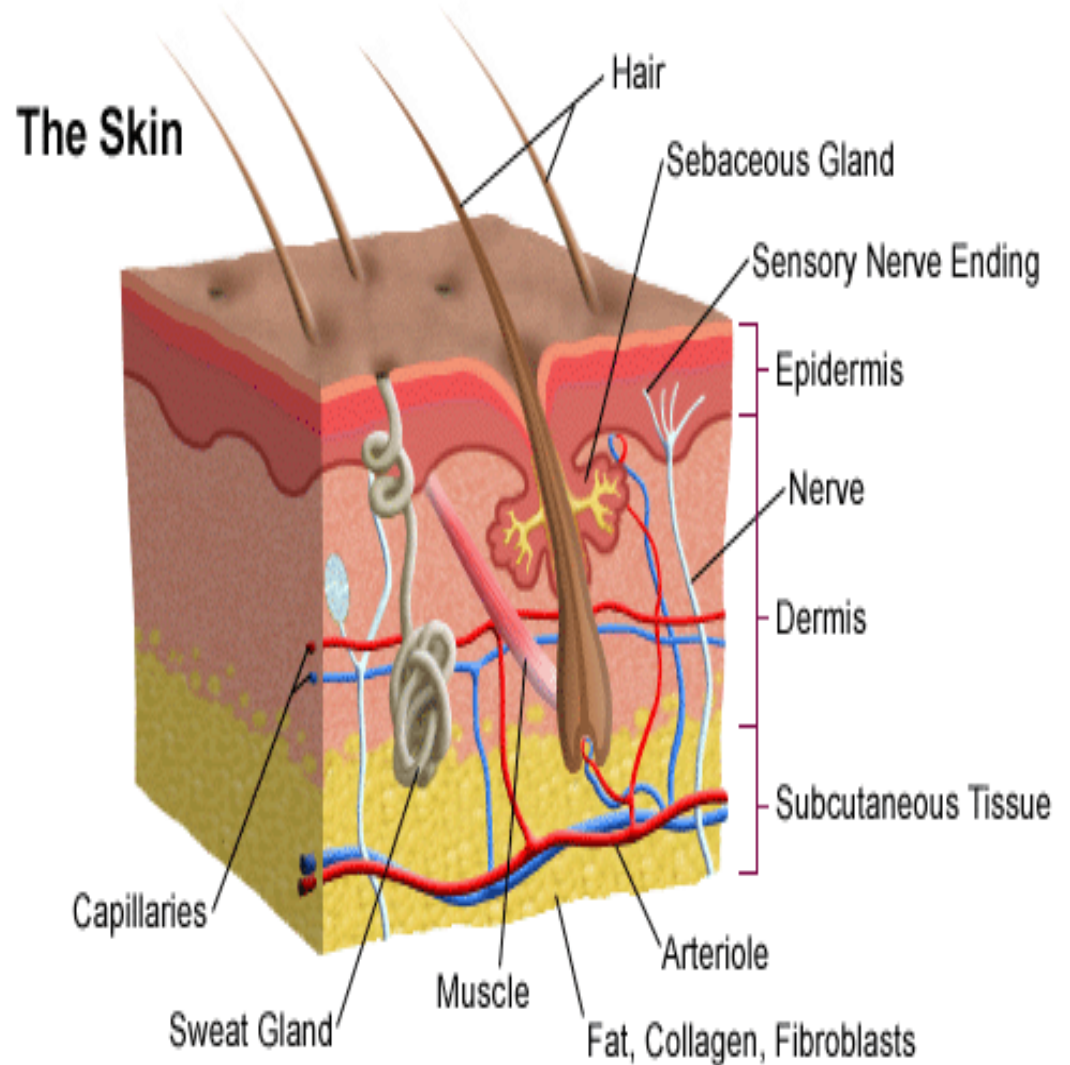
Dr. Heba Kalbouneh

Associate Professor of Anatomy and Histology

Integumentary system

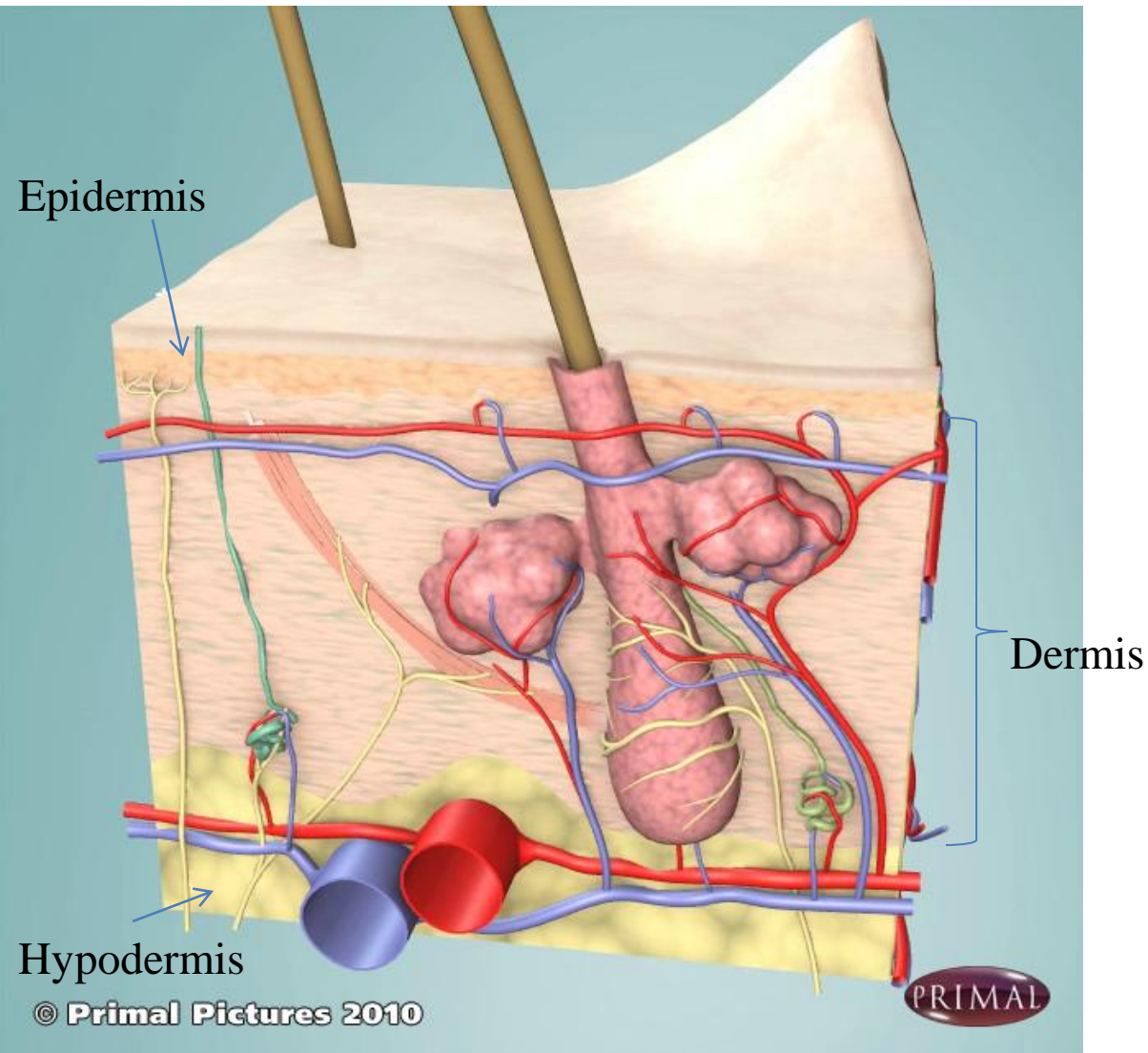


The skin is considered the largest organ of the body



Basic Skin Histology

The skin is composed of two layers: the outer epidermis and the deeper dermis
Rests on the hypodermis.

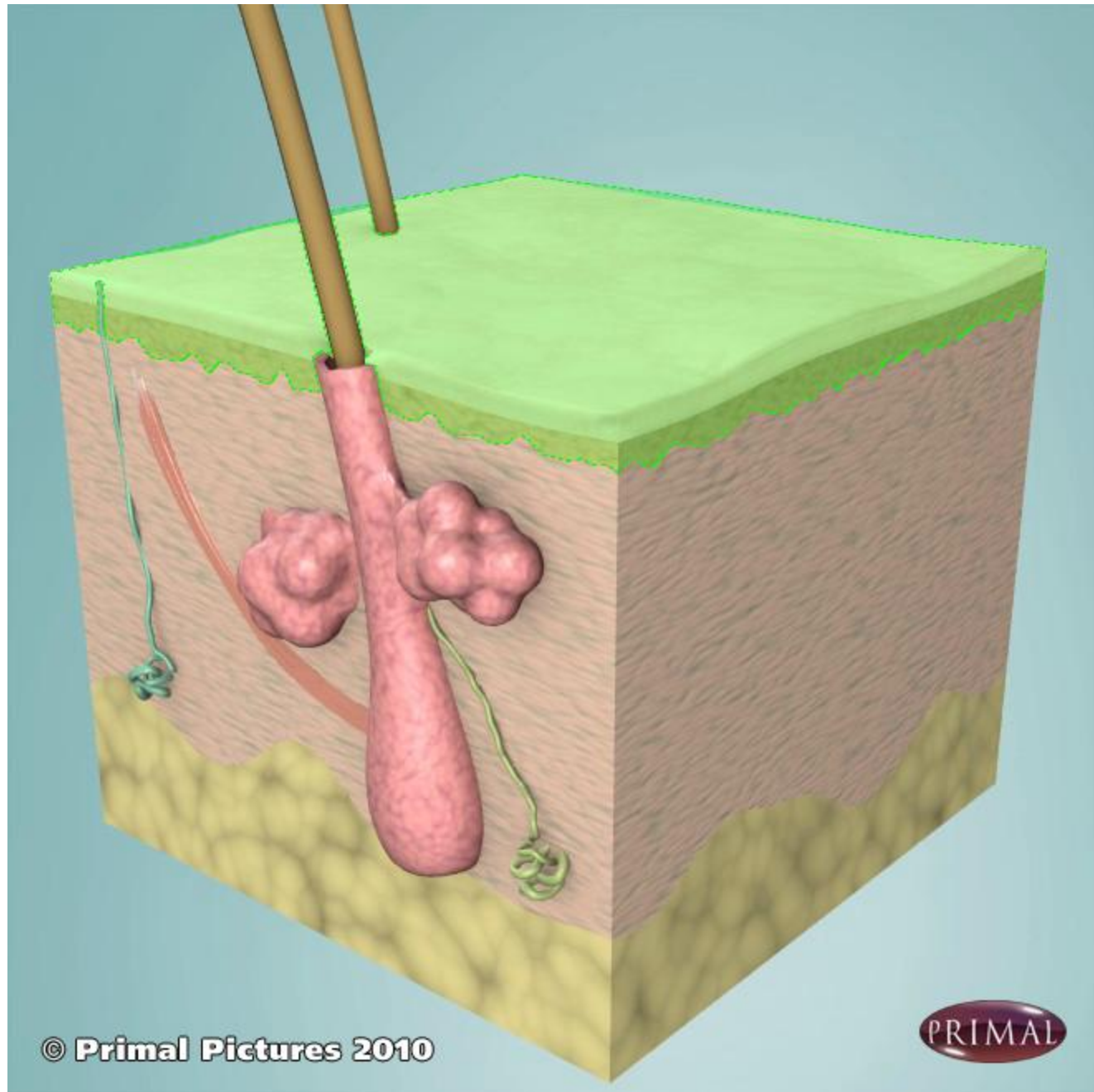


*Skin is an important
subject to know no matter
what clinical field you
want get into*

Dr. Heba Kalbouneh

- Major Skin Functions
- Protection
 - Sensory Perception
 - Temperature Regulation
 - Excretion
 - Formation of Vitamin D

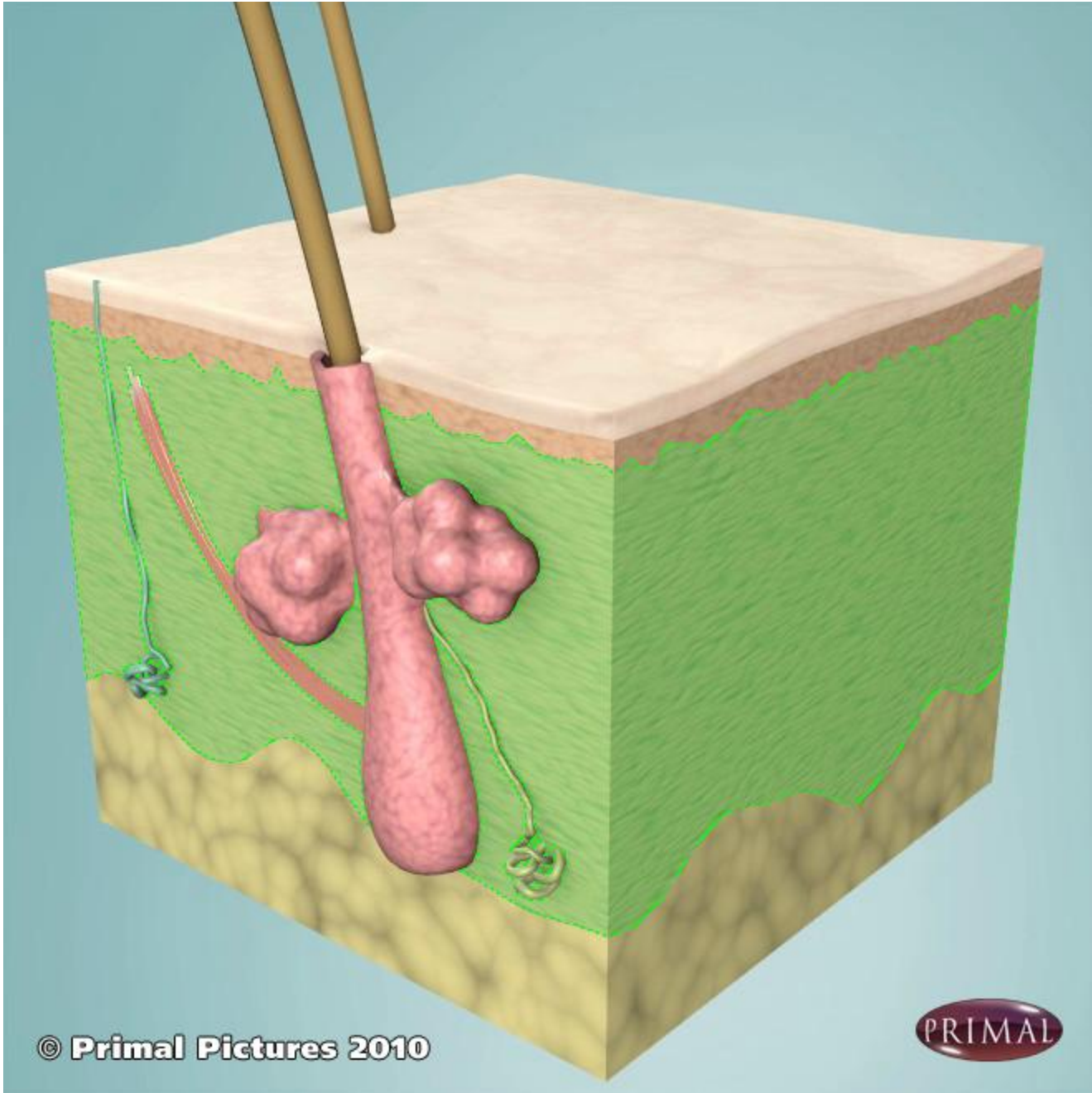
Epidermis



© Primal Pictures 2010



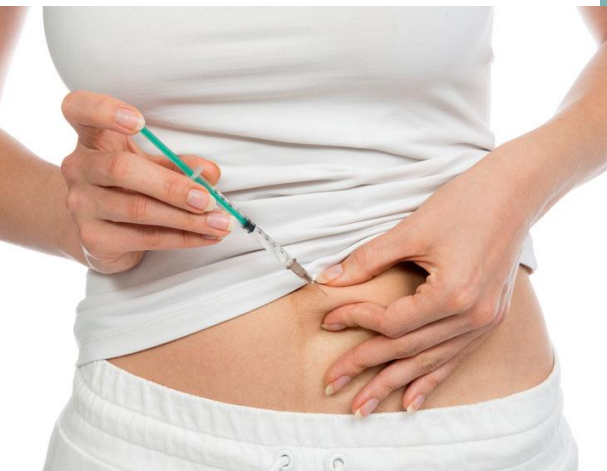Dermis



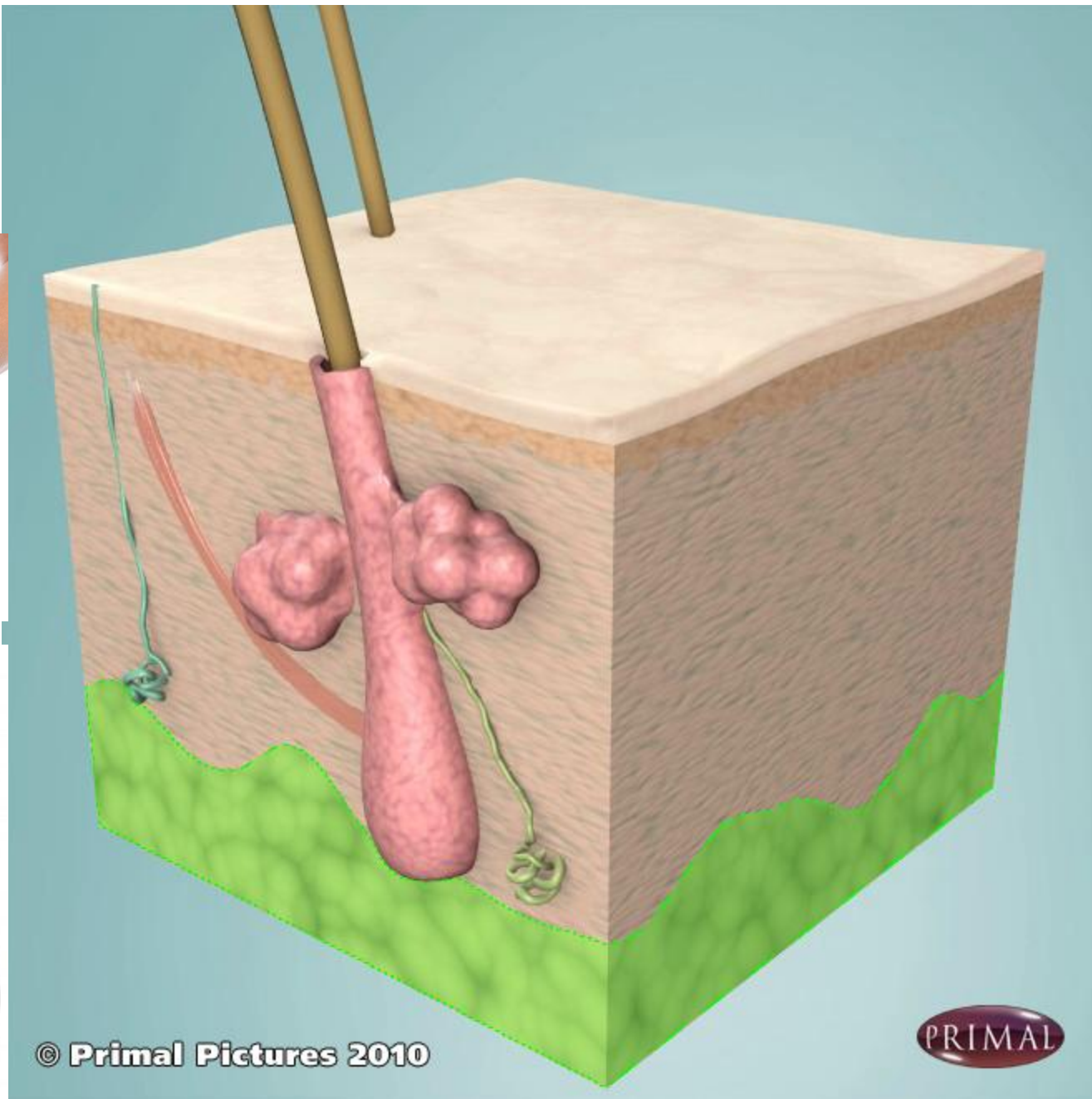
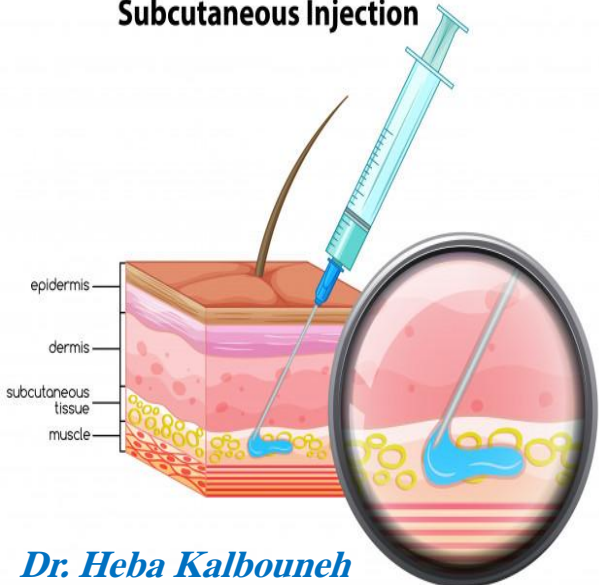
© Primal Pictures 2010



Hypodermis
Superficial fascia
Subcutaneous tissue
Subdermal fat



Subcutaneous Injection



© Primal Pictures 2010



The **dermal papillae** are nipple-like extensions of the dermis into the epidermis

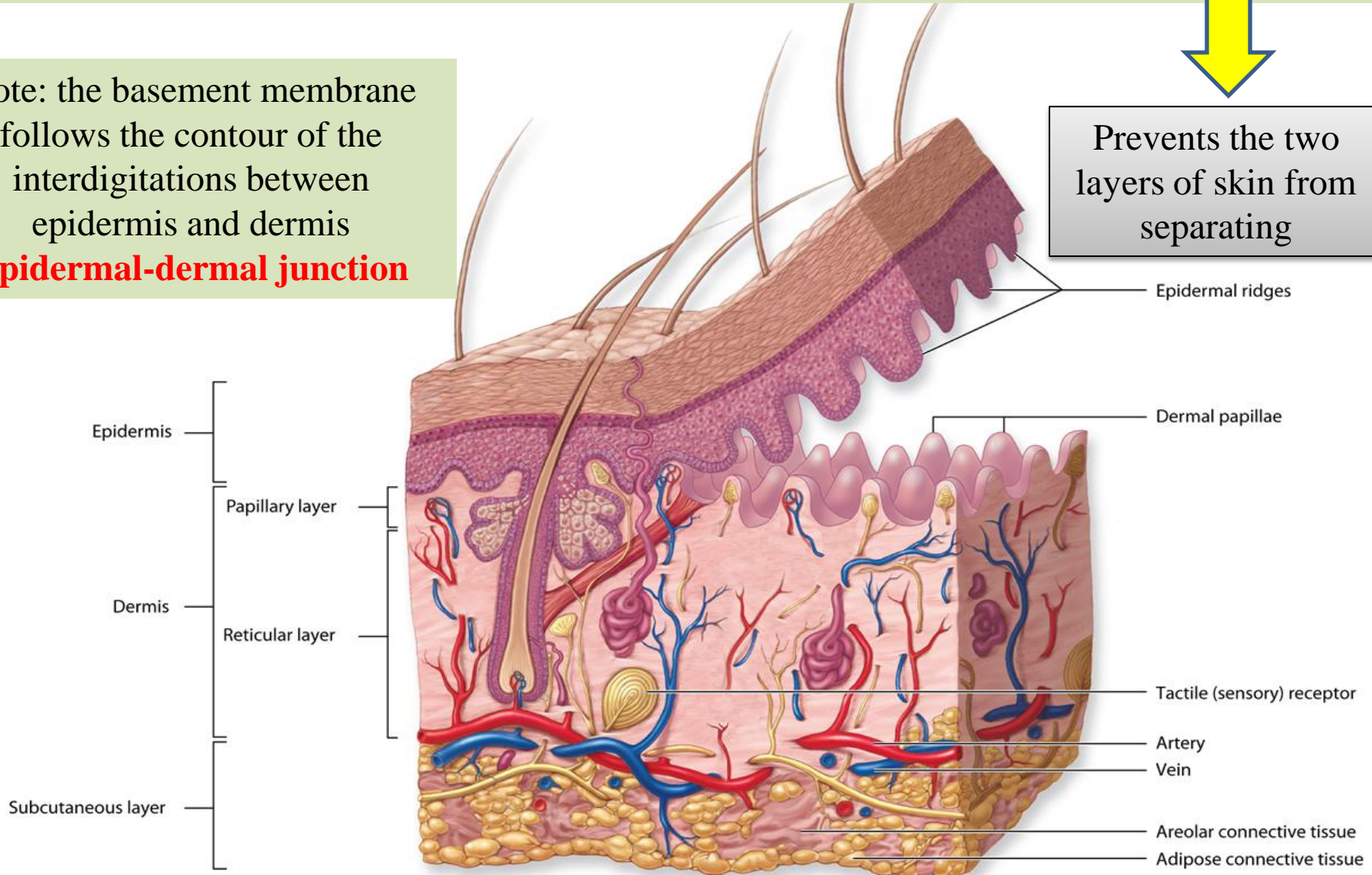
The epidermis conforms to the contours of the underlying dermal papillae forming **epidermal ridges**

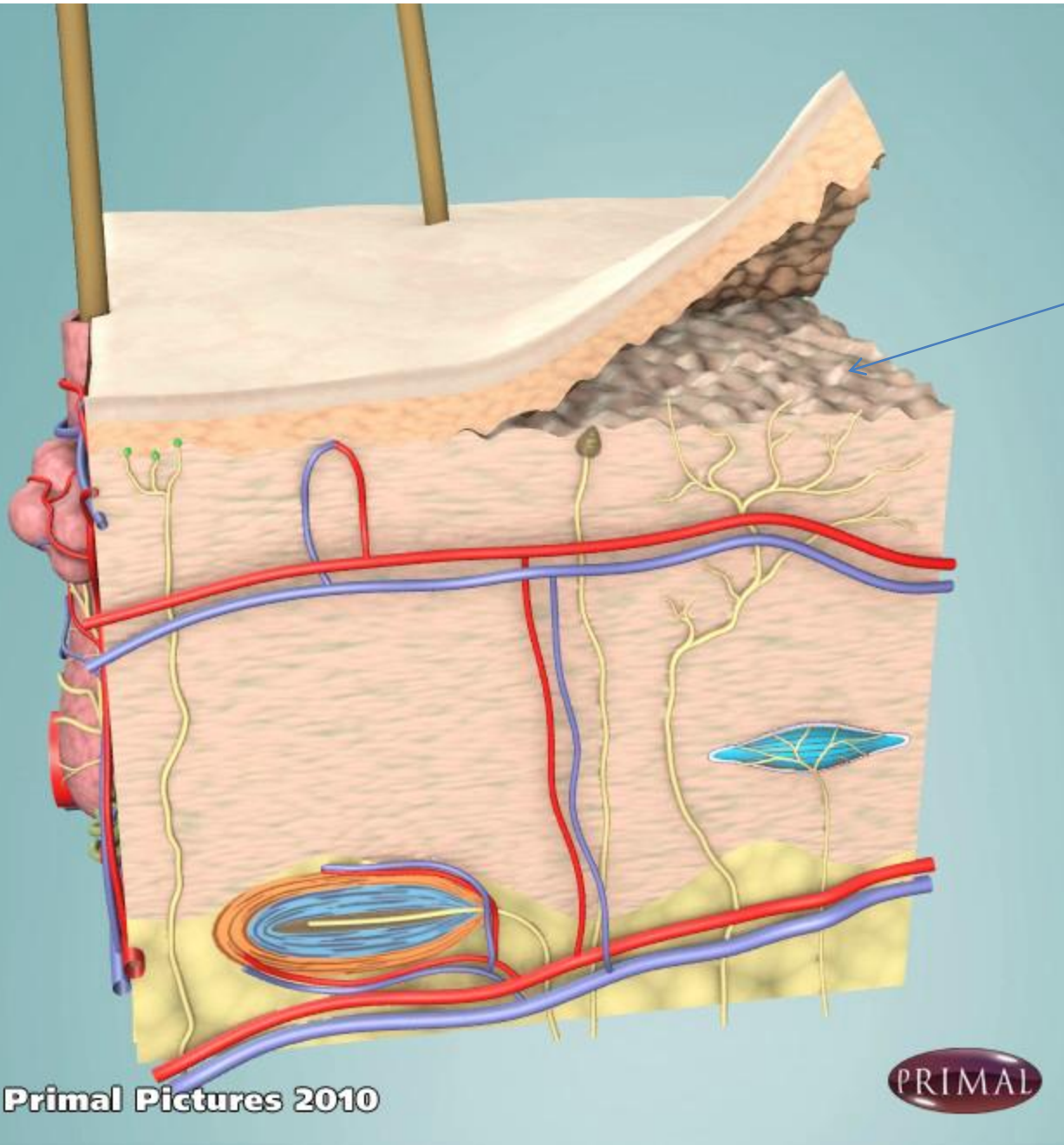
Note: the basement membrane follows the contour of the interdigitations between epidermis and dermis

Epidermal-dermal junction



Prevents the two layers of skin from separating





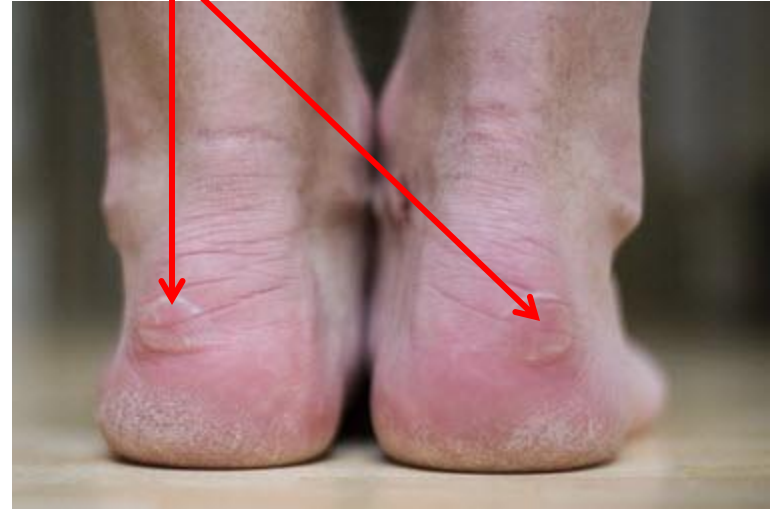Epidermal-dermal junction

More prominent in palms and soles

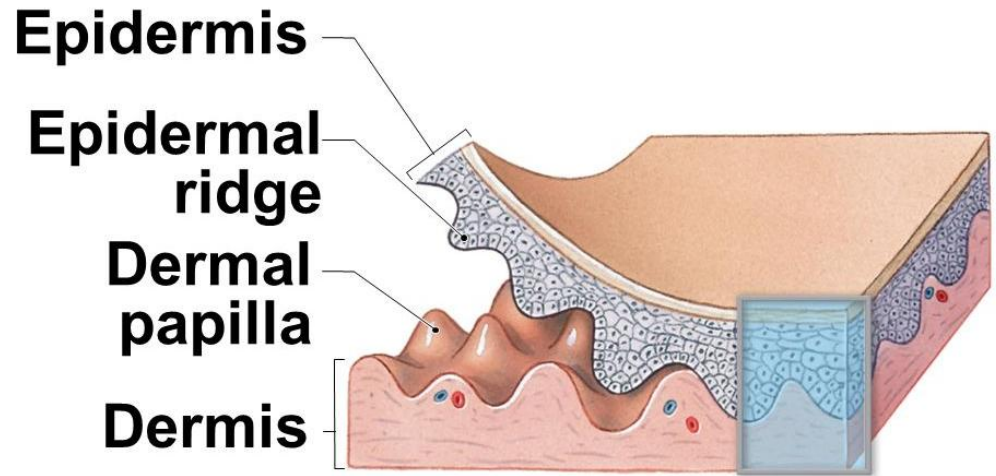
These interdigitations form distinctive patterns unique for each individual (fingerprints and footprints)



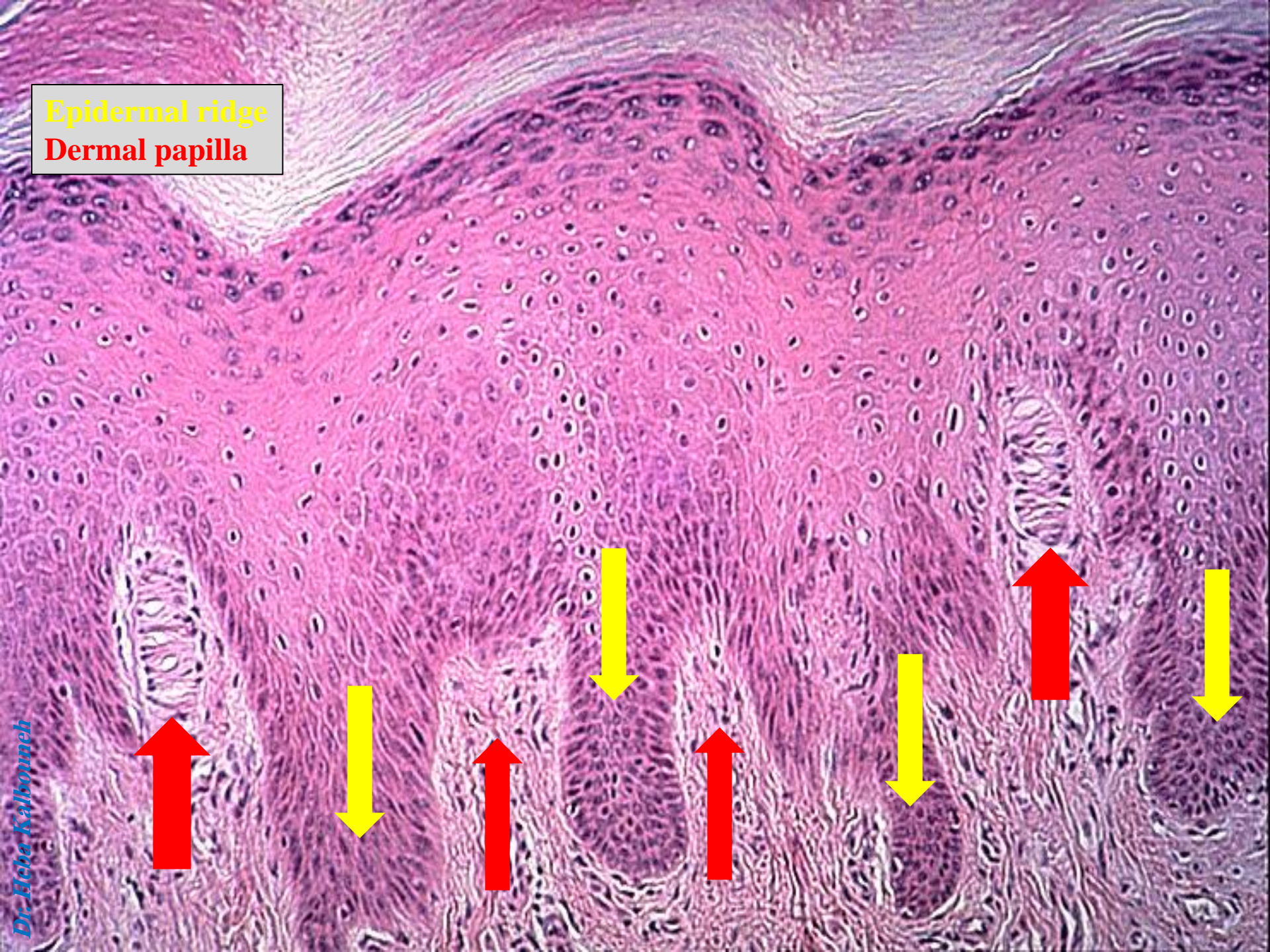
Blisters



These interdigitations are called **friction ridges** For grasping with our hands And for walking barefoot

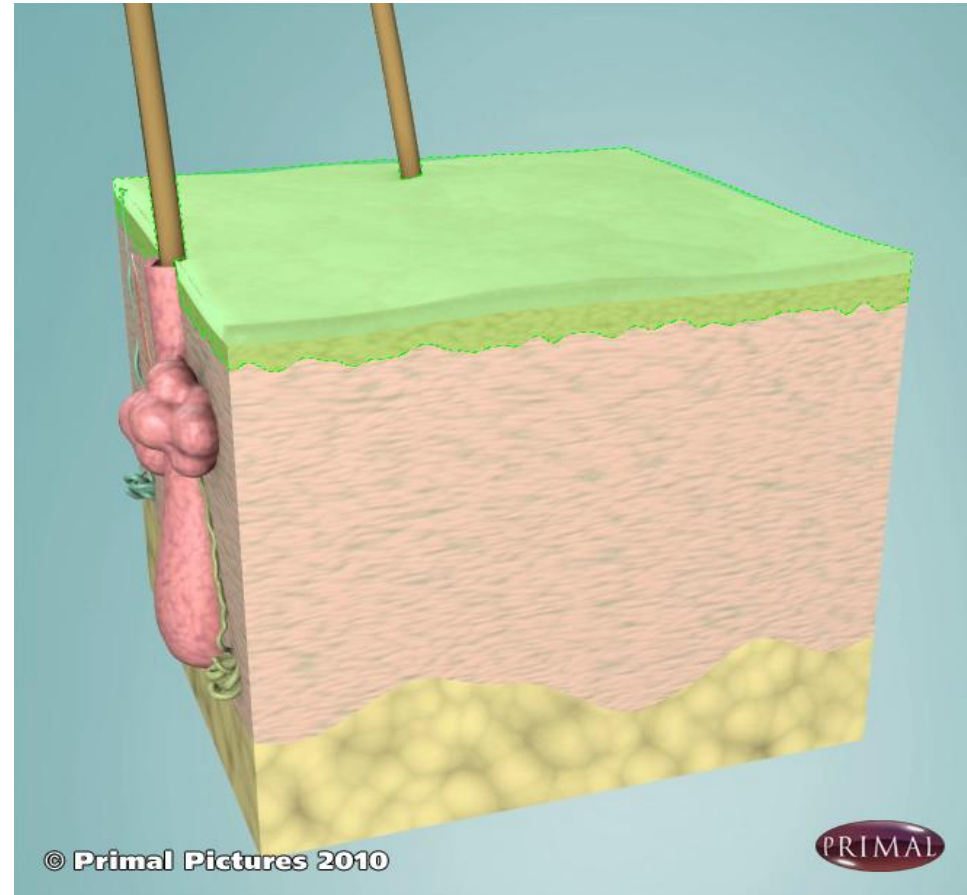


Epidermal ridge
Dermal papilla



Epidermis

- Is the outermost layer of the skin
 - It is composed of four or five layers, depending on the type of skin.
- It is rich in a tough protein called keratin
- Contains four different cell types:
 - Keratinocytes**
 - Melanocytes**
 - Langerhans cells**
 - Merkel cells**
- Avascular
- The epidermis forms a waterproof barrier between the body and the external environment, which resists friction and microbial invasion and prevents water loss
 - Is derived from ectoderm

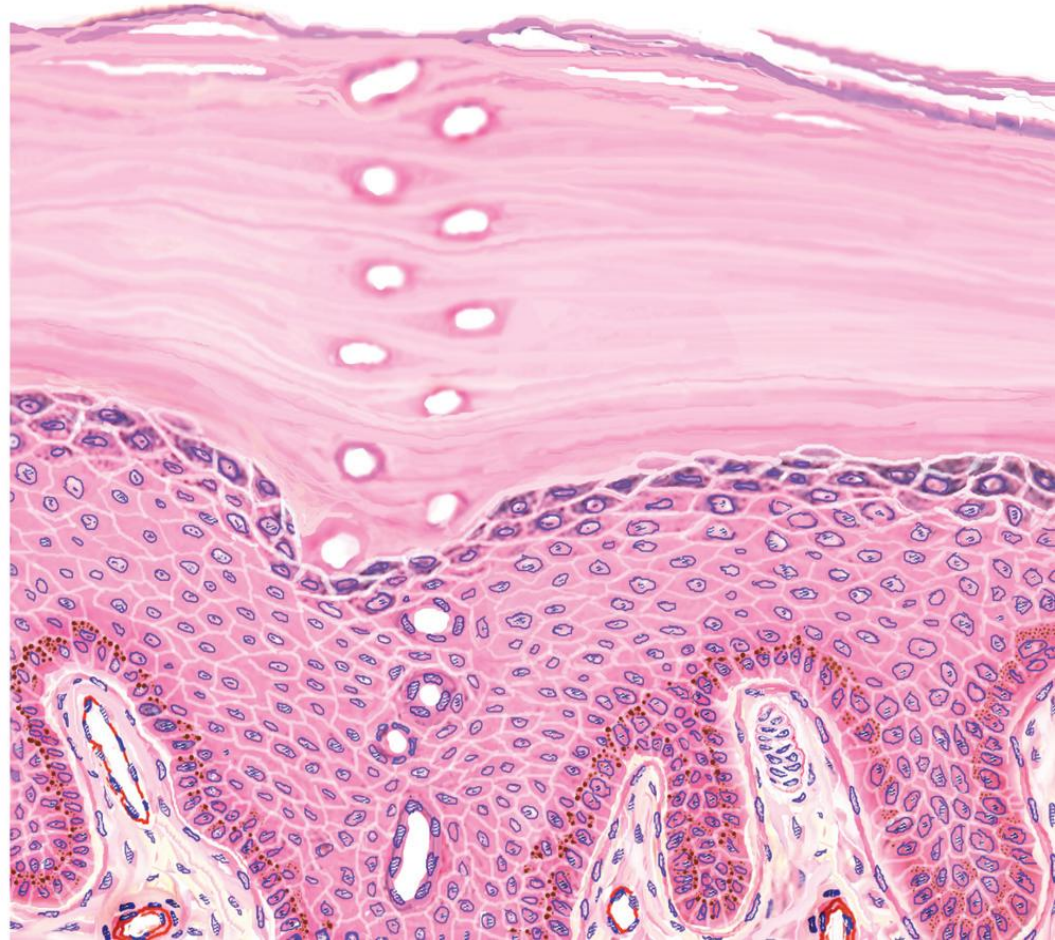


Keratinized stratified squamous epithelium

(1) Stratum basale

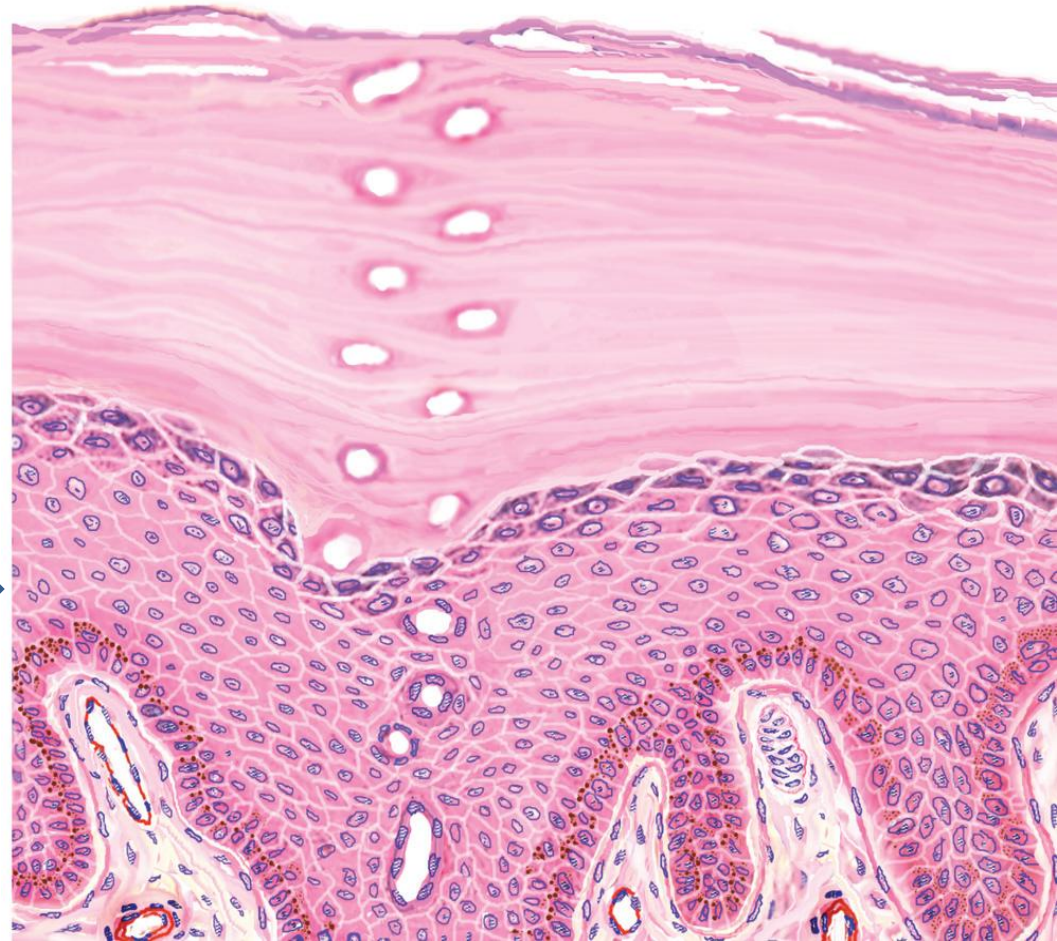

- Is the deepest layer in the epidermis.
- Consists of a single layer of basophilic columnar to cuboidal cells that rest on a basement membrane
- The cells are attached to one another by desmosomes, and to the underlying basement membrane by hemidesmosomes.
- Cells are characterized by intense mitotic activity

As cells of the outer surface of the epidermis are continually being sloughed off, some cells in the stratum basale divide continuously, replenishing the epidermis.



(2)Stratum spinosum

- Is the layer above the stratum basale
- Consists of 8-10 rows of cells
- Cells synthesize keratin filaments that become assembled into tonofilaments
- During histologic preparation, cells shrink and intercellular spaces appear as spines
- Spines represent sites of desmosome attachments to keratin tonofibrils



Dr. Heba Kalbouneh

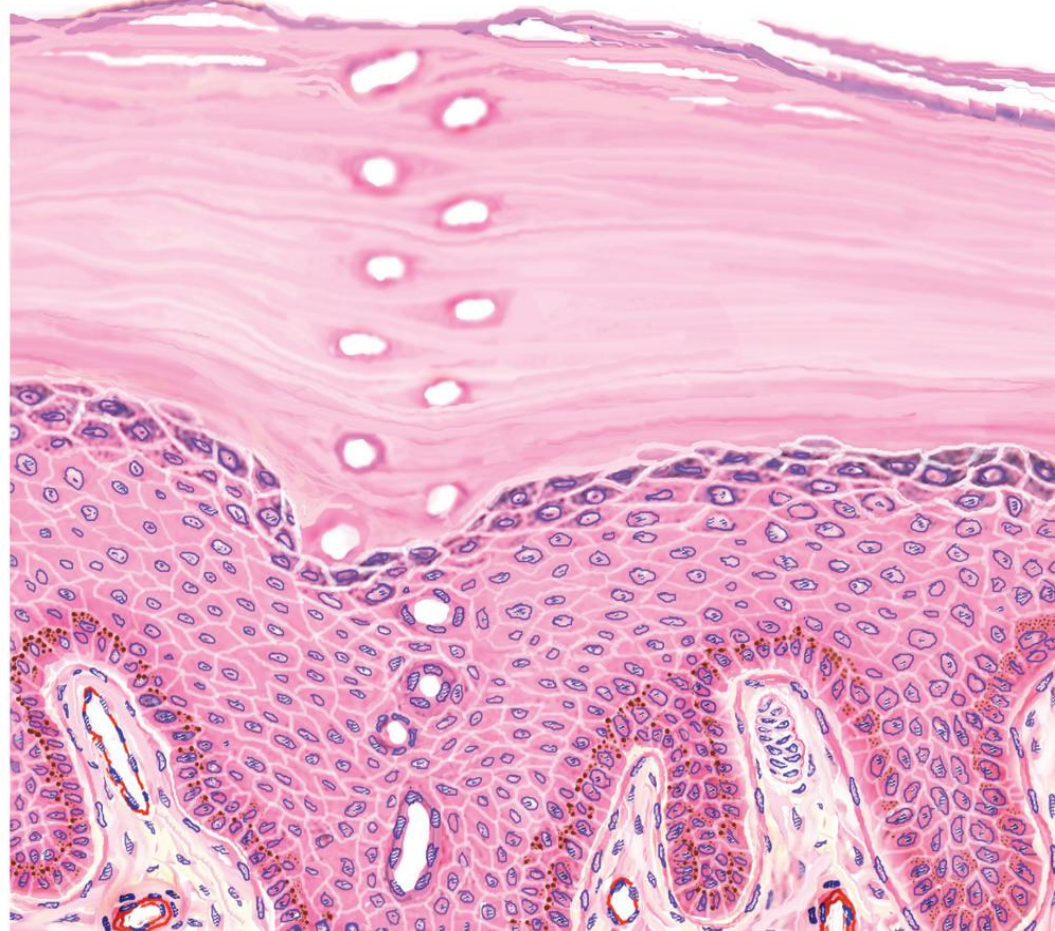

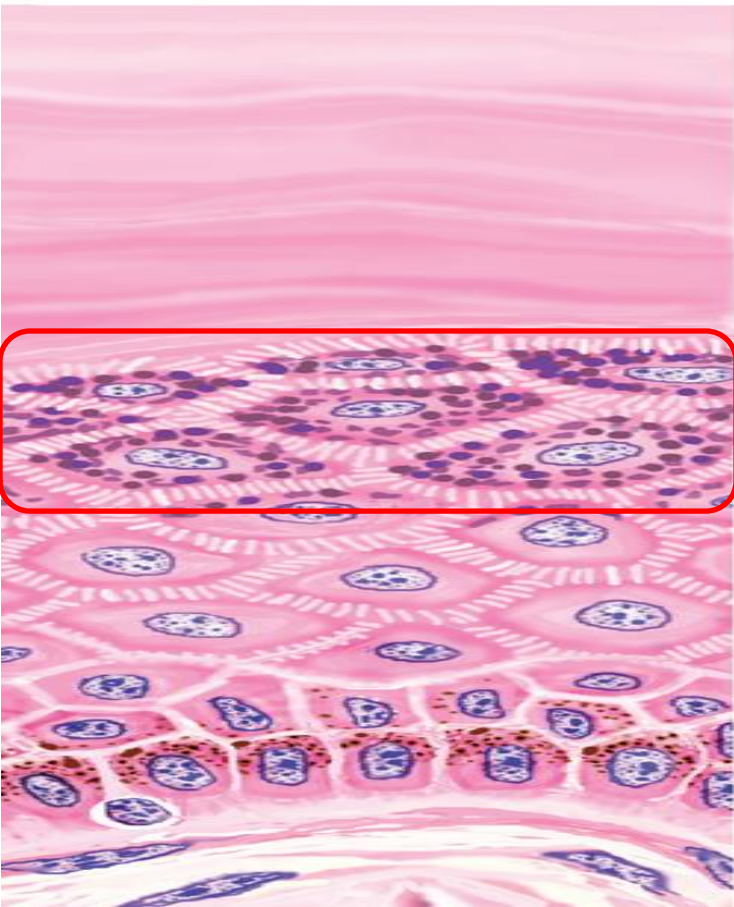


Stratum basale along with the
deepest part of stratum spinosum
is called
Stratum germinativum

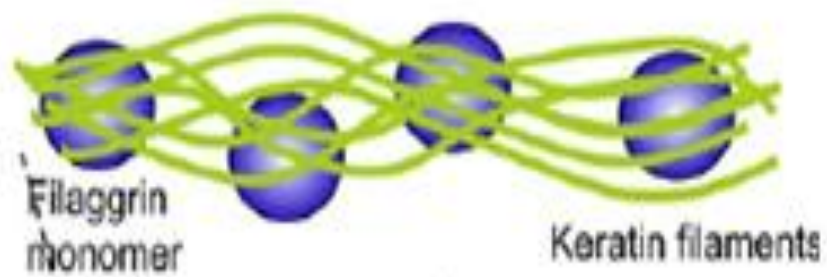
(3) Stratum granulosum

- Cells above the stratum spinosum
- Consists of 3-5 cell layers of flattened cells
- Cells filled with dense basophilic keratohyalin granules and membrane-bound lamellar granules

Dr. Heba Kalbouneh



Keratohyalin granules are intensely basophilic, non membranous bound masses of filaggrin cross-links with keratin tonofibrils



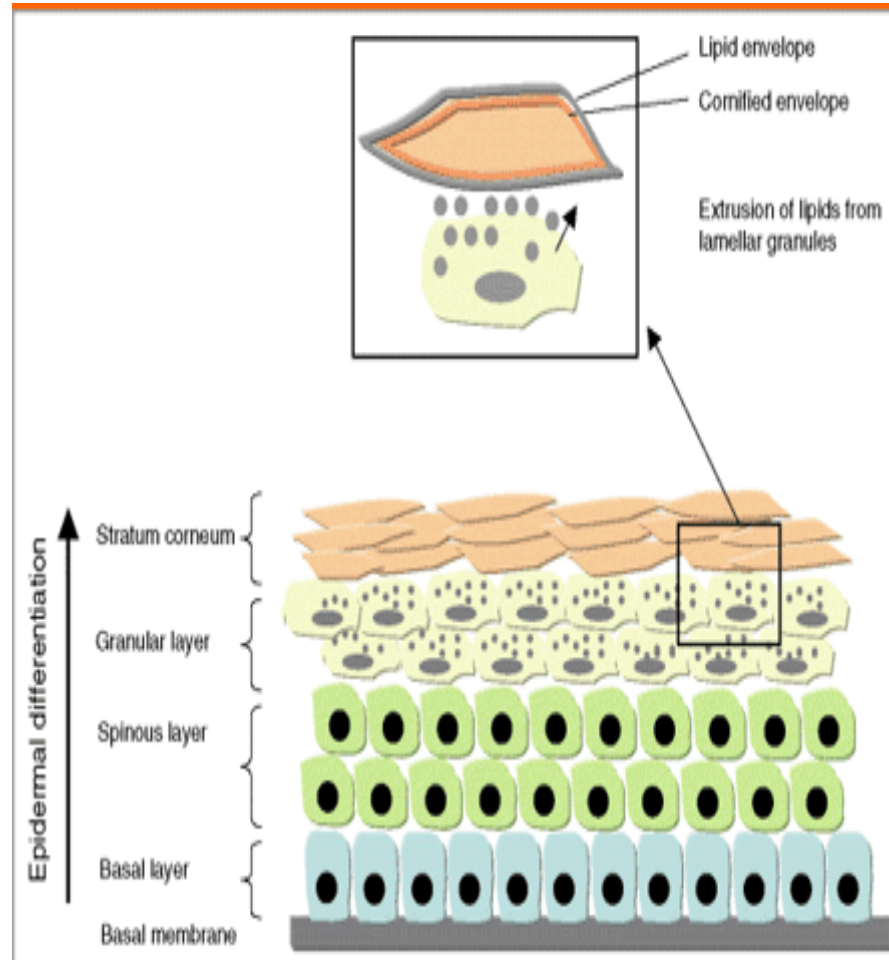
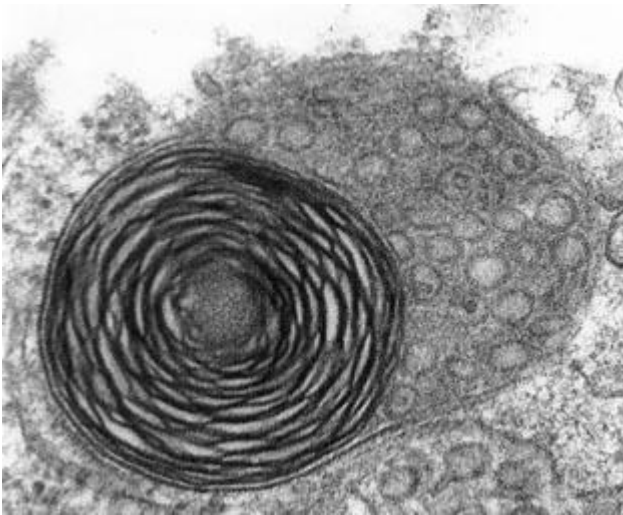
Intermediate filaments= keratin

Tonofibrils



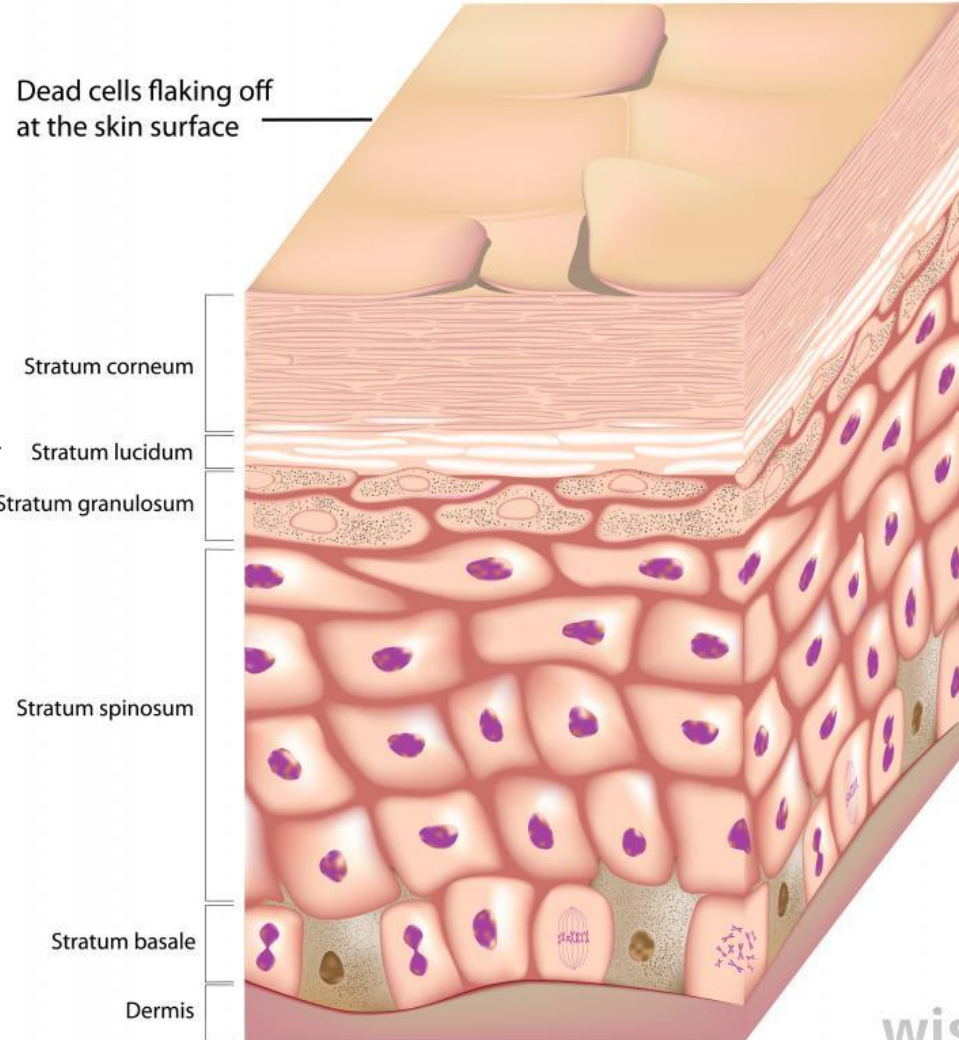
Tonofilaments

Lamellar granules discharge lipid material between cells and waterproof the skin



(4)Stratum Lucidum

- In thick skin only
- Is translucent and barely visible
- The tightly packed cells (desmosomes) lack nuclei or organelles and are dead.

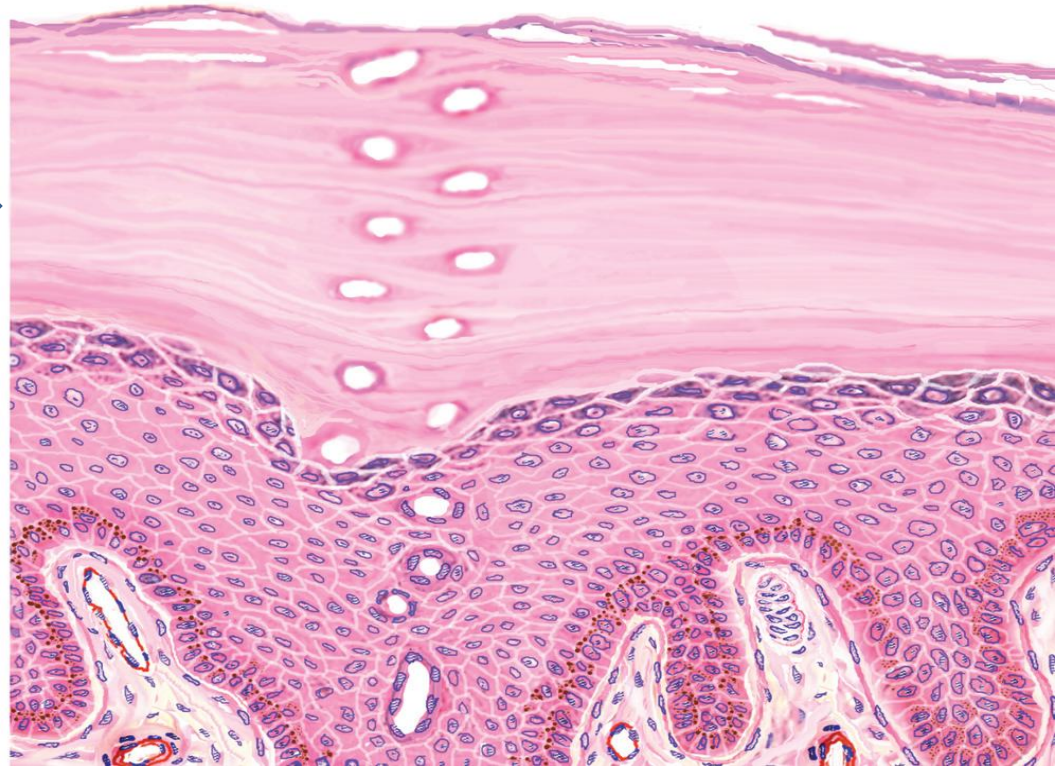

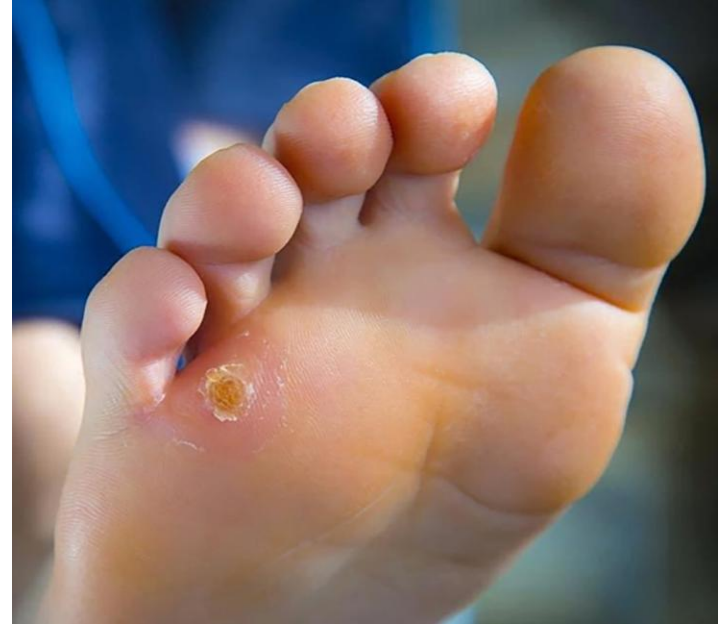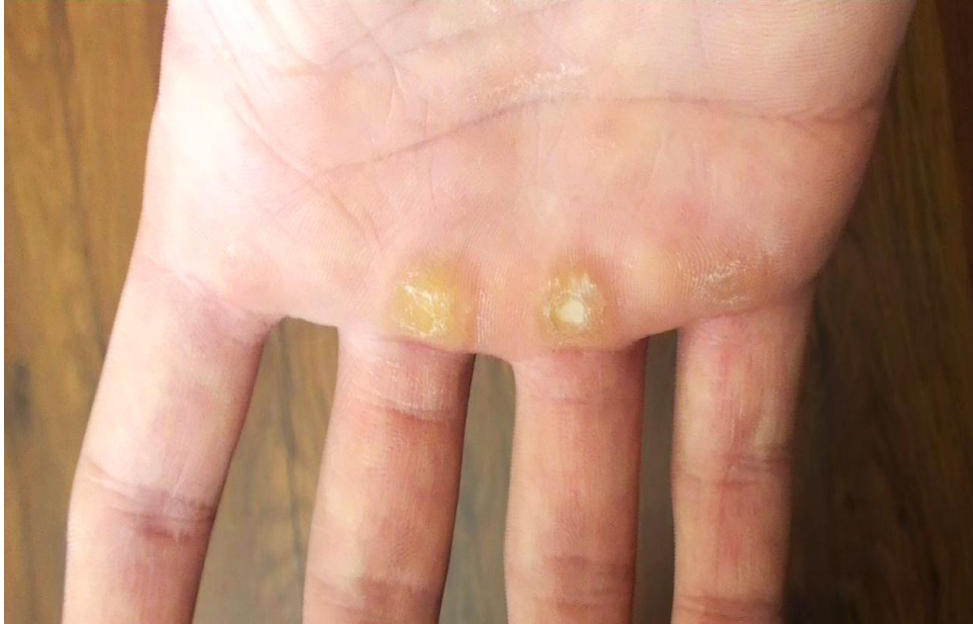(5)Stratum corneum

- Most superficial layer of the skin.
- Consists of dead, flattened cells with no nuclei and cell organelles
- The dead cells contain much keratin filaments with plasma membranes surrounded by lipid-rich layer
- The cells from this layer are continually shed, or desquamated, and are replaced by new cells arising from the deep stratum basale.
- During the keratinization process, the hydrolytic enzymes disrupt the nucleus and all cytoplasmic organelles, which disappear as the cells fill with keratin.

This layer acts to waterproof the skin surface

Keratin is a tough and fibrous protein that serves to protect the skin.

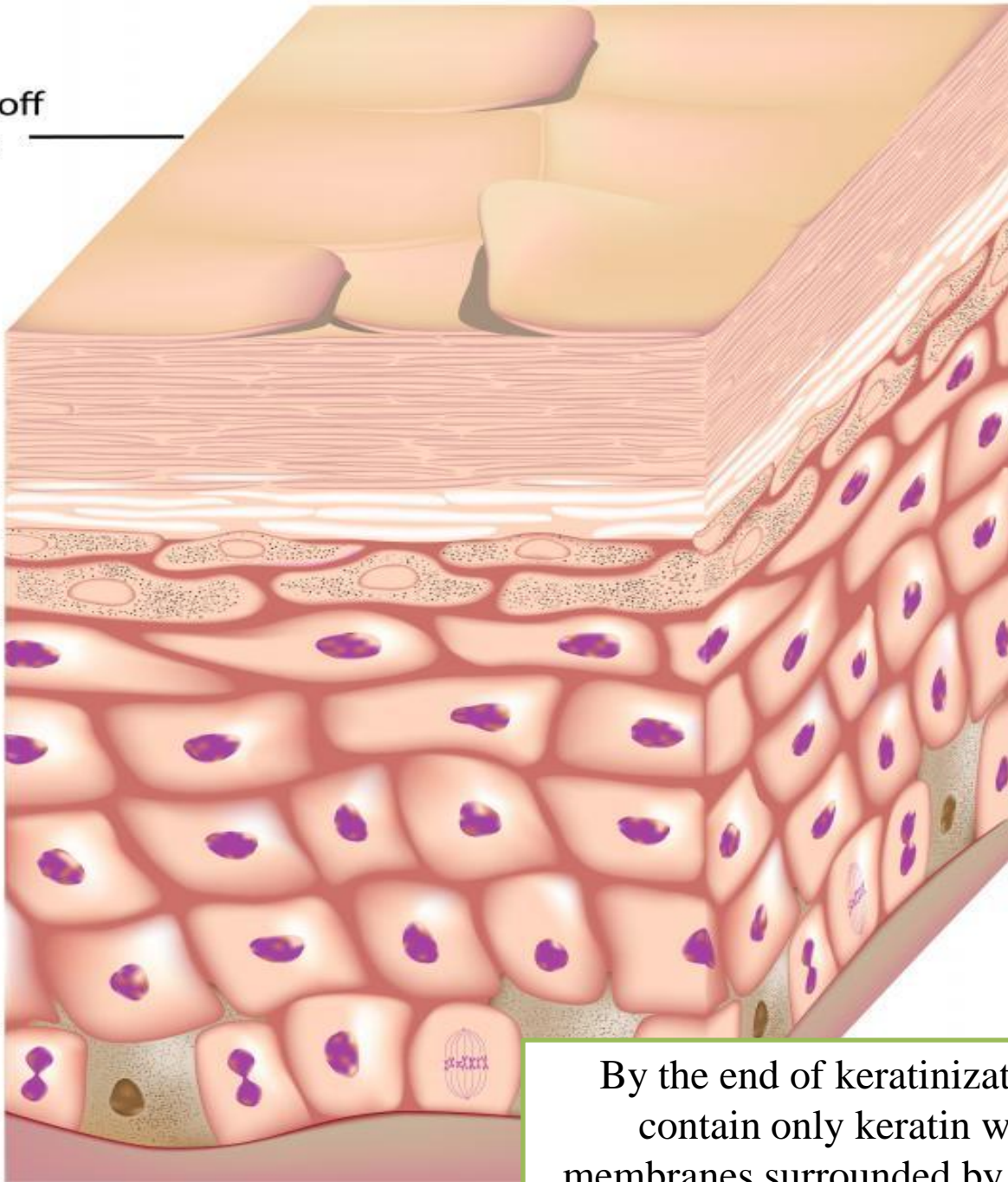




Calluses and corns

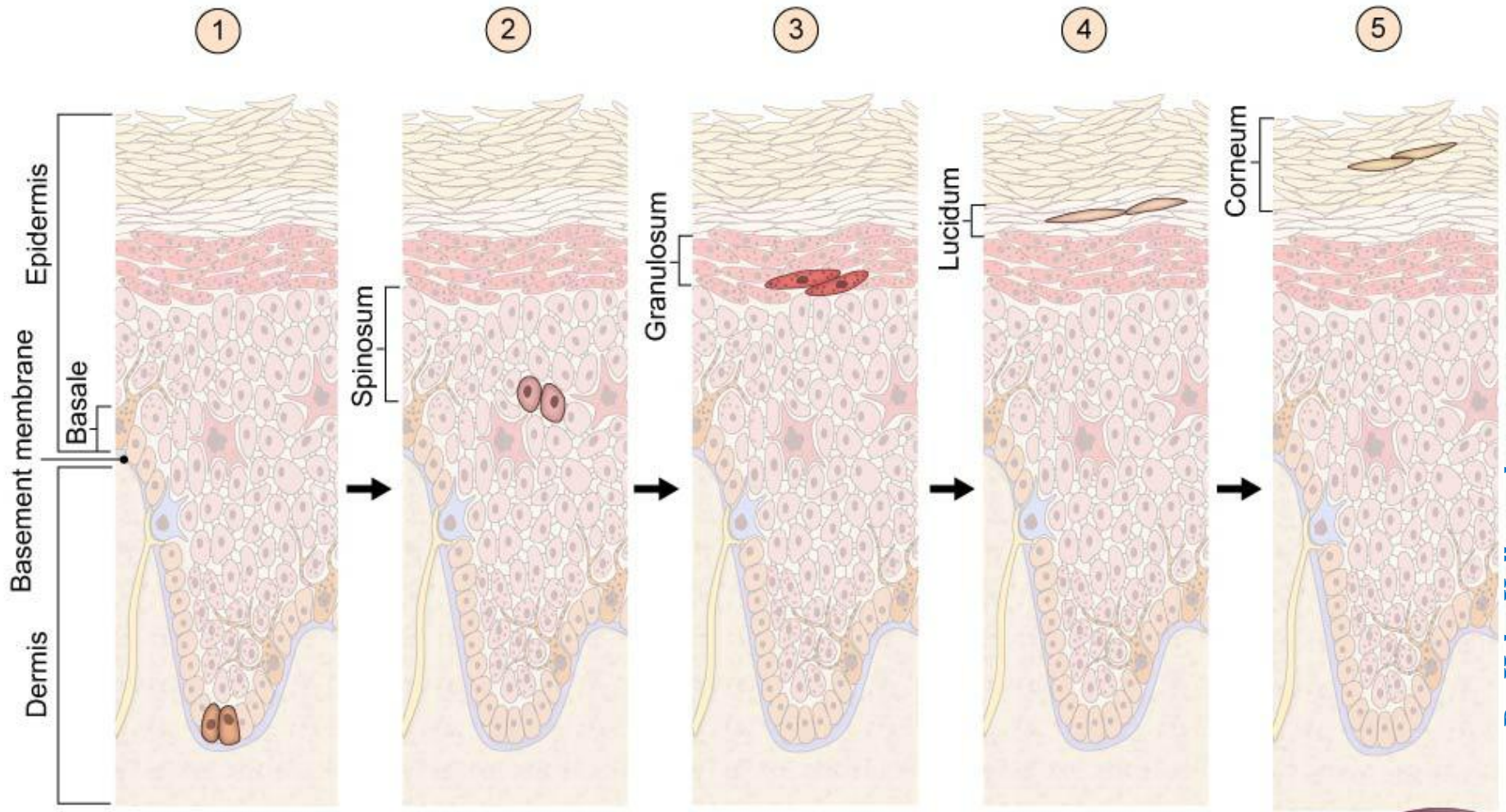
Dead cells flaking off at the skin surface

Stratum corneum
Stratum lucidum
Stratum granulosum
Stratum spinosum
Stratum basale
Dermis

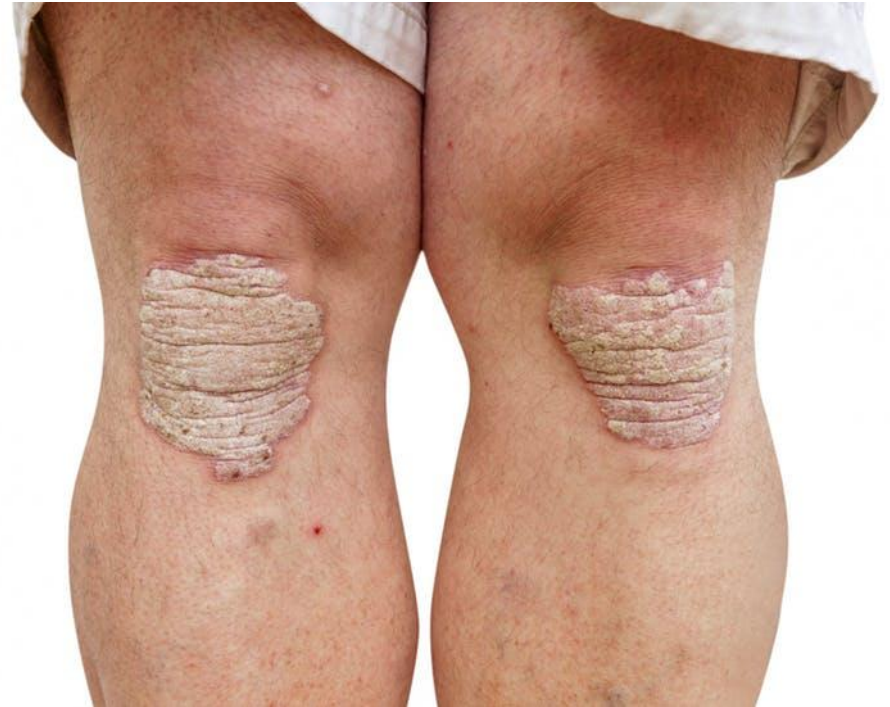

Keratinocytes move up as they age

By the end of keratinization, the cells contain only keratin with plasma membranes surrounded by lipid rich layer



Psoriasis is a common skin condition that speeds up the life cycle of skin cells. It causes cells to build up rapidly on the surface of the skin. The extra skin cells form scales and red patches that are itchy and sometimes painful.

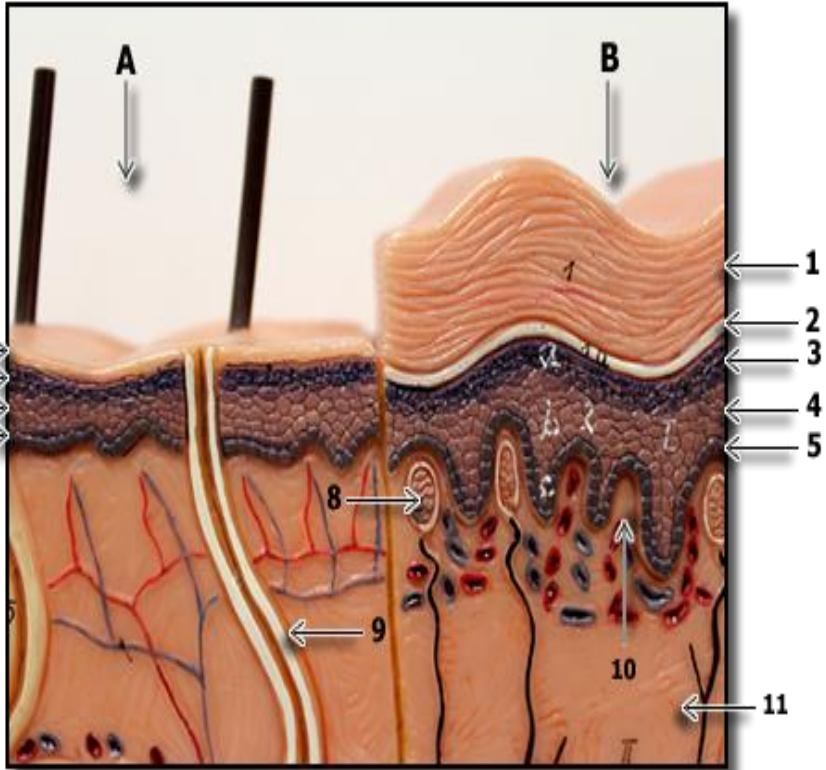


Types of skin

Thin skin

Thick skin

Thin vs. Thick skin



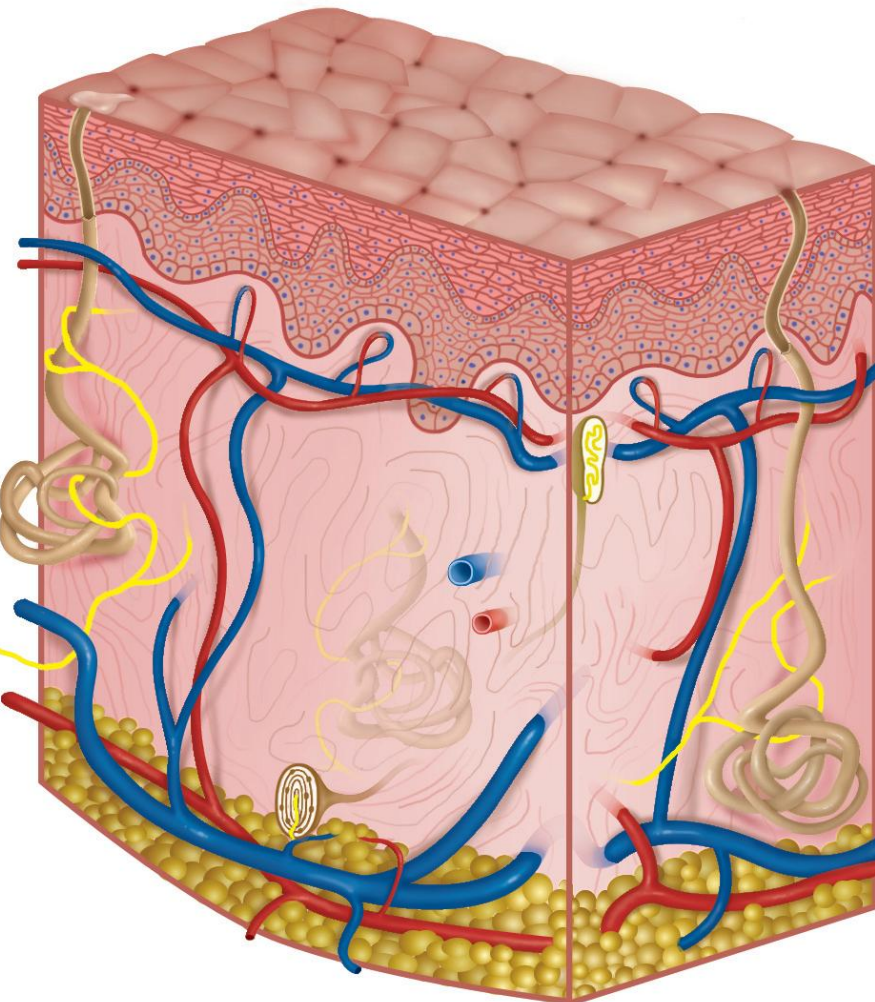
*** Dominant and lines most of the body surface**

*** Palms of the hands and soles of the feet**

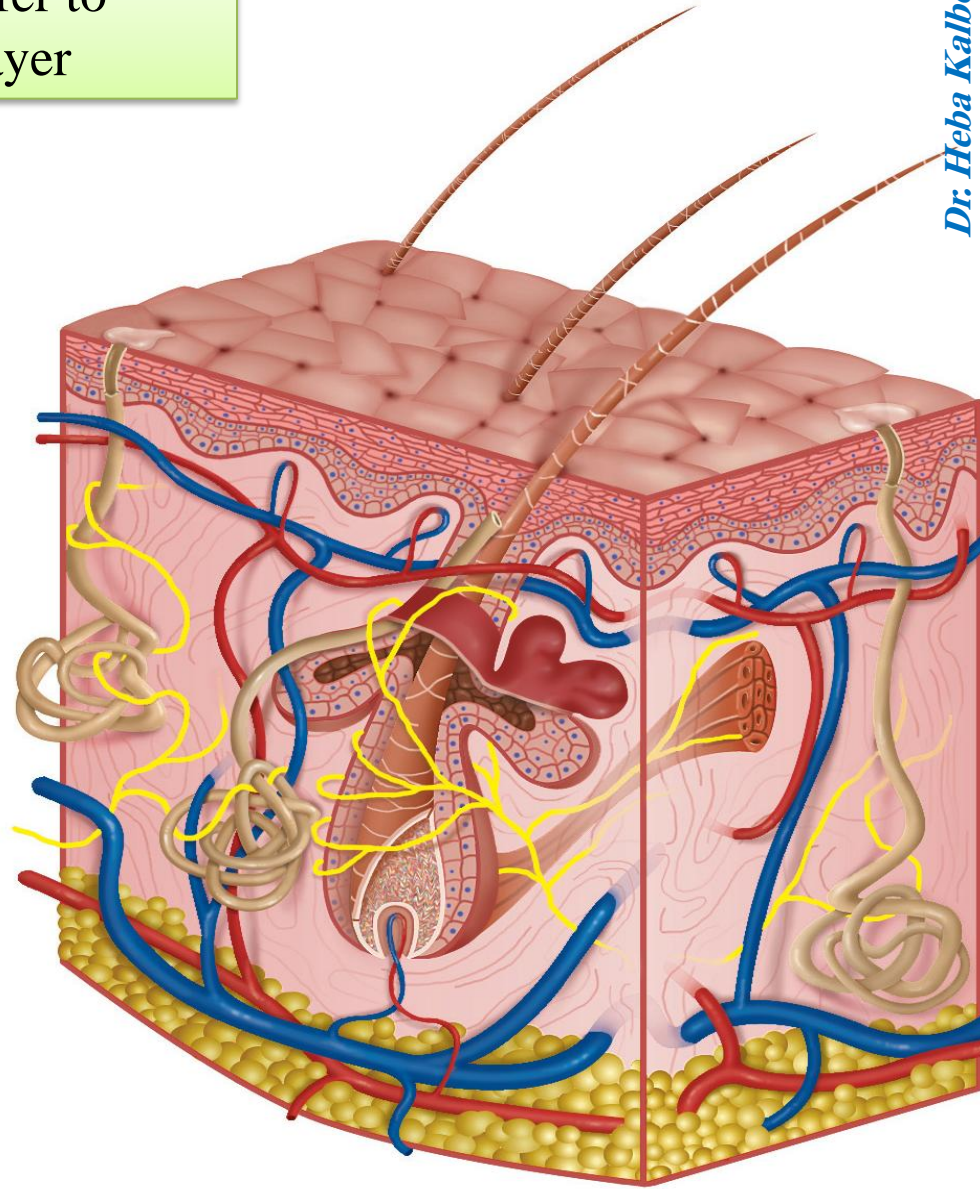
The skin of the back is thin.....The skin of the eyelids is thin too!!!

Thick skin resists the abrasion and friction

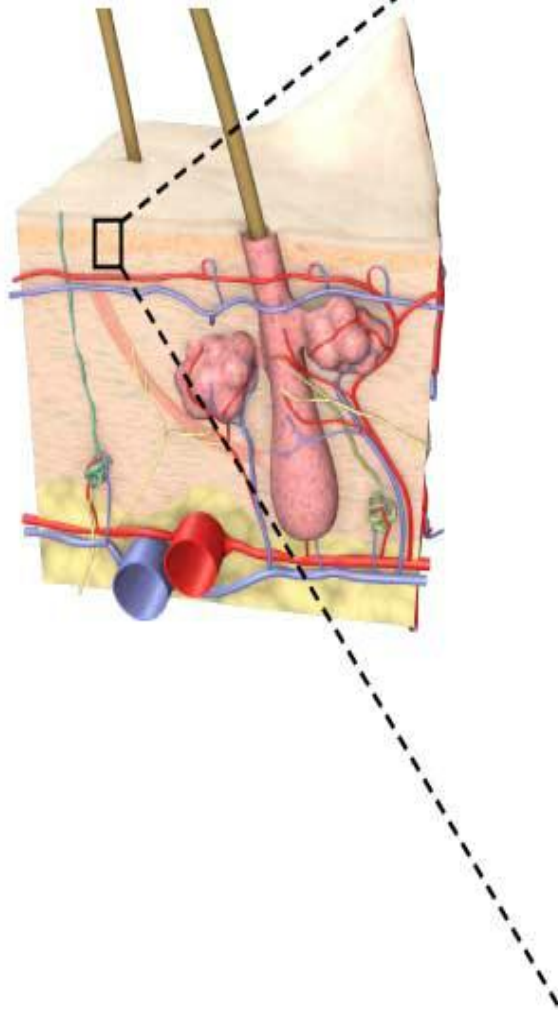
Note: that the thin and thick refer to the thickness of epidermal layer



Thick skin

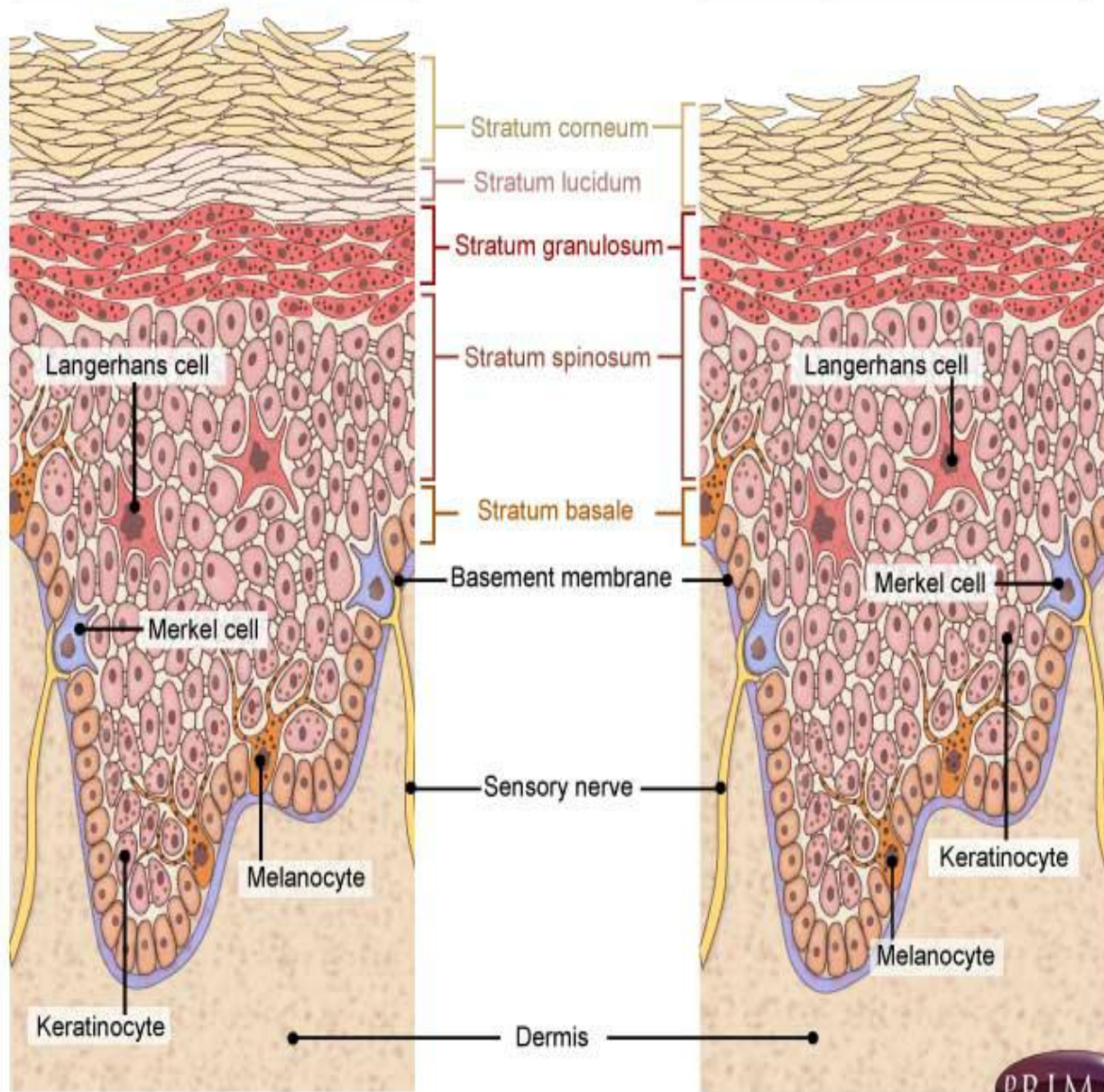


Thin skin



Non-hairy skin 1.5mm

Hairy skin 0.1mm

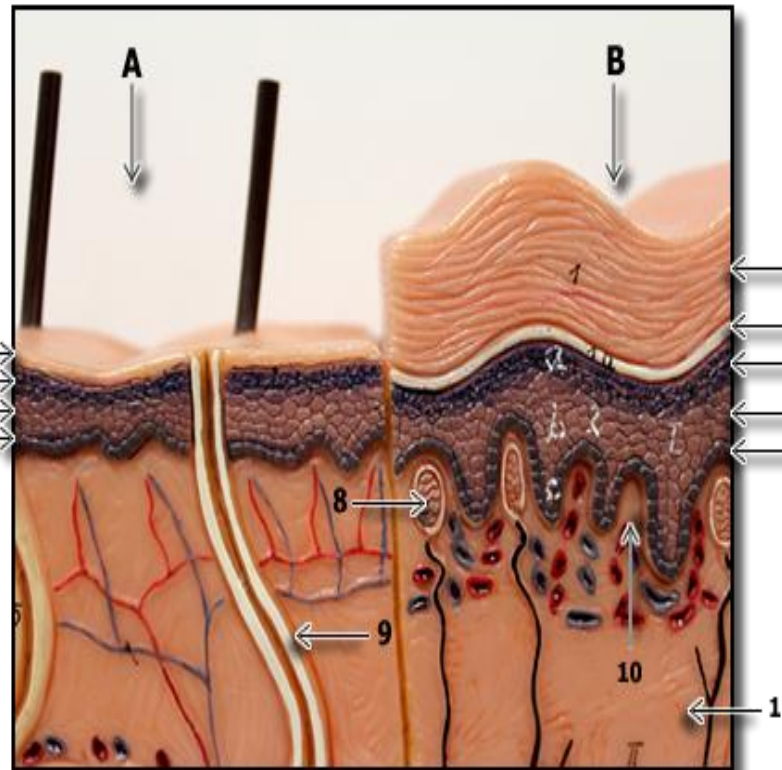


Types of skin

Thin skin

Thick skin

Thin vs. Thick skin



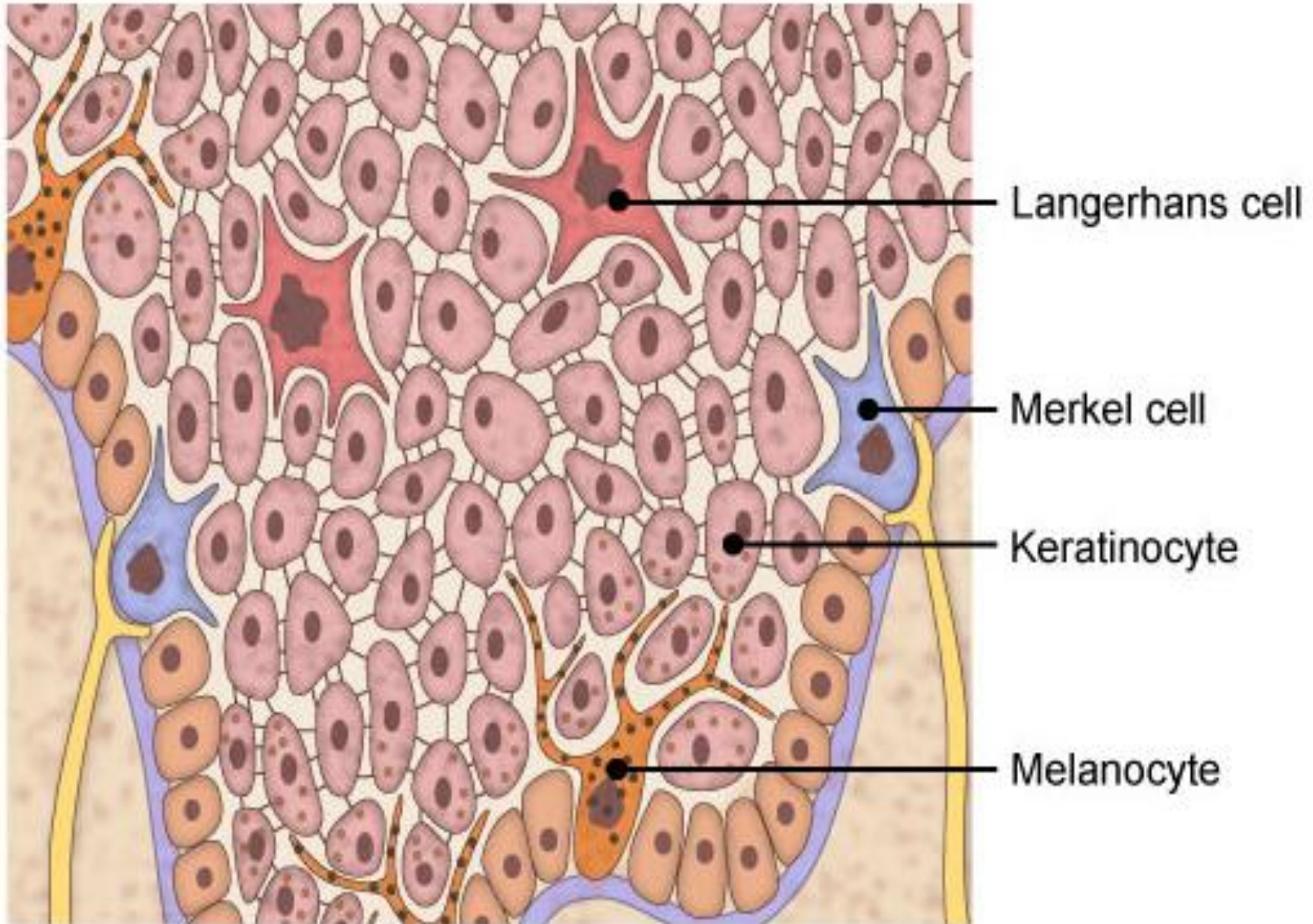
*4 layers

- *less Prominent stratum corneum
- * Less developed stratum granulosum
- * Dominant and lines most of the body surface
- * Thicker dermis
- * hair and sebaceous glands

*5 layers

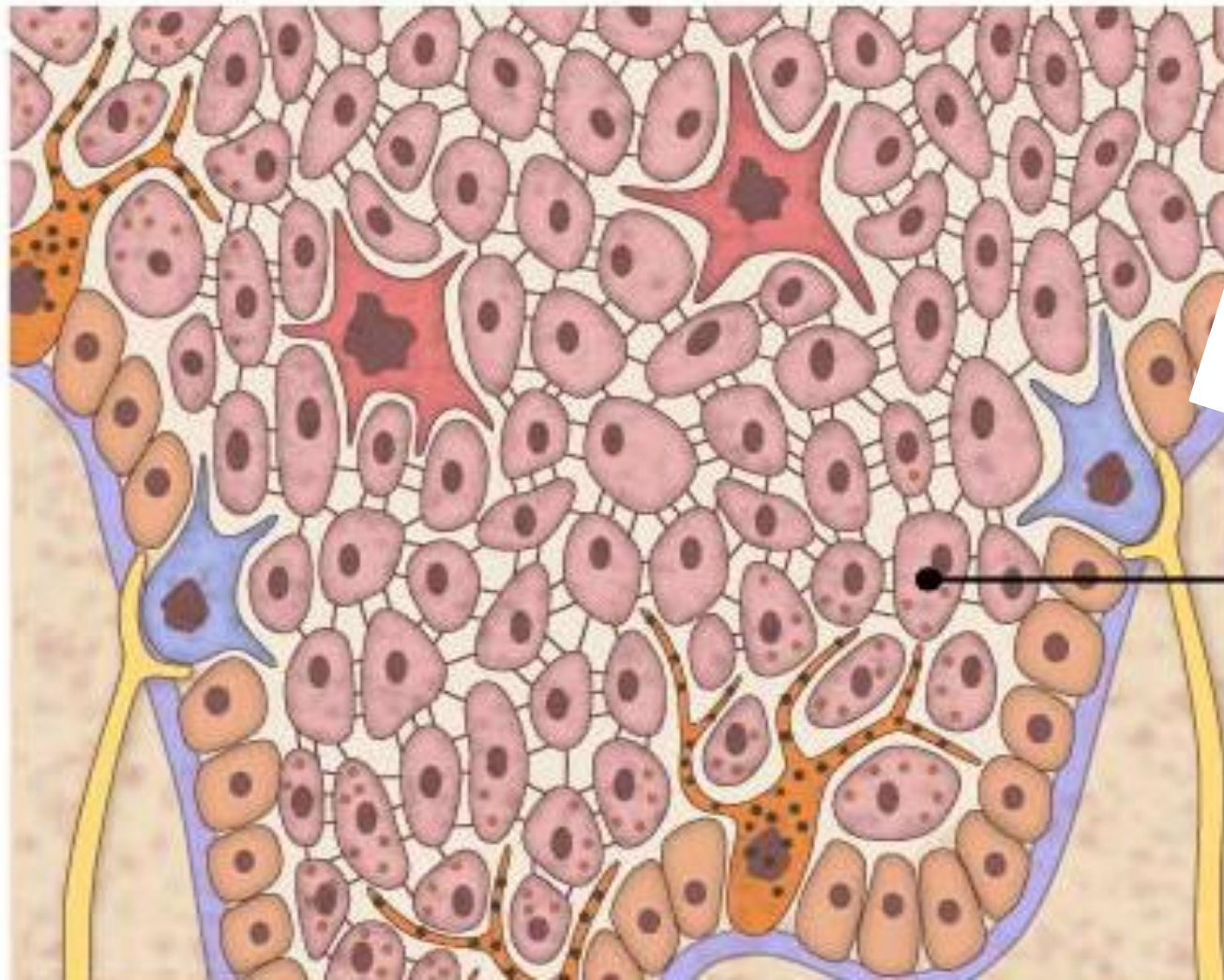
- * Prominent stratum corneum
- * Well developed stratum granulosum
- * Palms of the hands and soles of the feet
- * Thinner dermis
- * No hair and sebaceous glands

TYPES OF EPIDERMAL CELLS



(1)-keratinocytes:

- Approximately 90% of epidermal cells are keratinocytes.
- Produce **keratin**
- Produce **lamellar granules** that helps waterproof the skin

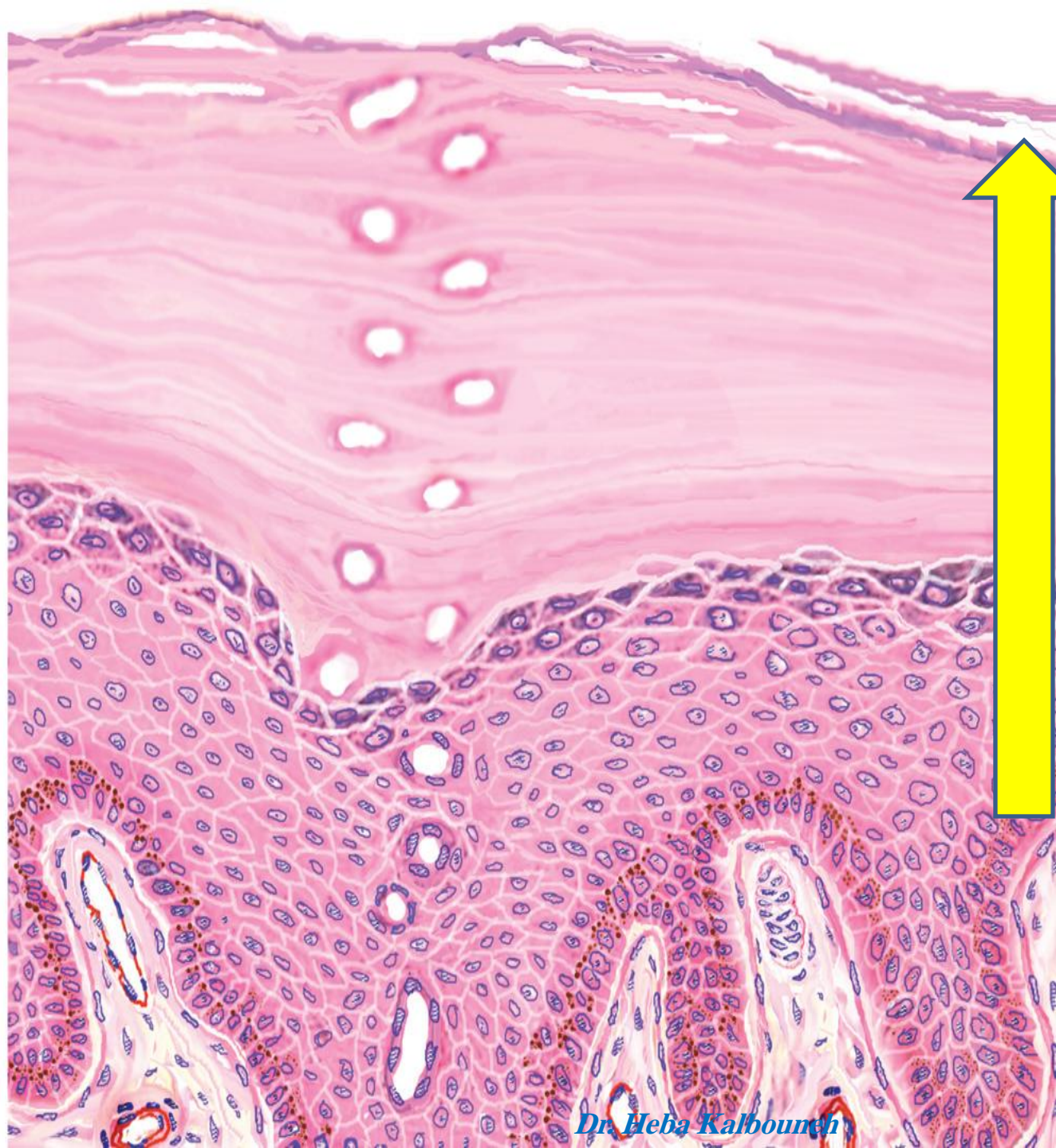

*keratinocytes continuously
shed and regenerate every
2-4 weeks*

Keratinocyte

NOTE: The structure of keratinocytes changes dramatically as they mature: they change from square-shaped cells to flat cells.

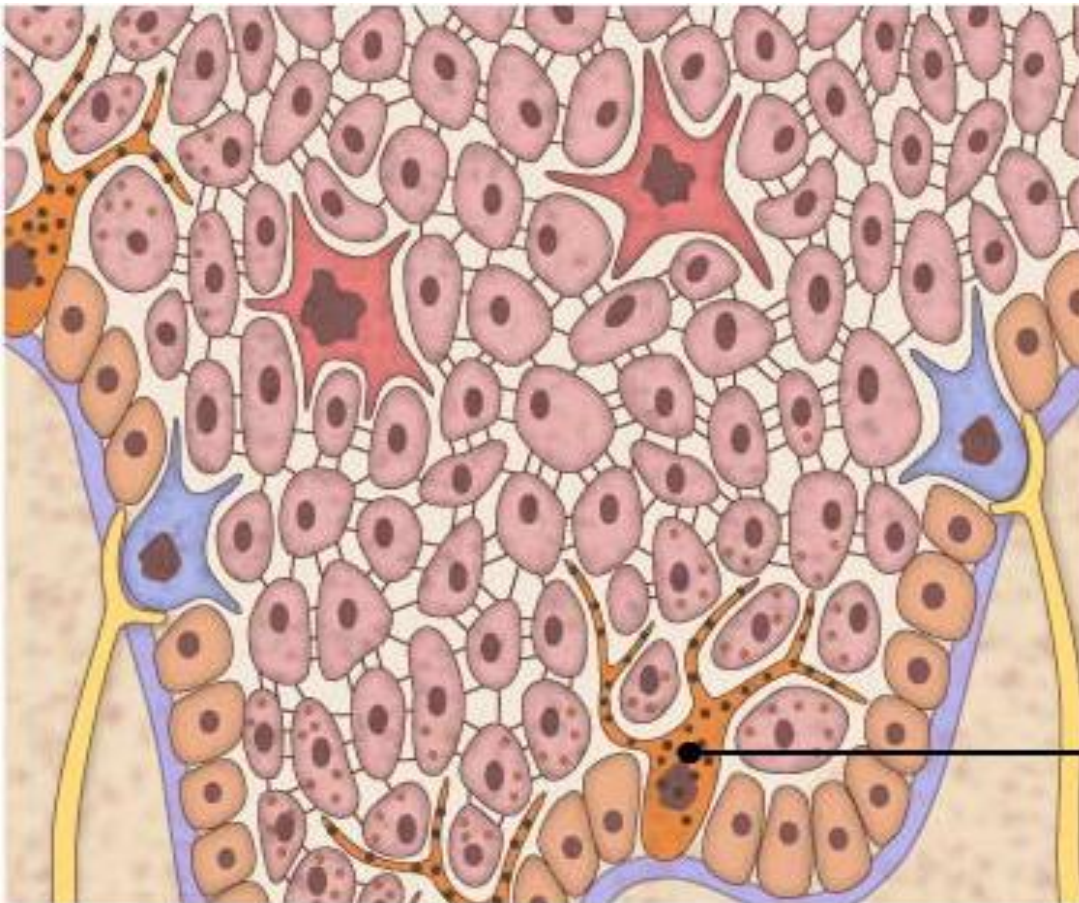
Throughout their life they become engorged with keratin before eventually dying, losing all of their internal structures.



(2)-Melanocytes:

Melanocytes are our natural **SPF**

- Are derived from the neural crest cells.
- Have protrusions that transfer melanin granules to the keratinocytes
- Are located in the stratum basale
- Synthesize the dark brown pigment melanin
- Melanin protects the skin from the damaging effects of ultraviolet radiation

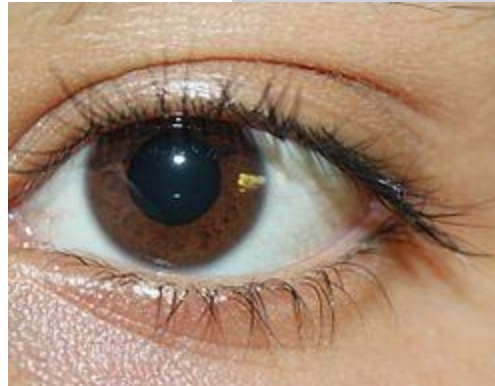

Melanin imparts a dark color to the skin, and exposure of the skin to sunlight promotes increased synthesis of melanin

1 melanocyte for every 10 basal keratinocytes

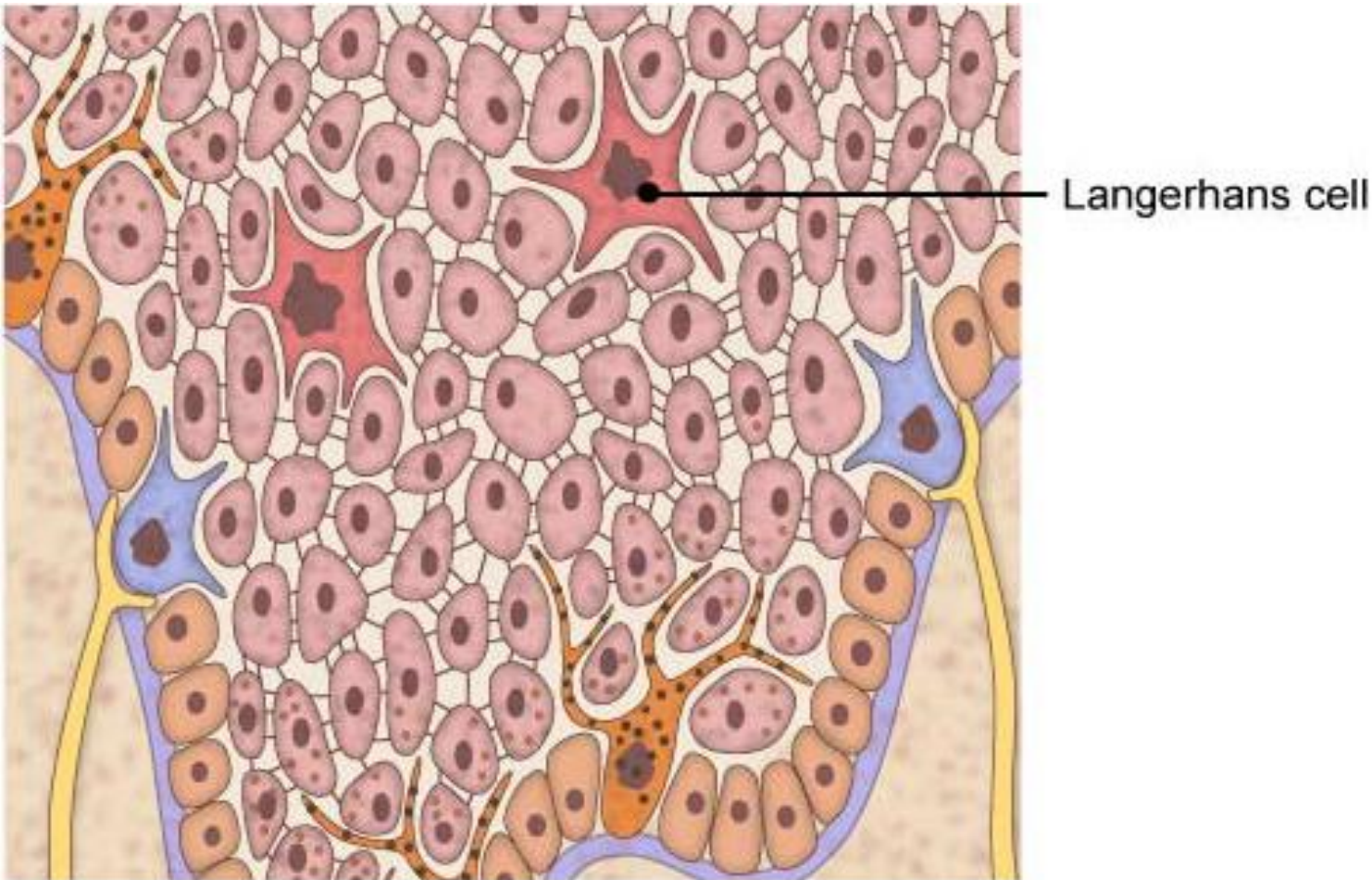
Melanocyte

Albinism



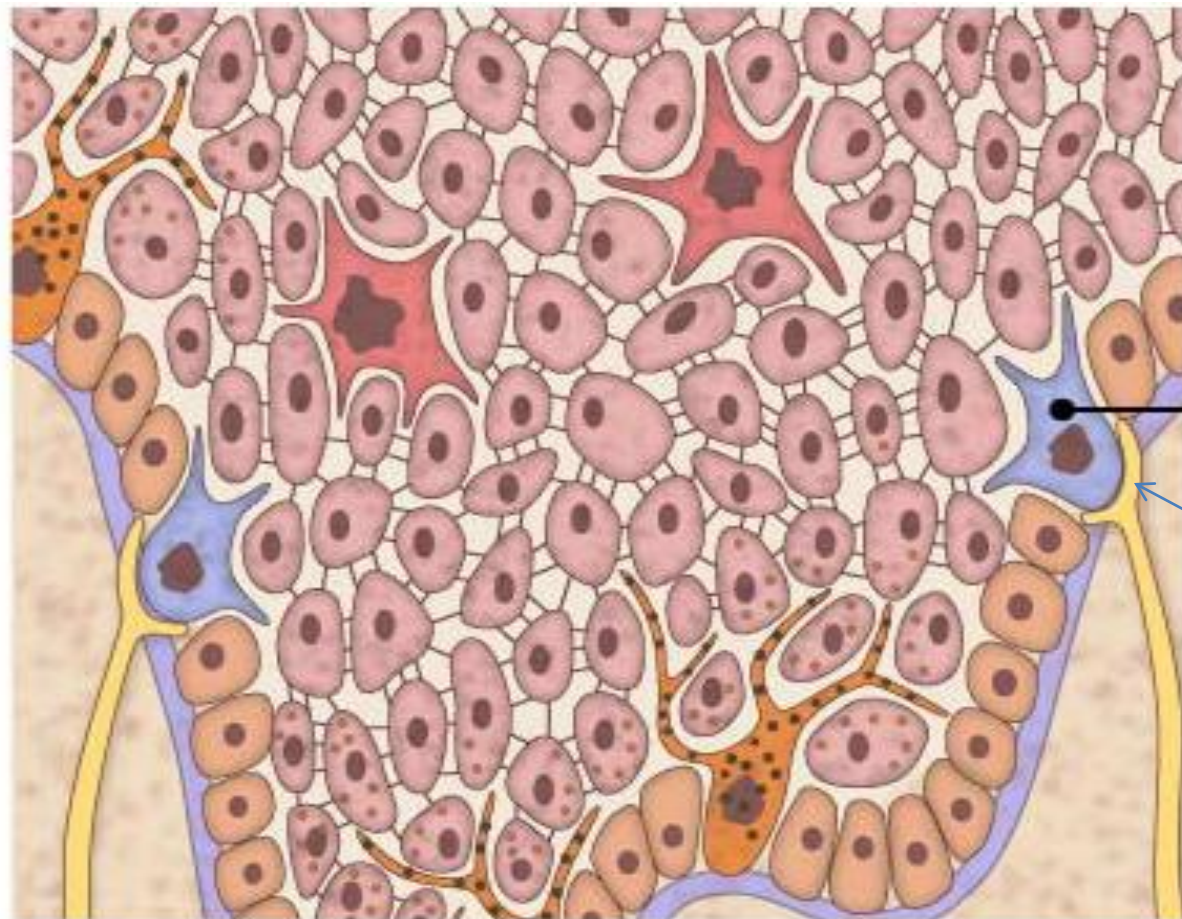
(3)- Langerhans cells:

- Originate from bone marrow (monocytes)
- Mainly in the stratum spinosum
- Langerhans cells recognize, phagocytose, and process foreign antigens
- Represent 2-8% of epidermal Cells



(4)- Merkel cells:

- Are found in the stratum basale
- Are most abundant in the fingertips
- Are closely associated with afferent (sensory) unmyelinated Axons
- Function as light touch receptors (mechanoreceptors)



Merkel cell

NOTE: Sensory neurons form terminal disk under Merckels cells

Dermis

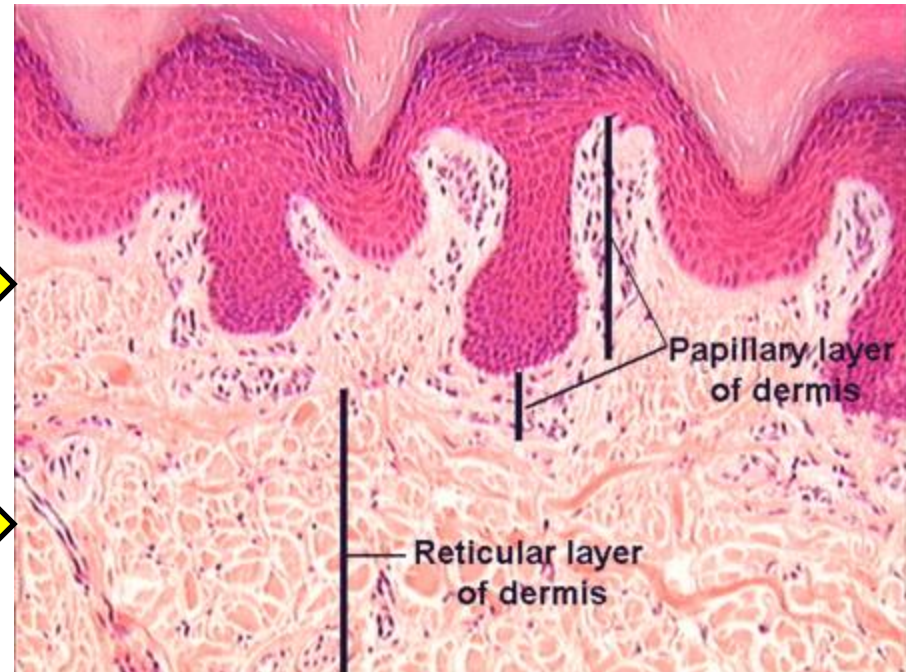
- The dermis lies immediately beneath the epidermis and is much thicker.
- It is responsible for the elasticity and strength of skin
- Contains blood vessels and nerve supply



It supplies the epidermis with nutrients,
and plays an important role in thermoregulation

- Is derived from mesoderm

The dermis can be divided into two sub-layers:



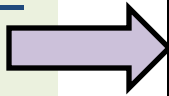
(1) Papillary layer of dermis

Loose connective tissue

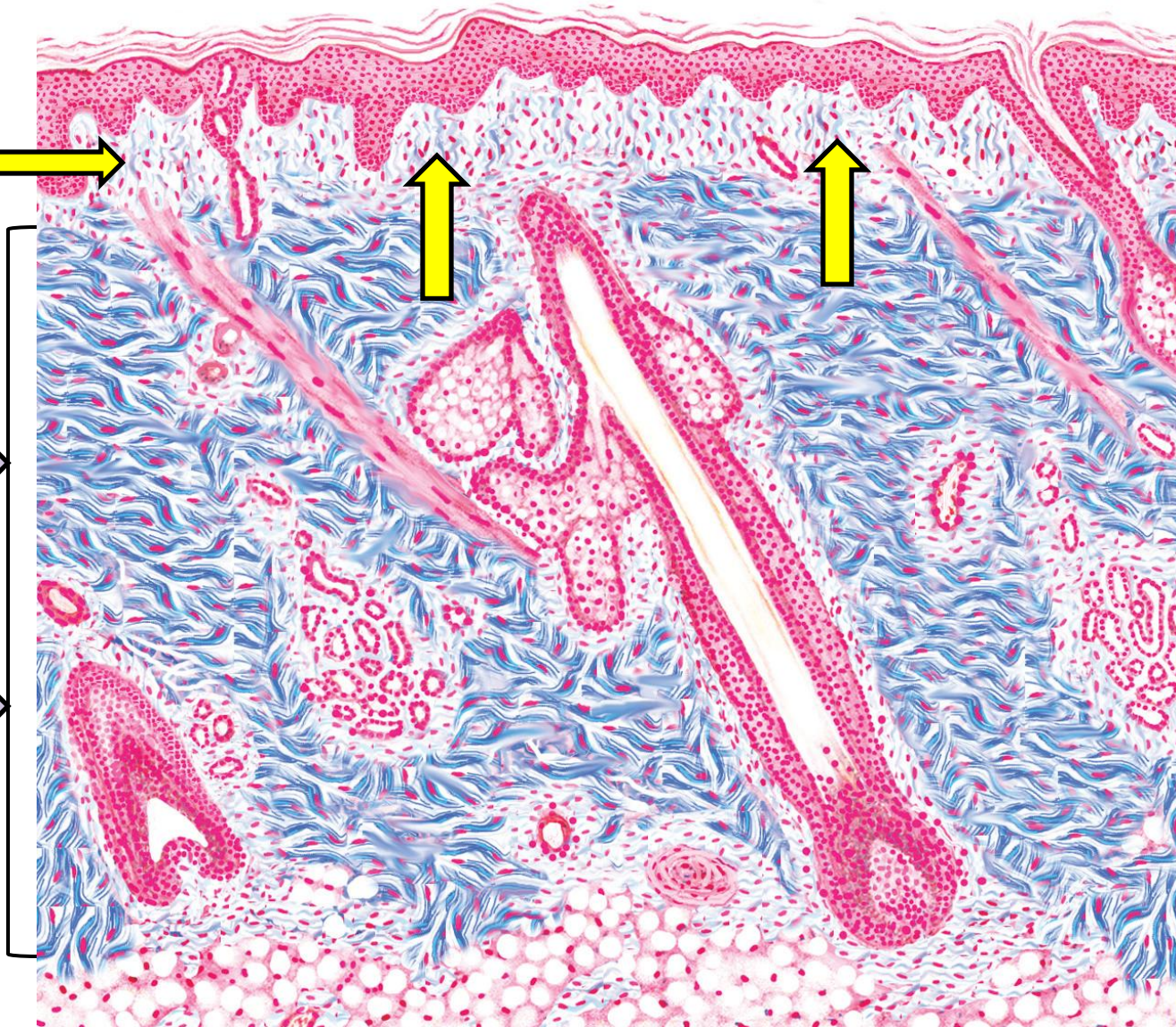


(2) Reticular layer of dermis

Dense irregular connective tissue



Is important in giving the skin its overall strength (collagen I) and elasticity (elastic fibers),



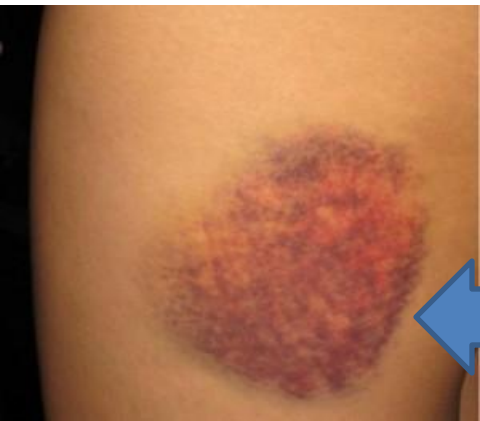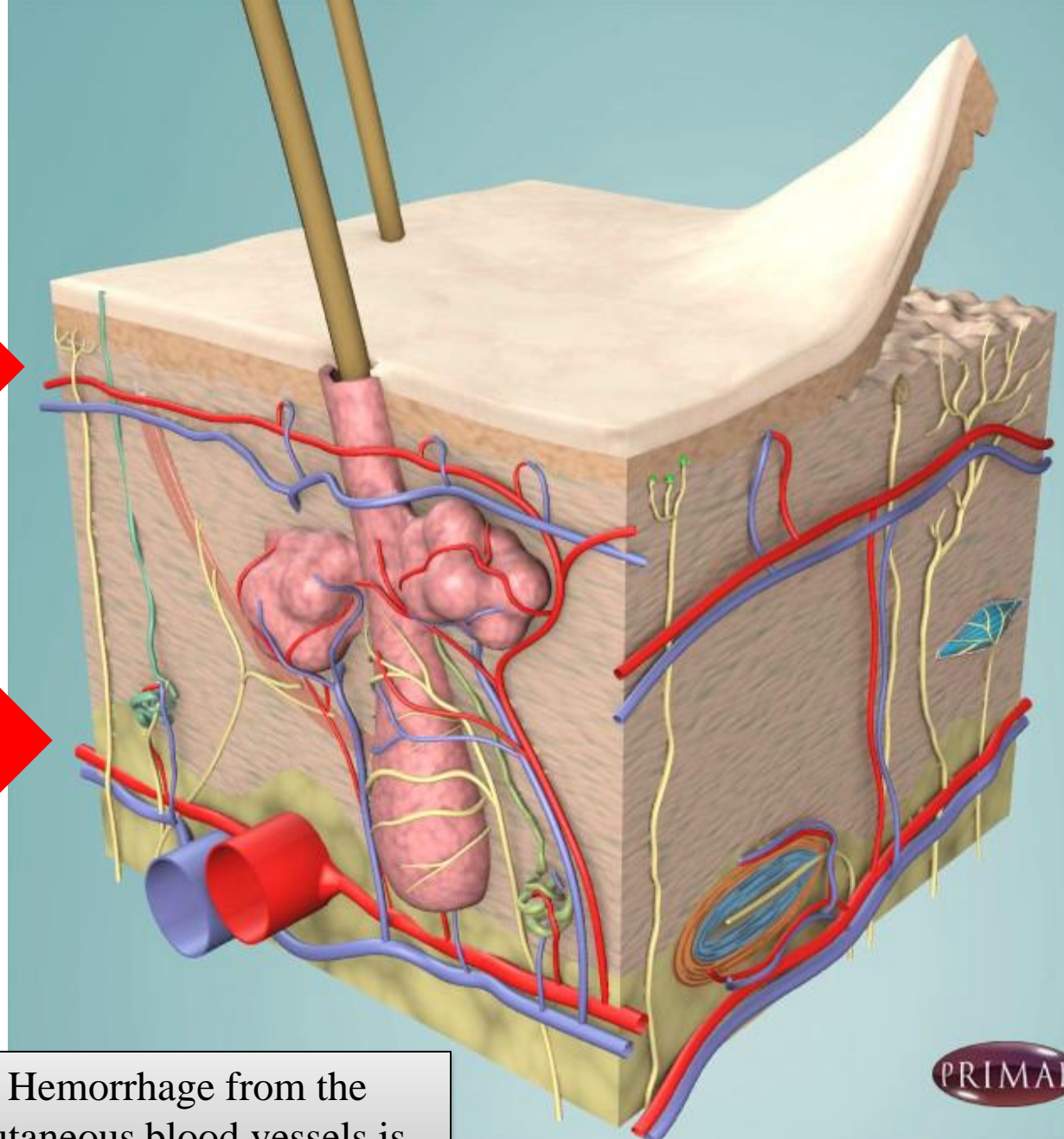

The blood vessels form two major plexuses:

Subpapillary plexus



Thermoregulation

Subdermal plexus



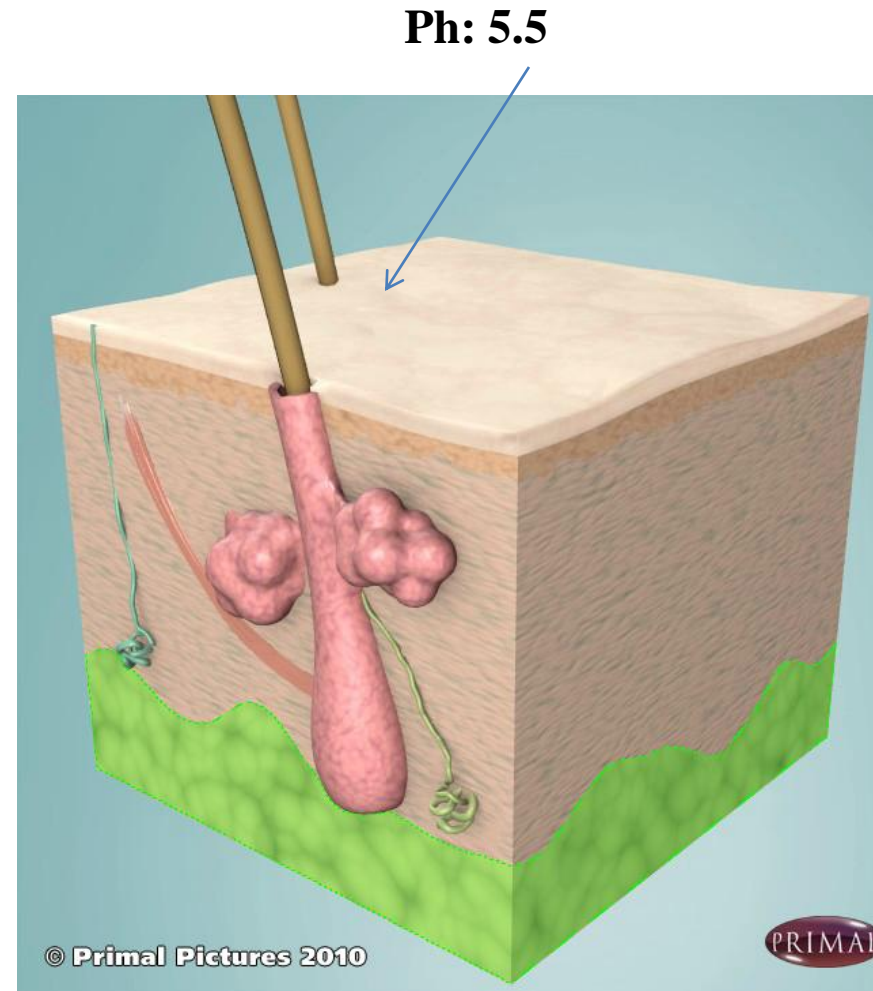
Hemorrhage from the cutaneous blood vessels is called **ecchymosis** (bruise)



The **acid mantle** is a very fine, slightly acidic film on the surface of human skin

Is made up of natural oils, sweat, and dead skin cells, and is slightly more acidic in nature to prevent harmful (naturally alkaline) contaminants from penetrating and damaging the skin

The **acid mantle** adds protection from bacteria, environmental pollutants, and moisture loss.



Sensory receptors



Unencapsulated receptors

Encapsulated receptors

1- Merkel disc

- for light touch and sensing an object texture
- expanded nerve endings associated with merkel cell

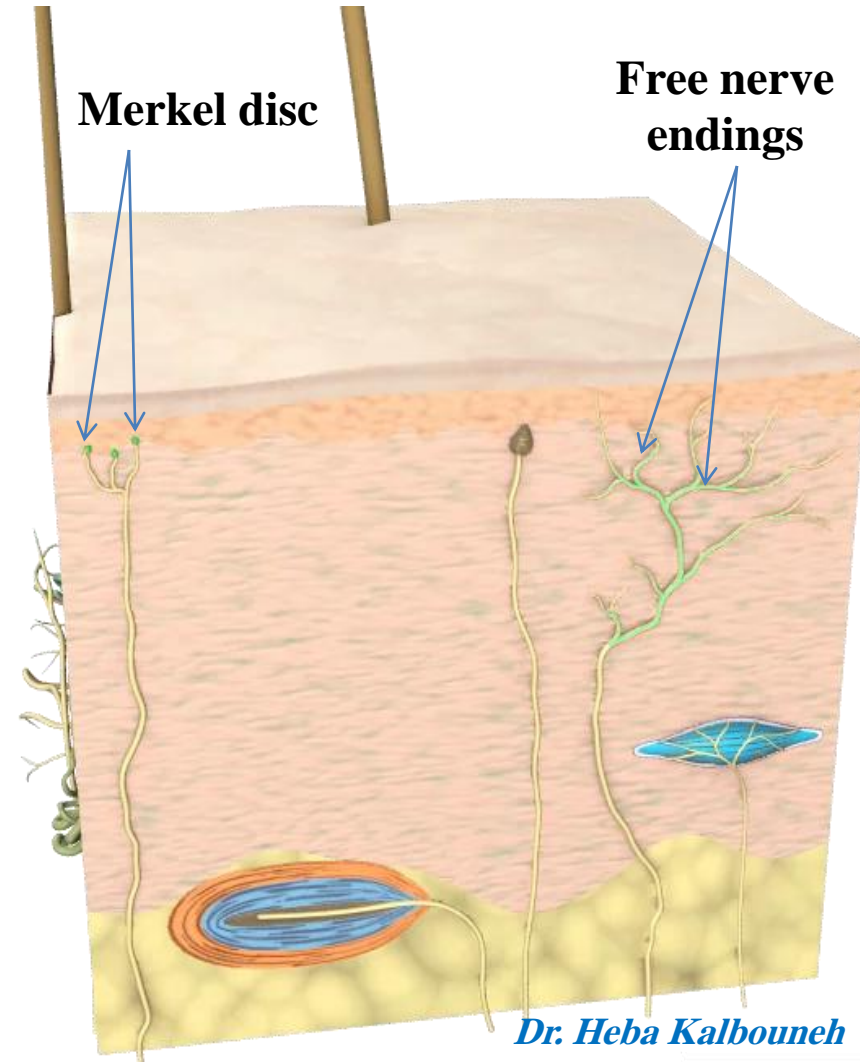
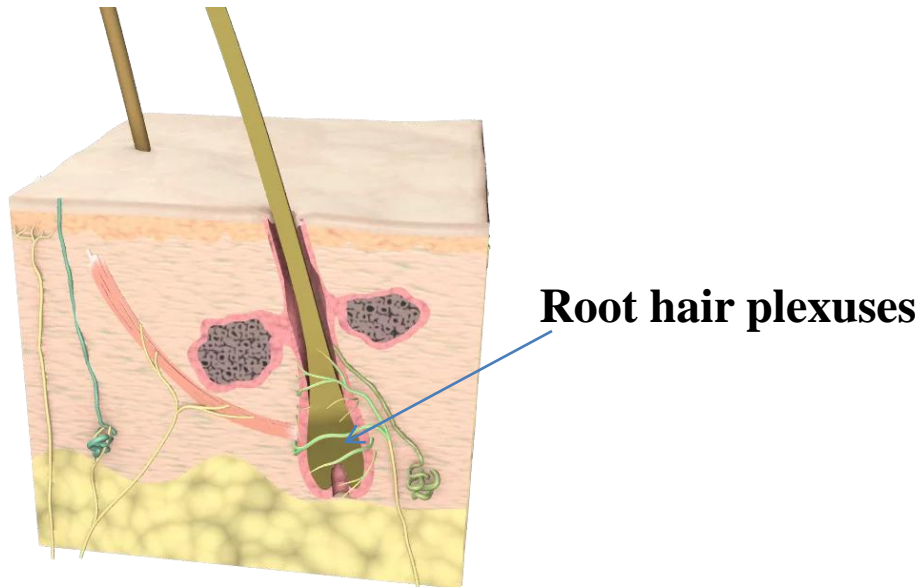
2- Free nerve endings

- In papillary dermis
- Temperature, pain, itching, tactile sensation

3- Root hair plexuses

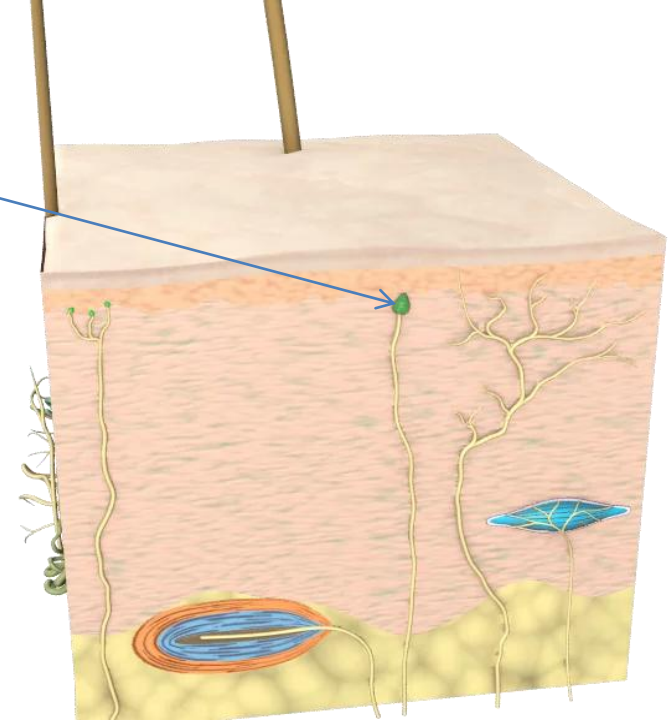
- Surround the bases of hair follicles in reticular dermis
- Detect movements of hair

Unencapsulated nerve receptors



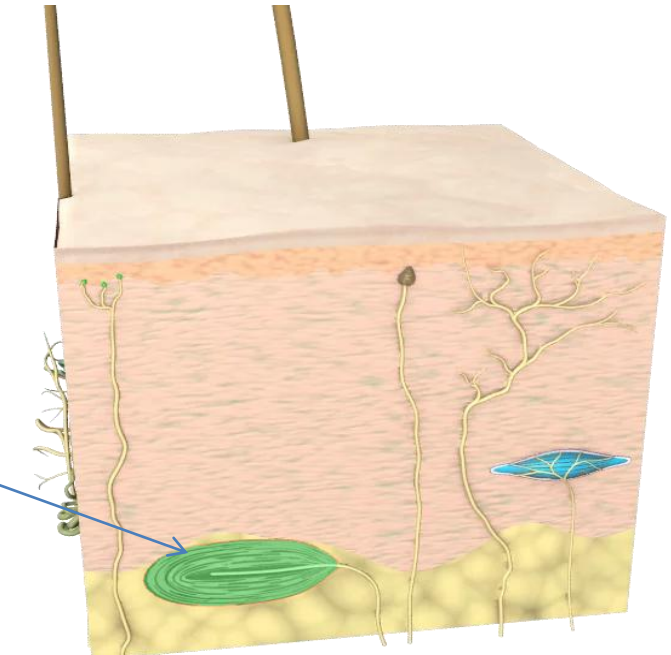
Meissner corpuscles:

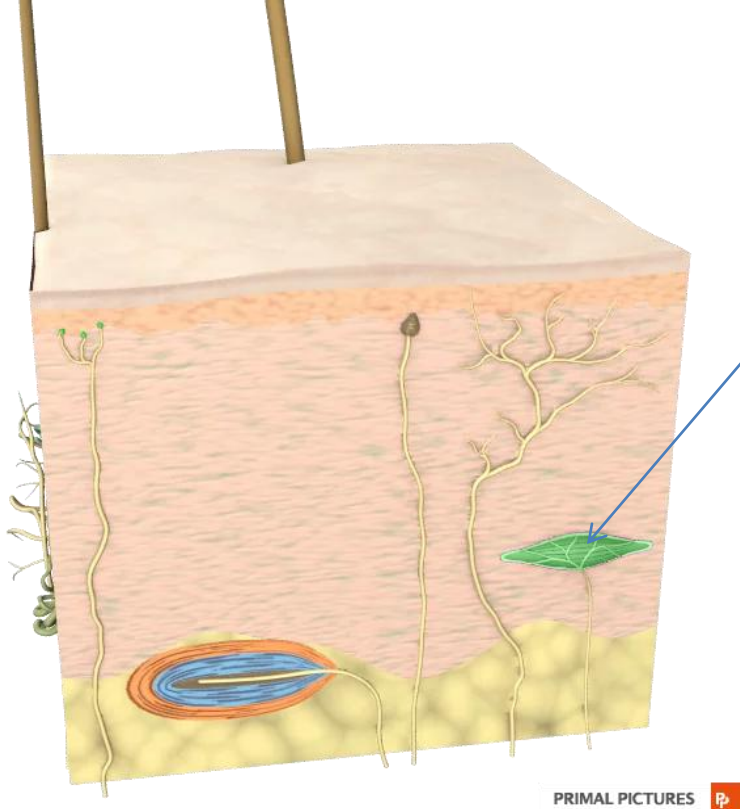
- Encapsulated
- In the dermal papilla
- Light touch
- Are numerous in fingertips, palms and soles
- Decline in number with aging



Pacinian corpuscles

- Encapsulated
- Found deep in reticular dermis and hypodermis
- Coarse touch, pressure (sustained touch) and vibrations





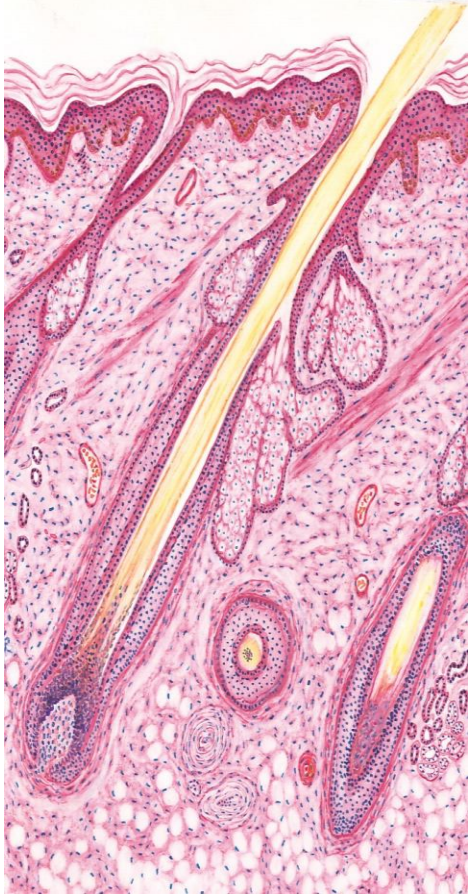Ruffini corpuscles:

- Encapsulated
- Stretch (tension) and twisting (torque)

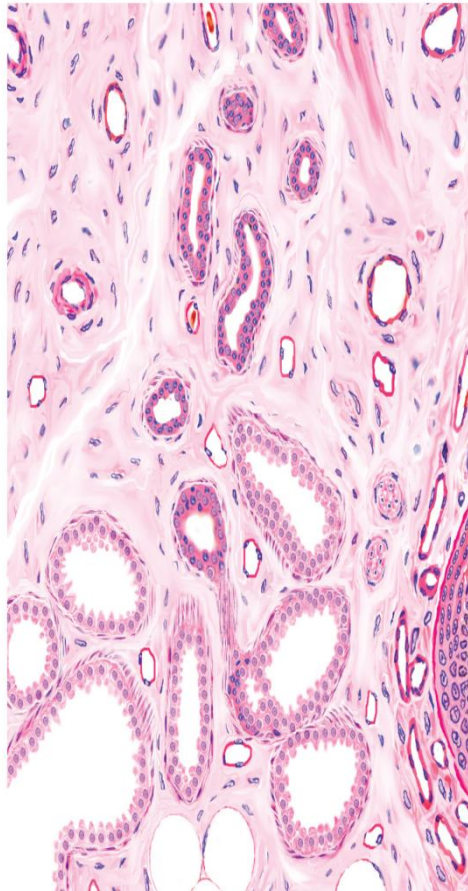
PRIMAL PICTURES 

Skin Appendages

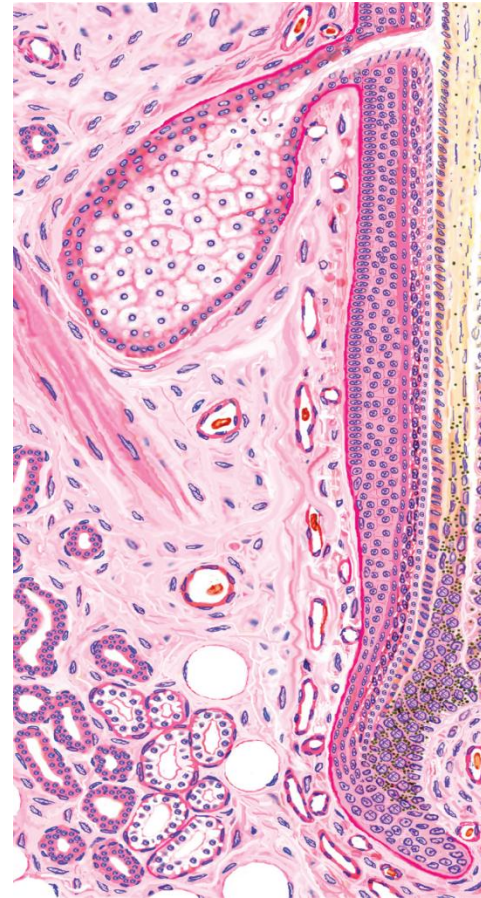
**Hair Follicles
and hair**



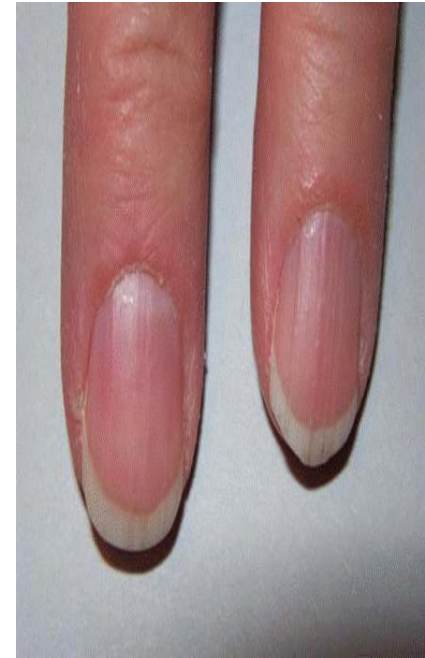Sweat glands



Sebaceous glands



Nails



Hairs are elongated keratinized structures that form within epidermal invaginations (hair follicles)

Types of hair:

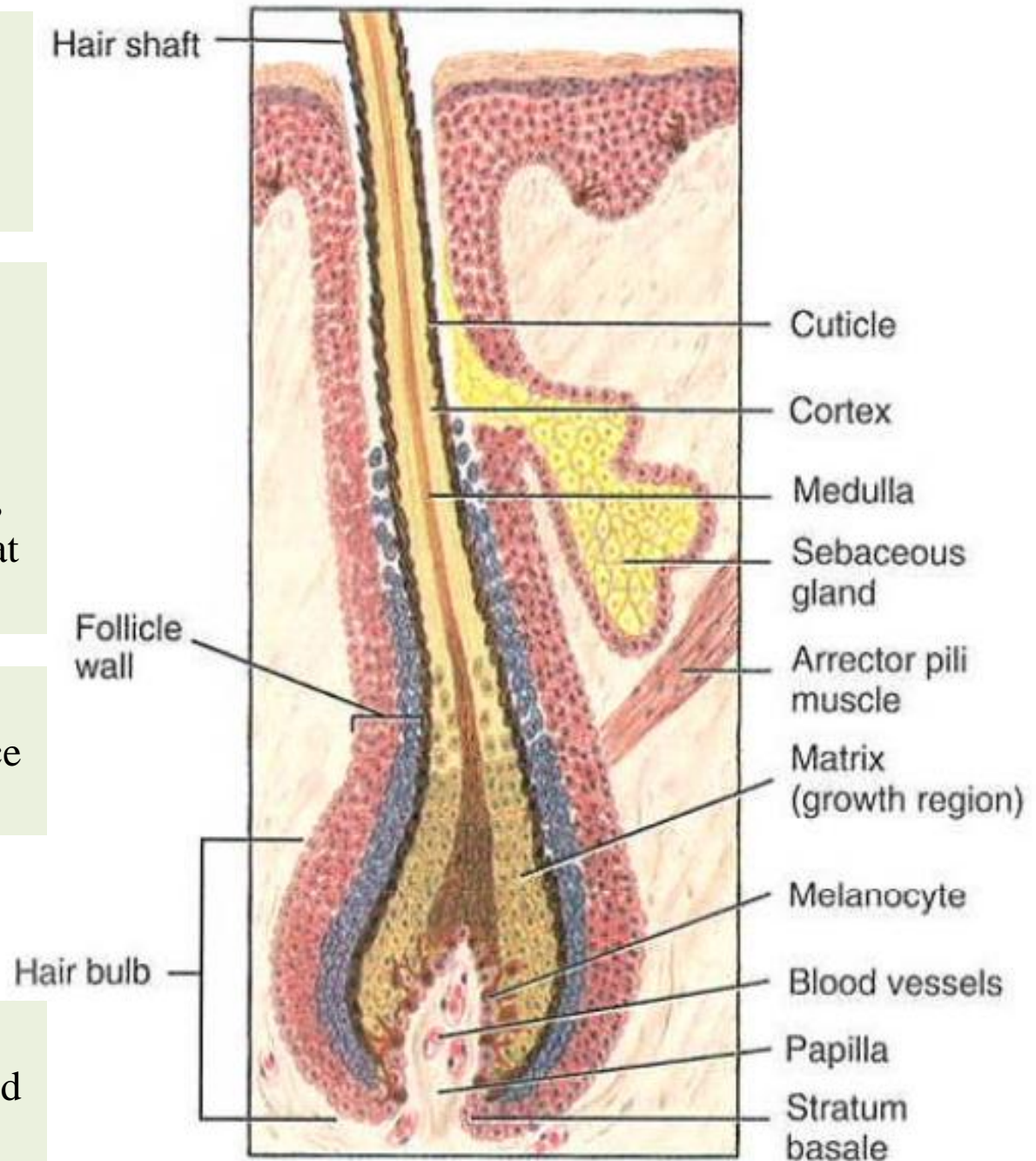
1- Lanugo: fetal hair

2- Down hair: light colored hair of child

3- Terminal (adult) hair: thicker, darker hair that begins to grow at puberty

Hair shaft: The part of a hair extending beyond the skin surface (visible part)

Hair root: The part of a hair below the skin surface (embedded part)



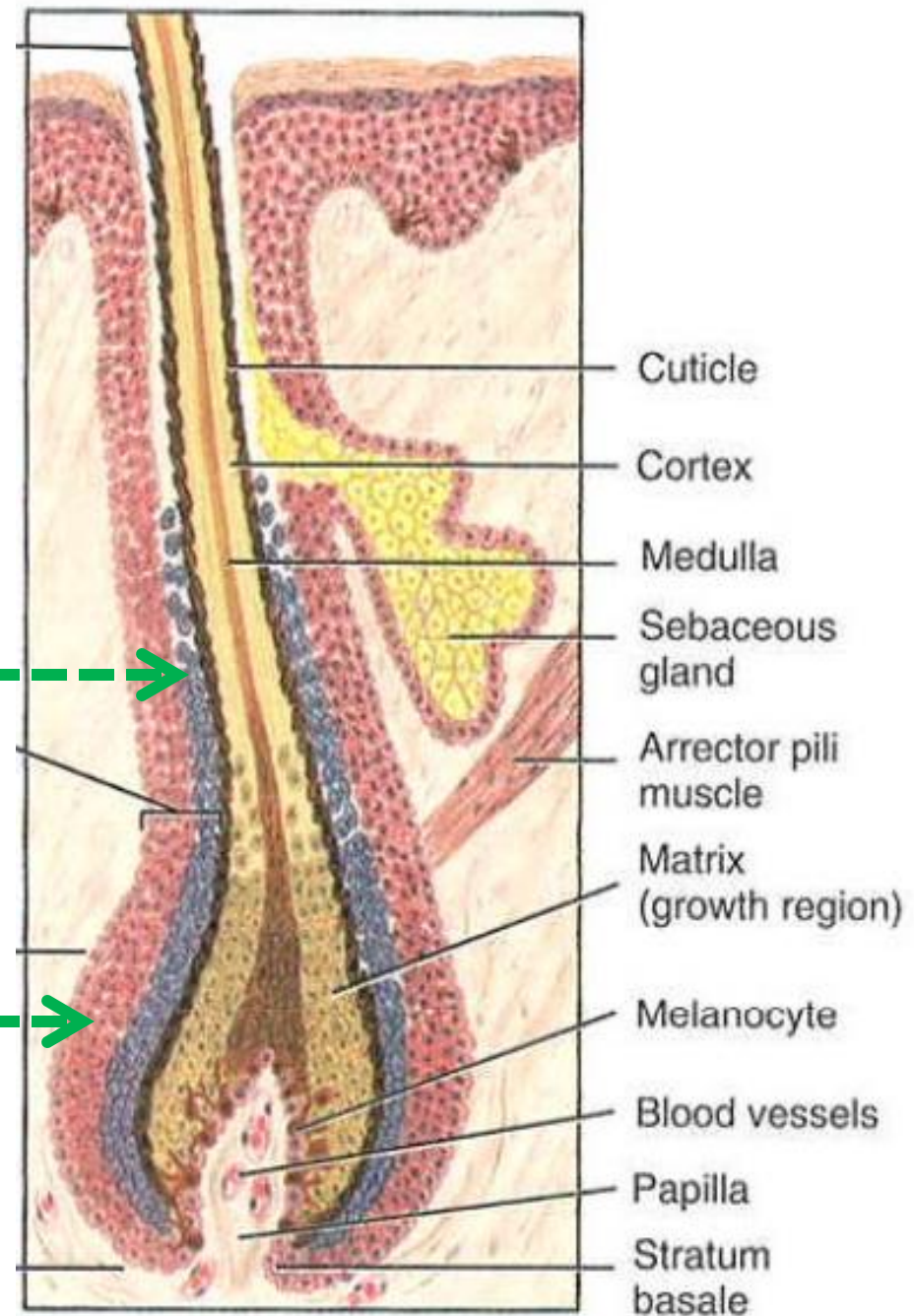
Hair follicle is a tube of stratified squamous epithelium, invaginated into the dermis

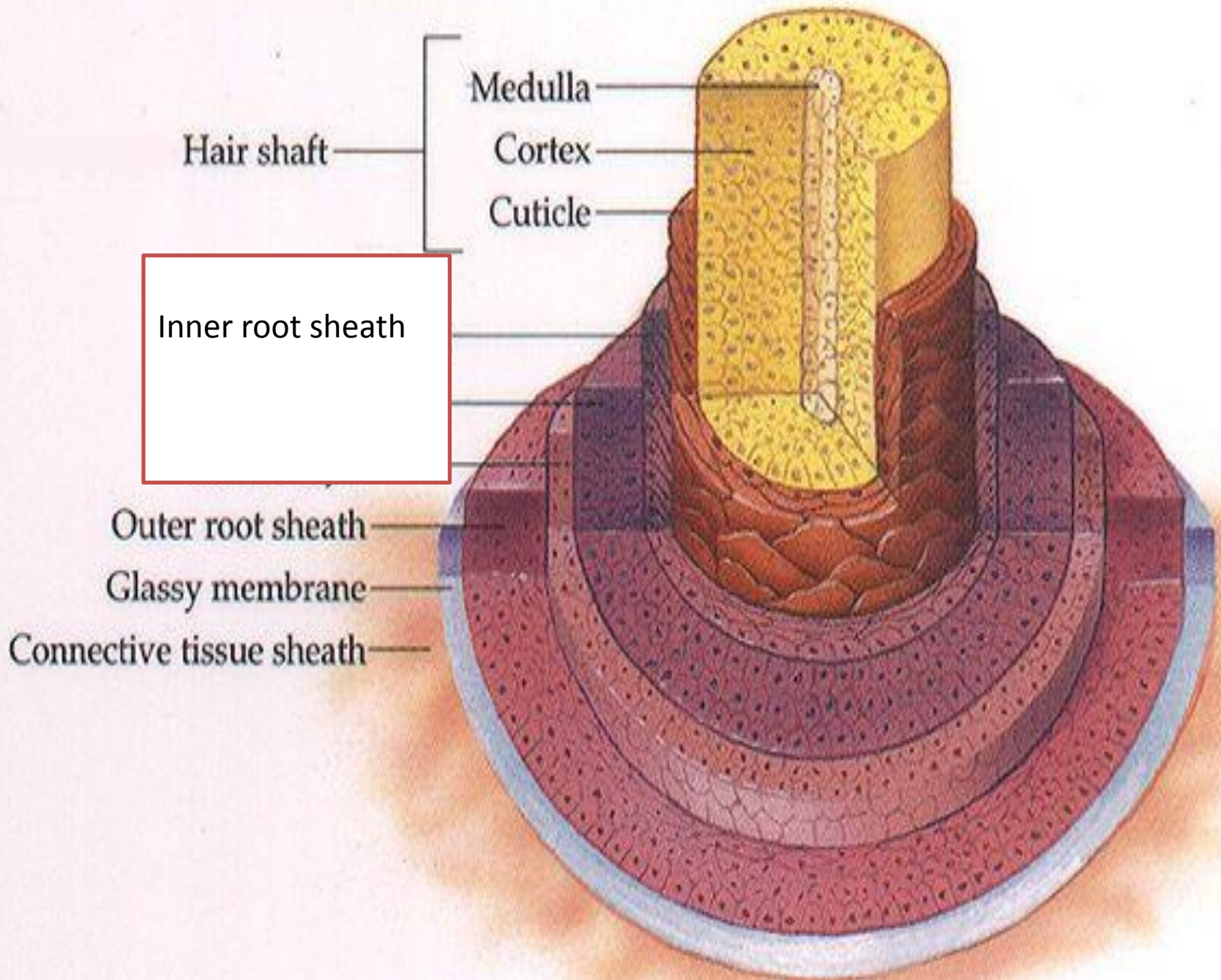
INNER ROOT SHEATH

Disintegrates at the level of the sebaceous gland

OUTER ROOT SHEATH

- Is continuous with the epidermis
- It does not take part in hair formation
- Surrounded by a glassy basement membrane
- Basement membrane is surrounded by a connective tissue sheath.

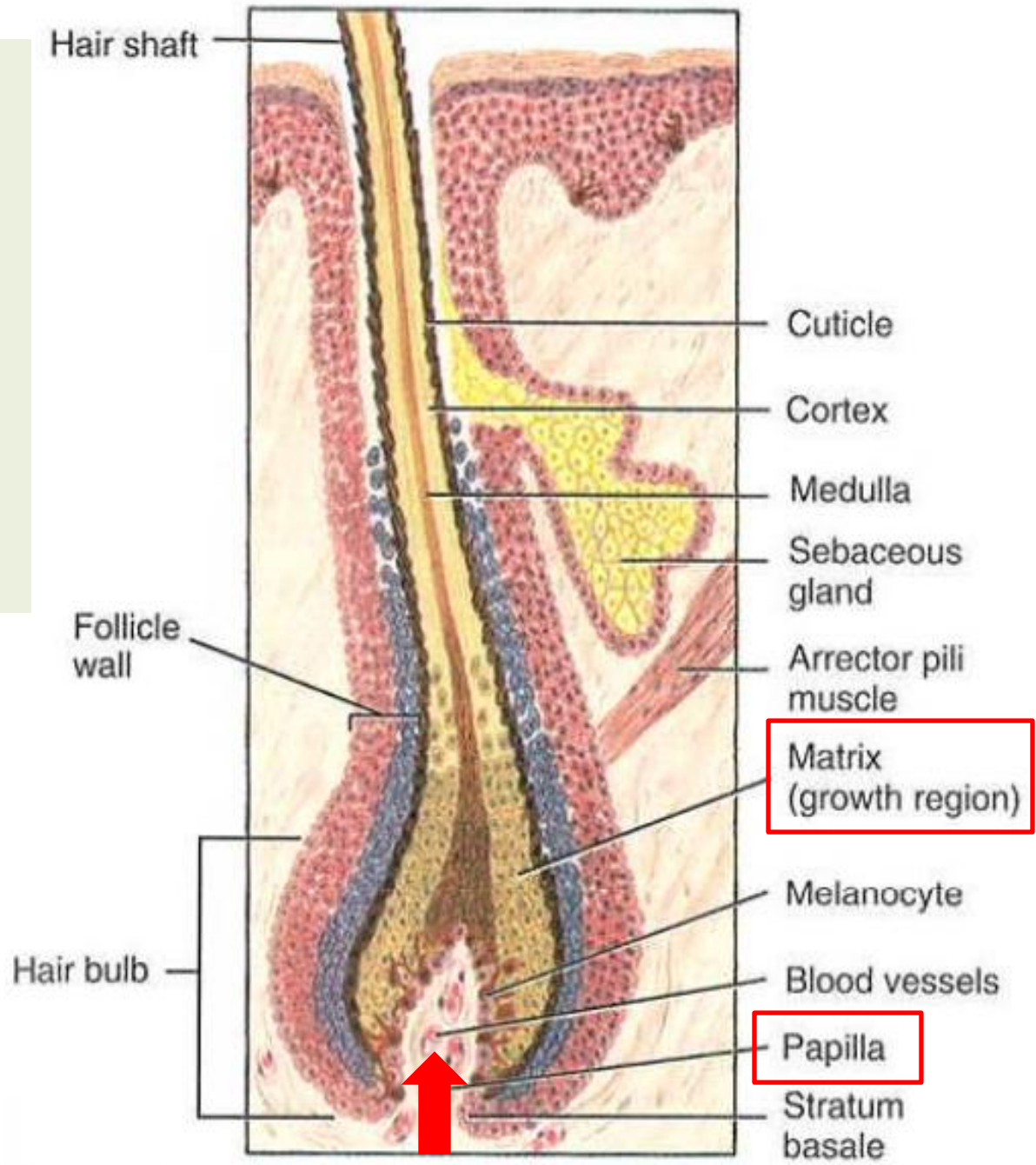




Hair matrix

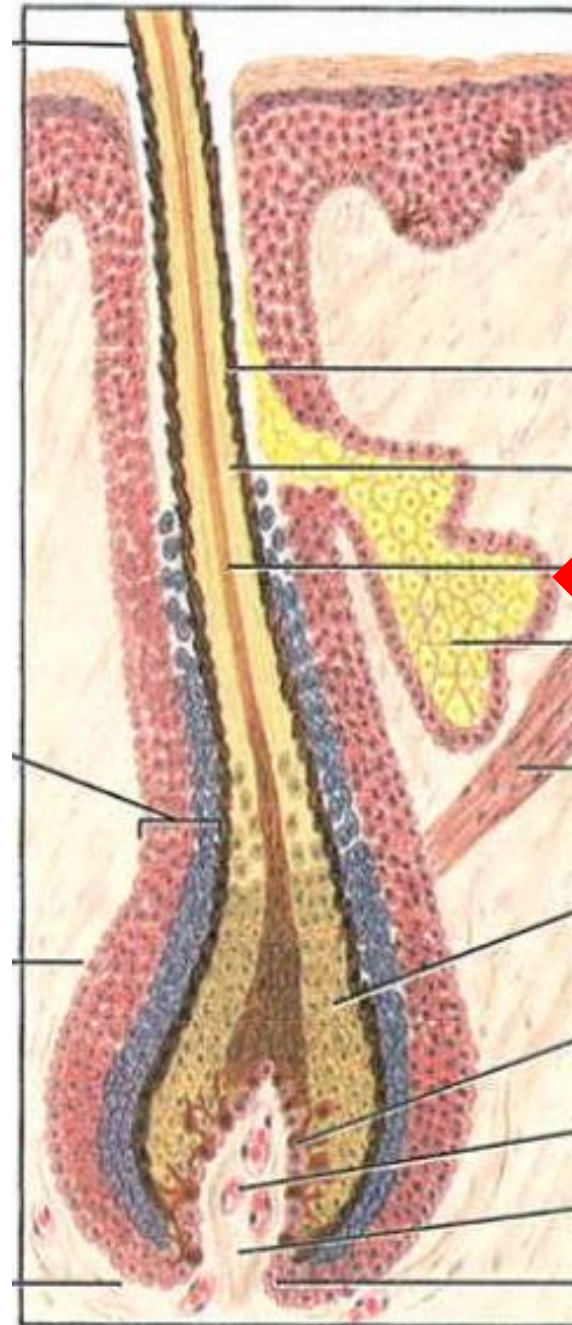
- Contains the proliferating cells that generate the hair and the internal root sheath
- Located just above the dermal papilla
- Melanocytes located in the matrix produce hair color.

The cells in the hair matrix proliferate and move upwards, gradually becoming keratinized to produce the hair.

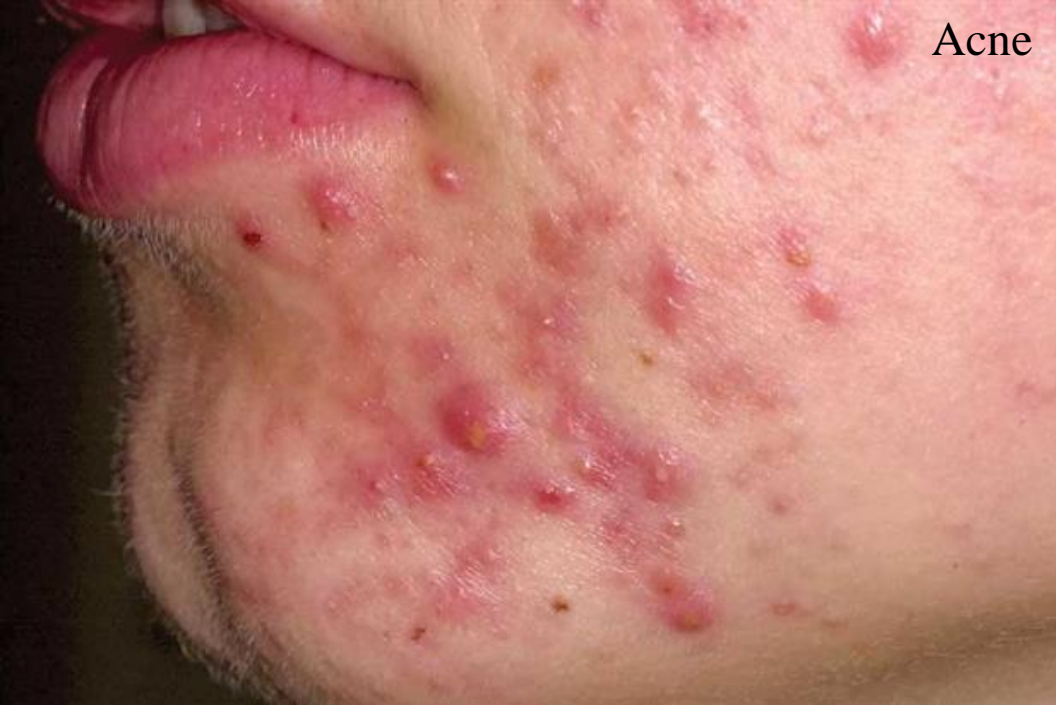

Sebaceous glands

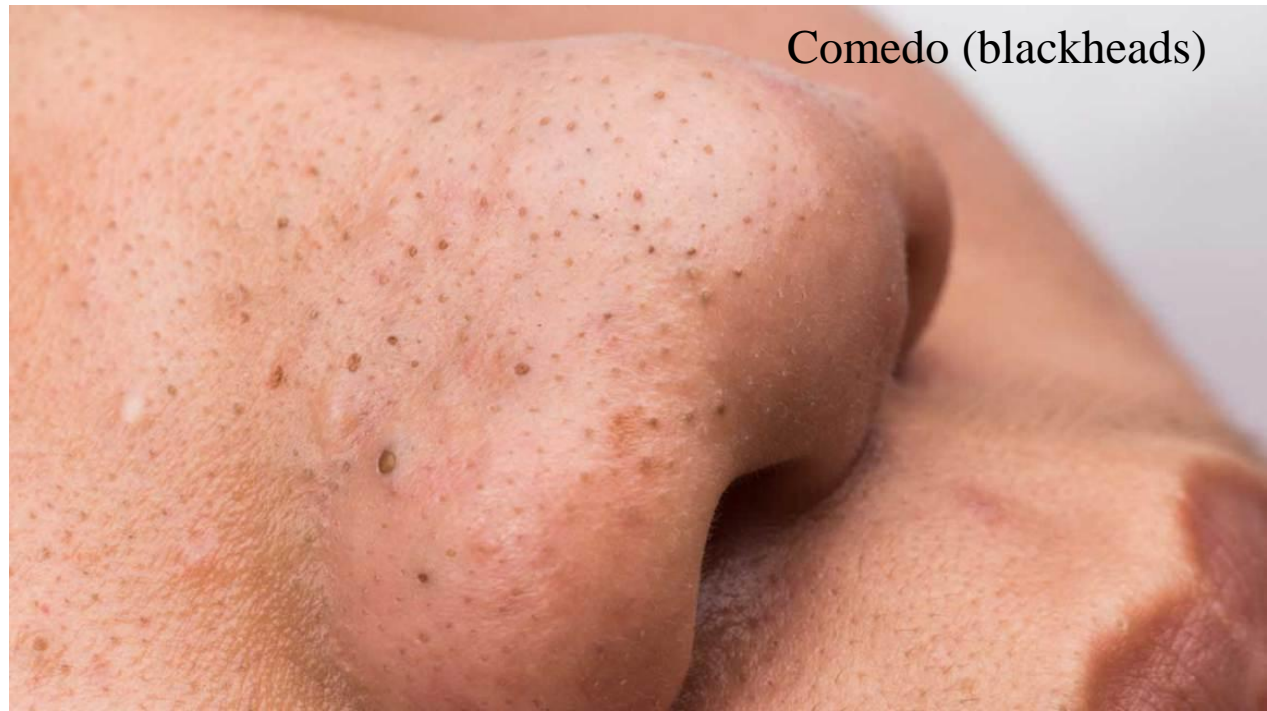- secrete an oily or waxy matter, called **sebum**, to lubricate and waterproof the skin and hair
- Secrete by holocrine mode of secretion



Acne

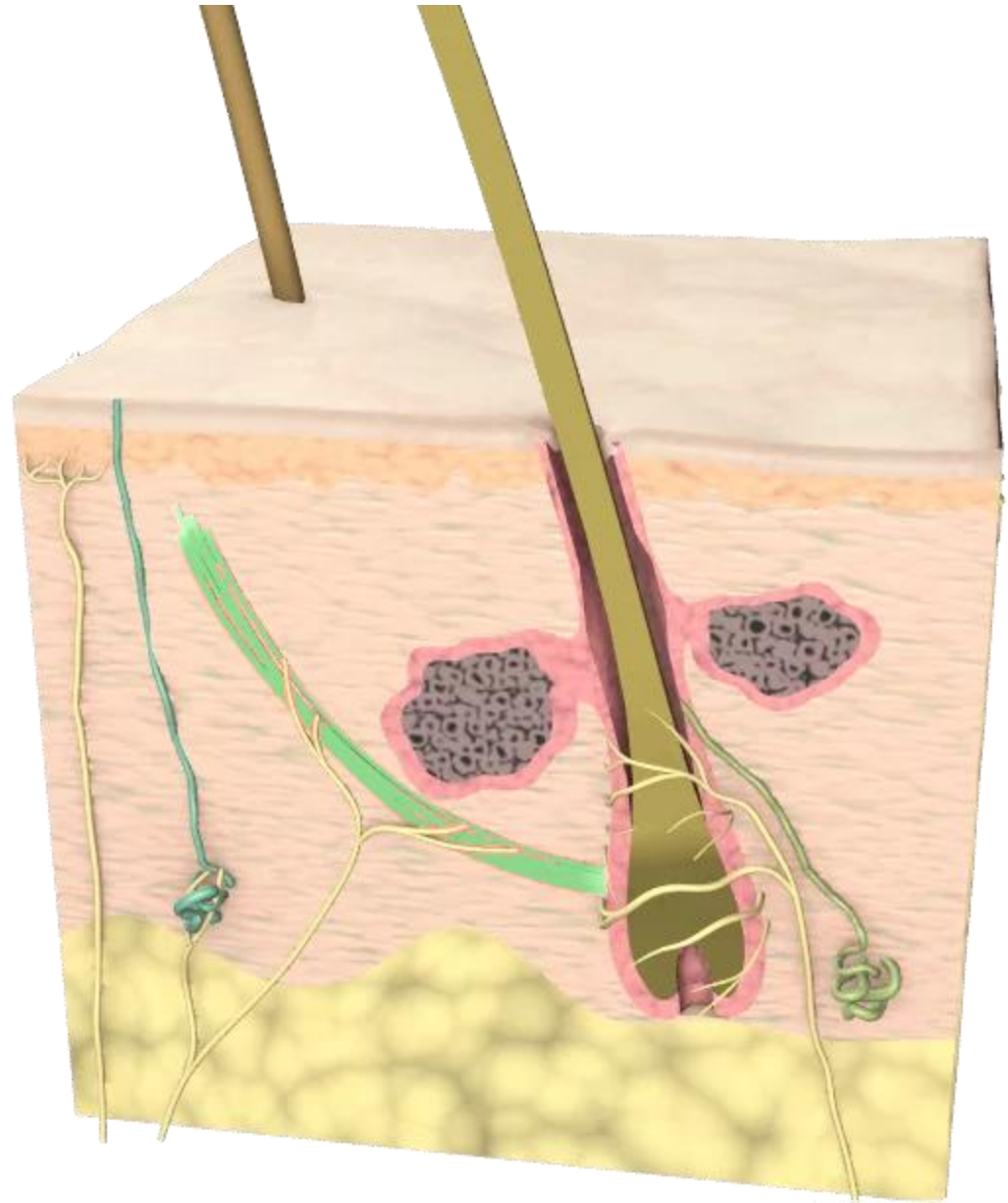
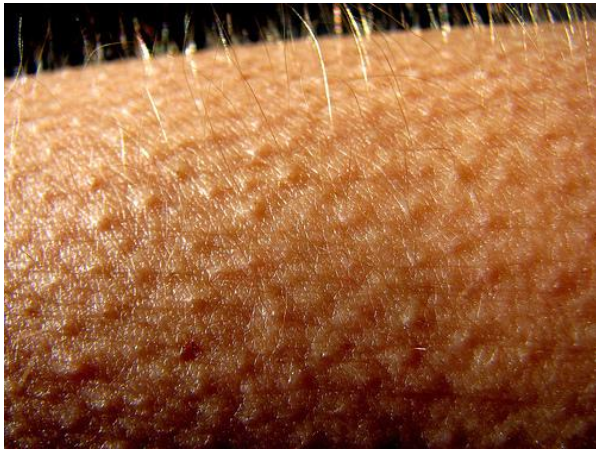

Comedo (blackheads)



A **comedo** is a clogged hair follicle (pore) in the skin. Keratin combines with oil to block the follicle





Pulls hairs upright when cold or frightened

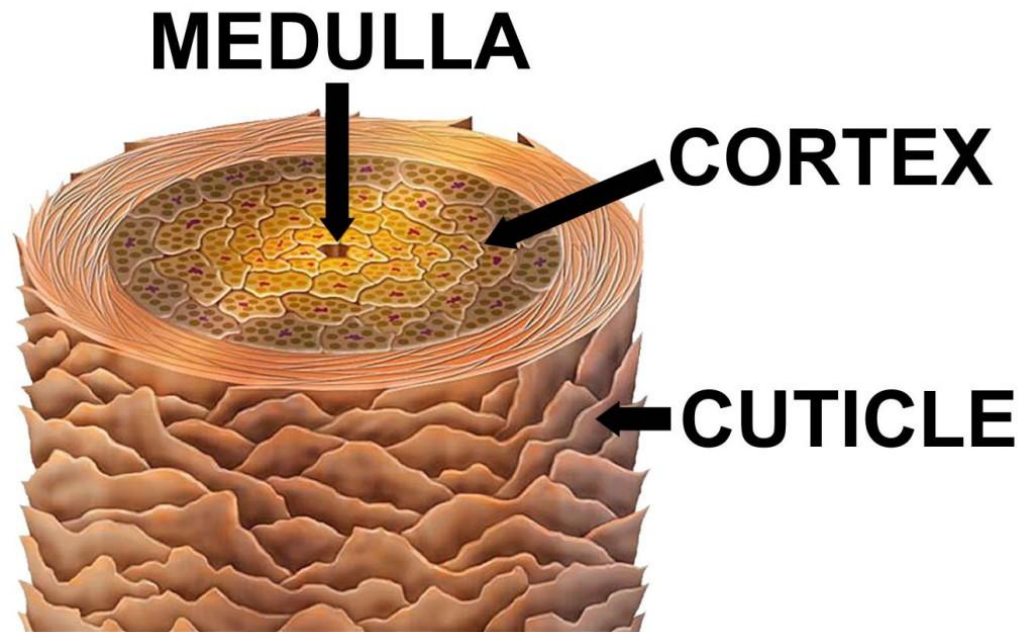


Structure of the hair shaft

Medulla: large vacuolated and moderately keratinized cells

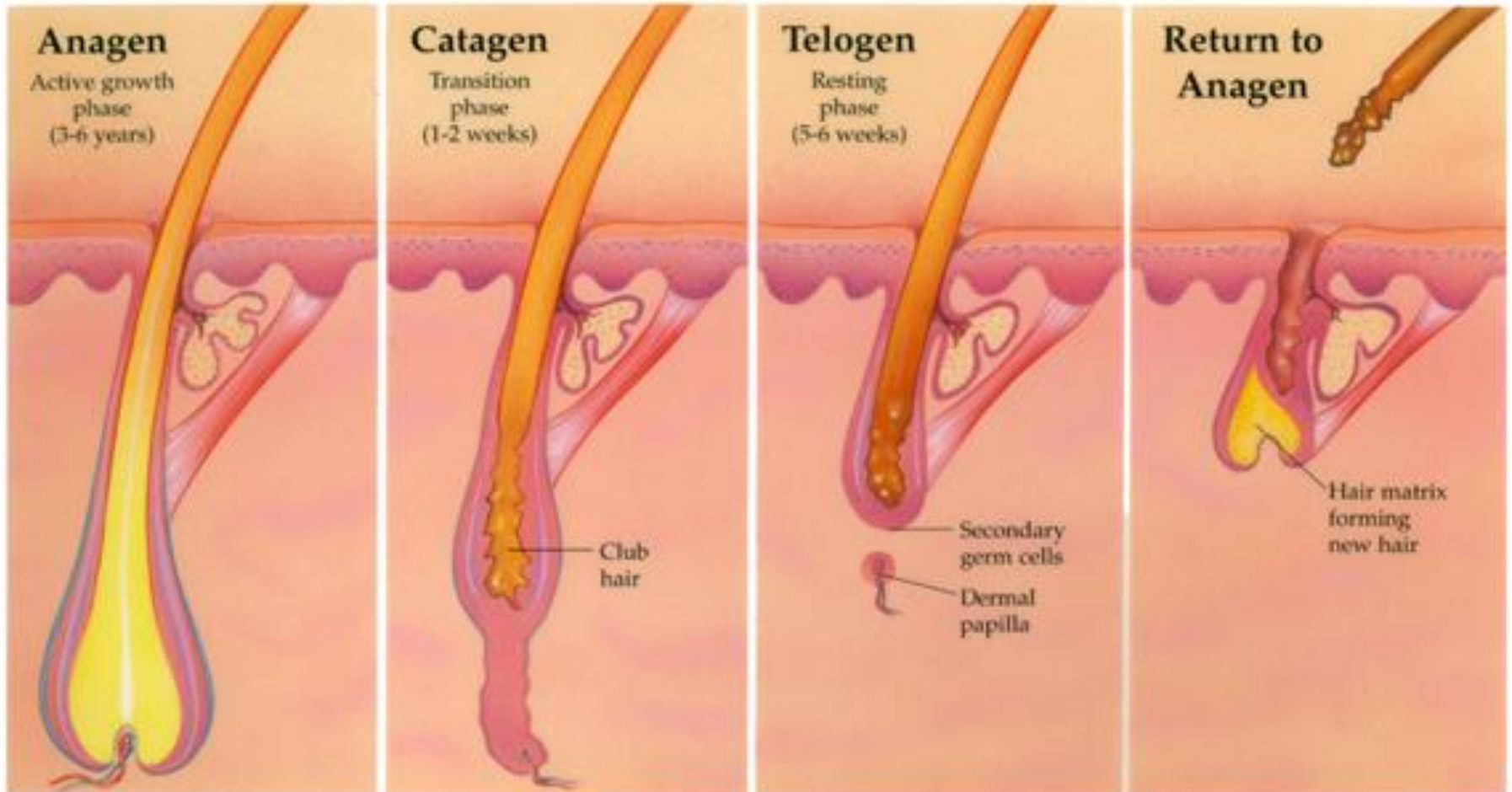
Cortex: heavily keratinized and densely packed cells

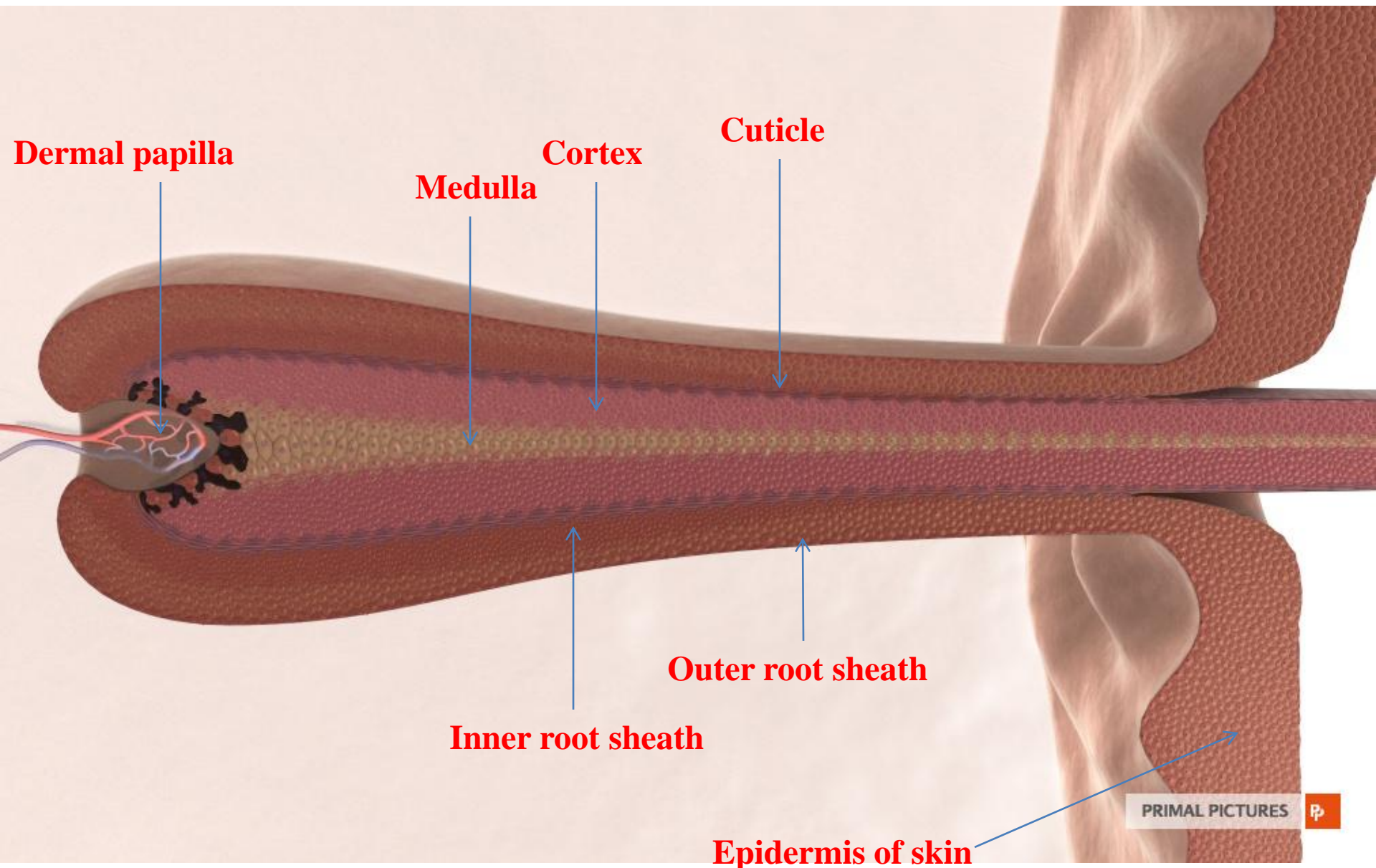
Cuticle: thin layer heavily keratinized squamous cells covering the cortex



Hairs grow discontinuously, with periods of growth followed by periods of rest and this growth does not occur synchronously in all regions of the body or even in the same area

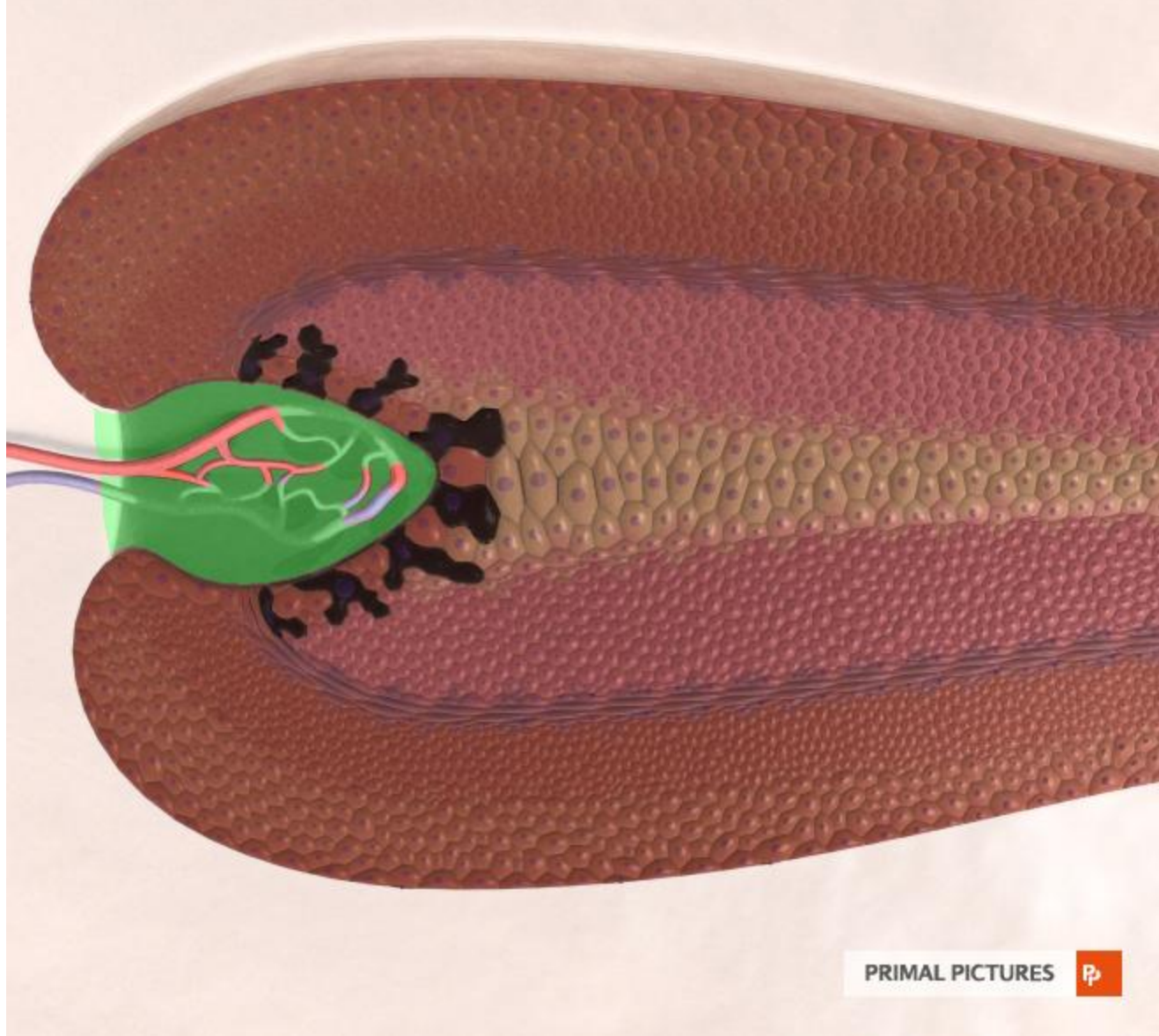
Hair Growth Cycle



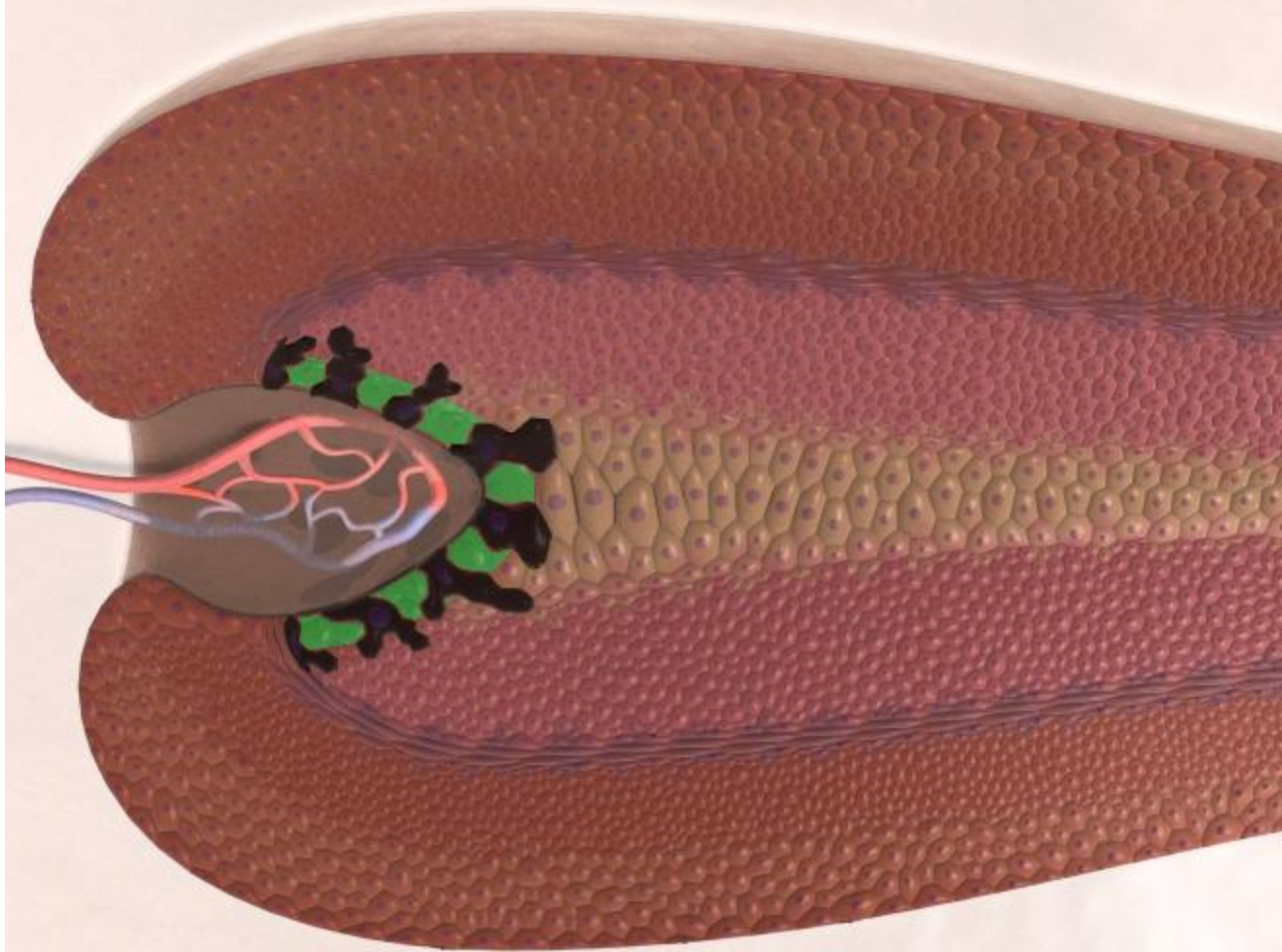

PRIMAL PICTURES 

Dermal papilla

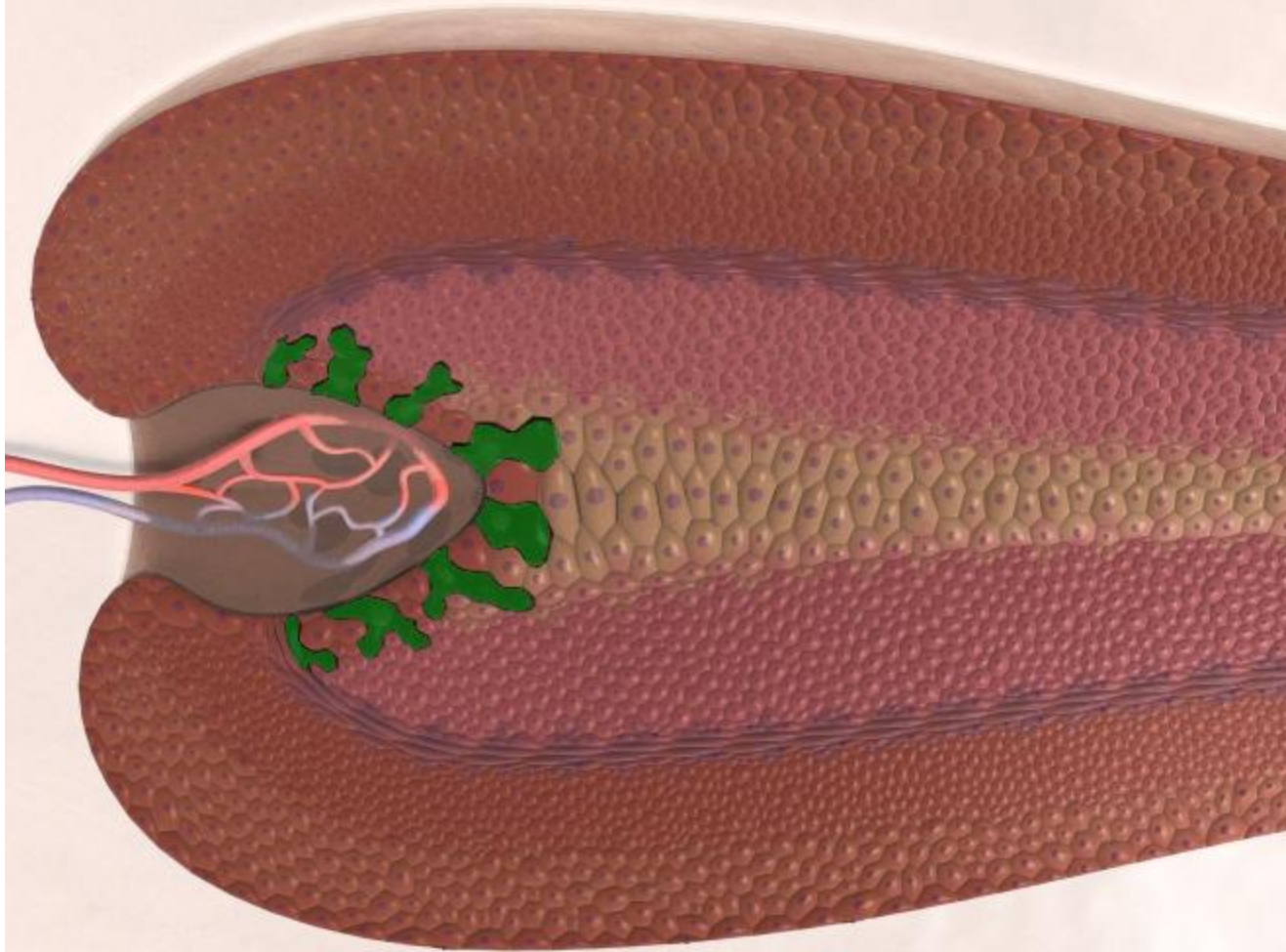


Matrix cells



PRIMAL PICTURES 

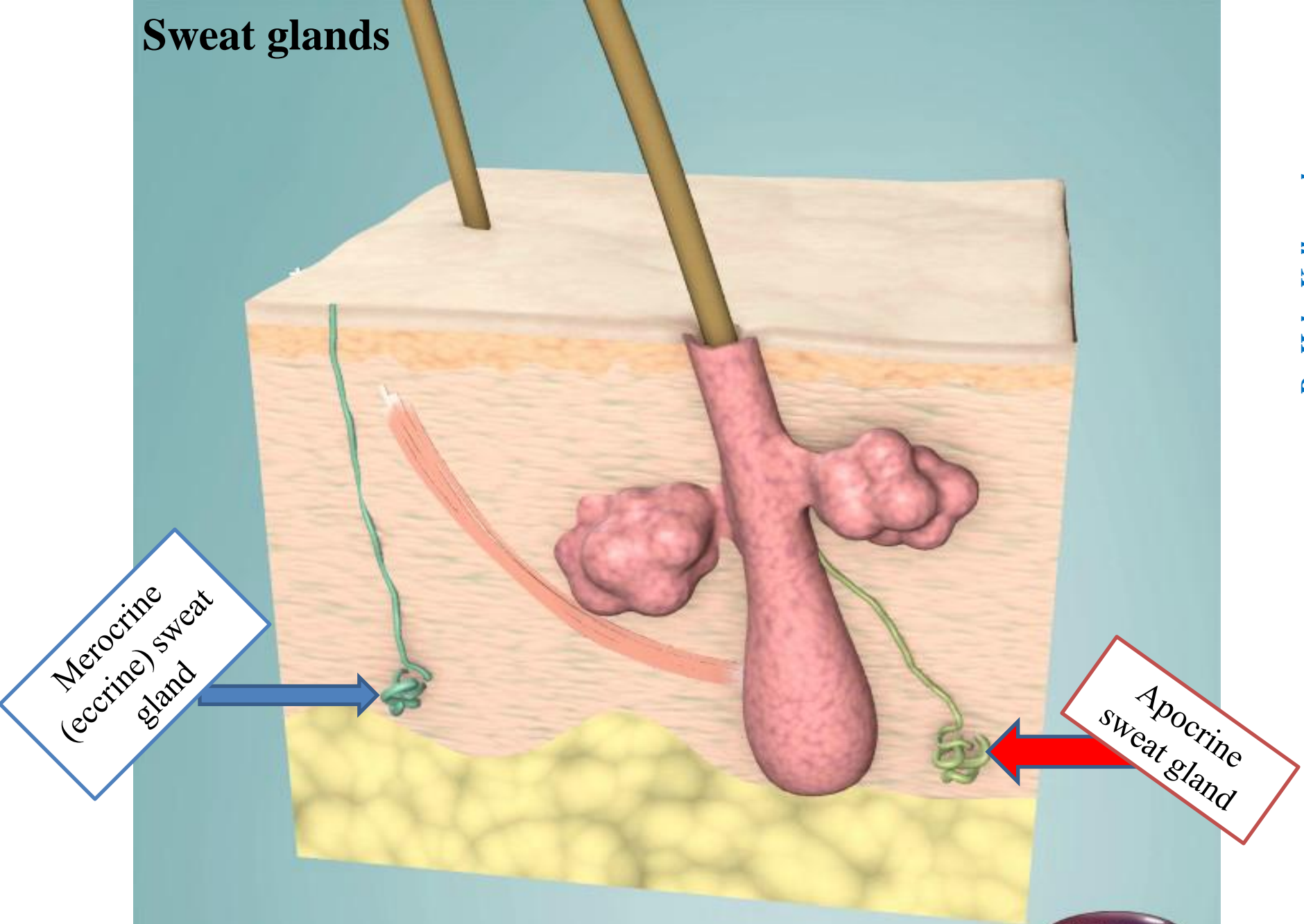
Melanocytes



PRIMAL PICTURES



Sweat glands



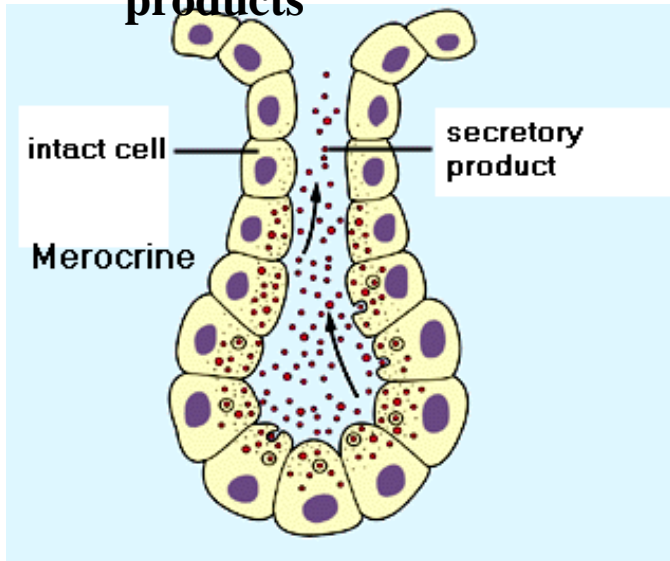
Merocrine
(eccrine) sweat
gland

Apocrine
sweat gland

Sweat Glands

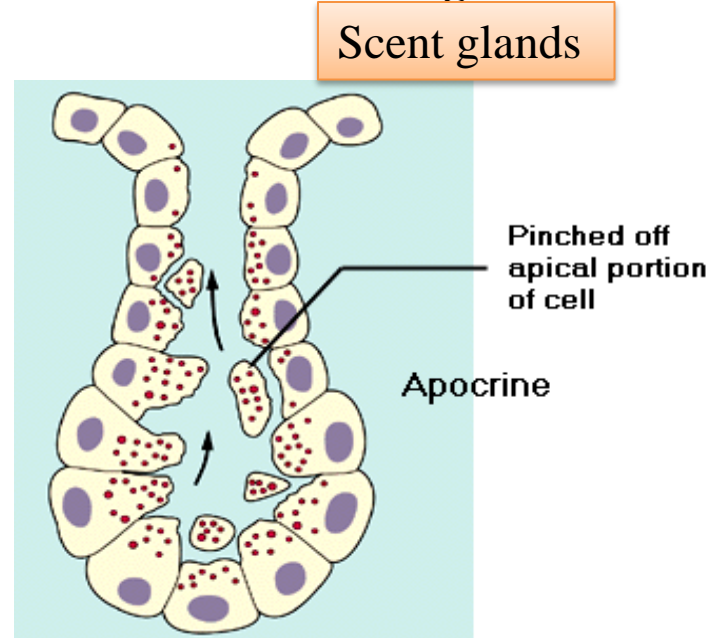
Eccrine sweat gland

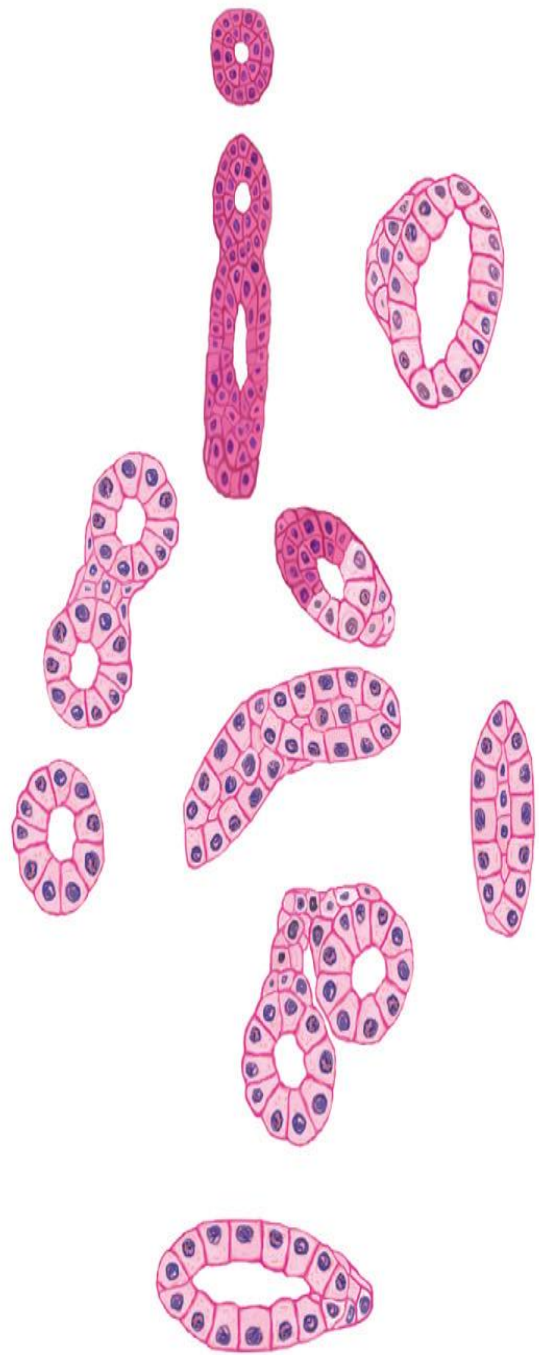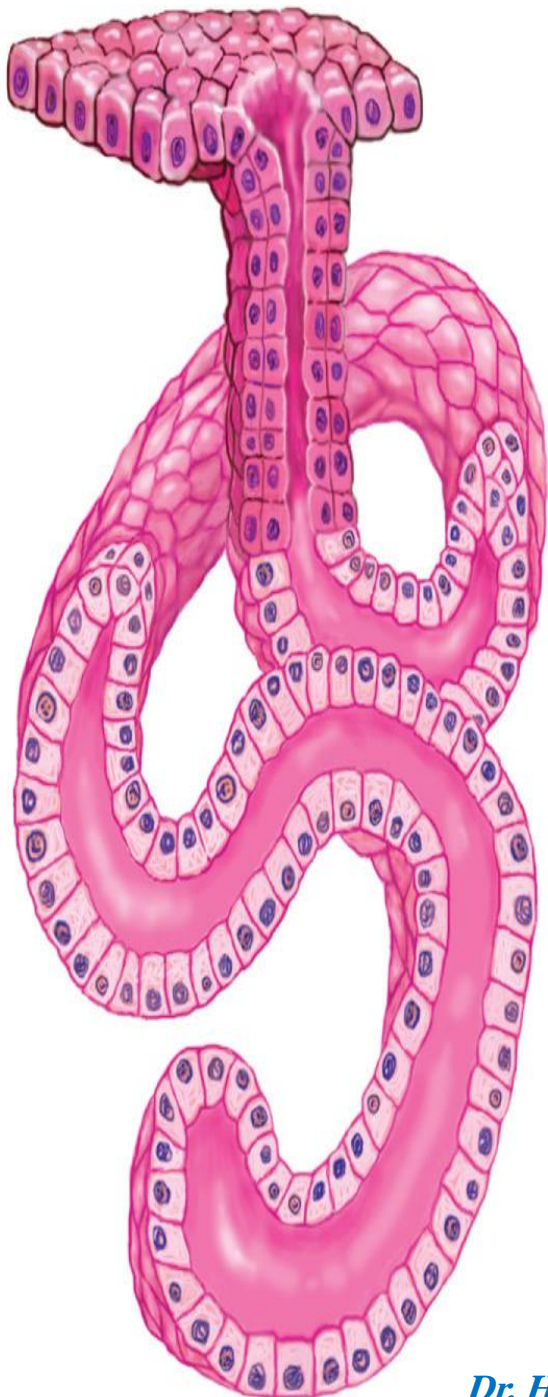
- Merocrine secretion
- Empty directly onto skin surface
- Location: most all over body (esp. abundant on palms & soles: ~ 500/cm²)
- Clear, watery secretion (99% H₂O; rest NaCl + some waste products)



Apocrine sweat gland

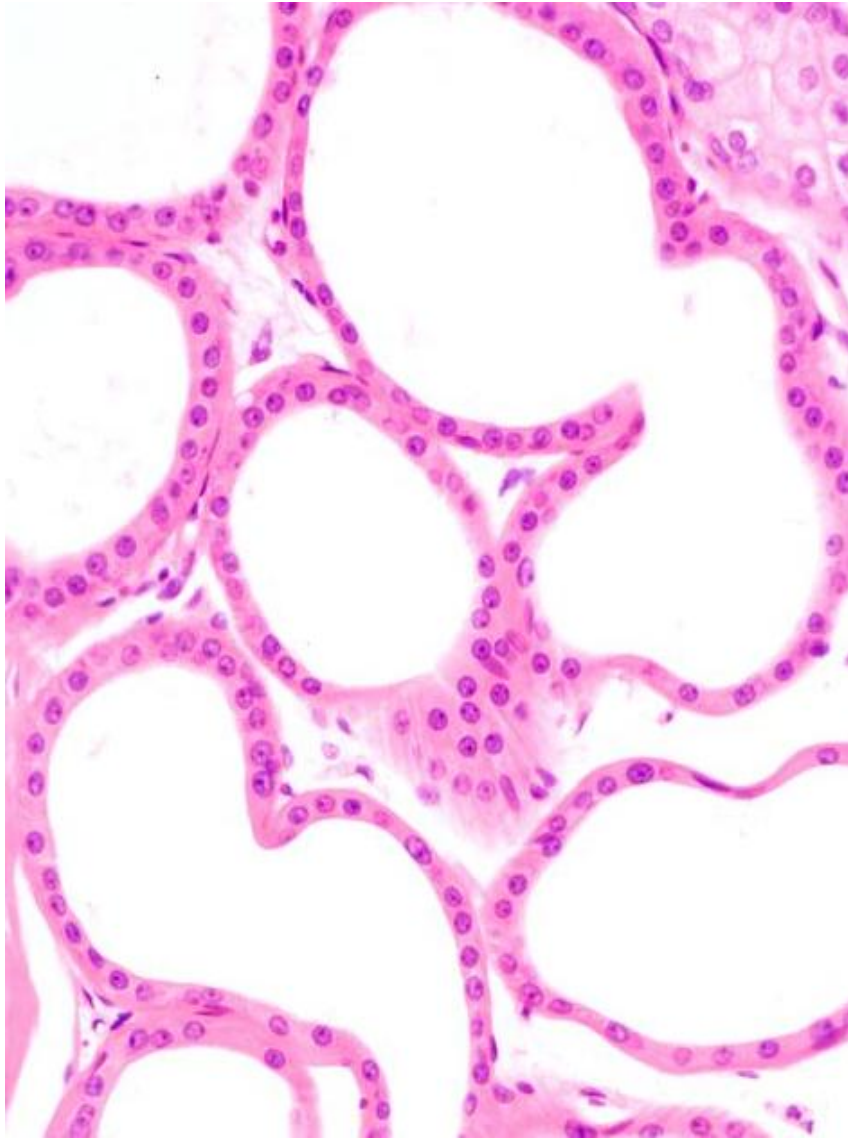
- Empty into hair follicle
- Location: armpits, groin, nipples
- Viscous, cloudy secretion → good nutrient source for bacteria (odor !!)
- Secretion may contain Pheromones
- Secretion begins at puberty and is stimulated during emotional distress



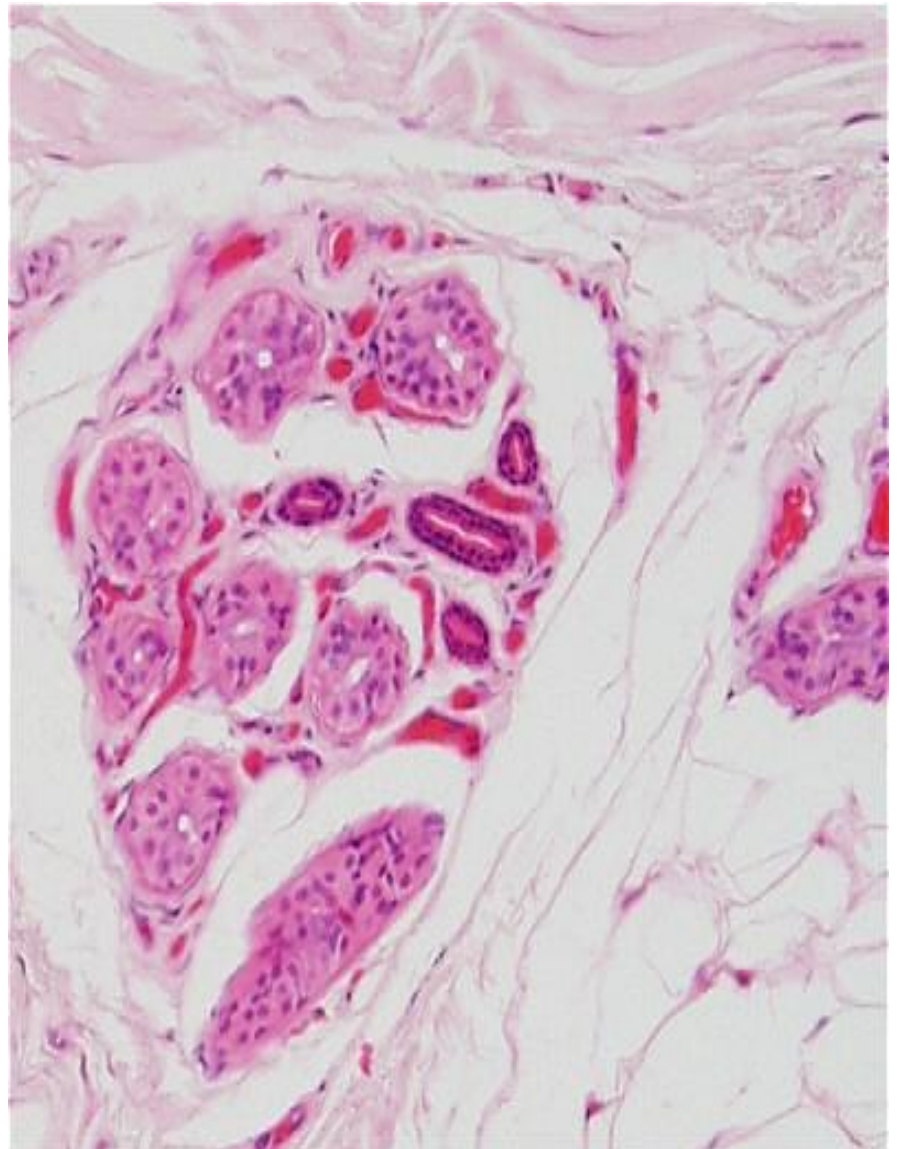


Dr. Heba Kalbouneh

Apocrine sweat glands



Eccrine (merocrine) sweat glands

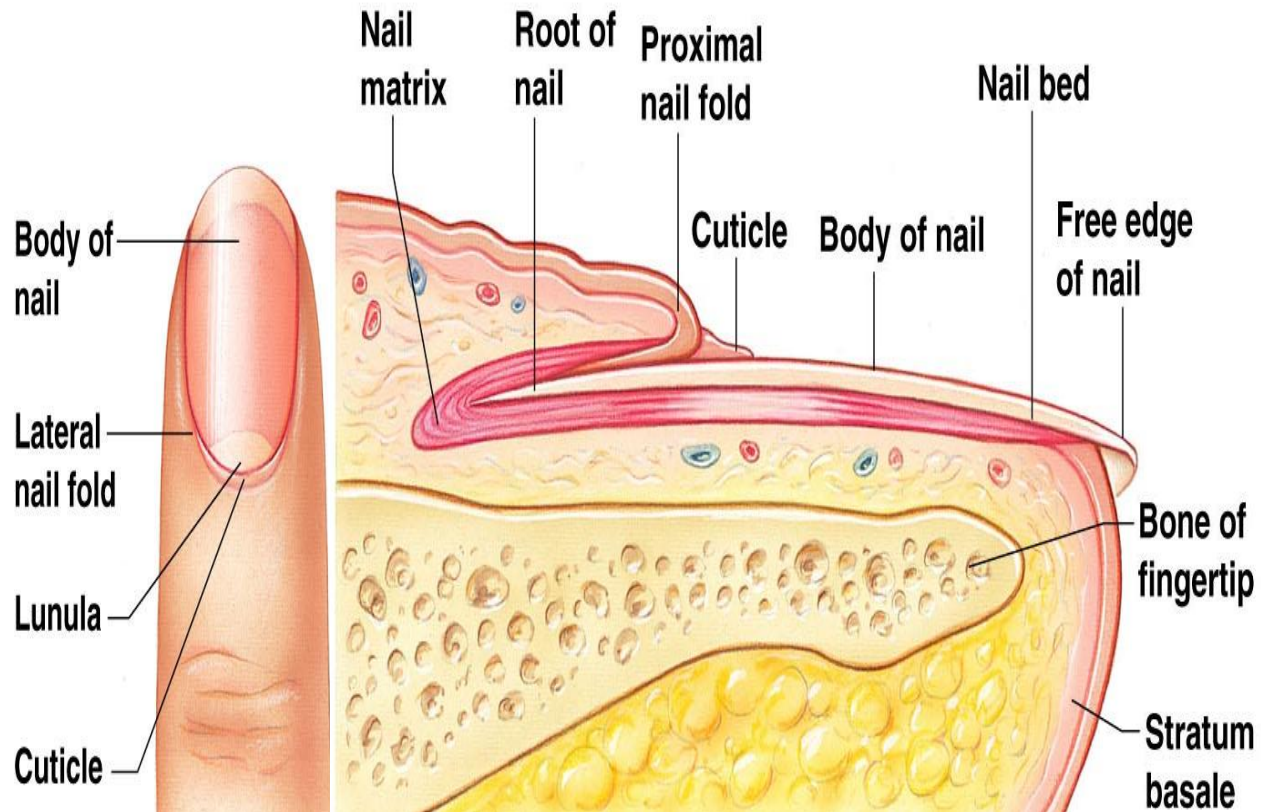


Nails

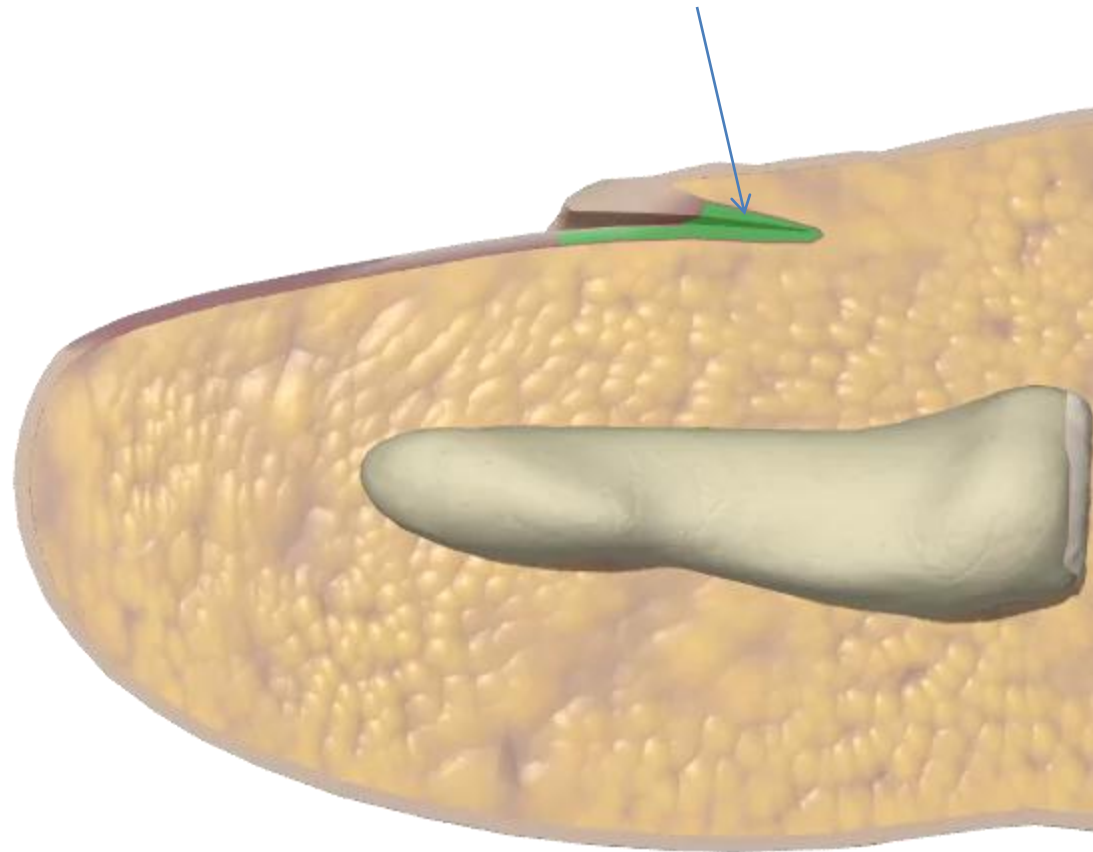
Hard plates of keratin on the dorsal surface of each distal phalanx
Lack of pigment makes them colorless

Nail parts

1. **Free edge**: the part you cut
2. **Body**: pink part
3. **Lunula**: white semicircle area
4. **Eponychium**: proximal nail fold (cuticle)
5. **Hyponychium**: under the free edge where dirt accumulates
6. **Nail bed**: directly under the pink part
7. **Nail matrix**: growth

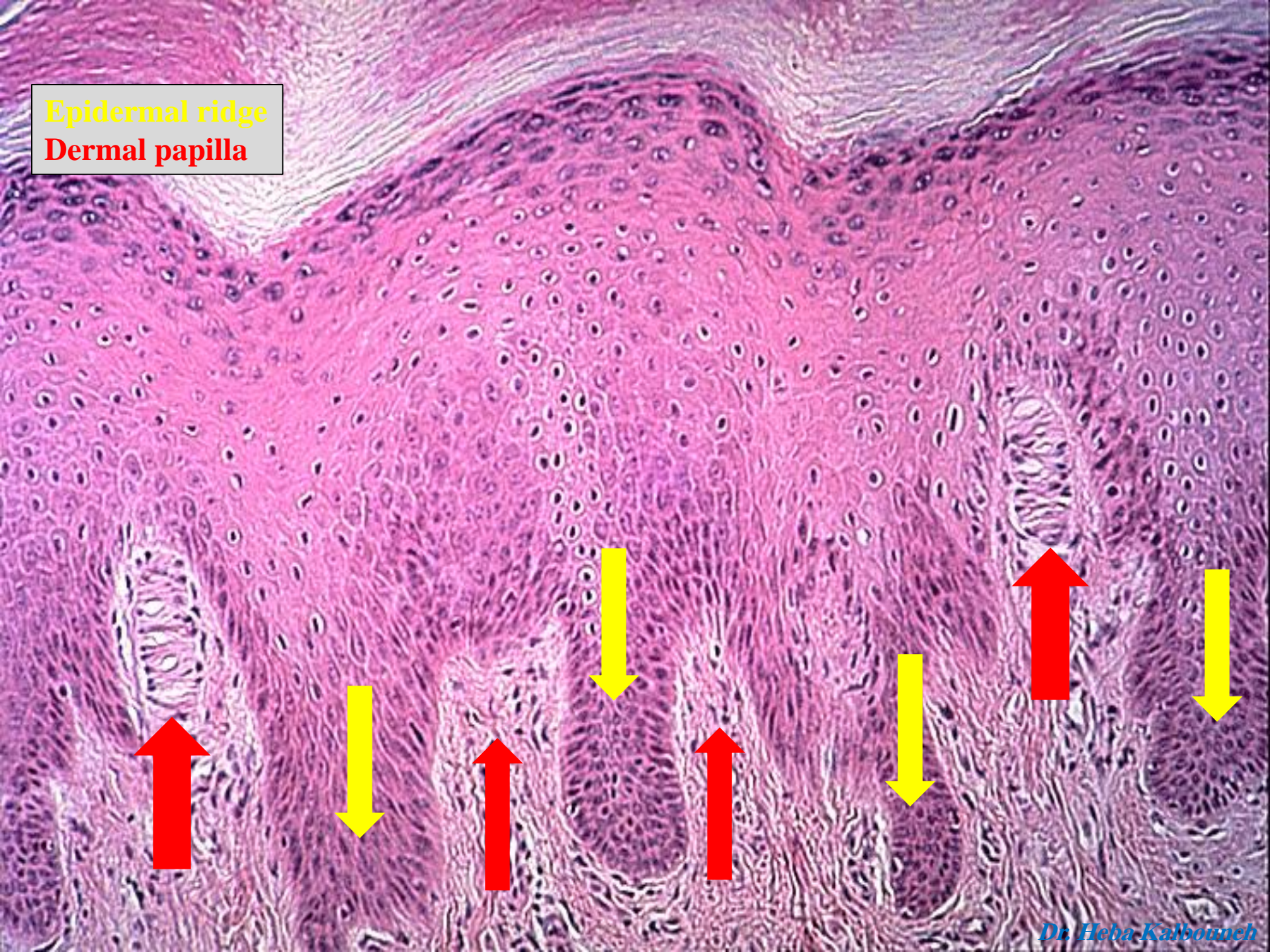


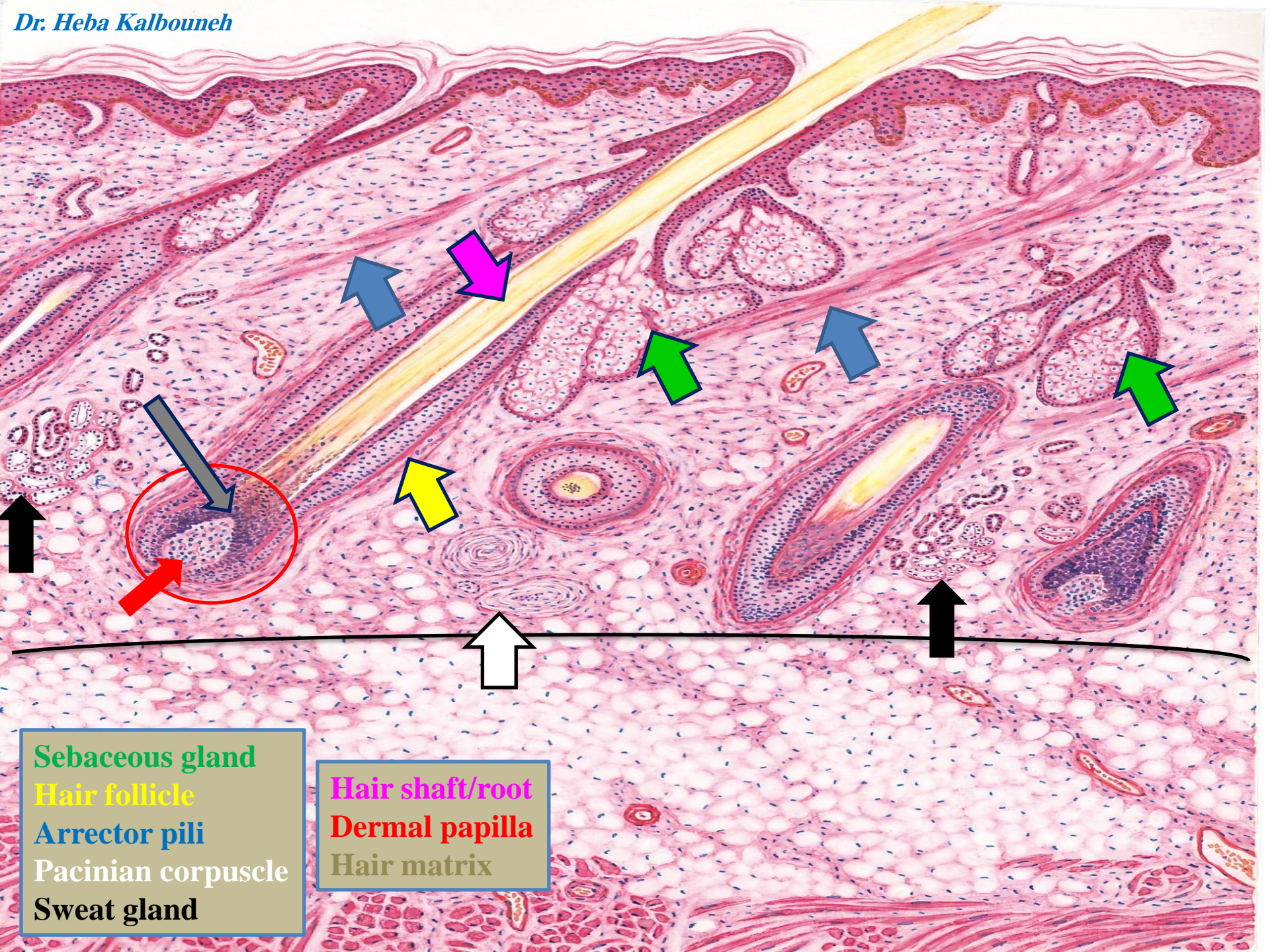
Nail matrix



Practical sections for the exam

Epidermal ridge
Dermal papilla

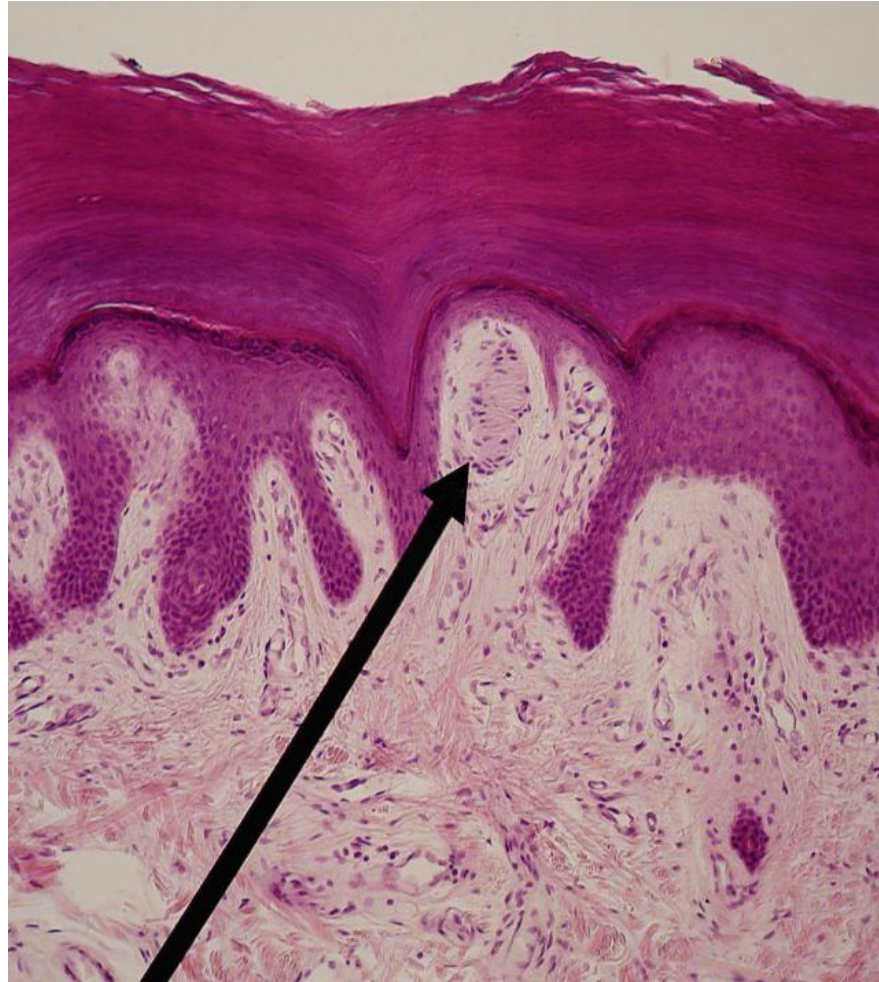




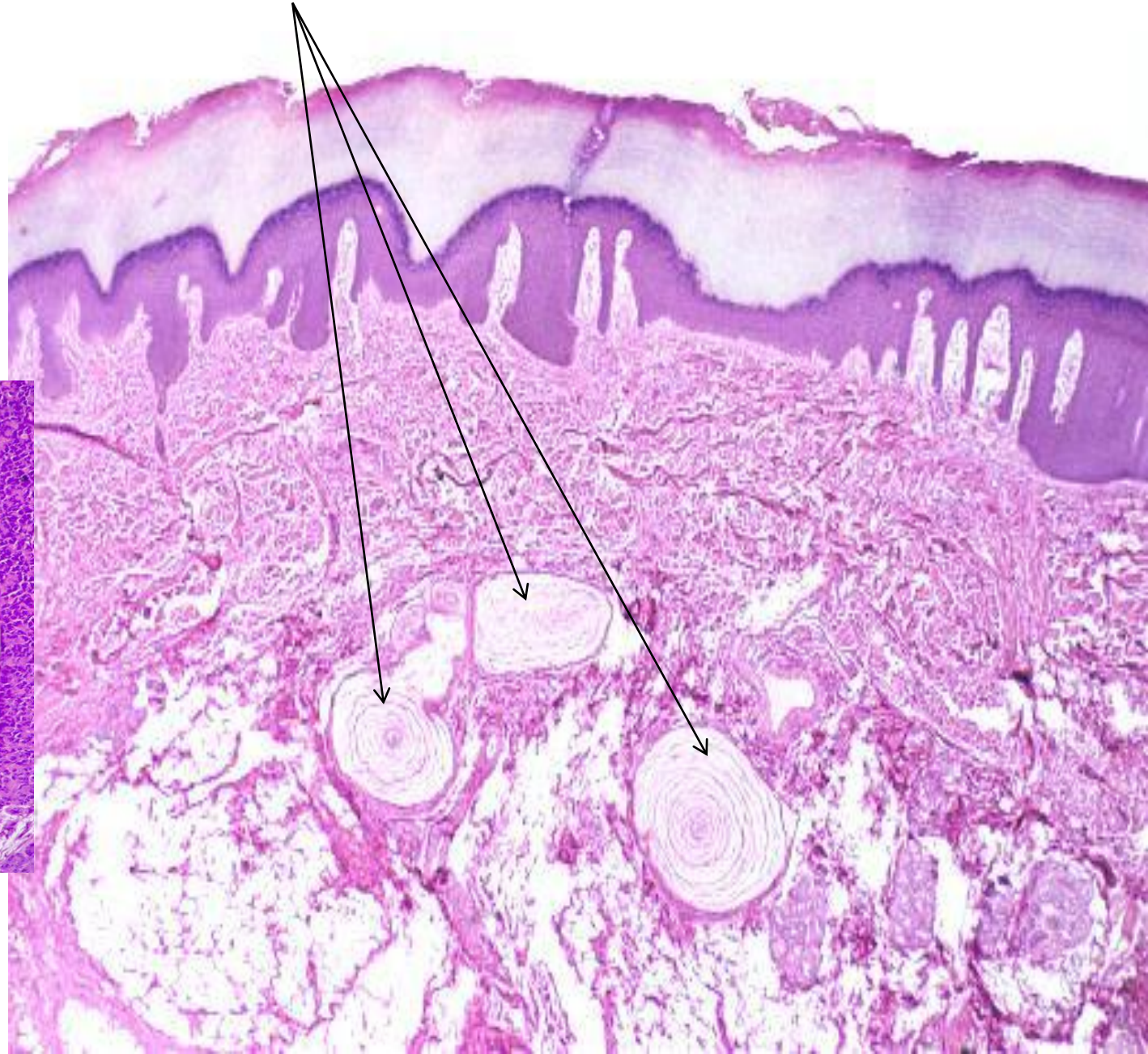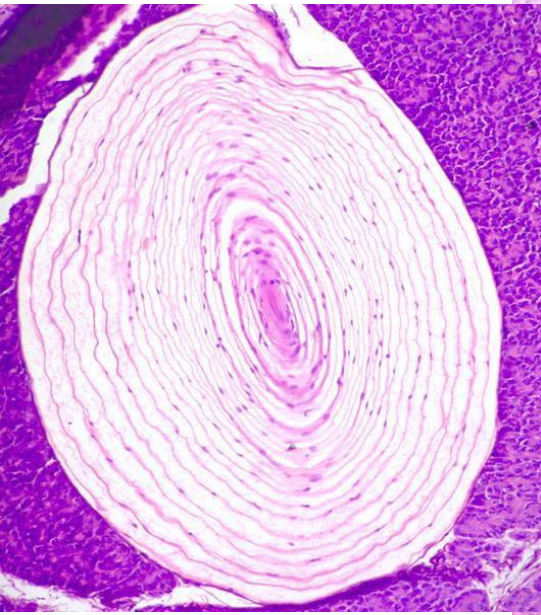
Sebaceous gland
Hair follicle
Arrector pili
Pacinian corpuscle
Sweat gland

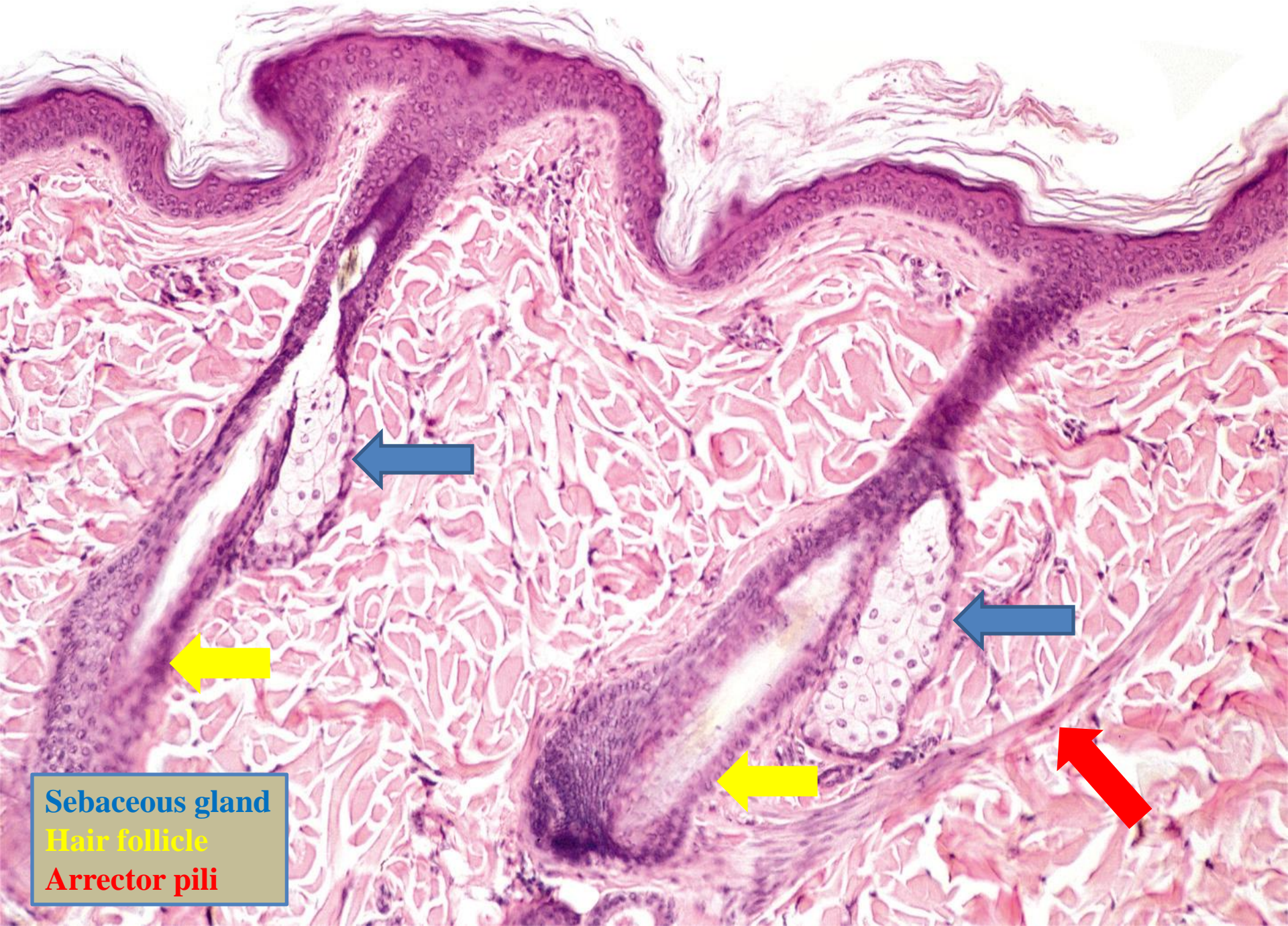
Hair shaft/root
Dermal papilla
Hair matrix

Meissner corpuscle

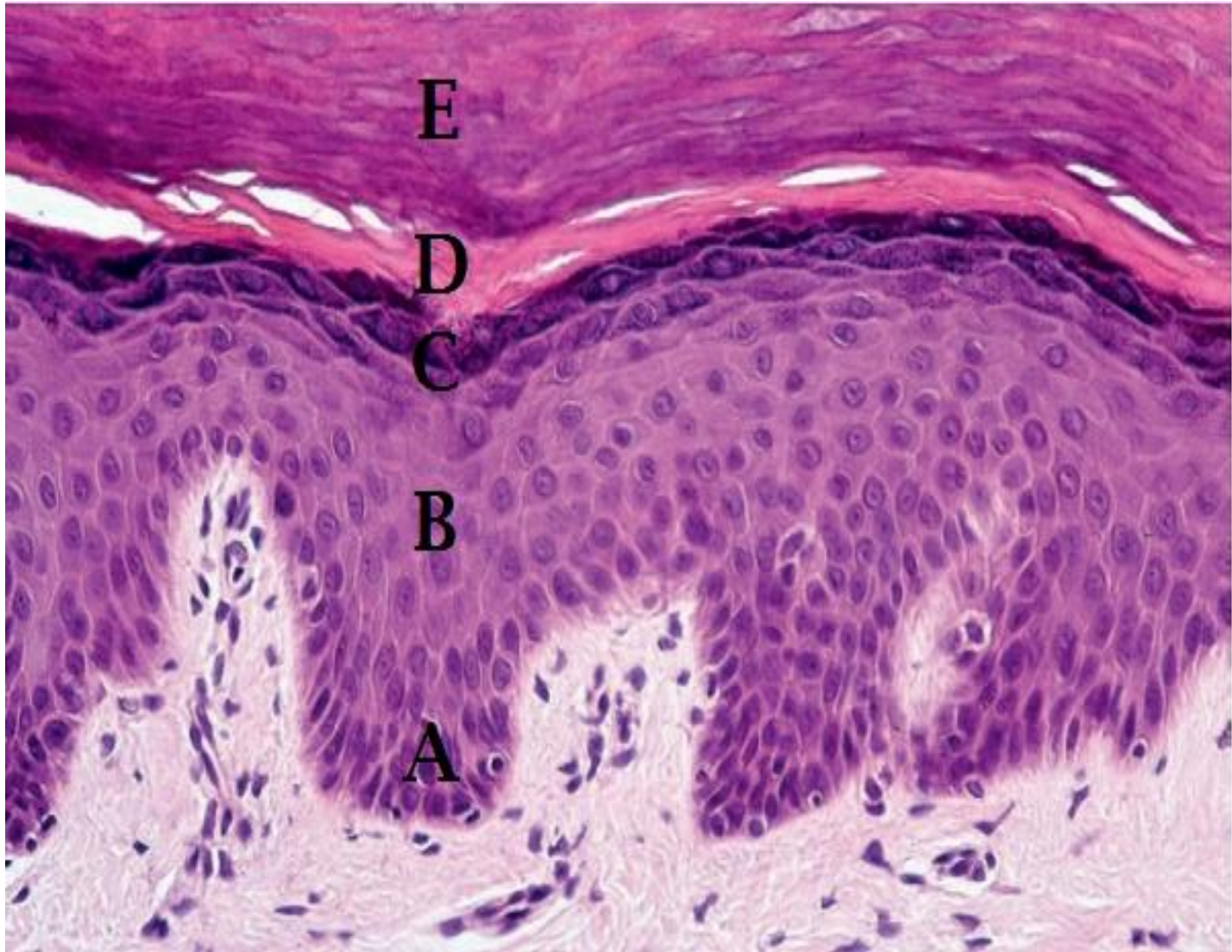


Pacinian corpuscles





Sebaceous gland
Hair follicle
Arrector pili



THICK OR THIN SKIN ????

