


MSS



Microbiology

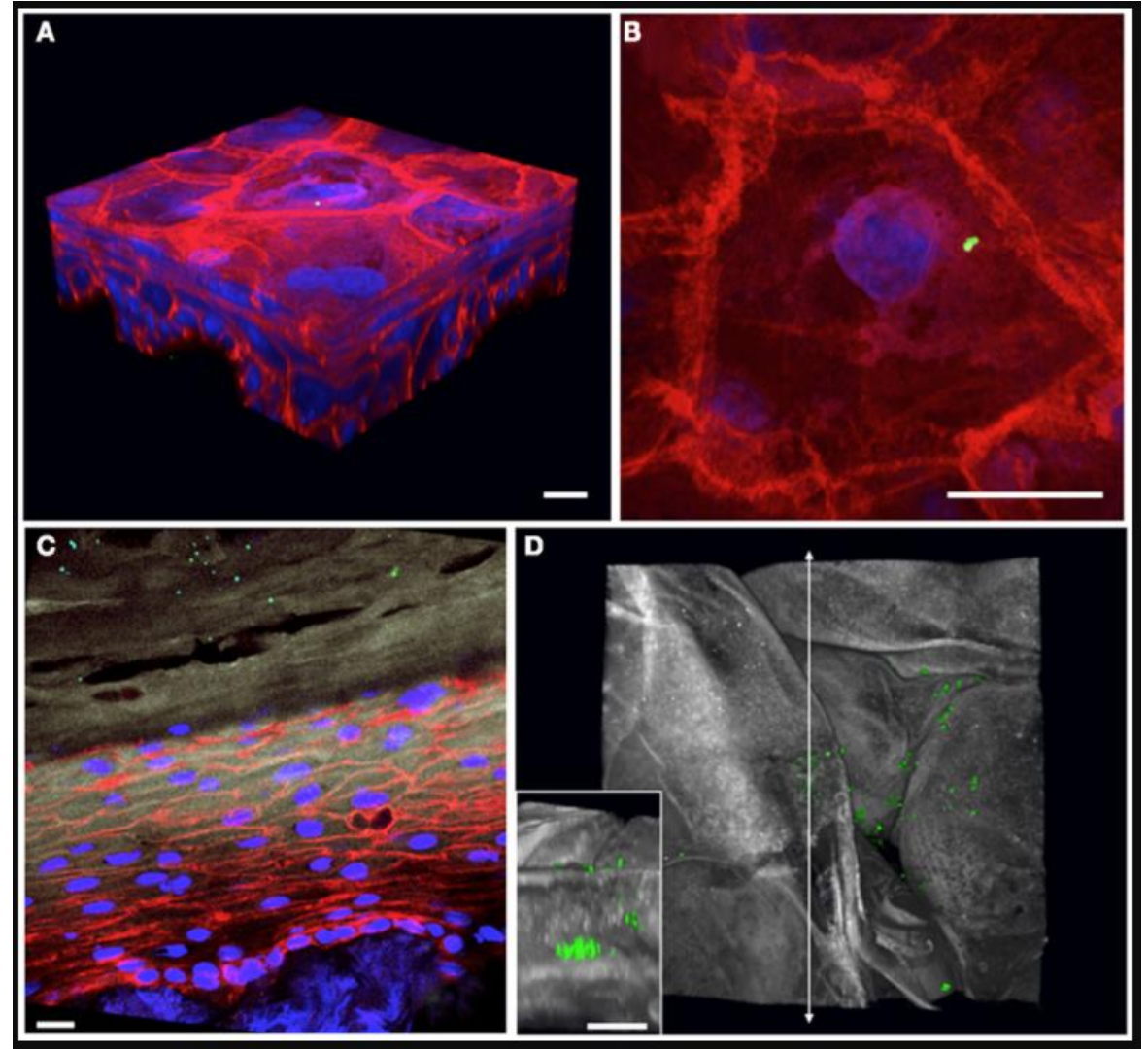
| Modified slides

Written by: Haitham Alsaifi
Correction: Dana Oshroqlaban
Doctor: Anas Abu-Humaidan



Musculoskeletal System Microbiology

Anas Abu-Humaidan
M.D. Ph.D.



Bacterial skin infections

Overview

Infections of the skin and soft tissues can be classified according to:

- The **tissue involved** and **depth of involvement** (e.g. Impetigo, cellulitis, necrotizing fasciitis, osteomyelitis).
- The **causative organism** (e.g. staph vs strep. Infections)
- The **predisposing factor** (e.g. diabetic foot infections, infections associated with animal bites)

The aim of the classification is to provide proper diagnosis and management of each clinical entity.

Overview

In this part of the course we will study bacterial infections associated with the following :

- Impetigo
- Folliculitis
- Erysipelas
- Cellulitis and skin abscess
- Osteomyelitis
- Septic arthritis
- Animal bites
- Necrotizing fasciitis .
- Clostridial myonecrosis
- Pyomyositis
- Diabetic foot infections



In this lecture

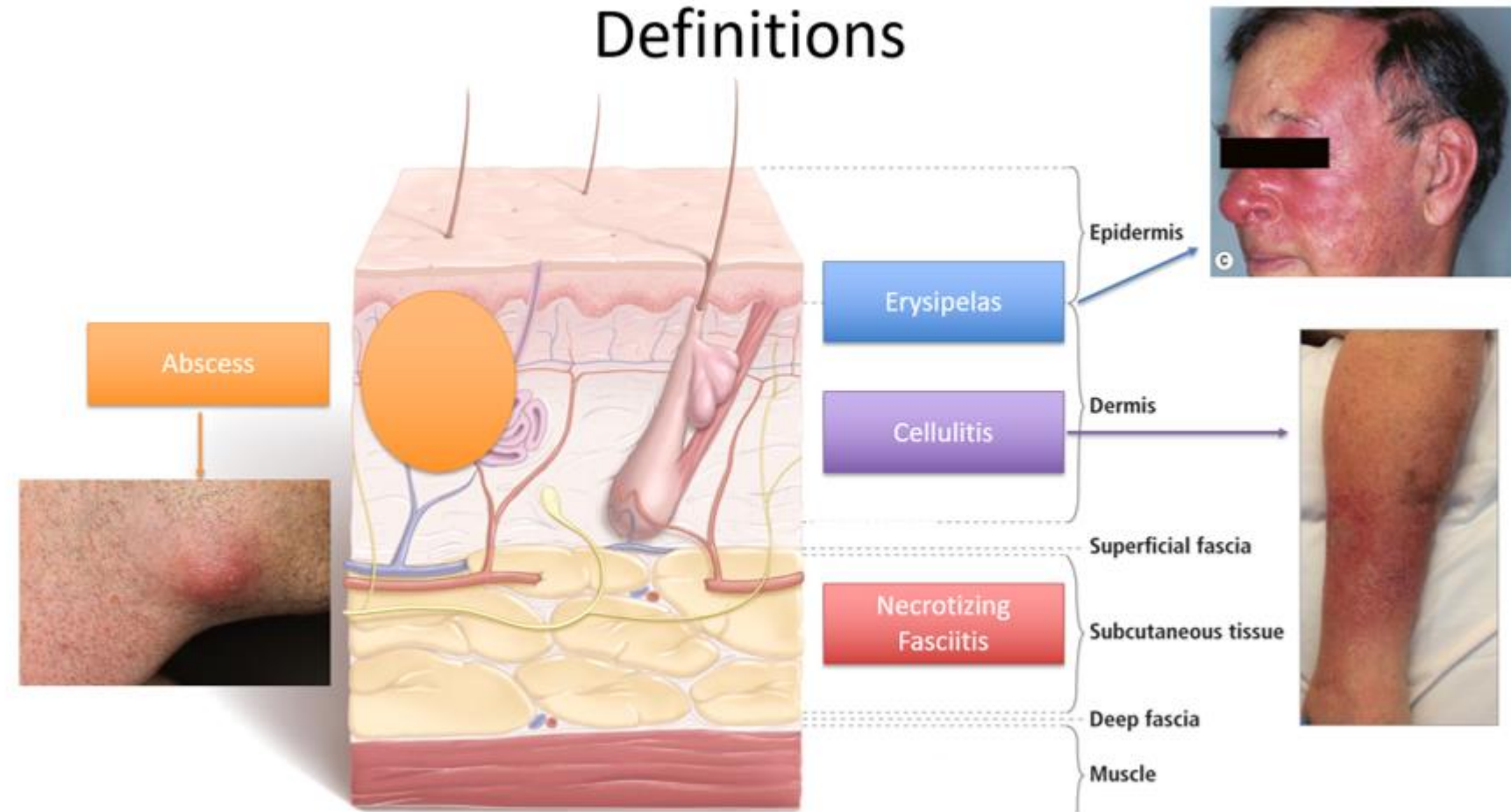
You can start with this
as an overview: 😊
[https://mega.nz/folder/
J883kQYT#CJez82eD-
eH2BWRRX5xDw](https://mega.nz/folder/J883kQYT#CJez82eD-eH2BWRRX5xDw)

Overview







The skin plays a part in our immunology system specially the dead keratinized layer (**stratum corneum**) which has different mechanisms in protecting our body, i.e. low pH, microbiota, AMPs.

pathogens that can evade these immune barriers will cause skin infection.

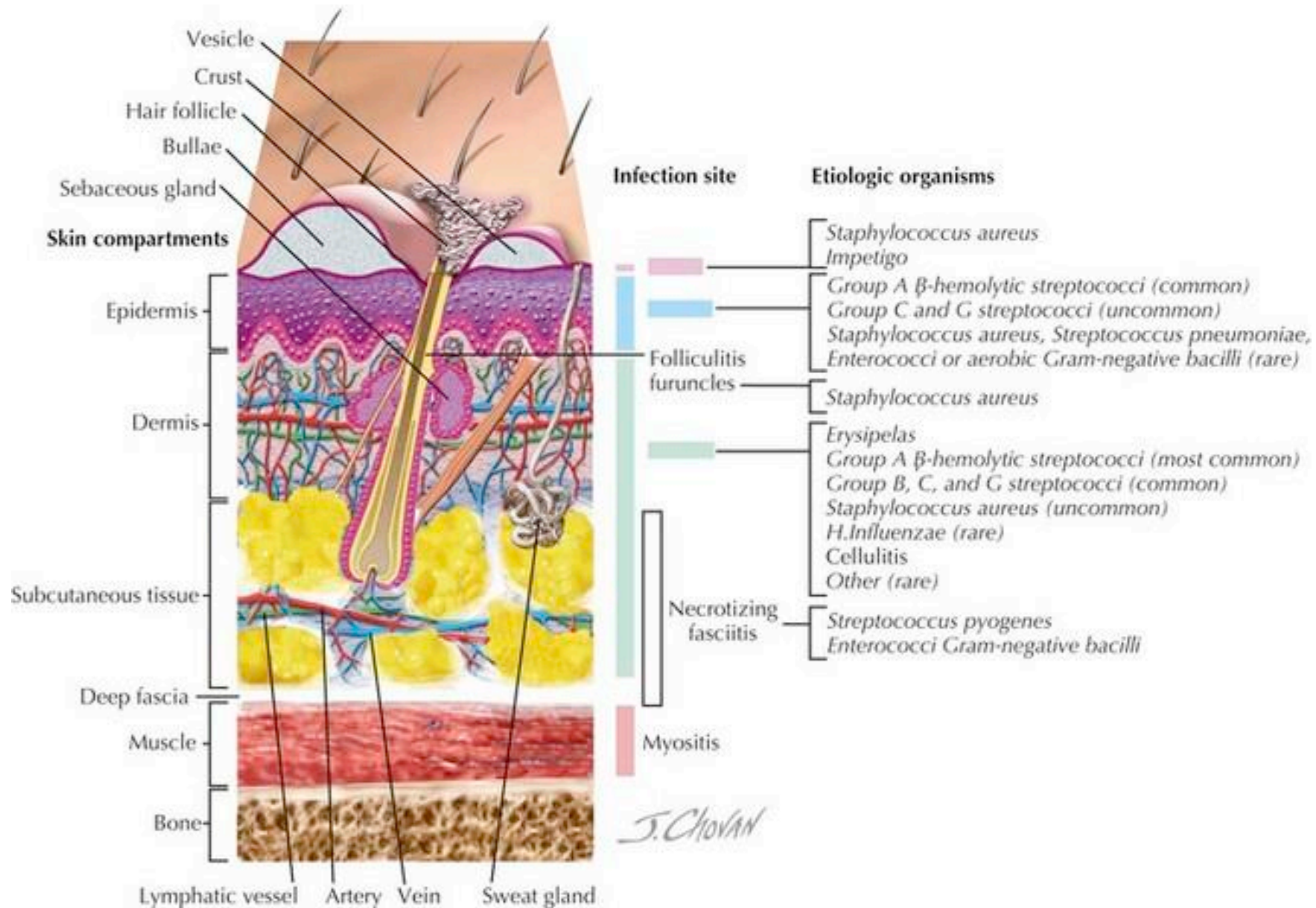
Skin infections can be classified according to the type of pathogen or the layer of the skin that get affected, so there will be different morphologies to the infection according to its location.



Overview

Type of Infection	Appearance of Lesion	Description of Lesion	Layer of Skin Involved	Common Pathogens	Treatment
Impetigo		Vesicles with honey-colored crust, often on the face of a child	Epidermis	<i>Staphylococcus aureus</i> , <i>Streptococcus pyogenes</i>	Few lesions: topical antibiotics (e.g., mupirocin); numerous lesions: systemic therapy (e.g., cephalexin, clindamycin)
Erysipelas		Erythematous, very painful lesion with sharply demarcated, raised, regular border	Superficial dermis	<i>S. pyogenes</i> , <i>Streptococcus agalactiae</i> > <i>S. aureus</i>	Systemic antibiotics (e.g., cephalexin or cefazolin)
Cellulitis		Erythematous diffuse, flat lesion with irregular border	Deep dermis	<i>Streptococcus pyogenes</i> , <i>Streptococcus agalactiae</i> > <i>Staphylococcus aureus</i>	Systemic antibiotics, eg cephalexin or cefazolin
Folliculitis		Localized, inflamed papules containing a small amount of pus	Hair follicle	<i>S. aureus</i> , <i>Pseudomonas aeruginosa</i> (associated with hot tubs)	Antibiotics often not needed; warm, moist compresses are useful
Skin abscess (furuncle also known as a boil, furuncle, carbuncle)		Raised, tender, inflamed nodule with central region of purulence; the area of pus initially is firm but then progresses to fluctuance (becomes movable)	Deep dermis	<i>S. aureus</i>	Incision and drainage is mainstay of therapy; antibiotics directed against <i>S. aureus</i> in select cases
Necrotizing soft tissue infections (necrotizing fasciitis)		Very painful area of inflammation with rapid progression to necrosis, bullae, purpura, anesthesia, and systemic toxicity	Fascia and muscle; local blood vessels and nerves also involved	1. Monomicrobial form: <i>S. pyogenes</i> , <i>Clostridium perfringens</i> , <i>Vibrio vulnificus</i> ; 2. Polymicrobial form: enteric gram-negative rods plus anaerobes	Surgical débridement is critical in addition to broad-spectrum systemic antibiotics

Overview

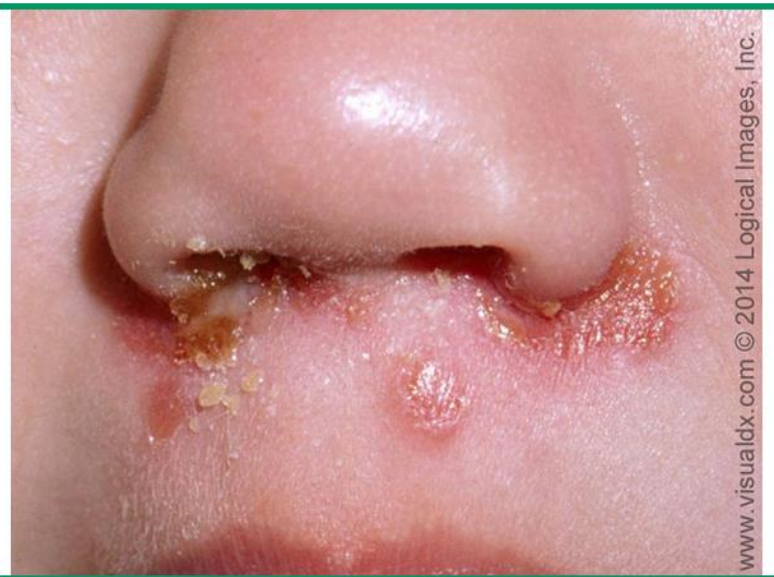

1. Impetigo : Epidermis

<https://youtu.be/wCxPy6BRC-g>

- **Impetigo** is a contagious superficial bacterial infection observed **most frequently in children** ages two to five years (**due to low hygiene and close contact**), although older children and adults may also be affected. It may be classified as **primary impetigo** (direct bacterial invasion of previously normal skin) or **secondary impetigo** (infection at sites of minor skin trauma such as abrasions, minor trauma, and insect bites, or underlying conditions such as eczema).
- **1. Nonbullous impetigo** is the most common form of impetigo. Lesions begin as papules that progress to vesicles surrounded by erythema. Subsequently they become pustules that enlarge and rapidly break down to **form thick, adherent crusts** with a characteristic **golden appearance**; over approximately one week.
- **2. Bullous impetigo** is a form of impetigo seen primarily in young children in which the vesicles enlarge to form flaccid bullae with clear yellow fluid.
- **3. Ecthyma** is an ulcerative form of impetigo in which the lesions extend through the epidermis and deep into the dermis. (Deeper form of impetigo)

Nonbullous impetigo

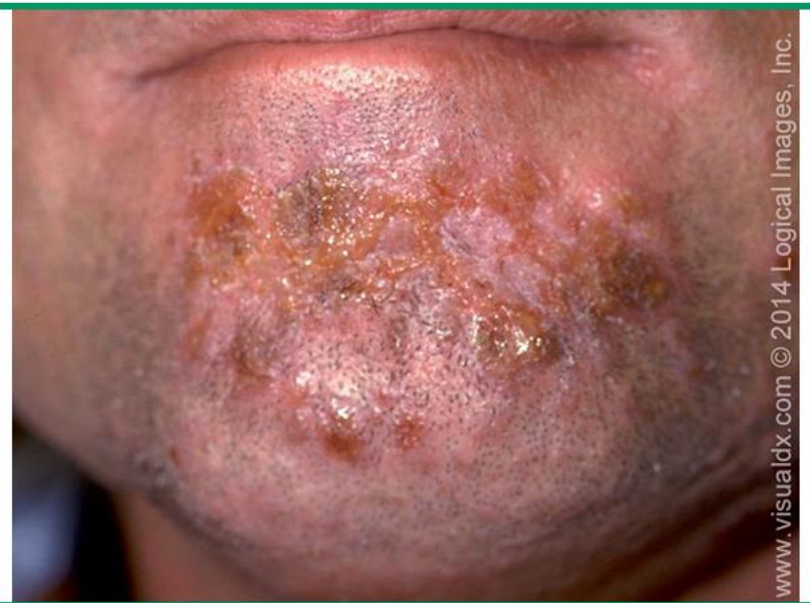

Perinasal erythema, erosions, and crusts in a child with nonbullous impetigo.

Reproduced with permission from: www.visualdx.com. Copyright VisualDx. All rights reserved.

UpToDate®

Non-bullous impetigo



Gold-colored crusts on the chin of a patient with non-bullous impetigo.

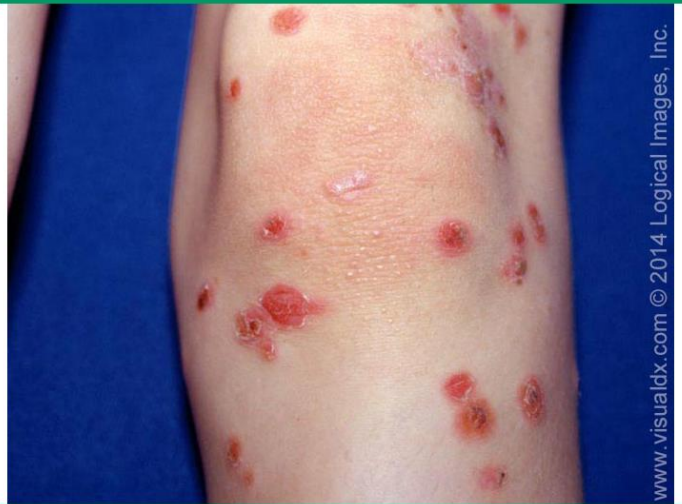Reproduced with permission from: www.visualdx.com. Copyright VisualDx. All rights reserved.

UpToDate®

Most of the time the diagnosis is done clinically without culturing except in severe cases.

Notice the golden crust that covers the mouth area.

Bullous impetigo

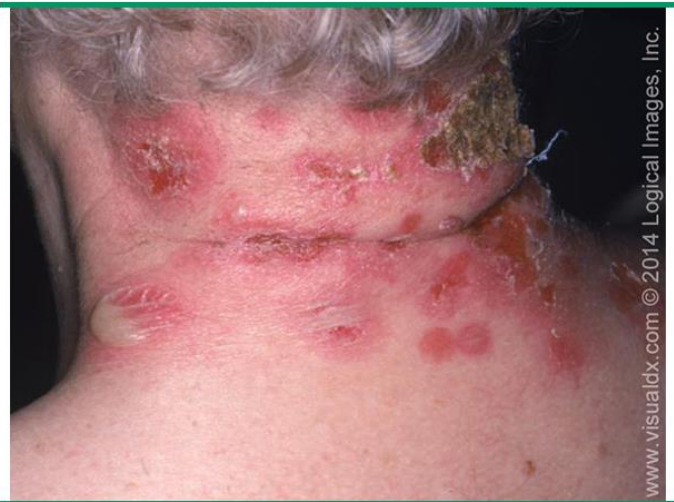

Multiple erosions with crust in a child with bullous impetigo.

Reproduced with permission from: www.visualdx.com. Copyright VisualDx. All rights reserved.

UpToDate®

Bullous impetigo

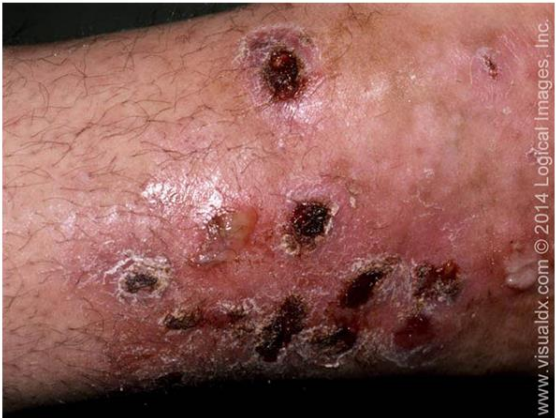

Bullae, erosions, and crusts in a patient with bullous impetigo on the neck.

Reproduced with permission from: www.visualdx.com. Copyright VisualDx. All rights reserved.

UpToDate®

Ecthyma



Multiple ulcers with adherent crusts.

Reproduced with permission from: www.visualdx.com. Copyright VisualDx. All rights reserved.

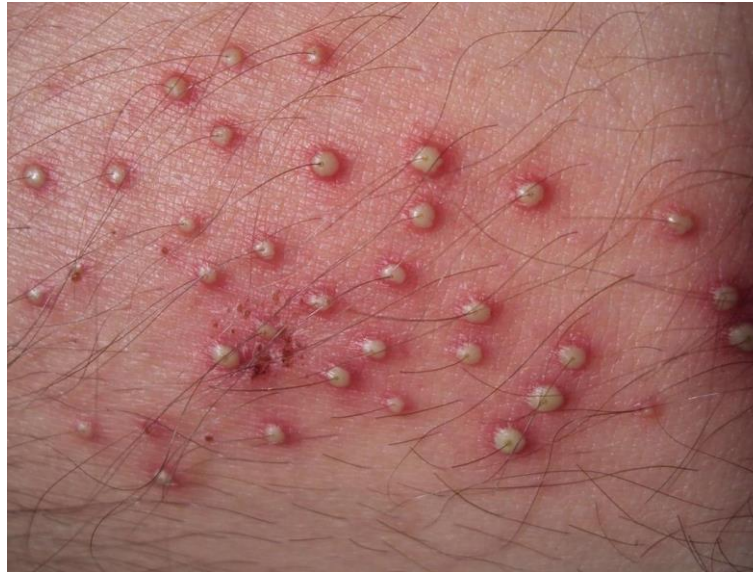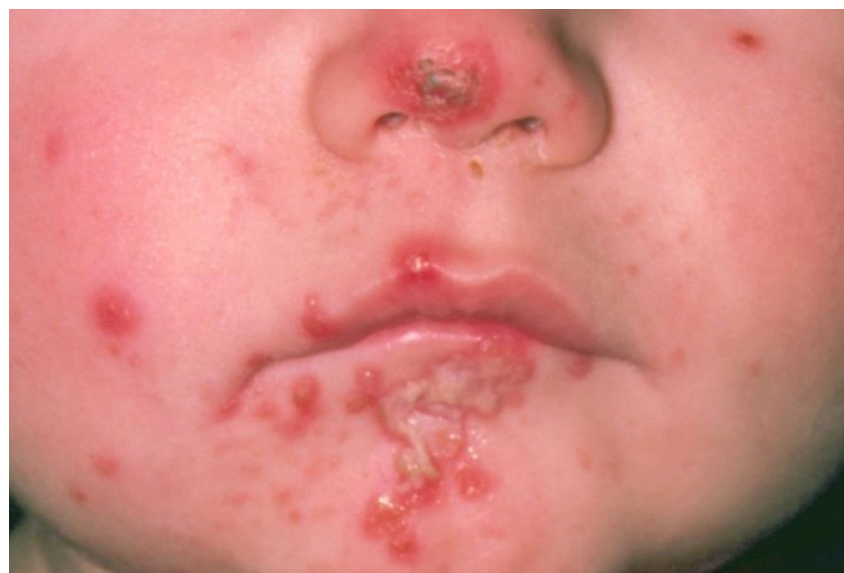Graphic 96273 Version 2.0

© 2022 UpToDate, Inc. and/or its affiliates. All Rights Reserved.

- The principal pathogen is **S. aureus** because it has many immune evad mechanisms like proein A, polysaccharide capsule and adhesins. Also, **Beta-hemolytic streptococci** (primarily group A, but occasionally other serogroups such as C and G) account for a minority of cases.
- The diagnosis of impetigo often can be made on the basis of clinical manifestations.
- A **Gram stain and culture of pus or exudate** is recommended to identify whether S. aureus and/or a beta-hemolytic Streptococcus is the cause. However, **treatment may be initiated without these studies** in patients with typical clinical presentations.
- Treatment of impetigo is important for reducing spread of infection, hastening the resolution of discomfort, and improving cosmetic appearance

Staphylococci / Clinical correlations

A localized staphylococcal infection appears as a “**pimple,**” **hair follicle infection,** or **abscess.** There is usually an intense, localized, painful inflammatory reaction that undergoes central suppuration and heals quickly when the pus is drained.

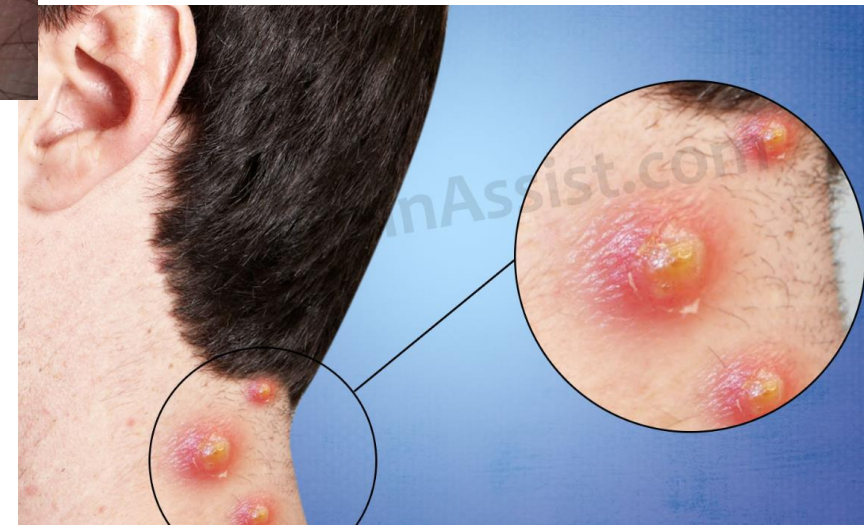

Impetigo: localized cutaneous infection characterized by pus-filled vesicle on an erythematous base

Folliculitis: impetigo involving hair follicles

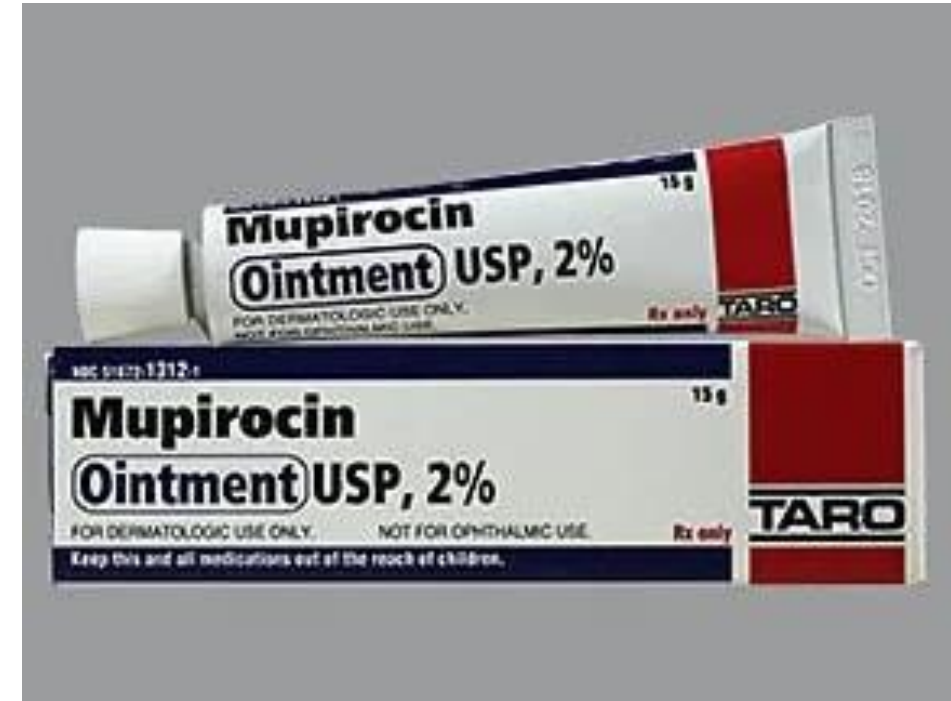Furuncles or boils: large, painful, pus-filled cutaneous nodules

Carbuncles: Coalescence of furuncles with extension into subcutaneous tissues and evidence of systemic disease (fever, chills, bacteremia)



- **Topical therapy** — Benefits of topical therapy include fewer side effects and lower risk for contributing to bacterial resistance compared with oral therapy.
Mupirocin and retapamulin are first-line treatments
- For patients with **numerous impetigo lesions**, we recommend treatment with **oral antibiotic therapy**.
- **Mupirocin** is a mixture of several pseudomonic acids. Pseudomonic acid inhibits isoleucine tRNA synthetase in bacteria, leading to depletion of isoleucyl-tRNA and accumulation of the corresponding uncharged tRNA. Depletion of isoleucyl-tRNA results in **inhibition of protein synthesis**.

Mupirocin for impetigo 🤔



2. Folliculitis (S.aureus >> P.aeruginosa)

<https://youtu.be/5v031DyqRBQ>

- **Folliculitis** refers to **inflammation of the superficial or deep portion of the hair follicle**.
- **Bacteria and purulent material accumulate** in hair follicles in the epidermal layer of the skin.
- **S. aureus is the most common cause of folliculitis**. **P. aeruginosa** can also cause folliculitis and is associated with the use of **unchlorinated hot tubs**. Rarely, Candida and certain dermatophytes can cause folliculitis.
- Diagnosis is made **clinically**, but if purulent material is present or in recurrent and extensive cases, it can be **cultured**.
- **Folliculitis often resolves on its own, and treatment is not needed**. Warm compresses or topical antibiotics can be considered in select cases.

Folliculitis

- Folliculitis presents with **pinpoint erythema** around individual hair follicles. A small amount of purulence may be seen. This can be seen in an isolated body area or throughout the skin.

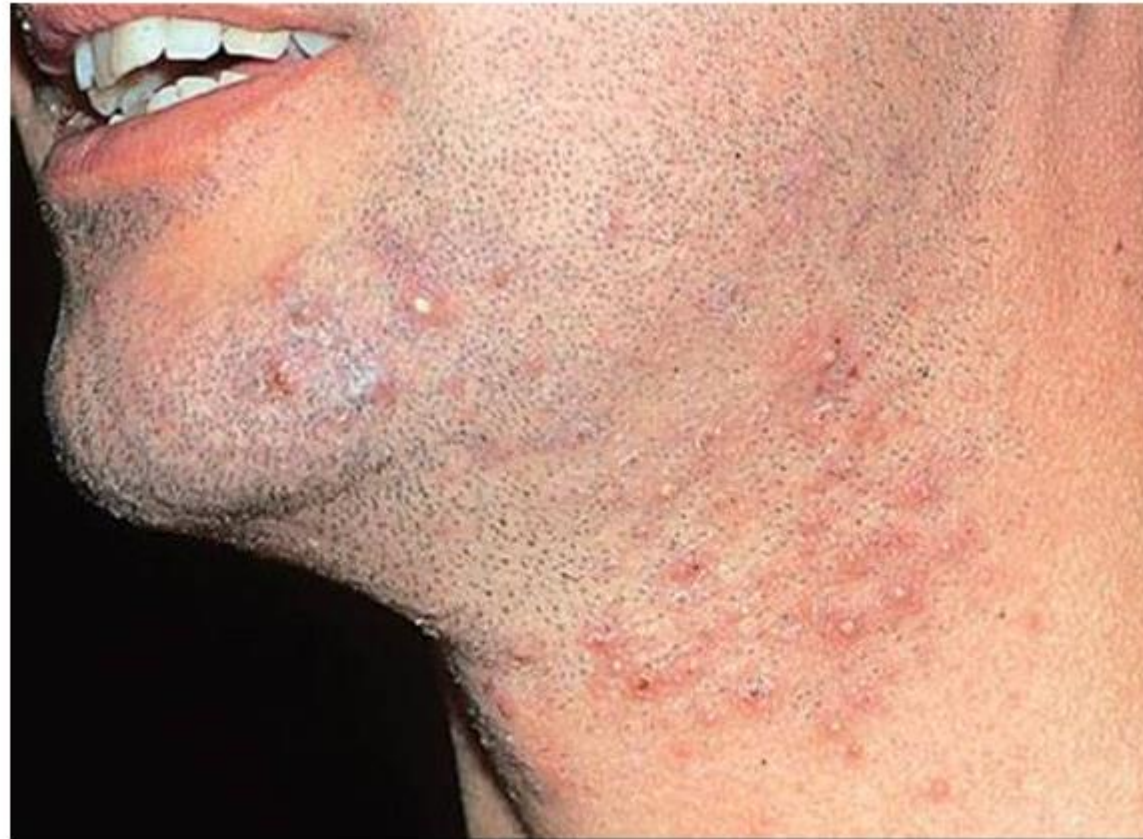

FIGURE 77-7 Folliculitis. Note the multiple, small pustules on the chin and neck. (Reproduced with permission from Wolff K, Goldsmith LA, Katz SI et al (eds): *Fitzpatrick's Dermatology in General Medicine*, 7th ed. New York: McGraw-Hill, 2008, pg 1699. Copyright © 2008 by The McGraw-Hill Companies, Inc.)

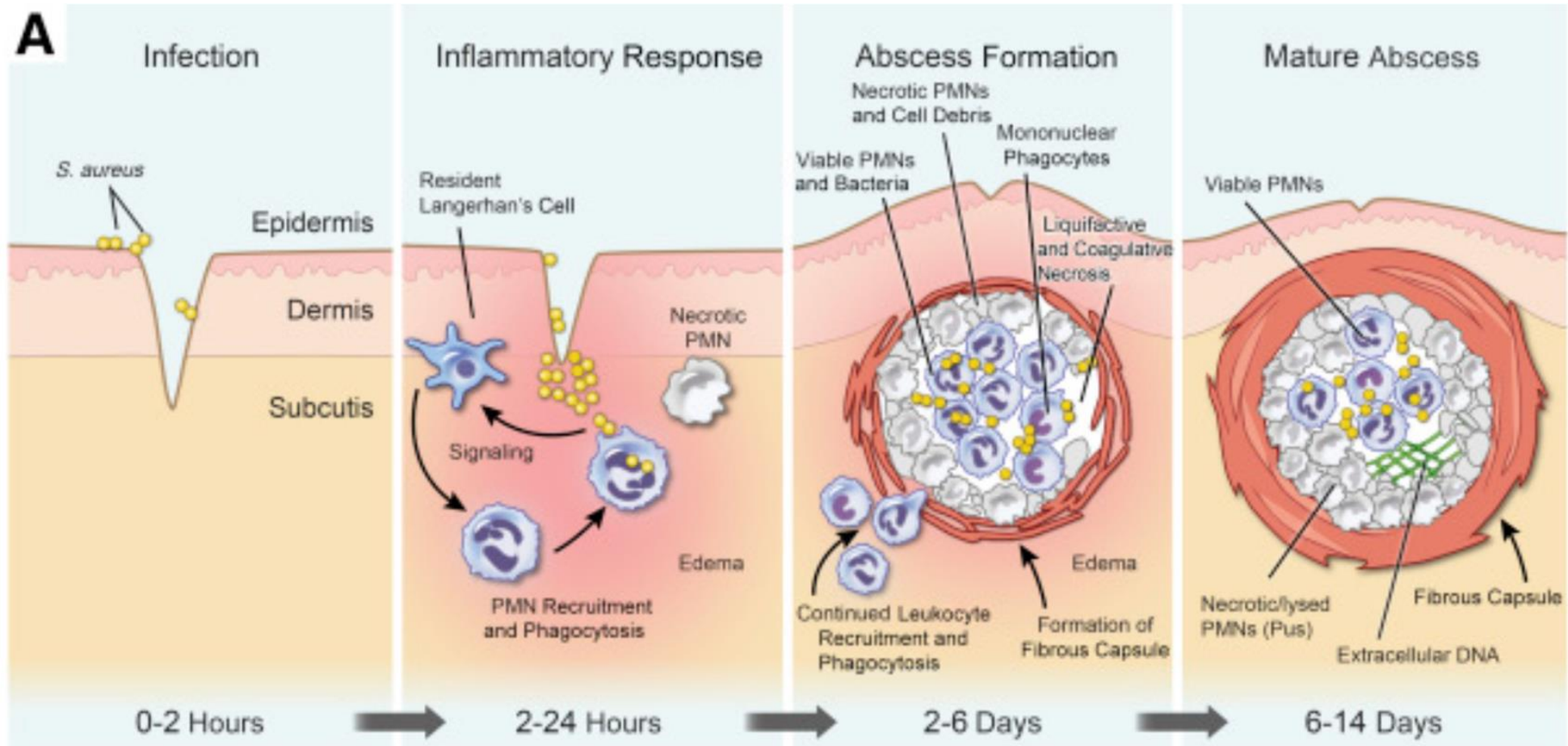
3. SKIN ABSCESS (furuncles or carbuncles): Dermis

<https://youtu.be/pL6rP8C1e7w>

- A **skin abscess** is an **infection of the dermis and deeper layers of skin** that contains purulent material. Skin abscesses can sometimes be referred to as carbuncles and furuncles.
- Bacteria causing cutaneous abscesses are typically indigenous to the skin of the involved area. For abscesses on the trunk, extremities, axillae, or head and neck, the most common organisms are **Staphylococcus aureus** (with methicillin-resistant S. aureus [MRSA] being the most common in the US) and streptococci. While abscesses in the **perineal** (i.e, inguinal, vaginal, buttock, perirectal) region contain **organisms found in the stool**, commonly anaerobes or a combination of aerobes and anaerobes that come from the GI tract microbiota.

Immune evasion techniques of staphylococcus aureus: MSCRAMS helps bacterial attachment to host cells , protein A that captures antibodies from fc region neutralizing them , peptidases that break down complement proteins and the capsule helps in decreasing the phagocytosis. So, the infection is not cleared directly right away, and when the infection persists there is more tissue damage until an ABSCESS is formed (which occurs usually within 2 weeks).

SKIN ABSCESS



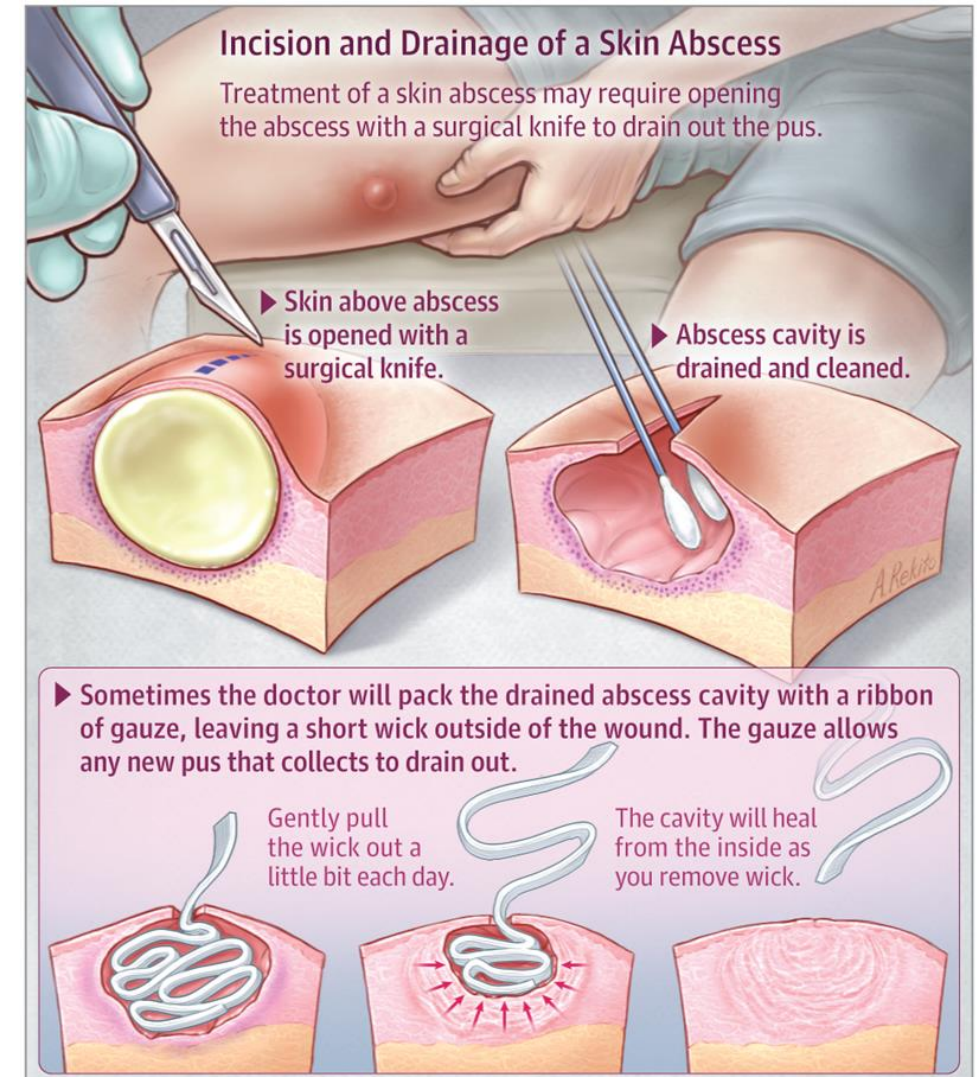
- A skin abscess is round and feels firm and squishy due to the thick membrane around it and the liquid pus inside. It is usually painful, and the overlying skin is often red.

SKIN ABSCESS

- Diagnosis of cutaneous abscess is usually obvious by **clinical examination**. **Culture is recommended**, primarily to identify **MRSA**.
- Conditions resembling simple cutaneous abscesses include **hidradenitis suppurativa** and **ruptured epidermal cysts**. *Difference: here there's NO infection.*
- **Hidradenitis suppurativa** is currently thought to be a **chronic inflammatory condition** of the hair follicle and associated structures. The exact cause of hidradenitis suppurativa is unknown, but it occurs near hair follicles where there are sweat glands, usually around the groin, bottom, breasts and armpits.

SKIN ABSCESS/ treatment

- The only certain way to treat an abscess is to open the pocket and drain the pus. This is known as an “**incision and drainage**.” It is a simple procedure that can be done with local anesthesia. A surgical knife is used to cut a hole in the wall of the abscess and empty it of pus.
- Antibiotics have traditionally been considered unnecessary unless the patient has signs of **systemic infection, cellulitis, multiple abscesses, immunocompromise**, or a **facial abscess** in the area drained by the cavernous sinus. In these cases, empiric therapy should be started with a drug active against MRSA pending results of bacterial culture



4. Erysipelas and Cellulitis: Dermis , strep. Pyogens.

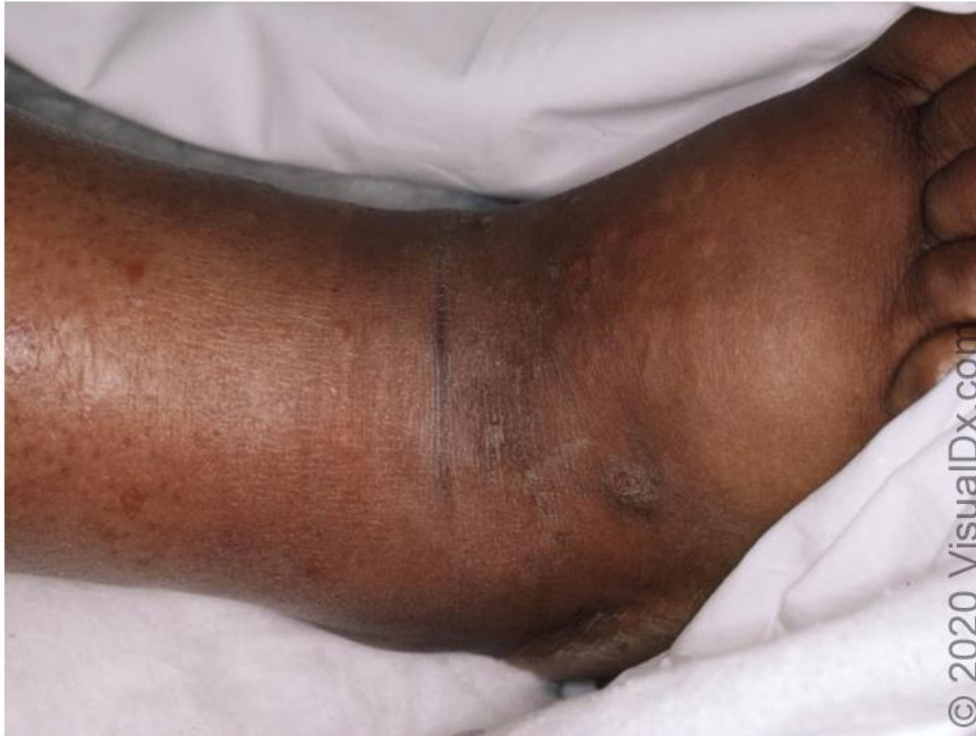<https://youtu.be/EAVVxLQxqNI>

- The difference between them is that erysipelas is more in the **superficial layer of the dermis** and it is **well-demarcated**, while cellulitis is deeper in the dermis and it is not well-demarcated.
- Cellulitis, abscess, or both are **among the most common skin and soft tissue infections**.
- **Cellulitis** (which includes erysipelas) manifests as an area of skin erythema, edema, and warmth; it develops as a result of bacterial entry via breaches in the skin barrier .

Well (better) demarcation.
- Cellulitis and erysipelas manifest as areas of skin **erythema**, **edema**, and **warmth**; they develop as a result of bacterial entry via breaches in the skin barrier. Petechiae and/or hemorrhage can be seen in erythematous skin, and **superficial bullae** can occur.
- **Fever and other systemic manifestations** of infection may also be present. Cellulitis and erysipelas are nearly always **unilateral**, and the **lower extremities** are the most common site of involvement.

Erysipelas and Cellulitis / Introduction

Cellulitis of the ankle



Edema and erythema around the ankle and on the dorsal foot.

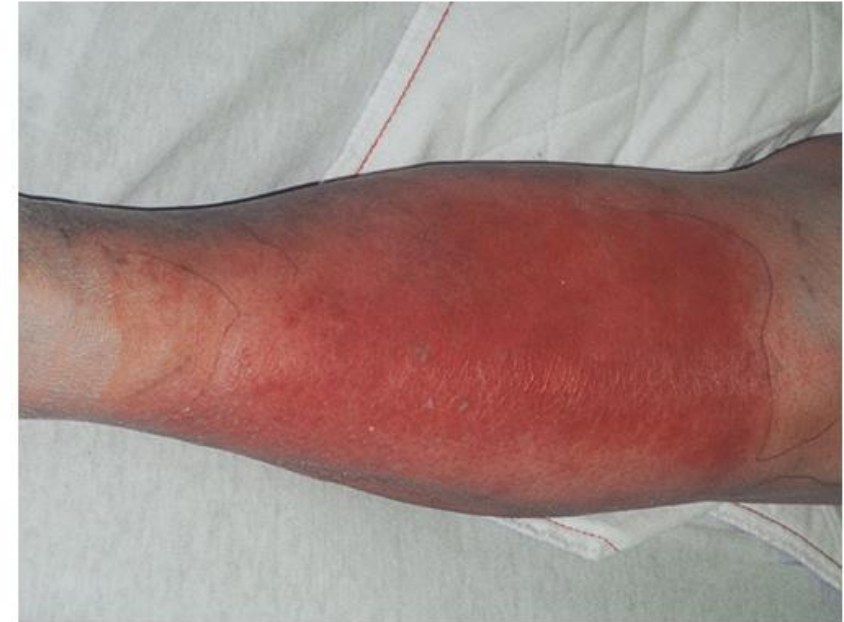Reproduced with permission from: www.visualdx.com. Copyright VisualDx. All rights reserved.

Graphic 128906 Version 1.0

© 2022 UpToDate, Inc. and/or its affiliates. All Rights Reserved.

Not well demarcated

Erysipelas of the leg



Erysipelas of the lower leg. The rash is intensely red, sharply demarcated, swollen, and indurated.

Reproduced with permission from: Berg D, Worzala K. *Atlas of Adult Physical Diagnosis*. Philadelphia: Lippincott Williams & Wilkins, 2006. Copyright © 2006 Lippincott Williams & Wilkins.

Graphic 82542 Version 3.0

© 2022 UpToDate, Inc. and/or its affiliates. All Rights Reserved.

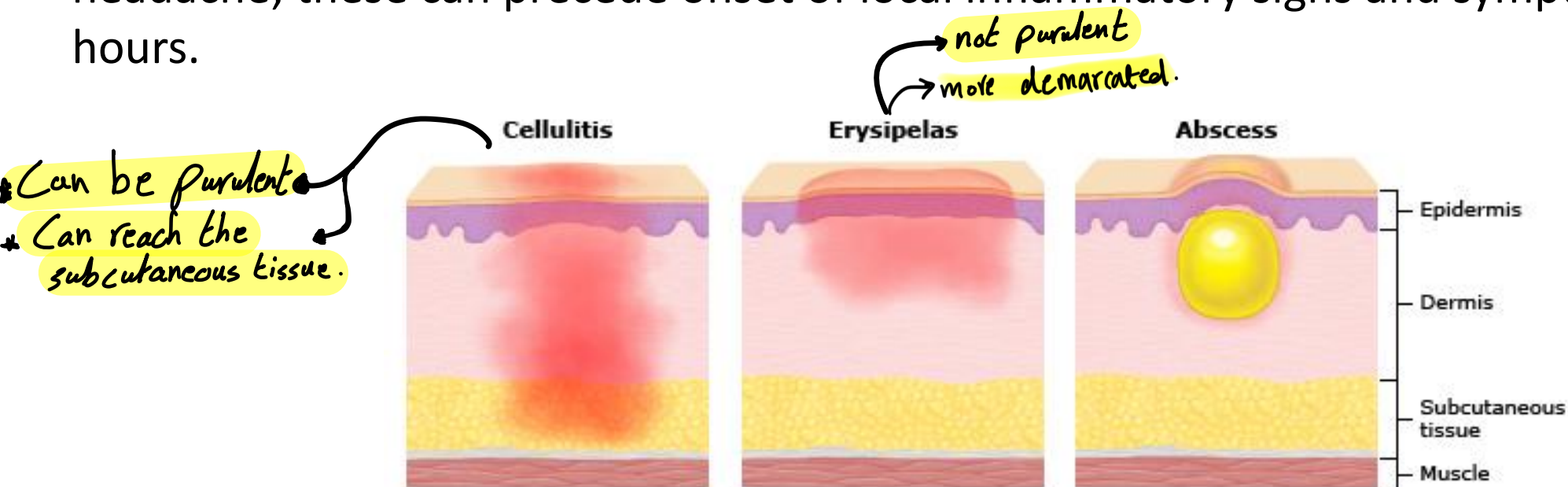
Well demarcated

- **Cellulitis** is observed most frequently among **middle-aged and older adults**. **Erysipelas** occurs in **young children** and older adults
- Erysipelas occurs in young children and older adults. The incidence of cellulitis is about 200 cases per 100,000 patient-years and, in nontropical regions, has a seasonal predilection for warmer months.
- The most common cause of cellulitis is **beta-hemolytic streptococci** most commonly **group A Streptococcus or Streptococcus pyogenes**; *S. aureus* (including methicillin-resistant strains) is a notable but less common cause.
- The vast majority of erysipelas cases are caused by **beta-hemolytic streptococci**.
- Mostly in extremities but can happen in the face.

Predisposing factors associated with risk of cellulitis and/or skin abscess include [16-25]:

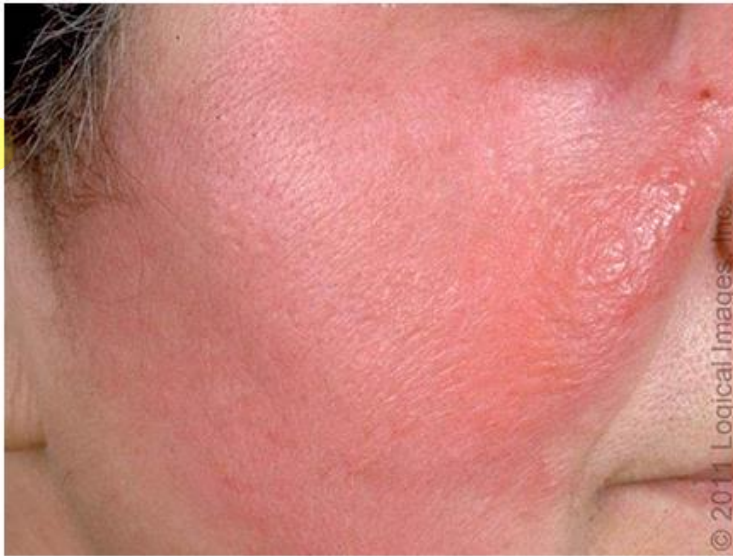- Skin barrier disruption due to **trauma** (such as abrasion, penetrating wound, pressure ulcer, venous leg ulcer, insect bite, injection drug use)
- Skin **inflammation** (such as **eczema**, radiation therapy, psoriasis)
- **Edema** due to impaired lymphatic drainage or due to venous insufficiency
- **Obesity**
- **Immunosuppression** (such as diabetes or HIV infection)
- **Skin breaks** between the toes ("toe web intertrigo"); these may be clinically inapparent
- **Pre-existing skin infection** (such as tinea pedis, impetigo, varicella)

- Cellulitis involves the **deeper dermis** and **subcutaneous fat**; erysipelas involves the **upper dermis and superficial lymphatics** (figure 1). Cellulitis may present with or without purulence; erysipelas is nonpurulent.
- Patients with cellulitis tend to have a more **indolent course** with development of localized symptoms **over a few days**. Patients with erysipelas generally have **acute onset** of symptoms with **systemic manifestations**, including fever, chills, severe malaise, and headache; these can precede onset of local inflammatory signs and symptoms by minutes to hours.



- In erysipelas, there is **clear demarcation** between involved and uninvolved tissue. There may be a raised, advancing border or erythema with central clearing. Classic descriptions of erysipelas note "butterfly" involvement of the face

Erysipelas



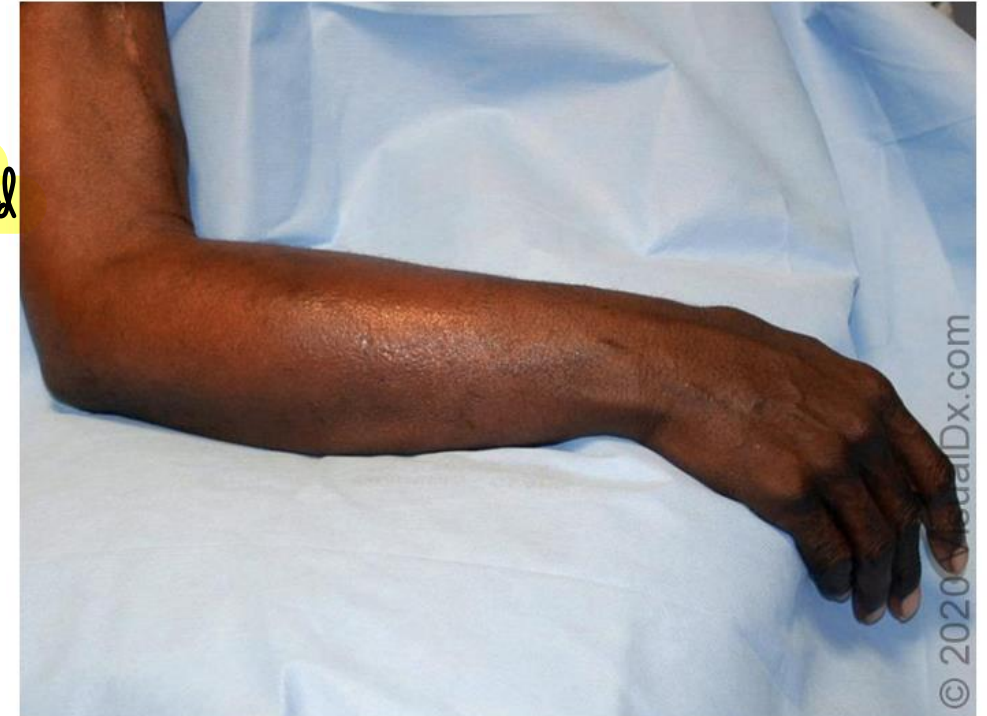Erysipelas lesions are raised above the level of surrounding skin, and there is a clear line of demarcation between involved and uninvolved tissue.

Reproduced with permission from: www.visualdx.com. Copyright VisualDx. All rights reserved.

Graphic 67112 Version 6.0

© 2022 UpToDate, Inc. and/or its affiliates. All Rights Reserved.

Cellulitis with erythema and edema



An extensive edematous and erythematous plaque on the arm.

Reproduced with permission from: www.visualdx.com. Copyright VisualDx. All rights reserved.

Graphic 128910 Version 1.0

© 2022 UpToDate, Inc. and/or its affiliates. All Rights Reserved.

Erysipelas and Cellulitis / Diagnosis

- The diagnosis of cellulitis, erysipelas, and skin abscess is usually based upon **clinical manifestations**. Cellulitis and erysipelas manifest as areas of skin **erythema**, **edema**, and **warmth**. Erysipelas lesions are raised above the level of surrounding skin with **clear demarcation** between involved and uninvolved tissue. A skin abscess manifests as a painful, fluctuant, erythematous nodule, with or without surrounding cellulitis.
- **Laboratory testing** is not required for patients with **uncomplicated infection** in the absence of comorbidities or complications.

Cultures of debrided material and blood cultures (prior to addition of antibiotic therapy) are warranted in the following circumstances :

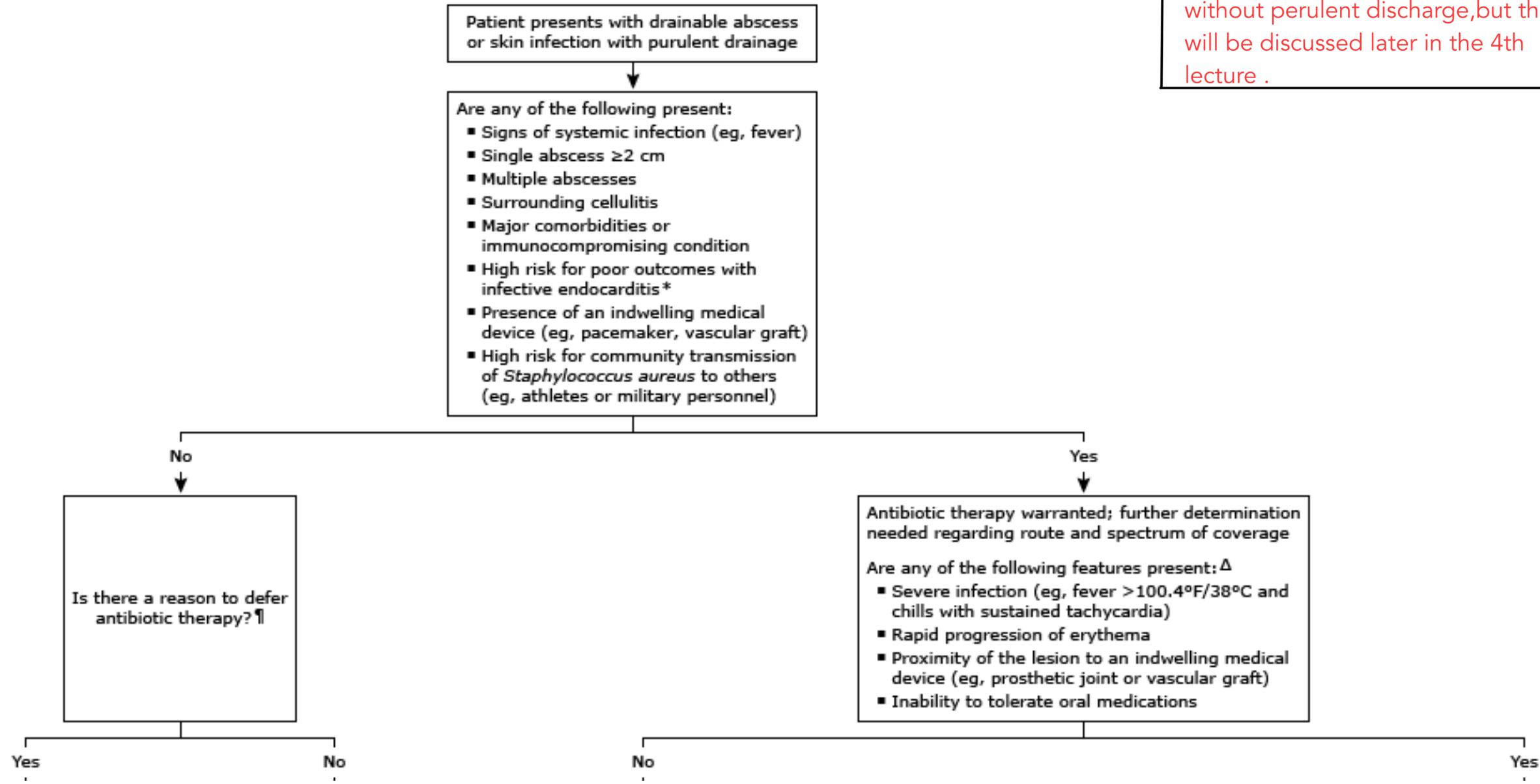
- Severe local infection (eg, **extensive cellulitis**)
- Systemic signs of infection (eg, **fever**)
- History of recurrent or multiple abscesses
- **Failure of initial antibiotic therapy**
- Extremes of age (young infants or older adults)
- Presence of underlying comorbidities (lymphedema, malignancy, neutropenia, **immunodeficiency**, splenectomy, **diabetes**) Special exposures (**animal bite, water-associated injury**)

Erysipelas and Cellulitis / Clinical approach

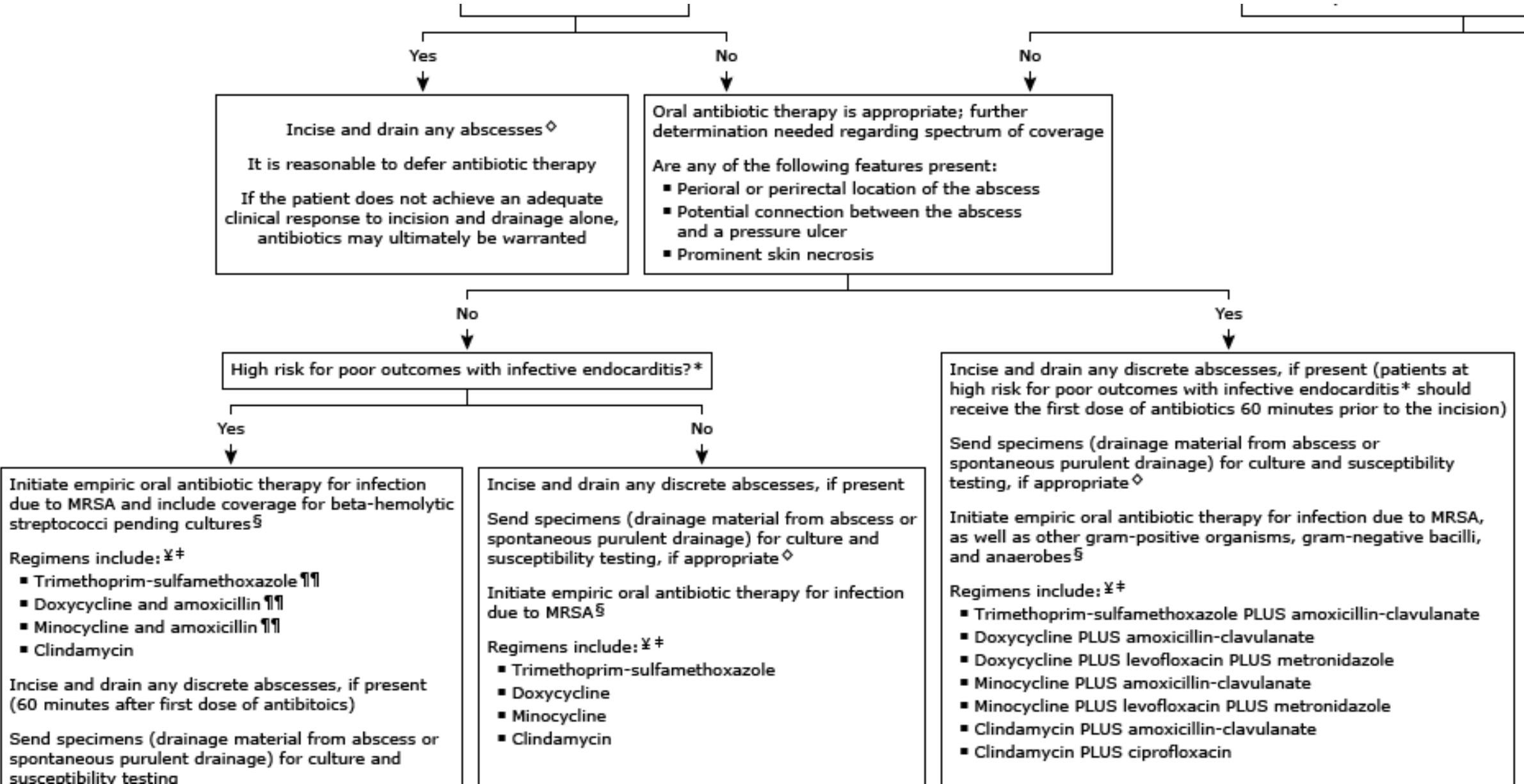
- Patients with nonpurulent cellulitis (eg, cellulitis with no purulent drainage or exudate and no associated abscess) should be managed with **empiric therapy** for infection due to beta-hemolytic streptococci and methicillin-susceptible *Staphylococcus aureus* (MSSA). Common options are **cefazolin** for intravenous therapy and **cephalexin** for oral therapy.
extra: → 1st generation of cephalosporins that work against G⁺ve mainly.
- Deepening of erythema may be observed following initiation of antimicrobial therapy. This may be due to destruction of pathogens that release particles that enhance local inflammation and should not be mistaken for therapeutic failure.
- Patients with cellulitis typically have symptomatic improvement **within 24 to 48 hours** of beginning antimicrobial therapy, although visible improvement of clinical manifestations in more severe cases may take up to 72 hours.

Erysipelas and Cellulitis / Clinical approach

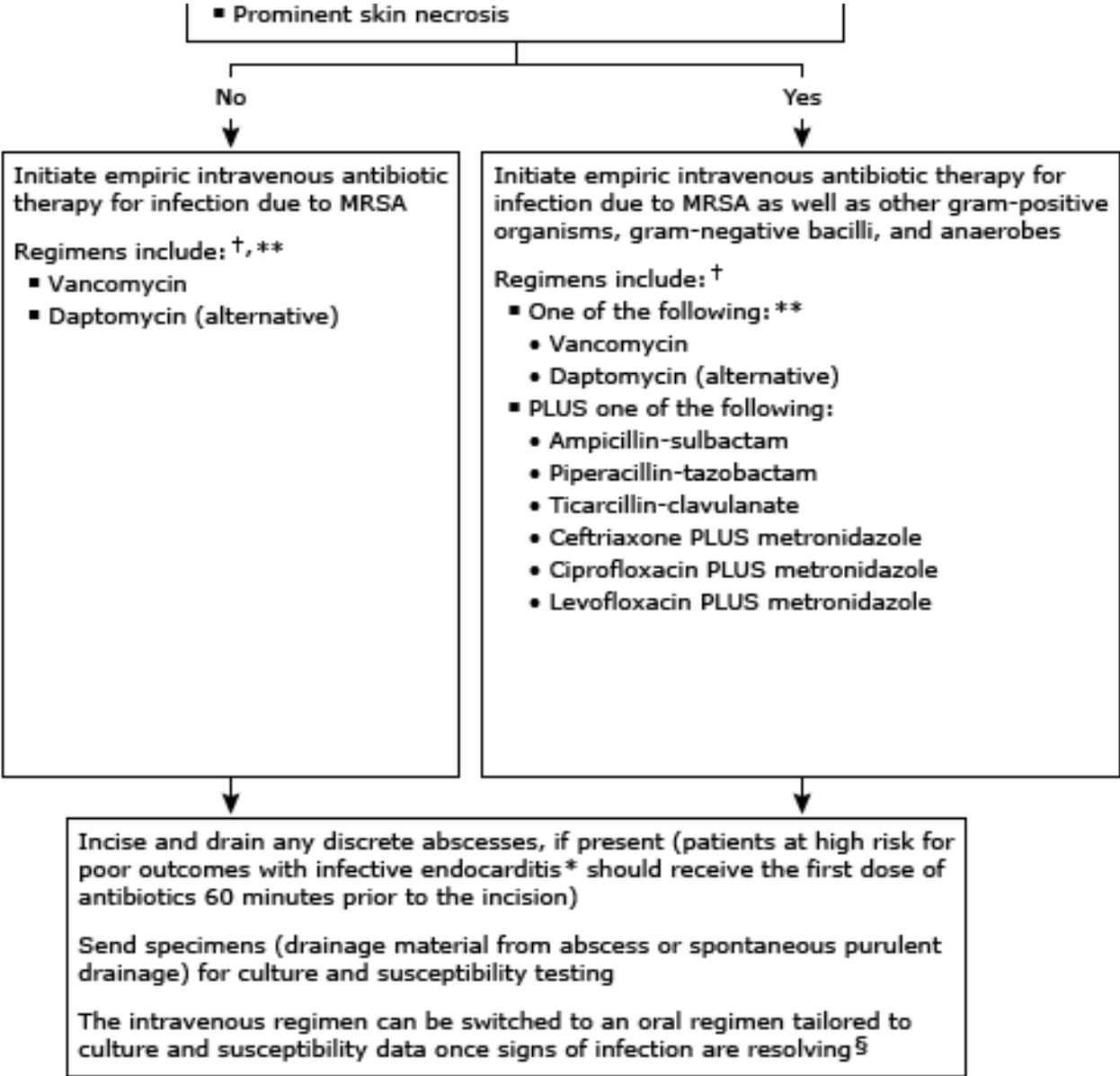
Dr Anas said you can read these 3 slides about algorithm of how to deal with patients that comes with or without purulent discharge, but they will be discussed later in the 4th lecture .



Erysipelas and Cellulitis / Clinical approach



Erysipelas and Cellulitis / Clinical approach



Further reading:

- Cellulitis and skin abscess

https://www.uptodate.com/contents/cellulitis-and-skin-abscess-epidemiology-microbiology-clinical-manifestations-and-diagnosis?search=cellulitis&source=search_result&selectedTitle=3~150&usage_type=default&display_rank=2