


Lecture

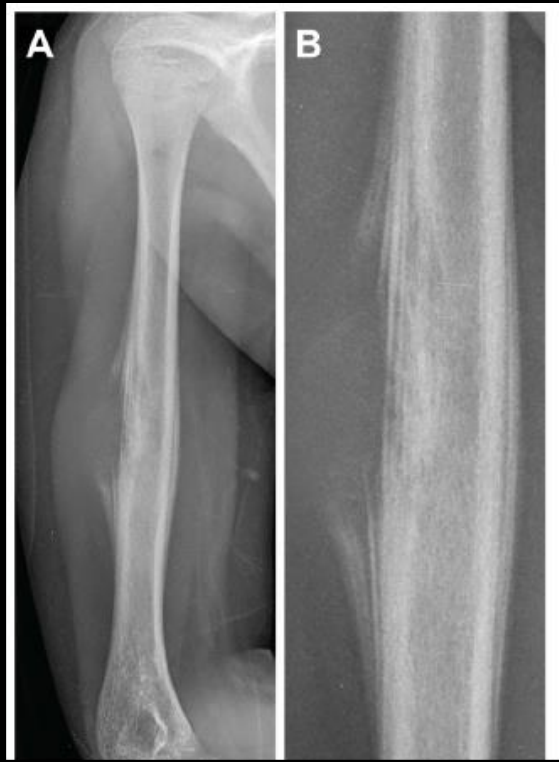6

EWING SARCOMA:

- Dr. James Ewing (1866-1943). Described this tumor 1920
- Small blue cell tumor (PNET)
- 2nd most common sarcoma of bone after osteosarcoma
- < 20 years, diaphysis
- The most common translocation, present in about 90% of Ewing sarcoma cases, is $t(11;22)(q24;q12)$, which generates an aberrant transcription factor through fusion of the EWSR1 gene with the FLI1 gene.
- Trx: neoadjuvant CT followed by surgery; long term survival now reaches 75%



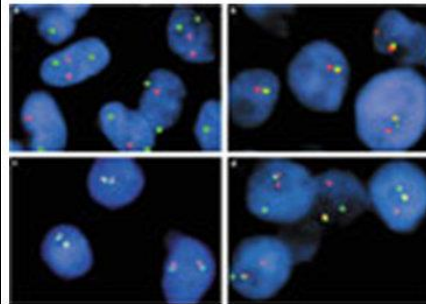
ES FEATURES:



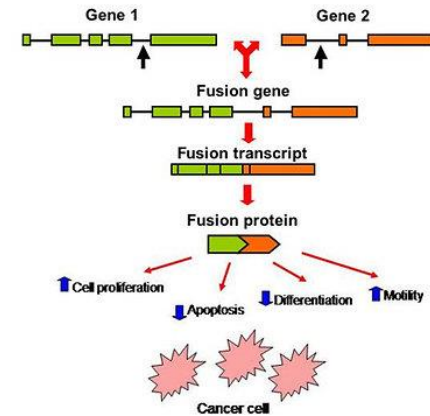
Positive translocation of EWS gene:

EWS FLI1 t(11;22)(q24;q12)

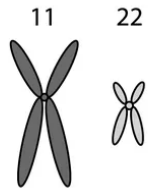
EWS FLI2 t(21;22)(q22;q12)



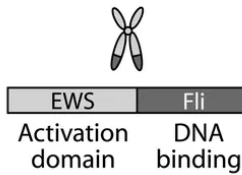
Pozit. EWS/FLI1 - FISH



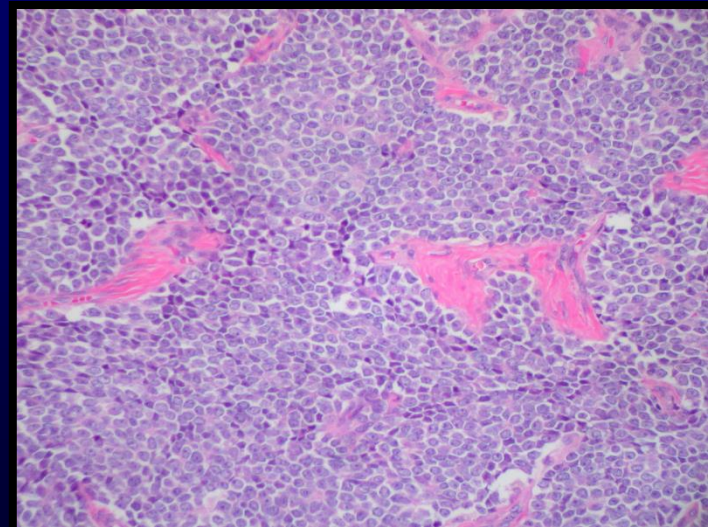
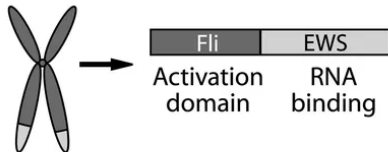
Normal



Ewing's sarcoma
t(11;22)(q24;q12)



Reciprocal
Translocation:
Lost in some
tumors



GIANT CELL TUMOR OF BONE:

- Locally aggressive neoplasm of adults.
- Epiphyses of long bones
- Osteoclast-like giant cells
- Rare malignant behavior
- Cells contain high levels of RANKL
- Trx: curetting

Giant cell tumors often destroy the overlying cortex, producing a bulging soft tissue mass delineated by a thin shell of reactive bone (Fig. 21.25). Grossly, they are red-brown masses that frequently undergo cystic degeneration. Microscopically, the tumor conspicuously lacks bone or cartilage, consisting of numerous osteoclast-type giant cells with 100 or more nuclei with uniform, oval mononuclear tumor cells in between (Fig. 21.26).

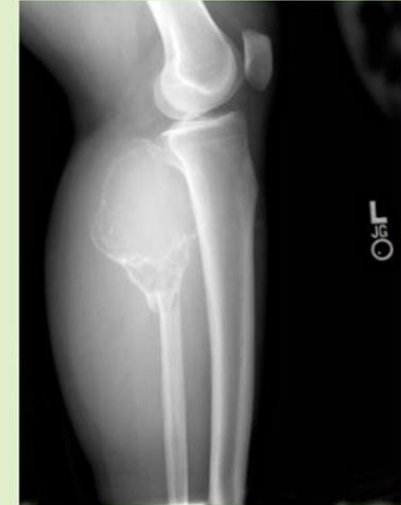

FIG. 21.25 Radiographically, giant cell tumor of the proximal fibula is predomi...

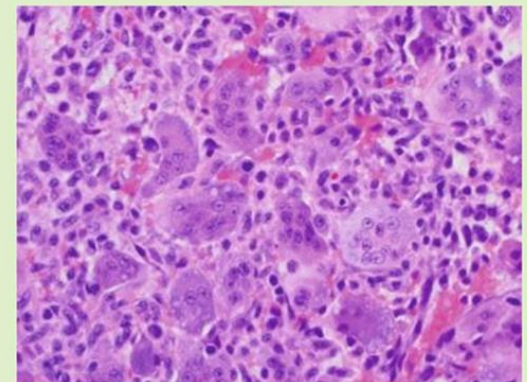
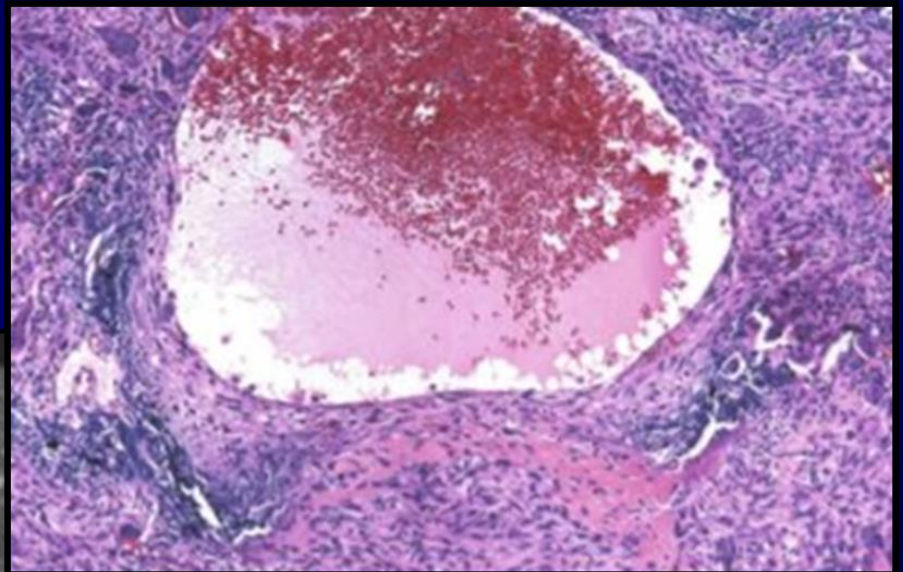
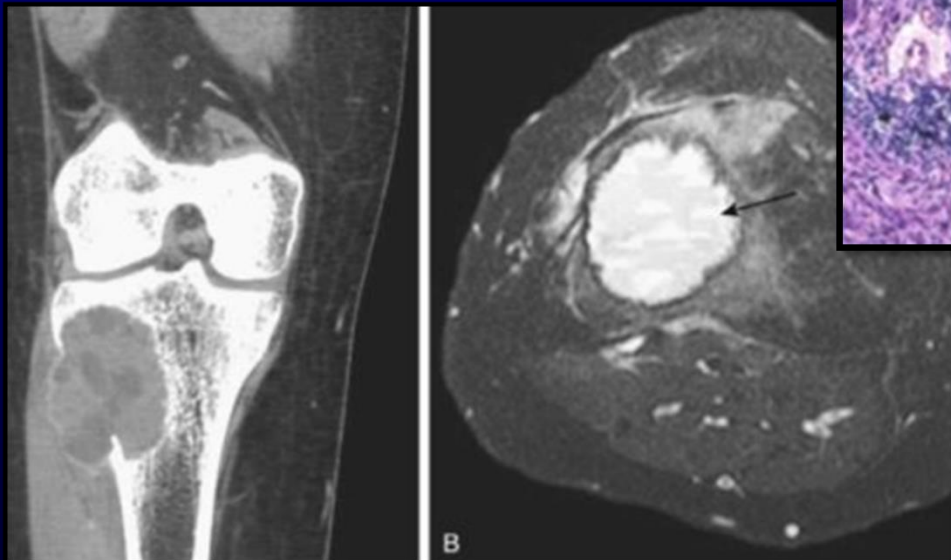


FIG. 21.26 Giant cell tumor illustrating an abundance of multinucleated giant c...

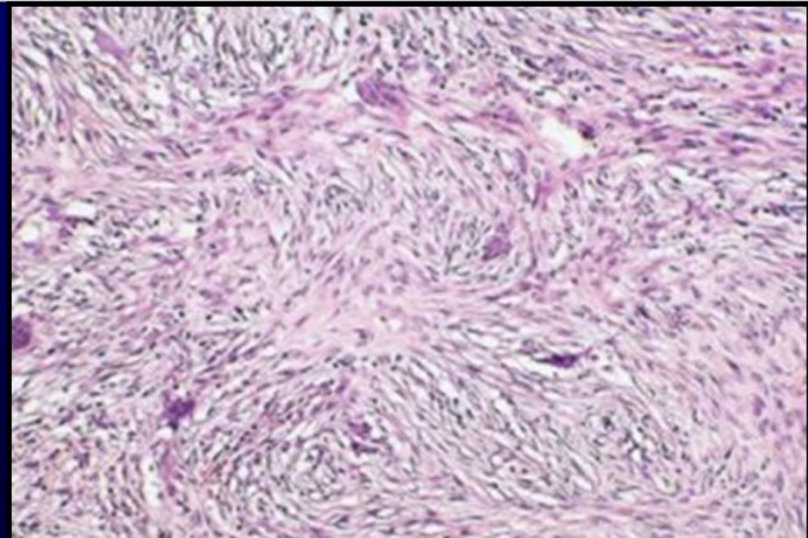
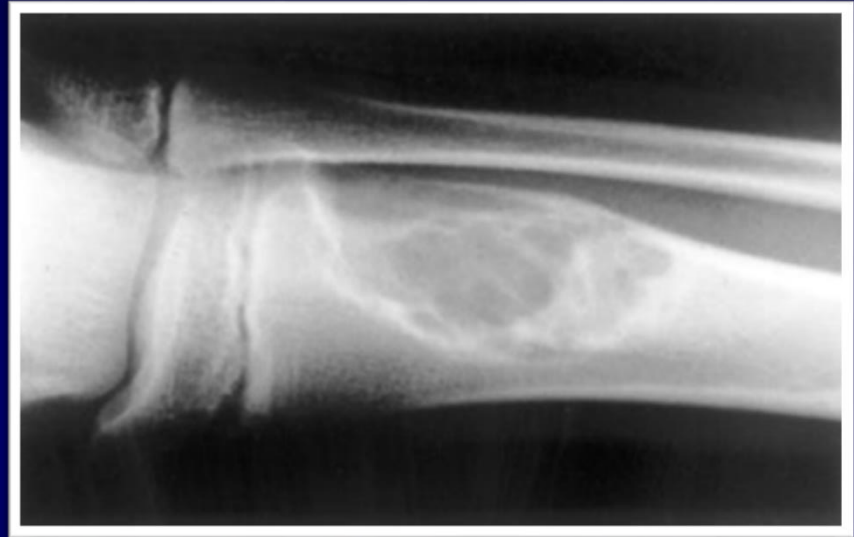ANEURYSMAL BONE CYST:

- Benign tumor
- Blood filled cyst
- Metaphysis of long bones; adults



NONOSSIFYING FIBROMA:

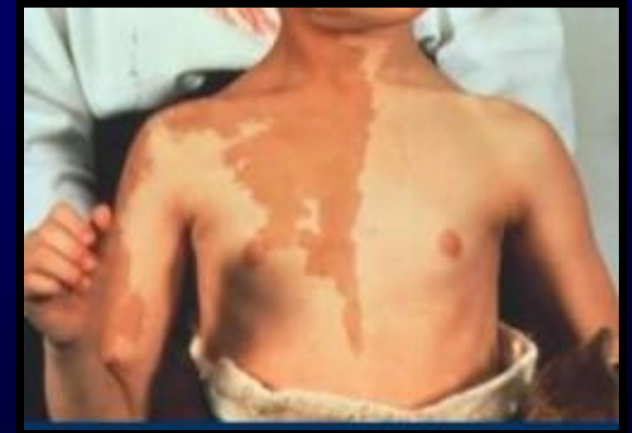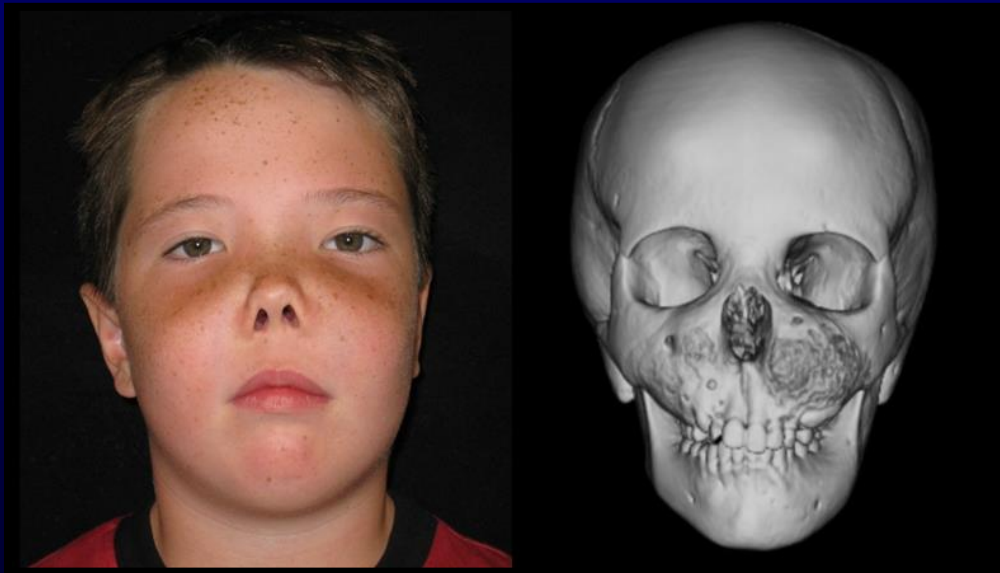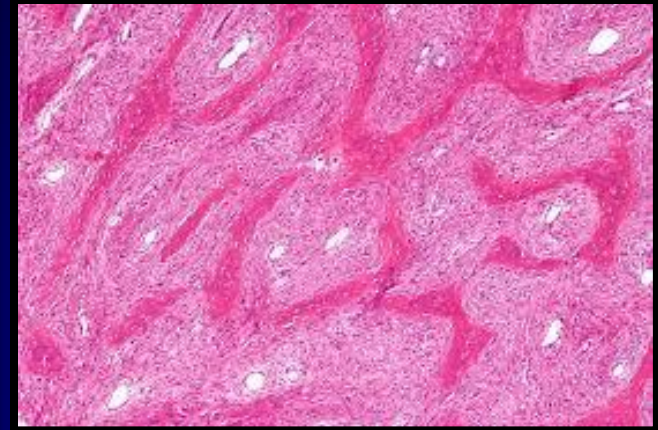
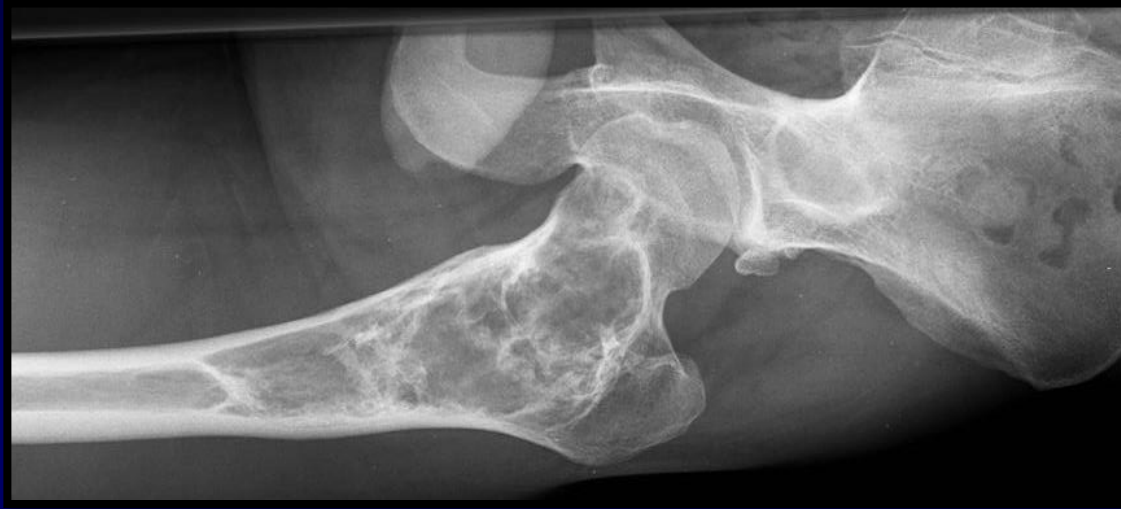- **Benign lesion, maybe reactive not a true neoplasm (other names: FCD, MFD)**
- **Metaphysis**
- **Histology: bland fibroblastic proliferation**
- **May resolve spontaneously**



FIBROUS DYSPLASIA (FD):

- **Not a real tumor; rather a developmental abnormality of bone genesis due to mutations in GNAS1 gene (cAMP mediated osteoblast differentiation).**
- **Forms of FD:**
 - **Monostotic: affecting one bone**
 - **Polystotic: multiple bones**
 - **Mazabraud syndrome: FD + soft tissue myxoma**
 - **McCune-Albright syndrome: polystotic FD + café-au-lait skin pigmentation + endocrine abnormalities (precocious puberty)**

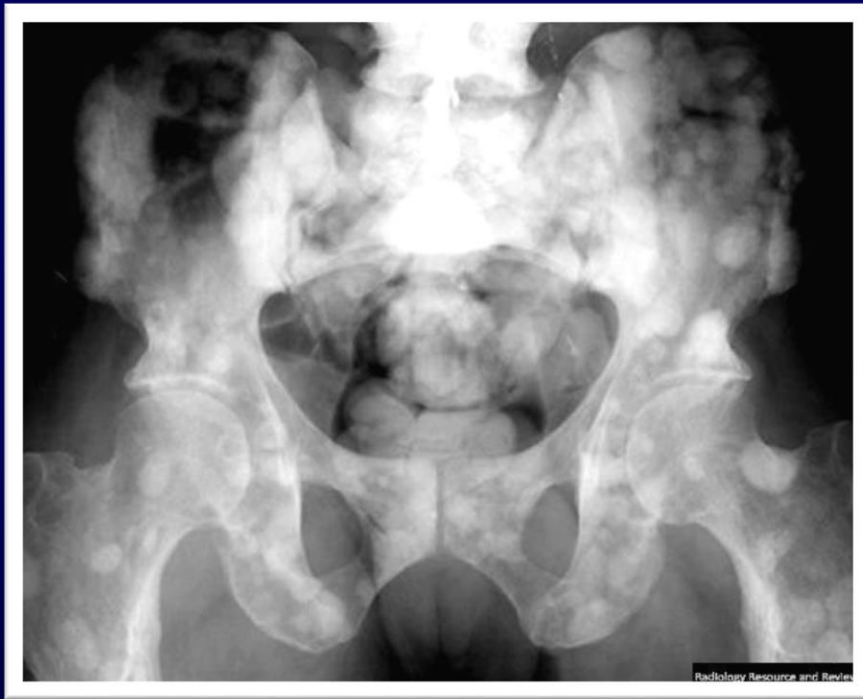McCUNE-ALBRIGHT SYNDROME:



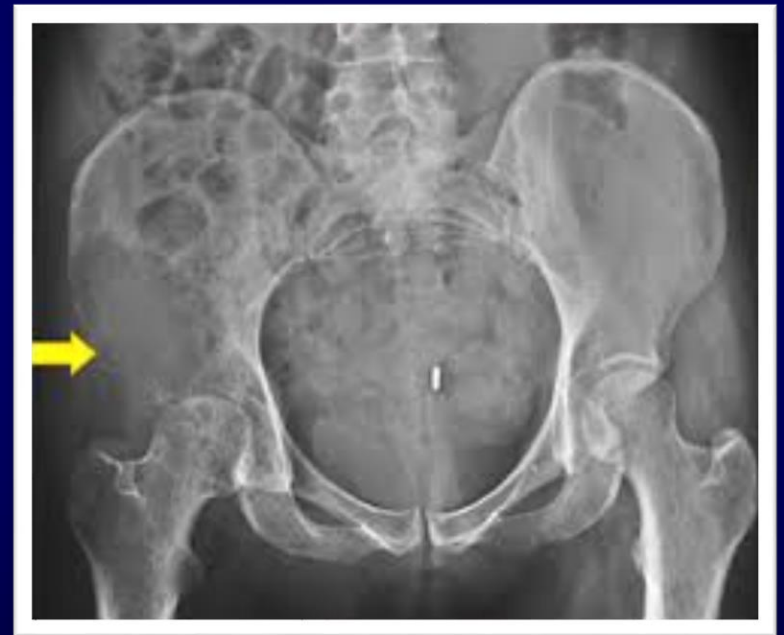METASTATIC TUMORS TO BONE:

- **Much more common than primary bone tumors**
- **In adults: most are carcinomas; lung, prostate, breast, kidney, thyroid & liver**
- **In children: Neuroblastoma, Wilms tumor and rhabdomyosarcoma**
- **Usually multiple and axial; mostly hematogenous spread.**
- **Lytic, blastic or mixed (via mediators secretions)**

BLASTIC METASTASIS



LYTIC METASTASIS





Summary

Bone Tumors and Tumorlike Lesions

Primary bone tumors are classified according to the cell of origin or the matrix that they produce. The remainder is grouped according to clinicopathologic features. Most primary bone tumors are benign. Metastases, especially from lung, prostate, kidneys, and breast, are far more common than primary bone neoplasms.

Major categories of primary bone tumors include

- **Bone forming:** Osteblastoma and osteoid osteoma consist of benign osteoblasts that synthesize osteoid. Osteosarcoma is an aggressive tumor of malignant osteoblasts, predominantly occurring in adolescents.
- **Cartilage forming:** Osteochondroma is an exostosis with a cartilage cap. Sporadic and syndromic forms arise from mutations in the *EXT* genes. Chondromas are benign tumors producing hyaline cartilage, usually arising in the digits. Chondrosarcomas are malignant tumors of chondroid cells that involve the axial skeleton in adults.
- **Ewing sarcomas** are aggressive, malignant, small round cell tumors most often associated with t(11;22).
- **Fibrous dysplasia** is an example of a disorder caused by gain-of-function mutations that occur during development.