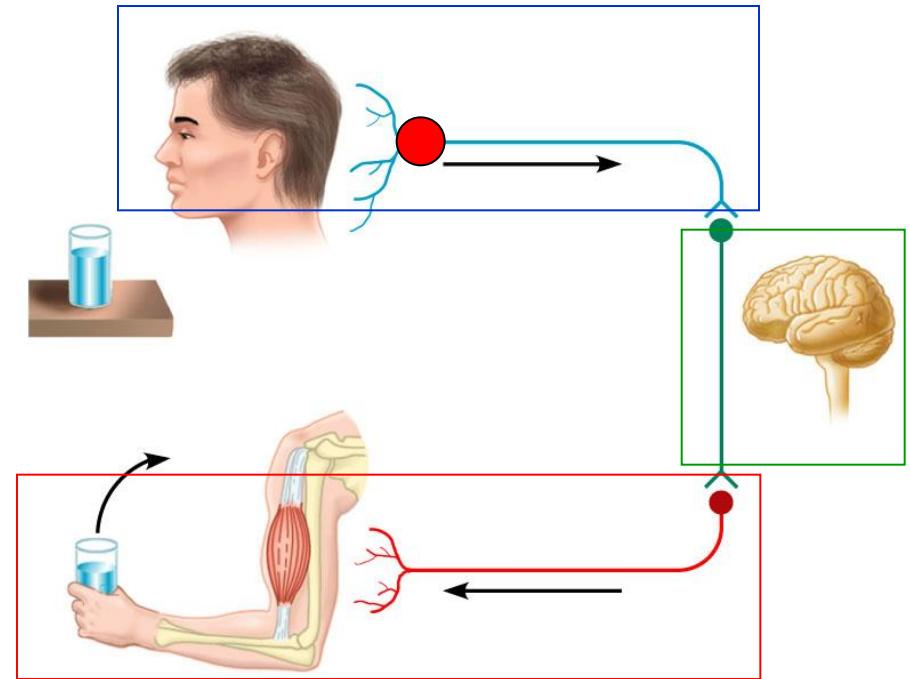
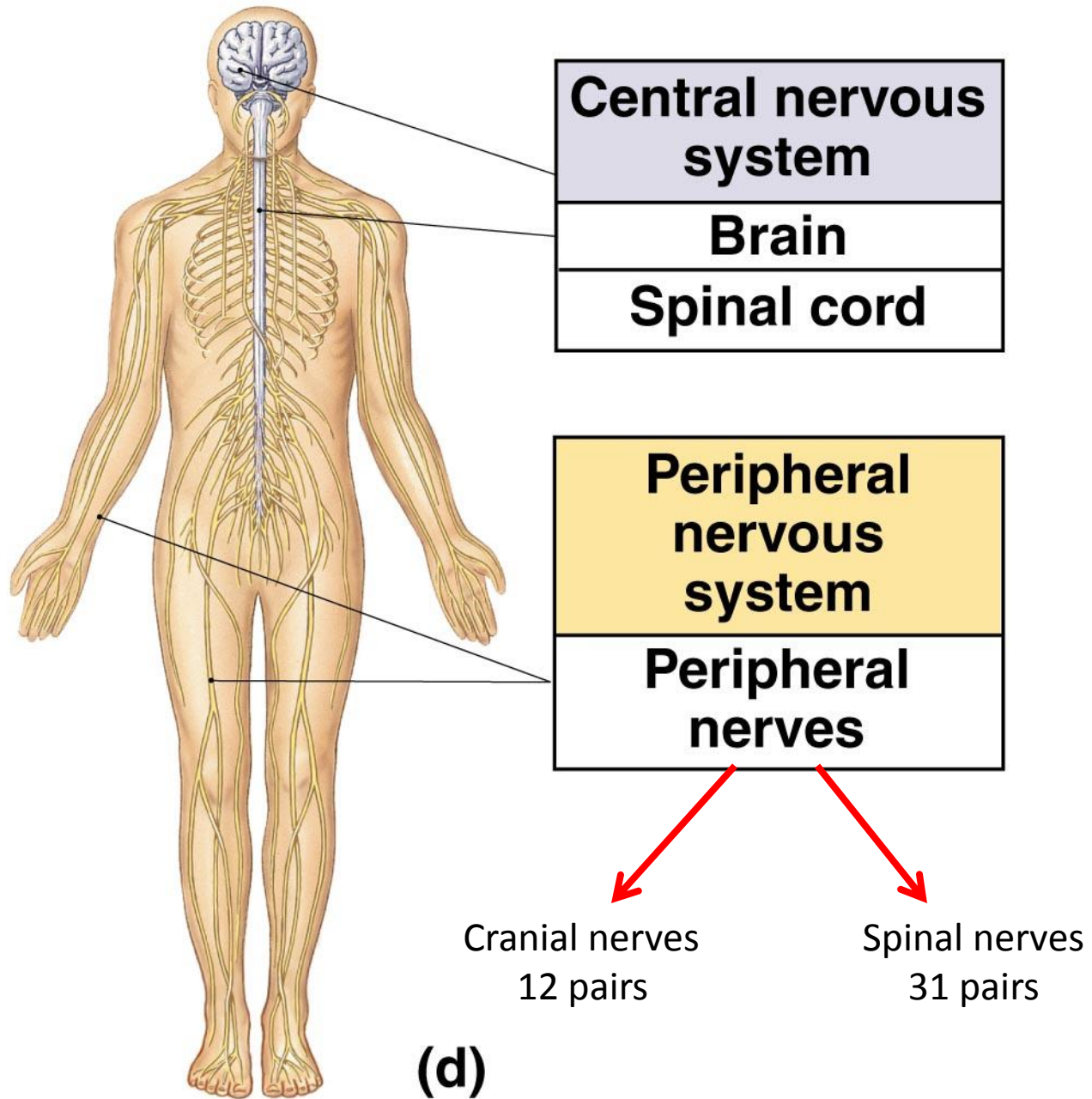


Introduction to Head and Neck Anatomy

Nervous Tissue

- Controls and integrates all body activities within limits that maintain life
- Three basic functions
 1. sensing changes with **sensory receptors**
 2. **interpreting** and remembering those changes
 3. **reacting** to those changes with effectors (motor function)

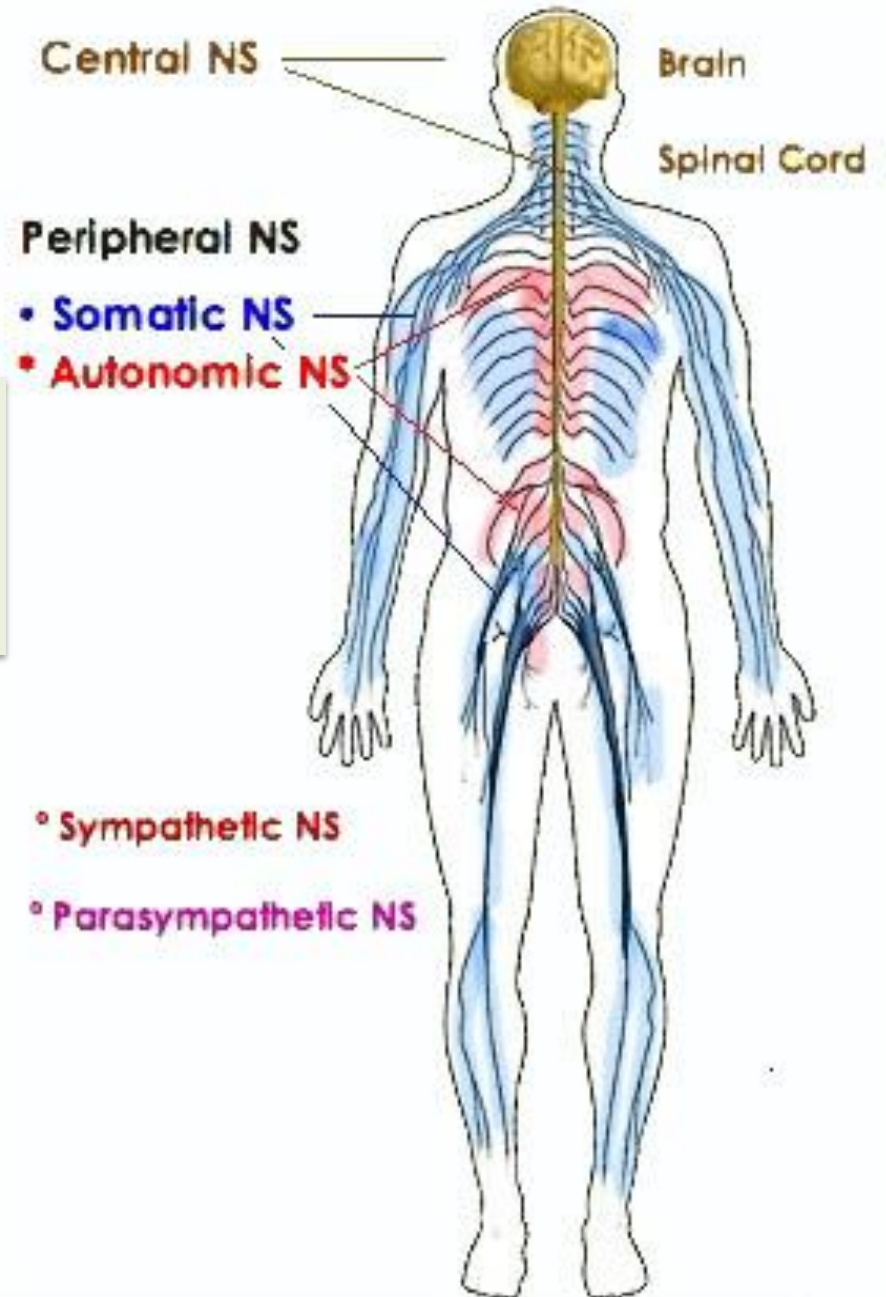




(d)

The PNS is divided into :

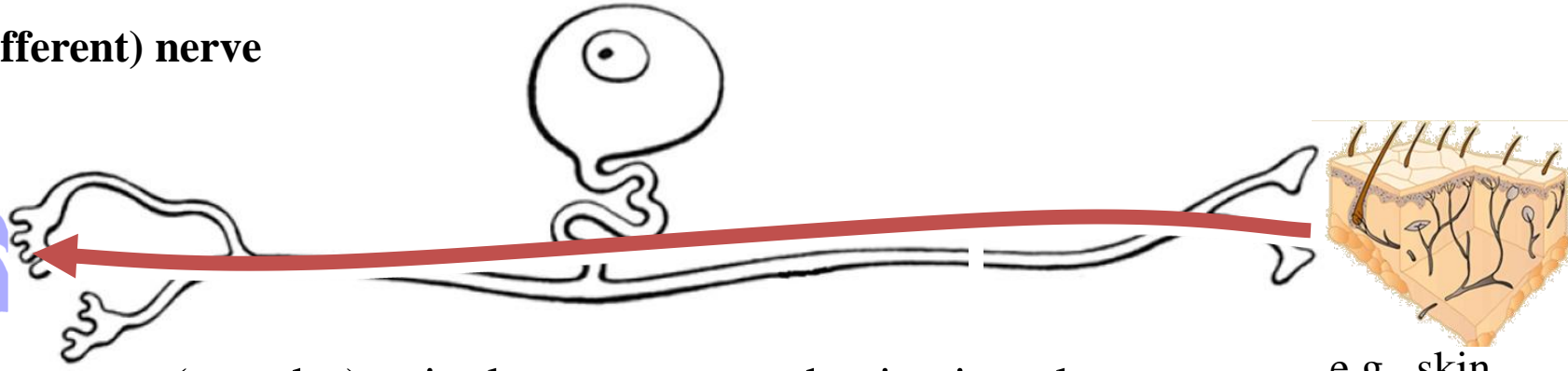- 1- **Somatic nervous system (SNS)**
- 2- **Autonomic nervous system (ANS)**



Sensory (Afferent) vs. Motor (Efferent)

sensory (afferent) nerve

CNS

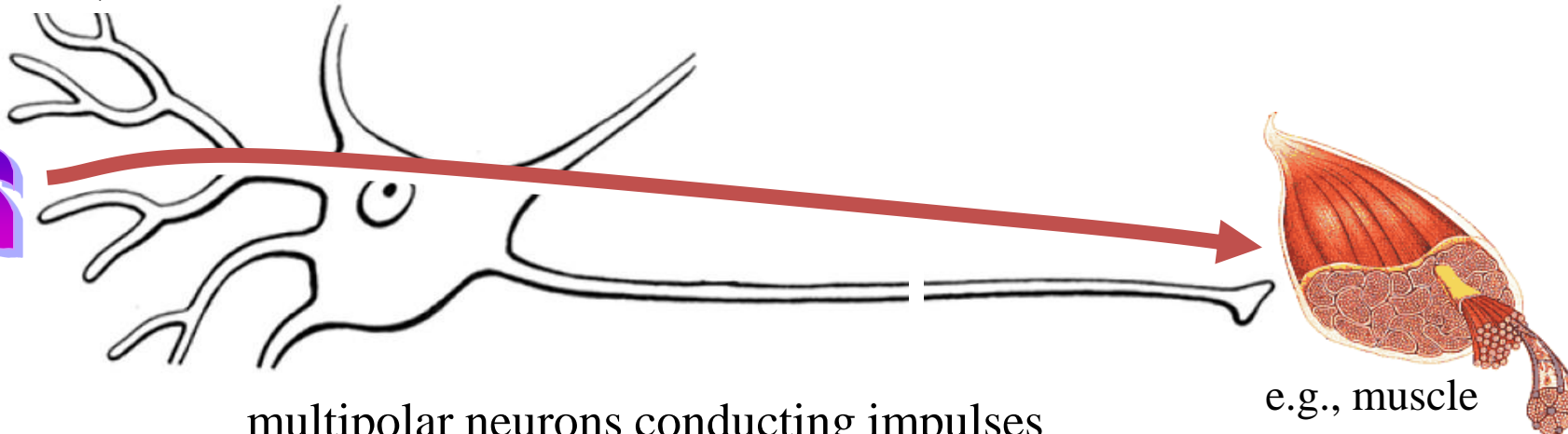


(pseudo-) unipolar neurons conducting impulses from sensory organs to the CNS

e.g., skin

motor (efferent) nerve

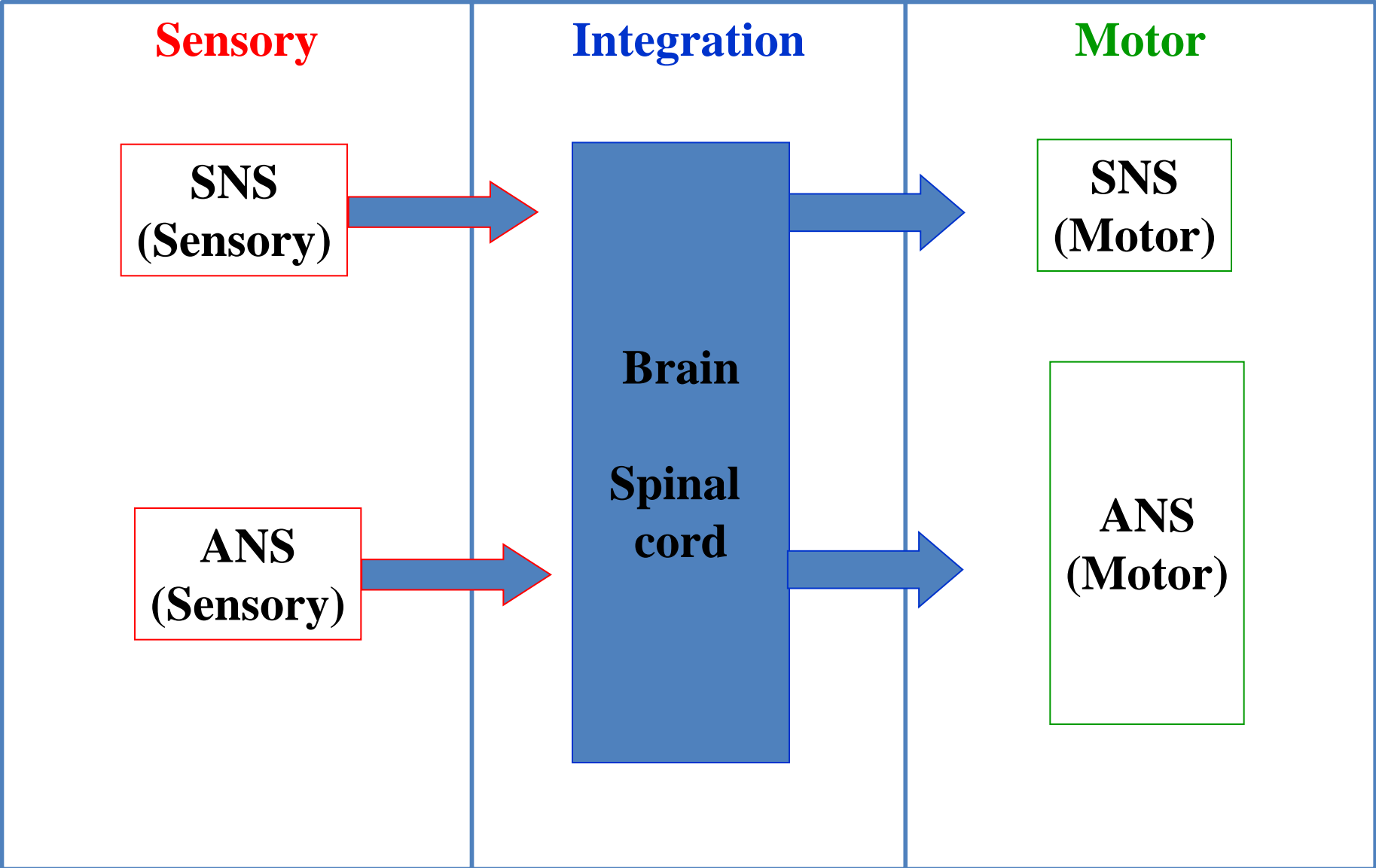
CNS



multipolar neurons conducting impulses from the CNS to effector organs (muscles & glands)

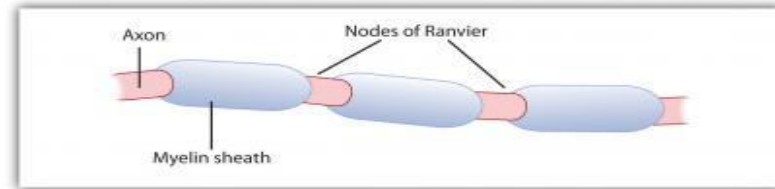
e.g., muscle

Organization



Neurons

- Dendrites: carry nerve impulses toward cell body
- Axon: carries impulses away from cell body
- Synapses: site of communication between neurons using chemical neurotransmitters
- Myelin & myelin sheath: lipoprotein covering that increases axonal conduction velocity



dendrites

axon with
myelin sheath

cell
body

synapses

Structural classification of neurons

1. Multipolar neurons

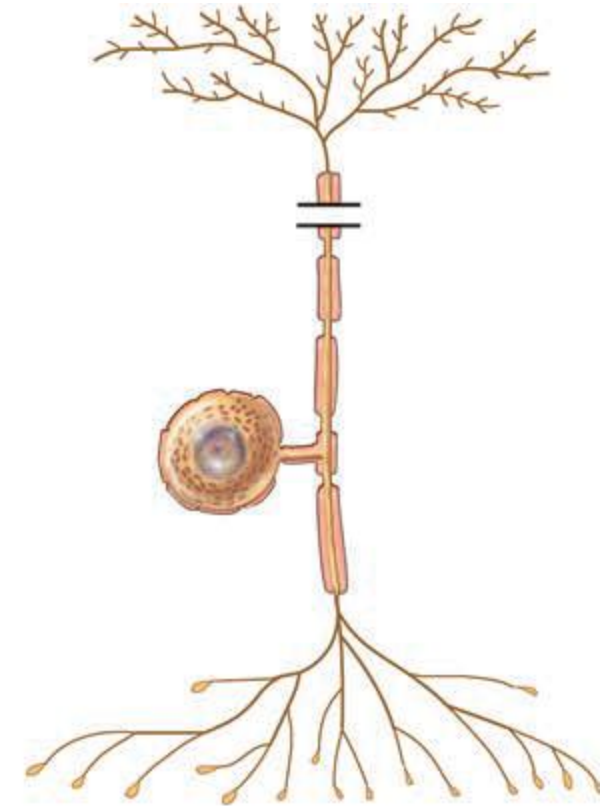
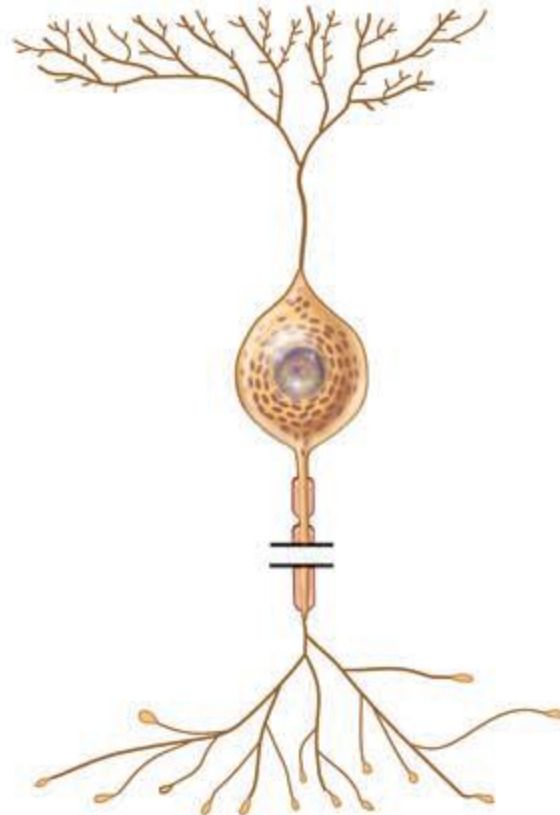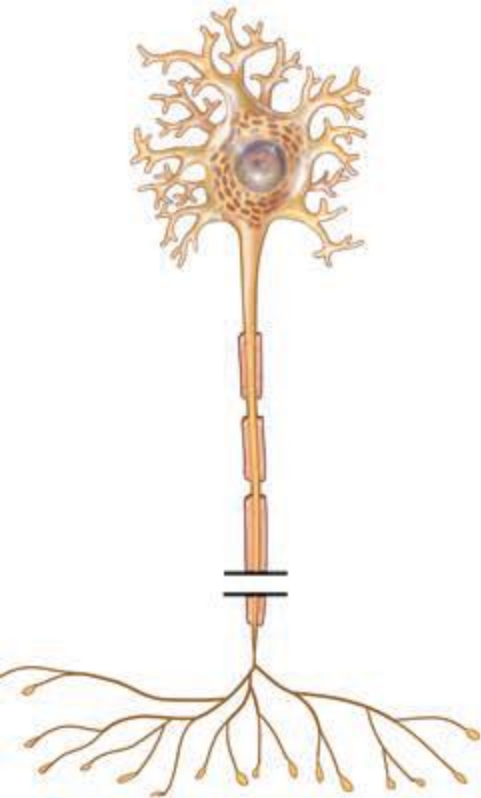
- Usually have several dendrites and one axon
- Motor neurons

2. Bipolar neurons

- Have one main dendrite and one axon
- The retina of the eye

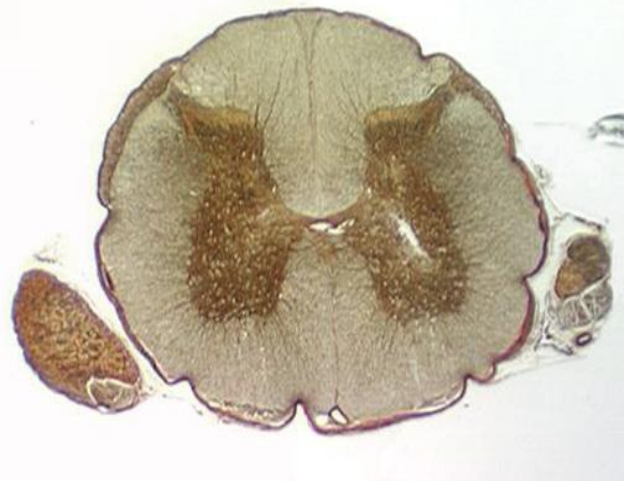3. Unipolar neurons (pseudounipolar neurons)

- Sensory neurons

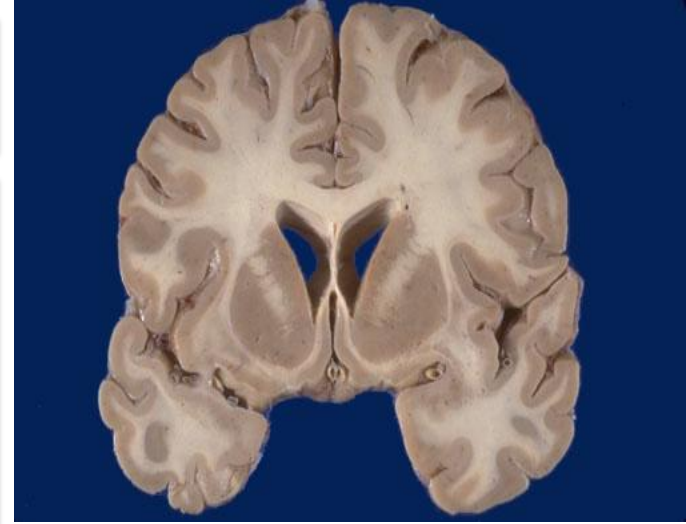


Clusters of Neuronal Cell Bodies

1. **Ganglion** (plural is ganglia) a cluster of neuronal cell bodies located in the PNS.
2. **Nucleus** (plural is nuclei) : a cluster of neuronal cell bodies located in the CNS.



Transverse section of spinal cord



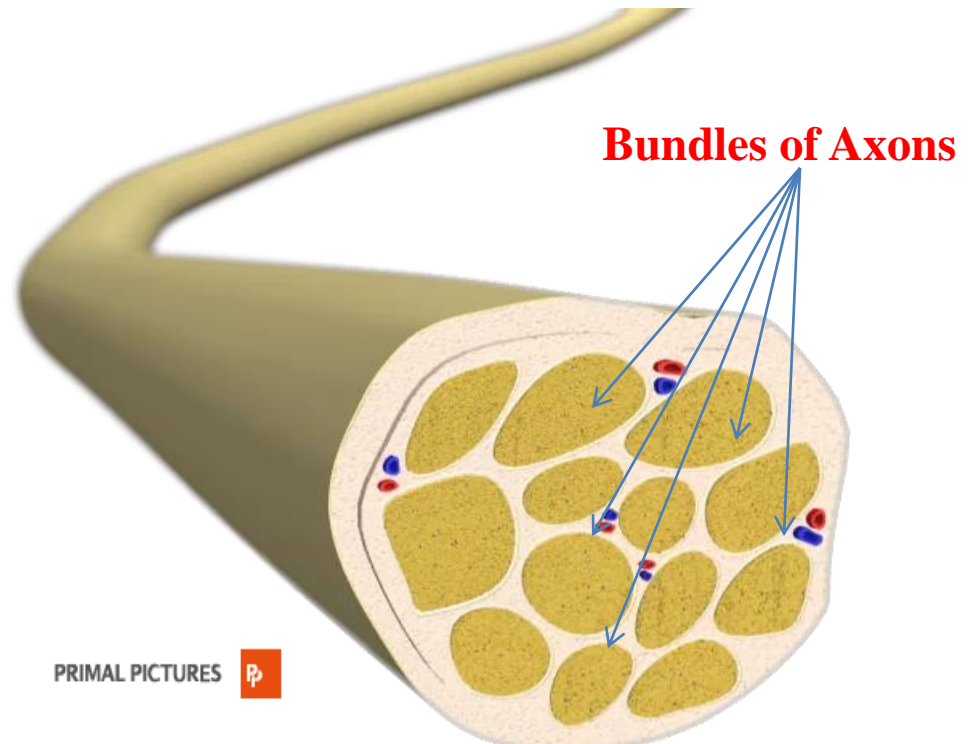
Coronal section of brain

Bundles of Axons

A **nerve**: is a bundle of axons that is located in the PNS.

- Cranial nerves connect the brain to the periphery
- Spinal nerves connect the spinal cord to the periphery

A **tract**: is a bundle of axons located in the CNS.



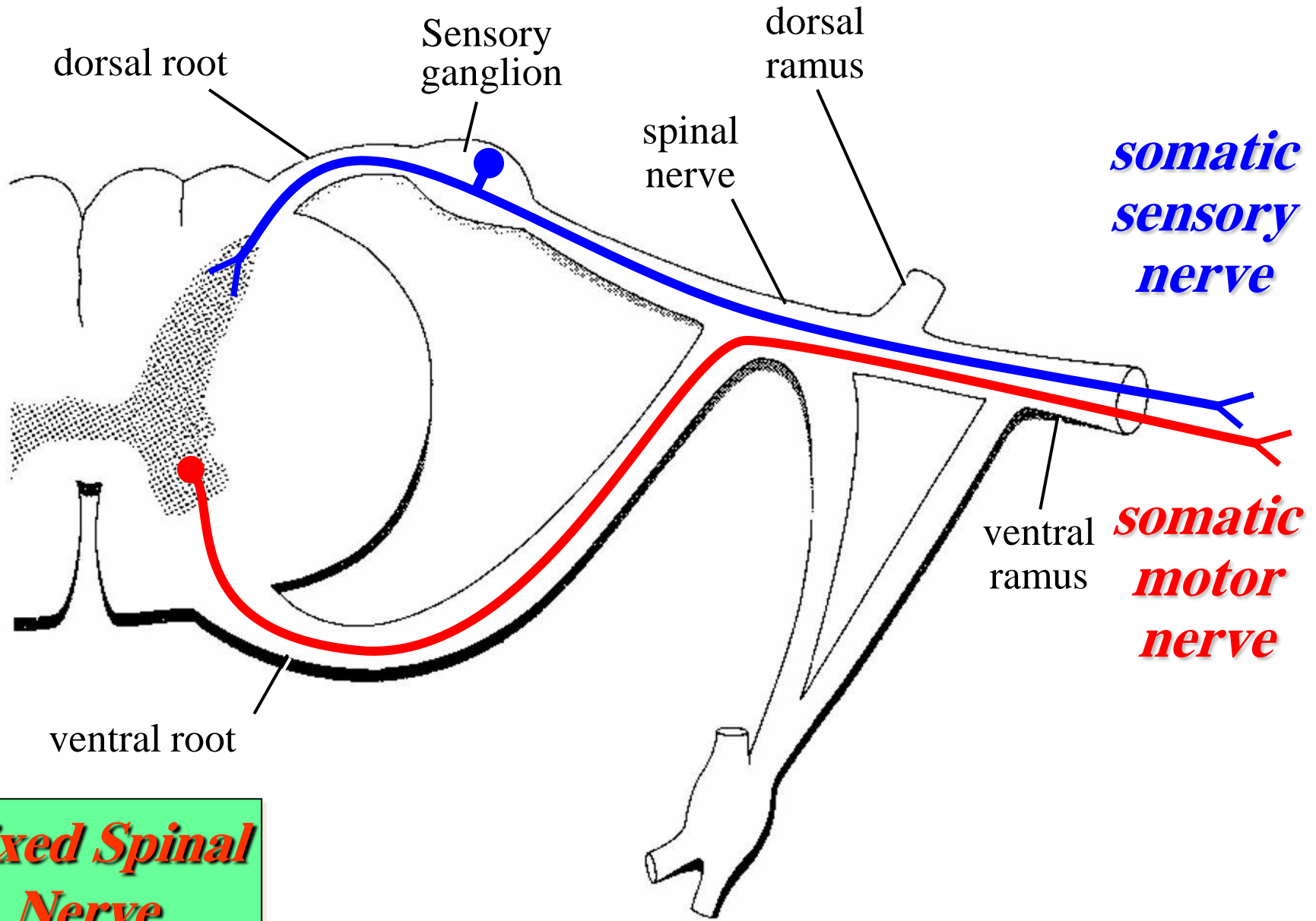
**Clusters of
Neuronal
Cell
Bodies**



**Bundles
of
Axons**

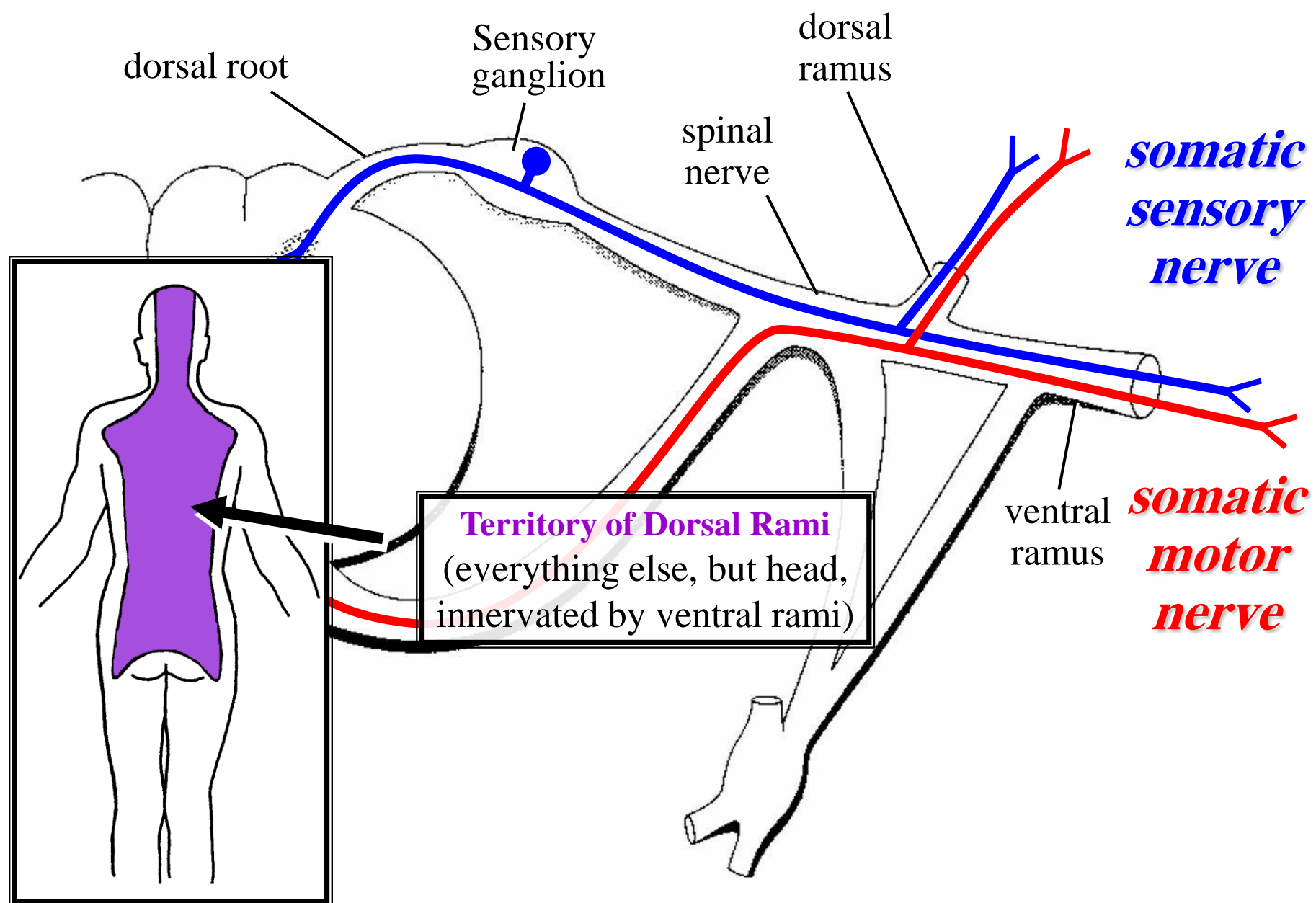


Structure of Spinal Nerves: Somatic Pathways

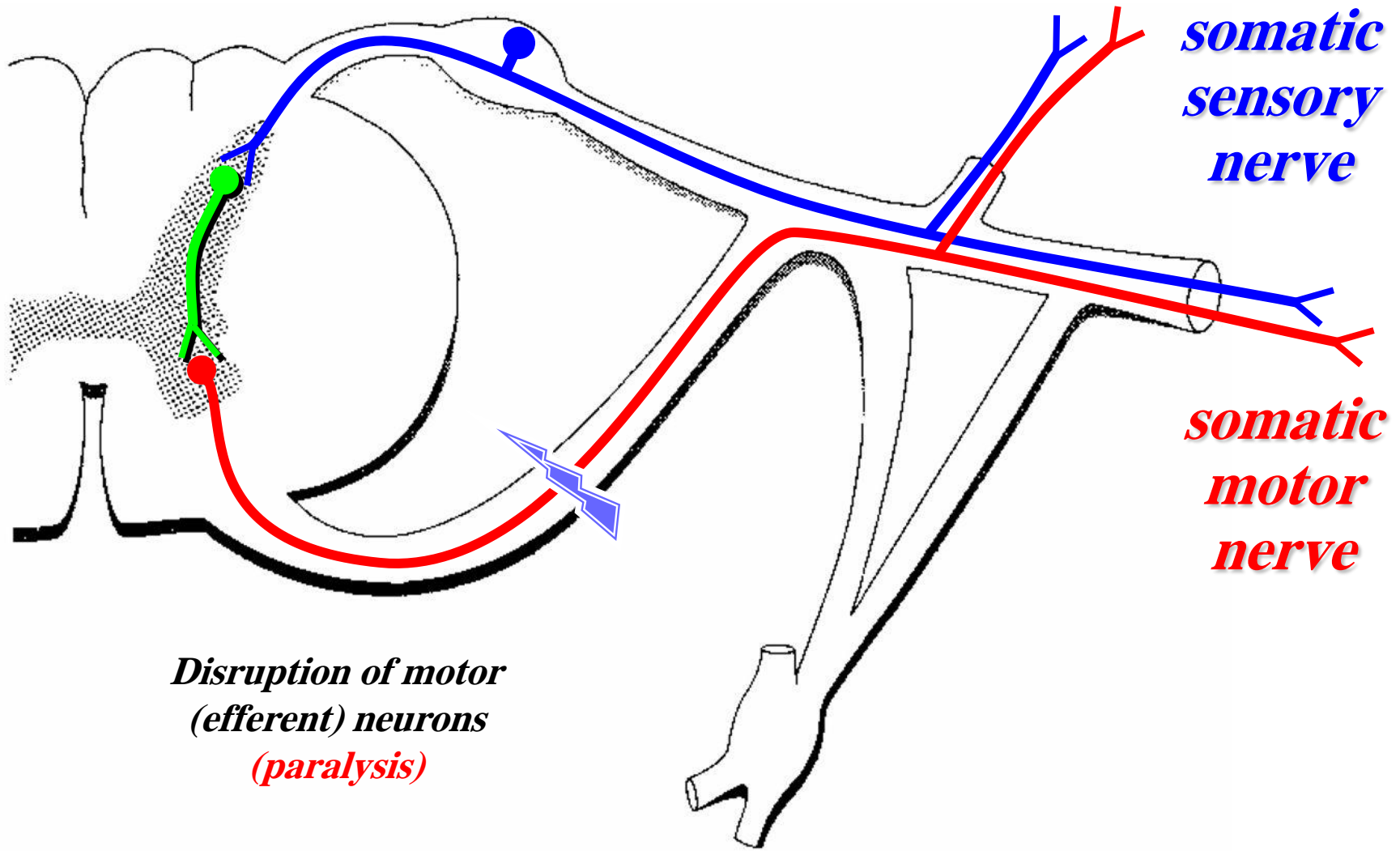


Mixed Spinal Nerve

Structure of Spinal Nerves: Dorsal & Ventral Rami

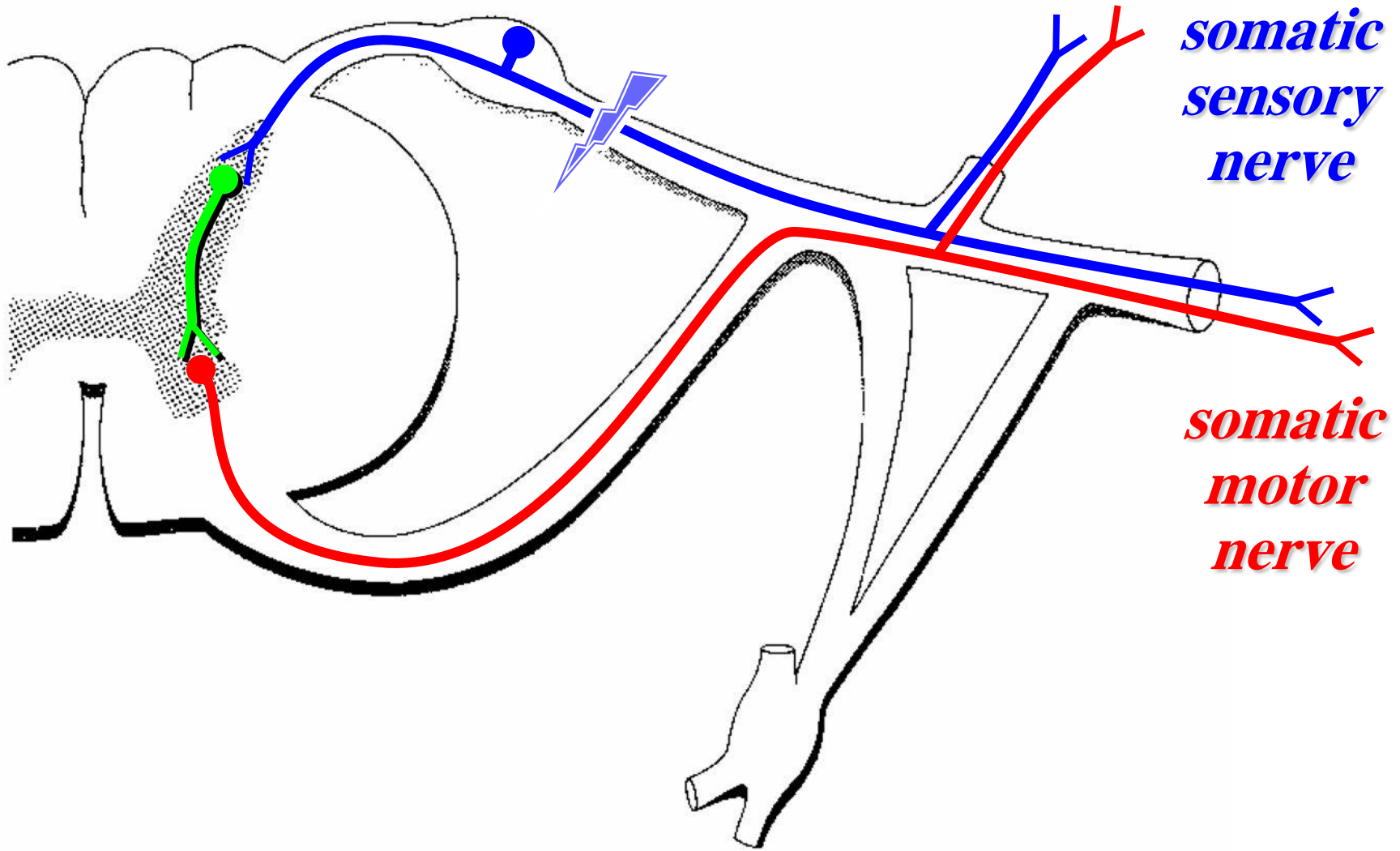


Impact of Lesions



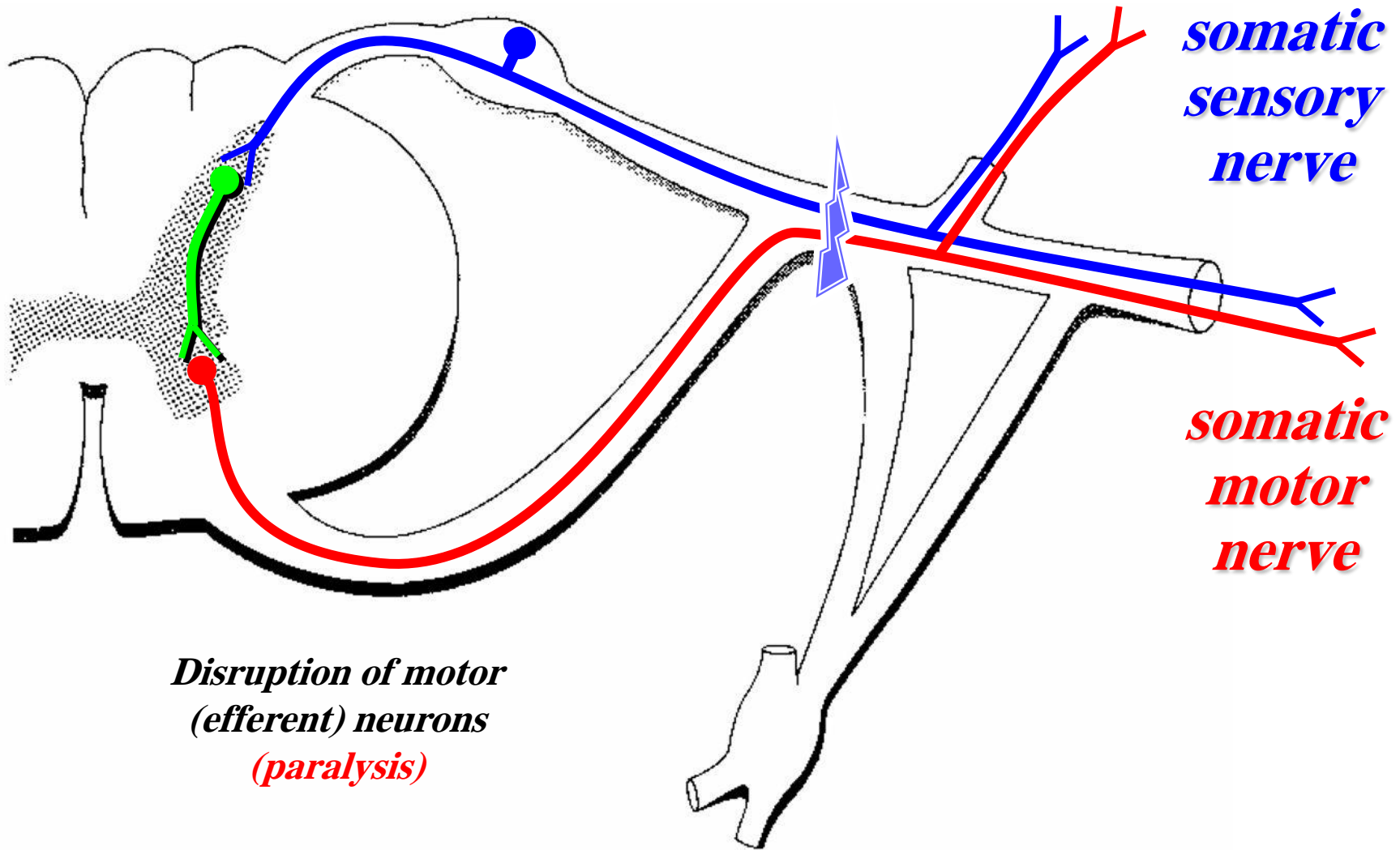
Impact of Lesions

Disruption of sensory (afferent) neurons (paresthesia)



Impact of Lesions

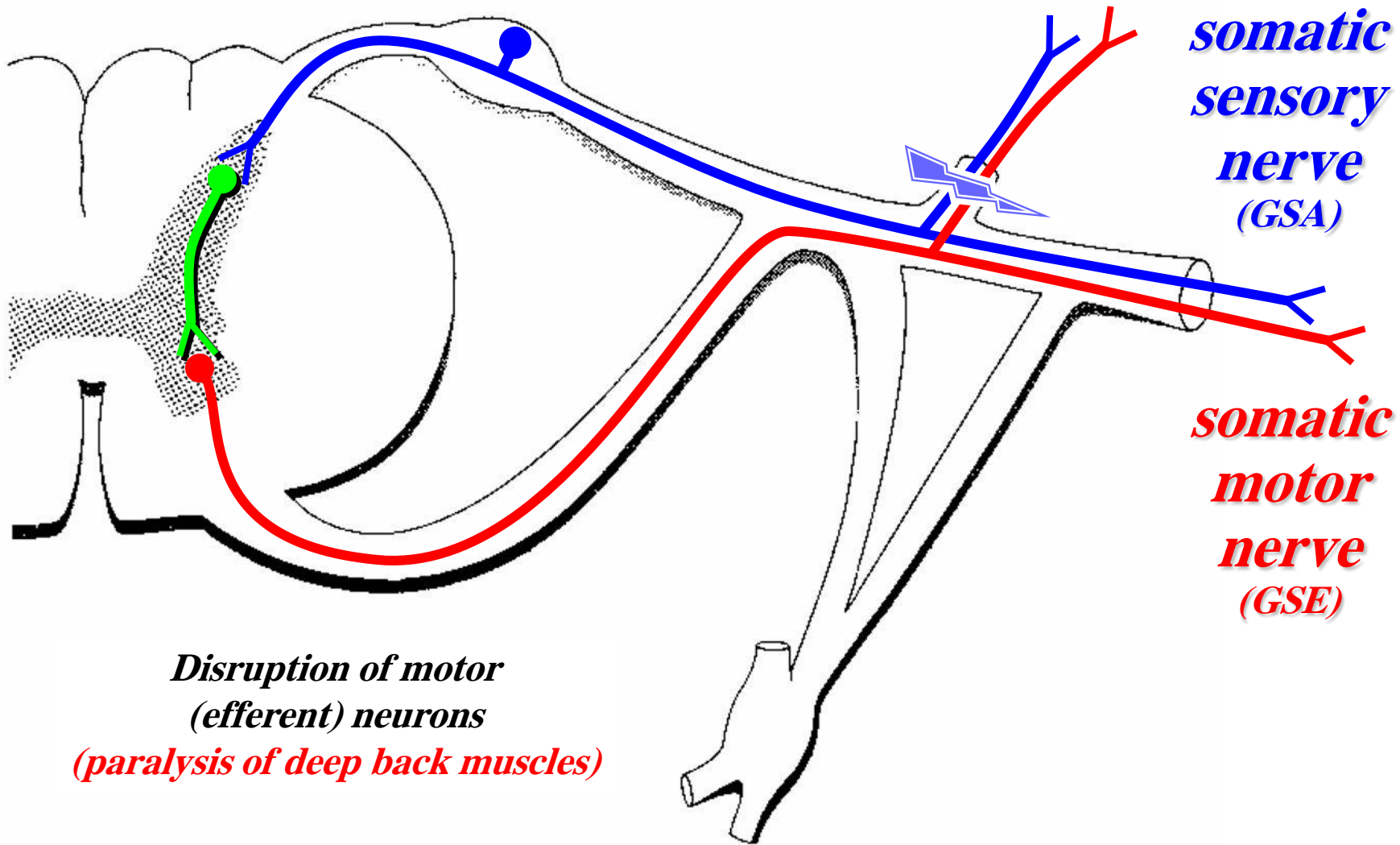
Disruption of sensory (afferent) neurons (paresthesia)



Disruption of motor (efferent) neurons (paralysis)

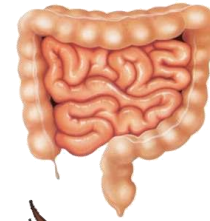
Impact of Lesions

Disruption of sensory (afferent) neurons (back paresthesia)



Autonomic nervous system

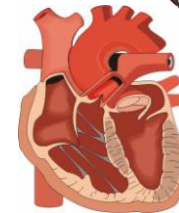
- ANS is the subdivision of the peripheral nervous system that regulates body activities that are generally **not under conscious control**
- **Visceral motor** innervates **non-skeletal (non-somatic) muscles**
- Composed of a special group of neurons serving:
 - Cardiac muscle (the heart)
 - Smooth muscle (walls of viscera and blood vessels)
 - Glands



glands



smooth
muscle



cardiac
muscle

Divisions of the autonomic nervous system

- Parasympathetic division
- Sympathetic division

Serve most of the same organs but cause opposing or antagonistic effects

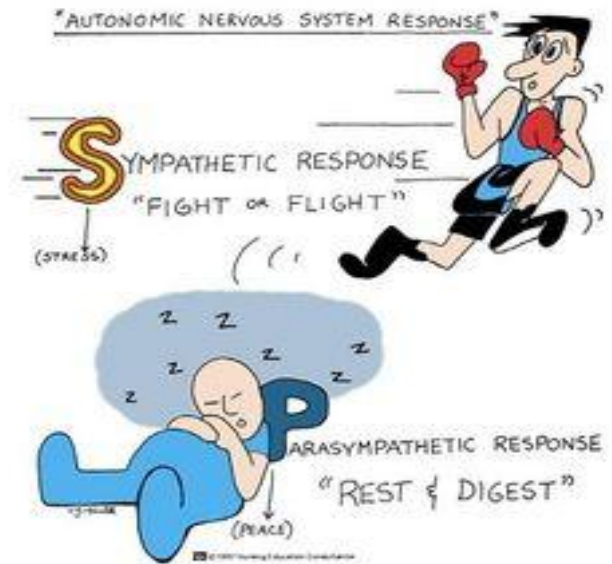


Parasympathetic: routine maintenance

“rest & digest”

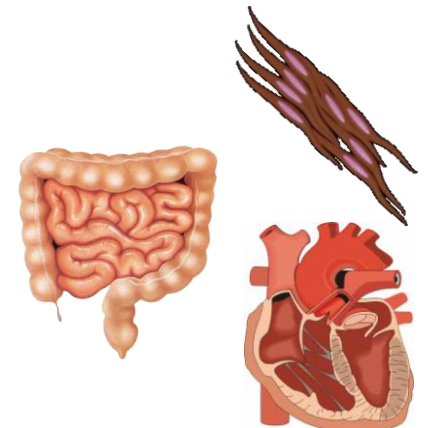
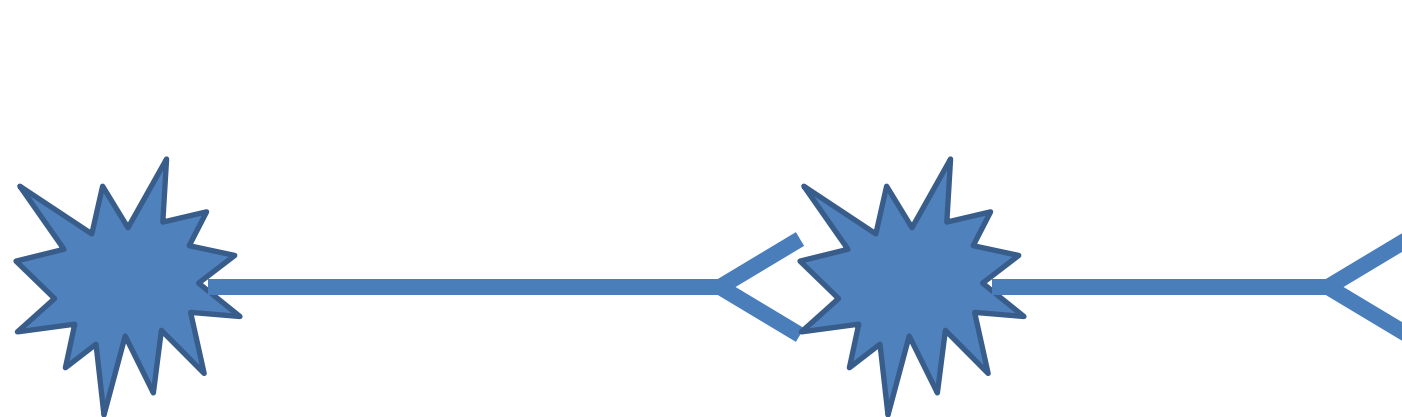
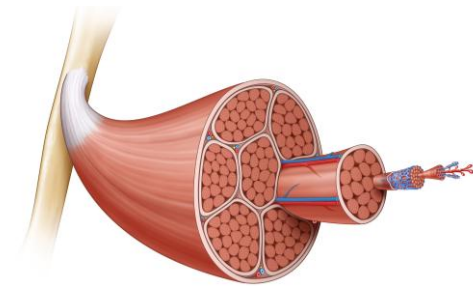
Sympathetic: mobilization & increased metabolism

“fight, flight or fright” or “fight, flight or freeze”

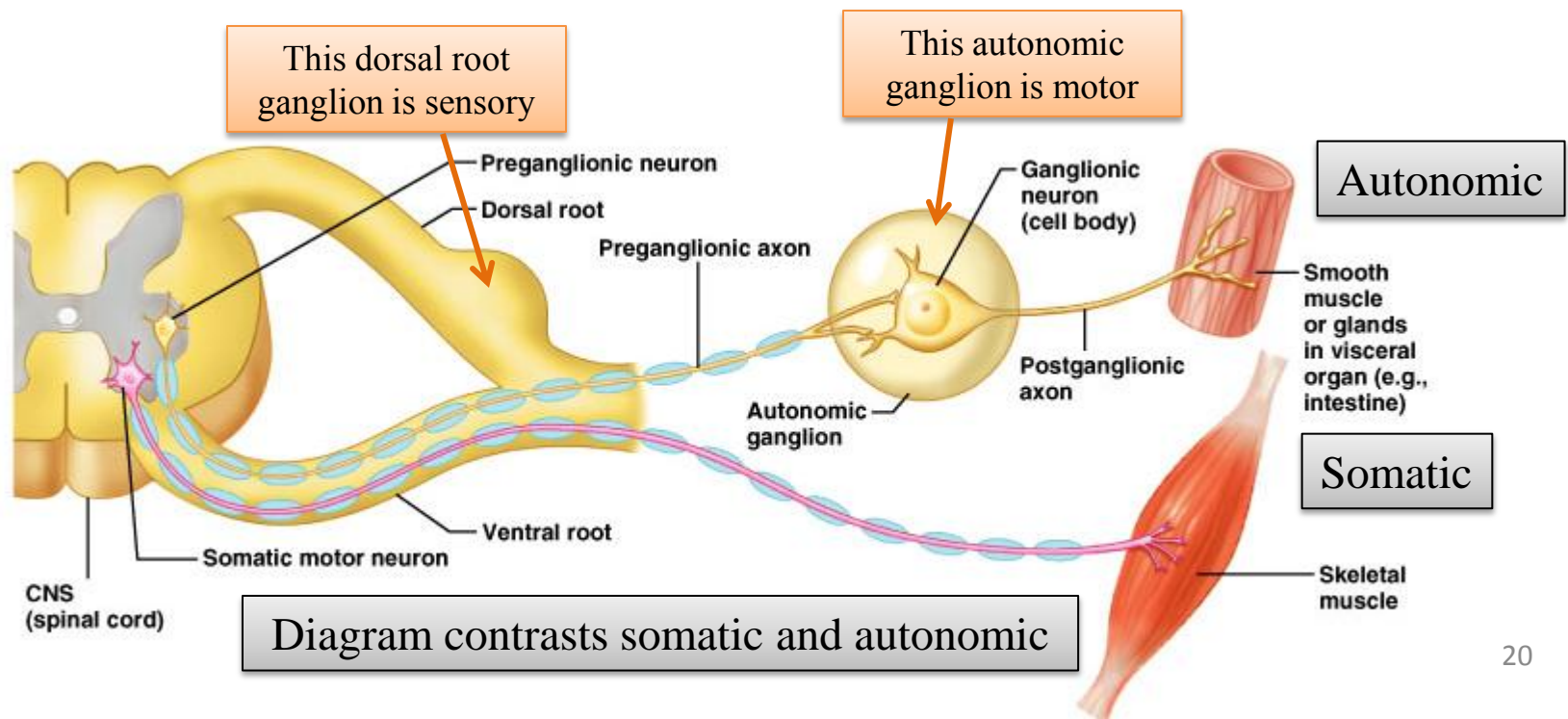


Basic anatomical difference between the motor pathways of the voluntary somatic nervous system (to skeletal muscles) and those of the autonomic nervous system

- Somatic division:
 - Cell bodies of motor neurons reside in CNS (brain or spinal cord)
 - Their axons (sheathed in spinal nerves) extend all the way to their skeletal muscles
- Autonomic system: chains of two motor neurons
 - 1st = preganglionic neuron (cell body in brain or cord)
 - 2nd = postganglionic neuron (cell body in ganglion outside CNS)



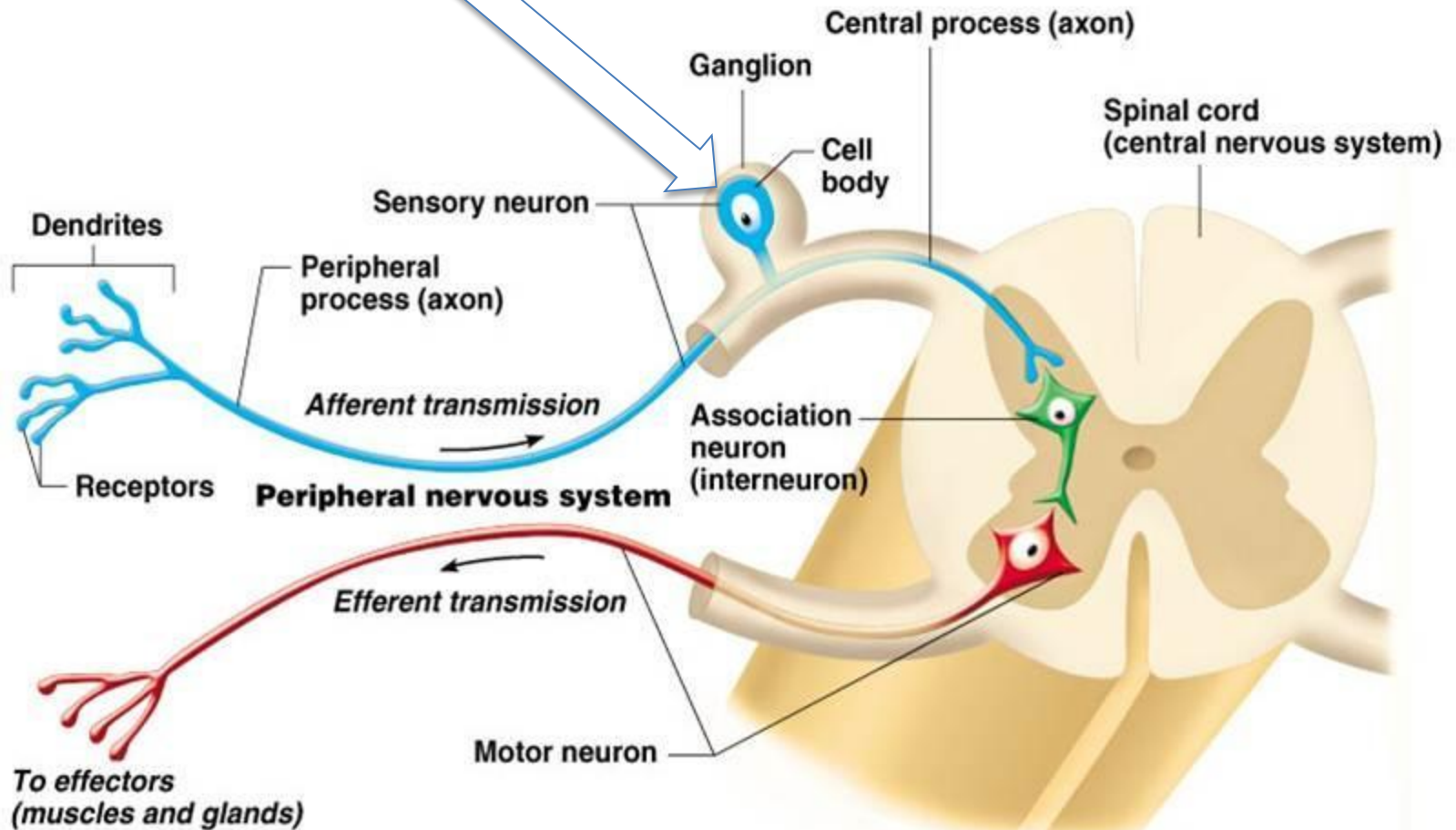
- Axon of 1st (preganglionic) neuron leaves CNS to synapse with the 2nd (ganglionic) neuron
- Axon of 2nd (postganglionic) neuron extends to the organ it serves



Ganglia

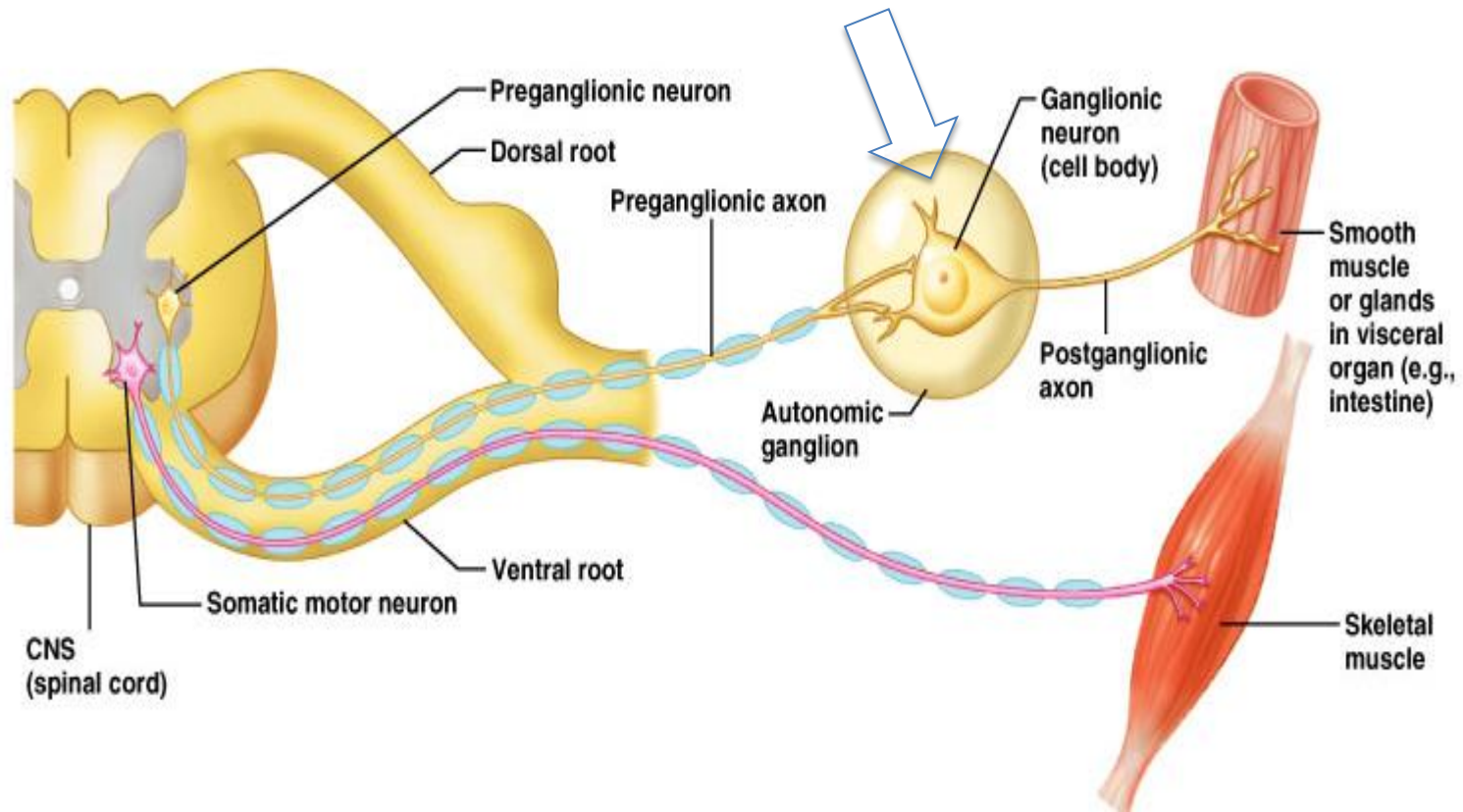
- Ganglia Are Masses Of Neuronal Cell bodies, Usually Defined As Being Outside The Central Nervous System. They Seem To Act As Coordinating Way Stations.
- Two type Ganglia:
 1. Sensory.
 2. Autonomic

Sensory ganglion



Sensory ganglia do not receive synapses

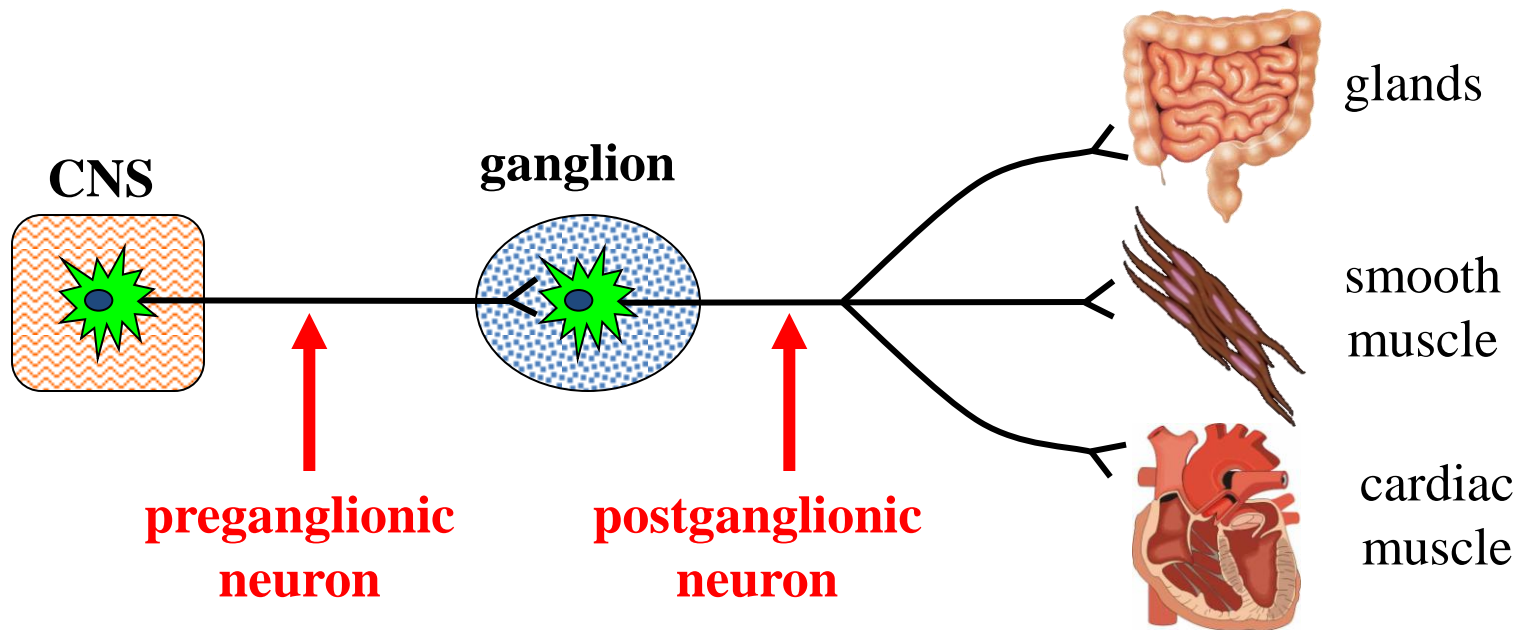
Autonomic ganglion



Autonomic ganglia do contain synapses

Autonomic Nervous System Similarities between Sympathetic & Parasympathetic

- Both are efferent (motor) systems: “visceromotor”
- Both involve regulation of the “internal” environment generally outside of our conscious control: “autonomous”
- Both involve 2 neurons that synapse in a peripheral ganglion
- Innervate glands, smooth muscle, cardiac muscle

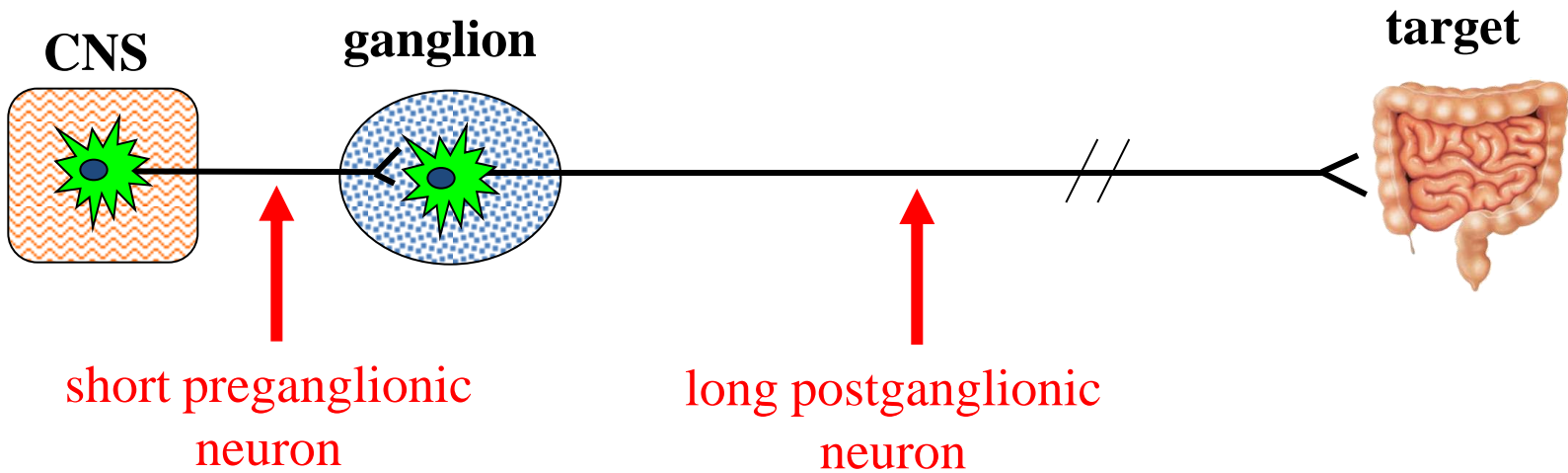


Autonomic Nervous System

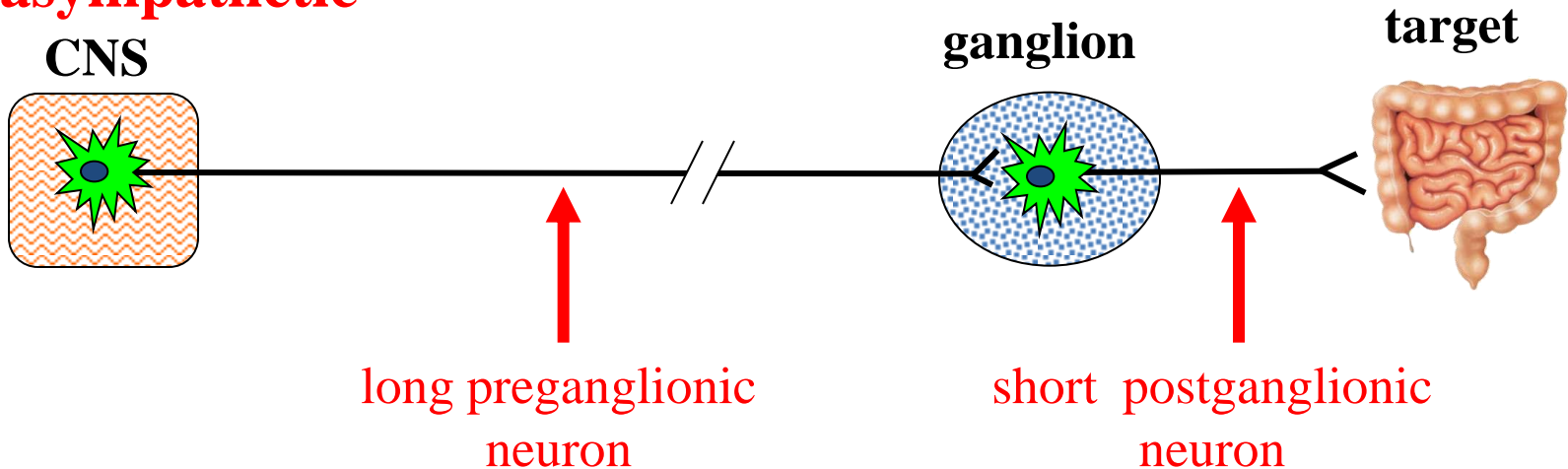
Differences between Sympathetic & Parasympathetic

Relative Lengths of Neurons

Sympathetic



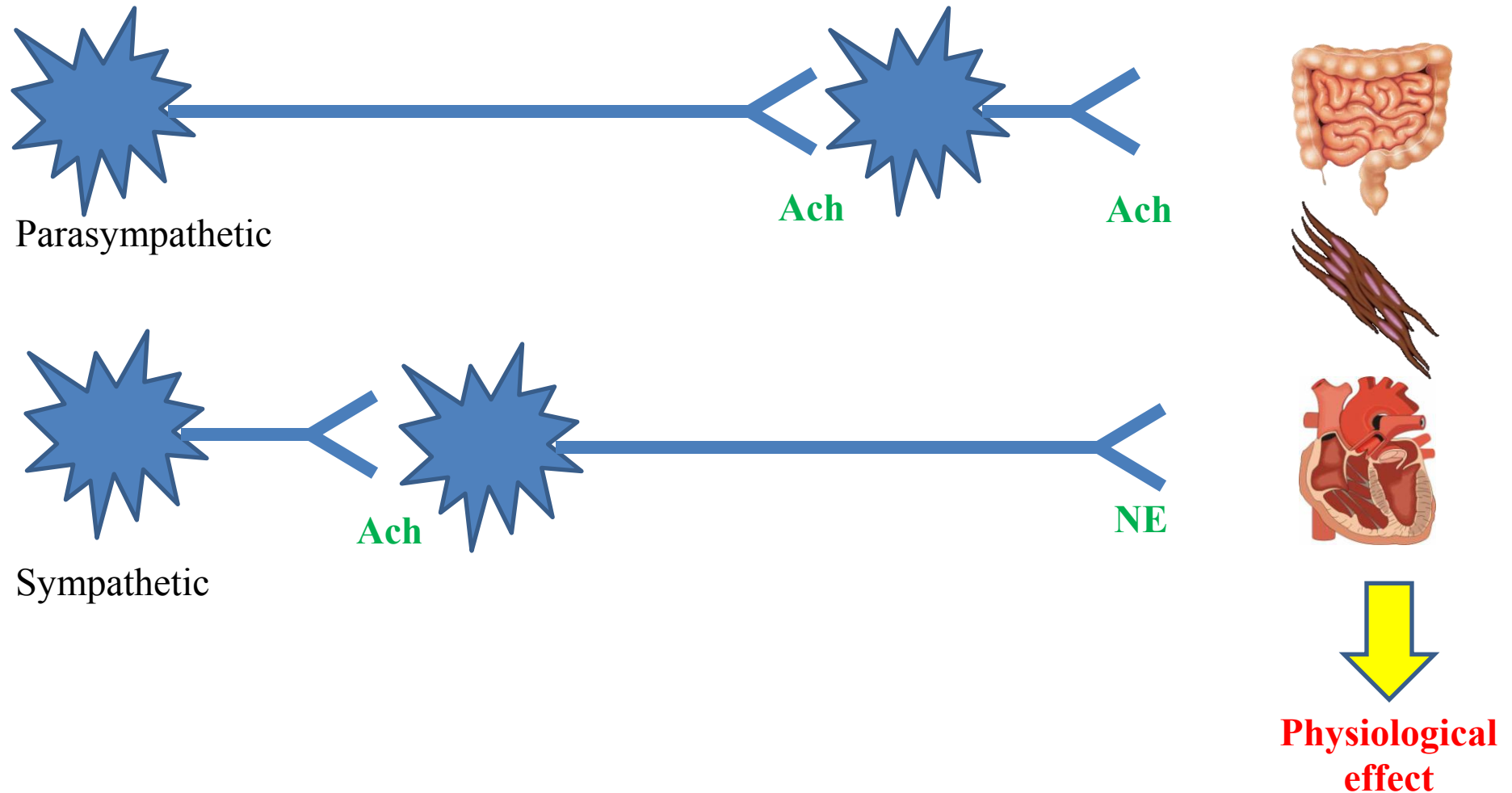
Parasympathetic



Overview of the Autonomic Nervous System

Differences between Sympathetic & Parasympathetic

Types of neurotransmitters



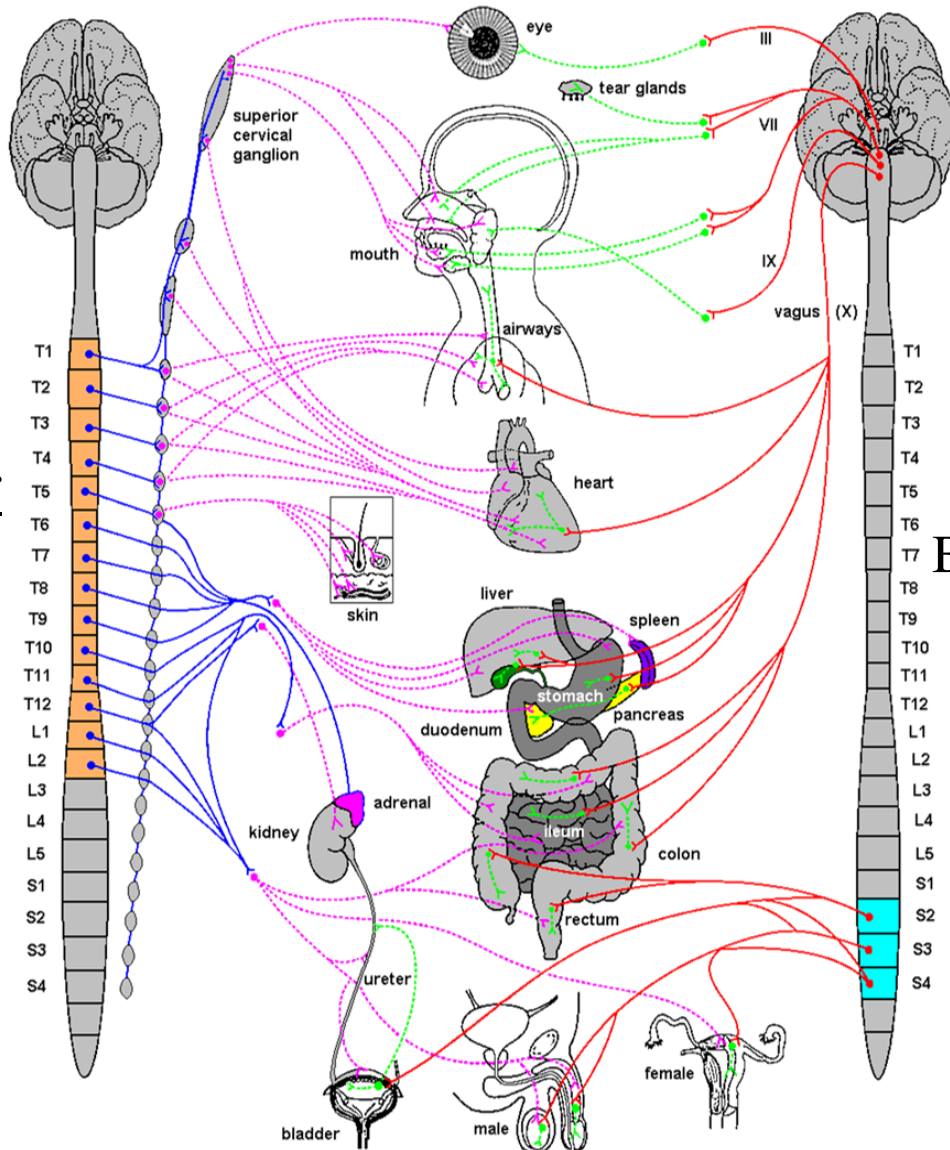
Autonomic Nervous System

Differences between Sympathetic & Parasympathetic

Location of Preganglionic Cell Bodies

Sympathetic

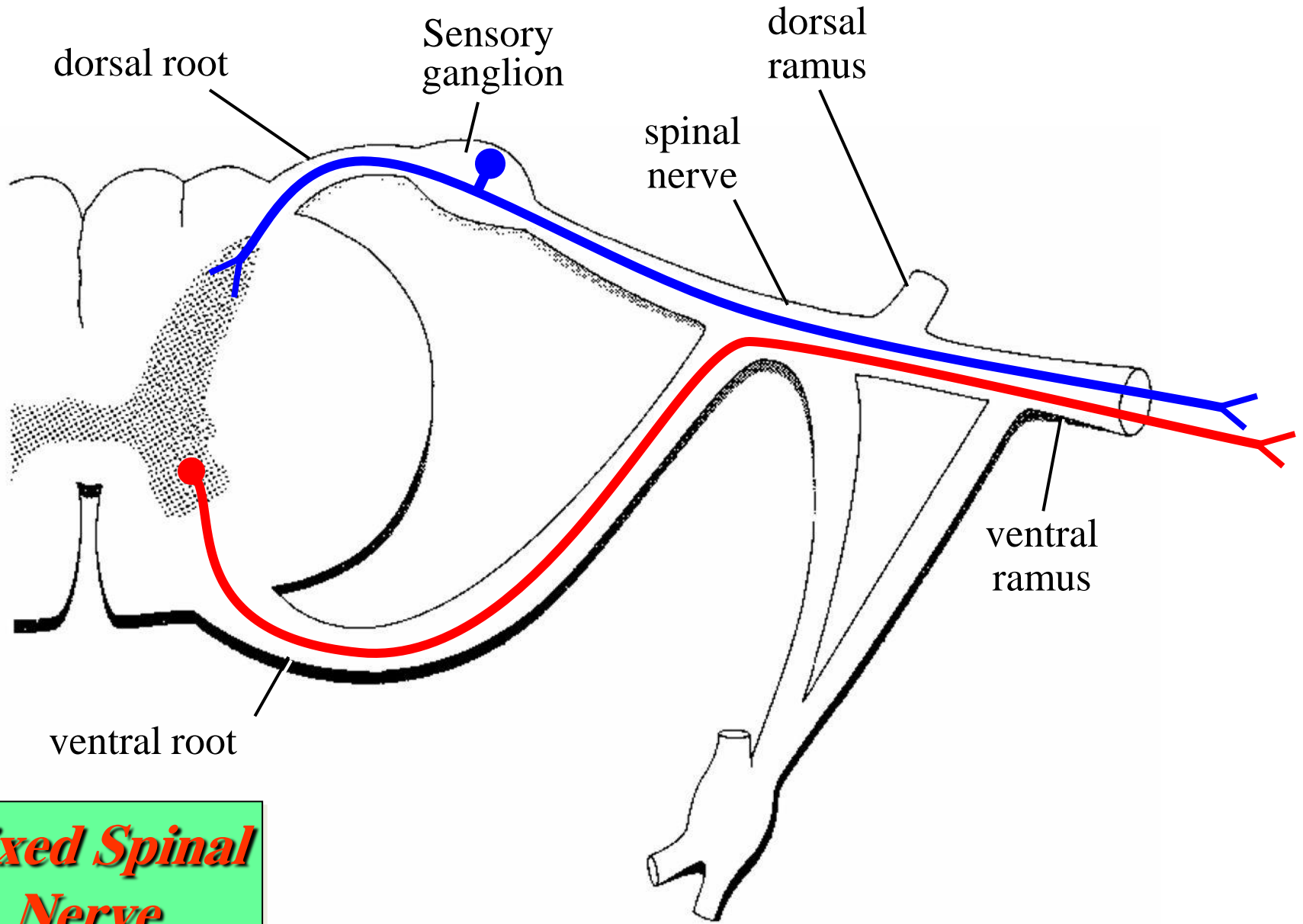
Thoracolumbar
T1 – L2 levels of
the spinal cord



Parasympathetic

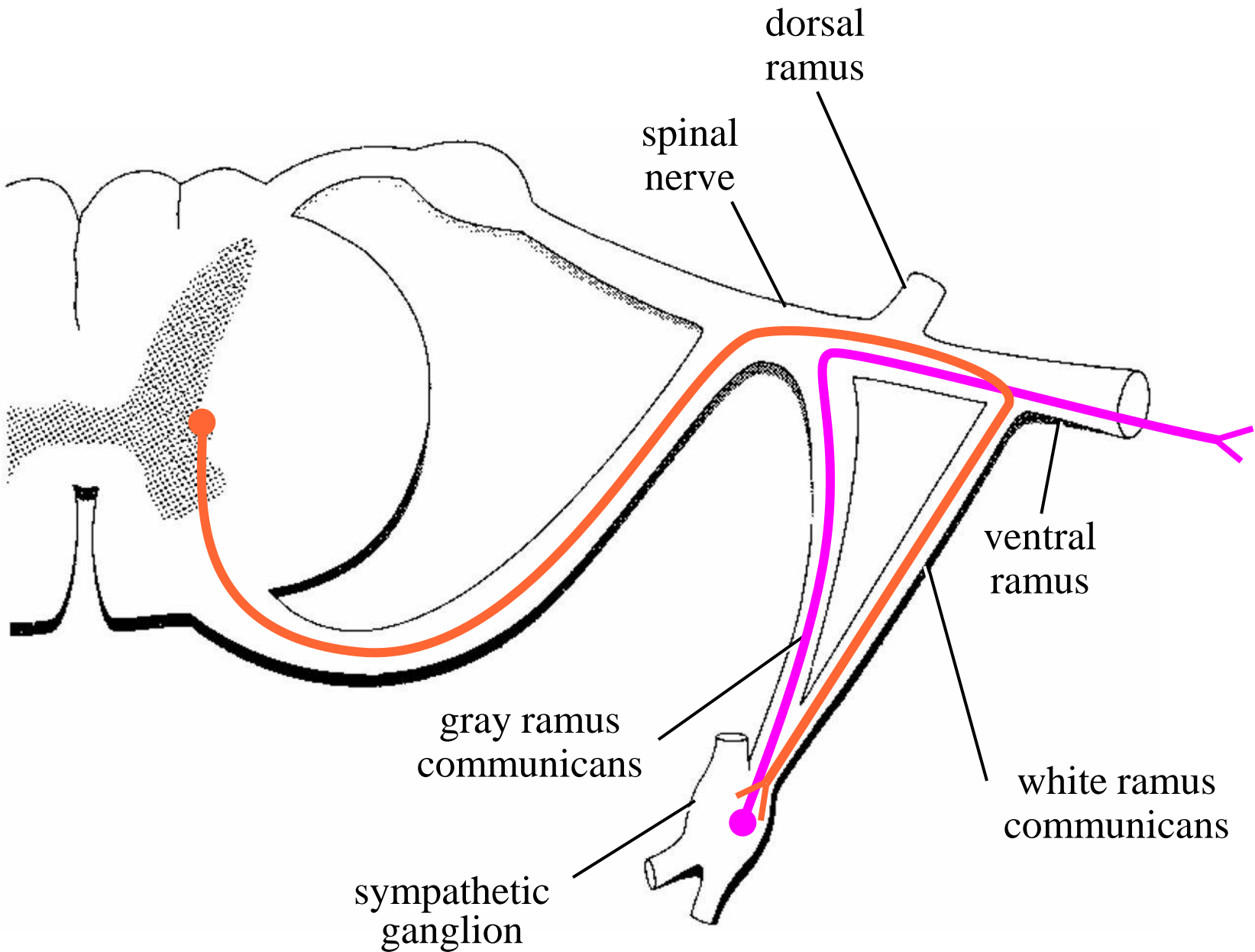
Craniosacral
Brain: CN III, VII, IX, X
Spinal cord: S2 – S4

Structure of Spinal Nerves: Somatic Pathways

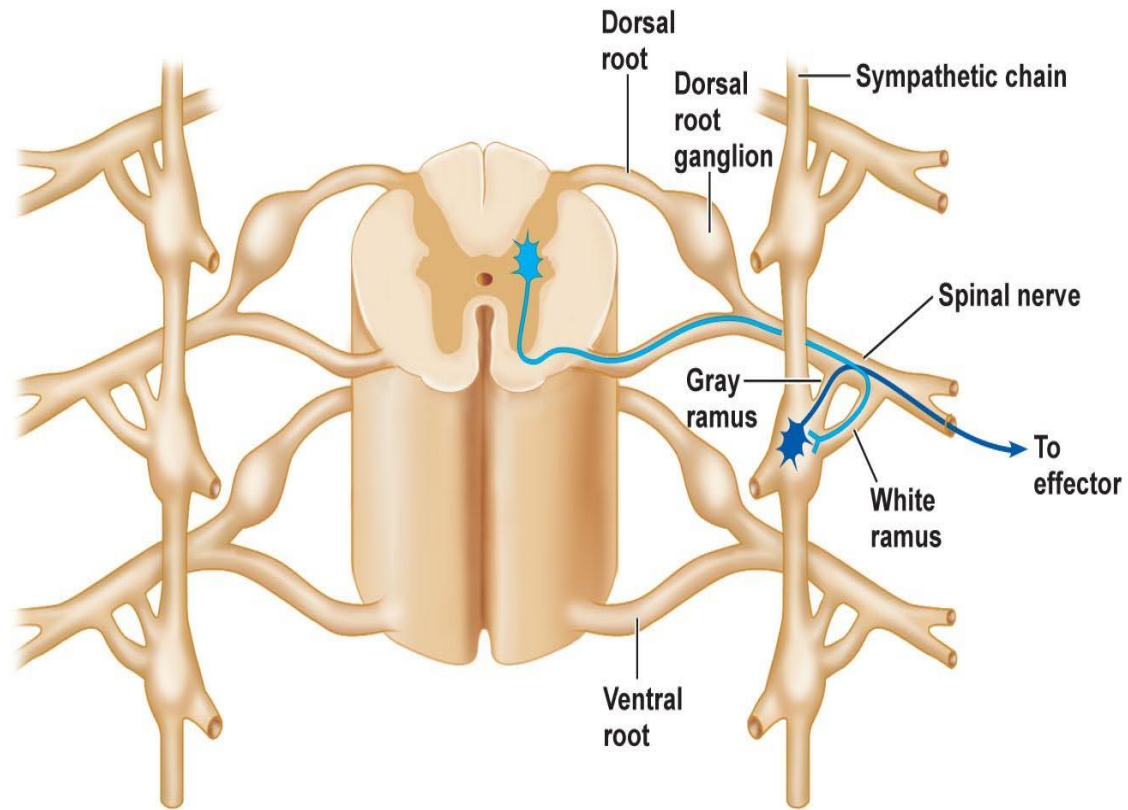
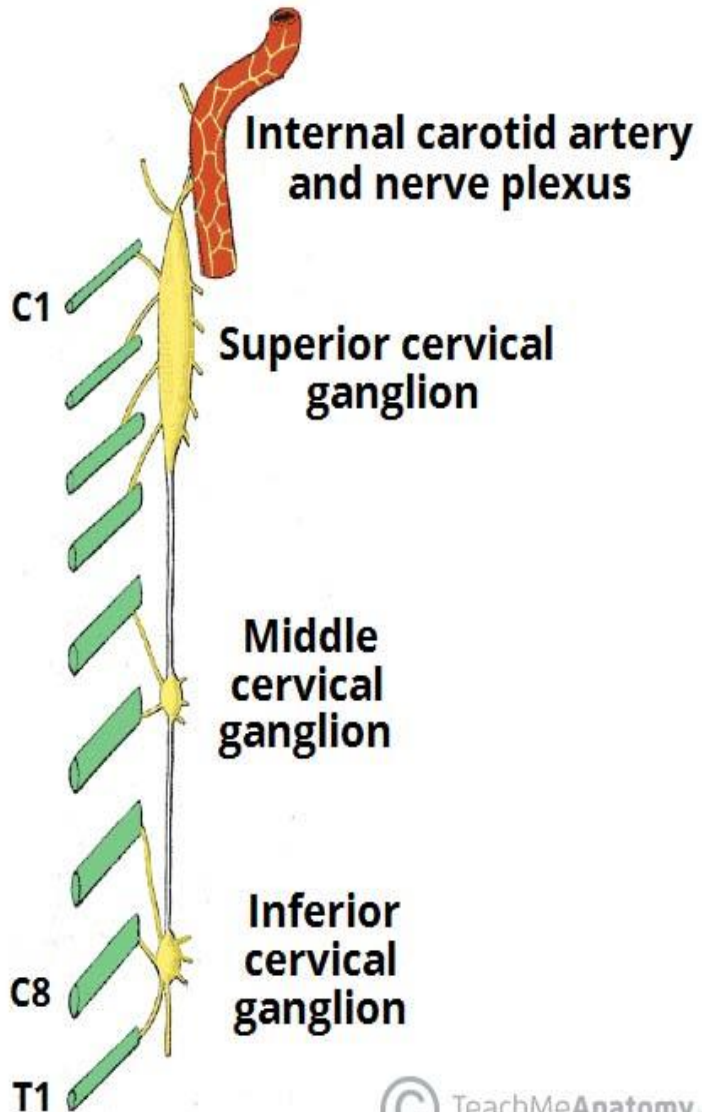


Mixed Spinal Nerve

Structure of spinal nerves: Sympathetic pathways



Sympathetic ganglia are the ganglia of the sympathetic nervous system
They are located close to and on either side of the spinal cord in long chains

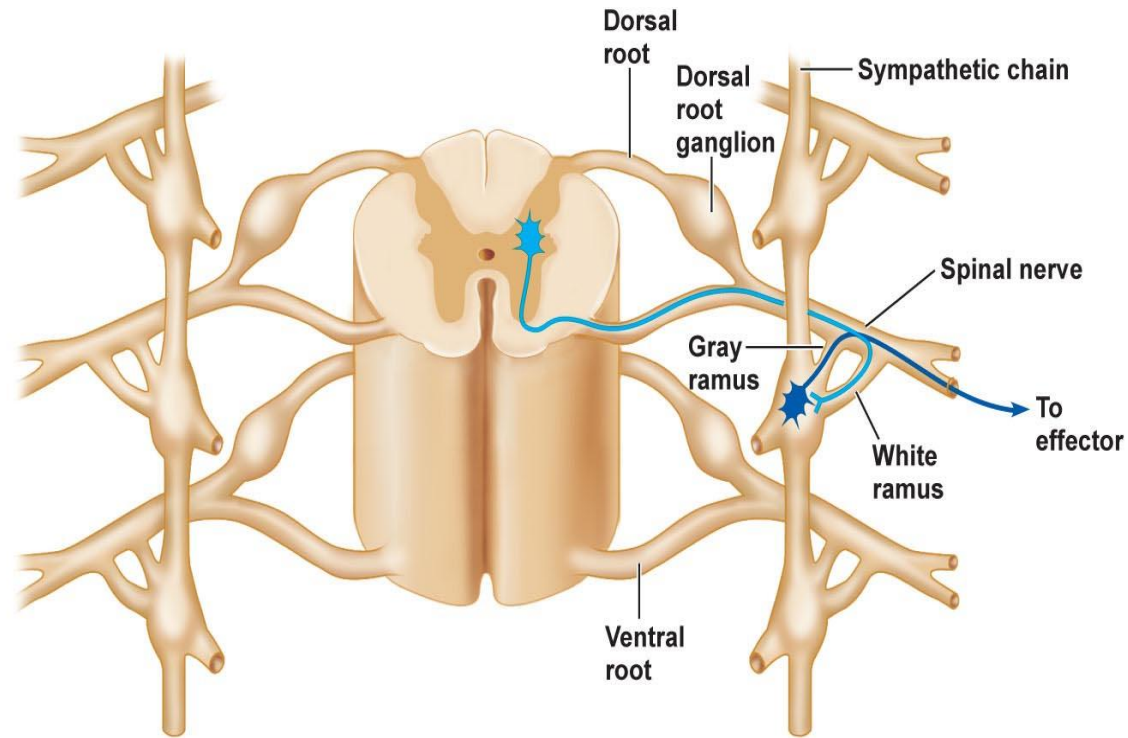


Sympathetic ganglia are the ganglia of the sympathetic nervous system
They are located close to and on either side of the spinal cord in long chains

There are usually 22-23 pairs of paravertebral sympathetic ganglia:

3 in the cervical region
(cervical ganglia)
11 in the thoracic region
4 in the lumbar region
4-5 in the sacral region

1 unpaired coccygeal ganglion



© 2011 Pearson Education, Inc.

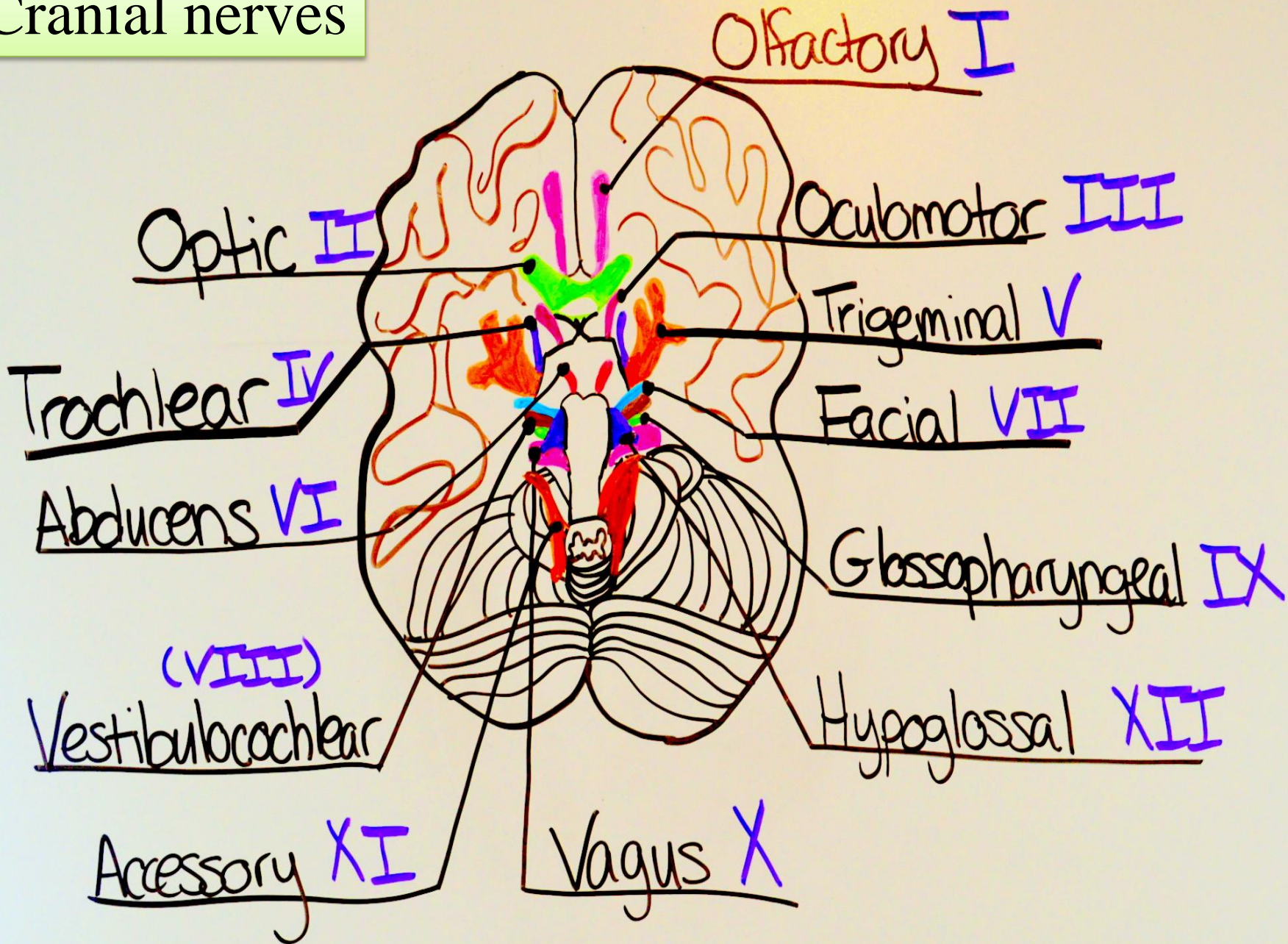
Preganglionic nerves from the spinal cord synapse at one of the chain ganglia,
and the postganglionic fiber extends to an effector

Parasympathetic ganglia lie near or within the organs they innervate

Parasympathetic ganglia in the head and neck:

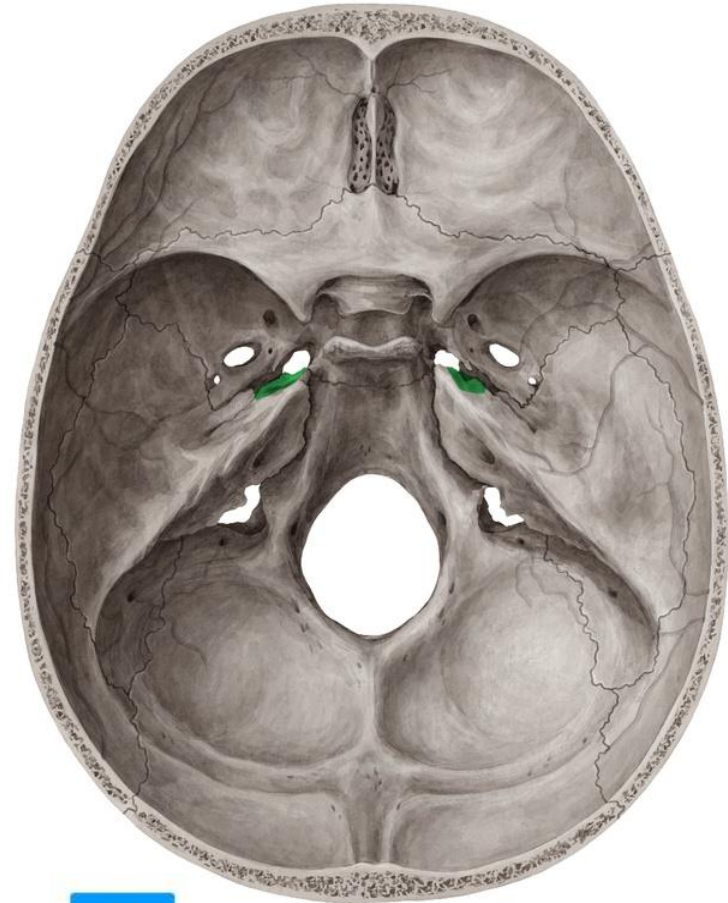
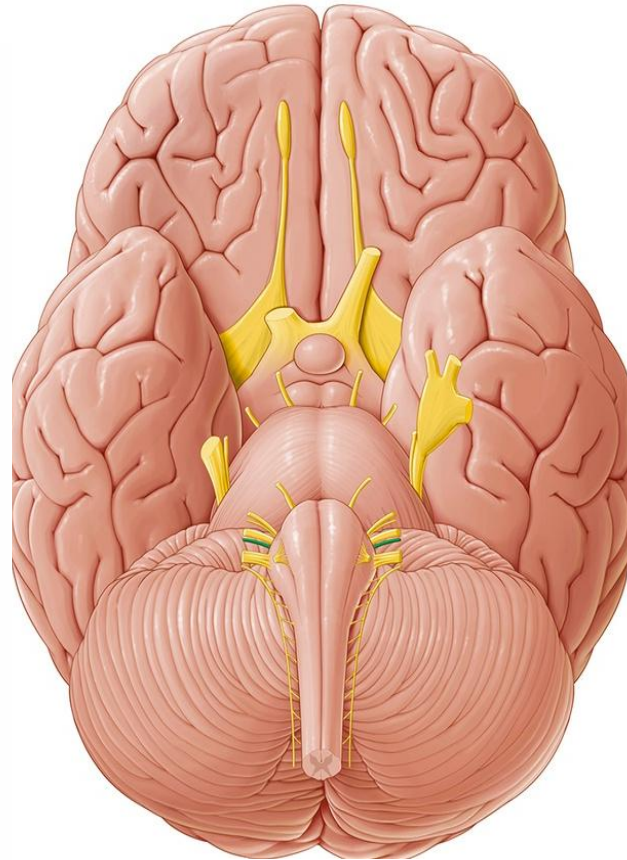
- 1- **Ciliary ganglion** (sphincter pupillae, ciliary muscle)
- 2- **Pterygopalatine ganglion** (lacrimal gland, glands of nasal cavity)
- 3- **Submandibular ganglion** (submandibular and sublingual glands)
- 4- **Otic ganglion** (parotid gland)

Cranial nerves



The numbering of the cranial nerves is based on the order in which they emerge from the brain, front to back

- I Olfactory
- II Optic
- III Oculomotor
- IV Trochlear
- V Trigeminal
- VI Abducens
- VII Facial
- VIII Vestibulocochlear
- IX Glossopharyngeal
- X Vagus
- XI Accessory
- XII Hypoglossal

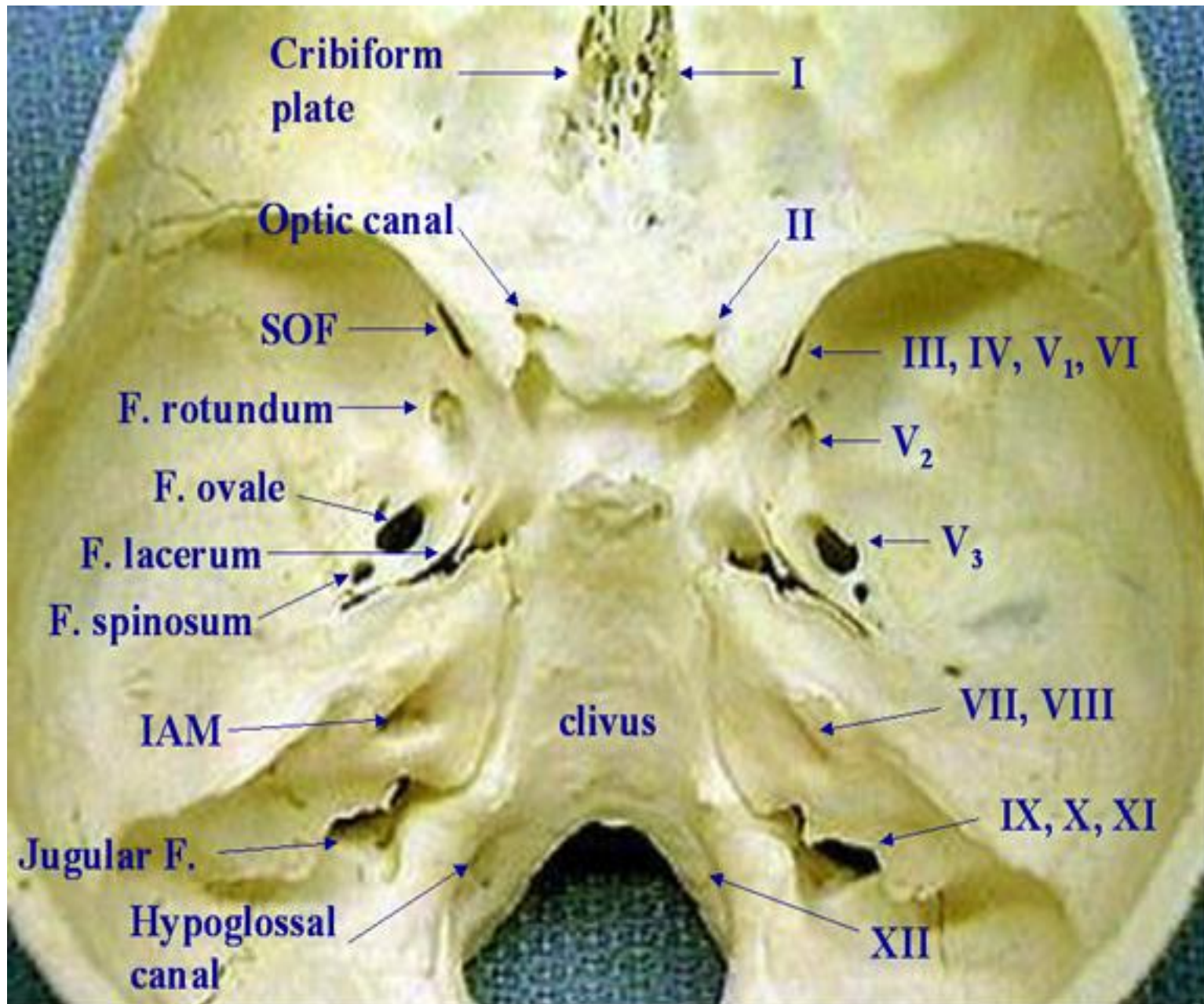


© www.kenhub.com



© www.kenhub.com

Foramina of skull and cranial nerves passing through



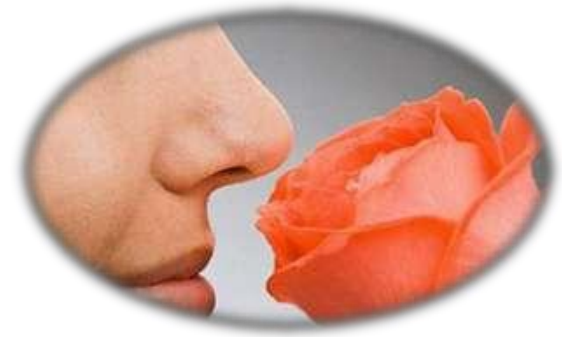1. Olfactory nerve

Component: sensory

Function: smell

Origin: Olfactory receptor nerve cells

Opening of the Skull: Openings in cribriform plate of ethmoid



2. Optic nerve

Component: sensory

Function: vision

Origin: Back of the eyeball

Opening of the Skull: Optic canal

Important



3. Oculomotor nerve

Component: motor

Function:

- Turns eyeball upward, downward and medially, upward and laterally
- Raises upper eyelid
- Constricts pupil
- Accommodates the eye

Opening of the Skull: Superior orbital fissure

Contains parasympathetic

Important



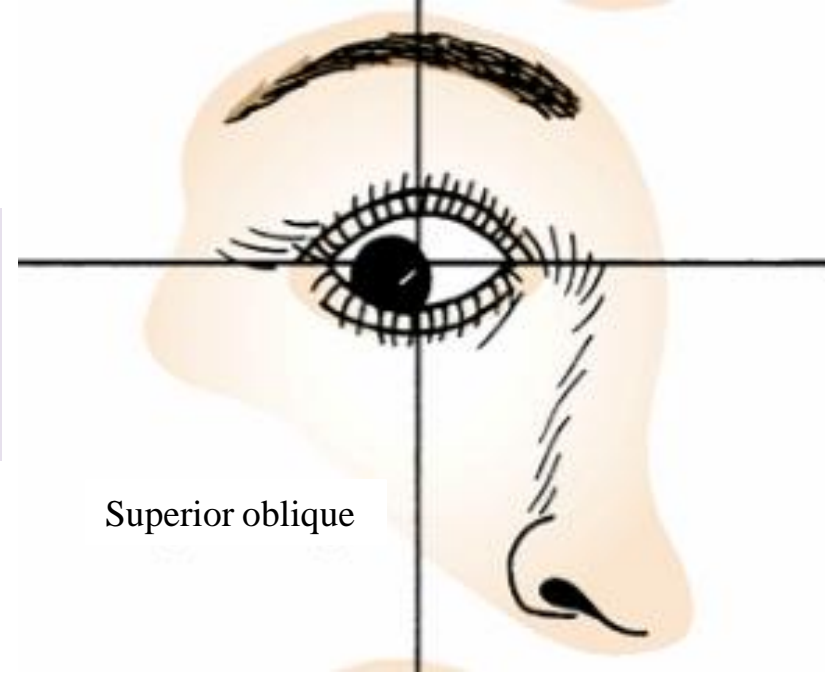
4. Trochlear nerve

Component: motor

Function: Turns eyeball downward and laterally

Opening of the Skull: Superior orbital fissure

Important



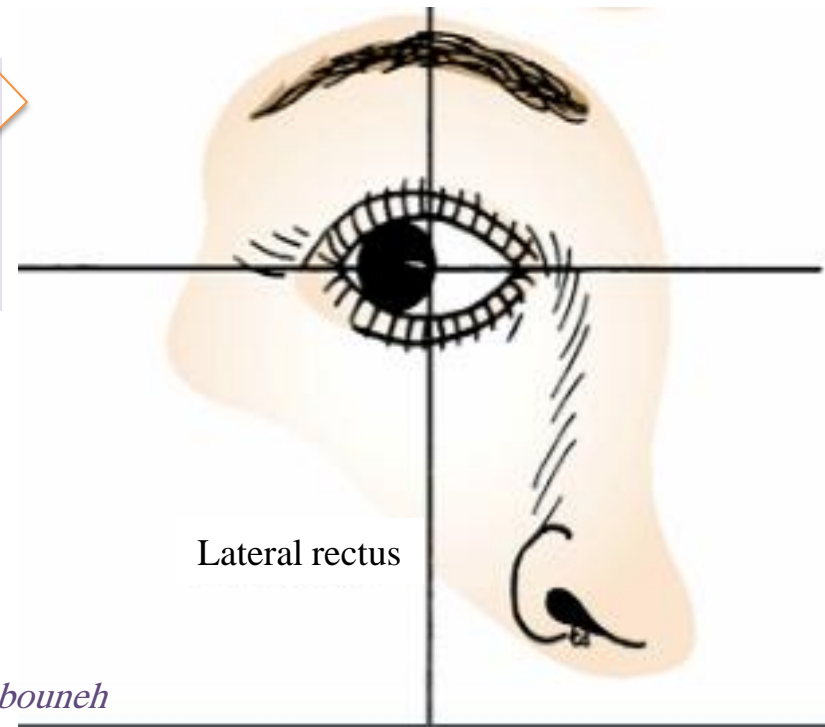
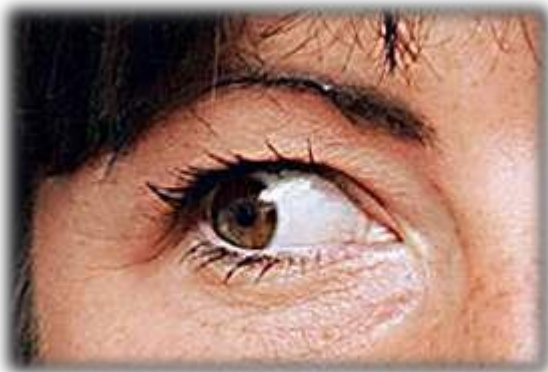6. Abducent nerve

Component: motor

Function: Turns eyeball laterally

Opening of the Skull: Superior orbital fissure

Important



Ophthalmic nerve



5. Trigeminal Nerve

Component: mixed (motor and sensory)

Function: **General sensation from the face, supplies muscles of mastication**

Large sensory root

Small motor root

Maxillary nerve



Mandibular nerve



V1. Ophthalmic Nerve

Component: sensory

Function: sensation from: cornea, skin of forehead, scalp, eyelids and nose, mucous membranes of paranasal sinuses and nasal cavity

Opening of the Skull: Superior orbital fissure

V2. Maxillary Nerve

Component: sensory

Function: sensation from: skin over maxilla, upper lip, teeth of the upper jaw, mucous membrane of the nose, the maxillary sinus and palate

Opening of the Skull: Foramen rotundum

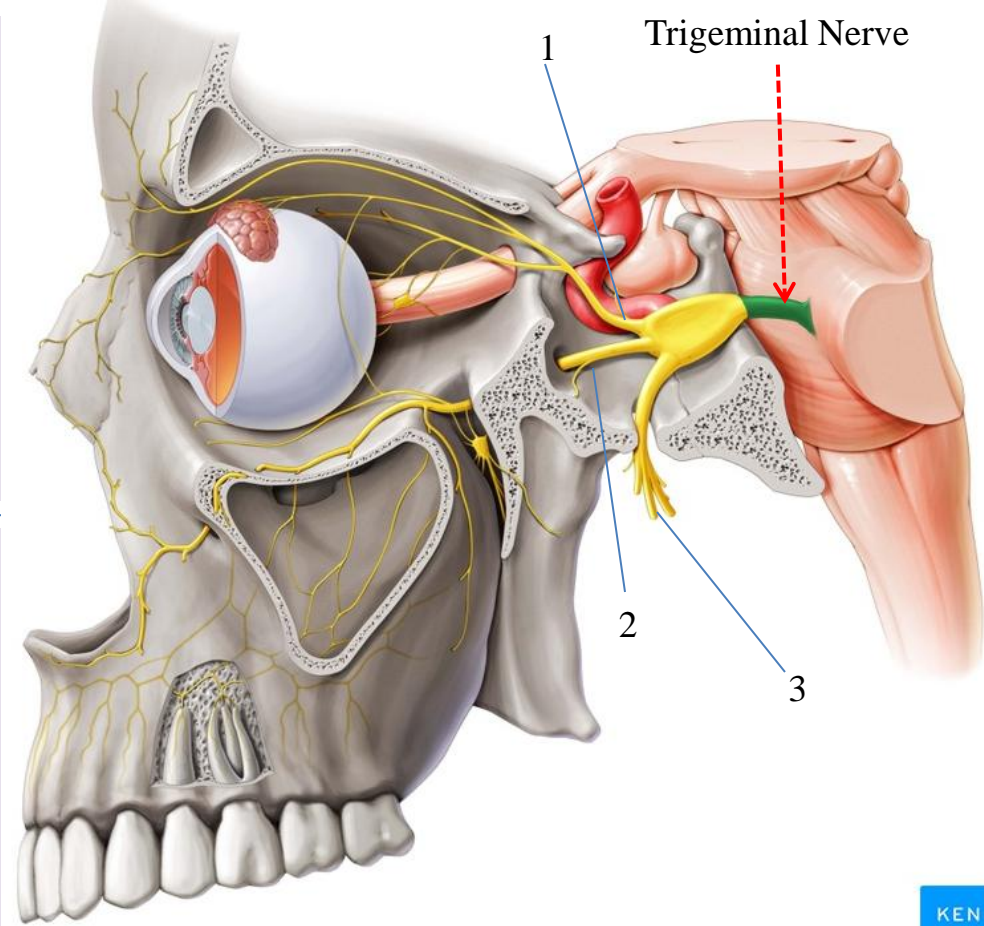
V3. Mandibular Nerve

Component: sensory and motor

Function: sensation from: skin of cheek, over mandible and side of head, teeth of lower jaw and TMJ, mucous membrane of mouth and anterior 2/3 of tongue

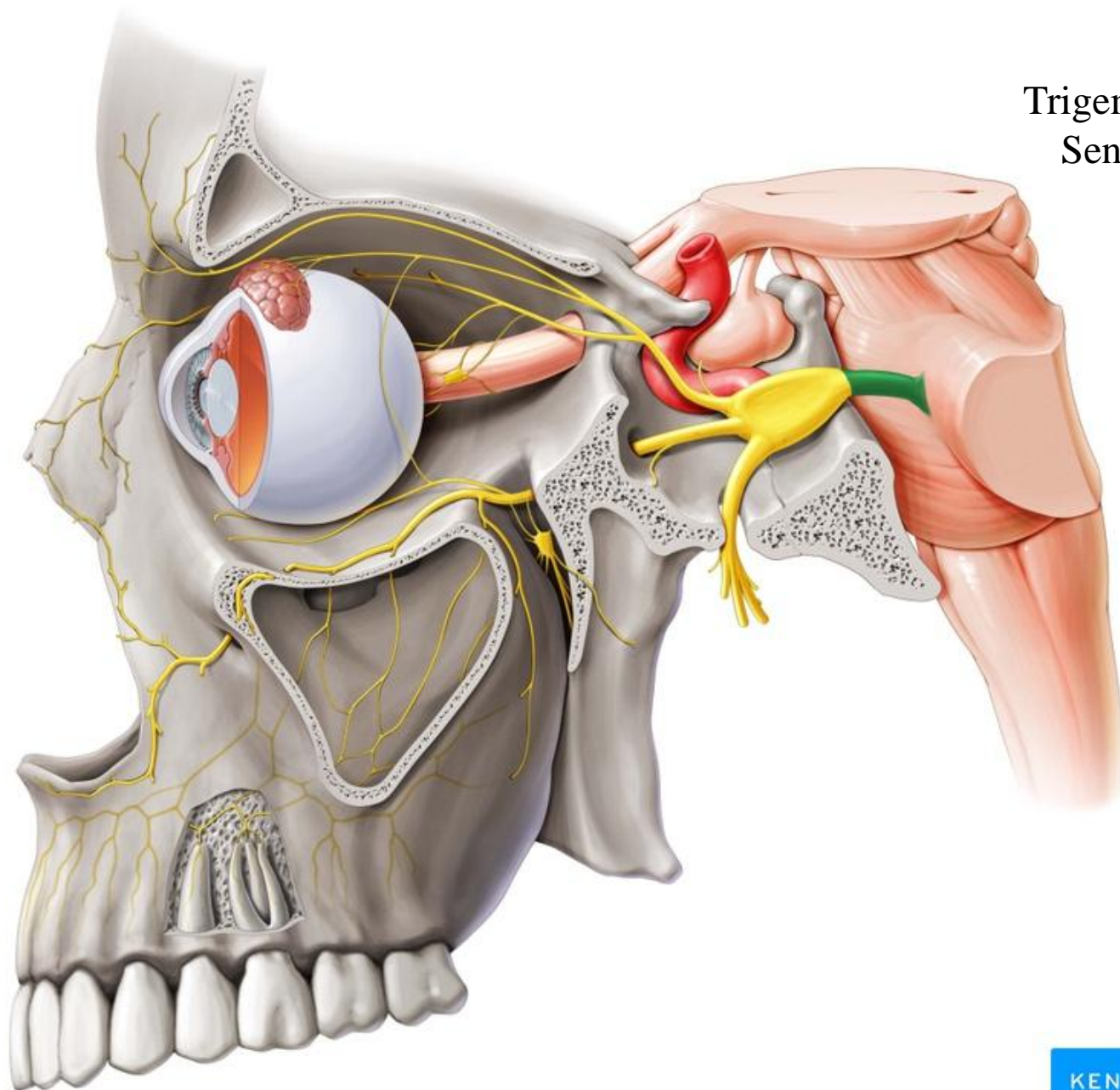
Motor to: Muscles of mastication, Mylohyoid, Anterior belly of digastric, Tensor veli palatine, Tensor tympani

Opening of the Skull: Foramen ovale



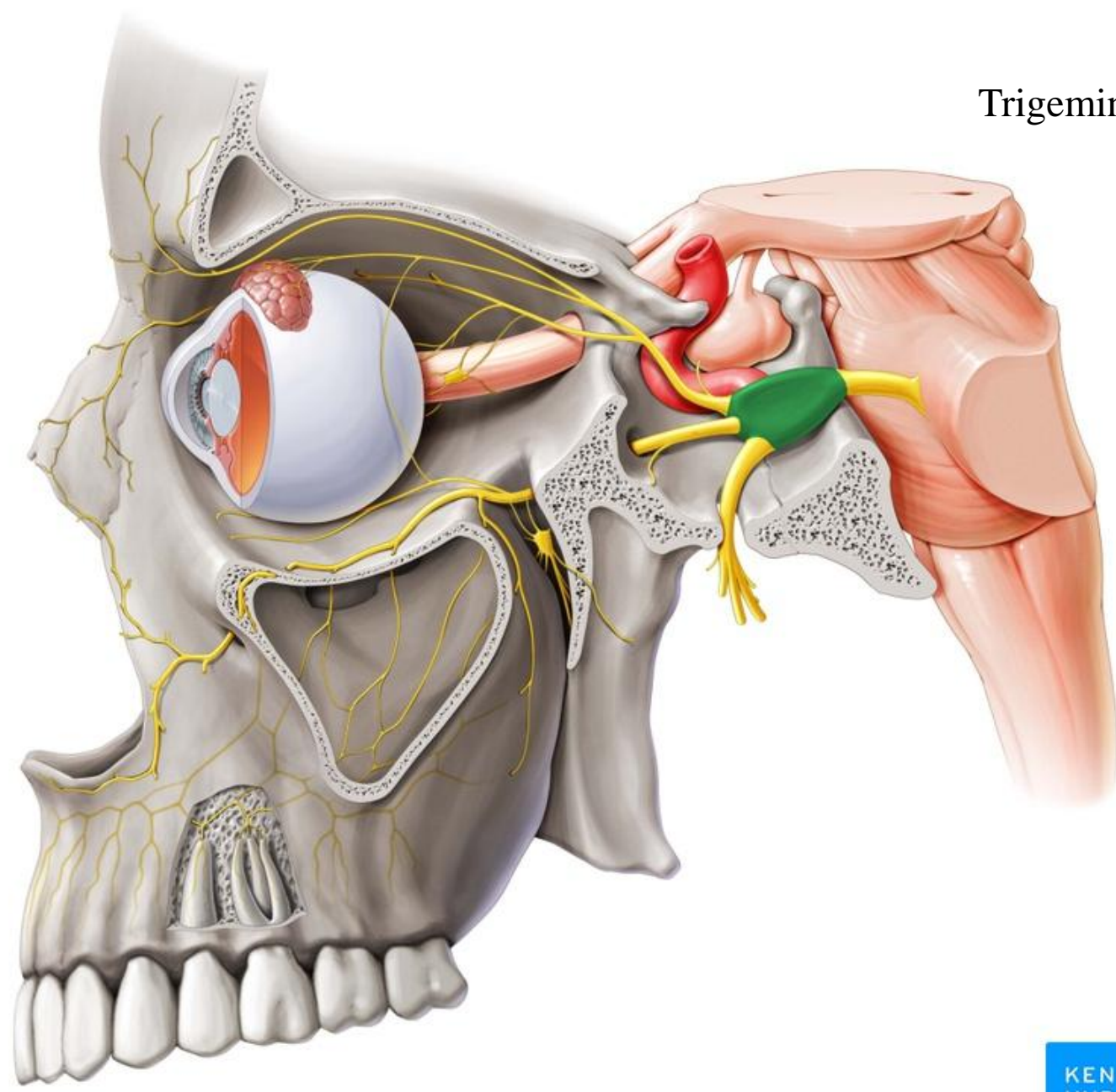
© www.kenhub.com

KEN
HUB

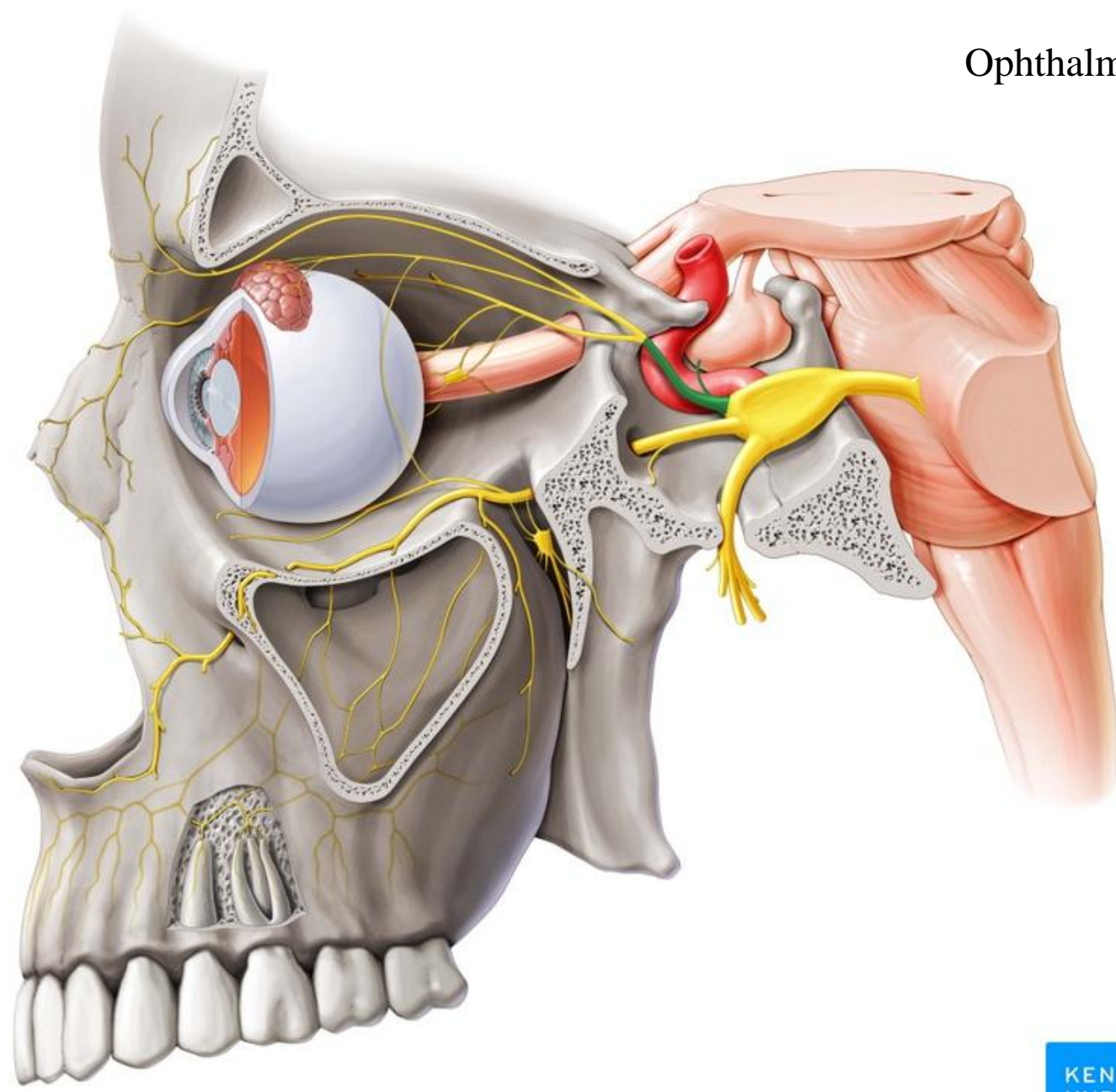


Trigeminal nerve
Sensory part

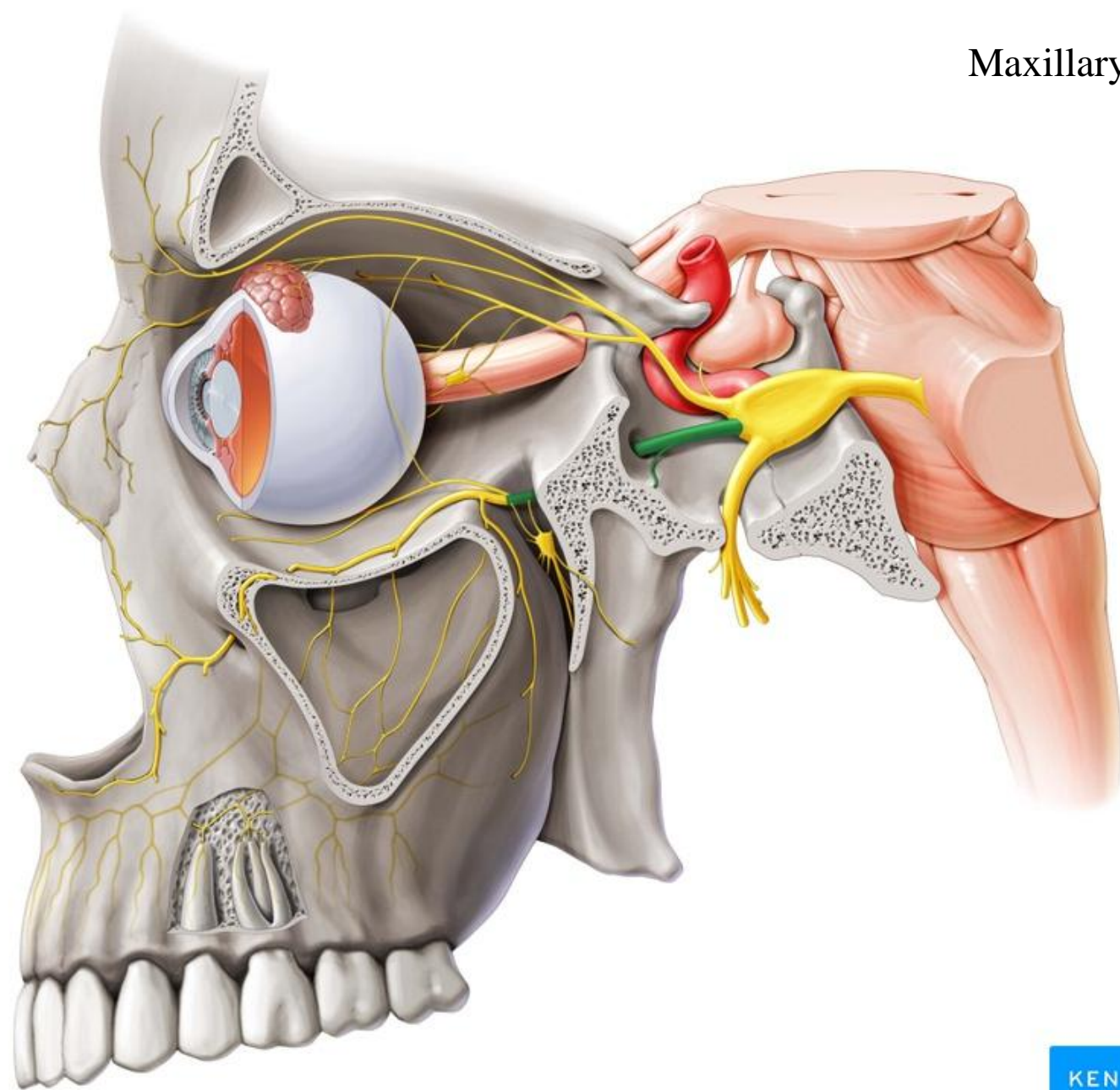
Trigeminal ganglion



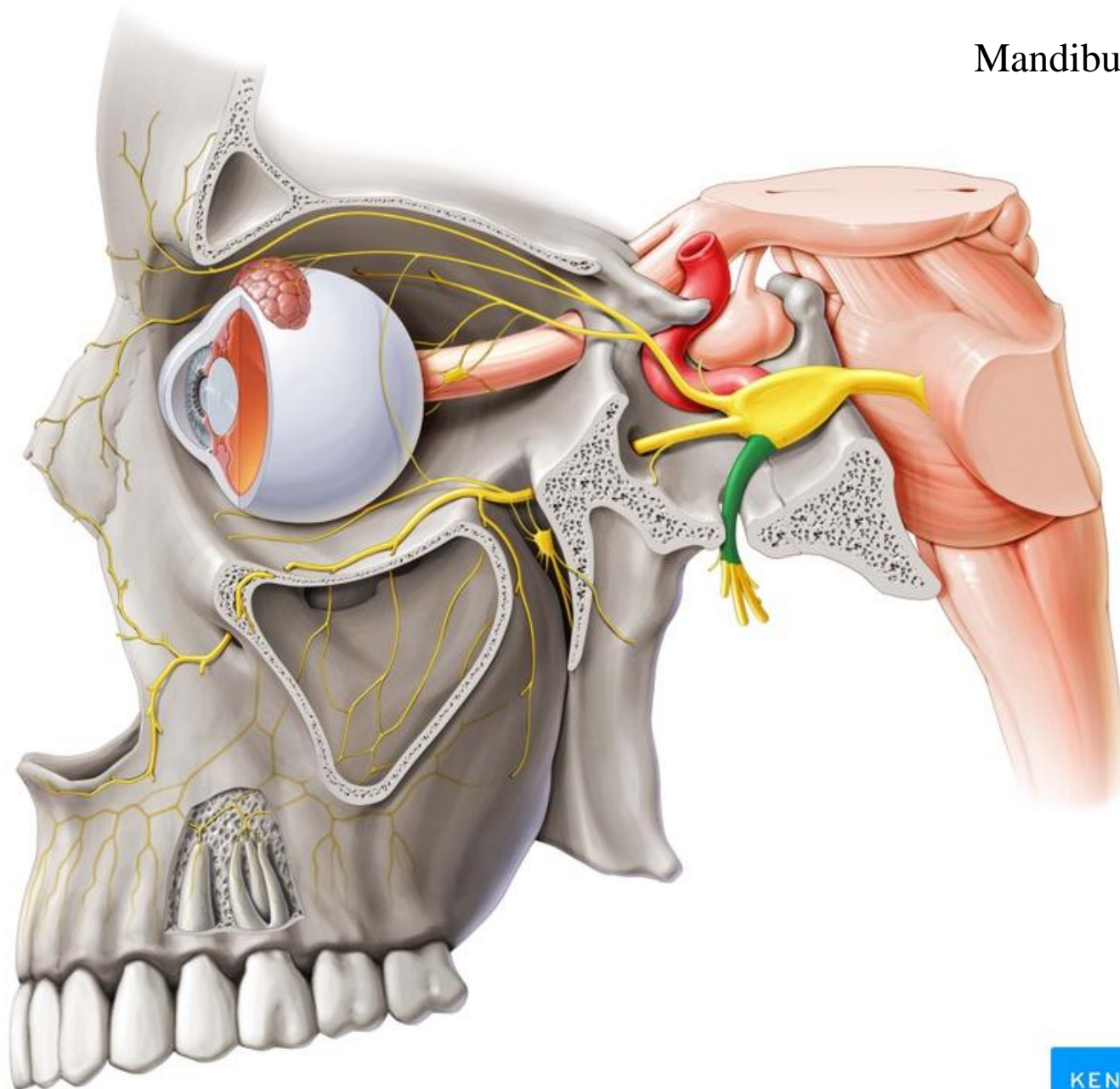
Ophthalmic division



Maxillary division



Mandibular division



7. Facial Nerve

Contains parasympathetic

Important

Component: mixed (sensory and motor)

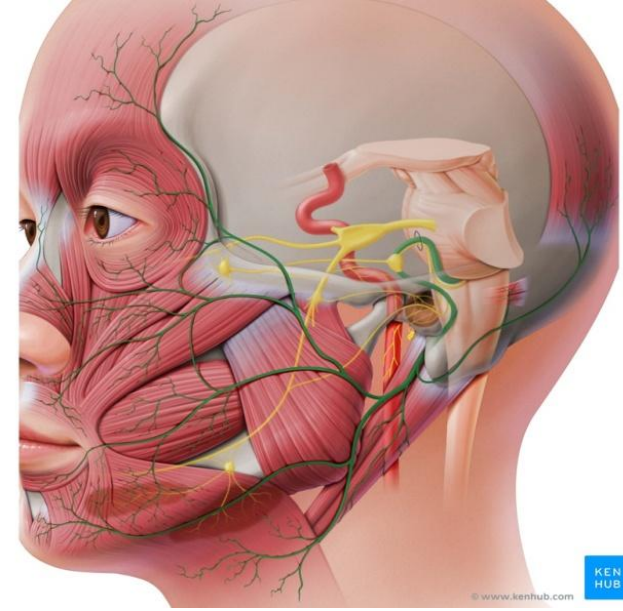
Function: taste sensation from the anterior 2/3 of the tongue

General sensation from a small area around the concha of the auricle, EAM

Motor to: muscles of the face and scalp, stapedius, posterior belly of digastric, stylohyoid

Parasympathetic to: Sublingual and submandibular glands, lacrimal gland

Opening of the Skull: Internal acoustic meatus, facial canal, stylomastoid foramen



8. Vestibulocochlear Nerve

Important

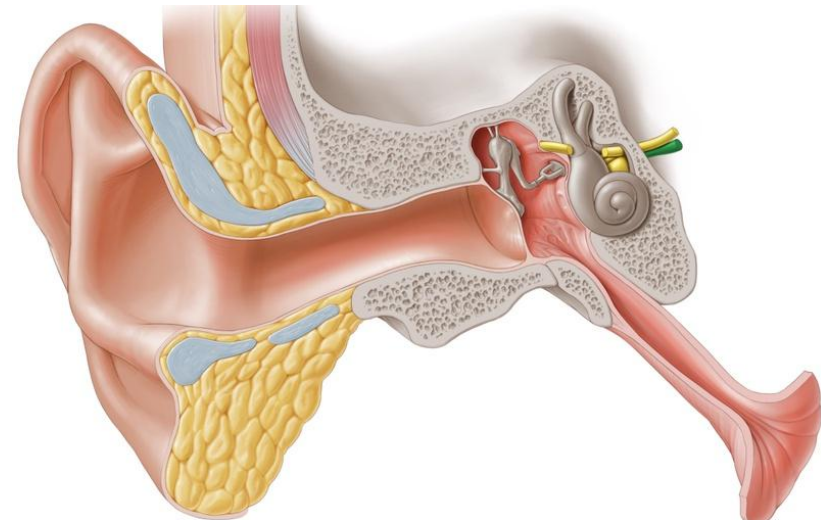
Component: sensory

Origin: Vestibular: utricle, saccule, semicircular canals

Cochlear: Organ of Corti

Function: balance and hearing

Opening of the Skull: Internal acoustic meatus



9. Glossopharyngeal Nerve Contains parasympathetic

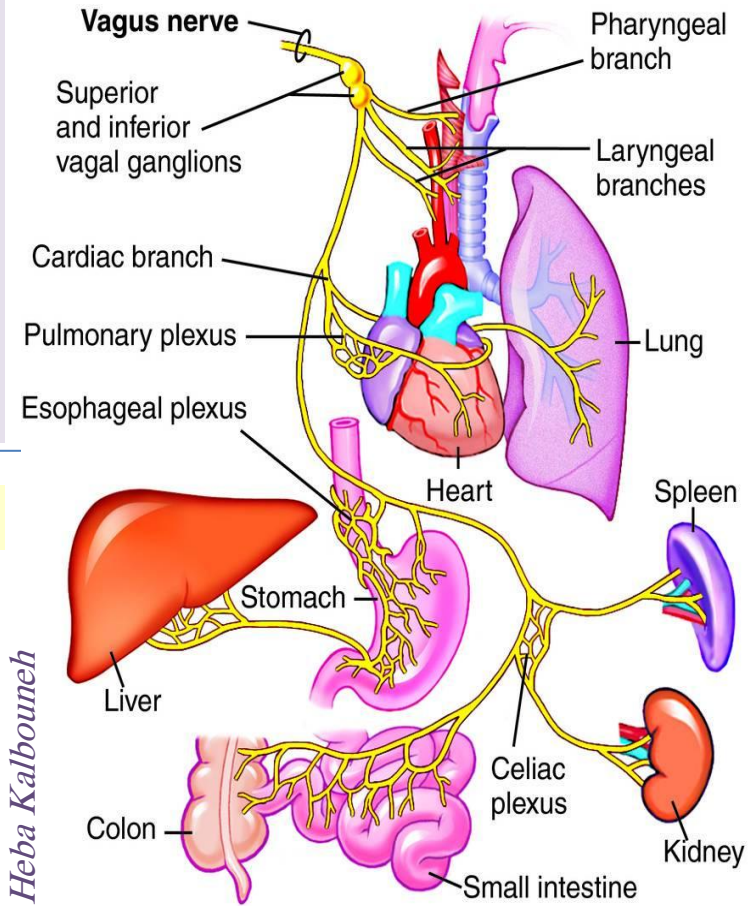
Component: mixed (sensory and motor)

Function: **General sensation and taste from post. 1/3 of the tongue and oropharynx, carotid sinus and carotid body**

Motor to: stylopharyngeus

Parasympathetic to: Parotid gland

Opening of the Skull: **Jugular foramen**



Dr. Heba Kalbouneh

10. Vagus Nerve

Contains parasympathetic

Component: mixed (sensory and motor)

Function: **Motor: Constrictor muscles of pharynx and intrinsic muscles of larynx; involuntary muscle of trachea and bronchi, heart, alimentary tract from pharynx to splenic flexure of colon; liver and pancreas**

Sensory: Taste sensation from epiglottis and vallecula and afferent fibers from structures named above, General sensation from skin of EAM

Opening of the Skull: **Jugular foramen**

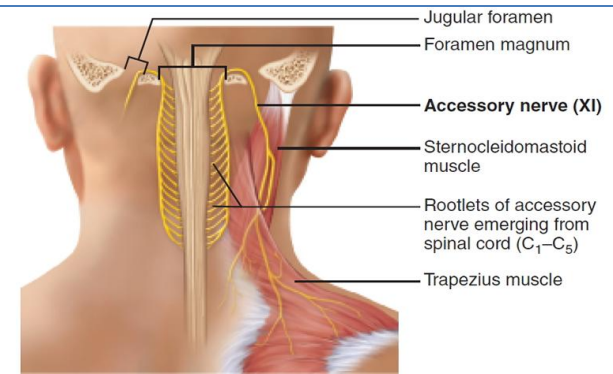
11. Accessory Nerve

Component: motor

Function: **Cranial root: Pharyngeal plexus (Muscles of soft palate, pharynx, and larynx)**

Spinal root: motor to Sternocleidomastoid and trapezius

Opening of the Skull: **Jugular foramen**



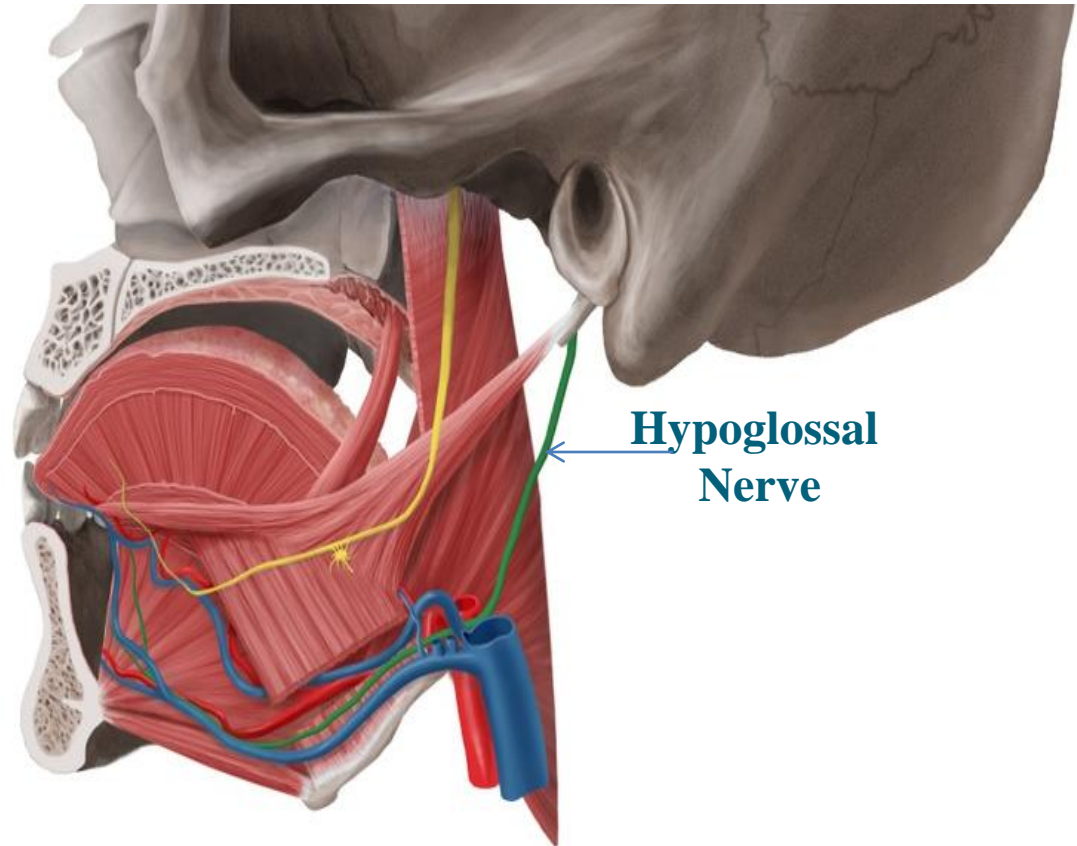
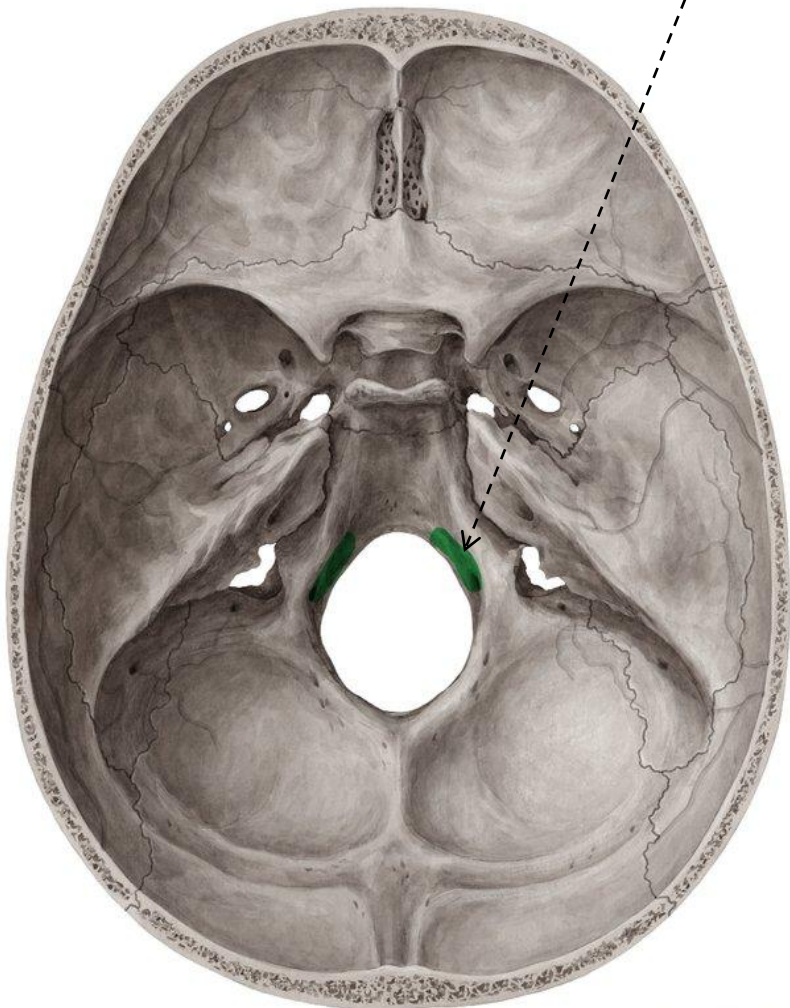
Important

12. Hypoglossal Nerve

Component: motor

Function: **Motor to muscles of the tongue**

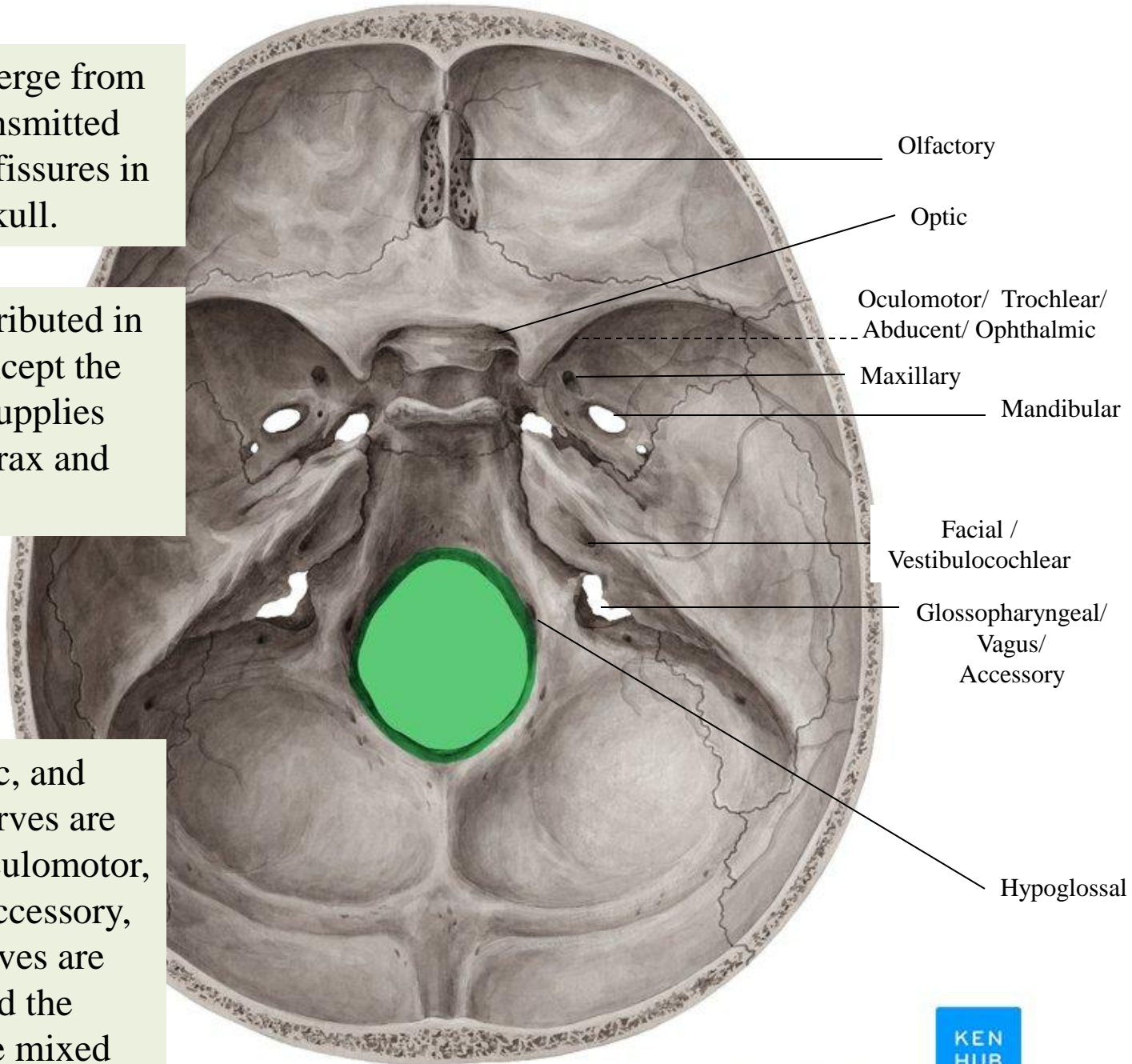
Opening of the Skull: **Hypoglossal canal**



The cranial nerves emerge from the brain and are transmitted through foramina and fissures in the base of the skull.

All the nerves are distributed in the head and neck except the vagus, which also supplies structures in the thorax and abdomen.

The olfactory, optic, and vestibulocochlear nerves are entirely sensory; the oculomotor, trochlear, abducent, accessory, and hypoglossal nerves are entirely motor; and the remaining nerves are mixed



Pure sensory:

Olfactory
Optic
Vestibulocochlear

Pure motor:

Oculomotor
Trochlear
Abducent
Accessory
hypoglossal

Mixed (motor and sensory):

Trigeminal
Facial
Glossopharyngeal
Vagus

Contains parasympathetic

(secretomotor):

Oculomotor
Facial
Glossopharyngeal
Vagus

