



Past papers Mid MSS 2020

Collected by: Lejan 2020

Written by: Laith Sami

Final MSS – 2020

1-Which of the following muscles is not formed by first arch?

Answer : Stylohyoid

2-How do probenecid decrease serum uric acid:

Answer : By inhibiting tubular reabsorption

3-Regarding ear anatomy which of the following is WRONG?

A-The organ of Corti is present in scala media

B-Reissners membrane separates scala media and scala vestibuli

C-Membrane Labyrinth contains endolymph

D-External acoustic meatus extends from concha to tympanic membrane

E-Upon an Examination of normal tympanic membrane using an otoscope, the cone of light is directed anterosuperior

Answer : E

4-All of the following regarding mucla lutea is correct, except?

A-Has diffuse margine

B-is avascular

C-Has the highest concentration of cone photoreceptor

D-Is located nasal and inferior to optic disc

Answer : D

5-Bedridden patient with ulcers on his lower back, some are deep to musclels and soft tissues ,regarding to that which of the following is true:

A-IF you make colonization one type of bacteria will be obtained

B-Topical drugs are useful to eliminate the bacteria

C-Bloodstream infection are considered

D-Biofilm existence is good indicator of improvement of patient state

E-Superficial swab is the best diagnose test

Answer : C

6-Scalp wound in posterior triangle of neck can cause :

A-Drop of shoulder

B-loss of taste sensation

C-tilting head to the same side

D-ptosis

Answer : A

7-which of the following causes decrease in leukotrienes :

A-Glucocorticoid

B-Zileuton

C-Montelukast

D-B and C

E-All of the above

Answer : E

8-Man come to the clinic has left knee pain, the arthroscopic picture showed finger like projection into the joint with brown pigment. Best disorder describes his condition ?

A-Pigmented villonodular synovitis (PVNS)

B-Rheumatoid arthritis

C-Degenerative joint disease

D-Lyme disease

Answer : A

9-Bone of the middle ear formed by :

A-1st pharyngeal arch

B-1st and 2nd pharyngeal arches

C-1st,2nd,3rd,4th,pharyngeal arches

D-2nd,3rd pharyngeal arches

Answer : B

10-All of the following is correct about candida infection of the skin except :

Answer : Amphotericin B is the drug of choice

11-All of the following are concerned as drugs of acute gout arthritis, except ?

A-Allopurinol

B-Probenecid

C-Colchicine

D-Diclofenac

Answer : A

12-The antagonist muscle of splenius capitis muscle is :

A-sternocleidomastoid

B-interspinales

C-longissimus

D-inertransversarii

E-multifidus

Answer : A

13-Regarding the two muscle of the middle ear , choose the wrong statement :

A-Both muscles are derived from the first and second pharyngeal arches

B-tensor tympani muscle is related to the anterior wall

C-stapedius muscle is related to the posterior wall

D-tensor tympani muscle Dampens down vibration of the secondary tympanic membrane .

E-Stapedius muscle dampens down vibration of stapes

Answer : D

14-A 16 years old female come to the ER after 12 hours from administration of 34 tablet of paracetamol, heart rate is 120 and her pressure is 110/80 what is the initial management that has to be taken for this patient :

A-N acetylcysteine

B-measuring the level of paracetamol in her blood

C-Activated charcoal

D-Send for liver transplantation

E-----

Answer : A

15-Which of the following diseases is an effective vaccine used against?

A-Oral herpes

B-Gentile herpes

C-Roseola infantum

D-Epstein Barr

E-Measles

Answer : E

16-Febrile Seizures?

Answer : Rosela infantum

17-Child with vesicles, macules, papules rash, negative kolpik spots?

Answer : Chicken POX

18-Aspirin interact with warfarin on :

A-the site of action

B-blood

C-liver

D-intestine

Answer : B

19-All of the following are contents of infratemporal fossae, except ?

Answer : masseter muscle

20-Which of the following is content of infratemporal fossae ?

A-greater wing of sphenoid

B-lesser wing of spheoid

C-palatine

D-occipital bone

Answer : A

21- which of the following is the best describe for giant cell tumor ?

Answer : it looks like osteoclast (الخيار ما كان هيك ولكن هيك المعنى)

22-A 60-year-old man came to the emergency and complained of pain in his joints. He denied that he had been exposed to such situations before, and when he was examined, it was found that the presence of positive birefringence, Imagine yourself in the place of the emergency doctor. What is the best diagnosis you can give?

A-acute gout arthritis

B-acute pseudogout

C-rheumatoid arthritis

D-osteoarthritis

Answer : B

23- A 54-year-old man came to the emergency and complained of pain and warm in his joints, when he was examined, it was found that there were traces of corrosion in the cartilage in the bone of the femur Which of the following is the best describe ?

Answer : subchondral cyst

24-All of the following are true about Extradaural hematoma , EXCEPT?

Answer : Venous supply

25- A 82-year-old female she complains of osteoporosis and pain in her entire joints, which of the following are possible complications that could affect her?

Answer : compact fracture

26-Which of the following is true regarding rheumatoid arthritis?

Answer : true non suppurative autoimmune synovitis

27-one of the following in wrong about the cornea ?

Answer : Descemets membrane is the membrane under the stratified epithelium layer

28-which of the following vertebrae that weight line does not pass through ?

Answer : T11

29-Patient has Hypopigmented macules on his chest and back with little itchiness what will be seen on KOH mount of the skin ?

A-Pencil shaped yeast

B-yeast.....

C-Pseudohyphae

D-hyphae

E- Round cells with short curved hyphae

Answer : Round cells with short curved hyphae

30- Which of the following is not true regarding brain injuries ?

Answer : Brain injuries are not known to cause intracranial hematomas

31-55 years old woman with femoral fracture and lytic lesion of her lower limb, the blood cell count is normal, and has no previous history of smoking, regarding that , WHAT IS THE BEST APPROACH ?

A-History of hematuria

B-Ask about a family breast cancer and do physical examination

C-History of abnormal uterine bleeding

D-See her neck for previous surgical fracture

E-Check alkaline phosphatase

Answer : B

32-Which of the following is not true :

Answer : The second right anterior intercostal space is supplied by one artery

33-Regarding the neck region , which is wrong ?

Answer : The occipital and carotid triangles are bounded posteriorly by trapezius muscle

هناك إجابة ثانية مختلف عليها .

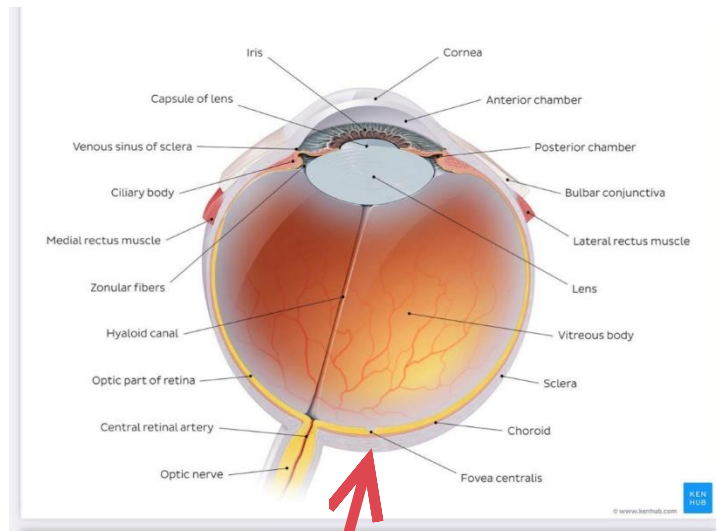
Which of the following conditions results from failure of fusion between maxillary process and intermaxillary segment on both side?

Answer: Bilateral cleft lip

35-All the following are correct about medial Pterygoid Except:

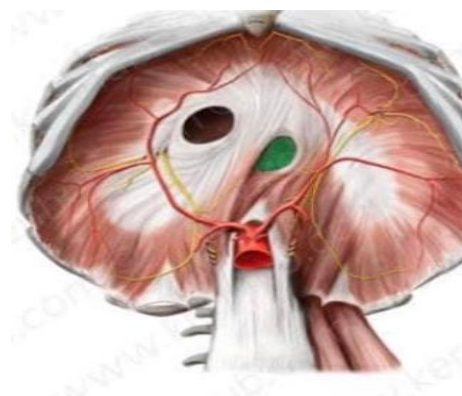
Answer: Fibers are oriented almost horizontally

Practical



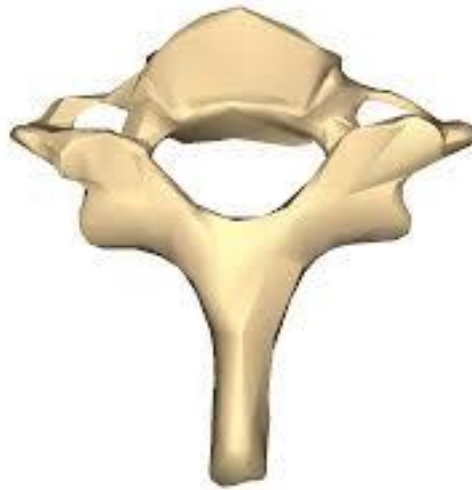Which of the following is not true ?

Answer : The sclera is made of dense connective tissues and is transparent



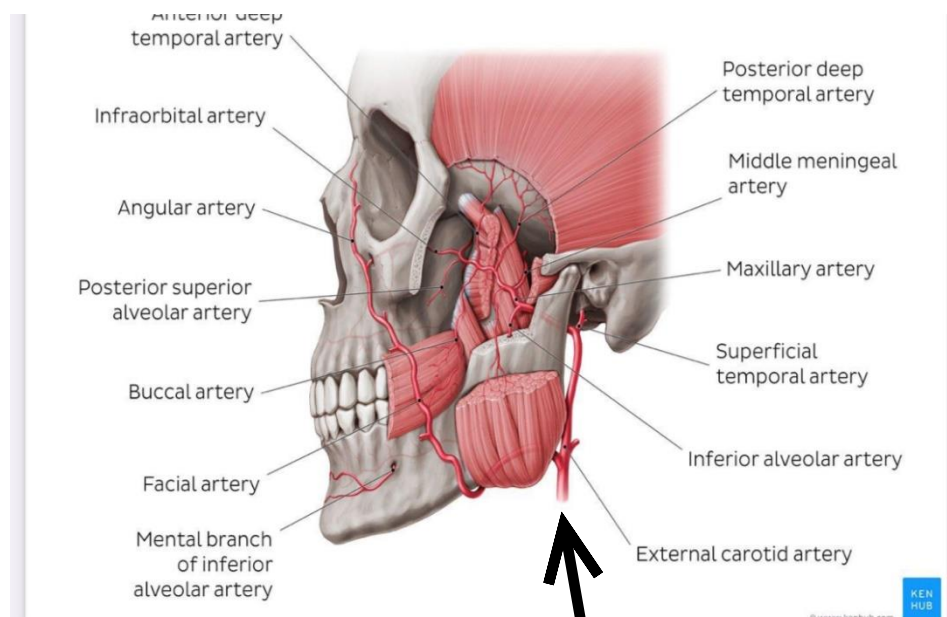
What is the name for that ?

Answer : 10th, left



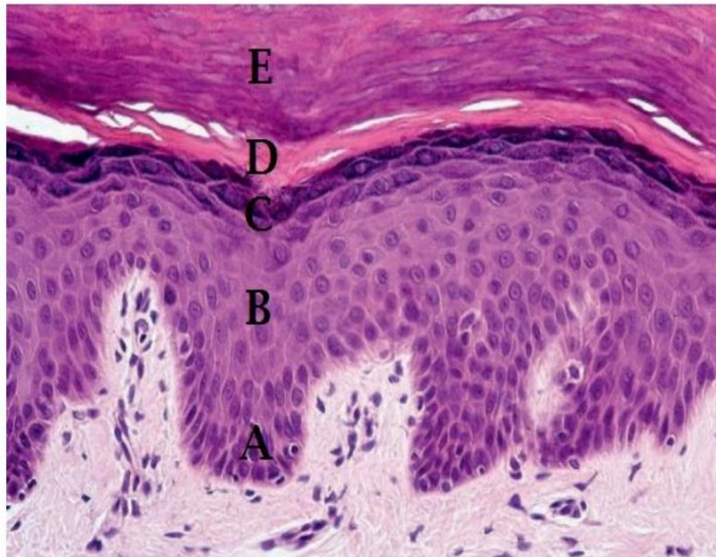What is the name for this vertebrae :

Answer : 7th cervical vertebrae



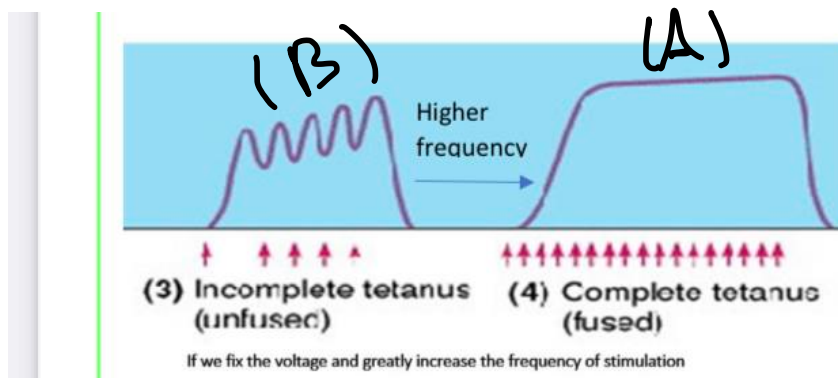
Which of the following is a miss match ?

Answer : Posterior auricular artery



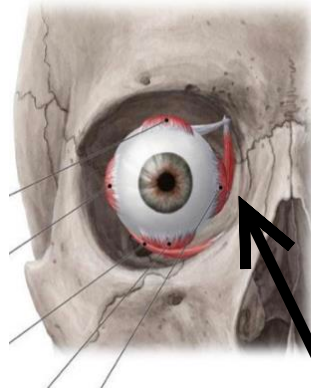
What the name of B,D respectively ?

Answer : stratum spinosum, stratum lucidum



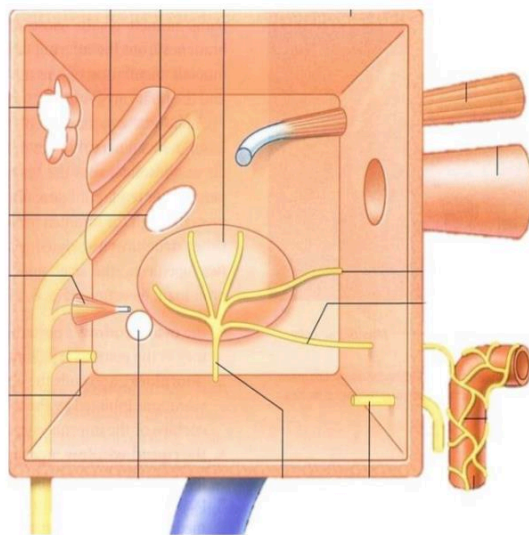
Which of the following is not true ?

Answer : The concentration of calcium ions in sarcoplasm of (B) is lower than that of (A).



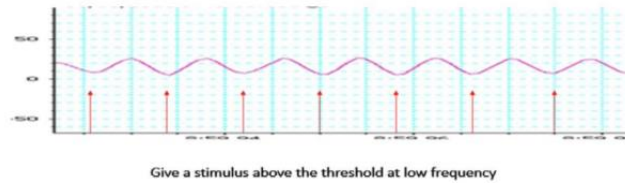
What is the function of this muscle ?

Answer : Adduction



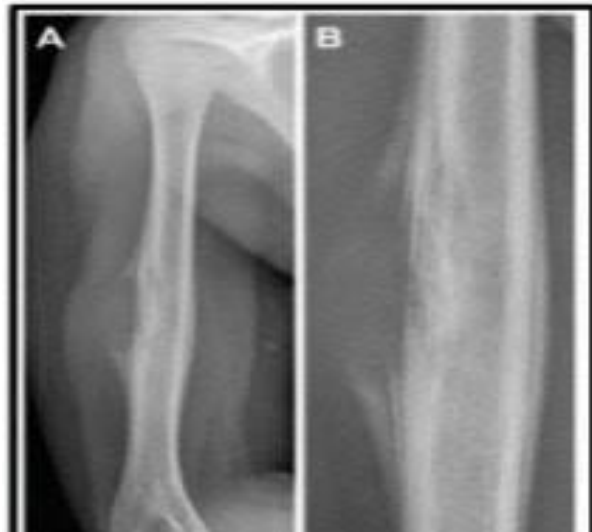Which of the following is miss match ?

Answer : Tensir tympani



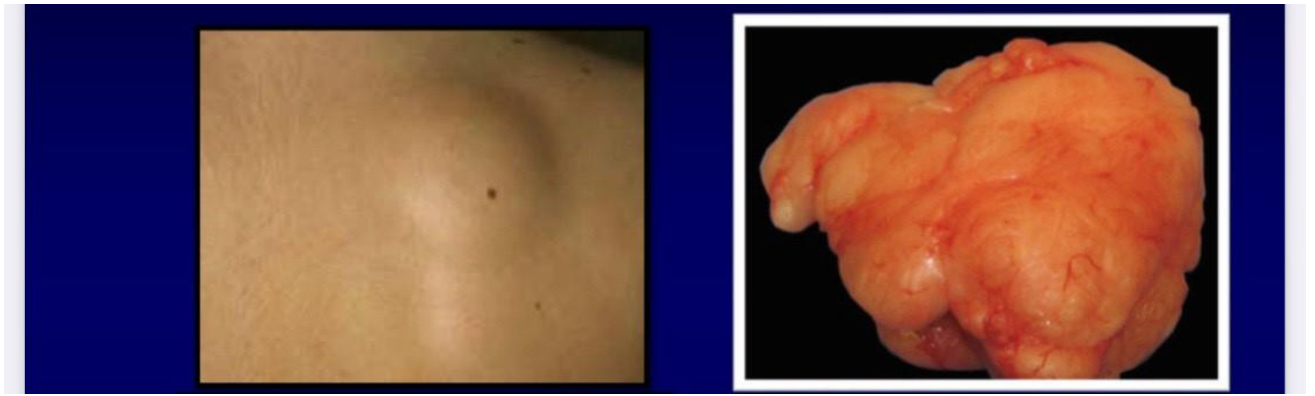
Which of the following is not true ?

Answer : Supramaximal threshold is lower than 2 mv

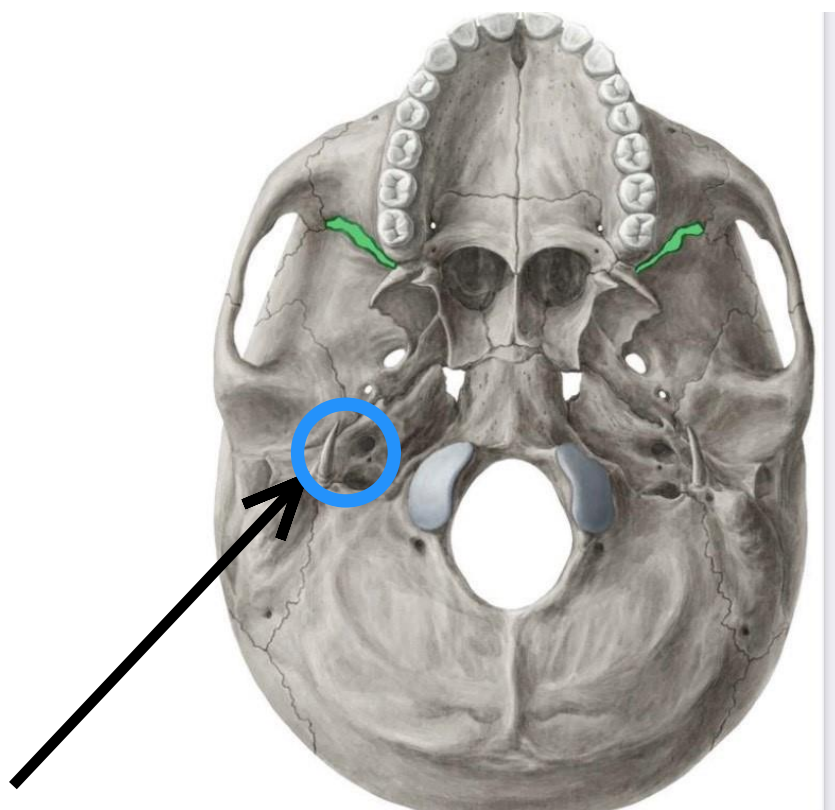


A patient came to the emergency with pain and small fracture in his body, biopsy is taken and under the microscope, we see alt of small blue cell tumors destroying the bone, if you are the Doctor, What do you expect this patient to have?

Answer : this is translocation (11,22), (q24;q12)



Answer : The forming cells are typical adipocytes



The cranial nerve that cross these foramen is ?

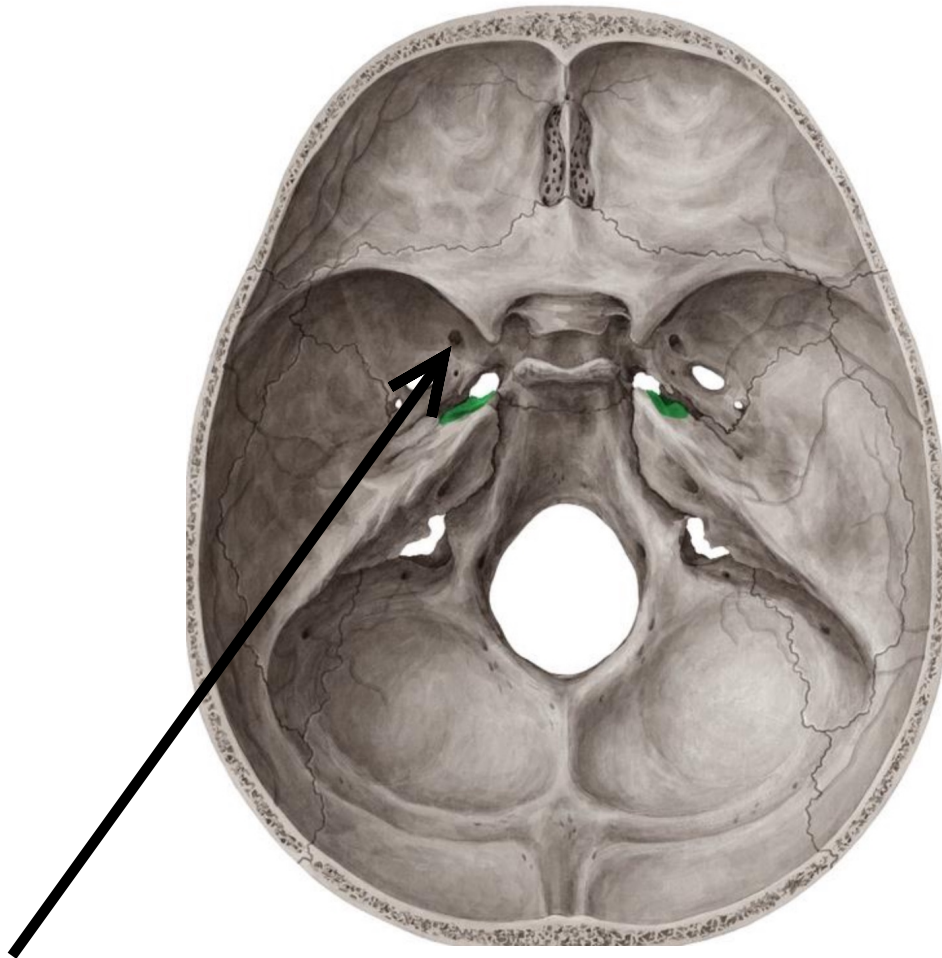
A-2nd

B-8th , 9th

C-7th

D-9th , 10th , 11th

Answer : 7th



Whats the name of these foramen?

A-ovale

B-rotundum

C-lacerum

D-Spinosum

Answer :B