DOCTOR 2020 | JU

PATHOLOGY

WRITER : Doctor 019

CORRECTOR : Jasmeen othman

DOCTOR: Mousa Al abbadi

Angiogenesis

- angiogenesis is an important process in repair and plays a central role in the process of healing (and this is why if you have somebody with for example severe peripheral vascular disease and there is injury to the foot or the ankle, the healing process takes longer time because of the lack of proper and complete angiogenesis where new blood vessels are formed).

- Angiogenesis require multiple steps: signaling pathways, growth factors , cell matrix interactions ,and enzymes of remodeling to be able to have a complete angiogenesis .

1- **GF (growth factors):** the major growth factors which are involved in the angiogenesis process are: (they are not the only ones but the major players)
   a- VEGF (vascular endothelial growth factor): there are multiple ones but the most important one is VEGF-A
   b- FGFs (Fibroblast growth factors family): specifically FGF-2 (fibroblast growth factor 2).
   c- TGF- ß (transforming growth factor beta) the most potent fibrogenic or scar-forming mediators

2- **Notch signaling (sprouting)**

the initial step which happens in angiogenesis (the best example to make you understand this is if you've seen somebody who has pipes to irrigate his yard and there is a major tube and a wire and then sprouts coming out of it) check the next page

3- **ECM proteins**

4- **Enzymes for final remodeling**

remember there is an important critical interaction between growth factors and the extracellular matrix proteins in addition to that in the final stages of remodeling enzymes are required to cut the extra collagen, the extra protein here and there and clean up the mess after the reparative process .

The process of angiogenesis

this is a quiescent or normal blood vessel

-the endothelial cells covering the blood vessels from inside sitting and lying on a

-basement membrane

composed of mainly collagen type 4 and laminin (the 2 major proteins of any basement membrane anywhere in your body)

-pericytes

(active cells located outside)

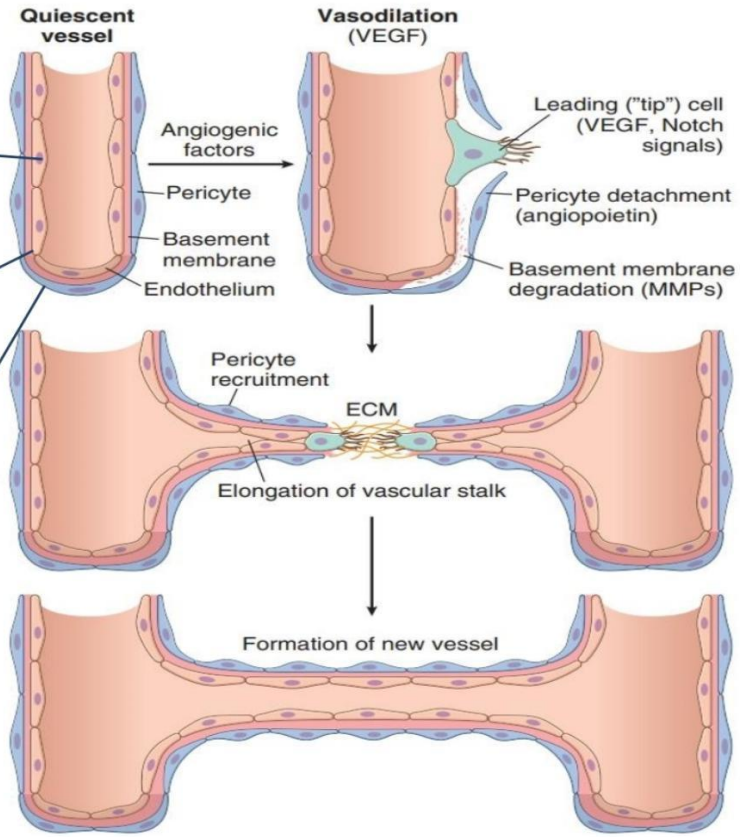

Fig. 3.25 Angiogenesis. In tissue repair, angiogenesis occurs mainly by the sprouting of new vessels. The steps in the process, and the major signals involved, are illustrated. The newly formed vessel joins up with other vessels (not shown) to form the new vascular bed.

-When there is any factor or injure stimulates the angiogenic factors:

- Notching (notch signaling) in which the pericytes will be opened up and the endothelial cell will be proliferating and stimulated to make a sprout (sprouting: the endothelial cells are very active and extend outside)

pericyte detachment affected by a certain factor (*angiopoietin factor*) then the leading tip (cell) Notching or sprouting from the endothelial cells

-the major factor which is responsible for this process is the VEGF (vascular endothelial growth factor)

-The basement membrane must be destroyed by the metalloproteinases (the enzymes which are responsible for degradation of the basement membrane) before this notching process starts

- this will continue on this side and if the same changes happening in the nearby capillary or blood vessel the process continues until there is ***extensive complex interaction*** between the *growth factors* released from this process and the *extracellular matrix* leading to the elongation of the vascular stock(it's like a branch of a tree) and then this process will continue where the pericyte will attach to the nearby pericyte from the other end and the basement membranes will be connected and the endothelial cells will be connected and before this final nice neat and clean thing happens a lot of remodeling process happens

Summary

1- sprouting (notch signaling) induced by the VEGF
2- pericytes detachment by angiopoietin
3- basement membrane destroyed by metalloproteinases which are stimulated by multiple growth factors
4- extracellular matrix and multiple growth factor interactions continues the process with elongation of the pericytes
5- extension of the basement membrane
6- extension of the endothelial pericytes and then epithelial cells
7- at the end after the remodeling a new capillary is formed

- if you multiply this by a thousand in like two centimeters square this is what we call the basics of granulation tissue formation where angiogenesis is an important step for that

Activation of fibroblast and deposition of matrix

so after the initial process of granulation tissue formation then comes the important role of the matrix cells and the matrix protein and the major(center) of this process are the fibroblasts

the fibroblasts also are very critical in the formation of reparative scar tissue at the end.

- 2 STEPS:

- Migrations and proliferation of fibroblasts

we need fibroblasts to migrate and proliferate in the tissue in the area of tissue injury so there are multiple growth factors which will stimulate the migration and then proliferation of fibroblasts , we need mesenchymal cells to come to the site of injury and then proliferate

- Deposition of ECM proteins by these cells (the activated fibroblasts)

- **Need cytokines and GFs: PDGF, FGF-2, TGF-ß**

these two steps again similar to any other inflammatory and reparative process needs multiple chemical mediators of repair or cytokines and growth factors, platelet-derived growth factors(PDGF) ,fibroblast growth factor number two(FGF-2) and then, the major and most important fibrogenic or scar-forming mediator in repair which is transforming growth factor beta (TGF-ß)

- **Fibroblasts and myofibroblasts help lay down collagen to close the gap**

myofibroblast is a fibroblast which slightly deviated and became slightly differentiated toward a muscle and have some contractile muscle functions

they always help lay down collagen to close up the gap at the end collagen will be the major protein deposited in the scar formation at the end of repair by granulation tissue formation

- TGF-ß is the most important (very important)

Remodeling of connective tissue

- It is needed to make the scar strong and contract it

because the initial scar formation which is composed of young fibroblasts and young matrix usually is not strong enough and additional injury additional trauma will destroy the healing process and will cause sometimes(especially after surgery) dehiscence so before we for example remove the sutures after surgery we have to make sure that the scar tissue is strong enough and it has a contractile force to protect the continuity of the superficial mucosal surface and this is done by remodeling of the connective tissue (an active process requiring multiple chemical mediators of inflammation including mainly multiple growth factors)

- Cross linking of collagen

- Switching type III to type I collagen

the initial collagen which is laid down is not a strong collagen it is mainly collagen type 3 later on collagen type 3 will be switched and transformed into type 1 collagen which is stronger by crosslinking and by a remodeling process

- Degradation of collagen by Matrix Metalloproteinases (MMPs) and balanced by their inhibitors (TIMPs)

(the matrix metalloproteinases are enzymes specifically designed to repair and digest some of the extra collagen and transform collagen type 3 to type 1)

those metalloproteinases are good and needed in a certain time in a certain phase of this remodeling process but we don't want these MMPs to continue and destroy the basic collagen structure so they are balanced by the presence of their inhibitors and the name of these inhibitors are called **TIMPs tissue inhibitors of metalloproteinases**

-this is the balance which we require in the remodeling process so that we don't need more damage to what we have previously built in the scar tissue.

graduation tissue vs mature scar

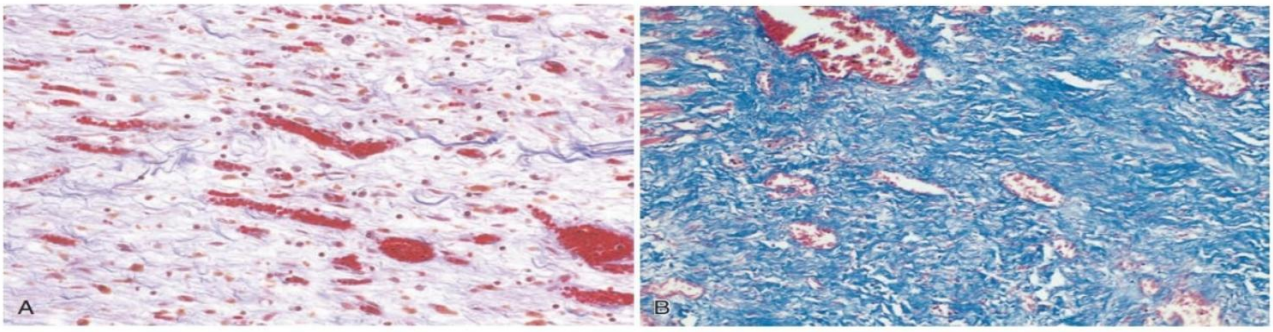

Fig. 3.26 (A) Granulation tissue showing numerous blood vessels, edema, and a loose extracellular matrix containing occasional inflammatory cells. Collagen is stained blue by the trichrome stain; minimal mature collagen can be seen at this point. (B) Trichrome stain of mature scar, showing dense collagen (stained blue) and scattered vascular channels.

young granulation tissue

H&E stain

each one of those is a blood vessel or young capillary very active angiogenetic process

this is not going to be strong enough to withstand any more tissue damage or pressure this granulation tissue should be transformed in the late phases of repair cross-linking type 3 to type 1 collagen to very strong scar tissue

the number of blood vessels is much more

the number of mature scar tissue is very minimal

Mature scar

trichrome stain (special stain which we use to highlight the scar tissue which is formed collagen type one predominantly and this is the blue color is the amount of scar tissue removed)

full of the **collagen type one** which is strong enough and difficult to separate

less blood vessels

more mature scar tissue

SUMMARY

REPAIR BY SCAR FORMATION

- Repair occurs by deposition of connective tissue and scar formation if the injured tissue is not capable of regeneration or if the structural framework is damaged and cannot support regeneration.
- The main steps in repair by scarring are clot formation, inflammation, angiogenesis and formation of granulation tissue, migration and proliferation of fibroblasts, collagen synthesis, and connective tissue remodeling.
- Macrophages are critical for orchestrating the repair process, by eliminating offending agents and producing cytokines and growth factors that stimulate the proliferation of the cell types involved in repair.
- TGF-β is a potent fibrogenic agent; ECM deposition depends on the balance among fibrogenic agents, matrix metalloproteinases (MMPs) that digest ECM, and the tissue inhibitors of MMPs (TIMPs).


www.namesWriter.com
تم بحمد الله