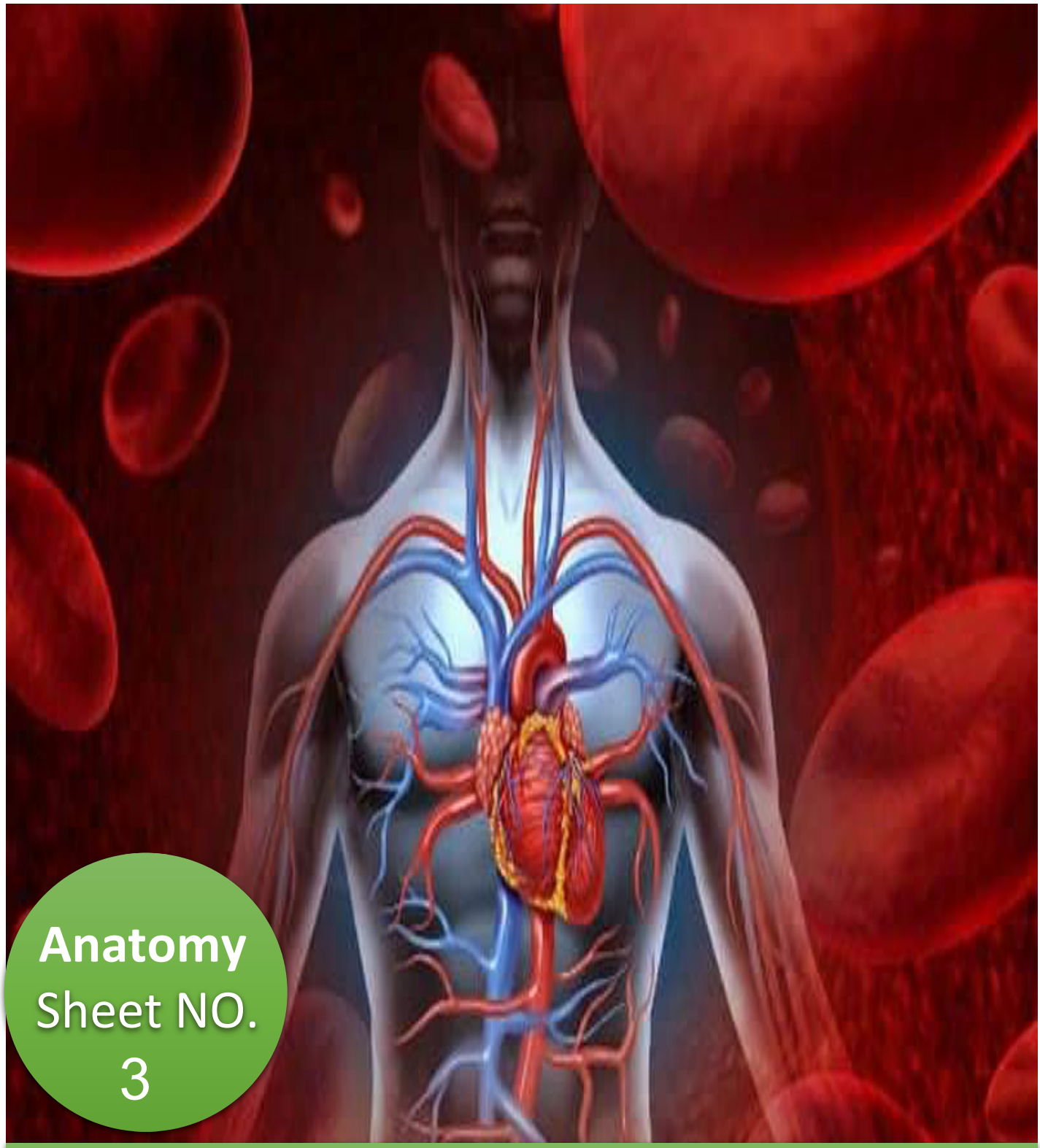

# Anatomy
## Sheet NO. 3

**Writer** Lana Raymoony & Hiba Mbaideen

**Scientific correction** **Hiba Mbaideen & Lana Raymoony**

**Grammatical correction** **Hiba mbaideen & Lana raymoony**

**Doctor Darwish badran**

## Overview about what we discussed in the previous lecture

(Heart & the pericardium)

This image shows the position of the heart,

which is in the middle of your chest, slightly to the left.

Note that: the apex of the heart is near the left nipple

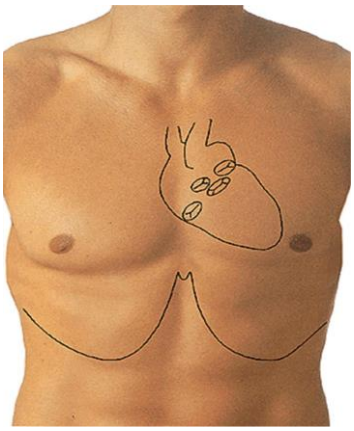

The heart is surrounded by a Conical

fibro - serous sac

**Outer tough layer**

**That contains**

**Collagen fiber type1**

**(fibrous pericardium)**

**Inner layer (serous pericardium) divides into**

1-Parietal pericardium
2- Visceral pericardium

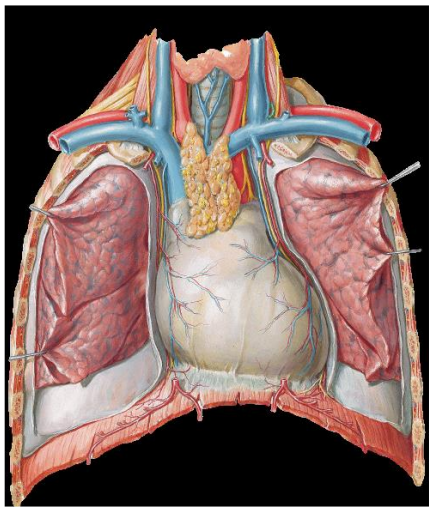

***parietal pericardium: lines the fibrous pericardium from inside

Visceral pericardium: A-it is in direct contact with the heart substance

B-It gives the glistening appearance for the heart in fresh state

***There is a space between them called the ***pericardial space, that allows the heart to slip without producing neither pain nor sound***

***``In human beings there are no spaces, instead we have potential spaces which are the areas with low resistance that allow materials to accumulate in ''***

## ANTERIORLY

1- Lungs should be retracted away from the anterior surface of the heart . In addition to , lung and pleura separate the heart from thymus which is in the anterior mediastinum

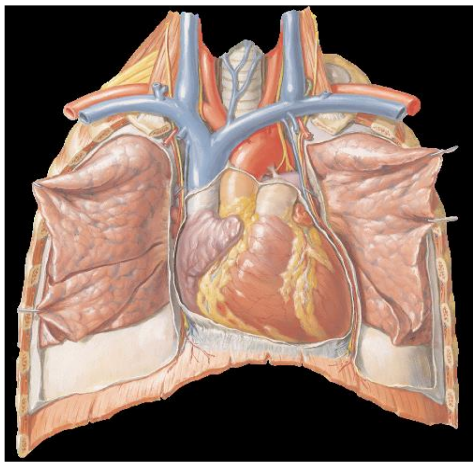

2-Body of the sternum
3-Cartilage of 2-6 ribs

# Posteriorly:

1-Bronchi

2-Esophagus

3-Esophageal plexus(nerve fibers rest on the esophagus)

4-Descending aorta (what arises from the heart is the ascending aorta , after that the arch is formed , then we have

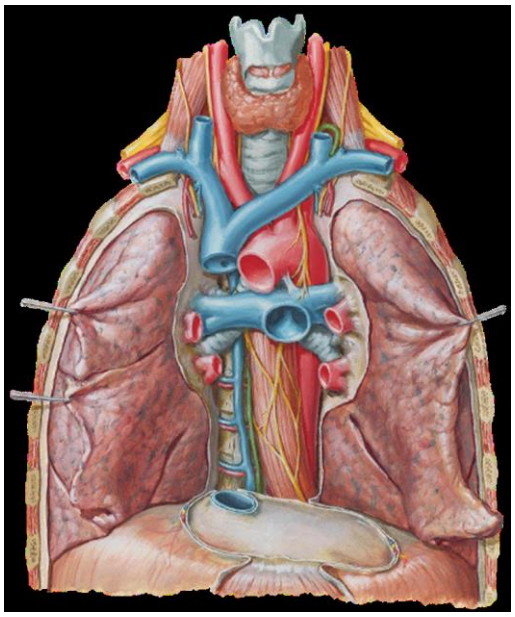

the descending aorta at T4 level where the arch ends )

5-T5-T8 vertebra

## Inferiorly:

Diaphragm

## Laterally:

1-Pleura and mediastinal surfaces of both lungs( السطح المواجه للقلب من الرئتين)

2-Phrenic nerves and musculophrenic vessels

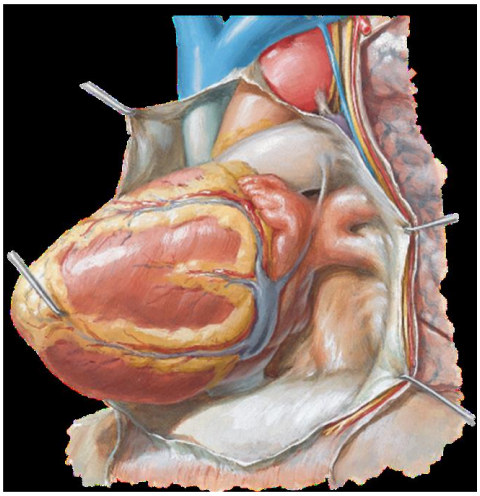

Quick notes

keep in mind that:

*clinically the transverse sinus is much more important than the oblique sinus

**the heart has an apex and base which is the area opposite to the apex not to the diaphragm ( not the area resting on the diaphragm)

*** right border extends from SVC to IVC and the right atrium between them

**** left border is exclusively formed by left ventricle

***** coronary sulcus = coronary groove :the beginning of the blood supply for the heart

The upper border of the heart is the line (horizontally) between

Upper border of the 3rd costal cartilage &
Lower border of the 2nd costal cartilage

The lower border is the line (horizontally) between

6th costal cartilage 3cm from 5th left intercostal space

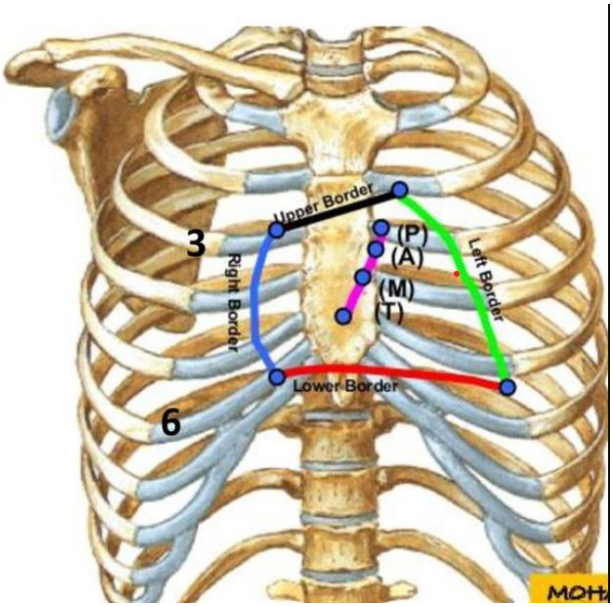


The **chordae tendineae** : tendinous strands in the heart thar prevent the prolapse of the cusps of the valves in opposite direction

**sinoatrial node (SA node)**: it is in the right atrium under the open of SVC which is the pacemaker of the heart

The end of the rapid revision

CONDUCTING SYSTEM OF HEART

The details of the arteries' distribution are not important

((what is written in orange color is from the slides))

# Coronary Arteries

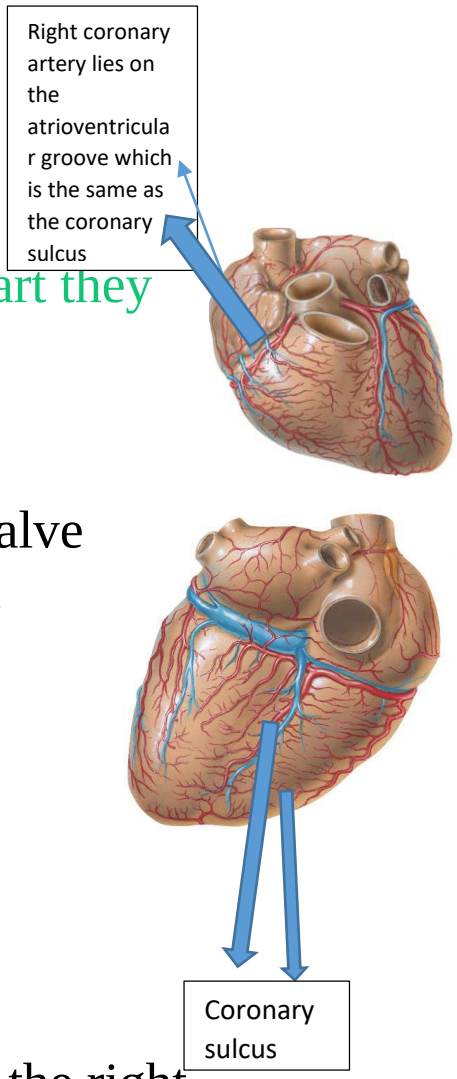


Coronary arteries make 2 loops around the heart they lies on what is called the coronary sulcus

Coronary artery originates from the coronary orifice that is made by the cusp of the aortic valve so mainly coronary artery originates from that orifice then it lies down on the sulcus

The heart is supplied by two coronary arteries (right & left) which arise from the ascending aorta.

NOTE THAT

We have 3 cusps but 2 coronary ostia one for the right CA and the other for the left one (ostia=orifice)

**The right coronary artery lies on the right coronary sulcus and then it rolls in the opposite direction to anastomose with the branches of the left coronary artery

Images for demonstrating

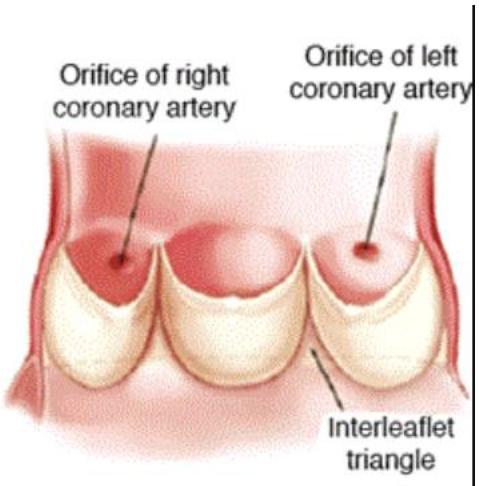


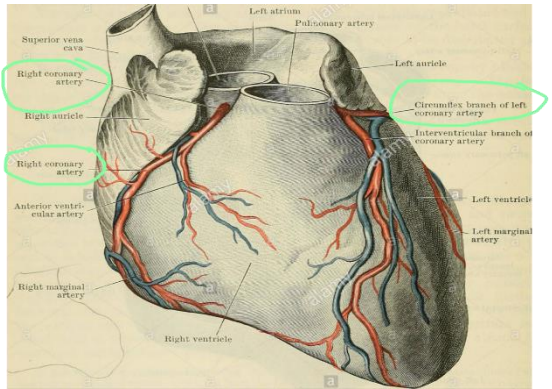

The right coronary artery arises from the anterior aortic sinus, while the left coronary artery arises from the left posterior aortic sinus.

Coronary arteries give branches that surround the heart and supply all the muscle tissue of the heart (cardiac muscle fibers).

Usually, one of the CA is more dominant than the other …e.g.; almost all males have a more dominant left CA than the right CA , which means that most of the blood supply comes from the left CA

# Left Main Coronary Artery

- Extends from the ostium in the left sinus of valsalva to its bifurcation into the left anterior descending & left circumflex branches.
- Usual length 10-20 mm.
- Normally courses between the pulmonary trunk & the left atrial appendage to reach the left A-V groove, occasionally an additional artery originates from the left main & called ramus intermedius & courses parallel to the diagonals.

The final branches of the CA are **end arteries**, they don't anastomose with anything else …for that , if they are blocked the area that is supplied by them will die and **myocardial infraction** (no blood flow ) (احدى أشكال الجلطات التي قد تصيب الانسان )will happen

One of the coronary artery goes into spasm sometimes (تضيّق), that means that we still have blood flow but below the normal level (not like the infarction) and that leads to ***angina pectoris*** ( ذبحة صدرية)

So if we have no blood supply that leads to → infarction

But if we have low rate of blood supply it leads to → angina

So what is the symptoms of angina in general ??

- If someone does an action that need more effort from the heart , there will not be an enough blood to do that, and for that he will feel the pain of the angina ….eg for such actions : a heavy meal or walking
- If this symptoms appear during rest , which is a serious problem , you have to interfere immediately by cardiac catheterization

**cardiac catheterization: we connect catheter to ascending aorta then we inject a dye that enters the distribution of the coronary arteries and this dye shows you the place of the block …now in this case either you dilate a balloon there or install a stent (شبكية)**
**to ensure the dilation of the artery**

***Left Anterior Descending Artery (LAD)+ Circumflex Artery +Right Coronary Artery (RCA) + Anastomosis between the Coronary Arteries**
**The doctor skipped them**

# Left Anterior Descending Artery (LAD)

Courses along the anterior interventricular sulcus to the apex of the heart.
In most cases the LAD extends around the apex into the posterior interventricular sulcus supplying the apical portion of both right & left ventricles.
Supplies branches to the right ventricular free wall, to the septum & to the left ventricular free wall.

# Circumflex Artery

From the LM coronary artery, with its initial course medial to the base of the left atrial appendage.
Large branch in the proximal segment called atrial circumflex artery, coursing around the left atrium.
The ventricular branches are called Obtuse marginal arteries, supply the obtuse margin of the heart.

In hearts with left dominance or codominance these obtuse marginal arteries supply the inferior surface of the LV.
Variations in the origin & length of the CX are common.

## Right Coronary Artery (RCA)

Usually single artery.
Courses down the right A-V groove.
Branches:

•1. Conus artery.
•2. Branches to the anterior right ventricular free wall
.•3. Anterior right atrial artery ** this artery commonly gives the SA nodal artery.
•4. Lateral right atrial artery (usually injured in oblique right atriotomy).
•5. Acute marginal artery in the region of the acute margin of the heart, which courses most of the way to the apex of the heart
.•6. A-V nodal artery at the crux.

## Anastomosis between the Coronary Arteries

Anastomosis exist at the arteriolar level between the terminations of the right & left coronary arteries in the atrioventricular groove & between the interventricular branches & conus branches.
These anastomosis on the surface of the heart are insignificant.

# Cardiac Veins…1/4

- Most of the cardiac veins accompany the coronary arteries.
- Most of the cardiac veins end in the coronary sinus, which opens into the right atrium.
- The heart is similar to the brain in the manner that the veins are not named similar to the accompanying arteries.

# Cardiac Veins ..2/4

The veins of the heart fall into three groups:

1. Venae cordis minimae(Thebesian veins): found within the myocardium and drain directly into the heart chamber.
2. Anterior cardiac veins (2-3 in number): run on the sternocostal surface and drain into the right atrium
3. Coronary sinus:

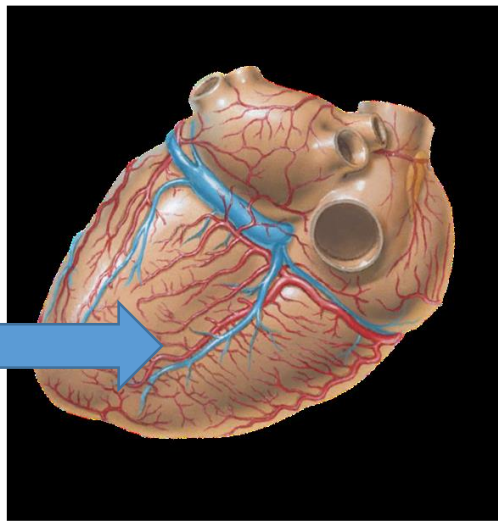


•Lies in the posterior part of the AV groove.

•Covered by a thin layer of myocardium.

It is a wide-bored vessel, about 3 cm long.

•It opens in the right atrium

*** Venae cordis minimae : it opens in the same chamber it drains blood from (left ventricle ) which has the oxygenated blood , then it pour the deoxygenated blood there

**That's why the oxygen saturation level in our bodies is not 100% instead , it is 97/98 %**

# Cardiac Veins ..3/4

The veins of the heart fall into three groups:

1. Venae cordis minimae: found within the myocardium and drain directly into the heart chamber.
2. Anterior cardiac veins (2-3 in number): run on the sternocostal surface and drain into the right atrium
3. Coronary sinus:

•Great cardiac vein•Middle cardiac vein•Small cardiac vein•Post vein of the LV•Oblique vein of the LA

# Cardiac veins 4/4

# Tributaries of the coronary sinus:

•Great cardiac vein
•Middle cardiac vein
•Small cardiac vein
•Post vein of the LV
•Oblique vein of the left atrium

# PLEURA AND LUNGS

***We have three serous cavities in the body including :

1. Pericardium
2. Pleura
3. peritoneum

## Surface anatomy of pleura

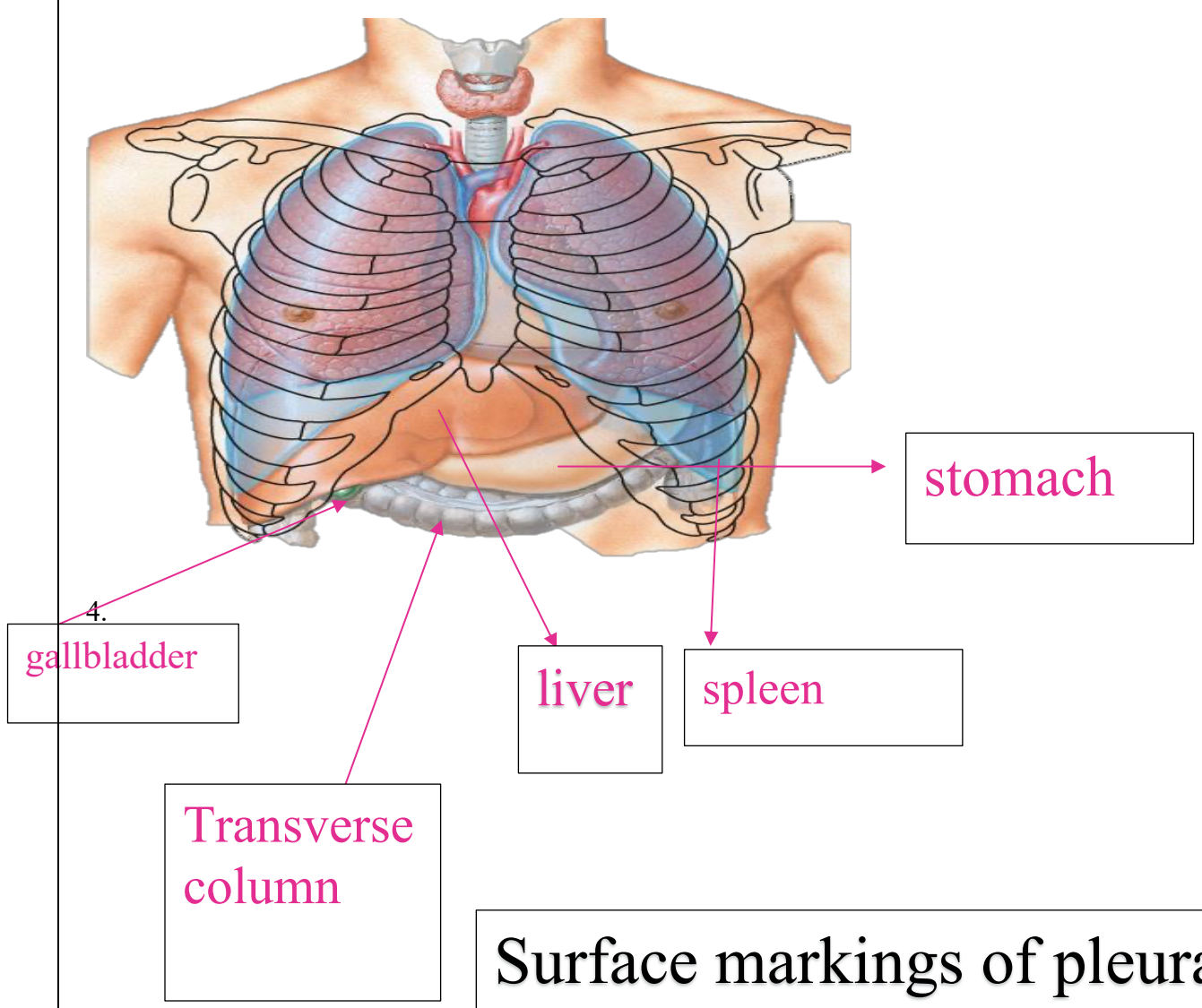


### Surface markings of pleura which surrounds the lungs

anterior margin:

1. At the junction between the medial one third of clavicle and the lateral two thirds we put the first mark.
2. At the sternoclavicular joint we put the second mark . ( the arch between first two marks is one inch above the clavicle) ** this arch makes the cervical pleura which is the apex of lung
3. Descending vertically until reaching the 6th costal cartilage

Inferior margin :

4 .at the point of 6th rib we draw a curved line until reaching the 10th rib ( the 8th rib is at the same level of mid clavicular line, 10th rib at the level of mid axillary line)
and finally reaching the last thoracic spine

Posterior margin :
along the vertebral column from the apex to the inferior margin.
*this was for the right pleura

Now for the left one : the cervical part a (the apex) is the same as the right .
The anterior margin extends from sternoclavicular joint to the level of 4th costal cartilage
Then a deviation will take place ( at the level of 6th rib) about one inch to the left until reaching the 8th rib. ( this deviation is actually presented to accumulate the heart on the left side) and is called the cardiac notch.
Then completes its way as the right pleura did.

**Notice that:
The even numbers of ribs are for pleural markings while the spleen takes numbers (1,3,5,7,9,11) (1,3,5 in inches are dimensions of the spleen) (7) is the weight of the spleen in ounces ( 200-210) gm.
(9-10-11) are the ribs where the spleen is located.

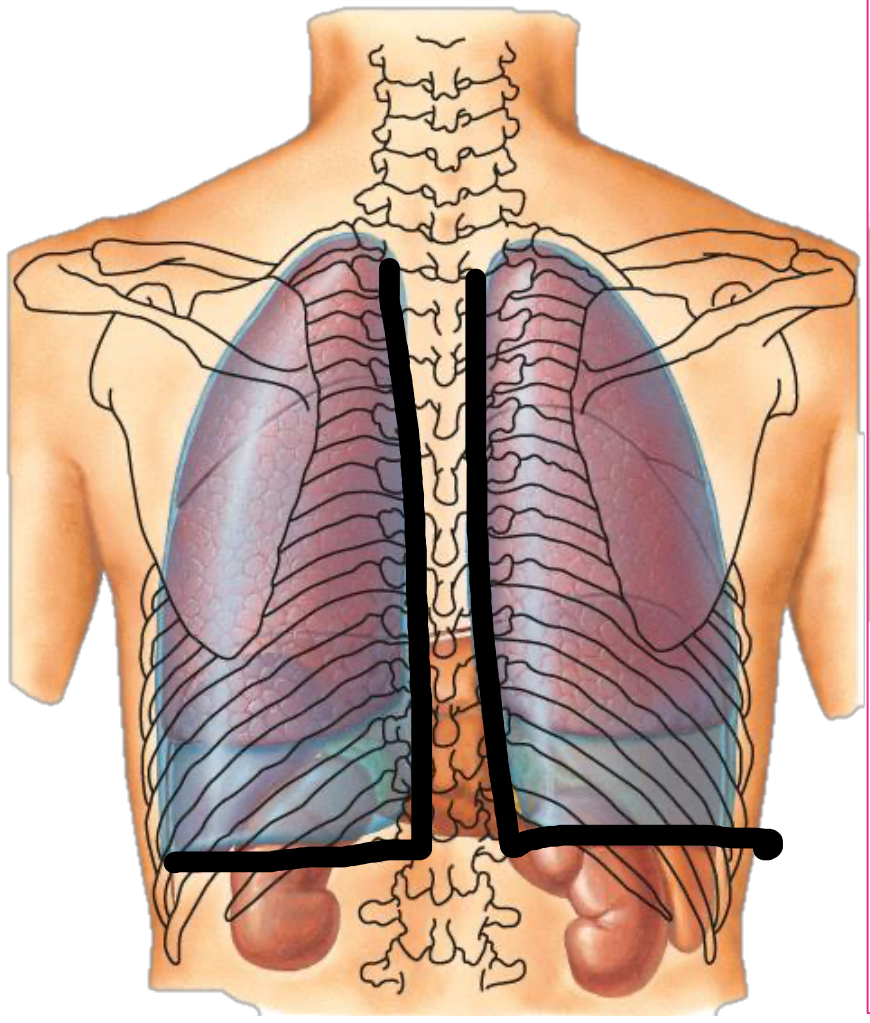

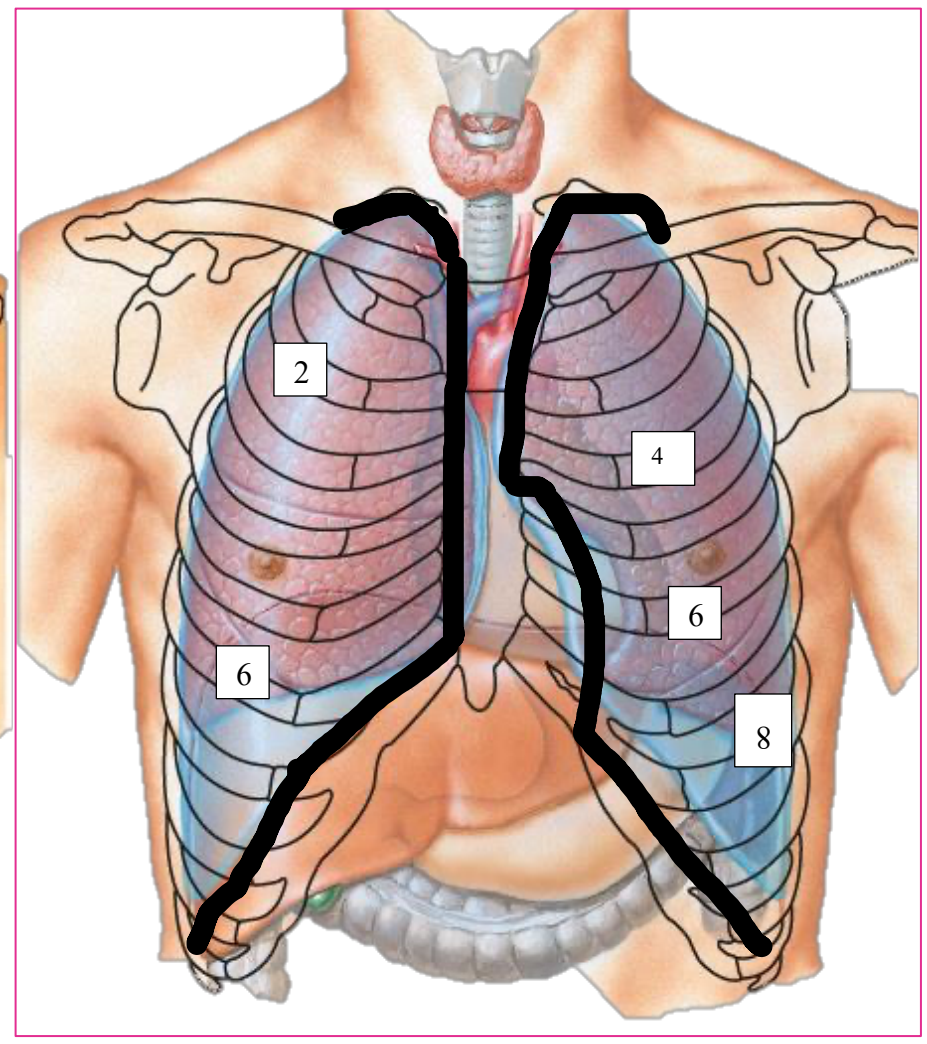


# SURFACE ANATOMY OF THE LUNG

The lungs are located inside the pleura and the pleura is formed by two layers:

1. The outer (parietal) which lines the inside of the chest wall (the thoracic cavity).
2. Inner (visceral) which wraps around the lungs.

Between these layers there is a space called pleural space

1. The apex, the anterior , the posterior borders are nearly the same as pleura but slightly away from the median plane.
2. Inferior margin as the pleura but more horizontal and reaches the $10^{th}$ thoracic spine.

**NOTE :
the lungs are normally at the level of $8^{th}$ thoracic spine but when taking a deep breath (full inspiration) the lungs get wider and its surface markings would be the same as the pleura.

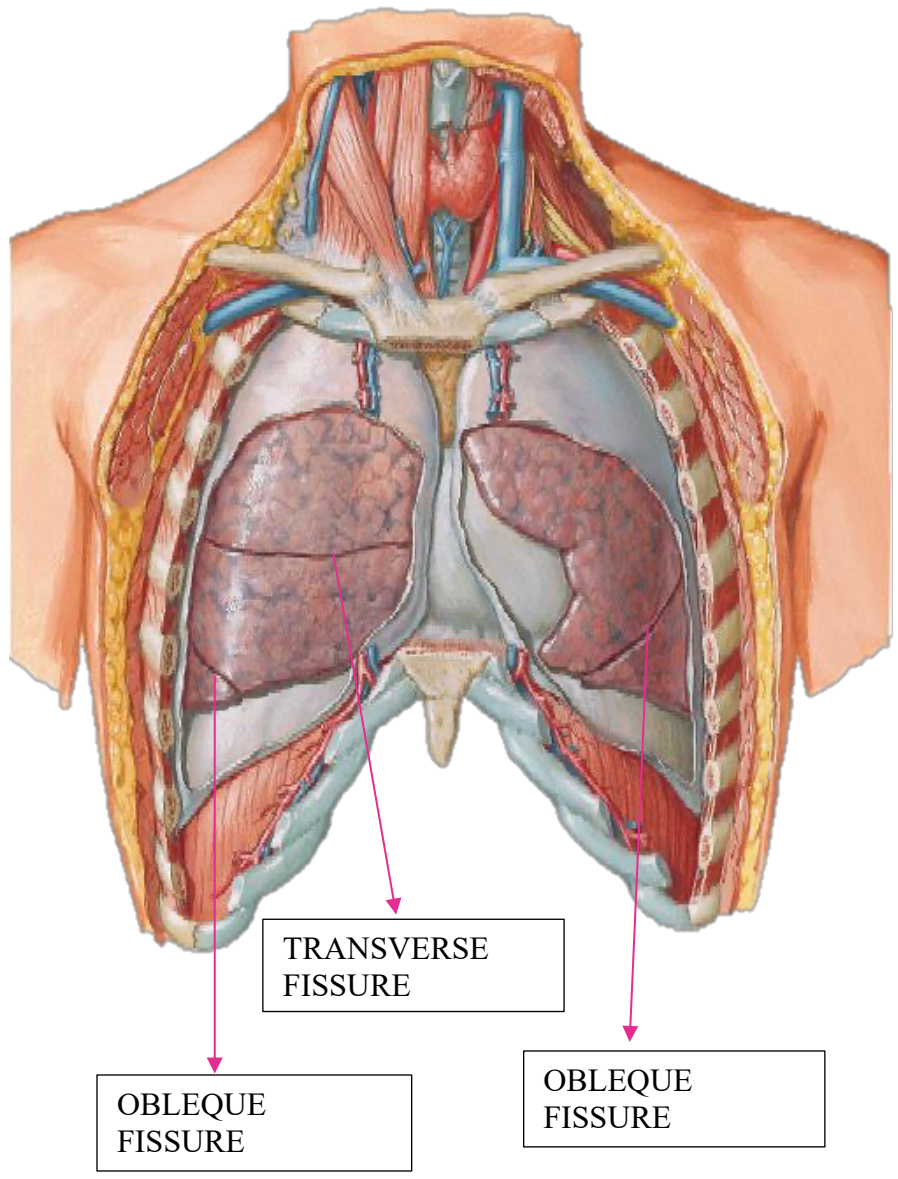


In the right lung there are two fissures (transverse and and oblique) while in the left lung there is only oblique fissure
The fissures in the right lung separate it into 3 lobes 1.the superior lobe ( superior to transverse) 2. The middle lobe (inferior to the transverse) 3. The inferior lobe (inferior to the oblique)
The fissures in the left separate it into two lobes, superior and inferior.
oblique fissure : line extending from 3rd thoracic spine, obliquely ending at 6th costal cartilage.
transverse fissure ; ( only right): line extending from 4th right costal cartelage to meet the oblique.

The doctor focused on this question: where do the fluids accumulate more in the left plural cavity or in the right?
In fact the fluids accumulate in both sides but way more in the right pleural cavity because of the area of low resistance (low pressure) in the right pleura due to the veinous structures, while the left side contains high pressure structures like the aorta, descending arch of aorta and other main arteries that reduces the chance for fluids to accumulate there.

Now define the pleura
A closed serous sac which surrounds the lung and invaginated from its medial side by the root of lung
Define the plural cavity
5-10 ml of serous fluid that separates the parietal layer from the visceral layer of pleura, lubricates both surfaces and allow the lungs to move free during respiration.

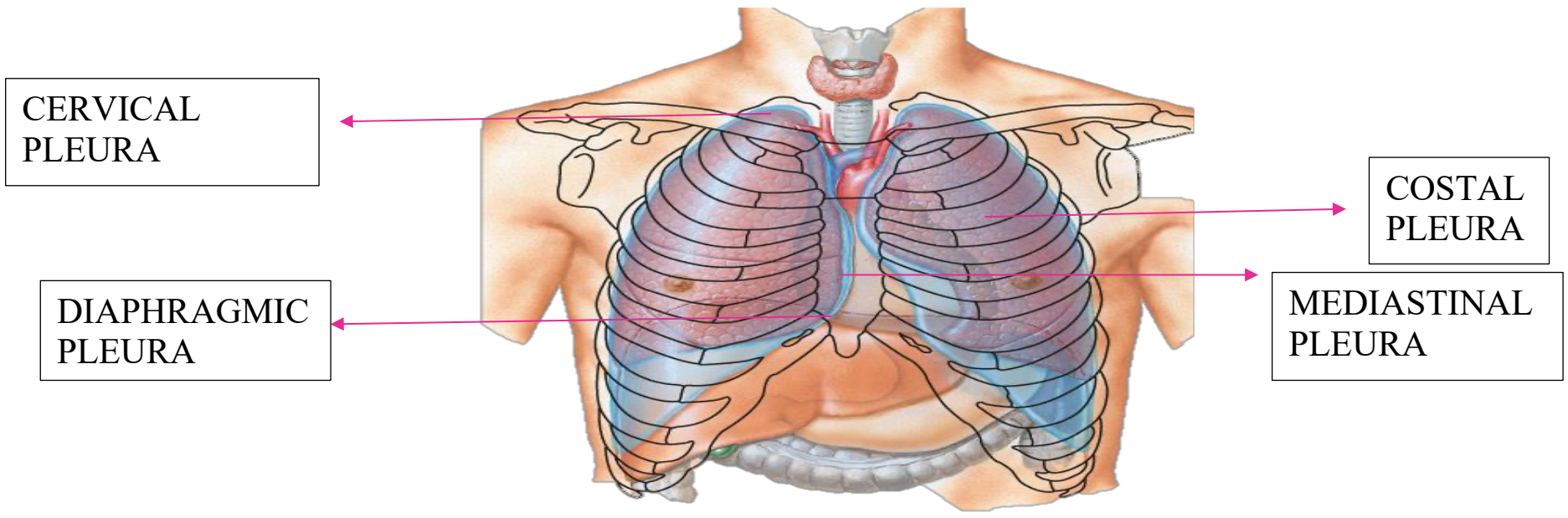


# PARTS OF PARIETAL PLEURA

## 1. CERVICAL PLUERA

Part of parietal pleura which protrudes up into the root of neck.
** there is a chance that hitting the cervical pleura (at the level of the neck) may cause a serios problem in the thorax.

## 2. COSTAL PLEURA

Lines inner surface of ribs, costal cartilages, intercostal muscles and back of sternum.
** innervation: intercostal nerves ( first intercostal space is supplied by first intercostal nerve an so on)

## 3. DIAPHRAGMATIC PLEURA

Covers the upper surface of diaphragm
Innervated: 1. Medially by the phrenic nerves 2. Peripherally by the lower 6 intercostal nerves
( note that the pleura and the lungs are above the diaphragm while the liver is directly under the diaphragm so any intervention (تدخل جراحي) in liver might hit the pleura)

## 4. MEDIASTINAL PLEURA

Covering mediastinal surface of lung ( facing the mediastinum)
** innervation: phrenic nerve

# VISCERAL PLEURA

Visceral pleura firmly covers all the lung ( the outer surfaces and extends into it fissures)

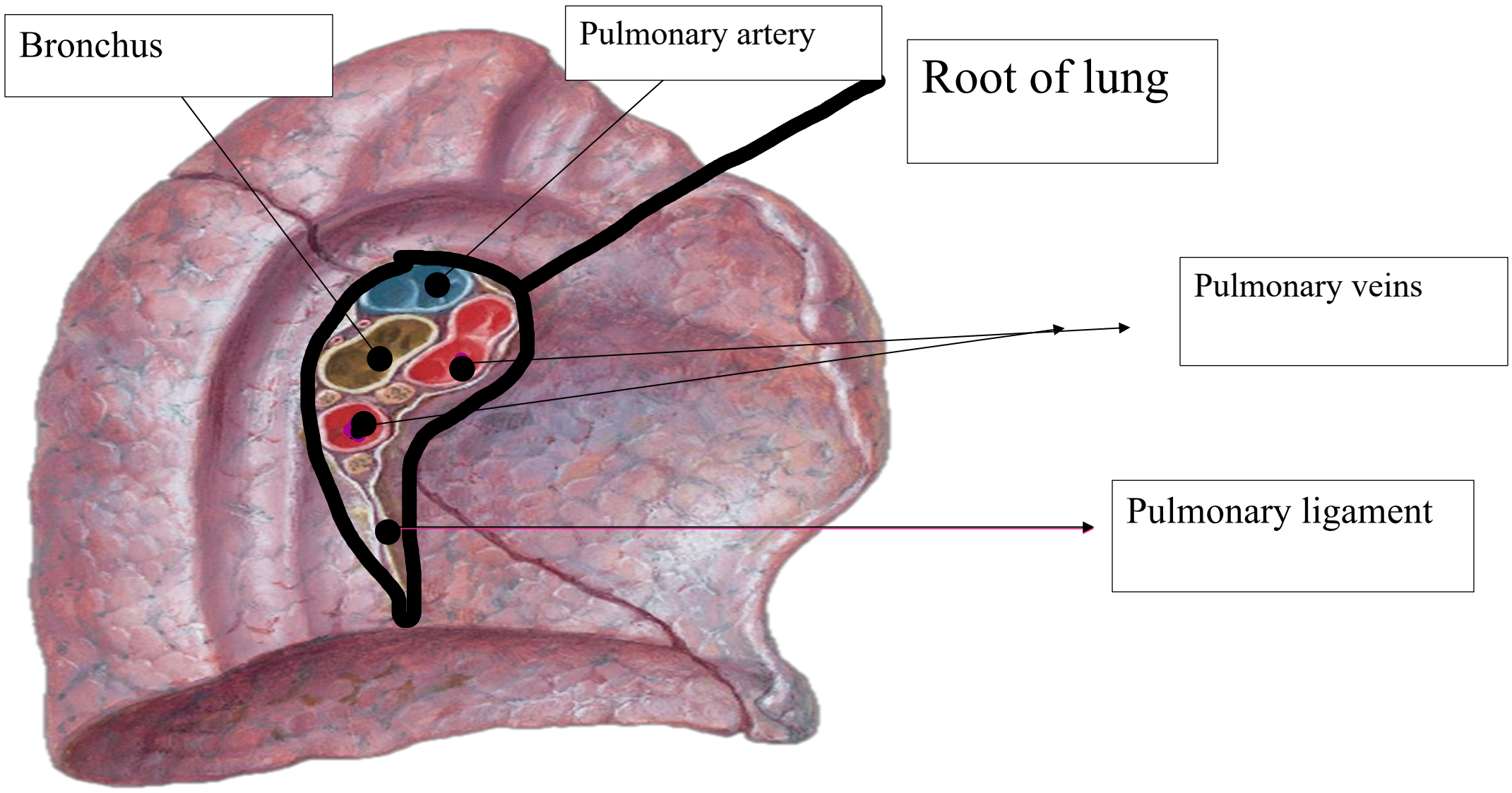


**NOTE : the pulmonary ligament is misnamed, its not pulmonary nor ligament ( pulmonary=(lung tissue) and its not lung tissue, its plural tissue, And ligament means dense regular connective tissue and in fact its not like this, its rather a visceral-parietal reflection surrounding the root of the lung

The reason behind the glossary appearance of the lung is existence of visceral pleura.

The parietal and visceral pleura are continuous to each other forming a tubular sheath (pleural cuff) that surrounds root of the lung (vessels, nerves, bronchi) in the hilum of the lung.

On the lower surface of the root of the lung pleural cuff hangs down as fold which is **(pulmonary ligament)**: a continuation of visceral and parietal pleura below the root of the lung. (important)

hilum of the lung : triangular section at the inner midpoint of each lung . It is the space where vessels and nerves pass from your bronchus to your lungs.

INNERVATION :

Sympathetic fibers from pulmonary plexus

# LUNGS

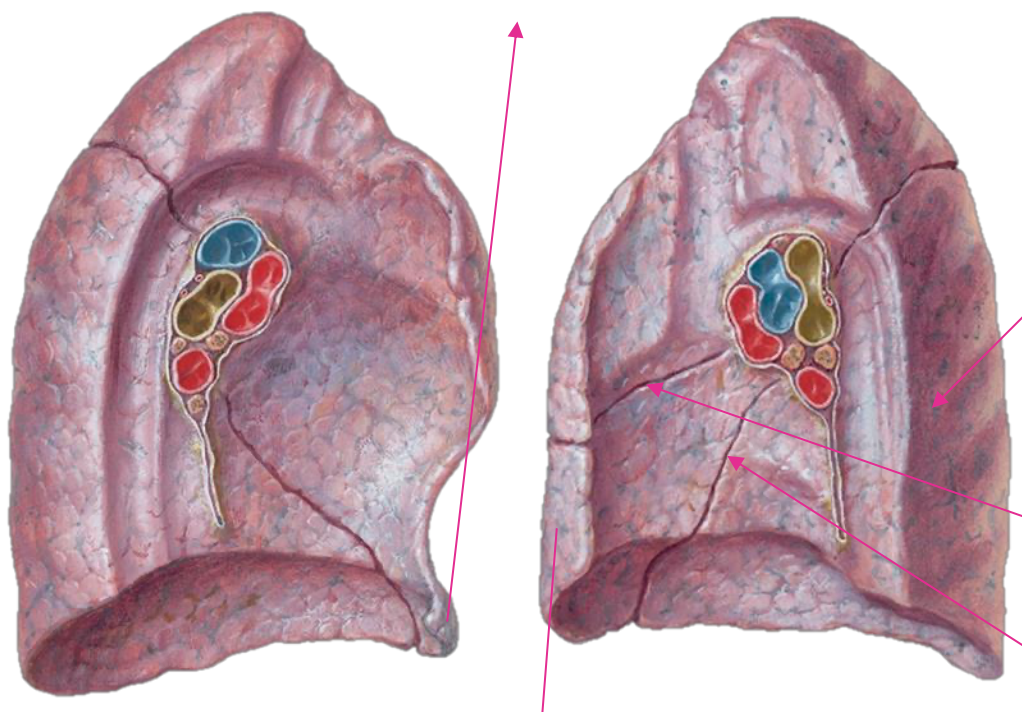


Anterior border: sharp, thin and overlaps the heart

Posterior border: rounded, thick and lies beside the vertebral column

NOTE: the anterior border of left lung presents a cardiac notch at the lower end (to accumulate the heart) and a thin projection called LINGULA below the cardiac notch.

If you take a look on the picture of the lungs above, you can see the markings of the ribs presented on its surface, but in the lab you can not see them because the formaldehyde makes the surface of the lungs looks puffier so you can't observe the rib markings.

** THE RIGHT LUNG IS SHORTER AND LARGER THAN THE LEFT ONE.

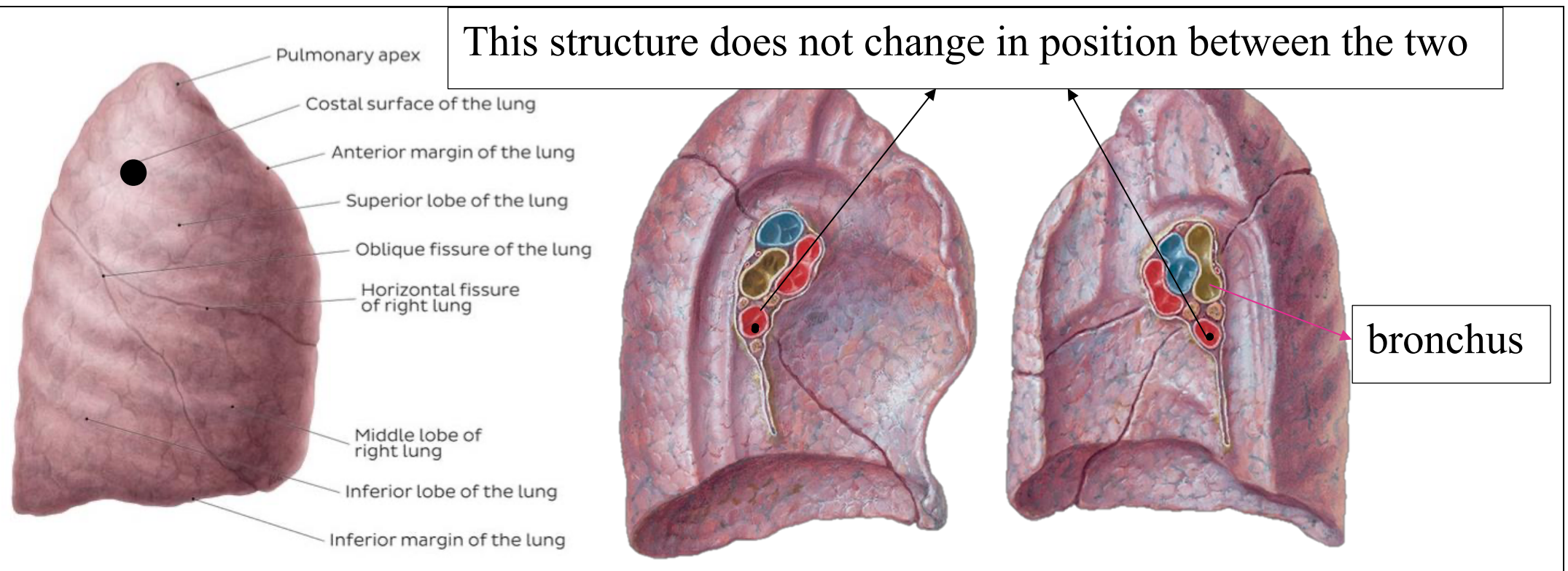


The order of the structures in the root of the lung is so important, it help us to distinguish between the right and left lungs, especially that its not rare to see the right lung contains four lobes and the left lung containing 3 lobes ( in some cases this might happen, but it has an embryological explanation that does not concern us now) In the right lung the bronchus has a different position from the left one ( in the right lung the bronchus located posteriorly to the pulmonary artery while in the left lung its located inferior to the pulmonary artery)

# SURFACES:

1. **Costal surface:** convex and covered by costal pleura (that we have mentioned above) which separates the lung from ribs, costal cartilages and intercostal muscles.
2. **Medial surface:** has two parts:

   ANTERIOR ( mediastinal part)

   Which contains: THE HILUM ( a depression in the middle in which bronchi, vessels and nerves forming the root of the lung)

   POSTERIOR ( vertebral part)

   Which is related to bodies of thoracic vertebrae, intervertebral discs, posterior intercostal vessels and sympathetic trunk.

# Quick overview:

- The lung is conical in shape ( مخروطية)
- Has apex, two surfaces: costal which borders the ribs (front and back), and mediastinal where lymphatic ,blood vessels and bronchi enters the lung at the helium.
- Apex ( the same as the pleural apex): into the root of the neck( one inch above the medial 1\3 of clavicle) covered by cervical pleura.
- Base( inferior = diaphragmatic surface) concave and rests on the diaphragm ( taking the shape of diaphragm).

THANK YOU