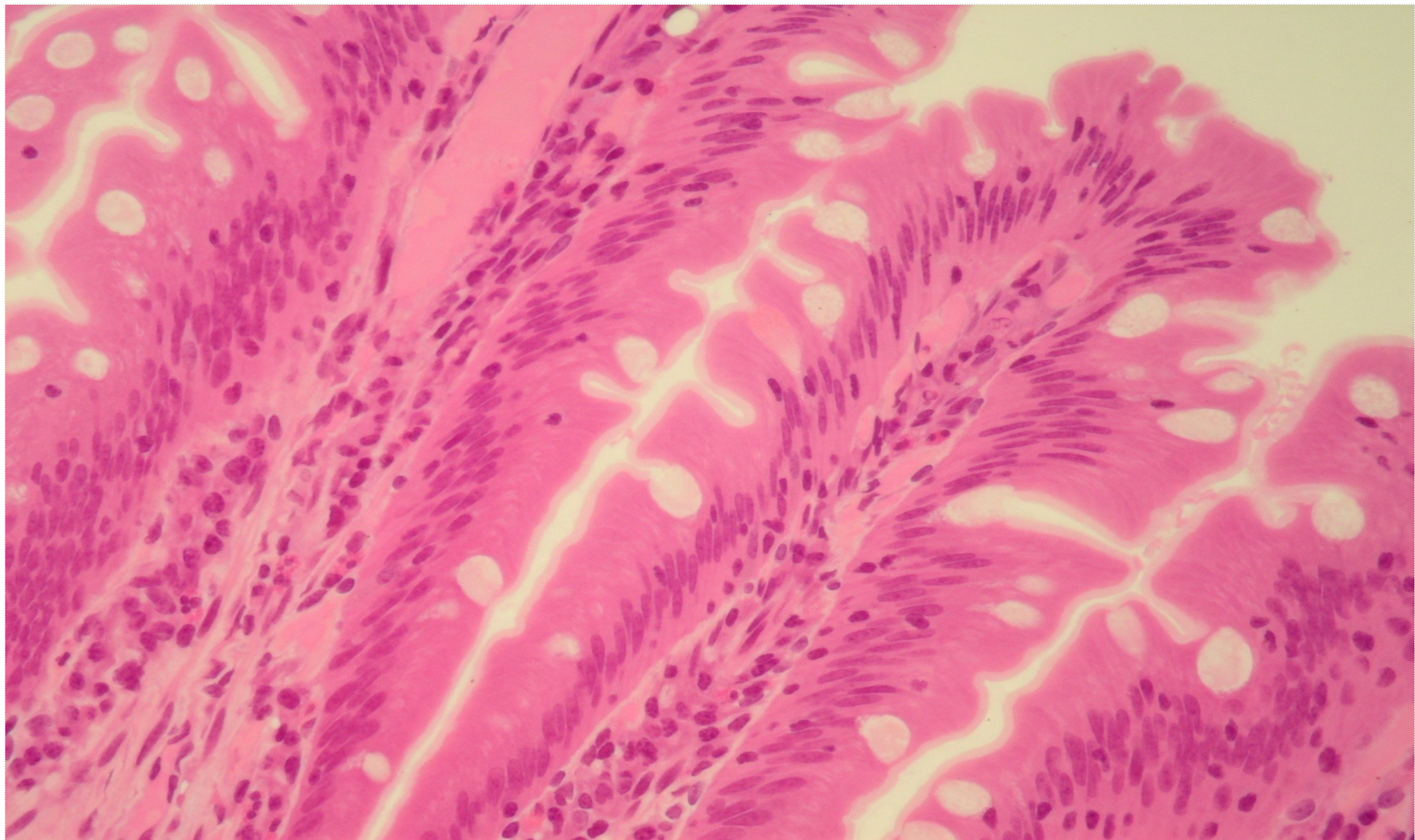
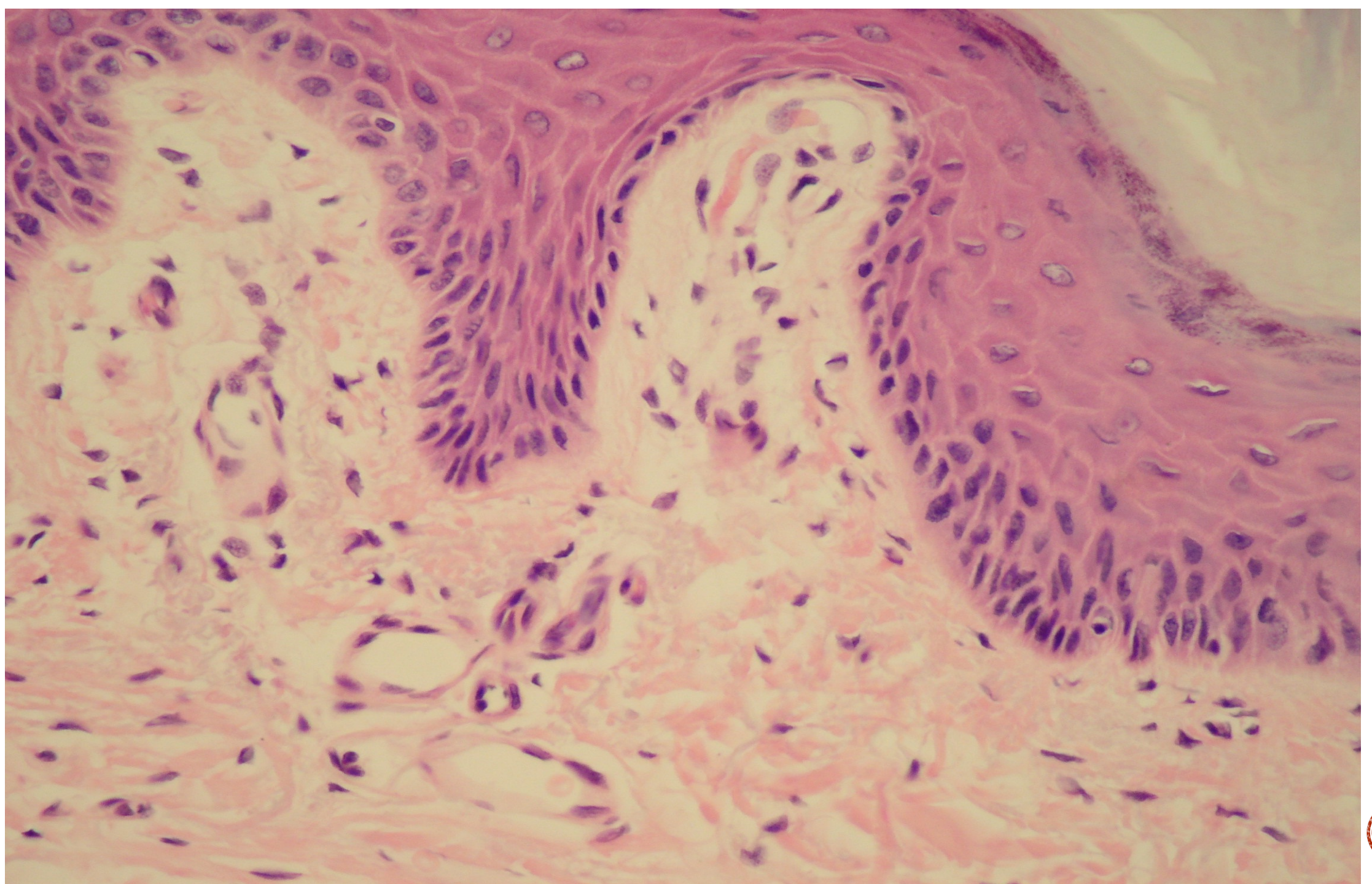


# CONNECTIVE TISSUE (CT) 1

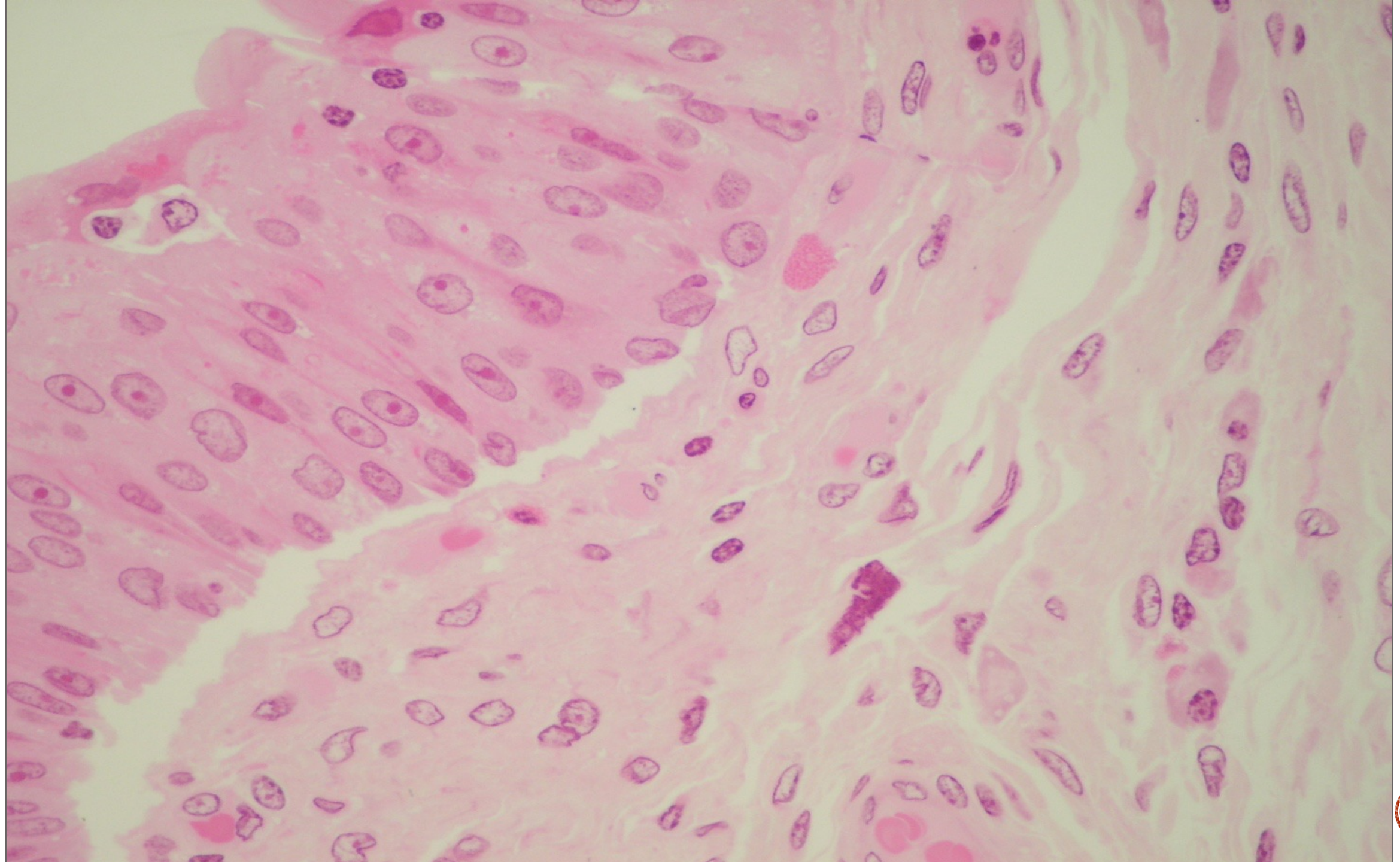






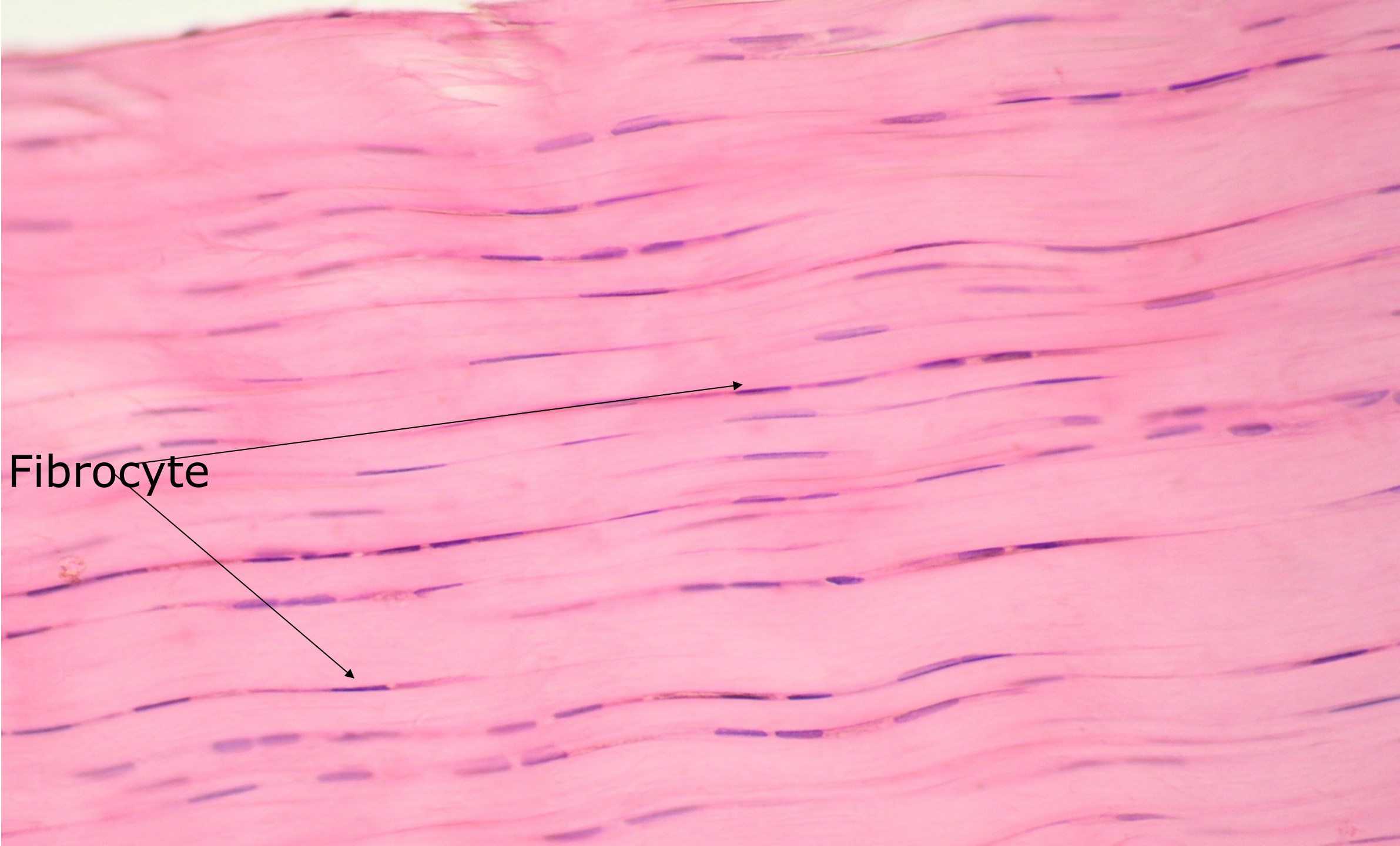




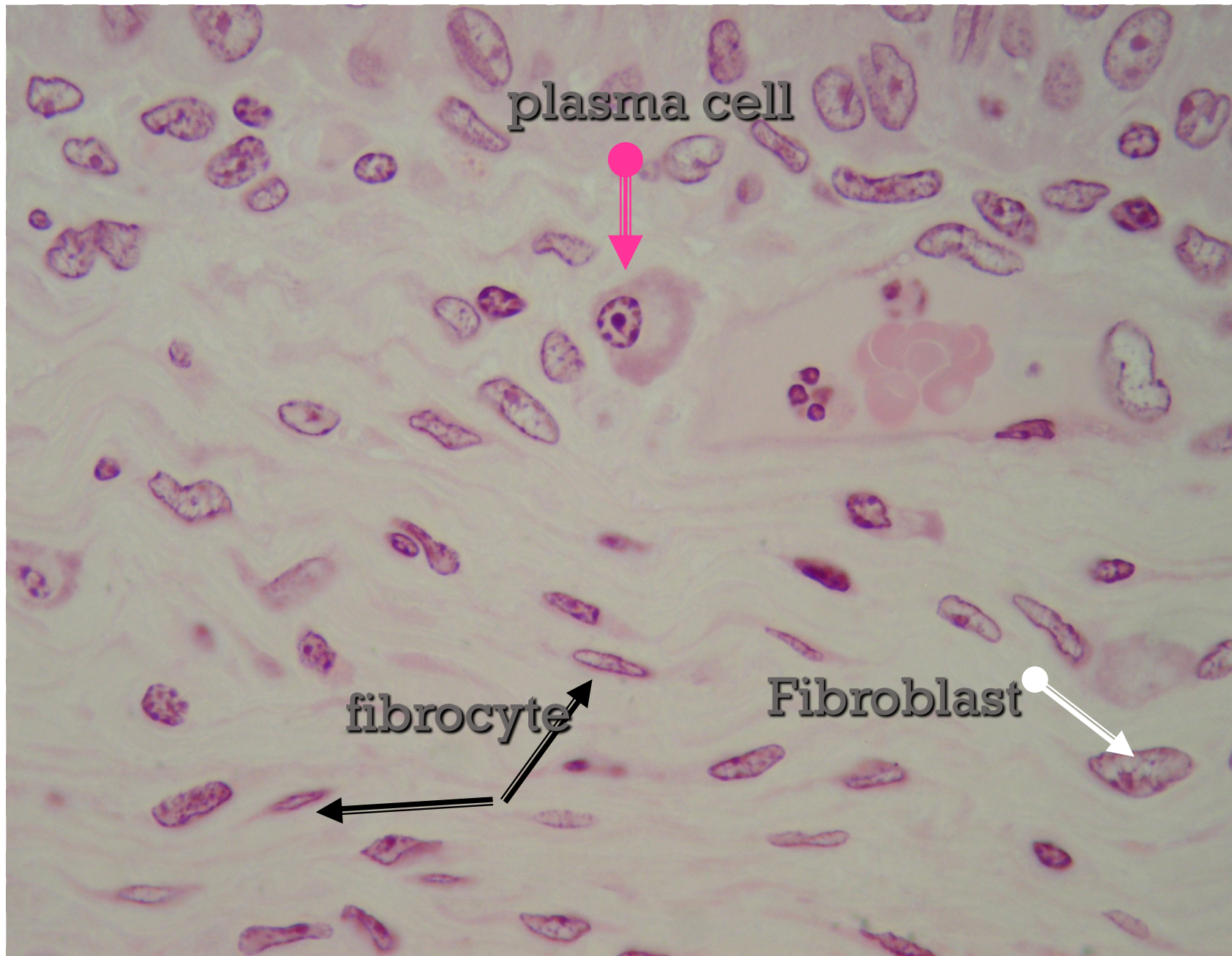




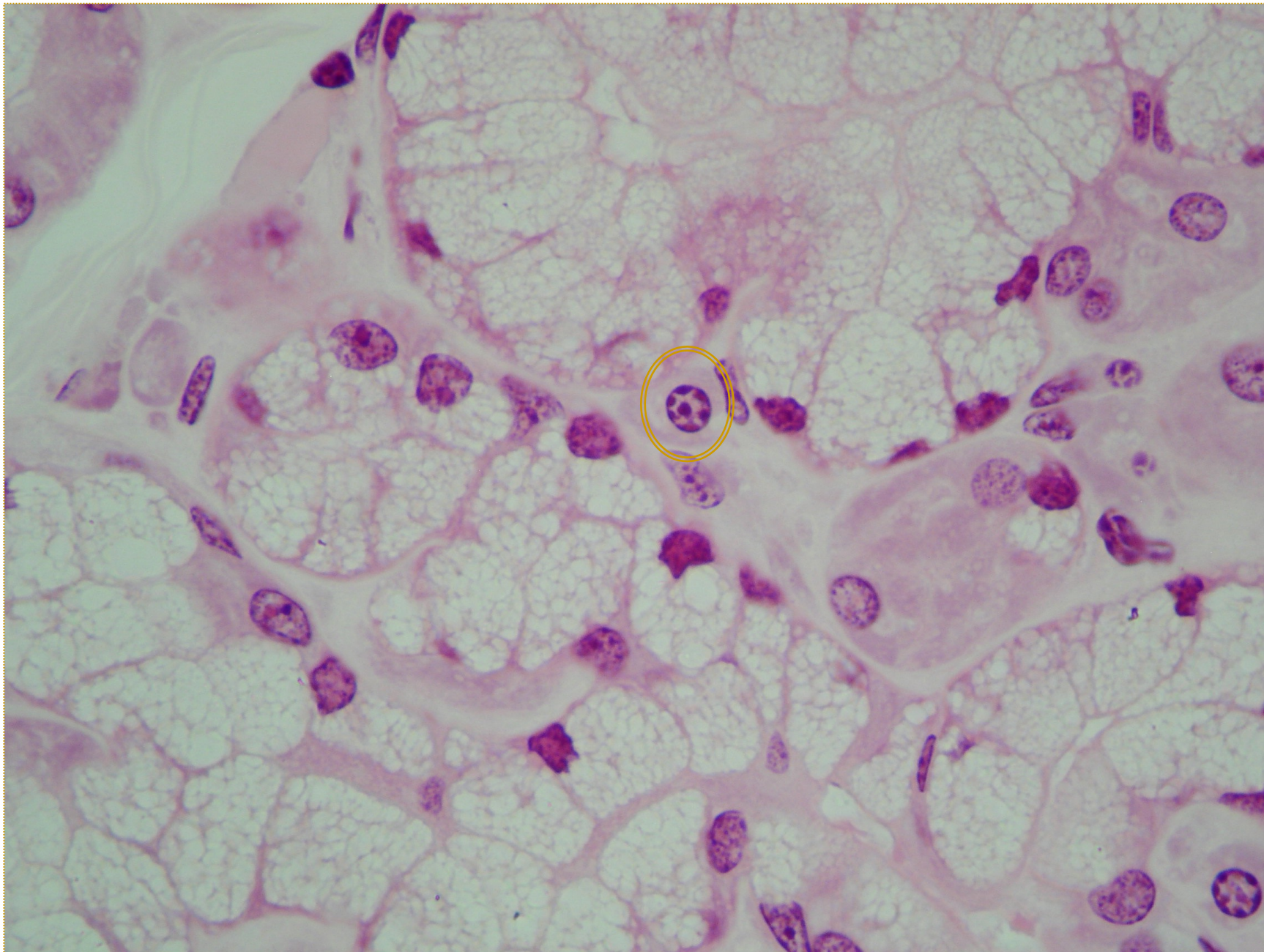
Fibrocyte





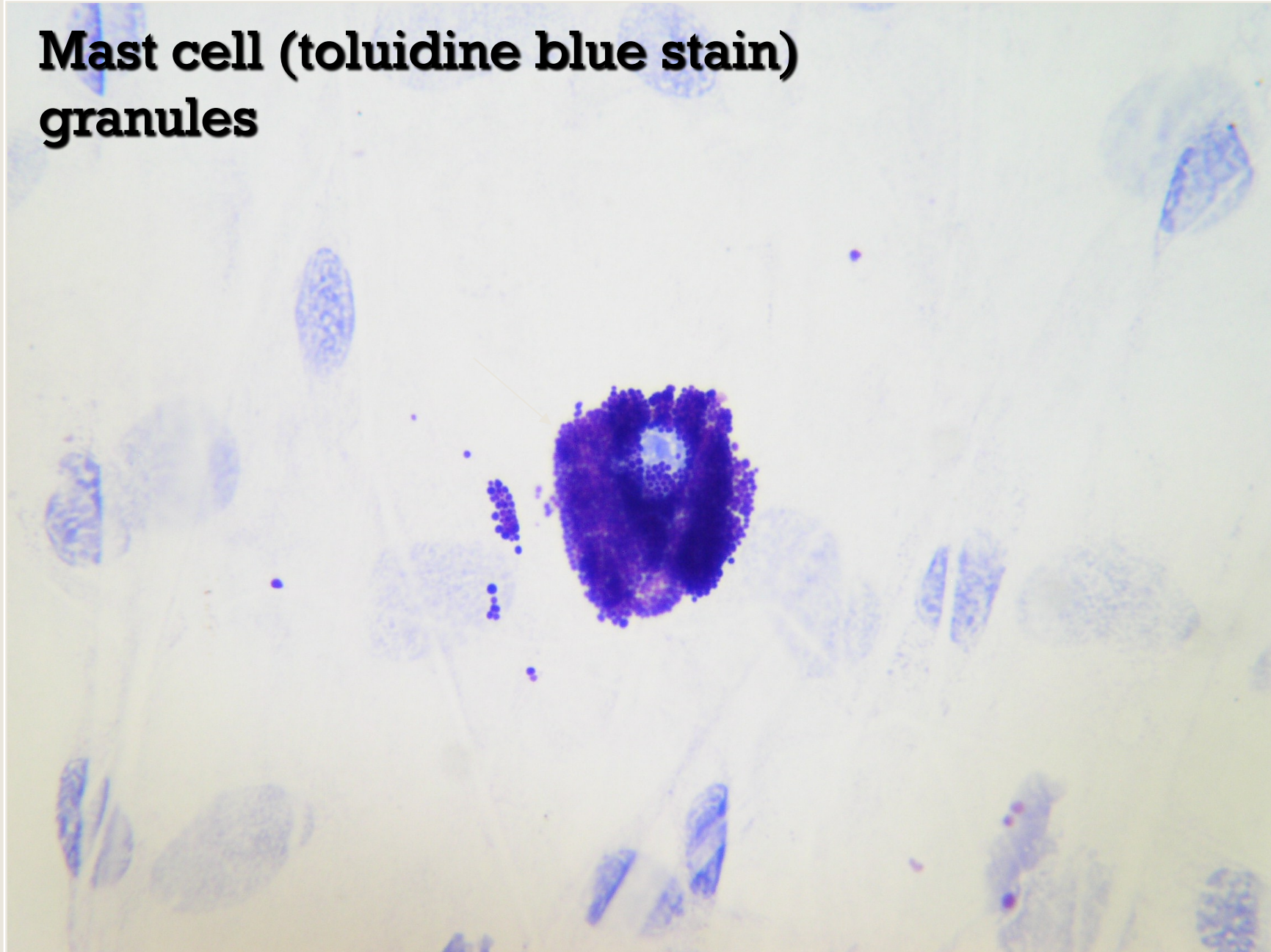






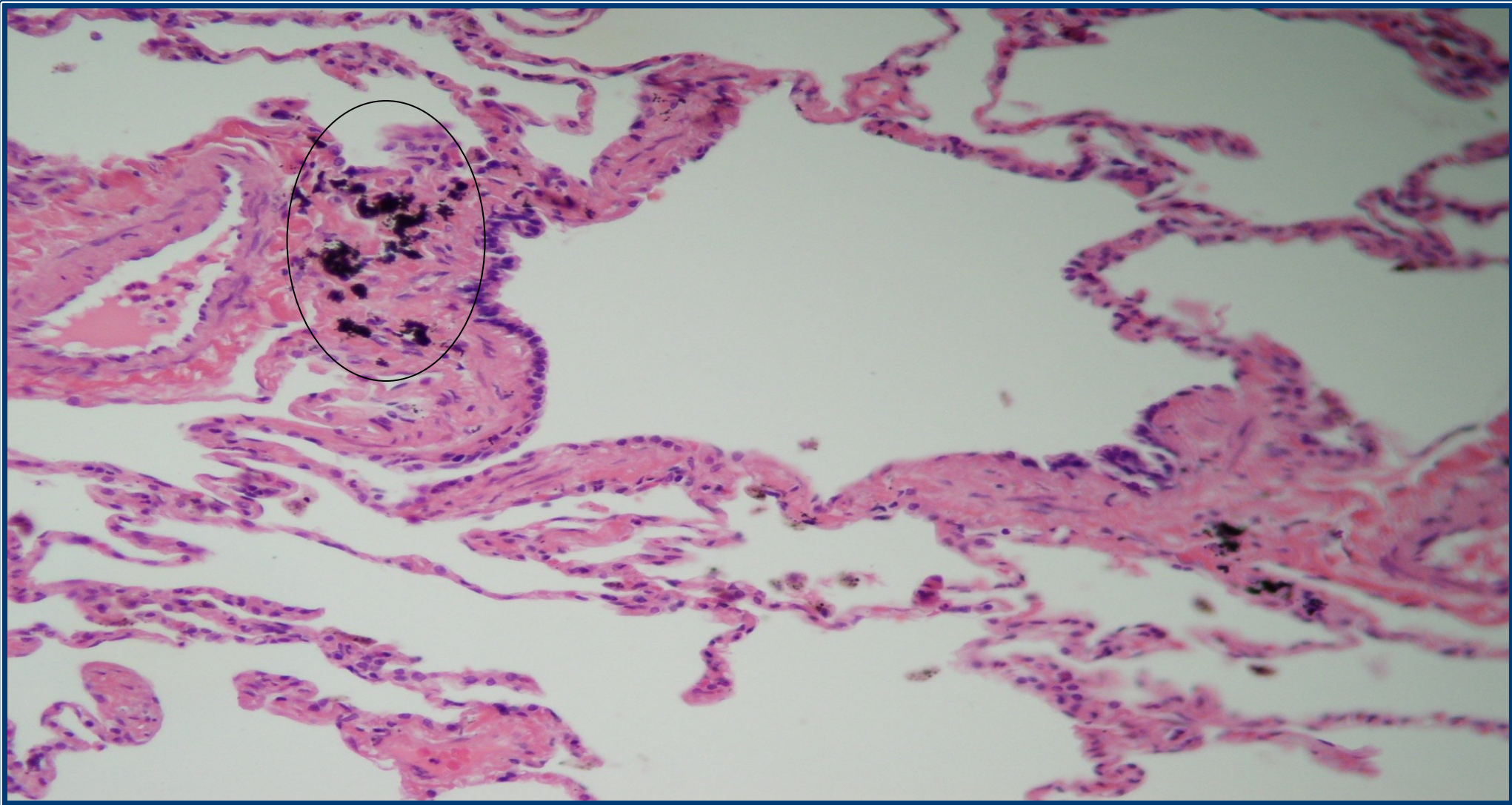


**Mast cell (toluidine blue stain)  
granules**





# LUNG TISSUE





# ALVEOLAR MACROPHAGE=DUST CELL

